Abstract 84° Congresso Nazionale della Società Italiana di Cardiologia

ARITMIE

A1: EFFECTS OF DIRECT IRRADIATION ON CARDIAC IMPIANTABLE ELECTRONIC DEVICES

Maria Giulia Bellicini (a), Gianmarco Arabia (a), Angelica Cersosimo (a), Manuel Cerini (a), Luca Bontempi (b), Andrea Dell'aquila (b), Emiliano Calvi (a), Marco Sciotta (a), Gianfranco Mitacchione (c), Antonio Curnis (a)
(a) UNIVERSITÀ DEGLI STUDI DI BRESCIA; (b) BOLOGNINI HOSPITAL-SERIATE; (c) LUIGI SACCO UNIVERSITY HOSPITAL-MILAN

Background. Implantable cardiac electronic devices (CIEDs) can be damaged during a radiotherapy cycle. Recent expert consensus, and all CIED manufacturers, recommend avoiding irradiation of devices with a cumulative dose that exceed 5 grays (Gy). In case of major doses, the eventualities expected by the device manufacturing companies are setup reset and/or sudden battery failure.
Aim of the study. In our prospective study we tested the effects of direct irradiation on CIEDs with different radiation doses 5-10Gy.
Methods. 124 CIEDs of Medronic, Abbott, Biotronik, Boston Scientific, Sorin were collected during system upgrading or lead extraction procedures and considered for the study in case of residual battery capacity of at least 80%. Depending by CIED type, pacing mode was configured in VVIR, VDDR or DDDR, and biventricular stimulation was activated, if present. Electrical therapies were setup with a pre-determined configuration. All devices were singularly placed in a 30 cm × 30cm plastic bowl containing 2 Lt of deionized water that was placed over 5cm Rockwool to simulate the backscatter and irradiated by a linear accelerator (Elekta Synergy®) with a dose of 5 Gy or 10 Gy.
Results. No significant differences in battery drainage were observed after irradiation respect to baseline in 5 Gy or in 10 Gy group (7.8±3.1 vs. 7.4±2.1 [years] battery longevity, p=0.693; 7.6±3.1 vs. 7.3±2.1 [years] battery longevity, p=0.677, respectively). All CIEDS saved the baseline program setting, without device reset events.
Conclusions. Our data confirm that direct irradiation of CIEDs at 5Gy is safe. Direct irradiation up to 10Gy appears to be equally safe with regard to the risk of electrical reset of CIEDs and battery depletion.

A2: SPONTANEOUS BRUGADA TYPE 1 ECG PATTERN IN PREVIOUS DRUG-INDUCED PATIENTS: A SYSTEMATIC REVIEW AND META-ANALYSIS

Luca Barca (c), Andrea Saglietto (b), Henry Xhakupi (c), Giuseppe Mascia (a), Rocco Vergallo (a, c), Gianluca Anastasia (c), Paolo Di Donna (a), Italo Porto (a, c)
(a) CARDIOVASCULAR DISEASE UNIT, IRCCS SAN MARTINO POLYCLINIC HOSPITAL, GENOA, ITALY; (b) DIVISION OF CARDIOLOGY, "CITTÀ DELLA SALUTE E DELLA SCIENZA DI TORINO" HOSPITAL, DEPARTMENT IF MEDICAL SCIENCES, UNIVERSITY OF TURIN, ITALY; (c) DEPARTMENT OF INTERNAL MEDICINE, UNIVERSITY OF GENOA, 16132 GENOA, ITALY

Introduction. Brugada syndrome (BrS) is diagnosed and its risk is stratified if a spontaneous or drug-induced type 1 electrocardiographic (ECG) pattern is present. However, spontaneous Type-1 Brugada pattern may be underestimated at diagnosis due to the fluctuations of the Brugada ECG pattern and some drug-induced BrS type 1 patients may develop the spontaneous pattern during their life. Few data are available regarding data on the incidence of spontaneous Type-1 Brugada pattern during follow-up of patients initially diagnosed with drug-induced type 1 BrS. Based on this information, the present research has the aim to conduct a systematic review of the literature.
Methods. A comprehensive literature search was performed in PubMed and Embase from inception to March 2023. A total of 10 studies with a total of 858 drug-induced BrS type 1patients were included. The studies included cohort studies that reported the finding of a spontaneous Brugada type 1 ECG pattern in previous drug-induced BrS type 1 patients.
Results. During a mean follow-up of 60 months, 159 of the 858 drug-induced BrS type 1 patients developed a spontaneous type 1 BrS pattern. The overall annual incidence of drug-induced BrS type 1 patients progressing to spontaneous BrS type 1 was 5 (95% confidence interval [CI]: 3-9) per 100 person-years. When we divided the studies according to active pattern ECG detection during follow-up, defined as repeated Holter ECGs or at least an ECG every 3 months, versus studies that did not perform an active search, the annual incidence was 16 (95% CI: 11-23) and 3 (95% CI: 2-4) per 100 person-years, respectively.
Conclusions. In the population considered, the annual incidence of conversion to a spontaneous BrS type 1 pattern is 5 per 100 person-year. Active search for the ECG pattern is necessary for better risk stratification.

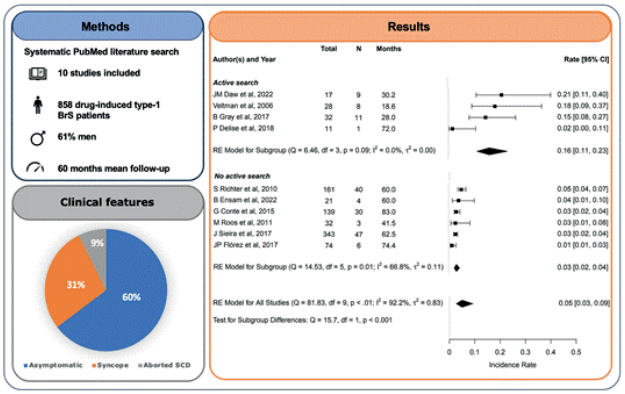

A3: SUPRAVENTRICULAR TACHYARRHYTHMIAS AND DEMORALIZATION SYNDROME: A JOINT ROLE FOR CARDIOLOGISTS AND PSYCHIATRISTS

Annalisa Maraone (b), Paolo Severino (a), Andrea D´amato (a), Tommaso Accinni (a), Alessio Bonucci (b), Agostino Piro (a), Marco Valerio Mariani (a), Carlo Lavalle (a), Massimo Pasquini (b), Carmine Dario Vizza (a)
(a) DEPARTMENT OF CLINICAL, INTERNAL, ANESTHESIOLOGY AND CARDIOVASCULAR SCIENCES, SAPIENZA UNIVERSITY OF ROME, VIALE DEL POLICLINICO 155, 00161 ROME, ITALY; (b) DEPARTMENT OF HUMAN NEUROSCIENCES, SAPIENZA UNIVERSITY OF ROME, ROME, ITALY

Introduction. Anxiety and depressive symptoms seem to be bidirectionally associated with supraventricular tachyarrhythmias. Demoralization syndrome (DS) is little investigate in chronic heart diseases. DS has been recently considered as a clinically distinct syndrome from depression, being characterized by several peculiarities: i) distress and subjective incompetence; ii) loss of meaning and purpose in life; iii) cognitive attitudes of pessimism, and hopelessness/helplessness; iv) sense of being trapped and personal failure; v) associated features of lack of perceived social support. The aim of this study is to assess the prevalence of DS in ambulatory and hospitalized subject affected by supraventricular tachyarrhythmias.
Methods. Consecutive patients were recruited from inpatient and outpatient clinic of Department of Clinical, Internal, Anesthesiology and Cardiovascular Sciences, Sapienza University of Rome. Inclusion criteria were: i) diagnosis of supraventricular arrhythmias according to ESC guidelines; ii) age ≥18 years; iii) written and signed informed consent. Psychiatric evaluation included structured interview based on DSM 5 criteria performed by well-trained psychiatrist and validated self-report questionaries to assess depressive symptoms and DS, respectively 9-item Patient Health Questionnaire (PHQ-9) and Demoralization Scale. Linear correlation between demoralization total score and cardiological variables has been performed.
Results. 110 adult patients were enrolled in the study. 40 (36.4%) patients were female and mean age was 76 (±10.7). Looking at the cardiological diagnosis, 52 patients (47.3%) were diagnosed with paroxysmal atrial fibrillation, 8 (7.3%) with persistent atrial fibrillation, 29 (26.4%) with permanent atrial fibrillation, and 21 (19.1%) received a diagnosis of other supraventricular tachyarrhythmias. Regarding the Kissane demoralization index, the total mean score for the entire recruited group was 22.7 (±11.9). Concerning the demoralization severity, 28 (25.5%) patients presented a clinically relevant DS. Of these, 14 (12.7%) had a moderate DS and 14 (12.7%) presented a severe DS. Among more severe patients 53.6% received a diagnosis of paroxysmal atrial fibrillation, 3.6% a diagnosis of persistent atrial fibrillation, 21.4% a diagnosis of permanent atrial fibrillation, and 21.4% received a diagnosis of other supraventricular tachyarrhythmias. 85.7% of patients were hospitalized. Regarding the PHQ scale for the entire sample, 14 (12.7%) patients showed a moderate to severe degree of depression, 96 (77.3%) did not result having a clinically relevant depression experiencing none or mild symptoms. Examining the overlap between depressive and demoralization symptoms, we found that 42.9% of patients with an over-threshold demoralization syndrome showed moderate to severe depressive symptoms; conversely, 57.1% of these patients showed none to mild depressive symptoms.
Conclusions. These data confirmed the high prevalence of clinically relevant DS in patients with atrial tachyarrhythmias. In our sample, we

found 25,5% patients with a significant demoralization index. Notably, 57,1% of participants with significant DS shown none to mild depressive symptoms, a potential group of patients not diagnosed by a categorical diagnosis, underling the differences from depressive symptomatology and potentially a different kind of treatment.

A4: SILENT ATRIAL FIBRILLATION EPISODES IN REAL-WORLD ADULT PATIENTS UNDERGOING PROLONGED ECG HOLTER MONITORING: A REPORT FROM THE ANCE SAFARI STUDY

Francesca Campanella (a), Antonino Di Franco (c), Antonio Vittorio Panno (d), Marco Di Franco (d), Giuseppe Scaccianoce (d), Salvatore M. Petrina (d), Rosa Rizzo (d), Pietro Pugliatti (d), Antonino Giannola (d), Serena Magro (d), Leonardo Costa (d), Calogero Di Maio (d), Vincenzo Manfrè (d), Santi Mangano (d), Marco Miano (d), Antonino Recupero (d), Luigi Scarnato (d), Giuseppe Brancatelli (d), Patrizia Grimaldi (d), Francesco Magro (d), Vincenzo Sucato (b, e), Chiara Alaimo (b, e), Luca Di Fazio (b, e), Fabrizio Fortunato (b, e), Salvatore Milazzo (b, e), Gabriele Di Francesco (b, e), Chiara Tubiolo (b, e), Tania Sacco (b, e), Carmelo M. Farruggia (b, e), Giuseppina Novo (b), Salvatore Novo (b), Cesare De Gregorio (a, d)

(a) DPT OF CLIN. & EXPER. MEDICINE, UNIVERSITY OF MESSINA (ITALY); (b) DPT OF HEALTH PROM, MOTHER CHILD CARE, INT MED AND MED SPEC, UNIV. OF PALERMO (ITALY); (c) DPT OF CARDIOTHORACIC SURGERY, WEILL CORNELL MEDICINE, NEW YORK CITY (USA); (d) ANCE SAFARI STUDY GROUP INVESTIGATORS, SICILY (ITALY); (e) CORE LAB TEAM, UNIPALERMO (ITALY)

Objectives. Silent atrial fibrillation (SAF) is emerging as an important clinical issue because of its potential adverse outcomes. Although SAF episodes have been frequently observed in patients with implanted devices, its prevalence in the general population is still uncertain. The "Silent Atrial Fibrillation ANCE-Sicily Research Initiative" (SAFARI) was a prospective, multicenter, observational study conducted in the Sicilian Region (Italy) by the ANCE - Cardiologia Italiana del Territorio - to investigate the SAF prevalence in adult patients from the general population, at risk for, but with no previous history of, AF.

Methods. Patients ≥55 years of age were screened according to prespecified inclusion criteria to undergo prolonged (>5 days) 3-lead ECG Holter monitoring. A small wearable device (CGM HI 3-Lead ECG; CGM TELEMEDICINE, Piacenza, Italy) was used to this purpose. ECG recording files were sent via mobile to a protected web-platform, and then to the Core Lab (at University Department of Palermo) for preliminary analysis. The final diagnosis was confirmed by the single cardiologist. If any, SAF episodes were classified based on their duration, as follows: Class A, events <30 seconds; Class B, 30 seconds to 5 minutes; Class C, ≥5 minutes. Patients suffering from cardiovascular disease were admitted, but previous history of AF, advanced heart failure, cancer, and/or recent myocardial infarction were exclusion criteria. At least one of the following additional conditions were also required for inclusion: 1) supraventricular premature beats on standard ECG; 2) palpitations of unknown origin; 3) history of transient ischemic attack or minor stroke; 4) evidence of gliosis at brain magnetic resonance imaging or computed tomography; 5) atrial chamber enlargement at echocardiography.

Results. A total of 119 patients (from 33 physicians, no COI to declare), 64 men, median age 71 [IQR 55-85] years, were studied. The median time length of ECG Holter-monitoring was 13 (IQR 5-21) days. SAF episodes were detected in 19 patients (16%), with 10,552 recorded events: 6,901 were class A (n=7 patients), 2,927 class B (n=3), and 724 class C (n=9) (p<0.001, class A vs B-C, Figure). These latter patients had multiple (all-class) episodes, and 2 had more than 1,000 episodes each. No clinical, echocardiographic or laboratory findings were able to discriminate patients with SAF from those in sinus rhythm at both univariate and multivariable analyses, but patients in class C showed higher diastolic blood pressure, resting heart rate, and left atrial volumes.

Conclusions. Over an average time of 13-day ECG-Holter monitoring, SAF episodes were detected in 16% of all study population, but only 7.6% were class C. Clinical impact, predisposing conditions, and the proper management of such episodes remain to be further elucidated.

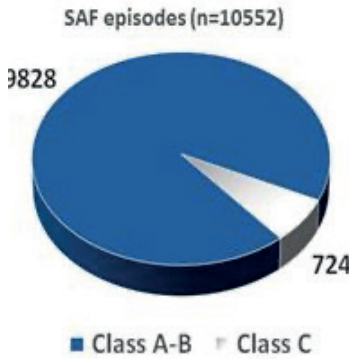

A5: LONG TERM PROGNOSIS FOLLOWING TRANSVENOUS LEAD EXTRACTION: INSIGHTS FROM A SINGLE CENTER REGISTRY

Gianmarco Arabia (a), Maria Giulia Bellicini (a), Gianfranco Mitacchione (b), Angelica Cersosimo (a), Emiliano Calvi (a), Francesca Salghetti (a), Luca Bontempi (c), Daniele Giacopelli (d), Manuel Cerini (a), Antonio Curnis (a)

(a) UNIVERSITÀ DEGLI STUDI DI BRESCIA; (b) LUIGI SACCO UNIVERISTY HOSPITAL-MILANO; (c) BOLOGNINI HOSPITAL-SERIATE; (d) CLINICAL UNIT BIOTRONIK -COLOGNO MONZESE

Background. Transvenous lead extraction (TLE) has shown a safe and efficacy profile in the intraoperative and short-term setting; however, data on long-term outcomes are limited.

Objective. The purpose of this study was to assess long-term outcomes and prognostic factors in patients who underwent TLE.

Methods. 199 patients with cardiac implantable electronic device (CIED) who underwent TLE between 2014 and 2016 were retrospectively studied. The primary outcome was the composite endpoint of death and repeated TLE stratified by infective/non-infective indication.

Results. After a median of 6.5 years infection indication was associated with significantly lower event-free survival (67% vs. 83% non-infection group, adjusted hazard ratio [aHR] 1.97, 95% confidence interval [CI] 1.02-3.81, p=0.04). All-cause mortality rate was higher in the TLE infection group (30% vs. 10%, p<0.01). The rate of repeated TLE did not differ between groups (4% vs. 7%, p=0.62). Among patients who had TLE for infection, the presence of vegetation (aHR 2.56; 95%CI 1.17-5.63, p=0.02) and positive blood cultures (aHR 2.64; 95%CI 1.04- 6.70, p=0.04) were independently associated with the primary outcome.

Conclusions. Patients who underwent TLE for CIED-related infection exhibit a high mortality risk during long-term follow-up. Vegetation and positive blood cultures in patients with CIED-related infection are associated with a worse prognosis regardless of successful and uncomplicated TLE.

A6: CATECHOLAMINERGIC POLYMORPHIC VENTRICULAR TACHYCARDIA IN A 74-YEAR-OLD PATIENT: NEVER TOO LATE!

Ylenia Calabrò (a), Valentina Alba Sassi (a), Silvia Rogiani (a), Margherita Casiraghi (a), Carlo Arnò (a), Roberto De Ponti (a)

(a) DEPARTMENT OF CARDIOLOGY, OSPEDALE DI CIRCOLO - UNIVERSITY OF INSUBRIA, VARESE, ITALY

Catecholaminergic polymorphic ventricular tachycardia (CPVT) is a rare primary arrhythmogenic disorder, caused by mutations in genes encoding for proteins involved in calcium handling in the cardiomyocyte, leading to exercise-related ventricular arrhythmias and sudden cardiac death (SCD). CPVT is usually diagnosed within the first 2 decades of life. Here, we describe a case of a first diagnosis of CPVT at an unusually advanced age. The patient is a 74-year-old woman with many cardiovascular risk factors and a previous admission for a suspected acute coronary syndrome but with no evidence of coronary artery disease. She had no history of syncope and no family history of SCD. In May, 2023 she came to our unit to undergo an exercise stress test due to reported exertional dyspnea, of which she has been complaining for about a year. Baseline ECG was normal. The exercise was initiated with steps of 25W every 2 min. As soon as the heart rate increased to 100 bpm, isolated premature ventricular complexes (PVCs) of different morphologies started to show up, then, the complexity of the arrhythmias increased and ventricular bigeminy could be seen. Upon reaching a heart rate of about 120 bpm, bidirectional ventricular tachycardia (VT) started (figure), the exercise was interrupted and during the recovery phase a brief run of polymorphic VT was seen. As the heart rate decreased, progressive reduction of the arrhythmic burden was observed, with regression to ventricular bigeminy, then to isolated PVCs and finally to complete suppression of the ventricular arrhythmias. The patient remained essentially asymptomatic, reporting only mild shortness of breath at peak exertion. She was not being treated with digoxin at the moment the test was performed, which is a known cause of bidirectional ventricular tachycardia. The patient was then admitted to our Cardiology unit for further investigations and treatment. Resting echocardiogram was within normal limits. Beta-blocker therapy with Metoprolol was initiated and titrated to the maximum dose (200 mg). Exercise stress test was repeated and discontinued at 50W due to muscular exhaustion; upon reaching 100 bpm, only 2 isolated PVCs appeared with no other arrhythmia during recovery. Moreover, a cardiac MRI was performed, revealing a sub-epicardial scar in the basal lateral segments of the left ventricle and an additional intramyocardial scar in the mid septum, these findings were consistent with a previous episode of myocarditis which could explain the previous admission for suspected acute coronary syndrome in the absence of angiographically relevant stenosis. Considering the ECG-graphic alterations during the stress test highly suggestive of CPVT, genetic counseling and testing were proposed to the Patient: two variants in the RYR2 gene (p.L73P and p.E1985K), the main culprit gene involved in the etiology of CPVT, were found. The genetic analysis will therefore be extended to the offspring of the proband. Although CPVT is a typical disorder of youth, this case demonstrates that it cannot be excluded in older subjects. This awareness could lead to an earlier diagnosis in the offspring, allowing us to prevent fatal events in them too.

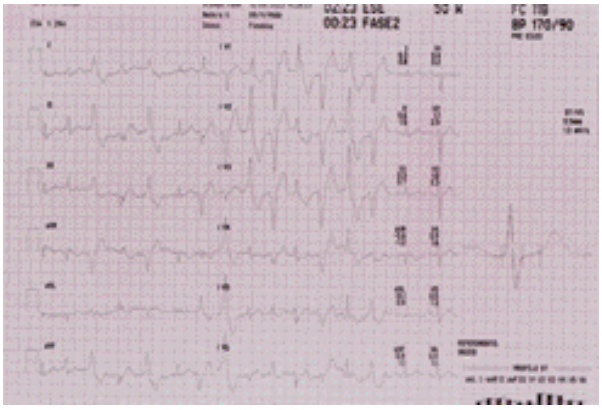

A7: CORRELATION BETWEEN VOLTAGE AND IMPEDANCE MAPPING IN PATIENTS WITH PAROXYSMAL AND PERSISTENT ATRIAL FIBRILLATION

Antonio Taormina (b), Guido Del Monaco (a, b), Benedetta Grossi (a), Diego Penela Maceda (a, b), Giulio Falasconi (a, b), Carlo Ceriotti (b), Paola Galimberti (b), Lorenzo Monti (a, b), Stefano Valcher (a,b), Kamil Stankowski (a, b), Gianluigi Condorelli (a, b), Giulio Giuseppe Stefanini (a, b), Antonio Frontera (a, b)
(a) DEPARTMENT OF BIOMEDICAL SCIENCES, HUMANITAS UNIVERSITY, 20090, PIEVE EMANUELE (MI); (b) CARDIO CENTER, HUMANITAS RESEARCH HOSPITAL, VIA MANZONI 56, 20089, ROZZANO (MI)

Background. Pulmonary veins isolation (PVI) represents the main strategy for paroxysmal atrial fibrillation (AF) treatment. Impedance values provide insights on tissue conductive properties.
Methods. 60 patients with paroxysmal and persistent AF were enrolled. Before ablation, every patient underwent a CT scan in order to evaluate atrial endocardial thickness. Electroanatomic maps were acquired with the ablation catheter. Every map was analysed for impedance values (W), voltage amplitude (mV) and bipolar EGMs.
Results. 40 paroxysmal (PAF) and 20 persistent (PsAF) patients were included. In all PAF cases no voltages lower than 0.05 mV were found. The corresponding impedance values ranged from 140.6 to 169.9 W, with an average value of 151.5 ± 5.4 W. In PsAF, instead, voltage values inferior to 0.05 mV have been reported in the posterior wall, anterior wall and roof in 19/20 patients. In tlow voltage areas, long duration fractionated signals have been reported and the average impedance value dropped to 129.1 ± 3.8 W, (range 110.2-139.6 W). As for atrial thickness, no correlation has been found neither with EGMs voltage amplitude nor with corresponding impedance value.
Conclusions. This study documents an association between voltage amplitude and impedance values (r_s=0.4166; p=0.000). Impedance might be used for arrhythmogenic substrate characterization. No direct correlation of these two parameters with atrial thickness exists (r_sv-t=0.1838; r_si-t=0.1133).

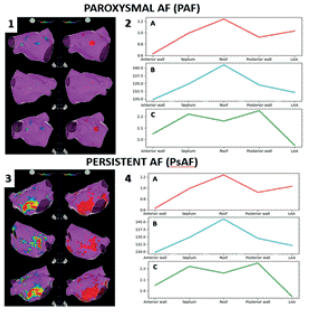

CENTRAL ILLUSTRATION:
Panel 1 and 3: comparison of voltage and impedance maps in PAF **(1)** and PsAF **(3)**.
Left side: bipolar voltage map **Right side:** impedance map. From top to bottom: Anteroposterior **(AP)**, posteroanterior **(PA)** and right anterior oblique **(RAO)** view of LA
Panel 2 and 4:
Variables (**A** :Voltage; **B:** Impedance; **C:** Thickness) in considered atrial segments in PAF **(2)** and PsAF **(4)**.

A8: NON-INVASIVE STEREOTACTIC ARRHYTHMIA RADIOABLATION OF REFRACTORY VENTRICULAR TACHYCARDIA (VT-ART): RESULTS FROM THE MULTICENTER PROSPECTIVE OBSERVATIONAL VT-ART STUDY

Chiara Pavone (a), Francesco Cellini (b, c), Federica Giordano (a), Gemma Pelargonio (d), Giorgio Escalar (a), Roberto Scacciavillani (a), Stefania Manfrida (b), Gaetano Pinnacchio (d), Maria Antonietta Gambacorta (b, c), Gianluigi Bencardino (d), Nicola Dinapoli (b), Francesco Perna (d), Alba Fiorentino (f), Antonio Di Monaco (e), Massimo Grimaldi (e), Filippo Crea (a), Maria Lucia Narducci (d)
(a) DIPARTIMENTO DI SCIENZE CARDIOVASCOLARI, UNIVERSITÀ CATTOLICA DEL SACRO CUORE, ROMA; (b) DIPARTIMENTO DI DIAGNOSTICA PER IMMAGINI, RADIOTERAPIA ONCOLOGICA ED EMATOLOGIA, FONDAZIONE POLICLINICO UNIVERSITARIO AGOSTINO GEMELLI IRCCS, ROMA; (c) DIPARTIMENTO DI DIAGNOSTICA PER IMMAGINI, RADIOTERAPIA ONCOLOGICA ED EMATOLOGIA, UNIVERSITÀ CATTOLICA DEL SACRO CUORE, ROMA; (d) DIPARTIMENTO DI SCIENZE CARDIOVASCOLARI, FONDAZIONE POLICLINICO UNIVERSITARIO AGOSTINO GEMELLI IRCCS, ROMA; (e) UNITÀ OPERATIVA COMPLESSA DI CARDIOLOGIA, OSPEDALE GENERALE REGIONALE F. MIULLI, ACQUAVIVA DELLE FONTI (BA); (f) UNITÀ OPERATIVA COMPLESSA DI RADIOTERAPIA, OSPEDALE GENERALE REGIONALE F. MIULLI, ACQUAVIVA DELLE FONTI (BA)

Aims. Ventricular tachycardia ablation through radiation therapy (VT-ART) is an innovative treatment strategy for the management of patients with refractory monomorphic ventricular tachycardia. VT-ART proved itself to be a remarkably effective and adequately safe intervention, with a significant reduction in arrhythmic burden and few adverse events described in literature. Nonetheless, more clinical data are still needed to better evaluate its long-term efficacy and toxicity. The aim of this multicenter observational study is to evaluate the efficacy and safety of VT-ART, considering the long-term clinical outcomes of enrolled patients.
Methods. In this prospective observational study we enrolled 10 patients with refractory monomorphic ventricular tachycardia or ventricular fibrillation. Substrate location was identified through fusion of CT images with electroanatomic mapping and VT-ART was performed by delivering a single 25 Gy dose to the target area. The primary efficacy endpoint was a statistically significant reduction in VT episodes on ICD interrogation, while primary safety endpoints included radiotherapy-related adverse effects and overall mortality.
Results. Ten patients (men, average age 69 years old, 80% at least NYHA class III, mean ejection fraction 27%, 4 non-ischemic cardiomyopathy) with recurrent monomorphic VT (5 electrical storm, 4 incessant sustained VT, 1 incessant VT) underwent VT-ART. During a mean follow up of 12 months, six patients had no VT recurrence, while one patient had an increase in arrhythmic burden associated with heart failure progression. 4/10 patients died during follow up (two before the 3-month programmed follow-up; two at 5 and 9 months respectively) all due to pre-existent progressive heart failure. Overall, the total number of ventricular arrhythmias decreased from 88 in the 2 months preceding treatment to 30±5 in the 2 months following treatment (66% decrease). No radiotherapy-associated adverse events were recorded.
Conclusions. Our study demonstrated the safety and efficacy of VT-ART in the management of patients with monomorphic VT refractory to traditional ablation strategies.

A9: IMPACT OF AIR POLLUTION ON VENTRICULAR ARRHYTHMIAS RISK IN PATIENTS WITH IMPLANTABLE CARDIOVERTER DEFIBRILLATOR

Davide Lazzeroni (a), Luca Moderato (c), Daniela Aschieri (c), Alessandro Filippi (a), Concetta Sticozzi (c), Alessia Zanni (c), Valentina Ziveri (a), Davide Donelli (b), Alberto Monello (c), Stefano Ferraro (c), Andrea Biagi (c), Giovanni Peretto (d), Matteo Bini (a), Francesco Nicolini (b), Diego Ardissino (b), Giampaolo Niccoli (b)
(a) PREVENTION AND REHABILITATION UNIT, IRCCS FONDAZIONE DON GNOCCHI, PARMA, ITALY; (b) DEPARTMENT OF CARDIOLOGY, OSPEDALE MAGGIORE ED UNIVERSITÀ DI PARMA, ITALY; (c) CARDIOLOGY UNIT, GUGLIELMO DA SALICETO HOSPITAL, PIACENZA, ITALY; (d) DEPARTMENT OF ELECTROPHYSIOLOGY, SAN RAFFAELE SCIENTIFIC INSTITUTE, MILAN, ITALY

Background and Aims. Air pollution is responsible for 20% of deaths worldwide, whether air pollution represents a trigger for potentially fatal ventricular arrhythmias (VAs) is still an open issue. The aim was to evaluate the association between particulate matter (PM) 2.5 and PM 10 levels and VA risk in a large cohort of 279 patients with remote ECG monitoring, such as implantable cardioverter defibrillator (ICD) patients, from a highly polluted urban area over a 9-year period.
Methods. Events were collected between 01/01/2013 to 31/12/2021; day-by-day PM 2.5 and 10 levels were extracted from the Environmental Protection Agency (ARPA) stations. All VAs and ICD interventions were collected and blinded analyzed. A total of 1.256 cases of VAs occurred in 1085 days (33%) out of 3.286 days.
Results. For each 10μg/m3 increase of PM 10 exposure, VAs relative risk increased by 6% (7-days; p=0.020), 17% (30-days; p<0.0001),18% (90-days; p<0.0001), 23% (180-days; p<0.0001), respectively (Figure Panel A). Similarly, for each 10μg/m3 increase of PM 2.5 exposure, VAs relative risk increased by 13% (30-days; p<0.004),14% (90-days; p<0.016), 18% (180-days; p<0.039), respectively (figure panel C). Moreover, in the months in which PM 10 and 2.5 mean values exceeded the safety limits, an increase in VAs risk of 46% (p<0.001 – figure panel B) and 41% (p<0.001 figure panel D), respectively, was found. Finally, the association between air pollution and VA risk remained significant even after adjustment for atmospheric data.
Conclusions. Mid- and long-term exposure to PM 2.5 and PM 10 are associated with VAs risk of in ICD patients.

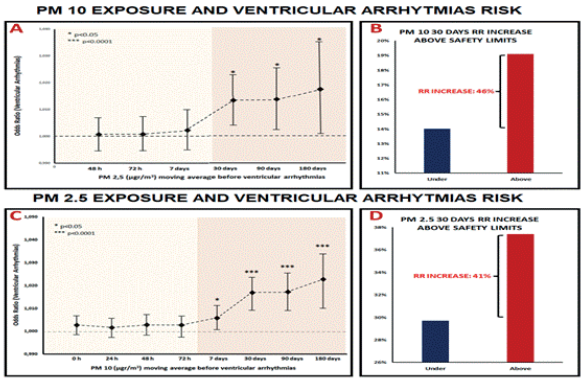

A10: ARRHYTHMIC RISK STRATIFICATION OF FILAMIN C TRUNCATING VARIANTS CARRIERS

Marta Gigli (a), Davide Stolfo (a, c), Matthew Taylor (b), Marco Merlo (a), Giulia Barbati (a), Luisa Mestroni (b), Gianfranco Sinagra (a)
(a) AZIENDA SANITARIA UNIVERSITARIA GIULIANO ISONTINA, CARDIOTHORACOVASCULAR DEPARTMENT AND UNIVERSITY OF TRIESTE; (b) MOLECULAR GENETICS, CARDIOVASCULAR INSTITUTE, UNIVERSITY OF COLORADO, DENVER ANSCHUTZ MEDICAL CAMPUS; (c) DIVISION OF CARDIOLOGY, DEPARTMENT OF MEDICINE, KAROLINSKA INSTITUTET, STOCKHOLM

Background. Filamin C truncating variants (FLNCtv) are a rare cause of cardiomyopathy with heterogeneous phenotypic presentation and high incidence of life-threatening ventricular arrhythmias, including sudden cardiac death. Nevertheless, there is a residual gap in the definition of solid risk markers for the stratification of arrhythmic risk and the impact of conventional predictors (i.e. left ventricular ejection fraction [LVEF]) remains extremely controversial.

Purpose. The aim of this study was to analyze the risk profile and to identify the factors associated with increased risk of life-threatening arrhythmias in an international multicenter cohort of FLNCtv carriers.

Methods. Patients were retrospectively collected from 19 international tertiary care centers for genetic cardiomyopathies. Primary endpoint was sudden cardiac death (SCD)/major ventricular arrhythmias (MVA, i.e. sustained ventricular tachycardia and appropriate implantable cardioverter defibrillator [ICD] shocks). Multivariate Cox regression analysis was performed to identify the predictors of SCD/MVA, taking into account non-sudden cardiac death/heart transplant/destination left ventricle assist device as competing event and including family clusters in the model as clustering factor.

Results. Among the 308 included carriers (median age 45 years, IQR 33-56; 52% males), 112 (36%) were probands. 83 (27%) carriers had no clinical signs of overt disease (phenotype negative). Median LVEF was 51% (IQR 38%-59%, 48% had LVEF<50%), 20% had right ventricle dysfunction. During a median follow-up of 36 months, 57 carriers (19%) experienced SCD/MVA, with an annual incidence rate of 4 cases/100 person/years (95%CI 3-6). Incidence rate was higher in probands vs non-probands and in phenotype positives vs phenotype negatives. A predictive model for the estimation of the risk of SCD/MVA was derived from multivariable analysis, which included age, male sex, previous syncope, non-sustained ventricular tachycardia and LVEF (tested as spline variable; while no association emerged for LVEF as linear or categorical variable) with a time-dependent AUC at 72 months 0.78 (95% CI: 0.70-0.86). Internal validation with bootstrapping confirmed good accuracy and calibration of the model.

Conclusions. In the largest worldwide cohort of mutation carriers, FLNCtv have confirmed to carry a high risk of SCD/MVA. A 5-variables predictive model was derived for risk estimation which might aid clinicians in the decisions on ICD implantation. Current recommended thresholds of LVEF for stratification of the arrhythmic risk should be probably reconsidered in carriers of FLNCtv. The higher risk observed in males compared with females advocates for prompt investigations on the influence of sex-related factors on the disease expression in genetic cardiomyopathies.

A11: ATRIAL FIBRILLATION AND PER-ATRIAL INFLAMMATION ON CARDIAC COMPUTED TOMOGRAPHY

Domenico Tuttolomondo (a, b), Nicola Gaibazzi (b), Carmine Pizzi (c, d), Giampaolo Niccoli (a, b)
(a) UNIVERSITÀ DESGLI STUDI DI PARMA, PARMA, ITALY; (b) AZIENDA OSPEDARLIERO UNIVERSITARIA DI PARMA, PARMA, ITALY; (c) UNIVERSITÀ DEGLI STUDI DI BOLOGNA, BOLOGNA, ITALY; (d) UNITÀ DI CARDIOLOGIA, IRCCS AZIENDA OSPEDALIERO UNIVERSITARIA DI BOLOGNA, BOLOGNA ITALY

Background. Inflammation plays a key role in atrial fibrillation (AF). Epicardial adipose tissue around the atrial wall can influence atrial morpho-functional properties. The aim of this study was to assess whether an increased quantity and/or density of adipose tissue located around the left atrium (Fat-LA) are related to AF, independently from atrial size.

Methods. eighty patients who underwent AF ablation and 80 patients without history of AF were selected. The Fat-LA mass was quantified as tissue within -190 to -30 Hounsfield Units (HU) on cardiac computed tomography angiograms (CCTA), and the mean adipose tissue attenuation was assessed.

Results. Adipose tissue mass was higher in patients with AF (5.42 ± 2.94 mL) versus non-AF (4.16 ± 2.55 mL, p=0.007), but relative fat quantity did not differ after adjusting for atrial size. Mean fat density was significantly higher in AF (-69.15 HU) versus non-AF (-76.82 HU, p<0.0001) participants. In the logistic regression models, only the addition of mean Fat-LA attenuation led to a significant improvement of the model's chi-square (from 22.89 of the clinical model to 31.69 of the clinical and adipose tissue attenuation model, p<0.01) and discrimination (AUC from 0.775 to 0.829).

Conclusions. Fat-LA volume is significantly greater only in absolute terms in patients with AF, but this difference does not hold after adjusting for the larger LA of AF subjects. On the contrary, a higher Fat-LA density was associated with AF, independently from LA size, providing incremental value over other variables that are associated with AF.

A12: HYBRID TRANSVENOUS AND SURGICAL APPROACH FOR THE EXTRACTION OF CORONARY SINUS LEADS: A CASE SERIES

Gianmarco Arabia (a), Maria Giulia Bellicini (a), Angelica Cersosimo (a), Manuel Cerini (a), Francesca Salghetti (a), Gianfranco Mitacchione (c), Luca Bontempi (b), Antonio Curnis (a)
(a) UNIVERSITÀ DEGLI STUDI DI BRESCIA; (b) BOLOGNINI HOSPITAL-SERIATE; (c) LUIGI SACCO UNIVERSITY HOSPITAL-MILAN

Background. Transvenous lead extraction is the standard therapy for cardiac device-related infection, however sometimes the procedure cannot be completed through the transvenous route alone and and it is necessary to resort to other methods. Hybrid surgical and transvenous approach can be useful in these cases. We present 3 cases of hybrid surgical and transvenous approach.

1st Case. 64-year-old male patient with a CRT-D from 2011 with an active-fixation coronary sinus (CS) lead (Attain StarFix, Model 4195 Medtronic Inc., Minneapolis, MN, USA).

During extraction of CS lead, we cannulated posterolateral transvenous with a Liberator stylet (Cook Medical, Bloomington, IN, USA), followed by the introduction of a 7 Fr mechanical polypropylene nonpowered sheath that failed to detach the lead from the surrounding adhesions. So we extracted the lead by left mini-thoracotomy.

2nd Case. 60-year-old male with a CRT-D from 2012. After a transvenous extraction of atrial and ventricular lead, we attempted to extract the coronary sinus lead (Celerity, Sorin/MicroPort CRM, Italy), positioned in the anterolateral vein, using a Liberator stylet, followed by 7, 8.5, and 10 Fr telescoping mechanical sheaths, a 9 Fr hand-powered Tightrail rotational sheath and a 16 Fr Glidelight Excimer Laser sheath. The lead was extensively fibrosed and could only be retrieved to the proximal part of the vein, approximately 2 cm from the body of the coronary sinus. Considering the high operative risk, a sternotomy was performed with complete extraction of the CS lead.

3rd Case. 74-year-old male with a CRT-D from 2012 with a bipolar CS lead (Easytrak 2 4542, Boston Scientific, Marlborough, MA, USA) positioned in the posterolateral vein. During CS lead extraction we firstly used an LLD-2 locking stylet, followed by the introduction of 7 and 8.5 Fr mechanical sheaths which ceased to advance 3 cm from the tip of the lead due to strong fibrosis. The procedure was interrupted due to the risk of coronary sinus tear and a left minithoracotomy was performed, and lead retrieved.

Conclusions. Sometimes TLE cannot be completed through the transvenous route alone and and need the intervention of the surgeon. Hybrid surgical and transvenous approach can be useful in these cases.

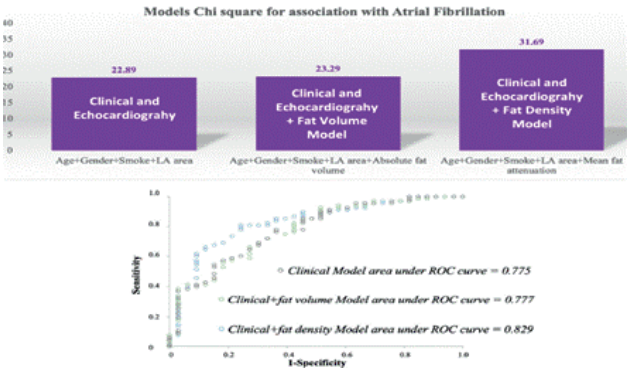

A13: PRESENCE OF ATRIAL FIBRILLATION IN PATIENTS WITH CRYPTOGENIC STROKE: PREDICTIVE VALUE OF LEFT AND RIGHT ATRIAL STRAIN

Angelica Cersosimo (a), Gianmarco Arabia (a), Maria Giulia Bellicini (a), Manuel Cerini (a), Francesca Salghetti (a), Luca Bontempi (b), Gianfranco Mitacchione (c), Antonio Curnis (a)
(a) UNIVERSITÀ DEGLI STUDI DI BRESCIA; (b) BOLOGNINI HOSPITAL-SERIATE; (c) LUIGI SACCO UNIVERISTY HOSPITAL-MILANO

Background. Often cryptogenic stroke (CS) is the first manifestation of asymptomatic atrial fibrillation (AF). Patients with CS often reiceve continuos ECG monitoring through insertable cardiac monitors (ICM) to detect the presence of AF.
Purpose. Evaluate the association between occurrence AF and standard and novel echocardiography parameters in a cohort of patients with previous CS wearing ICM.
Methods. Single center retrospective study. 204 patients with previous CS underwent ICM between May 2013 and July 2022. At the time of CS transthoracic Echocardiography (TTE) evaluation of the left atrium and left and right ventricle (including longitudinal strain) was performed. Patients with embolic sources at Transesophageal Echocardiography (TEE) were excluded. All detected AF episodes lasting more than 30 seconds were considered, according to Guidelines.
Results. AF was detected in 96 patients (47,0%) (median FU 15,3 months). The multivariate regression analysis revealed that peak atrial contraction strain of both atria were independently associated with AF ($p<0.001$ respectively).
Conclusions. In patients with cryptogenic stroke left atrium and right atrium strain analysis are strong and independent predictors of the occurrence of atrial fibrillation.

A14: IMPLANTABLE LOOP RECORDER IN BRUGADA SYNDROME: INSIGHTS FROM A SINGLE CENTER EXPERIENCE

Gianmarco Arabia (a), Angelica Cersosimo (a), Maria Giulia Bellicini (a), Manuel Cerini (a), Francesca Salghetti (a), Emiliano Calvi (a), Paolo Vinciguerra (a), Antonio Curnis (a)
(a) UNIVERSITÀ DEGLI STUDI DI BRESCIA

Background. Brugada syndrome (BrS) is an inherited arrhythmogenic disease, characterized by spontaneous or drug-induced coved-type ST segment elevation in the right precordial ECG leads and increased risk of sudden cardiac death (SCD). Risk stratification of SCD in BrS is a significant challenge due to low event rate and conflicting evidence. So over time the indications for device implantation in these patients have varied somewhat in identification of which patients should receive Implantable Cardioverter Defibrillator (ICD) and Injectable Cardiac Monitor (ICM) or no device. In particular, despite an increase in number of ICM implantation in BrS, data on the usefulness of an ICM in BrS patients are limited for now. In this study we have investigated features and outcomes of patients diagnosed with BrS who underwent ICD, ICM or no device insertion.
Methods. This is a single center retrospective cohort study of 147 consecutive patients who were diagnosed with BrS based on spontaneous or drug-induced type 1 ECG pattern, between January 2009 and May 2023. They received an ICD, an ICM or no device according with the clinical practice of the time and, if needed, electrophysiological study results.
We collected retrospectively baseline clinical patients' features, follow-up arrhythmic findings and major cardiovascular events from electronic clinical records and patients interviews and analyze tham between patients with different device.
Results. Patients who received an ICM were younger, had higher prevalence of suspected arrhythmic syncope and SCN5A gene mutations compared to patients without device, and underwent programmed ventricular stimulation less frequently compared to patients who received an ICD. Patients who received an ICD were 13, the median follow-up period was 32.2 months with no deaths occurred and no appropriate or inappropriate ICD therapies. Patients who received an ICM were 42, during a median follow-up period of 14.7 months there were no deaths but 3 patients experienced AF (including 1 case of new-onset AF), 1 patient had paroxysmal supraventricular tachycardia. 2 patients exhibited symptomatic asystolic pauses, and 2 patients had non-sustained ventricular tachycardia. Finally 92 patients didn't receive an implanted device, and during a median follow-up period of 81.4 months, no deaths or cardiovascular hospitalizations were reported.
Conclusions. Risk stratification of SCD in BrS is a significant challenge and device indication can be refined, in particular ICD indication. However continuous ECG monitoring with ICM, when indicated, can enable prompt detection of non-malignant rhythm disorders.

A15: CONFRONTO DELLA PERFORMANCE DEL LAVORO MIOCARDICO DURANTE STIMOLAZIONE DEL FASCIO DI HIS E DELL'AREA DELLA BRANCA SINISTRA

Giorgia Azzolini (a), Nicola Bianchi (a), Francesco Vitali (a), Stefano Clò (a), Michele Malagù (a), Cristina Balla (a), Matteo Bertini (a)
(a) AZIENDA OSPEDALIERO-UNIVERSITARIA DI FERRARA

Background. La stimolazione da pacemaker a livello del ventricolo destro è associata a effetti deleteri a lungo termine in conseguenza alla dissincronia ventricolare ad essa correlata, in modo analogo a quanto avviene in presenza di blocco di branca sinistra. Essa rimane tutt'oggi la strategia standard per la gestione delle bradiaritmie. La stimolazione del sistema di conduzione è una nuova strategia di pacing che sta sempre più diffondendosi con l'obiettivo di limitare questi effetti dannosi e garantire un'elettrostimolazione il più fisiologica possibile. Essa comprende la stimolazione del fascio di His (HBP) e dell'area della branca sinistra (LBBAP).
Ipotesi. Verificare eventuali differenze circa la performance ventricolare in termini elettrici e meccanici confrontando la stimolazione del fascio di His e dell'area della branca sinistra tra loro e con il ritmo spontaneo.
Materiali e metodi. Studio monocentrico prospettico di coorte derivato dallo studio EMPATHY. Sono stati arruolati 24 pazienti con indicazione di classe I o IIa ad impianto di pacemaker, 12 sottoposti a pacing del fascio di His e 12 dell'area della branca sinistra. In entrambi i gruppi abbiamo analizzato la durata del QRS, come parametro che valutasse la performance ventricolare in termini elettrici, e il lavoro miocardico, come parametro che valutasse la performance ventricolare in termini meccanici, confrontandoli dapprima con i rispettivi parametri durante l'attivazione ventricolare spontanea e poi confrontando i due diversi tipi di pacing tra loro. In quest'ultimo caso il confronto è stato eseguito come differenza relativa, in modo da evitare che eventuali fattori confondenti come i parametri basali di performance ventricolare dei due gruppi potessero influire sul risultato.
Risultati. La durata del QRS non differiva tra i due gruppi (HBP e LBBAP), sia nel confronto tra stimolazione da pacemaker e ritmo spontaneo all'interno di ciascun gruppo, sia come differenza relativa tra i due gruppi. In entrambi i gruppi non sono state osservate differenze tra i parametri di lavoro miocardico, in particolare global myocardial index (GWI) e global constructive work (GCW), quando messi a confronto tra ritmo spontaneo e stimolato. Nel gruppo LBBAP anche i parametri di global wasted work (GWW) e global work efficiency (GWE) non presentavano differenze tra ritmo stimolato e spontaneo. Inoltre, non sono state osservate differenze statisticamente significative confrontando le differenze relative di ciascun parametro di lavoro miocardico durante stimolazione da pacemaker tra il gruppo HBP e LABBP.
Conclusioni. Sia la stimolazione del fascio di His che dell'area della branca sinistra garantiscono un'attivazione ventricolare fisiologica, sia in termini di performance elettrica che meccanica. Inoltre, l'impianto di un pacemaker con stimolazione dell'area della branca sinistra è più semplice, ha una durata minore e necessità di minor radioesposizione rispetto a quello di un pacemaker con stimolazione hissiana.

A16: EMBOLIC SPLENIC INFARCTION: WHO IS THE GUILTY?

Simona Anna Maria Caporusso (a), Rosa Coppoletta (a), Roberto Mureddu (a), Valeria Sebastiani (a)
(a) DEPARTMENT OF EMERGENCY, CARDIOLOGY, ASL1 LIGURIA, IMPERIA

Acute splenic infarction (SI) is a rare event, as the incidence is about 0.004-0.01% among in-patients[1]. In this article, we discuss the case of an isolated SI in absence of definite cardiac causes. A 71-year-old woman was admitted to our department for fever associated with nausea, left hypochondrium pain, pre-syncope and neck pain in absences of vomiting, diarrhea and dysuria. In the emergency room ECG, chest x-ray and abdominal echo were unremarkable. C-Reactive Protein was mildly elevated (6 mg/dl). Computed Tomography scan of abdomen showed a clear hypoperfusion of the spleen, extended to the lower pole with thickening of the pre-renal fascia, referable to a recent ischemic injury. In order to search for possible cardio-embolic causes, a cardiologic evaluation was requested trans-thoracic (ETT) echocardiogram showed an inter-atrial septal aneurysm with bidirectional shunt, normal cardiac chambers, not left ventricular hypertrophy. The patient was therefore admitted to our Cardiology Department. Coagulation tests showed a heterozygous MTHFR mutation. Trans-esophageal echocardiogram confirmed ETT findings and a moderate right-to-left shunt at level of fossa ovalis. Neither valvular vegetations, nor thrombi in left auricle were observed. A moderate spontaneous echo-contrast was detected near the patent foramen ovale (PFO). In-hospital ECG monitoring was unremarkable. The clinical course was uncomplicated. In absence of trauma, arrhythmias, evident neoplasia and signs of infectious mononucleosis, that is a rare cause of splenic infarction, a cardioembolic event from the PFO was suspected. We discussed the possible percutaneous closure of the PFO, but we decided to postpone the closure for at least 6 months and proceed with a loop recorder implantation. The patient was discharged with aspirin 100 mg and clopidogrel 75 mg. One week later, we received an alert on remote monitoring showing a 15-hours episode of silent atrial fibrillation (AF). A direct oral anticoagulant was prescribed, and anti-platelet therapy was discontinued. Embolic events in young patients are frequently due to paradoxical embolism frequently associated with a pro-coagulative state. In older patients, even in case of suspicion of paradoxical embolism through a PFO, a long-term ECG monitoring should be always carried out before a trans-catheter closure, as AF is the prevailing cause of arterial embolism. In this case, a simple referral of PFO closure has led to make a right diagnosis and consequently an appropriate treatment, avoiding an invasive and unnecessary procedure[2,3].

Weber E, Grangeon F, Reynaud Q, et al. Acute renal and splenic infarctions: a review. QJM 2020;113:186-93.
Pristipino C, Germonpré P, Toni D, et al. European position paper on the management of patients with patent foramen ovale. Part II - Decompression sickness, migraine, arterial deoxygenation syndromes and select high-risk clinical conditions. Eur Heart J 2021;42:1545-53.
Pristipino C, Sievert H, D'Ascenzo F, et al. European position paper on the management of patients with patent foramen ovale. General approach and left circulation thromboembolism. Eur Heart J 2019;40:3182-95.

A17: CARDIAC CONTRACTILITY MODULATION IN A PATIENT WITH UNUSUAL ICD LEAD POSITION, A NEW POSSIBLE ROLE?

Salvatore Chianese (a, b), Antonio Ruocco (a), Salvatore Crispo (a), Eduardo Bossone (c), Ciro Mauro (a)
(a) CARDIOLOGY DIVISION, AORN CARDARELLI, VIA CARDARELLI 9, NAPLES, ITALY; (b) DEPARTMENT OF ADVANCED BIOMEDICAL SCIENCES, UNIVERSITY OF NAPLES FEDERICO II, VIA SERGIO PANSINI 5, 80131 NAPLES, ITALY; (c) DEPARTMENT OF PUBLIC HEALTH, UNIVERSITY OF NAPLES FEDERICO II, VIA SERGIO PANSINI 5, 80131 NAPLES, ITALY

A 81 year-old woman was referred to our center for upgrade to cardiac resynchronization (CRT) therapy. She had been previously diagnosed with heart failure with reduced ejection fraction (HFrEF) of ischemic etiology and treated with angioplasty and implantable cardiac defibrillator (ICD). Moreover, she was affected by chronic hypertension and atrial fibrillation. She was symptomatic for less than ordinary activity (NYHA III) and she was receiving maximized optimal medical therapy (OMT) according to the latest heart failure guidelines (ace-inhibitor, beta-blocker, mineralcorticoid receptor antagonist, loop diuretic and glifozin). ECG showed ventricular paced QRS complexes with RBBB morphology and a negative QRS in lead I (fig. 1). Echocardiography showed a dilated left ventricle with a severe reduced ejection fraction (30%), dilated left atrium, and normal right ventricle systolic function. ICD catheters could not be evaluated for suboptimal image quality. In the electrocardiographic suspicion of malposition of pacing leads, a chest X-ray in postero-anterior and lateral views was obtained which showed the ventricular lead positioned in a coronary sinus tributary. After collegial discussion, for the impossibility of an upgrade to CRT, the patient was referred for cardiac contractility modulation (CCM). At 3 months follow up exercise tolerance by 6-minute walk test, left ventricle ejection fraction (LVEF), and NYHA symptoms were improved. This is the first case of CCM implantation in a patient with ICD ventricular lead malposition in a coronary sinus tributary (Fig. 2) and shows feasibility and efficacy of the device in this setting. This case illustrates the utility of performing multiple fluoroscopic views at implantation to rule out malposition of pacing leads. LV capture results in a negative QRS in lead I (which may be observed occasionally also with RV pacing) and an RBBB QRS morphology. The differential diagnosis of an RBBB pattern of a paced QRS complex is: LV endocardial pacing via a patent foramen ovale, an atrial/ventricular septal defect, or an arterial puncture; LV epicardial pacing via a CS tributary; ventricular perforation; ventricular fusion/pseudofusion in a patient with pre-existing RBBB and intrinsic AV conduction; or 'pseudo-RBBB' pattern due to misplacement of V1 and V2 electrodes above the 4th intercostal space.

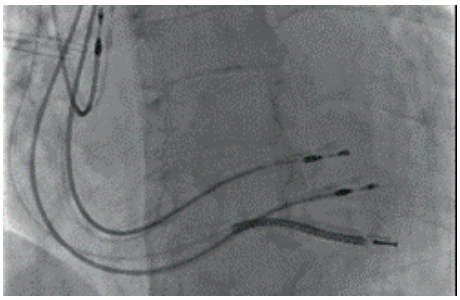

Figure 1. ECG presentation.

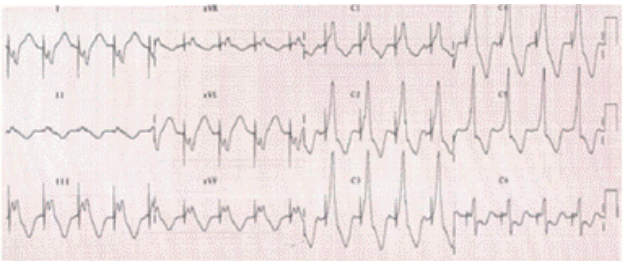

Figure 2. Fluoroscopy.

A18: POSTOPERATIVE ATRIAL FIBRILLATION AFTER CARDIAC SURGERY: THE ROLE OF SERUM ELECTROLYTES, INOTROPIC DRUGS AND CARDIOPLEGIC SOLUTIONS

Giuseppe Comentale (a, b), Vittoria Fontana (a), Anna Milione (a), Shadi Hamameh (a), Giovanna Bevilacqua (a), Mariarita Buono (a), Emanuele Pilato (a)
(a) UNIVERSITÀ DEGLI STUDI DI NAPOLI FEDERICO II; (b) ALMA MATER STUDIORUM UNIVERSITÀ DI BOLOGNA

Background. Postoperative atrial fibrillation (POAF) occurs in 20% to 40% of patients who underwent cardiac surgery and can compromise the postoperative course, especially in those with reduced left ventricular ejection fraction. The most common causes are related to surgical trauma and the high variations in volemic and electrolyte balance in the postoperative period. As extracorporeal circulation and cardioplegic solutions can significantly impact both these factors and as inotropes can trigger cardiac arrhythmias, the study aimed to assess the role of plasma electrolytes variation during the perioperative period, inotropic drugs, and cardioplegia on the onset of POAF.
Methods. A retrospective single-center analysis was carried out on 93 patients undergoing coronary artery bypass graft surgery where extracorporeal circulation and cardioplegia were used. The patients were divided into two groups according to the cardioplegic solution (Cold Blood vs. Del Nido), and perioperative outcomes were compared.
Results. POAF occurred in 21.5% of patients. The patients treated with cold blood cardioplegia (CBC) showed a 3-times higher rate of POAF compared to the DelNido (DN) group (OR: 3.44; 95% CI: 1.1 to 10.5; p=0.029). The CBC group showed higher serum K^+ levels both after the cross-clamp removal (p<0.001), at the ICU admission (p=0.007), and during the first 3 postoperative days (p=0.009) (Figure 2). The defibrillation rate at cross-clamp removal (p=0.003), the dose of postoperative epinephrine (p<0.001), and the peak of serum troponin (p=0.01) were lower in the DN Group (Figure 1). Univariate risk factor analysis revealed that POAF was significantly associated with the type of Cardioplegia (p=0.029), with high serum K^+ levels at cross-clamp removal (p=0.047), with the increased number of packed red cell transfusions (p=0.036) and the use of inotropes (dose of the inotropes, p<0.001; need for inotropes during 1st postoperative day, p=0.004).
Conclusions. DN cardioplegia showed significantly reduced POAF rates after cardiac surgery by acting on the electrolyte balance, myocardial protection, and the need for postoperative inotropic support.



Figure 1.

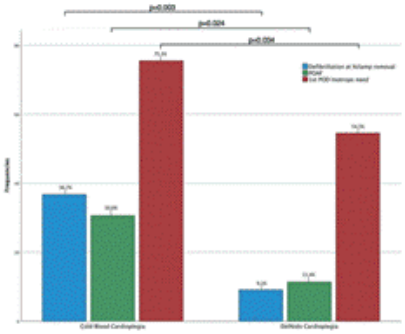

Figure 2.

A19: DESCRIPTION AND COMPARISON OF FOUR DIFFERENT PERMANENT HIS BUNDLE PACING TECHNIQUES

Andrea Dell'Aquila (a), Angelica Fundaliotis (a), Marina Moretti (a), Edoardo Cantù (a, b), Francesca Filippelli (a), Antonino Pitì (a), Gianmarco Arabia (b), Antonio Curnis (b), Luca Bontempi (a, b)
(a) CARDIAC ELECTROPHYSIOLOGY AND ELECTROSTIMULATION UNIT, CARDIOLOGY DEPT. - ASST BERGAMO EST, BOLOGNINI HOSPITAL OF SERIATE; (b) UNIT OF CARDIAC ELECTROPHYSIOLOGY AND ELECTROSTIMULATION, INSTITUTE OF CARDIOLOGY - ASST SPEDALI CIVILI HOSPITAL OF BRESCIA AND UNIVERSITY OF BRESCIA

Aims. Permanent His bundle pacing (HBP) is the most physiological pacing modality to date[1], and new implantation systems are now available.

However concerns about operative difficulty still limit its routine adoption[2,3]. The aim of the present study was to describe and compare four different techniques to perform HBP.
Methods. We included all consecutive patients who underwent a HBP attempt in our initial experience between March 2021 and July 2022. Procedural techniques were already described elsewhere[4]. The success and characteristics of the procedure were compared among four implantation techniques: the Biotronik Selectra 3D sheath with Solia S60 lead (Selectra 3D), the Boston Scientific Site Selective Pacing Catheter with Ingevity lead (SSPC), the Abbott steerable stylet locator with Tendril lead (Locator), and the use of a standard stylet manually pre-shaped with a conventional pacing lead (Curved stylet).
Results. One hundred twenty-one patients (median age 79 years [interquartile range, 73-83], 83% men) were identified. The Selectra 3D technique was used in 50 procedures, SSPC in 35, Locator in 18 and Curved stylet in 18. The groups had similar clinical characteristics. Overall, procedural success was achieved in 116 patients (95.8%) with similar proportions among groups (p=0.954). Fluoroscopy and procedural times were 6.7 (4.4-8.9) and 60 (45-76) minutes, respectively, without significant differences (p=0.461 and p=0.673). The rate of selective capture, the pacing threshold, and the paced QRS duration were also comparable. There were 7 cases of pre-discharge HBP lead dislodgment (737%) that required implant revision, 5 of which occurring in the first 20 device implanted, underlining the presence of a learning curve for HBP procedure. This complication rate was slightly higher compared to historical pacemaker cohorts[4], however it was already highlighted in other studies[2,3]. More studies are needed to correctly assess the risk of this complication and to clarify its clinical consequences.
Conclusions. In our experience, four techniques for HBP achieved comparable results in terms of safety and effectiveness[4]. The availability of different systems may lead to widespread use of physiological pacing.
References
Narula OS, et al. Pervenous pacing of the specialized conducting system in man. His bundle and A-V nodal stimulation. Circulation. 1970;41(1):77-87.
Zanon F, et al. Permanent His-bundle pacing: A systematic literature review and meta-analysis. Europace. 2018;20(11):1819-1826.
Abdin A, et al. Outcomes of conduction system pacing compared to right ventricular pacing as a primary strategy for treating bradyarrhythmia: systematic review and meta-analysis. Clin Res Cardiol. 2021;(0123456789).
Bontempi L, et al. Permanent his bundle pacing: Description and comparison of four implantation techniques. PACE - Pacing Clin Electrophysiol. 2023;(April):1-10.

A20: HIS BUNDLE PACING IN THE CONTEXT OF IMPLANTABLE CARDIOVERTER-DEFIBRILLATOR IMPLANTATION: A FEASIBLE APPROACH IN HEART FAILURE WITH NARROW QRS COMPLEX

Andrea Dell'Aquila (a), Angelica Fundaliotis (a), Marina Moretti (a), Edoardo Cantù (a, b), Francesca Filippelli (a), Antonino Pitì (a), Gianmarco Arabia (b), Antonio Curnis (b), Luca Bontempi (a, b)
(a) CARDIAC ELECTROPHYSIOLOGY AND ELECTROSTIMULATION UNIT, CARDIOLOGY DEPT. - ASST BERGAMO EST, BOLOGNINI HOSPITAL OF SERIATE; (b) UNIT OF CARDIAC ELECTROPHYSIOLOGY AND ELECTROSTIMULATION, INSTITUTE OF CARDIOLOGY - ASST SPEDALI CIVILI HOSPITAL OF BRESCIA AND UNIVERSITY OF BRESCIA

Aims. Permanent His bundle pacing (HBP) is the most physiological pacing modality to date[1], but concerns about operative difficulty still limit its routine adoption[2,3]. The combined use of an implantable cardioverter-defibrillator (ICD) and HBP may be an alternative to ICD and no-pacing in patients with symptomatic heart failure (HF) not candidates to cardiac resynchronization therapy (CRT) with defibrillator (CRT-D) due to a narrow QRS complex. However, data in literature regarding this approach are scanty. The aim of this study is to prospectively describe procedural and clinical outcomes of patients undergoing ICD implantation with HBP.
Methods. Between October 2021 and November 2022, HBP was attempted at our Institution in patients with New York Heart Association (NYHA) functional class II or III, electrocardiographic (ECG) signs of conduction disorders despite QRS duration <130 ms who underwent ICD implantation for standard indications. The HBP lead was connected to the left ventricle port of a CRT-D device. Procedural HBP lead implantation techniques were described elsewhere[4]. Patients also received a right atrial lead and a right ventricular defibrillator lead. After lead and generator implantation, AV delay was optimized based on ECG evaluation.
Results. Sixteen patients (median age 69 years [interquartile range, 57-72], 94% men) underwent ICD and HBP implantation. Most of the patients had ischemic cardiomyopathy (56%) and the median left ventricle ejection fraction was 30% (30%-37%). At implant, the ECG showed sinus rhythm for 14 (88%) and atrial fibrillation for 2 patients (12%). The QRS duration was 109 ms (89-119) with the following conduction disorders: right bundle branch block (69%), PR interval>200 ms (19%) and incomplete left bundle branch block (12%). All implantations were successful with a median procedural and fluoroscopy time of 80 min (64-98) and 11 min (9-16), respectively. HBP did not affect QRS duration (p=0.524). At 3-month follow-up, HBP was confirmed with a stable pacing threshold for all patients except for one (6.3%) who reported HBP lead dislodgment that required implant revision. The percentage of HBP was 90% (69%-98%) and 7 patients (44%) had NYHA class I.
Conclusions. Ventricular pacing delivered via the His bundle is feasible in patients with heart failure and ICD indication with a narrow QRS complex despite conduction disorders. More clinical research is needed to assess the impact of this approach on ventricular function, HF progression, and quality of life.
References
Narula OS, et al. Pervenous pacing of the specialized conducting system in man. His bundle and A-V nodal stimulation. Circulation. 1970;41(1):77-87.
Zanon F, et al. Permanent His-bundle pacing: A systematic literature review and meta-analysis. Europace. 2018;20(11):1819-1826.
Abdin A, et al. Outcomes of conduction system pacing compared to right ventricular pacing as a primary strategy for treating bradyarrhythmia: systematic review and meta-analysis. Clin Res Cardiol. 2021;(0123456789).
Bontempi L, et al. Permanent his bundle pacing: Description and comparison of four implantation techniques. PACE - Pacing Clin Electrophysiol. 2023;(April):1-10.

A21: UTILIZZO DEL MONITOR CARDIACO IMPIANTABILE PER LA DIAGNOSI DI PATTERN DI TIPO 1 NELLA SINDROME DI BRUGADA: UNA PROSPETTIVA PROMETTENTE PER LA STRATIFICAZIONE DEL RISCHIO ARITMICO

Alessandro Dinatale (a), Antonio Crocamo (a), Luca Bearzot (a), Gianluca Gonzi (a), Angela Guidorossi (a), Daniele Giacopelli (b), Matteo Bassini (b), Diego Grassini (b), Giampaolo Niccoli (a), Diego Ardissino (a), Maria Francesca Notarangelo (a)
(a) U.O. DI CARDIOLOGIA, A.O.U. DI PARMA; (b) BIOTRONIK ITALIA S.P.A., VIMODRONE (MI)

Introduzione. Nei pazienti con sindrome di Brugada, la percentuale di tempo con pattern di tipo 1 (BP1) manifesto è associata ad un rischio aumentato di aritmie maligne. Tuttavia, l'identificazione e la quantificazione del BP1 possono essere complicate a causa della sua comparsa intermittente. I monitor cardiaci impiantabili (ICM) offrono un monitoraggio continuo a lungo termine, che potrebbe superare le limitazioni dei monitoraggi ECG periodici ambulatoriali nel rintracciare la comparsa del BP1 spontaneo, ma il loro utilizzo con questa finalità non è ancora stato valutato.
Materiali e metodi. Da novembre 2022 a luglio 2023, sono stati arruolati tutti i pazienti con BP1 farmacologicamente indotto. È stato impiantato un ICM (Biomonitor IIIm; Biotronik) in posizione I-II spazio intercostale sinistro inclinazione 45° che permetteva di ottenere un tracciato con la stessa morfologia delle derivazioni ECG precordiali destre durante test all'ajmalina (AT). Tutti i pazienti sono stati seguiti in monitoraggio remoto. Oltre alle trasmissioni automatiche periodiche e quelle per disturbi aritmici, ogni paziente è stato dotato di telecomando per effettuare trasmissioni in caso di febbre o sintomi. Le trasmissioni sono state valutate per identificare: 1) sopraslivellamento ST; 2) aritmie ventricolari; 3) burden di extrasistoli ventricolari (PVC). Il tracciato è stato considerato positivo per BP1 se risultava morfologicamente sovrapponibile a quello registrato durante AT. La percentuale di trasmissioni con BP1 è stata valutata per quattro fasce orarie.
Risultati. L'ICM è stato impiantato in 16 pazienti (M:F 1:1; età media 45.6±13.3 anni). Durante un follow-up medio di 168±70.6 giorni, sono state ricevute in totale 7818 trasmissioni, equamente distribuite per fascia oraria (minimo di 1296 trasmissioni per fascia). Sono state identificate 173 trasmissioni positive per BP1 (2.2%) trasmesse da 6 pazienti (37.5% dei pazienti, tutti con nuova diagnosi di BP1 spontaneo). Il tempo mediano tra l'impianto e la diagnosi di BP1 spontaneo è stato 20 giorni (range 2-42). La mediana di giorni con almeno una trasmissione positiva è stata di 30.2 (range 13.4-73.9). La fascia serale (dalle 18 a mezzanotte) ha presentato una percentuale di trasmissioni positive significativamente maggiore rispetto a quella mattutina (p=0.04) e pomeridiana (p=0.01); ma non rispetto a quella notturna (p=0.8). Non sono state osservate aritmie ventricolari sostenute né differenze significative nel burden di PVC tra i pazienti.
Conclusioni. L'utilizzo dell'ICM per il monitoraggio continuo dei pazienti con BP1 indotto farmacologicamente ha permesso la diagnosi del pattern spontaneo nel 40% dei casi durante circa 6 mesi di follow-up. Le fasce orarie serali e notturne hanno mostrato la maggior prevalenza di BP1. Questo approccio potrebbe essere promettente per la quantificazione del burden BP1 e potrebbe essere utilizzato per stratificare il rischio aritmico nei pazienti con sindrome di Brugada.

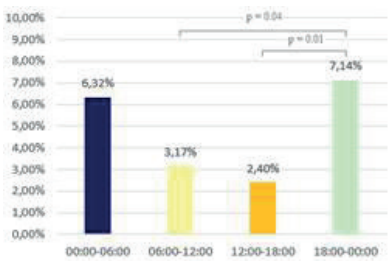

Percentuale di trasmissioni positive suddivise per fascia oraria

A22: THE ROLE OF SUBCUTANEOUS ICD IN THE POST-ORTHOTOPIC HEART TRANSPLANTATION WITH PREVIOUS IDIOPATHIC LIFE-THREATENING ARRHYTHMIAS IN THE HEART OF LIVING DONOR: A GREY ZONE.

Alessio Falagario (a), Paolo Basile (a), Giorgia Falco (a), Maria Cristina Carella (a), Riccardo Memeo (a), Vincenzo Ezio Santobuono (a), Francesco Monitillo (a), Daniela Santoro (a), Cinzia Forleo (a), Marco Matteo Ciccone (a), Andrea Igoren Guaricci (a)
(a) UNIVERSITÀ DEGLI STUDI DI BARI "ALDO MORO"

Introduction. Nowadays, orthotopic heart transplantation (OHT) is a well-established therapy in case of end-stage heart disease. Sudden cardiac death (SCD) affects a non-negligible proportion of patients after OHT, due to the onset of malignant arrhythmias. Implantable cardioverter defibrillator (ICD) plays a pivotal role in the prevention of SCD before OHT. Instead, the role of these devices in the post-transplantation period should be further explored. To the best of our knowledge, this case report represents the first experience of a subcutaneous ICD (s-ICD) implantation in the short-term post-OHT due to previous idiopathic life-threatening arrhythmias in the living donor.
Case report. A 70-years-old male patient was admitted to our institution for OHT screening. He had a history of smoking, hypertension, diabetes mellitus type 2, dyslipidemia, severe renal impairment and permanent atrial fibrillation. The patient was affected by an end-stage heart failure related to a severe ischemic cardiomyopathy. He received an ICD in primary prevention, then upgraded to cardiac resynchronization therapy with defibrillator (CRT-D). Getting on the national transplant waiting list, the patient was subsequently called for OHT. His donor experienced idiopathic ventricular fibrillation (VF) episodes treated by DC shocks and cardiopulmonary resuscitation (CPR). Before OHT, no underlying structural heart disease was identified in the donor. In the post-operative time and the rehabilitation period neither major complications nor malignant arrhythmias were observed in the patient. After 4 months from OHT a s-ICD was implanted.
Discussion. The ongoing global shortage of donor hearts dictates the need for innovative solutions to enlarge the donor pool and to reduce waiting list deaths. As established by current guidelines, in case of normal cardiac function and no structural heart disease, hearts after CPR can be used for OHT. However, in our case, the donor experienced life-threatening arrhythmias before OHT. According to current guidelines, ICD implantation may be considered in selected patients with cardiac allograft vasculopathy (CAV) or treated rejection. In our case these conditions were not observed in the follow up. Moreover, malignant arrhythmias were not registered after OHT. Consequently, our case should be collocated in a grey area, not considered by current guidelines. Given the idiopathic arrhythmogenic substrate of the transplanted heart, we decided to protect the receiver from SCD with an ICD. A s-ICD was preferred to transvenous devices due to the absence of pacing requirement and to avoid lead-related complications such as infections caused by the immunosuppressed state after OHT.
Conclusions. CPR donors are an expanding group of potential, yet currently underutilized, heart donors. Recent guidelines are supporting their utilization. Previous life-threatening arrhythmias in living donor may require the need of ICD implantation in the post-OHT to protect the recipient from SCD.

A23: LEFT ATRIAL STRAIN MARKS ATRIAL FIBRILLATION PROGRESSION IN PATIENTS UNDERGOING PERCUTANEOUS MITRAL VALVE REPAIR

Biagio Malizia (a), Letizia Rosa Romano (a), Giuseppe Scalzi (a), Iolanda Aquila (a), Alberto Polimeni (b), Ciro Indolfi (a), Antonio Curcio (a)
(a) DIVISION OF CARDIOLOGY, DEPARTMENT OF MEDICAL AND SURGICAL SCIENCES, MAGNA GRAECIA UNIVERSITY, CATANZARO, ITALY; (b) DIVISION OF CARDIOLOGY, DEPARTMENT OF PHARMACY, HEALTH AND NUTRITION SCIENCES, UNIVERSITY OF CALABRIA, COSENZA, ITALY

Background. Percutaneous mitral valve repair through transcatheter edge-to-edge repair (TEER) represents a therapeutic possibility in patients with severe mitral regurgitation (MR) considered at high surgical risk. Improvement of symptoms as well as left ventricular echocardiographic parameters have been accurately described in trials, while only in recent years, it has been realized that left atrial (LA) function plays a prognostic role in these patients. Two-dimensional speckle-tracking-echocardiography analysis (2D-STE) of LA performance showed a correlation between reduced LA function and atrial fibrillation (AF) occurrence even before enlargement of LA.
Aims. The aims of our study were to evaluate: i) LA function assessed by 2D-STE after TEER; ii) its association with AF and the risk of new onset of AF; iii) progression to persistent, long-standing persistent, or permanent AF.
Methods. We considered patients affected by symptomatic severe MR who underwent TEER at the division of Cardiology of our academic hospital from February '15 to December '20. We performed a two-dimensional transthoracic echocardiography to evaluate LA function by assessing LA strain, that is composed by strain reservoir (R_s), strain conduction (C_d) and strain contractile (C_s) as well as LA emptying fraction (LAEF-4CH), before TEER and after 1 month, 6 months, and 12 months. Statistical analysis was performed with SPSS; comparison between baseline, 6 months and 1 year follow-up was carried out by an ANOVA test. Multiple Bonferroni test was conducted as post hoc analysis.
Results. we included 75 patients (76,35±5.09 years). The main clinical characteristics are described in the Table. We obtained a significant improvement comparing baseline to 12 months follow up for R_s (P=0.001), for C_d (P=0.008) and for LAEF-4ch (P=0.001). Significant R_s improvement was observed even in 6 months follow-up (P=0.002). No significant changes were observed in C_s (P=0.11). Strikingly, a significant reduction in arrhythmic burden was observed, since only one case of subclinical AF detected by a previously implanted cardiac electronic device was found in the cohort of sinus rhythm patients undergone TEER; in addition, ventricular rate was reduced in the AF cohort (n=38) compared to baseline, together with few episodes of non-sustained ventricular tachycardias (3/38, 8%) after MR improvement.
Conclusions. TEER-associated MR improvement provoked LA remodelling and significant amelioration of LA function, mostly R_s; this parameter represents the most effective 2D-STE tool capable to detect LA function's changes in the early phases after TEER. Remarkably, R_s showed good specificity and sensitivity in predicting AF occurrence. LA positive remodelling contributes to limit arrhythmic burden.

Clinical features of the enrolled population	
	N = 75
Age, y ± SD	76.35 ± 5.09
Male, n (%)	44 (58.67)
Hypertension, n (%)	63 (84)
Diabetes Mellitus, n (%)	28 (37.33)
Hyperlipidemia, n (%)	48 (64)
Chronic kidney disease, n (%)	37 (49.33)
Atrial fibrillation, n (%)	38 (50.67)
Primary mitral regurgitation, n (%)	26 (34.67)
Secondary mitral regurgitation, n (%)	49 (65.33)

A24: PROBABILITY OF SPONTANEOUS CONVERSION TO SINUS RHYTHM IN PATIENTS WITH SYMPTOMATIC ATRIAL FIBRILLATION PRESENTING IN THE EMERGENCY DEPARTMENT: A NEW PROBABILITY SCORE

Marco Valerio Mariani (a), Nicola Pierucci (a), Sara Trivigno (a), Giovanna Manzi (a), Agostino Piro (a), Dario Vizza (a), Carlo Lavalle (a)
(a) POLICLINICO UMBERTO I - ROMA

Background. The probability of spontaneous conversion (SCV) to sinus rhythm (SR) in patients presenting to the emergency department (ED) with hemodynamically stable, symptomatic atrial fibrillation (AF) is not well-known.
Objective. To develop and validate a score to determine the probability of SCV in SR in patients presenting to the ED with hemodynamically stable, symptomatic AF.
Methods. This observational, retrospective study enrolled consecutive patients admitted with AF to the ED of Policlinico Umberto I Hospital of Rome from January 2020 to July 2023. We included AF patients in whom a rhythm control strategy was not performed before presentation at the ED or within 6 hours after ED admission, in order to analyse variables associated to SCV. In order to develop and validate a score to determine the probability of SCV in SR in AF patients presenting to the ED, the study was divided in two phases: 1) score development in a derivation cohort of AF patients admitted to the ED from January 2020 to December 2021; 2) validation of the predictive score in a set of consecutive AF patients admitted to ED from January 2022 to July 2023.
Results. Out of 749 eligible patients, 446 patients (46.6% female; mean age 69 ± 13.8 years) admitted to the ED between January 2020 and December 2021 were included in the derivation cohort, whereas 302 patients (35.1% female; mean age 65.9 ± 15.1 years) admitted from January 2022 and July 2023 were included in the validation cohort. In the derivation cohort, based on multivariable logistic analysis, a risk score weight was assigned to each significant predictor in the multivariable model by rounding the OR value to the next integer. In particular, the weighted score included: previous SCV (3 points), AF-related symptoms duration <24 h (5 points), age>65 years (3 points), female sex (2 points) and chronic OAT (-4 points). The weighted score allowed to divide patients in three groups on the basis of probability of SVC to SR during the 6-hours observation period. The probability prediction model showed an area under the curve (AUC) of 0.750 (95% CI 0.693 – 0.807), and the p-value of the Hosmer-Lemeshow goodness-of-fit test was 0.614. In the validation cohort, the score showed good discrimination power with an AUC of 0.725 (95% CI 0.666 – 0.784).
Conclusions. The proposed score allows to predict SCV probability with good accuracy and may help physicians in the management of hemodynamically stable, symptomatic AF patients in the ED.

A25: ELECTROPHYSIOLOGICAL ASSESSMENT OF SUPRAVENTRICULAR TACHYCARDIAS IN REPAIRED TETRALOGY OF FALLOT

Gianluca Mirizzi (a), Umberto Startari (a), Andrea Rossi (a), Luca Panchetti (a), Silvia Garibaldi (a), Martina Nesti (a), Pierluigi Festa (a), Lamia Ait-ali (a), Chiara Marrone (a), Giuseppe Santoro (a), Nadia Assanta (a), Marcello Piacenti (a)
(a) FONDAZIONE TOSCANA GABRIELE MONASTERIO

Introduction. Adults with repaired tetralogy of Fallot (rToF) are most often referred to Adult Congenital Heart Disease centers for atrial tachycardia (AT) and radiofrequency catheter ablation (RFCA) is often required. A systematic evaluation of the mechanisms and recurrences of arrhythmias in these patients is lacking.

Methods. 28 patients with rToF referred for catheter ablation to the Interventional Electrophysiology Unit of the Fondazione Toscana Gabriele Monasterio between January 2013 and January 2023 were evaluated. Pts underwent electrophysiologic study (EPS) with 3D electroanatomic high density mapping. Evaluation of right atrial bipolar voltage and activation mapping of the AT was performed. Intra-atrial re-entrant tachycardias (IART), focal AT (FAT), other. Activation mapping was performed to identify the critical isthmus for IART. FATs were localized according to the earliest unipolar signal. Whenever possible, all the induced tachycardias were treated besides the arrhythmia which represented the clinical indication to EPS. RFCA was aimed at the earliest activation point for FAT and at the critical isthmus for IART, anchoring lesion to fixed obstacles (valve annuli or atriotomy scar). All patients provided written informed consent for participating in the study.

Results. Among 28 adult (age 47±13 years) patients (females n=14, 50%), 53 AT were documented: 34 (64%) IART, 11 (21%) FAT and 8 (15%) atrial fibrillation (AF). Mean tachycardia cycle length (excluding AF) was 307±95 ms. At least 2 ATs were induced in 12 pts during index EPS. Among IARTs, incisional IART (IARTinc, atriotomy and superior and inferior vena cava orifices, SVC and IVC, respectively) was the prevalent critical part of the circuit (n=22, 52%), while CTI was the second mechanism (n=20, 48%). In three pts, due to non-inducibility, a pre-emptive lesion set comprising in one case CTI and in two cases CTI+SVC-atriotomy-IVC line was performed. 2 patient underwent scheduled pulmonary veins isolation and CTI ablation. Among FAT, in 3 cases the AT was mapped in the coronary sinus, in two at the tricuspid annulus, in the remaining at the crista terminalis, at the right appendage base, at the posterolateral incision scar or between atriotomy and SVC. In 6 patients AF was induced but not ablated. During a median follow up of 23 months (interquartile range, 6-37) recurrence occurred in 8 pts (18% of pts, 15% of tachycardias). Patients with recurrences were younger (43±7 vs. 48±17 y, p=0.04); no differences were found according to critical isthmus location (4 CTI and 4 IARTinc, 50%, p=ns).

Conclusions. Among rToF pts with AT, IART is the prevalent mechanism and atriotomy scar is the prevalent critical isthmus. FAT location is much more variable. Atrial fibrillation burden is not negligible. Long-term freedom from AT in this clinical setting is encouraging.

A26: LEADLESS PACEMAKER OUTCOMES IN CHRONIC KIDNEY DISEASE PATIENTS: REAL-WORLD DATA FROM THE I-LEAPER INTERNATIONAL REGISTRY

Gianfranco Mitacchione (a), Gianmarco Arabia (b), Marco Schiavone (g), Alessio Gasperetti (a), Matteo Ziacchi (j), Elisabetta Montemerlo (e), Ardan Saguner (f), Pietro Palmisano (h), Gian Battista Chierchia (d), Carlo De Asmundis (d), Antonio Dello Russo (i), Giovanni Rovaris (e), Mauro Biffi (j), Paolo Della Bella (c), Claudio Tondo (g), Antonio Curnis (b), Giovanni Battista Forleo (a)
(a) LUIGI SACCO-UNIVERSITY HOSPITAL, MILAN; (b) SPEDALI CIVILI HOSPITAL, UNIVERSITY OF BRESCIA, BRESCIA; (c) IRCCS SAN RAFFAELE HOSPITAL, MILAN; (d) HEART RHYTHM MANAGEMENT CENTRE, VRIJE UNIVERSITEIT BRUSSEL; (e) SAN GERARDO HOSPITAL, MONZA; (f) UNIVERSITY HOSPITAL ZURICH; (g) IRCCS CENTRO CARDIOLOGICO MONZINO, MILAN; (h) CARDINAL G. PANICO HOSPITAL, TRICASE; (i) UMBERTO I-SALESI-LANCISI HOSPITAL, ANCONA; (j) IRCCS POLICLINICO S. ORSOLA, BOLOGNA

Background. Chronic kidney disease (CKD) represents a serious risk factor for patients requiring transvenous pacemaker (TV-PM) promoting PM-related infections. Moreover, TV leads are an important concern for these patients, often needing vascular access patency for renal replacement therapy. In this setting leadless pacemakers (LPMs) are an attractive alternative due to their lower device-related infection rate and the absence of TV leads. To date, limited data on safety and efficacy of LPM in CKD patients are available.

Purpose. To assess long-term safety and efficacy of LPMs implantation in patients with different stages of CKD according to CKD-EPI equation for eGFR.

Methods. Consecutive patients who underwent LPM implantation in 12 Centers joining the i-LEAPER registry were retrospectively enrolled. Patients with G3a/b CKD stage (N=245) and G4/G5 CKD stage (N=67) were compared with patients with normal kidney function (NKF) (N=867). Primary endpoint was LPM-related major complications rate at implant and during FU. Additionally, the number of patients showing poor electrical performance (pacing threshold [PT]>1V@0.24ms) was compared between groups.

Results. 1179 were enrolled and followed for a median of 33[IQR 24-47] months. When compared with the NKF group, patients with G3a/b and G4/G5 CKD stage showed more cardiovascular comorbidities. The choice of a LPM was mainly due to vascular concern in the G4/G5 CKD group, while a perceived highest infective risk was reported in G3a/b CKD patient group. Major complication rate at implant and during FU did not differ between NKF and CKD patients, regardless of renal impairment stage. All-cause mortality incidence resulted higher in end-stage CKD patients (17.9% vs 6.8% NKF; HR 4.24; 95%CI 4.25-7.94, p<0.001). The rate of patients with PT>V1@0.24ms did not differ between groups, remaining consistent with historical data for LPM.

Conclusions. LPM showed a remarkable safety and efficacy profile in CKD patients regardless of renal impairment stage that was comparable to NKF population. LPM should be considered as first choice in CKD patients requiring a PM.

Baseline characteristics

	Normal kidney function N=867	CKD G3a/b stage N=245	P †	CKD G4/G5 stage N=67	P §
Male, N (%)	604 (69.7)	115 (46.9)	**<.001**	39 (58.2)	*0.056*
Age-Y, median [IQR]	79 [72-84]	82 [78-87]	**<.001**	80 [74-85]	*0.130*
Age≥65 Y, N (%)	724 (83.5)	231 (94.3)	**<.001**	62 (92.5)	*0.055*
BMI (Kg/m²)	25.0 [23.0-27.0]	25 [23.1-28]	*0.066*	26.6 [23.3-30]	***0.015***
Obesity (%)	65 (7.5)	41 (16.7)	**<.001**	18 (26.9)	**<.001**
Diabetes, N (%)	181 (20.9)	71 (29.1)	**0.009**	29 (43.3)	**<.001**
Hypertension, N (%)	415 (48.0)	200 (81.6)	**<.001**	54 (80.6)	**<.001**
CAD, N (%)	225 (26.1)	53 (21.7)	*0.181*	21 (31.3)	*0.388*
Valvular disease, N (%)	198 (22.9)	68 (28.0)	*0.126*	22 (32.8)	*0.071*
Cardiac surgery, N (%)	95 (11.0)	56 (23.0)	**<.001**	18 (26.9)	**<.001**
CABG, N (%)	52 (6.0)	25 (10.2)	**0.032**	7 (10.4)	*0.185*
LVEF %, median [IQR]	57 [53-61]	55 [50-60]	**<.001**	55 [40-57.5]	**<.001**
HF	64 (7.4)	46 (18.9)	**<.001**	15 (22.4)	**<.001**
Dialysis, N (%)				49 (73)	
LPM indication, N (%)					
Infective risk	570 (65.7)	178 (73.0)	**0.031**	36 (53.7)	*0.062*
Previous TLE (infection)	*113 (13.0)*	*41 (16.8)*	*0.143*	*11 (16.4)*	*0.453*
Vascular Issues	137 (15.8)	28 (11.5)	*0.103*	20 (29.9)	**0.006**
Patient choice	83 (9.6)	5 (2.0)	**<.001**	7 (10.4)	*0.829*
Other	77 (8.9)	33 (13.5)	**0.039**	4 (6.0)	*0.506*

P †: CKD G3a/b vs Normal group; P §: CKD G4/G5 vs Normal group

Outcomes

	Normal kidney function N=867	CKD G3a/b stage N=245	P †	CKD G4/G5 stage N=67	P §
LPM complications, N(%)	37 (4.3)	12 (4.9)	*0.724*	4 (6.0)	*0.529*
Pericardial effusion	*5 (0.6)*	*1(0.4)*	*1.0*	*0*	*1.0*
Cardiac tamponade	*2 (0.2)*	*0*	*1.0*	*0*	*1.0*
LPM dislodgement	*2(0.2)*	*0*	*1.0*	*0*	*1.0*
Battery depletion	*2 (0.2)*	*1 (0.4)*	*0.526*	*1 (1.5)*	*0.200*
Peri-procedure stroke	*0*	*1(0.4)*	*0.220*	*1 (1.5)*	*0.072*
Femoral artery injury	*10 (1.2)*	*3(1.2)*	*1.0*	*0*	*1.0*
Groin hematoma	*16(1.8)*	*4 (1.6)*	*1.0*	*1 (1.5)*	*1.0*
Systemic/LPM infection	*0*	*2 (0.8)*	***0.048***	*1 (1.5)*	*0.072*
Major complications, N (%)	15 (1.7)	7 (2.9)	*0.297*	3 (4.5)	*0.133*
Minor complications, N (%)	22 (2.5)	5 (2.0)	*0.816*	1 (1.5)	*1.0*
All cause of death, N (%)	59 (6.8)	17 (7.0)	*1.0*	12 (17.9)	***0.003***

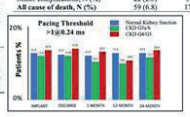

A27: CONTINUOUS STELLATE GANGLION BLOCK FOR VENTRICULAR ARRHYTHMIAS: CASE-SERIES, SYSTEMATIC REVIEW AND COMPARISON WITH EPIDURAL ANESTHESIA

Arianna Morena (a, b), Filippo Angelini (b), Antonio Toscano (c), Carol Gravinese (b), Simone Frea (b), Andrea Saglietto (a, b), Eleonora Balzani (d), Martina Cedrone (d), Matteo Giunta (c), Andrea Costamagna (c, d), Matteo Anselmino (a, b), Mauro Rinaldi (d, e), Luca Brazzi (c, d), Gaetano Maria De Ferrari (a, b), Veronica Dusi (a, b)
(a) CARDIOLOGY, DEPARTMENT OF MEDICAL SCIENCES, UNIVERSITY OF TURIN, TORINO, ITALY; (b) DIVISION OF CARDIOLOGY, CARDIOVASCULAR AND THORACIC DEPARTMENT, 'CITTÀ DELLA SALUTE E DELLA SCIENZÀ HOSPITAL, TORINO, ITALY; (c) DEPARTMENT OF ANESTHESIA, CRITICAL CARE AND EMERGENCY, 'CITTÀ DELLA SALUTE E DELLA SCIENZÀ HOSPITAL, TORINO, ITALY; (d) DEPARTMENT OF SURGICAL SCIENCES, UNIVERSITY OF TURIN, TORINO, ITALY; (e) DEPARTMENT OF CARDIOVASCULAR AND THORACIC SURGERY, 'CITTÀ DELLA SALUTE E DELLA SCIENZÀ HOSPITAL, TORINO, ITALY

Background. Percutaneous single bolus injection left stellate ganglion block (PLSGB) and thoracic epidural anesthesia (TEA) have been proposed for the acute management of refractory ventricular arrhythmias (VAs). Data on continuous PLSGB (C-PLSGB) are scant, mostly published in form of case reports.

Objectives. to report our single center experience with C-PLSGB and to perform a systematic review on C-PLSGB and TEA to preliminary compare these 2 techniques.

Methods. A combined cardio-anesthesiology program was started in January 2021 at our Center ensuring 24/7 capacity for bolus PLSGB and since December 2021 the capacity for C-PLSGB. Patients presenting with electrical storm (ES) and/or with short-time clustered VAs refractory to conventional management (nonselective beta-blockade when feasible + additional antiarrhythmic drugs) were considered for PLSGB (either single bolus or continuous infusion, CI). At first, a bolus 2% lidocaine plus 1% ropivacaine was injected under the prevertebral fascia and over the longus colli muscle, followed by an epidural catheter placement allowing for CI of either ropivacaine or lidocaine. The present analysis was performed on consecutive patients receiving C-PLSGB. The systematic literature review was performed following the latest PRISMA criteria; 16 papers were submitted to the systematic review.

Results. our single-center case series (12 pts, 92% male, 59 ±18 years, all with structural heart disease, 50% with cardiogenic shock, 25% with ongoing mechanical support) supports that C-PLSGB is feasible and safe, even on fully anticoagulated patients, and leads to a complete VAs suppression in half and to an overall clinical benefit (defined as ≥75% VAs episodes reduction allowing for patient's acute stabilization) in all patients; ropivacaine has been the most used drug for the continuous infusion (11 pts, 92%), with a starting infusion rate of 4-6 mg/h in the first three patients, subsequently increased to 12 mg/h in the next patients. Overall, considering previously published data, 38 patients received C-PLSGB, and 18 TEA for refractory VAs. Most (61%) in the TEA group were on general anesthesia, as opposed to 26% in the C-PLSGB group (p=0.02); 53% of patients were on full anticoagulation at C-PLSGB, none at TEA (p<0.01). C-PLSGB and TEA efficacy was not significantly different (35/38, 92%, versus 13/18, 72%, had a complete or at least partial response, p=0.09). No major complications occurred, yet the discontinuation rate was significantly higher in the TEA compared to C-PLSGB (22% versus 3%, p=0.03), mostly due to infective concerns and/or hypotension.

Conclusions. C-PLSGB preceded by a single bolus injection seems safe and effective for the acute management of patients with refractory VAs. Compared with TEA, C-PLSGB is easier to perform in acutely ill patients, allows a full anticoagulation regimen and advanced mechanical support. C-PLSGB appears to have a similar efficacy, despite a lower discontinuation rate, and no need to reduce infusion velocity to avoid hypotension. Ropivacaine has been the most used drug, and the available data support a starting dose of at least 12 mg/h.

A28: MORTE CARDIACA IMPROVVISA: RUOLO DEL LIFE VEST

Gennaro Vitulano (a), Michele Vitiello (b), Cristina Esposito (a), Giuseppe Caliendo (b), Alessandra Nocilla (b), Emanuele Nigro (b), Michele Manzo (a), Fabio Franculli (a), Nertil Kola (a), Angelo Silverio (b), Gennaro Galasso (b), Carmine Vecchione (b)
(a) A.O.U. SAN GIOVANNI DI DIO E RUGGI D'ARAGONA; (b) UNIVERSITÀ DEGLI STUDI DI SALERNO

Per morte cardiaca improvvisa si definisce una morte naturale, preceduta da improvvisa perdita di conoscenza, che si verifica entro un'ora dall'inizio dei sintomi, in soggetti con o senza cardiopatia nota preesistente, ma in cui l'epoca e la modalità di morte sono imprevedibili. Secondo le attuali linee guida, il Life-Vest è indicato nei pazienti con elevato rischio di aritmie ventricolari maggiori, come ad esempio nei pazienti con severa riduzione della frazione di eiezione del ventricolo sinistro (LVEF) così da poter assicurare un periodo di protezione per l'ottimizzazione della terapia medica ed effettuare una migliore valutazione del rischio per un potenziale futuro impianto di ICD. Attualmente, il motivo più frequente per la prescrizione del Life-Vest è la severa disfunzione ventricolare sinistra da cardiomiopatia non ischemica (NICM), seguita da pazienti con ridotta LVEF (≤35%) secondaria a recente infarto del miocardio. Il nostro studio ha incluso 36 pazienti, di cui 34 con una frazione d'eiezione ridotta (<50%), la maggior parte dei quali in terapia medica ottimizzata. Il tempo di utilizzo medio del Life-Vest è stato di circa 3 mesi. Dopo l'utilizzo del dispositivo, è stato riportato un miglioramento significativo della frazione di eiezione in 15 pazienti (41.6%), mentre in 18 (50%) la frazione di eiezione si è confermata inferiore a 35%. Di questi 18 pazienti con indicazione ad impianto di ICD, 15 sono stati effettivamente sottoposti ad impianto di defibrillatore cardiaco mentre 3 pazienti rifiutavano tale procedura. Due pazienti sono deceduti durante il periodo di osservazione: un paziente per asistolia mentre il secondo per cause non cardiache (neoplasia). Un paziente ha cessato autonomamente di indossare il Life-Vest. Nell'ambito dei pazienti con indicazione ad impianto di ICD, la maggior parte rientrava nel gruppo di pazienti affetti da cardiopatia ischemica, diabete mellito, tabagismo. È inoltre interessante notare che non vi fossero differenze significative nel trattamento tra i due gruppi di pazienti al follow-up. Durante il periodo di osservazione i pazienti sono stati monitorati a distanza tramite controllo remoto del dispositivo ed ambulatorialmente con l'esecuzione di visita clinica, tracciato elettrocardiografico a 12 derivazioni, controlli ecocardiografici e seriologici. Fin dai primi mesi sono stati evidenziati netti miglioramenti della frazione di eiezione e della sintomatologia dei pazienti. Un ulteriore miglioramento è stato poi riscontrato nei controlli ambulatoriali successivi per la maggior parte dei pazienti che al termine del noleggio del Life-Vest non hanno avuto necessità di impiantare l'ICD. Durante il noleggio del Life-Vest per la maggior parte dei pazienti in esame non si sono verificati eventi aritmici maggiori e di conseguenza il Life-Vest ha svolto unicamente funzione di controllo del ritmo h24 in remoto. In 2 pazienti tuttavia sono state registrate tachiaritmie ventricolari che non hanno richiesto lo shock da parte del Life-Vest. Inoltre questo studio evidenzia come l'ampia scelta di farmaci oggi a nostra disposizione, in grado di determinare reverse remodelling e miglioramento della FE, permette un graduale recupero della funzione contrattile ventricolare e di ridurre il rischio di aritmie maligne senza richiedere l'attivazione del Life-Vest. I risultati del nostro studio, oltre a confermare l'importanza del follow up continuo sia a distanza che in ambulatorio mette in luce l'importanza della terapia basale e l'utilizzo del Life-Vest per prevenire eventi aritmici importanti che possono condurre alla morte cardiaca improvvisa.

A29: SHORT DURATION HEAD-UP TILT TEST POTENTIATED WITH NITROGLYCERIN IN SUSPECTED VASOCAGAL SYNCOPE: THE FAST ITALIAN PROTOCOL

Erika Parente (a), Vincenzo Russo (a), Marco Tomaino (b), Angelo Comune (a), Antonella Sabatini (b), Nunzia Laezza (a), Domenico Carretta (c), Gerardo Nigro (a), Anna Rago (a), Paolo Golino (a), Michele Brignole (d)
(a) UNIVERSITÀ DEGLI STUDI DELLA CAMPANIA "LUIGI VANVITELLI", OSPEDALE MONALDI (NA); (b) OSPEDALE GENERALE DI BOLZANO (BZ); (c) POLICLINICO DI BARI OSPEDALE GIOVANNI XXIII; (d) ISTITUTO AUXOLOGICO ITALIANO ISTITUTO SAN LUCA MILANO

Background. The traditional nitroglycerin (NTG) head-up tilt test (HUTT) is time-consuming and the test duration is a barrier to widespread utilization in clinical practice. It was hypothesized that a short-duration protocol is not inferior to the traditional protocol as regards positivity rate and has a similar distribution of hemodynamic responses.
Method. Patients undergoing HUTT were randomized 1:1 to 10 min passive plus 10 min 0.3 mg NTG if the passive phase was negative (Fast) or to 20 min passive plus 15 min 0.3 mg NTG if the passive phase was negative (Traditional). A sample size of 277 patients for each group would have achieved 80% power to detect an expected difference of 0% with a non-inferiority margin of -10% using a one-sided t-test and assuming a significant level alpha of 0.025.
Result. A total of 554 consecutive patients (mean age 46.6± 19.3 years, 47.6% males) undergoing HUTT for suspected vasovagal syncope were randomly assigned to the Fast (n=277) or Traditional (n=277) protocol. A positive response, defined as the induction of syncope in presence of hypotension/bradycardia, was observed in 167 (60.3%) patients with Fast and in 162 (58.5%) patients with Traditional protocol. There was a trend for fewer vasodepressor responses (14.8% Fast versus 20.6% Traditional) which was significant during the passive phase (p=0.01). The optimal 10 min duration of the passive phase is consistent with the pattern of systolic BP changes observed during this phase. We showed a significantly increased HUTT positivity during the 10 min NTG phase in the Fast group compared to the first 10 min of NTG phase in the Traditional group (151 versus 101 patients, p=0.0001).
Conclusions. The diagnostic value of the Fast HUTT protocol is like that of the Traditional protocol and therefore the Fast protocol can be used instead of the Traditional protocol.

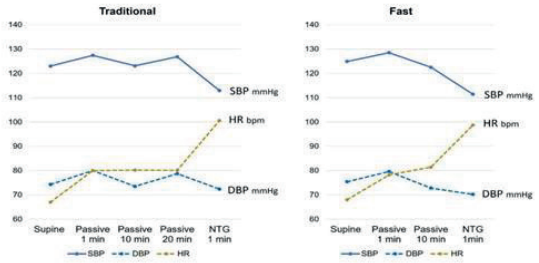

A30: CLINICAL PRESENTATION AND LONG-TERM OUTCOMES OF LEFT VENTRICULAR VS. RIGHT VENTRICULAR ARRHYTHMOGENIC CARDIOMYOPATHY

Elena Paiotti (b), Andrea Villatore (a), Lucia Molinari (b), Giulia Randi (b), Marianna Cariello (b), Gaia Souryal (b), Paolo Della Bella (a), Giovanni Peretto (a, b)
(a) IRCCS OSPEDALE SAN RAFFAELE, MILANO; (b) UNIVERSITÀ VITA-SALUTE SAN RAFFAELE, MILANO

Background. After the description of the left ventricular (LV) phenotype of arrhythmogenic cardiomyopathy (ACM), no studies attempted to compare clinical presentation and outcomes of LV vs. classic right ventricular (RV) ACM at long term follow-up.
Purpose. To describe clinical presentation and long-term outcomes of patients with LV vs. RV ACM.
Methods. From 2009 to 2022, 209 patients with ACM were retrospectively enrolled at a third-level center for ventricular arrhythmia (VA) management. RV ACM was defined according to the updated Task Force Criteria. LV ACM was defined based on the Padua criteria, provided endomyocardial biopsy was performed to rule out myocarditis. Patients with biventricular ACM (n=17) were excluded. The study endpoint was the occurrence of major VA (MVA, namely sustained VT, VF or appropriate ICD therapy) by 7-year follow-up.
Results. The study cohort includes 192 ACM inpatients, of whom 102 (53%) with isolated LV and 90 (47%) with RV phenotype. All patients presented with VA, including MVA in 64% of LV vs. 52% of RV patients (p=0.11). As compared with the RV group, LV patients were older (46 ±15 vs. 38±15 years) and had greater prevalence of females (40% vs. 20%), both p<0.001. In addition, while ventricular dilation was dominant among RV patients (56% vs. 29%, p<0.001), hypokinetic phenotype was more common in LV cases (44% vs. 25%, p=0.01; mean LVEF 49±13% vs. 60±6%, p<0.001). At discharge, betablocker and antiarrhythmic therapy was comparable between groups (88% LV vs. 90% RV, p=0.82). By a median follow-up of 7 (IQR 4-12) years, the incidence of MVA, was lower for LV ACM patients (respectively; 28% vs. 72% vs. 28%, p<0.001).
Conclusions. As compared with classic RV ACM, patients with isolated LV phenotype ALVC present a distinct epidemiological profile, and a lower likelihood of MVA at a median follow-up of 7 years.

A31: RISK/BENEFIT ANALYSIS ON THE PRIMARY PREVENTION OF SUDDEN CARDIAC DEATH IN BRUGADA SYNDROME

Elena Rossetto (b), Andrea Villatore (a, b), Simone Sala (a), Paolo Della Bella (a), Giovanni Peretto (a, b)
(a) IRCCS SAN RAFFAELE HOSPITAL, MILAN; (b) VITA-SALUTE SAN RAFFAELE UNIVERSITY, MILAN

Background. The 2022 ESC guidelines reported updated criteria for the primary prevention of sudden cardiac death (SCD) in Brugada syndrome

(BrS). In detail, subdivision has been made between arrhythmia-related and unexplained syncope to select suitable candidates to implantable cardioverter defibrillators (ICD) in primary prevention.
Purpose. To validate the new ESC guideline statements by conducting a risk/benefit analysis in a large cohort of patients with BrS at a referral center.
Methods. We retrospectively screened a large cohort of patients with BrS (n=238, median age 55 with IQR=47-65, 84% male) in regular follow-up at a third-level center for arrhythmia management. Patients undergoing ICD implant for the primary prevention of SCD were enrolled, to identify the subgroups with arrhythmia-related syncope and with unexplained syncope. The study endpoints were: 1) number of appropriate ICD shocks by 10-year follow-up; 2) rate of ICD-related complications.
Results. Of 155 ICD carriers, 142 (92%) were implanted in primary prevention. By a median follow-up of 10 years (IQR 5-10), only 7/142 patients (5%) received appropriate shocks, while 33 (23%) experienced a total of 37 ICD-related complications, including inappropriate shocks (n=16), catheter displacement/rupture (n=18), and infections (n=3). Our retrospective analysis identified 58/142 patients (41%) with history of syncope at the time of presentation, including 48 of probable arrhythmic type (34%), and 10 with unexplained syncope (7%). We found that all appropriate ICD shocks (7/7) occurred in patients with arrhythmia-related syncope, while none of the patients with unexplained syncope (0/10) had an appropriate shock (p<0.001). The rate of ICD-related complication was comparable between groups (25% vs. 20%, respectively, p>0.05).
Conclusions. Our retrospective risk/benefit analysis revealed that the application of the 2022 ESC guidelines for the primary prevention of SCD in BrS, allowed more accurate identification of high-risk patients, as well as potential sparing of relevant ICD-related complications.

A32: RIVAROXABAN TREATMENT DISCONTINUATION RATES IN ROUTINE CLINICAL PRACTICE IN ITALY IN PATIENTS WITH NVAF: RITMUS-AF

Carmine Pizzi (a), Leopoldo Pagliani (b), Luca Dalle Carbonare (c), Claudia Erminero (d), Davide Tosarello (d), Gian Piero Perna (e)
(a) UNIVERSITÀ DI BOLOGNA; (b) UNIVERSITÀ DI PADOVA; (c) UNIVERSITÀ DI VERONA; (d) BAJER ITALIA; (e) AZIENDA OSPEDALIERO-UNIVERSITARIA DELLE MARCHE

Background. Non-adherence to direct oral anticoagulants (DOACs) exposes patients with nonvalvular atrial fibrillation (NVAF) to increased risk of ischemic stroke and systemic embolism. However about one in five patients discontinues treatment within the first year. In Italy data on the DOACs discontinuation rate are scarce, especially in high-risk populations, such as diabetics or elderly patients (>75 years).
Methods. RITMUS-AF is a prospective, multicenter, observational cohort study conducted in NVAF patients observed in routine clinical practice in 31 Italian Centers reflecting the real use of rivaroxaban in all Italy Regions. Eligible patients were of age ≥18 years with a diagnosis of NVAF for whom the decision to initiate rivaroxaban treatment was made as per physician's routine treatment practice. The primary endpoint was the proportion of patients who discontinue rivaroxaban treatment during a follow-up period of 24 months. Secondary endpoints include reason for discontinuation, dose change, switch to another therapy and self-reported adherence to rivaroxaban therapy. The statistical evaluation was performed by using the software package SAS release 9.4 (64-bit) (SAS Institute Inc., Cary, NC, USA). Given the observational nature of the study, all statistical analyses had explorative and descriptive purposes.

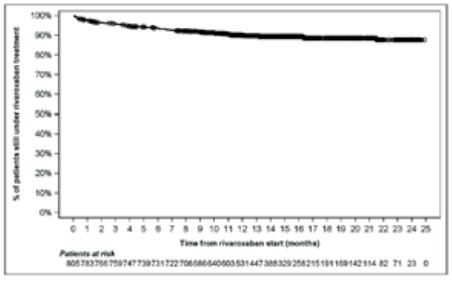

Results. Study starts in December 2019 and ended in June 2022. Screened patients were 821, of whose 805 patients were available for the primary endpoint analysis. Mean age was 75.1 and patients were at high risk of bleeding. The rate of patients who discontinued treatment was low – 10.31%. The total rate of discontinuation was 8.86 [95% CI: 7.06; 10.99] (100 patient/years). Time to rivaroxaban discontinuation curve shows most of the discontinuation in the first 3 months followed by a plateau in the subsequent months (figure 1). The main reasons for discontinuation were adverse events or physician decision. After 24 months adherence was high particularly in groups of naïve patients, younger patients, and patients with diabetes. Bleeding events were observed in 5.67% of patients (rate of major bleeding <0.5%) and ischemic stroke was detected in only one case (0.12%).
Conclusions. RITMUS-AF study, the first observational study on the persistence of direct oral anticoagulant therapy in daily clinical practice in Italy, demonstrated high treatment adherence and persistence in therapy among a population at high ischemic and hemorrhagic risk. The occurrence of ischemic stroke and bleeding events was relatively low, indicating the effectiveness and safety of the therapy. The study was conducted during the covid-19 pandemic but this does not seem to have affected either enrollment or adherence to therapy. These findings contribute to the understanding of the benefit-risk balance of direct oral anticoagulant therapy and may inform clinical decision-making regarding the use of direct oral anticoagulants in daily clinical practice.

A33: DISEASE HISTORY OF PATIENTS WITH NONVALVULAR ATRIAL FIBRILLATION (NVAF) TREATED WITH RIVAROXABAN IN ROUTINE CLINICAL PRACTICE IN ITALY

Gian Piero Perna (a), Piergiuseppe Agostoni (b), Egidio Imbalzano (c), Leopoldo Pagliani (d), Carmine Pizzi (e)
(a) AZIENDA OSPEDALIERO-UNIVERSITARIA DELLE MARCHE; (b) UNIVERSITÀ DI MILANO; (c) UNIVERSITÀ DI MESSINA; (d) UNIVERSITÀ DI PADOVA; (e) UNIVERSITÀ DI BOLOGNA

Background. NVAF patients in Italy are assigned to DOAC therapies and are recorded through a web-based therapeutic plan which is required by the National Health System to monitor the prescriptions of DOAC therapies. Nevertheless data regarding the disease history in patients with NVAF are scarce.
Methods. We evaluated the disease history of patients with NVAF enrolled in RITMUS-AF, a prospective, multicenter, observational cohort study conducted in NVAF patients observed in routine clinical practice in 31 Italian Centers reflecting the real use of Rivaroxaban in all Italy Regions. Eligible patients were of age ≥18 years with a diagnosis of NVAF for whom the decision to initiate Rivaroxaban treatment was made as per physician's routine treatment practice. The physician documented an initial visit, follow-up visits (site and telephone visits), and the end of observation/final visit for each patient in the electronic case report form (eCRF). Co-morbidities are any medical findings, whether or not they pertained to the study indication, that were still present before the start of therapy with rivaroxaban and were documented in the eCRF. The statistical evaluation was performed by using the software package SAS release 9.4.
Results. The enrolled population eligible set (805 pts) consists mostly of rivaroxaban-naïve patients (74%) without diabetes mellitus (80%), with a mean age of 75,1years. An electrical cardioversion within the last year was performed in 32.5% of 805 elegible patients, a catheter ablation in 5%, a cardiac pace-maker implantation in 16%. The mean age of the patients at first NVAF diagnosis was 72.7±10.22 years; the mean disease duration was 22.8±51.8 months. 441 patients (55%) had asymptomatic NVAF; 364 (45) had a symptomatic form of NVAF, mostly first diagnosed (39%) or paroxysmal (36.5%). The mean CHADS2 VASc Score value was 3.7, and 94% of patients had CHA2DS2 VASc Score value ≥2; 9.07% of patients had a history of prior bleeding; 161 (19.5%) patients had pharmacologically treated heart failure and 163 patients (20%) had Diabetes. Prior conditions were reported for 391 patients (49%), the most common were surgical and medical procedures (211 patients – 26.%), cardiac disorders (113 patients – 14%), nervous system disorders (78 patients – 10%), neoplasms benign, malignant, and unspecified (53 patients – 7%) and vascular disorders (48 patients – 6%), 50 patients (6%) had reported a history of stroke; mean Charlson Comorbility Index was 5 + 2. Mortality in eligible patients was 4% (32 fatal cases) and related to CHADS-VASc and to Charlson Comorbility Index.
Conclusions. The patients with NVAF treated with Rivaroxaban in italian clinical practice are mainly elderly, with a long disease history, at high ischemic and haemorrhagic risk and with multiple comorbidities. Mortality is relatively low and related to the patient' s complexity.

A34: PREVALENCE OF RIGHT AND LEFT ATRIUM NON PULMONARY VEIN TRIGGERS IN AMYLOIDOSIS PATIENTS UNDERGOING CATHETER ABLATION FOR ATRIAL FIBRILLATION

Nicola Pierucci (a), Vincenzo Mirco La Fazia (b), Marco Valerio Mariani (a), Agostino Piro (a), Cristina Chimenti (a), Andrea Natale (b), Carlo Lavalle (a)
(a) DEPARTMENT OF CLINICAL INTERNAL, ANESTHESIOLOGIC AND CARDIOVASCULAR SCIENCES, SAPIENZA UNIVERSITY OF ROME; (b) SAINT DAVID'S MEDICAL CENTER, TEXAS CARDIAC ARRHYTHMIA INSTITUTE

Background. Cardiac amyloidosis (CA) has been associated with an increased risk of atrial arrhythmias due to infiltration of the amyloid protein in the atrial wall. Though non-PV triggers are commonly seen in left atrium, they are also seen in the right side of the heart, so identifying them at the time of ablation is essential. Minimal data exists on the prevalence of triggers in amyloidosis patients.
Objective. The study evaluates the prevalence of non-PV triggers during catheter ablation in atrial fibrillation (AF) patients affected by cardiac amyloidosis.
Methods. This is a study including 74 consecutive patients with an established diagnosis of amyloidosis ATTR diagnosed with cardiac MRI or

myocardial biopsy that underwent their first AF catheter ablation. They underwent pulmonary vein (PV) isolation + isolation of left atrial posterior wall and superior vena cava. Additionally, extrapulmonary triggers, which are defined as ectopic triggers originating from sites other than PVs including left atrial appendage (LAA), coronary sinus (CS), interatrial septum, crista terminalis, mitral valve anulus were identified and ablation in all 74 patients. Post procedure, patients were followed up routinely with ECG during office visits, 7-day Holter monitor and event recorders for the duration of 1 year.

Results. Baseline characteristics of the study groups are: age 72.6, non-paroxysmal AF 51 (66.2%), Hypertension 45 (60.8%), Coronary artery disease 10 (13.5%), Obstructive sleep apnea 11 (14,8%), Dyslipidemia 24 (41.6%), BMI 28 ±6.6, la Diameter 4.71 ± 0.85, LV Ejection Fraction 53.9 ± 7,3, Mitral Valve regurgitation mild 31 (41,8%), Moderate 41 (55,4%), Severe 2 (2,7%), Pulmonary artery systolic pressure 45±6. Isoproterenol-challenge revealed non-PV triggers in 51 (68.9%) patients. These triggers were mostly mapped to LAA (39, 52.7%), CS (30, 40,5%), and crista terminalis (35, 47.3%). Besides, ectopic beats were seen originating from inter-atrial septum (19, 25.6%), mitral valve annulus (10, 13.5%). More than one of non-pulmonary vein trigger was found in (68%) patients. At 1-year after the ablation, 65 (87.8%) were arrhythmia-free off antiarrhythmic drugs.

Conclusions. Our findings suggest that non-PV triggers are highly prevalent in cardiac amyloidosis AF patients including a much higher rate crista terminalis firing compared to the standard population.

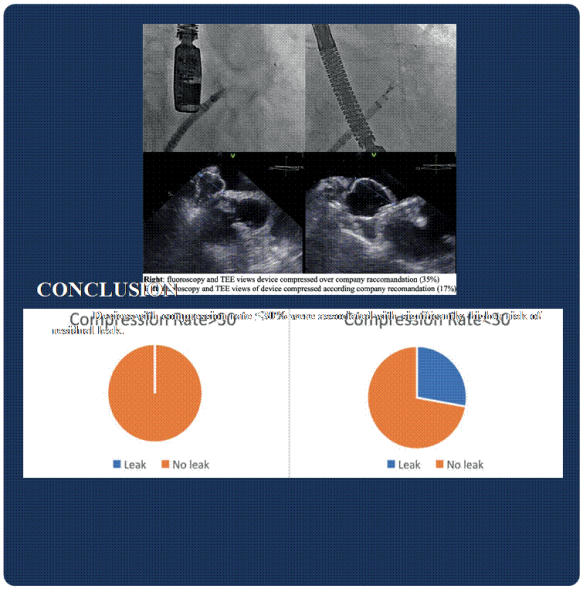

A35: VENTRICULAR TACHYCARDIA ABLATION IN PATIENTS IN WAITING LIST FOR HEART TRANSPLANTATION: A SINGLE CENTER EXPERIENCE

Alberto Preda (a), Lorenzo Gigli (a), Enrico Ammirati (b), Patrizio Mazzone (a)
(a) CARDIO-THORACO-VASCULAR DEPARTMENT, ELECTROPHYSIOLOGY UNIT, ASST GRANDE OSPEDALE METROPOLITANO NIGUARDA, MILAN, ITALY; (b) DE GASPERIS CARDIO CENTER, TRANSPLANT CENTER, NIGUARDA HOSPITAL, MILAN, ITALY

Background. the indication to catheter Ablation (CA) of ventricular tachycardia (VT) in patients with end-stage HF in waiting list for heart transplantation (HT) is particularly challenging and should consider many clinical and procedural concerns, therefore, the decision to perform VT CA should be made on a case-by-case basis. Here we report a single center experience from a Italy's leading HT center on management and decision making in patients waiting HT admitted for recurrent VTs/Ventricular Fibrillation (VF).

Methods. We enrolled all patients in waiting list for HT from April 2021 until April 2023 referred to our department for multiple (≥three) episodes of sustained VT/VF requiring shock therapy by the implantable cardioverter defibrillator (ICD). Patients were judged suitable for VT ablation if met several criteria. Short-term outcome was defined as length of in-hospital stay. Long term outcome was defined as: clinical VT recurrence, VT/VF treated with shock therapy, need for upgrade to a higher priority HT list due to arrhythmic cause and death for any cause.

Results. The study cohort included 14 patients (median age 51±11 years; 93% men). Six patients were in cardiogenic shock on admission. Seven patients underwent VT ablation. In total, 11 VT were recognized and ablated. The median follow-up was 375 ± 150 days. The ablation group reported lower in-hospital stay (median of 55 vs. 130 days). In the CA group, 2 patients had recurrence of VTs. In the non-CA group, 3 patients had early recurrence of clinical VT treated with multiple ICD-shocks leading to refractory cardiogenic shock requiring mandatory upgrade to HT urgency list. Compared to non-CA group, two patients of CA group improved INTERMACS class. No patient from CA group needed for upgrade to HT urgency list.

Conclusions. Our experience showed that through an accurate patient selection, CA may be a safe and effective option for VA burden reduction also among patients with end-stage HF on the HT waiting list.

A36: IS THERE A SIGNIFICANT 1-YEAR IMPACT ON TRICUSPID VALVE REGURGITATION EVOLUTION IN LEADLESS-PM IMPLANTED TAVI-SUBJECTS?

Nicolo Pellegrini (a), Antonella Sabatini (a, b, c), Solange Piccolo (a), Alessandro Varriale (a), Sofia Capocci (a), Luca Tomasi (a), Giacomo Mugnai (a), Elena Franchi (a), Ruggero Tomei (a), Flavio Ribichini (a), Bruna Bolzan (a)
(a) AOUI VERONA UNIV. HOSPITAL - CARDIOLOGY; (b) CARDIOVASCULAR CENTER OF SARASOTA, SARASOTA, FLORIDA, USA; (c) BOLZANO/BOZEN REGIONAL HOSPITAL, BOLZANO

Background. Leadless pacemaker implanted subjects (leadless-VVI and "AV") have been shown to experience lower chronic complications and less device-related reinterventions compared to transvenous ventricular pacemakers (Transvenous-VVI, VDD) in the general PM-implanted-population. Also, conventional transvenous pacemaker ventricular leads may interfere with the tricuspid valve structures yielding significant tricuspid valve regurgitation (TR). Subject who underwent a Transcutaneous Aortic Valve Implant (TAVI), needing a PM could be indicated to a leadless pacing.

Purpose. This single-center study focusses on tricuspid valve disease to demonstrate the impact/benefits of leadless pacing at 1-year follow-up period by comparing tricuspid valve regurgitation grading at implant time and at 1-year follow-up in a subgroup of subjects who underwent TAVI.

Methods. This study is a retrospective, observational research study: 78 consecutive subjects (February 17, 2016 - January 18, 2023), treated in our Center, implanted with Micra VVI/AV leadless-PMs Micra MC1VR01 and Micra AVMC1AVR1, Medtronic, Inc., were evaluated at implant time via transthoracic echocardiography, and at 1-year follow-up period. Tricuspid valve disease was evaluated. A subgroup of 28 subjects underwent TAVI at basal time.

Results.

		Results	
Total Number of Subjects		129	
Total Male		108	84%
Total Female		21	16%
Number of subjects with 1-Year-Follow-up-Echocardiography		28	22%
Number of subjects who underwent TAVI		36	28%
Number of implanted subjects with Leadless-PM		78	60%
Number Leadless-PM implanted Subjects with Remote Monitoring		45	58%
Age (average)		76 ± 9	
Weight (average)		82 ± 18	
Height (average)		171 ± 11	
BMI (Average)		28 ± 5	
BSA (Average)		2 ± 0	
Number of subjects who underwent Surgical Aortic Valve Substitution		15	12%
Medtronic CoreValve™		24	67%
Medtronic Evolut™ PRO		0	0%
Edwards SAPIEN 3		14	39%
General Population Subjects: EF	Basal TTE Echocardiography	56 ± 8	
General Population Subjects: EF	1 Year F-up TTE Echocardiography	53 ± 8	
TAVI Subjects Subjects: EF	Basal TTE Echocardiography	55 ± 6	
TAVI Subjects Subjects: EF	1 Year F-up TTE Echocardiography	56 ± 6	

General Population Subjects						
Number of Subjects: Basal Echo	59		Number of Subjects: 1 Year F-up Echo	25		p-Values
Tricuspid Regurgitation: Mild	42	71%	Tricuspid Regurgitation: Mild	13	52%	0,1013
Tricuspid Regurgitation: Mild-Intermediate	3	5%	Tricuspid Regurgitation: Mild-Intermediate	2	8%	0,6056
Tricuspid Regurgitation: Intermediate	14	24%	Tricuspid Regurgitation: Intermediate	6	24%	0,9787
Tricuspid Regurgitation: Intermediate-Severe	0	0%	Tricuspid Regurgitation: Intermediate-Severe	1	4%	0,5264
Tricuspid Regurgitation: Severe	0	0%	Tricuspid Regurgitation: Severe	3	12%	0,0483

Subjects who underwent TAVI						
Number of Subjects: Basal Echo	20		Number of Subjects: 1 Year F-up Echo	12		p-Values
Tricuspid Regurgitation: Mild	16	80%	Tricuspid Regurgitation: Mild	6	50%	0,0821
Tricuspid Regurgitation: Mild-Intermediate	1	5%	Tricuspid Regurgitation: Mild-Intermediate	2	17%	0,2161
Tricuspid Regurgitation: Intermediate	3	15%	Tricuspid Regurgitation: Intermediate	2	17%	0,9525
Tricuspid Regurgitation: Intermediate-Severe	0	0%	Tricuspid Regurgitation: Intermediate-Severe	1	8%	0,6309
Tricuspid Regurgitation: Severe	0	0	Tricuspid Regurgitation: Severe	1	8%	0,6309

Conclusions. The main results from this study show that many patients at higher risk of transvenous pacemaker complications relatively to the tricuspid valve have similar tricuspid valve disease at implant time as compared to 1 year-F-up time, implicating a negligible impact of leadless pacing on the tricuspid valve compared to transvenous lead PMs in this subgroup of population. According to our data, considering the already demonstrated benefits of leadless pacing in subjects at high risk of PM complications, determination should be made to increment the rate of leadless PM implants.

A37: IS EXCESS EPICARDIAL FAT IN THE PRESENCE OF ELEVATED CALCIUM SCORE LEVELS THE PREDOMINANT EARLY CONTRIBUTOR TO SUBCLINICAL INFLAMMATION PHENOTYPING INTO ECG ABNORMALITIES?

Antonella Sabatini (a, b), Olena Mahneva (b), Mahfouz El Shahawy (b)
(a) AOUI VERONA UNIV. HOSPITAL - CARDIOLOGY; (b) CARDIOVASCULAR CENTER OF SARASOTA, SARASOTA FLORIDA, USA

Background. Elevated EFV has been recently reported to be prevalent and a possible contributor to higher cardiovascular morbidity and mor-

tality, particularly in the presence of elevated CACS. In addition, Excess EFV/cardio obesity has been reported to be an independent cardiovascular (CVD) risk marker.
Purpose. To assess whether elevated EFV in the presence of CACS has significant effects on the cardiac electrical activity as evidenced by the 12-lead ECG, in addition to triggering inflammation in the microvasculature (C2), altering the lipid profile and altering BP rise PME, in comparison to population without elevated EFV and the same demographic.
Methods. 2932 asymptomatic subjects, 50 years +, underwent cardiovascular disease (CVD) risk assessment using the Early Cardiovascular Disease Risk Scoring System (ECVDRS). The ECVDRS includes 10 cardiovascular tests, 7 vascular and 3 cardiac. 334 subjects underwent a cardiac CT for EFV and CACS determination. Out of these, 55 participants (43M + 12F) with significantly elevated CACS and elevated or normal EFV were further assessed regarding their exercise level, structural/functional abnormalities, presence of significant OCAD or INOCAD as assessed by cardiac catheterization, exercise stress test, and nuclear stress test. Successively, in 31 non obese female subjects, precordial 12-lead-ECG QRS voltages were evaluated.
Results.

	H-High CAC and Elevated EFV	H-High CAC and Elevated EFV (%)	L-High CAC and Low EFV	L-High CAC and Low EFV (%)	p-Values
# of subjects	33	60%	22	40%	0.020030
Age	68		69		0.496305
# of Females	6	18%	6	27%	0.433057
# of Males	27	82%	16	73%	0.423679
C1	14.13		13.06		0.533995
# of Abnormal C1	7	21%	7	32%	0.376571
C2	5.23		3.73		0.010711
# of Abnormal C2	9	27%	12	55%	0.041398
# of Abnormal CIMT	19	58%	13	59%	0.911140
pro-BNP	188.24		114.23		0.516622
CRP	0.53		0.19		0.260905
# of Abnormal BPrisePME	24	73%	15	68%	0.719150
BP-risePME	39.09		27.64		0.023615
Micro-Albuminuria	0.51		0.19		0.038052
LDL-c	74.70		94.32		0.034000
HDL-c	47.09		51.50		0.176407
Triglycerides	147.55		110.86		0.031618
Glycemia	104.03		92.82		0.073606
Waist Circumference	43.67		37.26		0.000144
ECVDRS	7.75		6.64		0.243630
ACC/AHA Risk Score	18.86		22.06		0.430192
ECG Abnormalities	14	42%	6	27%	0.025665
Ca Score	1345.19		997.33		0.366262
Epicardial Fat	153.24		69.76		0.000000

	Non- Obese Females: n = 31	
	Group 1: n=21 (68%)	Group 2: n=10 (32%)
Average EFV (cm^3)	65.5	100
Subjects with ECG with low QRS voltage	10 (47.6%)	7 (70%)

Conclusions.
- Increased CACS in the presence of normal EFV is not as strongly associated with significant inflammatory factors, obstructive CAD, and functional abnormalities as in excess EFV subjects.
- It is possible that increased CACS in the presence of normal EFV may be associated with perivascular rather than intravascular calcium deposition.
- Subjects with elevated EFV are associated with significant prevalence of ECG abnormalities: low precordial QRS voltage on ECG and arrhythmias.
- Based on our data, we recommend lifestyle modification with an emphasis on high levels of exercise along with novel treatment reported recently to decrease EFV aiming to reduce the risk of arrhythmias. Early detect to protect!

A38: UTILIZZO DELLA MAPPA DI IMPEDENZA PER IDENTIFICARE LE STRUTTURE NON CONDUTTIVE DURANTE ABLAZIONE DELL'ISTMO CAVO TRICUSPIDALICO

Riccardo Sciarroni (a), Antonio Crocamo (a), Matteo Fioravanti (b), Gianluca Gonzi (a), Luca Bearzot (a), Giampaolo Niccoli (a), Diego Ardissino (a), Maria Francesca Notarangelo (a)
(a) AZIENDA OSPEDALIERA-UNIVERSITARIA DI PARMA; (b) BIOSENSE WEBSTER MILANO

Background. L'ablazione dell'istmo cavo-tricuspidalico (ICT) è spesso inficiata dalla variabilità anatomica di strutture costituite da tessuto non conduttivo (NCS): la valvola di Eustachio (ER), il lembo della valvola tricuspide (TR) e la valvola di Tebesio (TV), la cui presenza può associarsi a mancato blocco istmico nonostante un elevato numero di erogazioni e a recidive post-ablazione. Poichè tali strutture hanno proprietà conduttive diverse dal tessuto atriale è plausibile che siano caratterizzate da impedenza tissutale propria, e che pertanto possano essere identificate mediante una mappa di impedenza (IM). Obiettivi dello studio sono stati: 1) caratterizzare l'ICT mediante IM, al fine di identificare le NCS; 2) eseguire ablazione dell'ICT mirata all'isolamento del solo tessuto conduttivo combinando la IM alla tecnica del Maximum Voltage Gradient (MVG), al fine di valutare l'efficacia di tale strategia in acuto e durante il follow-up.
Materiali e metodi. Da 01/2021 a 09/2023 è stata eseguita IM e mappa di substrato dell'ICT (sistema CARTO 3, V7, Smarttouch SF, Biosense Webster), senza utilizzo di fluoroscopia, in tutti i pazienti sottoposti ad ablazione di flutter atriale tipico. Una riduzione dell'impedenza di 15 Ohm rispetto all'impedenza media atriale è stata considerata il cut-off per definire la presenza di NCS. Sono state costruite le mappe di substrato secondo la tecnica del MVG (soglie 0.5-2.5 mV), ricercando particolarmente i canali ad alto voltaggio laddove l'IM rilevava la presenza di NCS. L'ablazione è stata effettuata solo nei canali ad alto voltaggio (W45, AI500).
Risultati. Su 48 pazienti (età media di 68±13 anni; uomini 92%; volume medio dell'atrio destro 153 mL; numero medio di punti per mappa 1205) l'utilizzo della IM ha consentito di identificare la presenza delle NCS in 25 (52%). La distribuzione delle NCS e del voltaggio medio suddiviso per quadranti è riportato nelle figure B-C. Il numero medio di applicazioni di RF per ottenere blocco istmico è stato significativamente minore (6.3 vs 10; p=0.007) nei pazienti in cui sono state identificate le NCS. Nel 60% di tali pazienti sono state effettuate erogazioni di RF in canali ad alto voltaggio rilevati nel quadrante in cui era presente la NCS (OR 3.42, p=0.04). In tutti i pazienti è stato ottenuto blocco istmico in acuto; ad un follow-up medio di 186 giorni non è stata documentata nessuna recidiva.
Conclusioni. L'utilizzo della IM combinata alla tecnica del MVG è una tecnica efficace per ottenere il blocco istmico con un ridotto numero di erogazioni. Infatti identificare le NCS consente di ricercare i canali ad alto voltaggio con maggior precisione (scavalcando le NCS) ed eseguire pertanto ablazioni sempre a contatto con il tessuto. Tale accortezza risulta infatti fondamentale per la riuscita della procedura.

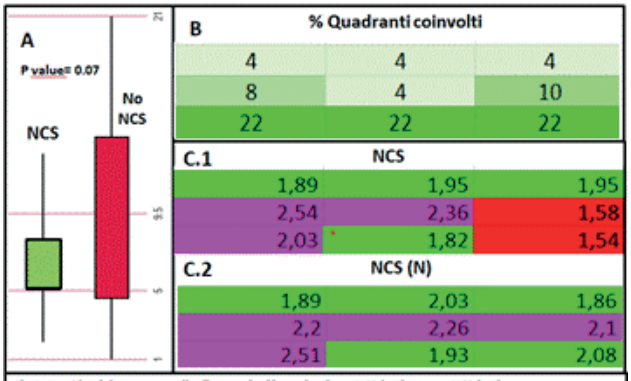

Fig A: Box Plot del numero medio di erogazioni in pazienti con NCS (a.1) e senza NCS (a.2).
Fig B: Heat Map di distribuzione delle NCS nei nove quadranti dell'ICT.
Fig C: Heat Maps di distribuzione del voltaggio medio (espresso in mV) nei nove quadranti nell'ICT.

A39: ATRIAL FIBRILLATION PREVALENCE AND PROGNOSTIC ROLE IN CARDIAC AMYLOIDOSIS: A MULTICENTER STUDY

Lucio Teresi (a), Giancarlo Trimarchi (a), Roberto Licordari (a), Alessia Argirò (b), Paolo Liotta (a), Giovanni Taverna (a), Giuseppe Dattilo (a), Pasquale Crea (a), Antonio Micari (a), Scipione Carerj (a), Francesco Cappelli (b), Gianluca Di Bella (a)
(a) GAETANO MARTINO UNIVERSITY HOSPITAL, MESSINA; (b) CAREGGI UNIVERSITY HOSPITAL, FLORENCE

Background. Transthyretin amyloidosis (ATTR) is an infiltrative disease due to transthyretin (TTR) tissue accumulation. Both patients without mutations in the TTR gene (wild-type ATTR, ATTRwt) and those with such mutations (variant ATTR, ATTRv) may develop cardiac amyloidosis (CA). Atrial fibrillation (AF) is the most common arrhythmia in CA. Indeed, it has been described in up to 70% of CA, even if its prognostic role has been poorly investigated.
Purpose. The current study aimed to investigate AF prevalence and prognostic impact in a large cohort of CA amyloidosis patients.
Methods. Patients with at least 6 months follow-up were recruited by two Italian CA referral centers in a retrospective cohort study. CA diagnosis was performed through an invasive or non-invasive approach and AF was diagnosed only when a 12-lead pathognomonic electrocardiogram was available at diagnosis or during the follow-up. All-cause mortality was considered as endpoint.
Results. In our study 251 CA patients were retrospectively recruited (210 ATTRwt and 41 ATTRv). They were mainly old male (89% male, average age 78±8 years). Among them, 239 had a bone scintigraphy which showed Perugini score 2-3 in 91% of cases (n=219). AF was observed in 149 patients (59%) without significative difference for gender (p=0.57), age (p=0.10), ATTRwt and ATTRv (n=123 and n=26 respectively, p=0.61), New York Heart Association (NYHA) class (p=0.45) and NT-proBNP (p=0.45). However, AF was more common in patients with Perugini score 2-3 at bone scintigraphy than in patients with Perugini score 1 (n=134 and n=15 respectively, p=0.02). Furthermore, at echocardiography patients with AF had higher interventricular septum (p=0.008) and posterior wall diameter (p=0.001), higher left atrial volume (p=0.01) and systolic pulmonary artery pressure (p=0.01), lower tricuspid annular plane systolic excursion (p=0.001) and left ventricle global longitudinal

strain (p=0.02). During a median follow-up of 24 months (interquartile range 15-38 months) 57 patients (23%) died for any cause without significant difference among patients with and without AF (n=39 and n=18 respectively, p=0.11) in the general population, or specifically in ATTRwt (p=0.32) or ATTRv (p=0.20) patients. Furthermore, at univariate analysis AF was not a significant predictor for all-cause mortality (p=0.62), while NT-proBNP was the only strong prognostic predictor analyzed (p=0.005).
Conclusions. AF is a frequent finding in CA and it is more common in patients with higher cardiac involvement showed by Perugini score at bone scintigraphy or by pathognomonic findings at echocardiography, irrespective of ATTR subtype. However, overall mortality in CA is not significantly influenced by AF itself. Therefore, AF could be probably considered an epiphenomenon of the disease whose mortality is mainly related to heart decompensation severity, which can be expressed by NT-proBNP.

A40: LEFT ATRIUM ELECTRICAL CHARACTERIZATION IN PATIENTS WITH PERSISTENT ATRIAL FIBRILLATION

Stefano Valcher (a), Giulio Falasconi (a), Diego Penela Maceda (a), Antonio Taormina (a), Carlo Ceriotti (a), Paola Galimberti (a), Guido Del Monaco (a), Alessandro Giaj Levra (a), Alessia Latini (a), Francesco Villella (b), Fabrizio Bologna (c), Stefano Paganini (d), Benedetta Grossi (d), Gianluigi Condorelli (a), Antonio Frontera (a)
(a) HUMANITAS RESEARCH HOSPITAL; (b) UNIVERSITÀ DEGLI STUDI DI MILANO-BICOCCA; (c) ISTITUTO CLINICO CITTÀ STUDI MILANO; (d) POLITECNICO DI MILANO

Background. A small but significant number of patients cannot achieve freedom from atrial fibrillation (AF) owing to non–pulmonary vein (PV) triggers or drivers. The left atrium posterior wall (LAPW) is considered an area of interest for the origin and the perpetuation of AF.
Aims. In this study we sought to characterize LAPW in patients with persistent AF. Specifically, this involves describing the electrophysiological characteristics, including rotational and focal activities during AF, propagation uniformity during sinus rhythm (SR), and defining functional sites during pulmonary vein isolation (PVI).
Methods. Consecutive patients undergoing catheter ablation for persistent AF were enrolled. The navigation system was CARTO3 for all the procedures. Pentaray and Octaray catheters were employed to collect all high-density electrogram (EGM) data. For each patient, the CARTOFINDER module was utilized during atrial fibrillation (AF) to detect rotational and focal activities. After electrical cardioversion, the same high-density mapping protocol was conducted during sinus rhythm (SR) and paced rhythm (PR). Mapping during PR was obtained by introducing an additional beat from the coronary sinus every three sinus beats. Rotational and focal activities during AF were pinpointed and correlated with signals recorded during SR and PR. EGMs were assessed in terms of voltage amplitude (mV), signal duration (ms), and fractionation.
Results. Areas of focal activity were found in all patients. In most cases, these were located on the LAPW (11 out of 16; 69%), the roof (11 out of 16; 69%), and around the left atrial appendage (11 out of 16; 69%). Rotational activity areas, on the other hand, were only observed in a few patients, mostly on the atrial roof (3 out of 16; 19%). In all patients, areas of slow conduction were identified during SR, mostly corresponding to regions with a higher concentration of focal and rotational activities. Furthermore, in these areas, the voltage amplitudes recorded during SR and PR were significantly lower compared to those in healthy areas (SR: 1.19 ± 0.68 mV vs. 2.79 ± 0.87 mV, p<0.05; PR: 1.18 ± 0.62 mV vs. 2.72 ± 0.73 mV, p<0.05). Similarly, the signal duration was significantly longer in these regions (SR: 49.8 ± 11.4 ms vs. 28.3 ± 8.1 ms, p<0.05; PR: 51.5 ± 10.8 ms vs. 30.1 ± 6.4 ms, p<0.05). Lastly, the signals in these areas were more frequently fragmented compared to normal regions.
Conclusions. A correlation exists between rotational activity during atrial fibrillation and signal abnormalities during SR and PR. These abnormalities are primarily localized on the roof and LAPW. Identifying these areas during sinus rhythm and pacing could facilitate the recognition of potential targets for atrial fibrillation ablation. However, further larger studies are needed.

A41: TRATTAMENTO DELLA FIBRILLAZIONE ATRIALE MEDIANTE PULSED FIELD ABLATION: SICUREZZA, EFFICACIA E ANDAMENTO DEI BIO-MARCATORI CARDIACI

Yari Valeri (a, b), Paolo Compagnucci (a, b), Giovanni Volpato (a, b), Quintino Parisi (b), Laura Cipolletta (b), Francesca Campanelli (a, b), Leonardo D'Angelo (a, b), Michela Casella (a), Antonio Dello Russo (a, b)
(a) UNIVERSITÀ POLITECNICA DELLE MARCHE, ANCONA; (b) CLINICA DI CARDIOLOGIA E ARITMOLOGIA "OSPEDALI RIUNITI", ANCONA

Introduzione. L'ablazione a campo pulsato (Pulsed Field Ablation, PFA) è una modalità di ablazione trans-catetere per il trattamento della fibrillazione atriale (FA), che determina l'elettro-porazione irreversibile e selettiva dei cardiomiociti, mediante impulsi elettrici ad alta ampiezza.
Obiettivi. Valutare il trend peri-procedurale dei marcatori di necrosi miocardica, la sicurezza e l'efficacia a medio termine nei pazienti sottoposti a PFA per il trattamento della fibrillazione atriale.
Materiali e metodi. Abbiamo condotto uno studio osservazionale e retrospettivo coinvolgendo 100 pazienti (età media 65 ± 9,2 anni; 59% uomini) con FA parossistica e persistente sottoposti a PFA. Per ogni paziente sono state effettuate 4 erogazioni in configurazione "basket" e 4 in configurazione "flower" per ogni vena polmonare. In tutte le procedure, per valutare sia il numero di vene polmonari sia il contatto/interfaccia catetere-parete è stato utilizzato l'ICE. Tutti i pazienti sono stati sottoposti a prelievi ematici seriati, compresa la hsTnI al tempo 0 e a 3, 24 e 48 ore post-procedura. L'end-point primario di efficacia era la libertà da recidive di FA, valutata mediante periodici Holter 24 ore; l'end-point primario di sicurezza era rappresentato dalle complicanze nei primi 120 giorni.
Risultati. Sono stati inclusi nell'analisi 100 pazienti; le caratteristiche cliniche e procedurali di base sono riassunte in Tabella 1. Dopo un follow-up mediano di 8 mesi, la sopravvivenza libera da qualsiasi recidiva di FA è stata del 92% (n=91/100). Tutti i pazienti avevano valori normali di hsTnI al basale (6 ng/l, IQR 4-9); è stato riscontrato
un incremento esponenziale dei valori di hsTnI in tutti i pazienti a 3 ore post-procedura (15000 ng/l, IQR 7200-24300) e successivamente una progressiva riduzione a 24 ore (6000 ng/l, IQR 4300-9600) e 48 ore (4500 ng/l, IQR 3000-7300). Ad eccezione di uno pseudo-aneurisma e di una FAV femorale, non sono stati riscontrati ulteriori eventi avversi nel follow-up mediano di 120 giorni, quali tamponamento cardiaco, ictus, lesione del nervo frenico, stenosi delle vene polmonari e lesioni esofagee.
Conclusioni. La PFA sembra presentare vantaggi in termini di riduzione dei tempi procedurali rispetto alle modalità tradizionali di ablazione, a discapito di un maggiore utilizzo della fluoroscopia. L'incremento della hsTnI è superiore a quanto osservato in letteratura rispetto alla crio-ablazione e la radiofrequenza, probabilmente legato ad una maggior selettività miocardica ed al compimento di lesioni più antrali con la PFA; sarebbe tuttavia necessario, per confermare o confutare i dati, un confronto con pazienti appaiati sottoposti ad ablazione con altre forme di energia. Nonostante un breve follow-up mediano, la PFA sembra essere altamente efficace e sicura, senza evidenza di complicanze cardiache ed extra-cardiache significative a medio termine.

Age (years) – mean (ST)	**65** (± 9,2)
Male Gender – no. (%)	59 (59%)
CHA2DS2-VASc – median (IQR)	2 (1 – 4)
Risk factors:	
_ hypertension – no. (%)	71 (71%)
_ DM type II – no. (%)	12 (12%)
_ eGFR <45 ml/min – no. (%)	1 (1%)
_ Chronic coronary syndrome – no. (%)	17 (17%)
_ BPCO – no. (%)	7 (7%)
_ BMI – median (IQR)	27 (24 – 30)
Antiarrhythmic drugs at admission:	
_ amiodarone – no. (%)	12 (12%)
_ flecainide – no. (%)	44 (44%)
_ beta-blocker – no. (%)	63 (63%)
Echocardiogram:	
_ LVEF (%) – median (IQR)	60 (55 – 64)
_ iLVA (ml/m2)– median (IQR)	38 (27 – 43)
Peri-procedural ECV – no. (%)	18 (18%)
Time in left atrium (min) – mean (SD)	27 (±5)
Skin-to-skin duration (min) – mean (SD	78 (±31)

A42: RELATIONSHIP BETWEEN AUTONOMIC FUNCTION AND VENTRICULAR ARRHYTHMIAS IN CARRIERS OF ICDS TREATED WITH SACUBITRIL/VALSARTAN: INTERVENTIONIST STUDY

Andrea Vannelli (a), Edoardo Navazio (a), Maria Grazia Ricci (a), Claudia Tamburro (a), Mirco La Fazia (a), Domenico Sergi (a), Gaetano Idone (a), Carlo Chiaramonte (a), Lucy Barone (a), Francesco Barillà (a)
(a) POLICLINICO TOR VERGATA

Background. Heart failure remains a major cause of morbidity, mortality, and hospitalization worldwide. Currently, pharmacological therapy for heart failure with reduced ejection fraction (HFrEF) is based on the use of four main pharmacological classes, of which the association between Sacubitril, a neprilysin inhibitor, and Valsartan is one of the cornerstones. In addition, several recent studies have shown that this pharmacological class reduces the incidence of ventricular arrhythmias and the number of appropriate defibrillator shocks, although the mechanism is still unclear. Autonomic function is known to be impaired in heart failure. Therefore, in patients with HFrEF, an increase in sympathetic autonomic activity is associated with the occurrence of potentially li-

fe-threatening ventricular arrhythmias. One of the methods used to assess the activity of the cardiac autonomic nervous system is the study of Heart Rate Variability (HRV), the reduction of which has been associated with the occurrence of ventricular arrhythmias.
Objective. The aim of our study is to investigate whether administration of Sacubitril/Valsartan can affect sympathetic tone and whether this correlates with a reduction in arrhythmia burden.
Methods. We enrolled 13 patients with HFrEF who were carriers of an ICD capable of assessing HRV using the SDANN parameter (Standard Deviation of the 5-minute Average NN intervals) and who were eligible for treatment with Sacubitril/Valsartan. All patients underwent regular device checks with assessment of HRV by analysis of SDANN, ventricular arrhythmias, and any therapies by the device before initiation of therapy with Sacubitril/Valsartan and at follow-up of 6 and 12 months after initiation of therapy.
Results. Statistical analysis of the data revealed a significant increase in the SDANN parameter from baseline at both the first 6-month follow-up (85.15 + 31 ms vs. 93.15 + 29 ms, p-value 0.05) and the second 12-month follow-up (85.15 + 31 ms vs. 102.16 + 26.7 ms, p-value 0.05). When analyzing the data on ventricular arrhythmias, which was limited to the values of the first follow-up, an inverse relationship was found between the values of the SDANN parameter and the number of ventricular tachycardias (OR 0.011, p-value 0.036). In addition, there was a statistically significant association between the values of the SDANN parameter and the dosage of Sacubitril/Valsartan at the 12-month follow-up (OR 168, p-value 0.014).
Conclusions. The results of the study show that in patients with HFrEF carrying an ICD and having an indication for therapy with Sacubitril/Valsartan, the SDANN parameter was statistically significantly increased compared to baseline values at both the first 6-month follow-up and the second 12-month follow-up. In addition, limited to the first follow-up, there was an inverse association between the values of the SDANN parameter and the number of ventricular tachycardias and, limited to the second follow-up, an association between the values of the SDANN parameter and the dosage of Sacubitril/Valsartan. These results, although from a small patient sample, confirm the dose-dependent efficacy of Sacubitril/Valsartan therapy in improving autonomic activity in HFrEF patients and also suggest efficacy in reducing ventricular arrhythmia burden. This last aspect should be further investigated by enrolling a larger number of patients, as it has not been clarified in the literature.

A43: VALIDAZIONE DELLO SCORE UB-ROSC PER PREDIRE IL RITORNO DELLA CIRCOLAZIONE SPONTANEA IN PAZIENTI CON ARRESTO CARDIACO EXTRAOSPEDALIERO

Luca Vicini Scajola (b), Maria Luce Caputo (a), Roman Burkart (c), André Wilmes (c), Ruggero Cresta (d), Claudio Benvenuti (d), Roberto Cianella (e), Roberto Primi (b), Alessia Currao (b), Sara Bendotti (b), Sara Compagnoni (b), Francesca Romana Gentile (b), Luciano Anselmi (e), Catherine Klersy (b), Simone Savastano (b), Enrico Baldi (b)
(a) ISTITUTO CARDIOCENTRO TICINO; (b) FONDAZIONE IRCCS POLICLINICO SAN MATTEO; (c) IAS; (d) FONDAZIONE TICINO CUORE; (e) FEDERAZIONE TICINALE CANTONESE SERVIZI AUTOAMBULANZE

Background. La predizione della probabilità di ritorno alla circolazione spontanea (ROSC) durante l'arresto cardiaco extraospedaliero (OHCA) è una delle più grandi sfide nella scienza della rianimazione. Lo score Utstein Based-ROSC (UB-ROSC) è stato sviluppato per predire la probabilità di ROSC nelle vittime di OHCA. Lo scopo dello studio è di convalidare il punteggio UB-ROSC utilizzando due grandi registri OHCA basati su criteri Utstein.
Materiali e metodi. I pazienti vittima di arresto cardiaco extraospedaliero di qualsiasi eziologia verificatisi tra il 1° gennaio 2019 e il 31 dicembre 2021, inseriti in questi 2 registri, sono stati inclusi nello studio di validazione prospettico. Per la convalida dello score è stato utilizzato un modello di calcolo di area sotto la curva ROC (AUC ROC) di discriminazione, utilizzando un 10-fold cross-validation test. Il punteggio dello score è stato rapportato al raggiungimento di un ROSC prolungato e quindi alla sopravvivenza al ricovero in ospedale.
Risultati. Nello studio sono stati inclusi 14.715 pazienti. Un ROSC prolungato è stato ottenuto in 3.151 pazienti (21%). Complessivamente, il modello UB-ROSC ha mostrato una buona capacità di discriminazione (AUC 0,72, 95% CI 0,71-0,73). La curva del rischio predetto è pressoché lineare ed il modello è risultato ben calibrato. Nel sottogruppo di UB-ROSC a bassa probabilità (ossia con un punteggio inferiore o uguale a -19) solo il 9% dei pazienti ha raggiunto un ROSC prolungato. Questa percentuale è salita al 35% per il punteggio UB-ROSC intermedio, compreso tra -18 e 12 (OR 5,3, 95% CI 2,9-9,4, P<0,001). Infine, nell'85% dei pazienti con valori UB-ROSC superiori o uguali a 13 è stato ottenuto un ROSC (OR 52,1, 95%CI 15,6-173,0, P<0,001).
Conclusioni. Lo score UB-ROSC può rappresentare uno strumento affidabile per prevedere la probabilità di ROSC. La sua applicazione può aiutare nel processo decisionale fornendo una stratificazione realistica della probabilità di raggiungimento del ritorno stabile alla circolazione spontanea e al ricovero in ospedale.

A44: REDUCED RIGHT VENTRICULAR OUTFLOW TRACT STRAIN AT CARDIAC MAGNETIC RESONANCE CORRELATES WITH LOW-VOLTAGE AREAS AT UNIPOLAR ELECTROANATOMIC MAPPING IN PATIENTS WITH BRUGADA SYNDROME.

Giacomo Virgili (a), Maurizio Pieroni (a), Michele Ciabatti (a), Chiara Zocchi (a), Pasquale Notarstefano (a), Valentina Tavanti (d), Martina Nesti (a), Carlo Fumagalli (b), Francesca Raimondi (b), Gianni Pedrizzetti (c), Iacopo Olivotto (b), Leonardo Bolognese (a)
(a) OSPEDALE SAN DONATO DI AREZZO - DIPARTIMENTO CARDIOVASCOLARE - AREZZO, ITALIA; (b) AZIENDA OSPEDALIERA UNIVERSITARIA CAREGGI - UNIT CARDIOMIOPATIE - FIRENZE, ITALIA; (c) UNIVERSITÀ DI TRIESTE - DIPARTIMENTO DI INGEGNERIA E ARCHITETTURA - TRIESTE, ITALIA; (d) OSPEDALE SAN DONATO DI AREZZO - DIPARTIMENTO DI RADIOLOGIA - AREZZO, ITALIA

Background. Brugada Syndrome (BrS) was traditionally considered as a pure channelopathy, but right ventricular outflow tract (RVOT) pathological and electroanatomic (EAM) abnormalities are increasingly recognized. Novel cardiac magnetic resonance (CMR) tools can identify subtle myocardial abnormalities in many cardiomyopathies.
Objectives. We aimed to assess the presence of RVOT abnormalities by CMR-derived strain in BrS patients. We also sought to evaluate the relationship between CMR parameters and RVOT pathological areas at EAM.
Methods. We retrospectively enrolled BrS patients undergoing CMR and RV endocardial EAM. Abnormal voltage areas were defined by the presence of signal amplitude <4mV at unipolar mapping and signal amplitude <1.5mV at bipolar mapping. We included a control group of 15 healthy subjects undergoing CMR.
Results. We studied 16 patients, 12/16 males, mean age 42±9 years. In all cases CMR showed normal left and right ventricular ejection fraction (LVEF 57±4%, RVEF 56±6%). RVOT peak strain values were significantly impaired in BrS patients compared to controls (-17.9±8.6% vs -26.4±9.5%, p=0.011), while RV-GLS did not differ between the two groups (-22.2±4.0% vs 24.6±2.5%, p=0.061). EAM showed the presence of pathological voltages at both unipolar and bipolar mapping in 12 patients, abnormal unipolar and normal bipolar maps in 1 case and both unipolar and bipolar normal maps in 3 patients. Median extent of abnormal voltage areas was 5.3 cm^2 [IQ 1-4=0.6-9.3 cm^2] at unipolar and 4.1 cm^2 [IQ 1-4=0.7-7.5 cm^2] at bipolar map. RVOT peak strain showed a significant correlation with abnormal voltage areas at unipolar EAM (r=0.546, r2=0.525, p=0.029). Patients with both unipolar and bipolar normal maps (n=3) had normal RVOT strain values compared to controls (-25.7±3.9 vs -26.4±9.5%, p=0.90).
Conclusions. In patients with BrS, RVOT peak strain is significantly reduced compared to controls and is associated with abnormal voltage areas at endocardial unipolar EAM. Noninvasive evaluation of BrS patients with CMR-derived RVOT feature tracking may help to identify patients requiring invasive evaluation with EAM. Prospective studies evaluating the prognostic role of RVOT strain and EAM in BrS patients are needed.

A45: COGNITIVE IMPAIRMENT, ATRIAL FIBRILLATION PATTERNS AND ASSOCIATION WITH OUTCOMES: A REPORT FROM A CONTEMPORARY COHORT OF PATIENTS WITH ATRIAL FIBRILLATION

Marco Vitolo (a), Marta Mantovani (a), Jacopo Francesco Imberti (a), Niccolò Bonini (a), Davide Antonio Mei (a), Luigi Gerra (a), Ilaria Righelli (a), Kevin Serafini (a), Chiara Birtolo (a), Francesca Rampini (a), Benedetta Cherubini (a), Emilia Caliano (a), Enrico Tartaglia (a), Matteo Martella (a), Paolo Cataldo (a), Giuseppe Boriani (a)
(a) UNIVERSITÀ DEGLI STUDI DI MODENA E REGGIO EMILIA, SC CARDIOLOGIA, POLICLINICO DI MODENA, MODENA, ITALIA

Background. Patients with atrial fibrillation (AF) are associated with an increased risk of cognitive impairment (CImp). The association between AF and CImp is multifactorial involving complex pathophysiological pathways. There are limited data on the association between specific arrhythmia patterns (paroxysmal vs. non-paroxysmal) and cognitive status in real-world AF patients.
Purpose. To explore the association between AF patterns and CImp, as well as the association between CImp and all-cause mortality among AF patients with different arrhythmia patterns.
Methods. We analyzed consecutive AF patients enrolled in a prospective single-centre observational study. Cognitive Impairment (CImp) was assessed by the Mini-Mental State Examination (MMSE) and it was defined as MMSE score at baseline <24. Patients were divided into 4 groups according to CImp and type of AF: Group 1=Paroxysmal AF (PAF) and No CImp, Group 2=Non-paroxysmal AF (Non-PAF) and No CImp, Group 3=PAF and CImp and Group 4=Non-PAF and CImp. Patients with first detected AF were excluded. All-cause mortality was the primary endpoint of the study. **Results.** A total of 856 AF patients were included (median age 75 [IQR 66-82], CHA_2DS_2VASc score median 4 [2-5], HAS-BLED median 1 [1-2]). Overall, CImp (i.e. MMSE<24) was found in 157/856 (18.3%) patients, with a significantly higher prevalence among patients with Non-PAF compared to PAF patients (20.5% vs 11.4%, p=0.003). Patients with CImp were significantly older with a higher prevalence of female sex. Table 1 shows the baseline characteristics according to the 4 study groups. Oral anticoagulants were used in 90.4% (774/856) of the

patients, without significant differences among groups. After a median follow-up of 607 [IQR 205-1285] days, there were 124 (16.4%) all-cause deaths with a significantly higher prevalence in patients with CImp (Group 1: 4.5% vs Group 2: 16.2% vs Group 3: 31.6% vs Group 4: 30.7%, p<0.001). At Cox regression analysis adjusted for age, sex, hypertension, diabetes, previous stroke, coronary artery disease, chronic kidney disease, peripheral artery disease and malignancy, patients with CImp were independently associated with a higher risk of all-cause death both in PAF and Non-PAF groups, with progressively higher HRs across the 4 groups (HR ranging from 2.23 to 4.39 vs. PAF and No Cimp, Table 2).
Conclusions. In a prospective observational real-world cohort of AF patients CImp was present in almost one out of five individuals, with a significantly higher prevalence in patients with non-paroxysmal AF. Interestingly, CImp conferred a significantly higher risk of all-cause mortality in AF patients independently of the arrhythmia pattern highlighting its critical prognostic role and the need for appropriate integrated and holistic management.

Table 1. Baseline characteristics of the study cohort stratified according to cognitive status and AF pattern.

	No Cognitive Impairment (N= 699, 81.7%)		Cognitive Impairment (N=157, 18.3%)		
	Group 1 PAF and No CImp (n=179, 20.9%)	Group 2 Non-PAF and No CImp (n=520, 60.7%)	Group 3 PAF and CImp (n=23, 2.7%)	Group 4 Non-PAF and CImp (n=134, 15.7%)	p
Age (years), median (IQR)	70 (60-77)	74 (66-81)	83 (74-86)	82 (78-86)	<0.001
Female, n (%)	70/179 (39.1)	170/520 (32.7)	12/23 (52.2)	60/134 (44.8)	0.01
Hypertension, n (%)	116/179 (64.8)	389/520 (74.8)	19/23 (82.6)	114/134 (85.1)	<0.001
Diabetes mellitus, n (%)	34/179 (19.0)	111/519 (21.4)	2/23 (8.7)	31/134 (23.1)	0.39
Lipid disorder, n (%)	94/178 (52.8)	271/518 (52.3)	9/23 (39.1)	65/134 (48.5)	0.54
Heart failure, n (%)	40/179 (22.3)	158/520 (30.4)	6/23 (26.1)	55/134 (41.0)	0.005
Valvular heart disease, n (%)	60/179 (33.5)	243/520 (46.7)	8/23 (34.8)	69/133 (51.9)	0.004
Coronary artery disease, n (%)	40/179 (22.3)	131/520 (25.2)	5/23 (21.7)	42/134 (31.3)	0.31
CKD, n (%)	37/178 (20.8)	152/520 (29.2)	11/23 (47.8)	65/134 (48.5)	<0.001
CHA2DS2VASc, median (IQR)	3 (2-4.25)	3 (2-5)	4 (3-5)	5 (4-5)	<0.001
HASBLED, median (IQR)	1 (0-2)	1 (1-2)	1 (1-3)	2 (1-2)	<0.001

Table 2. Adjusted and unadjusted Cox Regression Analysis for all-cause death

	Unadjusted		Adjusted Model	
	HR (95%CI)	p	aHR (95%CI)	p
Group 1- PAF and No CImp	*ref*		*ref*	
Group 2- Non-PAF and No CImp	2.94 (1.35-6.38)	0.006	2.23 (1.03-4.88)	0.04
Group 3- PAF and CImp	6.40 (2.15-19.06)	<0.001	3.84 (1.22-11.98)	0.02
Group 4- Non-PAF and CImp	7.60 (3.35-17.26)	<0.001	4.39 (1.90-10.14)	<0.001

A46: LEFT VENTRICULAR NON COMPACTION AND VENTRICULAR ARRHYTHMIAS: I KNOW THAT I KNOW NOTHING

Michele Alfieri (a, b), Samuele Principi (b), Alessandro Barbarossa (b), Paolini Federico (a, b), Torselletti Lorenzo (a, b), Bastianoni Gianmarco (a, b), Brugiatelli Leonardo (a, b), Giulia Stronati (a, b), Antonio Dello Russo (a, b), Federico Guerra (a, b)
(a) UNIVERSITÀ POLITECNICA DELLE MARCHE; (b) CLINICA DI CARDIOLOGIA ED ARITMOLOGIA, AZIENDA OSPEDALIERO-UNIVERSITARIA DELLE MARCHE

Background. Excessive trabeculation of the left ventricle, also known as left ventricular non compaction (LVNC), is a rare condition where a hampered ventricular development leads to the presence of trabeculae and deep intertrabecular recesses. Its presentations range from thromboembolic events to heart failure and ventricular arrhythmias (VAs) with the latter being one of the leading causes of death. In this study we want to give light to some undiscussed problems of this controversial and complex disease.
Methods and Objectives. We prospectively enrolled patients diagnosed with LVNC in our centre, followed them up and analysed a possible correlation between baseline characteristics and a composite outcome made of death for-all-causes, ventricular arrhythmias, appropriate ICD intervention and sudden cardiac death (SCD). Survival analysis was conducted by using the Kaplan-Meyer method while multivariate analysis was applied to assess prognostic factors.
Results. 51 patients (34 males, 66.7%) were enrolled after meeting diagnostic criteria for excessive trabeculation and were followed for 8 years. 6 patients (11.8%) experienced the final outcome, with 1 death, 1 episode of VF and one sustained VT, while 3 patients experienced at least one appropriate ICD intervention. The strongest predictor of the final outcome was the anamnesis of VAs, with NSVTs and SVTs conferring an increased risk of respectively 13 and 21 times higher compared to other patients.
Conclusions. LVNC represents a complex condition where unknown genetic mechanisms, on top of microvascular disfunction, abnormal intercellular coupling and interstitial fibrosis, induce an increased tendency to the development of VAs. Interestingly, in our population NSVTs were predictive of the composite outcome independently from systolic function; this observation is in line with some studies, such as the DANISH trial, already conferring a lower importance to ejection fraction for the development of arrhythmias in non-ischemic cardiomyopathies. These data might be a first step in order to clear the possibility of a proper risk stratification even in this problematic and underdiagnosed condition.

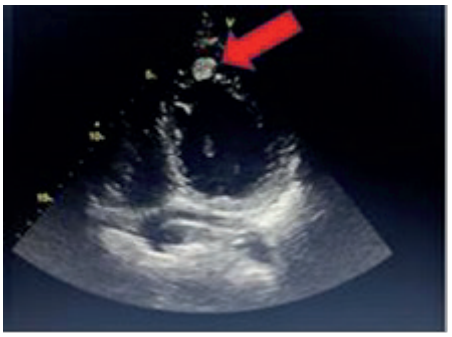

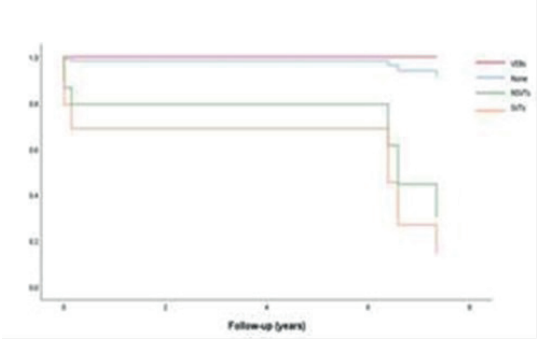

A47: SINDROME DI BRUGADA: DIFFERENZE CLINICHE ED ELETTROCARDIOGRAFICHE IN PAZIENTI MUTATI E NON

Marco Giardino (a), Giorgia Azzolini (a), Francesco Vitali (a), Cristina Balla (a), Matteo Bertini (a)
(a) AZIENDA OSPEDALIERO-UNIVERSITARIA DI FERRARA

Introduzione. La sindrome di Brugada (BrS) è una condizione caratterizzata dalla predisposizione allo sviluppo di aritmie ventricolari in assenza di franche alterazioni strutturali. Il reperto elettrocardiografico diagnostico, se presente assieme a sintomatologia, è un sopraslivellamento sopra-concavo del tratto ST ≥2 mm associato ad un'onda T negativa nelle derivazioni precordiali destre. Ad oggi mutazioni patogenetiche codificanti prevalentemente per i canali del sodio vengono identificate in mendo di un terzo dei pazienti.
Obiettivi. Valutare le differenze cliniche ed elettrocardiografiche in pazienti con diagnosi di BrS con o senza mutazione genetica identificata.
Materiali e metodi. Abbiamo analizzato retrospettivamente una coorte di 203 pazienti probandi con pattern ECG di Brugada tipo 1 spontaneo. Tutti i pazienti avevano eseguito analisi genetica dei geni più frequentemente coinvolti nelle cardiopatie/canalopatie (pannello di 180 geni). I pazienti son stati divisi in due gruppi a seconda dell'identificazione o meno di una mutazione BrS-relata francamente patogenetica. Abbiamo confrontato i due gruppi in base a criteri anamnestici (sesso, età, storia familiare di morte cardiaca improvvisa), criteri clinici (sincope cardiogena prima della diagnosi, arresto cardiocircolatorio o tachicardia ventricolare prima della diagnosi, utilizzo di farmaci antiaritmici, studio elettro fisiologico, test alla flecainide, necessità di impianto di ICD), criteri elettrocardiografici (presenza di pattern ECG nei familiari, presenza di fibrillazione atriale/flutter) e criteri di imaging (risonanza magnetica con alterazioni strutturali).
Risultati. Il nostro campione è costituito per il 63% da uomini e per il 34% da donne. In accordo con i dati della letteratura attuale il 35% del campione aveva la mutazione patogenetica per BrS. Nel 67% dei casi i pazienti avevano mutazione di SCN5A, nella restante parte abbiamo identificato mutazioni, anche in associazione, di molteplici geni relati a cardiomiopatie/canalopatie (SCN1B, PKP2, MYH7, MYBPC3, LMNA/C, KCNH2, KCNE1, HCN4, DSP, DSC2, DPP6, CACNA2). I pazienti con test genetico positivo avevano più frequentemente dei pazienti in cui non abbiamo individuato una mutazione un familiare con pattern di Brugada tipo 1 ad ECG (60% vs 35%, p=0,01). I pazienti con mutazione identificata erano più frequentemente portatori di ICD (25% vs 11%, p=0,01), avevano uno studio elettro-fisiologico più frequentemente positivo (8,4% vs 45.5%, p=0,015) e anche test alla flecainide positivo (14.0% vs 13.6% p=0.035).
Conclusioni. Ad oggi la genetica nei pazienti con BrS è ancora non completamente descritta. Oltre alle mutazioni di SCN5A anche altri geni, noti per essere se mutati causativi di altre canalopatie/cardiomiopatie, sembrano giocare un ruolo soprattutto se presenti mutati in associazione. Dalla nostra analisi emerge come pazienti con mutazioe patogenetica identificata di SCN5A tendano ad avere più frequentemente uno studio elettrofisiologico di induzione e un test alla flecainide positivo, oltre ad avere più ICD impiantati.

A48: MEDICAL DECISION SUPPORT TOOL FOR NEUROLOGICAL OUTCOME PREDICTION FROM POST-RESUSCITATION ELECTROCARDIOGRAMS (MILESTONE)

Sara Compagnoni (a, b), Francesca Romana Gentile (a, b), Syed Taimoor Hussain Shah (c), Michela Sperti (c), Konstantinos Panagiotopoulos (c), Roberto Primi (b), Sara Bendotti (b), Alessia Currao (b), Enrico Baldi (b), Clara Lopiano (a, b), Luca Vicini Scajola (a, b), Gianluca Marconi (d), Marco Agostino Deriu (c), Simone Savastano (b)
(a) SCUOLA DI SPECIALIZZAZIONE IN MALATTIE DELL'APPARATO CARDIOVASCOLARE, UNIVERSITÀ DEGLI STUDI DI PAVIA; (b) DIVISIONE DI CARDIOLOGIA, FONDAZIONE IRCCS POLICLINICO SAN MATTEO, PAVIA; (c) POLITO BIOMED LAB, DIPARTIMENTO DI INGEGNERIA MECCANICA E AEROSPAZIALE, POLITECNICO DI TORINO; (d) AGENZIA REGIONALE EMERGENZA URGENZA, MILANO

Introduzione. La previsione di un esito neurologico sfavorevole dopo un arresto cardiaco extraospedaliero (OHCA) rappresenta una sfida importante nell'assistenza post-rianimazione e attualmente gli strumenti di supporto decisionale non sono soddisfacenti.
Obiettivo. Lo scopo del presente studio è sviluppare uno strumento di machine learning (ML) in grado di predire l'esito neurologico di pazienti vittime di OHCA partendo dagli ECG post-rianimazione. Questo innovativo strumento di supporto decisionale si chiama MILESTONE (MedIcaL dEcision Support tool for neurological ouTcome predictiOn from post-resuscitatioN Electrocardiograms).
Materiali e metodi. MILESTONE usa un'immagine ECG come input da cui estrae le caratteristiche mediante tecniche di visione artificiale. Tali caratteristiche, utilizzate per alimentare il modello ML per la previsione dell'esito neurologico, sono state recuperate da un set di dati di 1341 ECG raccolti da un registro OHCA basato sullo stile Utstein: 431 ECG post-ROSC di pazienti con esito neurologico sfavorevole (Cerebral Performance Category>2) alla dimissione (classe 1); 568 ECG post-ROSC di pazienti con buon esito neurologico (CPC≤2) e 342 ECG di soggetti sani (classe 0). Le caratteristiche dell'immagine sono state estratte da diversi algoritmi di visione artificiale derivati dal metodo SIFT (scale-invariant feature transform). Le caratteristiche estratte, l'età e il sesso del paziente sono stati usati per addestrare un classificatore XGBoost. La validazione incrociata è stata applicata per ottimizzare i parametri del modello e testarne la capacità di generalizzazione. La tecnica del peso delle classi è stata introdotta per rendere il nostro classificatore più incline a rilevare casi positivi. Le prestazioni del modello sono state valutate in base all'accuratezza bilanciata, alla curva AUC-ROC (Area Under the Curve of the Receiver Operating Characteristic) e al punteggio F1 nei set sia di validazione che di test.
Risultati. Il nostro modello ha raggiunto rispettivamente una curva AUC-ROC e un punteggio F1 rispettivamente di 88,5±4,1% e 78,2±7,3% nell'hold-out set (Figura). MILESTONE ha raggiunto un'accuratezza bilanciata di oltre l'80% come prova della solidità dei risultati e dell'elevata capacità di discriminazione per entrambe le classi, sebbene abbia un bias verso l'identificazione dei pazienti con esiti peggiori. In termini di spiegabilità, MILESTONE ha il potenziale per correlare le caratteristiche dell'ECG leggibili dalla macchina con le caratteristiche più note utilizzate nella pratica clinica, come gli intervalli QT, le forme dei picchi, ecc.
Conclusioni. Questo strumento rappresenta il primo utilizzo di intelligenza artificiale basata sulla visione artificiale applicata agli ECG in grado di prevedere un esito neurologico sfavorevole in pazienti rianimati dopo un OHCA: esso può essere riaddestrato sia per diverse patologie che per qualsiasi durata della registrazione dell'ECG, migliorando continuamente le sue prestazioni.

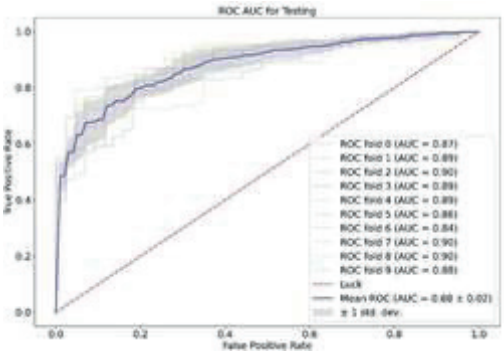

A49: ABLAZIONE TRANS CATETERE DELLA FIBRILLAZIONE ATRIALE CON TECNICA HIGH POWER SHORT DURATION MEDIANTE CATETERE TACTIFLEX: UN MAGGIOR SUCCESSO PROCEDURALE IN SICUREZZA E RAPIDITÀ

Leonardo D'Angelo (a, b), Yari Valeri (a, b), Francesca Campanelli (a, b), Lara Luciani (a, b), Paolo Compagnucci (a), Giovanni Volpato (a), Quintino Parisi (a), Laura Cipolletta (a), Silvano Molini (a), Agostino Misiani (a), Federico Guerra (b), Michela Casella (b), Antonio Dello Russo (b)
(a) AZIENDA OSPEDALIERO UNIVERSITARIA DELLE MARCHE; (b) UNIVERSITÀ POLITECNICA DELLE MARCHE

Introduzione. L'ablazione trans catetere (ATC) della fibrillazione atriale (FA) mediante radiofrequenze (RF) con tecnica standard power long duration (SPLD) è ad oggi la tecnologia più diffusa. Gli insoddisfacenti risultati in termini di recidiva della FA hanno portato allo sviluppo di nuovi cateteri capaci di erogare elevate potenze di RF per pochi secondi al fine di generare lesioni più ampie ma meno profonde capaci di garantire un duraturo isolamento delle vene polmonari (IVP) riducendo il rischio di complicanze termiche. È questo il caso del catetere Tactiflex™(Abbot) capace di eseguire il protocollo high power short duration (HPSD).
Obiettivi. Lo scopo del nostro studio è valutare l'efficacia e la sicurezza dell'ATC con tecnica HPSD mediante catetere Tactiflex™ (Abbot), confrontandone gli aspetti procedurali con la tecnica SPLD eseguita mediante catetere Tacticath™ (Abbot).
Materiali e metodi. È stato condotto uno studio retrospettivo su 159 pazienti affetti da FA parossistica e persistente afferiti al nostro centro per eseguire l'ATC della FA. I pazienti sottoposti al protocollo HPSD erano 85, mentre i pazienti trattati con tecnica SPLD erano 74 (età media 59 ± 11 HPSD vs 61 ± 11 SPLD, p=0.563; genere maschile n=64 [75%] HPSD vs n=46 [71%] SPLD, p=0.322). Il protocollo HPSD veniva applicato erogando impulsi di radiofrequenza con una potenza massima di 50 W per 10 sec nei segmenti posteriori delle vene polmonari (VP) e 40W per 20 sec nei segmenti anteriori delle VP, con un indice di contact force compreso tra 5 e 20 g. Nel gruppo SPLD l'ATC veniva eseguita erogando impulsi di radiofrequenza con potenza pari a 40W e lesion index (LSI) target 5-5,5 nei segmenti anteriori delle VP, e 35 W con LSI pari a 4-4,5 nei segmenti posteriori delle VP. Il principale obiettivo della procedura ablativa era l'IVP. Sulla base della mappa di voltaggio-substrato, l'ablazione di foci extra polmonari è stata eseguita a discrezione dell'operatore. Il monitoraggio della temperatura esofagea è stato eseguito via posizionamento di sondino naso-esofageo con sonda termica nelle fasi preliminari della procedura ablativa
Risultati. L'IVP è stato ottenuto in tutti i pazienti. Nessuna complicanza maggiore si è verificata nel corso dello studio. Non sono emerse differenze statisticamente significative tra i due gruppi in termini clinici ed ecocardiografici. Il gruppo HPSD ha evidenziato un maggior tasso di first pass isolation (FPI) (n=313, 95% HPSD; n=248, 84% SPLD; p<0.005) e un minor tempo IVP (9 [7-9] min HPSD; 50 [37-54] min SPLD; p<0.001). L'impedance drop si è dimostrato superiore nel gruppo HPSD (17 [18-17] Ω vs 16 [17-15] Ω; p<0.001). Conseguentemente si è registrata una riduzione dei tempi procedurali (110 [100-130] min vs 173 [139-187] min; p<0.001), dei tempi di fluoroscopia (15 [10-18] min vs 18 [13-26]; p<0.001) e del DAP (1452 [662-2173] μGm^2 vs. 7200 [3400-20800] μGm^2, p<0.001) nel gruppo HPSD.
Conclusioni. Un maggior tasso di FPI ed un più elevato impedance drop testimoniano la miglior efficacia della tecnica HPSD nell'isolare elettricamente le vene polmonari. Il minor tempo di IVP è il principale responsabile della riduzione dei tempi procedurali e della radio-esposizione, fattori rilevanti sia per pazienti sia per operatori.
Ulteriori studi ed un follow up longitudinale sono necessari per verificare se i vantaggi procedurali e la maggior efficacia della tecnica HPSD correlino con un minor numero di recidive di FA rispetto alla metodica SPLD.

A50: AN UNUSUAL CASE OF PROPOFOL-RELATED INFUSION SINDROME (PRIS) PRESENTING WITH STEMI-LIKE PATTERN

Guido Del Monaco (a, c), Riccardo Mantovani (a, c), Antonio Taormina (a, c), Elena Costantini (b, c), Francesca Sala (b, c), Nadia Fusilli (b, c), Renato Maria Bragato (a, c), Maurizio Cecconi (b, c), Gianluigi Condorelli (a, c), Antonio Frontera (a, c)
(a) CARDIO CENTER, HUMANITAS RESEARCH HOSPITAL, 20089 ROZZANO (MI); (b) DEPARTMENT OF ANESTHESIA AND CRITICAL CARE, HUMANITAS RESEARCH HOSPITAL, 20089 ROZZANO (MI); (c) DEPARTMENT OF BIOMEDICAL SCIENCES, HUMANITAS UNIVERSITY, 20090, PIEVE EMANUELE (MI)

Case presentation. A 29 years old man was admitted to the Emergency Department for crushing head and thoracoabdominal trauma occurred in the workplace, complicated by bilateral pneumothorax and hepatic laceration. He was immediately intubated and transported to Intensive Care Unit (ICU) after surgical management (thoracic drainage and abdominal revision). At ICU admission his neurological state was comatose (GCS 3) and was sedated with propofol and remifentanil. Due to hypotension, fluid resuscitation with crystalloid and norepinephrine infusion were started. 12-lead ECG and transthoracic echocardiography (TTE) at admission didn't show any abnormality. The following days the patient experienced new hypotensive episodes with the need of increasing norepinephrine infusion rate, moreover, also propofol dosage was increased due to ventilator maladaptation. The 6th day after ICU admission, 12-lead ECG (Figure, panel A) showed diffuse ST segment elevation>2 mm (mainly seen from V1 to V4) without any contralateral ST depression and with following negative T wave and prolonged QTc interval. Cardiac troponin was mildly risen but its kinetic wasn't suggestive of acute coronary syndrome and bedside TTE revealed no significant abnormality. Blood exams showed increase in serum creatine-phosphokinase, transaminases and lactic acidosis, which, together with ECG changes, were suggestive for Propofol-Related Infusion Syndrome (PRIS).

Discussion. PRIS is a potentially lethal condition caused by high-dose intravenous propofol. Risk factors include catecholamines, young age and critical illness and the most frequent ECG changes are represented by a "Brugada-like" pattern in right precordial leads which may degenerate in malignant arrhythmias. PRIS management include propofol withdrawal and replacement with other drugs and eventual treatment of complications. In fact, despite a "STEMI-like" ECG pattern, which is unusual for PRIS, in our case coronary angiography wasn't performed and propofol infusion was gradually stopped and replaced with midazolam and remifentanil. 12-lead ECG 24 and 72 hours after propofol withdrawal (Panel B and C) showed respectively isoelectric ST segment with T-wave inversion from V1-V4 and complete normalization with new onset right bundle branch block. No malignant arrhythmia was recorded with continuous ECG monitoring. The patient was discharged from ICU to ward 21 days after admission without any cardiac complication.

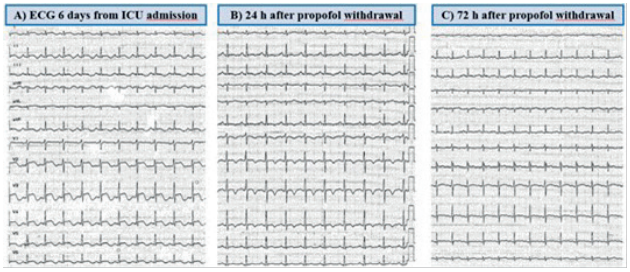

A51: HIS-OPTIMIZED CARDIAC RESYNCHRONIZATION THERAPY (HOT-CRT) IN A SUBCUTANEOUS IMPLANTABLE DEFIBRILLATOR PATIENT: A CASE REPORT

Andrea Dell'Aquila (a), Angelica Fundaliotis (a), Marina Moretti (a), Edoardo Cantù (a, b), Francesca Filippelli (a), Antonino Pitì (a), Gianmarco Arabia (b), Antonio Curnis (b), Luca Bontempi (a, b)
(a) CARDIAC ELECTROPHYSIOLOGY AND ELECTROSTIMULATION UNIT, CARDIOLOGY DEPT. - ASST BERGAMO EST, BOLOGNINI HOSPITAL OF SERIATE; (b) UNIT OF CARDIAC ELECTROPHYSIOLOGY AND ELECTROSTIMULATION, INSTITUTE OF CARDIOLOGY - ASST SPEDALI CIVILI HOSPITAL OF BRESCIA AND UNIVERSITY OF BRESCIA

Introduction. Recent developments in arrhythmology have enabled the use of new devices, such as subcutaneous implantable cardioverter-defibrillators (s-ICD), and the comeback of older strategies, such as His-Bundle pacing (HBP) in clinical practice, alongside the use of thoroughly proven therapies such as cardiac resynchronization therapy (CRT), e.g. with His-Optimized CRT (HOT-CRT)[1]. However, interplay between these new and older techniques is not always clear. We report a case of biventricular pacemaker (CRT-P) implantation with HOT-CRT in an s-ICD patient.

Case report. An active-fixation bipolar HBP lead (Ingevity MRI 7842 59 cm, Boston Scientific) was implanted in the right ventricle by means of SSPC3 delivery (Boston Scientific) and a pace-mapping approach, obtaining non-selective capture. A quadripolar left ventricular pacing (LVP) lead (Acuity X4 Straight, Boston Scientific) was then implanted, in an antero-lateral branch of the coronary sinus. Correct paced QRS (pQRS) identification by the s-ICD was established by means of intraprocedural device interrogation, and was confirmed for HBP, LVP (LV1-LV2 configuration) and biventricular pacing (BiVP), i.e. HBP with sequential LVP after 20 msec. BiVP yielded a pQRS morphology similar to that of the sQRS, albeit shorter, i.e. pQRS 100 msec vs. spontaneous QRS 115 msec. A right atrial lead was then implanted and the procedure was concluded as a standard CRT-P implantation. Electrical parameters were optimal, with capture thresholds below 1 V @ 0.4 msec. After the procedure, QRS recognition by the s-ICD was tested again, both by device interrogation and by the automated s-ICD screening tool (AST, Boston Scientific), both of which confirmed correct pQRS identification in both the supine and standing positions.

Conclusions. CRT remains a landmark therapy for heart failure (HF), particularly in the context of HF with a high expected percentage of RVP[1,2]. HOT-CRT was recently shown to be safe and potentially superior to conventional CRT in the case of intraventricular conduction defects[3]. To our knowledge, we reported the first case of transvenous CRT-P implantation in an s-ICD patient, and also the first case of HOT-CRT in an s-ICD patient. This approach was chosen in order to reduce both costs and generator size, and to respect patient preference, while ensuring possible bailout to conventional CRT-D during implantation in the event of suboptimal pQRS recognition by the s-ICD. In conclusion, considering that potentially up to 5.2% of s-ICD patients develop a need for permanent pacing[4], we demonstrated that CRT-P, and particularly HOT-CRT implantation in an s-ICD patient, was both feasible and safe, yielding optimal electrical parameters and correct pQRS identification by the s-ICD both intra- and post-procedurally.

References

Glikson M., et al. 2021 ESC Guidelines on cardiac pacing and cardiac resynchronization therapy - Developed by the Task Force on cardiac pacing and cardiac resynchronization therapy of the European Society of Cardiology (ESC). Eur Heart J. 2021;42(35):3427–3520.
Curtis AB, et al. Biventricular Pacing for Atrioventricular Block and Systolic Dysfunction. N Engl J Med. 2013;368(17):1585-1593.
Zweerink A, et al. His-Optimized Cardiac Resynchronization Therapy With Ventricular Fusion Pacing for Electrical Resynchronization in Heart Failure. JACC Clin Electrophysiol. 2021;7(7):881-892.
Kutyifa V, et al. Need for pacing in patients who qualify for an implantable cardioverter-defibrillator: Clinical implications for the subcutaneous ICD. Ann Noninvasive Electrocardiol. 2020;25(4):e12744.

A52: LEFT ATRIAL THROMBUS FORMATION DURING PULMONARY VEIN CRYOABLATION: THE PIVOTAL ROLE OF INTRACARDIAC ECHOCARDIOGRAPHY AND CEREBRAL EMBOLIC PROTECTION DEVICE

Andrea Dell'Aquila (a), Angelica Fundaliotis (a), Marina Moretti (a), Edoardo Cantù (a, b), Francesca Filippelli (a), Antonino Pitì (a), Gianmarco Arabia (b), Antonio Curnis (b), Luca Bontempi (a, b)
(a) CARDIAC ELECTROPHYSIOLOGY AND ELECTROSTIMULATION UNIT, CARDIOLOGY DEPT. - ASST BERGAMO EST, BOLOGNINI HOSPITAL OF SERIATE; (b) UNIT OF CARDIAC ELECTROPHYSIOLOGY AND ELECTROSTIMULATION, INSTITUTE OF CARDIOLOGY - ASST SPEDALI CIVILI HOSPITAL OF BRESCIA AND UNIVERSITY OF BRESCIA

Introduction. Trans-septal puncture (TSP) is commonly performed to achieve left atrial (LA) access for a variety of cardiac procedures, including pulmonary vein isolation (PVI) for atrial fibrillation (AF) treatment[1], and it has always being challenging for operators[1,2]. Fluoroscopy guidance alone is burdened by an estimated not negligible complication rate (~1%)[2]. Therefore, additional transesophageal echocardiography (TEE) or intracardiac echocardiography (ICE) guidance is recommended to reduce the risk of adverse events[3,4]. We report the case of a PVI procedure using cryoablation complicated by the formation of a serpiginous left atrial swinging thrombus after TSP.

Case report. A 59-year-old male patient without cardiovascular risk factors was referred to our center for PVI for symptomatic paroxysmal AF episodes. Considering that the patient missed a dose of Rivaroxaban the week before, pre-procedural TEE was undertaken excluding LA thrombosis. Therefore, a PVI by cryoablation attempt was performed on the same day. Three femoral venous accesses were obtained: one for TSP, one for insertion of a decapolar diagnostic catheter (Dynamic Xt 10-poles, Boston Scientific), and one for insertion of the ICE probe (Viewflex Xtra ICE, 3Mhz, Abbott Medical). For TSP, an 8Fr Swartz introducer (Abbott Medical) with a Brockenbrough needle (Abbott Medical) inside of it was used. TSP with ICE guidance was performed safely. An IV bolus of unfractionated heparin (UFH) was administered according to patient weight (10,000 UI). Checking the correct position of the introducer in the LA with ICE, the formation of a serpiginous thrombus swinging from the tip of the introducer was noticed. Activated clotting time was therefore tested, being 221 sec. Therefore, an additional IV bolus of 2000 UI of UFH was administered. A cerebral embolic protection device (TriGuard 3, Keystone Heart – Venus MedTech, Hangzhou, China) was deployed in the aorta to improve safety. Under continuous ICE and fluoroscopic guidance, the introducer was carefully removed from the LA, taking care not to detach the clot from the introducer. The patient remained asymptomatic and was transferred to the cardiac intensive care unit for monitoring. After four days, UFH anticoagulation therapy was switched to Rivaroxaban and the patient was discharged without documented thromboembolic complications. Three weeks later, a second successful PVI attempt was conducted using the same TSP technique described above.

Conclusions. In our case, ICE guidance allowed early diagnosis of LA thrombus formation on the tip of the introducer used for PVI after introduction into the LA, thus avoiding thromboembolic complications. If only fluoroscopy guidance had been used, it would not have been possible to diagnose said thrombus formation and therefore prevent thromboembolic complications, such as ischemic stroke.

References

Hsu JC, et al. Randomized trial of conventional transseptal needle versus radiofrequency energy needle puncture for left atrial access (the TRAVERSE-LA Study). J Am Heart Assoc. 2013;2(5)
Mol D, et al. Complications in pulmonary vein isolation in the Netherlands Heart Registration differ with sex and ablation technique. Europace. 2021;23(2):216-225.
Dello Russo A, et al. Role of intracardiac echocardiography in atrial fibrillation ablation. J Atr Fibrillation. 2013;5(6):118-135.
Rosu R, et al. Intracardiac echocardiography for transseptal puncture. A guide for cardiac electrophysiologists. Med Ultrason. 2019;21(2):183-190.

A53: IDENTIFICAZIONE DEL PATTERN DI BRUGADA DI TIPO 1 MEDIANTE LOOP RECORDER: STUDIO DI FATTIBILITÀ

Alessandro Dinatale (a), Antonio Crocamo (a), Luca Bearzot (a), Gianluca Gonzi (a), Angela Guidorossi (a), Daniele Giacopelli (b), Matteo Bassini (b), Diego Grassini (b), Giampaolo Niccoli (a), Diego Ardissino (a), Maria Francesca Notarangelo (a)
(a) U.O. DI CARDIOLOGIA, A.O.U. DI PARMA; (b) BIOTRONIK ITALIA S.P.A., VIMODRONE (MI)

Introduzione. Il pattern di Brugada di tipo 1 (BP1) spontaneo è associato ad un aumentato rischio di eventi aritmici. Spesso la diagnosi è sotto-

stimata, poiché il pattern può essere intermittente. Il monitoraggio ECG periodico ambulatoriale può identificare, tra i pazienti con pattern indotto farmacologicamente, quelli con pattern spontaneo, tuttavia il potere diagnostico di tale strumentazione rimane limitato.
I monitor cardiaci impiantabili (ICM), registrando di continuo il ritmo cardiaco, potrebbero avere una maggiore sensibilità nell'identificare i pazienti con pattern intermittente. Ad oggi, la capacità degli ICM di identificare morfologicamente il sopraslivellamento del tratto ST associato al BP1 non è nota.
Materiali e metodi. Sono stati arruolati tutti i pazienti sottoposti a test all'ajmalina (AT) tra novembre 2022 e luglio 2023. Nei pazienti positivi sono state testate, utilizzando il working demo del ICM Biomonitor IIIm (Biotronik), quattro posizioni (I-II spazio intercostale sinistra inclinazione 45°; II-III spazio intercostale sinistra inclinazione 45°; II-III spazio intercostale parasternale destra; II-III spazio intercostale parasternale sinistra) con lo scopo di acquisire la traccia che presentava maggior sopraslivellamento del punto J durante massima positività dell'ECG al test all'ajmalina. Le misure sui tracciati sono state acquisite utilizzando un software dedicato (Digitizelt).
Risultati. L'AT è risultato positivo in 18/52 pazienti (M:F 1.64:1; età media 43.9±13.7 anni). In 16 pazienti la traccia del working demo ha registrato un sopraslivellamento ST durante massimo dosaggio di ajmalina. Nel 75% dei pazienti la posizione ottimale per la registrazione era al I-II spazio intercostale sinistra inclinazione 45°. La mediana del sopraslivellamento ST registrato dal demo è stata 0.9 mm (range interquartile 0.6-1.1 mm). Non è stata osservata alcuna correlazione tra l'entità del sopraslivellamento ST all'ECG e quello rilevato dalla traccia registrata dal working demo (coefficiente lineare di Pearson=0.09).
Conclusioni. L'ICM può essere in grado di registrare il BP1. Questo risultato potrebbe avere implicazioni diagnostiche e prognostiche significative per i pazienti asintomatici con BP1 indotto farmacologicamente. Ulteriori ricerche saranno necessarie per identificare gli algoritmi di programmazione utili a registrare automaticamente il pattern.

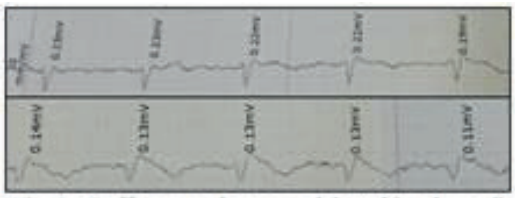

Fig. 1 - Raffronto tra le tracce del working demo di uno stesso paziente. In alto: basale. In basso: in corso di massima positività ad ajmalina. 20 mm/mV

Fig.2 - Distribuzione, mediana e range interquartile del sopraslivellamento del punto J registrato dalla traccia del working demo

A54: L'AMPIEZZA DELL'AREA SPETTRALE (AMSA) DELLA FIBRILLAZIONE VENTRICOLARE È ASSOCIATA ALLA SOPRAVVIVENZA AD UN ANNO CON BUON ESITO NEUROLOGICO NELL'ARRESTO CARDIACO EXTRAOSPEDALIERO

Francesca Romana Gentile (a), Alessandro Fasolino (a), Sara Compagnoni (a), Enrico Baldi (a), Federico Quilico (a), Luca Vicini Scajola (a), Clara Lopiano (a), Roberto Primi (a), Sara Bendotti (a), Alessia Currao (a), Simone Savastano (a), Enrico Contri (b), Alessandra Palo (b), Elisabete Aramendi (c), Iraia Isasi (c)
(a) IRCCS SAN MATTEO; (b) AAT PAVIA - AGENZA REGIONALE EMERGENZA URGENZA (AREA) C/O FONDAZIONE IRCCS POLICLINICO SAN MATTEO; (c) BIORES GROUP, UNIVERSITY OF THE BASQUE COUNTRY, BILBAO, SPAIN

Introduzione. I pazienti rianimati da un arresto cardiaco extraospedaliero (OHCA) con ritmi defibrillabili presentano tassi di sopravvivenza solitamente maggiori. L'AMSA della fibrillazione ventricolare, un surrogato dello stato metabolico del miocardio, può predire il successo dello shock e il ritorno alla circolazione spontanea (ROSC). Le evidenze sul suo ruolo nel predire la sopravvivenza da OHCA sono minime e quelle esistenti sono limitate alla sopravvivenza alla dimissione. Il nostro obiettivo è stato quello di verificare l'ipotesi che il primo, il massimo, il minimo ed il valore medio di AMSA siano associati alla sopravvivenza ad un anno con buon esito neurologico nei pazienti con OHCA.
Materiali e metodi. Sono stati considerati tutti gli OHCA con almeno un ritmo defibrillabile, verificatisi da gennaio 2015 a dicembre 2020, raccolti da un database secondo lo stile Utstein. I valori AMSA sono stati calcolati analizzando retrospettivamente i dati raccolti dai monitor/defibrillatori, considerando un intervallo ECG pre-shock di 2 secondi. Sono stati calcolati il primo, il massimo, il minimo e il valore medio di AMSA durante la rianimazione. I dati sono stati analizzati utilizzando l'analisi di regressione di Cox.
Risultati. Sono stati inclusi 250 pazienti (84% maschi, età mediana 67 [57-77] anni) con almeno un valore AMSA calcolabile. Il 12% ha raggiunto il ROSC e il 9,4% è sopravvissuto a un anno con un buon esito neurologico, definito come categoria di performance cerebrale (CPC) ≤2. Il primo, il massimo, il minimo e il valore medio di AMSA sono risultati più alti nei pazienti vivi ad un anno dopo OHCA con CPC≤2 (primo: 11.6 [9.9-14.7] vs 7.8 [5.1-11.8]; max: 15.4 [12-20] vs 9.2-14.4]; min: 9.9 [8.5-12.2] vs 6.1 [4.3-9.6]; medio: 12.5 [10.15.2] vs 8.5-12.5]; p<0.01). Questi valori hanno mostrato aree sotto la curva ROC simili per la sopravvivenza ad un anno con buon esito neurologico (primo: 0.77; max: 0.76; min: 0.78; medio: 0.78, p=ns). Nel modello univariabile, la probabilità di sopravvivenza con un buon esito neurologico era significativamente inferiore nel primo terzile di AMSA rispetto al terzo terzile (p<0.05). Nell'analisi multivariabile, dopo la correzione per sesso, presenza di RCP da parte degli astanti, età, tempo di arrivo dell'EMS, presenza di testimoni, luogo dell'OHCA, uso di RCP meccanica e quantità totale di epinefrina somministrata, l'AMSA è risultata significativamente associata alla probabilità di morte o di esito neurologico sfavorevole [HR 0.5 (95%CI 0.3-0.9), p=0.03].
Conclusioni. L'AMSA è associata indipendentemente alla sopravvivenza a un anno con un buon esito neurologico nei pazienti con OHCA. Il primo, il massimo, il minimo e il valore medio di AMSA hanno tutti un potere predittivo simile nel tasso di sopravvivenza con buon outcome neurologico.

A55: PERIOPERATIVE AND POSTOPERATIVE PAIN IN PATIENTS UNDERGOING SUBCUTANEOUS IMPLANTABLE CARDIOVERTER-DEFIBRILLATOR PLACEMENT

Antonio Bisignani (a), Mauro Biffi (b), Fabrizio Caravati (c), Carmelo La Greca (d), Gianfranco Tola (e), Pietro Palmisano (f), Antonio D´onofrio (g), Gerardo Nigro (h), Paolo Sartori (i), Pasquale Notarstefano (j), Alessandro Vicentini (k), Sergio Valsecchi (l), Mariolina Lovecchio (l), Antonio Mazziotti (m), Giovanni Bisignani (m)
(a) FATEBENEFRATELLI ISOLA TIBERINA HOSPITAL, GEMELLI-ISOLA (ROME); (b) SANT'ORSOLA-MALPIGHI POLYCLINIC(BOLOGNA); (c) CIRCOLO E FONDAZIONE MACCHI HOSPITAL(VARESE); (d) FONDAZIONE POLIAMBULANZA (BRESCIA); (e) BROTZU HOSPITAL (CAGLIARI); (f) G. PANICO HOSPITAL (TRICASE); (g) MONALDI HOSPITAL (NAPLES); (h) VANVITELLI HOSPITAL (NAPLES); (i) SAN MARTINO HOSPITAL (GENOVA); (j) SAN DONATO HOSPITAL (AREZZO); (k) IRCCS SAN MATTEO POLYCLINIC (PAVIA); (l) BOSTON SCIENTIFIC ITALY (MILAN); (m) FERRARI HOSPITAL (CASTROVILLARI)

Background. The recent Avoiding Transvenous Leads in Appropriate Subjects (ATLAS) Trial demonstrated that the subcutaneous implantable cardioverter-defibrillator (S-ICD) reduces lead-related complications without significantly compromising the effectiveness of ICD shocks, but with more postoperative pain.
Purpose. To assess the perioperative and postoperative pain during S-ICD implantation in current clinical practice and evaluate the influence of implantation techniques.
Methods. We analyzed 255 consecutive patients (84% male, 52±16 years, body mass index 26±4 Kg/m2, ejection fraction 42±16%) who had undergone S-ICD implantation from 2017 to 2022. The primary endpoint was pain during S-ICD placement. The secondary outcome measure included static and dynamic pain intensity 6 hours after the end of the procedure. Patients were asked to rate pain intensity on a 10-point visual analogue scale from 0 (no pain) to 10 (worst imaginable pain).
Results. The mea n procedure duration was 62±22 minutes. The serratus anterior piane block (SAPB) was performed in 161 (63%) patients for anesthesia/analgesia, and 161 (63%) patients underwent the defibrillation testing. Implantation success was reported in all patients with no operative complications. In the overall group, the pain intensity was 2 [range: 1-8] during the implantation procedure, and 1 [1-7] for both static and dynamic pain, 6 hours after the end of the procedure. Significantly lower values were recorded during implantation in the SAPB group (p=0.010) and among those who did not undergo the defibrillation testing (p=0.008). The adoption of the SAPB (coefficient: -0.54, p=0.047) and the omission of defibrillation testing (coefficient: -0.70, p=0.028) remained associated with less pain during implantation after correction for age, sex, body habitus, ejection fraction. Six hours after

the end of the procedure the static and dynamic pain intensity remained lower among those with omitted testing (p=0.018 and 0.004, respectively).

Conclusions. In current clinical practice, S-ICD implantation is associated with very little discomfort. The adoption of novel anesthetic techniques and the omission of defibrillation testing is associated with lower pain levels.

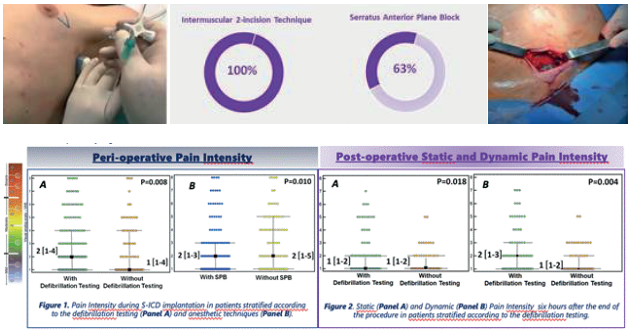

A56: TACHICARDIE VENTRICOLARI (TV) INNESCATE DALLE AUTOSOGLIE ATRIALI DEL DEFIBRILLATORE CARDIACO IMPIANTABILE (ICD) BICAMERALE

Daniele Melis (a, b), Filippo Angelini (a), Andrea Saglietto (a, b), Simone Frea (a), Andrea Visalli (a, b), Davide Castagno (a, b), Matteo Anselmino (a, b), Carla Giustetto (a, b), Gaetano Maria De Ferrari (a, b), Veronica Dusi (a, b)

(a) DIVISIONE DI CARDIOLOGIA, DIPARTIMENTO CARDIOVASCOLARE E TORACICO, CITTÀ DELLA SALUTE E DELLA SCIENZA, TORINO; (b) DIPARTIMENTO DI SCIENZE MEDICHE, UNIVERSITÀ DEGLI STUDI DI TORINO

Anamnesi. Uomo di 63 anni, affetto da cardiomiopatia ipertrofica (HCM) non ostruttiva, nota dal 1980. Dal 2003 insorgenza di aritmie sopraventricolari (fibrillazione atriale e flutter atriale atipico) persistenti e resistenti alla terapia antiaritmica, sottoposte a plurime procedure ablative transcatetere con radiofrequenza. Nel 2018 ricovero per angina instabile: alla coronarografia lesione critica sull'arteria discendente anteriore al tratto medio sottoposta ad angioplastica percutanea, all'ecocardiogramma evoluzione dilatativo-ipocinetica (frazione di eiezione 32%). Da allora insorgenza di tachicardie ventricolari (TV) rapide emodinamicamente instabili, per cui eseguita ablazione endo-epicardica anterosettale apicale ed impiantato defibrillatore cardiaco transvenoso (ICD) bicamerale, con successiva riduzione del burden aritmico; terapia antiaritmica limitata da intolleranza alla mexiletina e ipertiroidismo da amiodarone. Progressivo sviluppo di insufficienza cardiaca avanzata, per cui da maggio del 2022 veniva inserito in lista attiva trapianto cuore.

Evento. Giunge alla nostra attenzione ad agosto 2022 per episodio di TV (BBsx, asse inferiore) emodinamicamente mal tollerata (astenia, dolore toracico, pressione arteriosa sistolica 50 mmHg, Lattati 3.5 mmol/L), sottoposta a cardioversione farmacologica con amiodarone sul territorio, e sviluppo di quadro di shock cardiogeno con danno d'organo cardiaco ed epatico.

Gestione. In UTIC è stata impostata terapia antiaritmica con amiodarone endovena e decongestione con vasodilatatori e diuretici endovenosi, ed eseguito controllo dell'ICD bicamerale.

Diagnosi. All'analisi del dispositivo venivano segnalati 4 episodi di TV monomorfa della medesima morfologia a 151 bpm (in zona monitor 150-170 bpm) di cui solo della prima era visibile l'innesco. Si trattava di un unico episodio di TV con frequenza cardiaca (Fc) a cavallo della Fc minima della zona monitor e pertanto registrata a tratti dal device (per Fc>150 bpm). Il dispositivo era programmato con ritardo atrioventricolare (AV) stimolato di 350 ms in modo da minimizzare la percentuale di battiti ventricolari stimolati, tuttavia durante la ricerca delle autosoglie atriali (ACap-Confirm, Abbott®), l'intervallo AV si riduceva drasticamente (AV delay 100 ms) generando una sequenza tipo lungo-breve-lungo (figura) che ha innescato la TV. Analizzando gli eventi precedenti nella memoria dell'ICD, lo stesso meccanismo di innesco si era verificato anche 90 giorni prima allo stesso orario (le autosoglie venivano eseguite ogni 24 ore), configurando l'insorgenza della medesima TV a 151 bpm, in quel caso autorisoltasi dopo pochi minuti. Non è noto se durante tale periodo siano state innescate ulteriori TV al di sotto dei 150 bpm (limite di riconoscimento).

Terapia. La terapia specifica per questo paziente è stata la disattivazione delle autosoglie atriali. È stata inoltre ridotta la zona monitor TV per FC>121 bpm, e la zona di terapia per FC>135 bpm in considerazione della scarsa tolleranza emodinamica del paziente all'aritmia di presentazione. Non recidive aritmiche nel follow-up.

Conclusioni. Il caso sottolinea come l'interrogazione e la riprogrammazione attenta dell'ICD nello storm aritmico debba essere eseguita il prima possibile, al fine non soltanto di definire la natura degli episodi aritmici e minimizzare il rischio di interventi non necessari, ma anche di escludere un eventuale potenziale pro-aritmico di alcuni algoritmi frequentemente utilizzati.

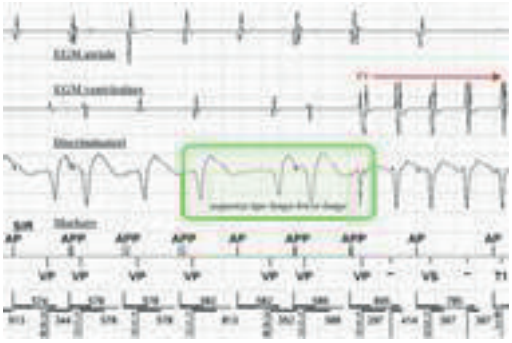

A57: LEFT BUNDLE BRANCH AREA PACING IN THE SETTING OF CARDIAC AMYLOIDOSIS: A CASE SERIES

Gianluca Mirizzi (a), Giuseppe Vergaro (a, b), Michele Emdin (a, b), Andrea Rossi (a), Luca Panchetti (a), Umberto Startari (a), Silvia Garibaldi (a), Martina Nesti (a), Alberto Aimo (a, b), Marcello Piacenti (a)

(a) FONDAZIONE TOSCANA GABRIELE MONASTERIO; (b) SCUOLA UNIVERSITARIA SUPERIORE SANT'ANNA

Background. Cardiac amyloidosis (CA) is a highly prevalent cause of congestive heart failure. It often requires cardiac pacing due atrioventricular conduction (AV) system disorders, often with cardiac resynchronization (CRT) to prevent development/deterioration of left ventricular (LV) dysfunction. Left bundle branch area pacing (LBBAP) is an emerging alternative to CRT, offering a strict physiological LV activation and very limited use of iodinated contrast. The feasibility of LBBAP in CA is considered limited due to the presence of septal pseudohypertrophy which theoretically limits left-sided conduction system engagement.

Methods. Consecutive patients with CA (both light-chain -AL- or wild-type transtiretin -wtATTr) with a pacing indication for AV conduction disorders were enrolled. Patients underwent baseline echocardiographic examination. LBBAP was achieved by means of stylet-driven catheters advanced transeptally (right ventricle (RV)->LV) via dedicated delivery systems, with continuous monitoring of 12-lead electrocardiographic morphology and impedance until a typical QRS morphology in V1 was obtained (usually rSr' or Sr'). Standard measures for left bundle (LB) capture were used (stimulus to peak R in V6 – S-RV6, V6-V1 interpeak interval, presence of transition in these measures during threshold testing, presence of fascicular signal during spontaneous QRS).

Results. Between January 2022 and June 2023, among 63 patients undergoing LBBAP, 7 patients (11%) had CA, 2 AL (28%) and 5 (72%) wtATTR. Patients were prevalently old (78±7 y) males (6, 85%); LV mean septal thickness was 17±2 mm (min 16, max 20 mm) and mean LV ejection fraction (LVEF) was 45±6%. Indications were PR prolongation in 3, bradycardic atrial fibrillation and LB branch block (LBBB) in 2, primary LBBB in 1 and chronic RV pacing in 1. Baseline QRS duration was 145±47 ms (QRS<120 ms: 97±15 ms, QRS>120 ms: 182±13 ms). LBBAP success was 100%. Fascicular electrograms were observed in ¾ of patients without LBBB; S-RV6 interval was 74±11 ms (>70 ms in 3), RV6-RV1 interpeak interval was 47±9 ms (>30 ms in 6 patients). deltaQRS in baseline broad QRS was -52 ms and +32 ms in narrow. No complications were observed. Over a short follow up of 6 months, an increase in average LVEF was observed (LVEF at 6 months: 51±3%, p<0.05).

Conclusions. In patients with CA, LBBAP is easily achievable with stylet-driven systems with frequent selective engagement of conduction system. QRS narrowing in baseline broad QRS is significant while QRS broadening in baseline narrow QRS is limited. Early results regarding follow-up of surrogate endpoint such as LVEF are promising.

A58: ACUTE IMPACT OF THE VEIN OF MARSHALL ETHANOL INFUSION ON NEWLY-FORMED LESION AND MITRAL LINE BLOCK IN PERSISTENT ATRIAL FIBRILLATION ABLATION

Martina Nesti (a), Andrea Rossi (a), Luca Panchetti (a), Silvai Garibaldi (a), Umberto Startari (a), Gianluca Mirizzi (a), Marcello Piacenti (a)

(a) FONDAZIONE TOSCANA GABRIELE MONASTERIO, PISA

Background. Catheter ablation in persistent atrial fibrillation (PeAF) has limited success. Strategies beyond pulmonary veins isolation failed to demonstrate improvement of long-term rhythm maintenance. The vein of Marshall (VoM) is a promising therapeutic target because it contains triggers and autonomic parasympathetic and sympathetic activity implicated in arrhythmogenesis of AF. Moreover, VOM-ETHO facilitates bidirectional block across the line eliminating protected epicardial

connections. Recent evidences suggest that PVI plus linear lesions and ethanol infusion into the VoM (VoM-ETHO) give a favorable outcomes in PeAF patients.
Purpose. We evaluated acute impact on lesion formation post-VOM-ETHO and the mitral line block validation after a methodical approach including VOM-ETHO, pulmonary vein isolation (PVI), roof-line, mitral line (ML) and cavo-tricuspid isthmus line in a population of PeAF patients. We aimed also to report procedural outcomes after a short follow-up period.
Methods. After a detailed electroanatomical map of the left atrium (LA) (filter at 0.05-0.5 mV if the patient was in sinus rhythm or 0.05-0.3 mV in the case of AF), we thus proceeded with the VoM-ETHO. LA map was thus repeated to assess the extension of the newly-formed low voltage area (LVA). According to the newly-formed LVAs, mitral isthmus ablation was completed endocardially. PVI, roof-line and cavo-tricuspid isthmus line were performed to complete the ablation setting. Bidirectional block across line was then validated during pacing from left atrial appendage. In case of persistence of conduction through the mitral line due to epicardial gaps, additional ablations were applied in the "anchored wall" or in the "free-wall" of the great cardiac vein (GCV).
Results. Twenty-one PeAF patients (67±6 years; 67% male) underwent ablation. The medium value of basal LA-LVAs was 3.1±3.8 cmq and the newly-formed LVAs after the VoM-ETHO procedure was 12.35±7.28 cmq. All patients had bidirectional block validated across the roof-line. Bidirectional block of the ML was achieved in 19/21 patients: in 12/21 patients after endocardial line only and in 9/21 after epicardial gaps ablations into the coronary sinus. The ML procedural time was 11.3±5.9 minutes. No major complications occurred. One patient had mild pericardial effusion due to VoM perforation with a spontaneous resolution. After a short follow-up period (6±3 months), no relapse of AF was observed in 19/21 (90%) patients. 12/21 patients were free from antiarrhythmic drugs (AADs). Interestingly, recurrences happened in patients in whom bidirectional block of the mitral line was not achieved
Conclusions. VoM ethanol ablation added to PVI and linear lesions in the context of a methodical and anatomical approach seems to have promising results in PeAF patients. This strategy seems to be safe and reproducible. A favourable outcome depended on the interventional setting completion and the procedural end-points validation is crucial.

A59: INTOSSICAZIONE DA FLECAINIDE

Costantina Prota (a), Ciro Formisano (b), Giuseppe Caliendo (b), Alessandra Nocilla (b), Emanuele Nigro (b), Fabiana De Simone (b), Alfonso Campanile (a), Gennaro Galasso (b), Carmine Vecchione (b), Amelia Ravera (a)
(a) A.O.U. SAN GIOVANNI DI DIO E RUGGI D'ARAGONA; (b) UNIVERSITÀ DEGLI STUDI DI SALERNO

La flecainide è un farmaco antiaritmico di classe IC molto utilizzato per il controllo del ritmo nei pazienti affetti da fibrillazione atriale parossistica (FAP). Tuttavia in pazienti con insufficienza renale cronica (IRC) il suo utilizzo come terapia cronica non è scevro da rischi, risultando un farmaco poco maneggevole e responsabile di rari casi di intossicazione. Data la scarsità di dati esistenti in letteratura a riguardo le linee guida non indicano una terapia specifica da attuare in questi casi e le poche esperienza riportate in letteratura fanno principalmente riferimento all'utilizzo del bicarbonato di sodio ev per tentare una risoluzione dell'intossicazione. I sintomi che più frequentemente si possono sviluppare sono generalmente dispnea, astenia e palpitazioni, collegati all'insorgenza di tachicardie ventricolari. Il caso clinico che vi proponiamo mette a confronto i diversi effetti e conseguenze dell'intossicazione acuta da flecainide. Nella nostra unità di terapia intensiva cardiologica, infatti, abbiamo ricoverato a distanza di pochi mesi due pazienti, entrambe di sesso femminile, over 75, affette da FAP ed IRC in terapia con flecainide. Entrambe le pazienti accedevano presso il PS della nostra AOU San Giovanni di Dio e Ruggi d'Aragona-Salerno per astenia e dispnea ingravescente insorte nei giorni precedenti al ricovero. In entrambi i casi, all'ECG di ingresso riscontro di tachicardia ventricolare con fcm di 130 bpm circa. In entrambi i casi si è deciso di sottoporre le pazienti a terapia infusionale con bicarbonati ev per tentare una risoluzione del quadro clinico, tuttavia con esiti opposti. In un primo caso, infatti, la paziente è purtroppo deceduta mentre nel secondo abbiamo assistito ad un progressivo miglioramento clinico-laboratoristico delle condizioni generali con conseguente trasferimento in reparto di degenza e successiva dimissione al domicilio.

A60: PEAK STRAIN DISPERSION NEL PACING DELLA BRANCA SINISTRA: CASE REPORT

Giuseppe Caliendo (b), Alessandra Nocilla (b), Emanuele Nigro (b), Angelo Giano (b), Antonella Rispoli (b), Gennaro Vitulano (a), Fabio Franculli (a), Michele Manzo (a), Cristina Esposito (a), Gennaro Galasso (b), Carmine Vecchione (b), Rodolfo Citro (a)
(a) A.O.U SAN GIOVANNI DI DIO E RUGGI D'ARAGONA; (b) UNIVERSITÀ DEGLI STUDI DI SALERNO

La stimolazione selettiva della branca sinistra è un nuovo metodo di pacing che prevede il collocamento di un elettrocatetere nell'area circostante la branca sinistra, che risolve buona parte dei problemi correlati alla stimolazione hissiana. Presentiamo il caso di un paziente di 82 anni sottoposto ad impianto di pacemaker bicamerale con stimolazione selettiva di branca sinistra. Dopo l'impianto si è evidenziato un netto accorciamento della durata del QRS (da 166 msec a 126 msec) nonché, a livello ecocardiografico, un accorciamento del PSD (Peak Strain Dispersion) da 69 msec a 49 msec, indice di una migliore sincronia della contrazione miocardica. Giunge alla nostra osservazione un paziente maschio di 82 anni in seguito ad insorgenza improvvisa di dispnea per sforzi minimi (NYHA III). In anamnesi: ipertensione arteriosa, diabete mellito di tipo II insulino-dipendente e anemia multifattoriale. L'elettrocardiogramma evidenzia ritmo idioventricolare di scappamento a frequenza ventricolare media di 30 bpm. Gli esami ematochimici mostrano iperkaliemia (k+ 6.8 mEq/L) ed iposodiemia (118 mEq/L) con rialzo dei valori di creatinina (1.5 mg/dl). Dopo aver corretto l'iperkalemia e l'iposodiemia, si somministra terapia infusiva con Isoprenalina con evidenza all'ECG di superficie di ritmo sinusale a frequenza cardiaca di 58 bpm, blocco di branca sinistra (QRS della durata di 166 msec), extrasistolia sopraventricolare. Viene eseguito esame ecocardiografico che evidenzia funzione contrattile globale conservata (LVEF 57%), dissincronia del SIV come da BBsx, lieve ipertrofia parietale concentrica, sezioni destre nei limiti per dimensioni e cinesi, segni indiretti di ipertensione polmonare sistolica (PAPs 50 mmHg). Durante la degenza il paziente esegue Holter ECG delle 24 ore in seguito ad un episodio sincopale, con evidenza di malattia del nodo del seno per cui si pone indicazione ad impianto di pacemaker bicamerale con stimolazione di branca sinistra. La procedura è decorsa in assenza di complicanze, al controllo radiografico post-impianto assenza di complicanze pleuro-parenchimali acute ed elettrocateteri normoposizionati. All'ECG evidenza di ritmo da pacemaker (atrio guidato-ventricolo stimolato) con QRS della durata di 126 msec. Al controllo ecocardiografico, evidenza di funzione contrattile globale e segmentaria conservata con netto miglioramento della sincronia del SIV. A sostegno di ciò ci si è affidati al global longitudinal strain, con evidenza al bull eye di accorciamento del Peak Strain Dispersion da 69 msec a 49 msec, parametro in grado di riflettere accuratamente la dissincronia, il cui accorciamento quindi è un indice di una migliore sincronia della contrazione miocardica. Avvalendoci poi dell'equazione di continuità si è poi registrato un notevole miglioramento dello stroke volume (da 60 ml/mq a 80 ml/mq). Questo caso clinico evidenzia come la stimolazione selettiva della branca sinistra possa determinare un significativo accorciamento del QRS che a livello ecocardiografico ha comportato, nel nostro caso, un miglioramento della sincronia di contrazione miocardica ed un aumento della gittata cardiaca. La stimolazione di branca infatti garantisce un pacing più fisiologico e una maggiore sincronia della performance cardiaca. Pertanto, per quanto siano necessari più dati e studi di larga scala a supportare tali conclusioni, possiamo affermare che la tecnica della stimolazione selettiva della branca sinistra costituisca potenzialmente una valida alternativa all'impianto di pacemaker/defibrillatore biventricolare, laddove si preveda una stimolazione pressoché costante.

A61: CLINICAL PREDICTORS OF LEFT ATRIAL LOW VOLTAGE AREAS IN ATRIAL FIBRILLATION PATIENTS UNDERGOING TRANSCATHETER ABLATION: SYSTEMATIC REVIEW AND META-ANALYSIS

Carlo-agostino Oliva (a, b), Michele Golino (a, c), Matteo Morello (a, b), Carlo Arno´ (a), Sara Stella Pesenti (a), Stefano Marzorati (a), Roberto De Ponti (a)
(a) UNIVERSITÀ DEGLI STUDI DELL'INSUBRIA; (b) UNIVERSITÀ DEGLI STUDI DI BRESCIA; (c) VCU HEALTH PAULEY HEART CENTER, RICHMOND, VIRGINIA (US)

Background. Low voltage areas (LVAs) are a frequent finding during voltage mapping of the left atrium (LA) in atrial fibrillation (AF) patients, mainly in the context of transcatheter pulmonary vein isolation (PVI). They are associated with myocardial remodeling and with arrhythmia recurrence. However, the clinical features that may predict the presence of LVAs are still unclear.
Aim. Thus, the aim of this meta-analysis was to summarize the current evidence on the relationship between the main clinical features and risk factors of AF patients and the presence of LVAs in the left atrium.
Methods. A systematic review of peer-reviewed original research studies published up to March 2023 was conducted using the MEDLINE, Web of Science, Scopus and Cochrane Central databases. The technical requirements for performing a meta-analysis of the main population characteristics associated with the presence with LVAs were met.
Of the 413 results after duplicates removal, 22 articles met the inclusion/exclusion criteria (5250 patients).
Results. We found a significant association between the presence of any low voltage area on voltage mapping and the parameters displayed in Figure 1 (in ascending order, based on odds ratio as a measure of size effect). Significant patient-related predictors were female sex, diabetes mellitus, hypertension, CHA2DS2-VASc score; eGFR showed an inverse correlation with LVAs. Among echocardiographic parameters LA volume, LA volume indexed, LA antero-posterior diameter and E/E' ratio were associated with increased risk of LVAs; left ventricular ejection fraction showed an inverse correlation with LVAs. Regarding AF-related characteristics, non-paroxysmal type of AF was identified as a significant predictor of LVAs.

Conclusions. This systematic review and meta-analysis identified consistent associations between readily available clinical characteristics of AF patients and the presence of LVAs in the left atrium. The predictive value of such features can help the clinicians in identifying the best management strategy for AF and those who can benefit from substrate modification therapy.

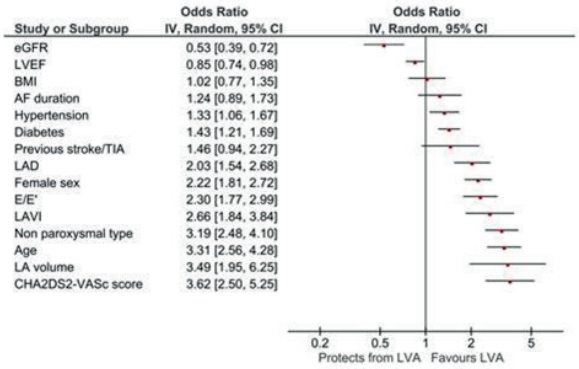

Figure 1. Risk factors for the presence of LVAs. AF: atrial fibrillation; BMI: body mass index; eGFR: estimated glomerular filtration rate; LA: left atrium; LAD: left atrial antero-posterior diameter; LAVI: left atrial volume indexed; LVEF: left ventricular ejection fraction; TIA: transient ischaemic attack.

A62: LE ARITMIE FETALI: DIAGNOSI IN UTERO, TRATTAMENTO E FOLLOW UP A LUNGO TERMINE

Giovanni Taverna (a), Letteria Bruno (b), Francesco Letterio De Luca (b), Placido Gitto (c), Paolo Guccione (c), Giuseppe Pelaggi (a), Ignazio Massimo Scimone (d), Pasquale Crea (a), Concetta Zito (a), Scipione Carerj (a), Gianluca Di Bella (a), Lilia Oreto (a, b)
(a) UNIVERSITÀ DI MESSINA, DIPARTIMENTO DI MEDICINA CLINICA E SPERIMENTALE; (b) UNIVERSITÀ DI MESSINA, UOSD CARDIOLOGIA PEDIATRICA; (c) CENTRO CARDIOLOGICO PEDIATRICO MEDITERRANEO, TAORMINA; (d) SERVIZIO DI CARDIOLOGIA FETALE ASP, REGGIO CALABRIA

Introduzione. Le aritmie fetali si possono riscontrare occasionalmente durante una visita ginecologica o un esame ecografico di routine e rappresentano una causa potenziale di morbidità e mortalità in utero e in età neonatale. La diagnosi delle aritmie fetali è ecocardiografica e si basa sull'osservazione, mediante M-mode o Doppler pulsato, della sequenza delle contrazioni atriali e ventricolari e sulla successiva deduzione del tipo di aritmia in base alle peculiarità dei rapporti tra le onde. Abbiamo condotto uno studio retrospettivo allo scopo di valutare le caratteristiche, la gestione clinica e l'evoluzione delle aritmie diagnosticate in utero e seguite in follow up pre- e post-natale.

Metodi e Risultati. Sono stati esaminati retrospettivamente tutti i casi di aritmie (extrasistoli, tachicardie, bradicardie e blocchi) ad esordio in epoca fetale, identificando 48 pazienti seguiti presso il Policlinico Universitario di Messina ed il Centro Cardiologico Pediatrico Mediterraneo di Taormina dal 2014 al 2020. L'età gestazionale media alla diagnosi era di 27 settimane (range 17-34), in 3 casi vi era idrope fetale, in 7 casi è stata somministrata terapia antiaritmica alla madre, l'età gestazionale media alla nascita era di 37 settimane (range 31-41), in 21 casi è stato eseguito un taglio cesareo urgente; il follow up medio è stato di 4,5 anni. La Tabella riporta le caratteristiche delle aritmie riscontrate ed il loro trattamento. In 4 casi la tachicardia è stata osservata esclusivamente in epoca fetale e non più alla nascita, in 2 di questi associata a grave scompenso fetale con idrope, tutti trattati in utero con digitale e/o amiodarone. I casi di scompenso fetale grave sono stati tre: 1) taglio cesareo urgente a 32 settimane con evidenza di flutter atriale in stato anasarcatico del neonato, trattato con cardioversione elettrica e successiva profilassi con digitale e amiodarone, in assenza di recidive; 2) risoluzione della tachicardia fetale in assenza di aritmia alla nascita e nel follow up a tre anni; 3) risoluzione della tachicardia fetale con ricomparsa all'età di 17 anni in forma di rientro su via accessoria, trattata con ablazione della via stessa. Degli 8 casi di blocco atrioventricolare completo, due hanno presentato evoluzione dal blocco di II grado tipo Wenckebach fino al blocco di III grado durante l'epoca fetale. Sei degli 8 casi di blocco erano associati a patologia autoimmune materna, mentre gli altri due erano associati a cardiopatia strutturale.

Conclusioni. Le aritmie ad esordio fetale sono relativamente rare, ma rappresentano una sfida diagnostica per il ginecologo ed il cardiologo pediatra. L'accurata diagnosi prenatale è fondamentale per il corretto trattamento in epoca pre- e post natale.

Tipo di aritmia	Extrasistoli (18 casi)	Bradicardia (1 caso)	Tachicardia (20 casi)	Blocchi A-V (9 casi)
Caratterizzazione dell'aritmia	16 atriali 2 ventricolari	Sindrome del QT lungo	5 Flutter atriale, 8 AVRT, 3 Atriale ectopica, 4 TSV non specificata	1 BAV 2:1 8 BAV completo
Scompenso fetale	No	No	3 idrope (AVRT, flutter, TSV) 2 disfunzione transitoria (atriale ectopica, flutter, via lenta)	1 dilatazione transitoria
Terapia fetale	No	No	1 flutter (digitale), 2 AVRT (digitale) 1 via acc. lenta (digitale + flecainide) 3 TSV (solo in utero, 2 digitale, 1 amiodarone)	No
Terapia neonatale	No	No	-Flutter: CVE, amiodarone, -AVRT: diving reflex, amiodarone, -Via acc. lenta: adenosina, digitale, nadololo, propranololo -Atriale: propranololo, flecainide	6 impianto pacemaker
Terapia di profilassi	No	Nadololo	Amiodarone, digitale, nadololo, propranololo, flecainide, amiodarone, ablazione	-
Cardiopatia strutturale	No	Stenosi polmonare severa	Valvola aortica bicuspide con insufficienza lieve (AVRT da Kent occulto) Origine della coronaria circonflessa dalla destra e succlavia destra aberrante (TAE)	1) CCTGA 2) CMP dilatativa, 3) Fibroelastosi dei papillari

A63: RUOLO DEL MAPPAGGIO ELETTROANATOMICO NELLA DIAGNOSI E STRATIFICAZIONE DELLE CARDIOMIOPATIE IN CARDIOLOGIA DELLO SPORT

Zefferino Palamà (a), Antonio Gianluca Robles (a), Gabriele De Masi De Luca (a), Simona Minardi (a), Luigi Sciarra (a), Silvio Romano (a)
(a) DIPARTIMENTO DI MEDICINA INTERNA E SANITÀ PUBBLICA, UNIVERSITÀ DEGLI STUDI DELL'AQUILA, L'AQUILA

Caso clinico. Canottiere di 38 anni sottoposto ad idoneità agonistica con riscontro di anomalie ECG suggestive, con frammentazione del QRS, tendenza a bassi voltaggi ed extrasistolia ventricolare monomorfa a cadenza bigemina e trigemina. L'ecocardiogramma che ha mostrato un ventricolo sinistro globoso e dilatato con VTD 185 ml con ridotta funzione sistolica (FE 39%) e sezioni destre nei limiti, in assenza di valvulopatie significative. Il paziente non è riuscito ad eseguire RMN cardiaca per claustrofobia si è pertanto optato per un mappaggio elettroanatomico ad alta densità del ventricolo destro con catetere multipolare HD Grid e sistema di mappaggio NavX Ensite Precision (Abbott). Il mappaggio elettroanatomico del ventricolo destro ha rilevato aree diffuse su tutto il ventricolo destro di alterato voltaggio (con aspetto a chiazza di Leopardo) ed un mappaggio unipolare con aree di alterato voltaggio in parete libera come da coinvolgimento transmurale (figure 2 e 3) procedendo al termine ad ablazione di extrasistolia ventricolare in RVOT-LVOT. Il paziente è stato quindi dimesso con diagnosi di "Ablazione di TVNS in disfunzione ventricolare sinistra (Esiti miocarditici? Cardiomiopatia aritmogena?), Coronarie indenni all'esame contrastografico". Al follow up eseguito a due mesi il paziente mostrava un pressochè completo recupero della funzione sistolica, pur tuttavia con tracciato elettrocardiografico di base immodificato. Il paziente ha eseguito circa un mese dopo RMN cardiaca che ha documentato discinesia dei segmenti medi della parete libera del ventricolo destro e mostrava piccole ma diffuse aree di delayed enhancement subepicardico a livello di parete libera del ventricolo destro e del setto anteriore medio-basale. Veniva pertanto confermata la diagnosi di Cardiomiopatia aritmogena, tuttavia, vista la asintomaticità del paziente per sincope, l'assenza di tachicardie ventricolari sostenute, il recupero della funzione sistolica si soprassedeva all'impianto di ICD rimandando il paziente a follow up. Veniva inoltre confermata la non idoneità ad attività sportiva agonistica, vista la documentata correlazione con la progressione di malattia.

Conclusioni. Il mappaggio elettroanatomico, se correttamente eseguito, rappresenta un valido strumento diagnostico che, come nel caso presentato, può essere valido supporto nella diagnosi delle cardiomiopatie.

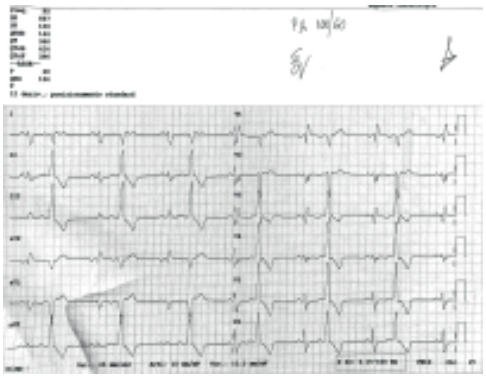

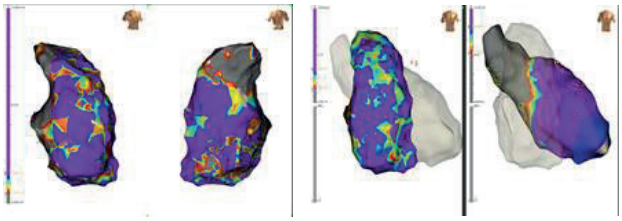

Figure 2 e 3. Mappaggio bipolare e unipolare ad alta densità del ventricolo destro [Purple color: tessuto sano, altri colori: tessuto con alterato voltaggio, scala 0,5-1,5 mv bipolare, 1,5-3,5 mv unipolare].

A64: BRUGADA, OR IS IT

Andrea Palermi (a), Lorena Iezzi (a), Carmelita Cieri (a), Fabrizio Ricci (a), Giulia Renda (a), Sabina Gallina (a)
(a) DEPARTMENT OF NEUROSCIENCE, IMAGING AND CLINICAL SCIENCES, G. D'ANNUNZIO UNIVERSITY OF CHIETI-PESCARA, 66100 CHIETI, ITALY

Brugada Syndrome (BrS) is a hereditary heart condition characterized by abnormal ion channels, leading to distinctive ECG patterns and an increased risk for life-threatening ventricular arrhythmias. However, certain conditions, known as Brugada phenocopies (BrP), can mimic these ECG characteristics without overt ion channel defects. According to the 2022 VAs guidelines, these mimicking conditions must be excluded before confirming a BrS diagnosis.

The case involves a 59-year-old woman who entered the ER displaying mental confusion and drowsiness. She had a history of active smoking and eating disorders. She was hemodynamically stable but showed signs of dehydration, malnourishment, and altered mental status. ECG was performed showing sinus rhythm, heart rate 71 bpm, ST depression in the infero-lateral leads with coved ST elevation in right precordial leads in keeping with type 1 Brugada pattern (Figure A). Laboratory tests indicated acute kidney failure and significant electrolyte imbalances (creatinine 6,21 mg/dL, K+ 2.0 mmol/L, Na+ 121 mmol/L) which led to her being admitted for cardiac monitoring. For the first 14 days, her ECG consistently displayed a Type 1 Brugada-like pattern, even after electrolyte levels were corrected. The latency of type 1 Brugada pattern after electrolyte correction is noteworthy. Eventually, the ECG pattern reverted to normal (Figure B) with occurrence of T-wave inversion in the antero-lateral leads. In the absence of other clinical risk factors and a modified Shangai score of 3.5, the patient was given general recommendations about importance of genetic testing, avoidance of specific drugs and treatment of fever with antipyretics, and a loop recorder was implanted. According to 2014 Anselm classification, this case can be classified as type 1, class B BrP, since no sodium channel blocker test was performed. Rarely has the relationship between electrolyte imbalances and BrP been discussed, especially with the observed latency in ECG changes following electrolyte correction. This unique aspect could offer new perspectives on the mechanisms of ion channel function in BrP.

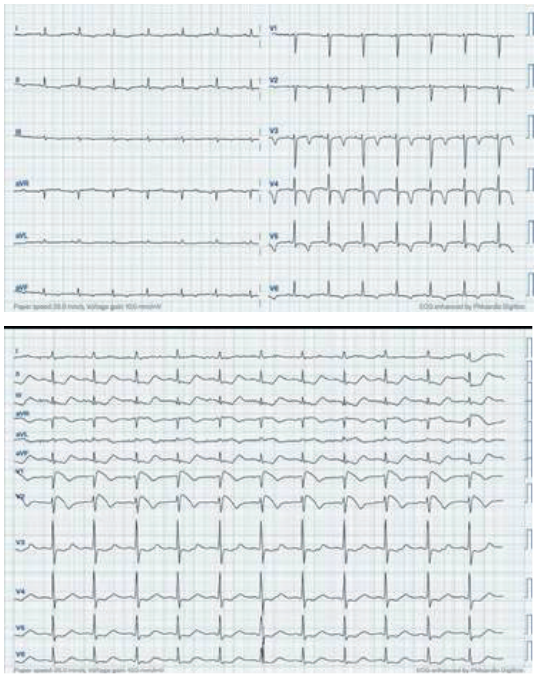

A65: CLINICAL FEATURES AND RESPONSE AT HEAD-UP TILT TEST OF PATIENTS WITH SITUATIONAL SYNCOPE

Angelo Comune (a), Vincenzo Russo (a), Erika Parente (a), Nunzia Laezza (a), Anna Rago (a), Gerardo Nigro (a), Michele Brignole (b)
(a) UNIVERSITÀ DEGLI STUDI DELLA CAMPANIA "LUIGI VANVITELLI" OSPEDALE MONALDI; (b) ISTITUTO AUXOLOGICO ITALIANO OSPEDALE SAN LUCA MILANO

Objective. The study compared clinical characteristics and response at head-up tilt test (HUTT) between situational (SS) and vasovagal syncope (VVS).

Methods. Consecutive patients who underwent nitroglycerin-potentiated HUTT were retrospectively dichotomized into two groups: those with a history of SS and those with a history of VVS. The patients with SS were further subdivided into patients with SS alone and with SS and at least one episode of VVS.

Results. 1285 patients were enrolled: 246 (19.1%) had SS (SS alone in 121 and SS+VVS in 125). SS patients were older (48.8±20.0 vs 44.4±19.1, p=0.007) and more frequently male (57.3% vs 47.7%, p=0.001). At multivariable analysis, smoking habit (OR: 2.28; p<0.0001) were independently associated to SS. HUTT was positive in 175 (71.1%) SS patients and in 737 (70.9%) VVS patients (p=0.9). SS patients showed more mixed (42.3% vs 32.0%, p=0.002) and vasodepressor forms (10.6% vs 6.1%, p=0.01) and less cardioinhibitory responses compared to others (18.3% vs 32.8%, p<0.0001)

Conclusions. Compared with VVS, patients with SS have different clinical characteristics and a high prevalence of hypotensive drugs leading to hypotensive susceptibility. The positivity rate of HUTT is high and similar to that of VVS, although SS patients show a higher prevalence of hypotensive responses.

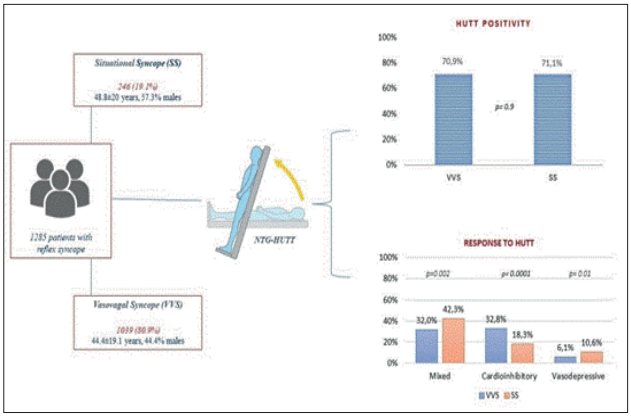

A66: SINUS RHYTHM RESUMPTION IN PERMANENT ATRIAL FIBRILLATION PATIENTS UNDERGOING ABLATE AND PACE WITH CONDUCTION SYSTEM PACING

Antonio Parlavecchio (a, b), Giovanni Coluccia (b), Giampaolo Vetta (a, c), Rodolfo Caminiti (a), Manuela Ajello (a), Pasquale Crea (a), Domenico Giovanni Della Rocca (c), Scipione Carerj (a), Michele Accogli (b), Pietro Palmisano (b)
(a) CARDIOLOGY UNIT, DEPARTMENT OF CLINICAL AND EXPERIMENTAL MEDICINE, UNIVERSITY OF MESSINA, MESSINA, ITALY; (b) CARDIOLOGY UNIT, CARD. G. PANICO HOSPITAL, TRICASE, ITALY; (c) HEART RHYTHM MANAGEMENT CENTRE, UNIVERSITAIR ZIEKENHUIS BRUSSEL-VRIJE UNIVERSITEIT BRUSSEL, BRUSSELS, BELGIUM

Introduction. Spontaneous sinus rhythm resumption (SRR) in patients with symptomatic permanent atrial fibrillation (AF) undergoing "ablate and pace" (A&P) is a curious phenomenon of great clinical impact (Figure 1A). Data on SRR in patients receiving A&P and conductive system pacing (CSP) are lacking. The aim of this study was to assess the incidence and the predictors of spontaneous SRR in a population of permanent AF patients underwent A&P with CSP.

Methods. This study enrolled consecutive patients with symptomatic permanent AF and uncontrolled ventricular rate who underwent A&P with CSP. The incidence and predictive factors of SRR were prospectively evaluated.

Results. A total of 107 patients (79.0±9.1 years, 33.6% male, 56.1% with LVEF <40%, 30.8% with wide QRS, 74.8% with NYHA class ≥III) were enrolled. After a median of 3 months from A&P (IQR: 1-6; range: 0-17), spontaneous SRR was observed in 14 patients (13.1%) (Figure 1B). Multivariable analysis showed that left atrial volume index (LAVi) <49 mL/m2 and a duration of permanent AF <12 months were independent predictors of SRR. Chronic kidney disease was a negative predictor of spontaneous SRR.

Conclusions. In patients undergoing A&P with CSP, 13% spontaneously reverted to sinus rhythm during follow-up. LAVi <49 mL/m2 and permanent AF <12 months appear to be positive predictors of SRR.

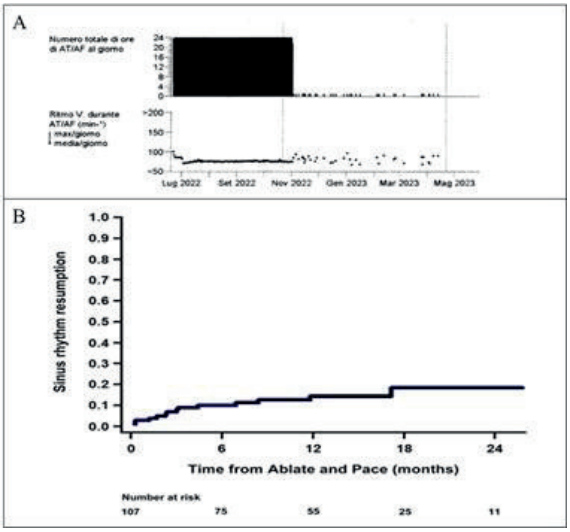

Figure 1. (A) A significant reduction in the burden of atrial fibrillation (from 100% to 2%) recorded by the pacemaker after "ablate and pace". (B) Kaplan–Meier estimation of cumulative sinus rhythm resumption.

A67: ROLE OF HIGH DENSITY ELECTRO-ANATOMIC MAPPING IN REDO PULMONARY VEINS ISOLATION

Alessia Pellitteri (b), Andrea Imporzani (b), Martina Renda (a), Raffaella Marazzi (a), Lorenzo Adriano Doni (a), Vittoria Parisi (a), Roberto De Ponti (a, b)
(a) OSPEDALE DI CIRCOLO; (b) UNIVERSITÀ DEGLI STUDI INSUBRIA

Introduction. Patients undergoing repeat procedures for recurrences of atrial fibrillation after pulmonary veins isolation (PVI) could benefit from high-density mapping (HD) of the left atrium using innovative technologies.

Case description. We report a case of 34 years old male affected by atrial fibrillation (AF) initiated by P/T ectopies which sometimes organized into typical atrial flutter. He had multiple arrhythmia episodes despite oral flecainide, in some cases requiring electrical cardioversion. At the age of 32 he underwent in the same procedure electrophysiology (EP) study, PVI using a three-dimensional mapping system and radiofrequency energy, and ablation of the cavotricuspid isthmus conduction. In the months after the first procedure, he complained of daily episodes of irregular heart palpitations and AF was again documented with moderate (42%) impairment of left ventricular ejection function (LVEF). He underwent a second EP procedure during which resumption of pulmonary vein conduction in all 4 branches was observed. Therefore, PVI was performed again using the same methodology. In the weeks after this procedure and also after blanking period, the patient had multiple recurrences of irregular palpitations documented as AF initiated by monofocal ectopy. The echocardiogram documented further worsening of left ventricular dysfunction (LVEF 35%). Given the failure of the previous procedures and the worsening of the LVEF, a third procedure was performed using HD electroanatomic mapping with a multipolar catheter (Octaray, Biosense Webster). Two punctiform conduction gaps in the superior and inferior antrum of the left common os were clearly identified; interestingly, HD mapping identified ectopies inducting atrial fibrillation originating from these sites. Both gaps and ectopies were ablated by limited RF delivery. Persistent and complete electrical pulmonary veins isolation and absence of ectopies were confirmed at the end of the procedure. After 3 months an echocardiogram showed significant improvement of LVEF to 50%. After 6 months, the patient is still asymptomatic and no recurrence is observed.

Conclusions. This case represents the paradigm of how HD mapping can improve characterization of the arrhythmogenic substrate improving also efficacy of a complex ablation procedure.

A68: FIRST-DEGREE ATRIOVENTRICULAR BLOCK AS A RISK FACTOR FOR MALIGNANT VENTRICULAR EVENTS IN ARRHYTHMOGENIC CARDIOMYOPATHY

Gaia Souryal (b), Andrea Villatore (a), Marianna Cariello (b), Elena Paiotti (b), Paolo Della Bella (b), Giovanni Peretto (a, b)
(a) IRCCS SAN RAFFAELE HOSPITAL, MILAN; (b) VITA-SALUTE SAN RAFFAELE UNIVERSITY, MILAN

Background. First-degree atrioventricular block (I°-AVB) is an acknowledged risk factor for malignant ventricular arrhythmias (VA) in specific cardiomyopathies. So far, however, the prognostic significance of I°-AVB has never been systematically investigated in primary arrhythmogenic cardiomyopathy (ACM).

Purpose. We aimed to evaluate the prevalence of I°-AVB and its prognostic impact in patients with ACM.

Methods. We retrospectively screened a cohort of patients diagnosed with ACM according to the Modified Task Force Criteria in regular follow-up at a national referral center for the management of arrhythmias. All patients underwent a detailed baseline characterization, including ECG, echocardiogram, and continuous arrhythmia monitoring. The primary endpoint was the prevalence of I°-AVB (defined as PQ interval>200 ms) and the occurrence of malignant VA (including sustained ventricular tachycardia, ventricular fibrillation, and antitachycardia pacing or shocks) during follow-up.

Results. Of 42 patients with ACM (median age 42 years, IQR 32-51 years; 64% males), 12 (29%) presented with I°-AVB (median PQ 225 ms, IQR 204-265 ms), while the remaining 30 (71%) had median PQ 160 ms, IQR 144-178 ms. No significant differences were observed between groups in baseline diagnostic work-up, including left ventricular ejection fraction (all p>0.05). During follow-up (median duration 4 years, IQR 1-9 years), a significantly higher proportions of patients with I°-AVB (10/12, 83%) met the primary endpoint, as compared with patients without I°-AVB (11/30, 37%; p=0.006). Remarkably, the baseline ARVC Risk Score at 1, 2, and 5 years (p=0.386, p=0.371, p=0.342, respectively) as well as the rate of ICD implantation in secondary prevention (70% vs. 64% in patients with and without I°-AVB, respectively; p=0.757), did not significantly differ between the two groups.

Conclusions. Our preliminary analysis suggests that I°-AVB may represent a significant prognostic factor in ACM.

A69: LEFT BUNDLE BRANCH AREA PACING: ALTERNATIVE OPTION FOR CARDIAC RESYNCHRONIZATION THERAPY

Sara Stella Pesenti (a), Alessia Carpani (a), Carmela Melania Barbaro (b), Fabrizio Caravati (b), Roberto De Ponti (a, b)
(a) UNIVERSITÀ DEGLI STUDI DELL'INSUBRIA, VARESE; (b) OSPEDALE DI CIRCOLO E FONDAZIONE MACCHI, VARESE

Introduction. Left bundle branch area pacing (LBBAP) could be an alternative option for cardiac resynchronization therapy (CRT) in patients with impaired left ventricular function, left bundle branch block (LBBB) and conventional indication for anti-bradycardia pacing. In this report, the case of a patient with HFmrEF (NYHA class II), LBBB and indication for antibradycardia pacing for 2:1 atrioventricular block is presented.

Case report. A 77-year-old man, with multiple cardiovascular risk factors, presented at the Emergency Department for a prolonged pre-syncopal episode. Prior medical history was uneventful. The 12-lead ECG showed sinus rhythm, first-degree atrioventricular block (AVB) and new onset LBBB. At blood sample, CBC, liver function, renal function and electrolytes within normal limits; D-dimer 1213 mcg/L, Troponin T 15-16 ng/L, Nt-proBNP 662 ng/L and TSH-reflex 2.14 mU/L. At transthoracic echocardiogram, hypertrophic not dilated left ventricle with mild hypertrabeculation of the inferolateral wall and with marked interventricular septal dyssynchrony and mild diffuse hypokinesia more evident to the inferior wall was observed; left ventricular ejection fraction was 40-45% with altered relaxation pattern, while the other findings were unremarkable. Coronary angiography was deemed appropriate and absence of significant stenosis was observed. During electrocardiographic monitoring episodes of 2:1 AVB were documented. Therefore, implantation of a dual-chamber pacemaker with LBBAP was performed through the left subclavian vein, using a dedicated delivery system (Selectra 3D, Biotronik) to position the bipolar screw lead in the selected area of the interventricular septum. The subsequent hospitalization was unremarkable, and the chest X-ray showed correct lead placement (figure 1). At electrocardiographic monitoring, ventricular pacing with a QRS-complex duration of 100 ms (figure 2).

Conclusions. LBBAP is feasible and safe and provides an alternative option for CRT in patients with impaired left ventricular function, LBBB and a conventional indication for anti-bradycardia pacing.

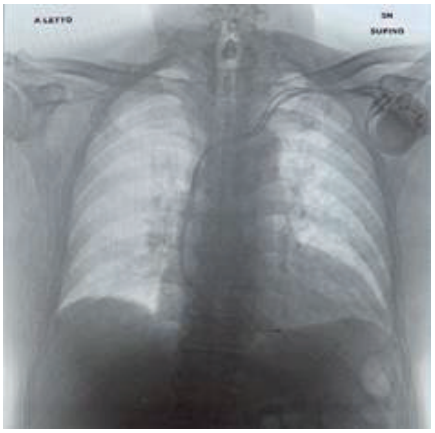

Figure 1

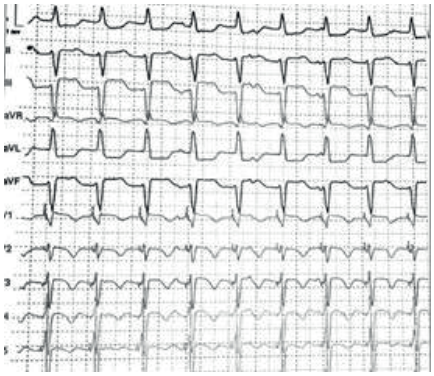

Figure 2

A70: A MALIGNANT ATRIAL ARRHYTHMIA

Matteo Lezzi (a, b), Francesco Angeli (a, b), Luca Bergamaschi (a, b), Francesco Pio Tattilo (a, b), Khrystyna Ryabenko (a, b), Ornella Di Iuorio (a, b), Daniele Cavallo (a, b), Nicole Suma (a, b), Francesca Bodega (a, b), Damiano Fedele (a, b), Davide Bertolini (a, b), Matteo Armillotta (a, b), Carmine Pizzi (a, b)
(a) CARDIOLOGY UNIT - IRCCS AZIENDA OSPEDALIERO-UNIVERSITARIA DI BOLOGNA; (b) DEPARTMENT OF MEDICAL AND SURGICAL SCIENCES - DIMES - ALMA MATER STUDIORUM, UNIVERSITY OF BOLOGNA

A 48-years-old woman presented to the Emergency Department after a syncopal episode, complaining of shortness of breath over the prior three weeks. She was a current smoker with no cardiologic history. Admission ECG showed ectopic atrial bradycardia (HR 35 bpm) and non-specific ventricular repolarization abnormalities; chest radiography revealed a mediastinal bulky mass. Patient was admitted into Cardiology Unit for additional diagnostic procedures. At admission a transthoracic echocardiogram (TTE) was performed that reported a thickening of right atrial free wall with an endoluminal, hyper-echoic, nodule at upper interatrial septum and minimal retro-atrial pericardial effusion; the same findings were confirmed by Cardiac Magnetic Resonance (CMR) which showed in addiction the involvement of superior cave vein, roof and posterior wall of both atriums. To better evaluate the mass metabolic activity, an 18-Fluorodeoxyglucose Positron Emission Tomography/Computed Tomography (^{18}F-PET/CT) was performed, which detected an intense radiotracer uptake (Maximum Standardized Uptake Volume, SUV max, 21.1) by the neoformation, with hypo-uptake spots (necrotic foci). Afterward, patient underwent fibro-bronchoscopy with biopsy; the histological report confirmed the malignant nature of the mass, specifically a Diffuse Large B-Cell lymphoma (DLBCL). At this point, the diagnosis was cardiac metastasis from hematologic cancer and an appropriate specific polychemotherapy was started. Patient remained under a continuous telemonitoring and sinus bradycardia with intra-atrial conduction delay (large and biphasic P waves) alternating with ectopic atrial rhythm and sinus-atrial block with junctional escape rhythm were observed despite continuous chronotropic therapy; at the withdrawal patient experienced periods of sinus arrest (with the longest pause being 8 seconds) associated with syncopal episodes. In consideration of the ECG abnormalities, after electrophysiological assessment, the patient underwent right ventricle leadless pacemaker implantation. In conclusion, cardiac mass presentation is extremely heterogeneous; this case is a unique example of a progressive atrial conduction disease symptomatic of syncope caused by a haematological malignancy infiltrating atrial walls. The diagnostic process was made up of non-invasive diagnostic procedures (TTE, CMR and PET/CT) to make an initial evaluation of the nature of the mass and staging the neoplasia; to confirm the diagnosis a histologic examination was essential. Treatment was based on specific chemotherapy and a pacemaker was implanted to prevent bradyarrhythmias in consideration of the extensive atrial infiltration; a leadless pacemaker was chosen in order to reduce the infective and haemorrhagic risk in a fragile oncologic patient.

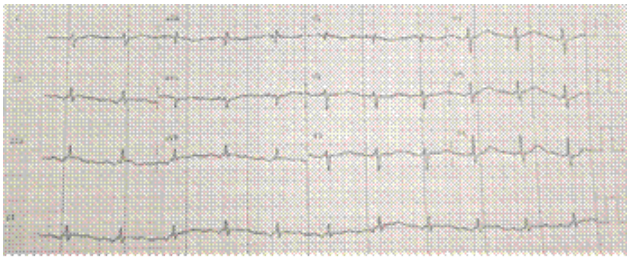

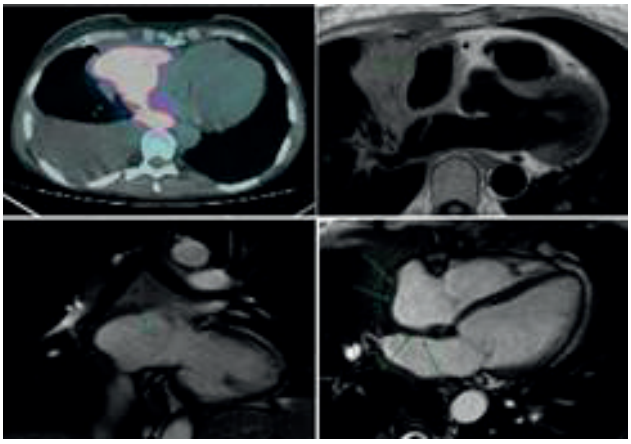

A71: LEAD PLACEMENT IN EXTRAVASCULAR ICD RECIPIENTS: THE FIRST STEP TO PREVENT P-WAVE OVERSENSING

Andrea Quaranta (a), Alessandro Carecci (a), Mirco Lazzeri (a), Michele Bertelli (a), Andrea Angeletti (a), Cinzia Valzania (a), Matteo Ziacchi (a), Cristian Martignani (a), Igor Diemberger (a), Alberto Spadotto (a), Giulia Massaro (a), Nazzareno Galiè (a), Mauro Biffi (a)
(a) ELETTROFISIOLOGIA

Background. Extravascular Implantable Cardioverter Defibrillators (EV ICD) with substernal lead have recently proved to be a safe and effective alternative to conventional transvenous (TV) and subcutaneous defibrillators (S-ICDs). However, in EV ICD Pivotal Study inappropriate shock delivery occurred in almost 10% of patients, and P-wave oversensing (Pwo) accounted for 42% of inappropriate shocks.
Purpose. To investigate the difference of lead placement in patients with and without Pwo.
Methods. 17 patients undergoing implantation as part of the EV ICD Pivotal Study received the substernal lead placement based on computer tomography imaging (CT) and following the protocol recommendations. Lead placement beyond the left lateral sternum border was attempted whenever possible, guided by CT. P-wave detectability (Pwd, detected visually but not sensed by the device) on the sensing vector and Pwo by the device were investigated at each follow-up. The distance of sensing Ring electrodes (R1/R2) from the mid-spine line, connecting the spinous processes from cervical to lumbar vertebral processes, was measured on the posterior-anterior chest radiogram.
Results. Mean age, BMI, NYHA class and LVEF were respectively 53±9yrs, 25.3 ±6 kg/m2, 2 ±0.7, and 39±14%. The main aetiology was non-ischemic cardiomyopathy (12/16), including 3 arrhythmogenic and one hypertrophic cardiomyopathy patients. The implantation was successful in 16 (6 females) out of 17 patients without any complication, with one implant failure due to inadequate sensing (0,5 mV) despite several attempts at tunnelling in different locations (rightward and leftward of the sternum). One patient with P-wave detectability had lead dislodgement after 2 weeks, and underwent repositioning to a more leftward location, where P-wave was not detectable. Only one patient had Pwo at follow-up and received inappropriate shocks (A); the remaining 15 patients neither had Pwd on the sensing vector nor inappropriate shocks (B). Mean sensing amplitude at implantation was 2.7±1.4 mV and 2.6±1.2 mV along a 18±4 months follow-up. The distance of R1/R2 from the mid-spine line was significantly longer in patients with Pwd compared to those without (37±13 vs 18 mm and 30±15 vs 16 mm, respectively).
Conclusions. Placement of EV-ICDs lead leftward to the left sternum border is safe and prevents Pwd. The mid-spine line represents an easy landmark to guide lead placement. R1/R2 distance respectively ≥25/20 mm from the mid-spine line provide a reliable marker of freedom from Pwo.

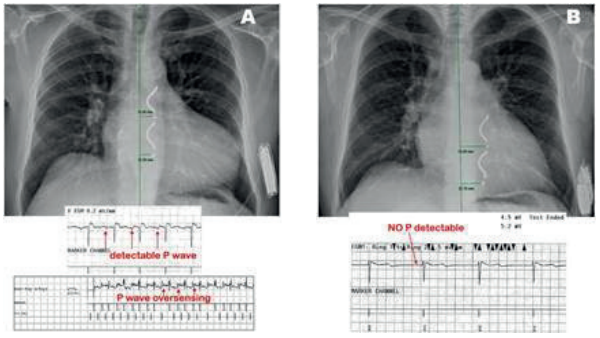

A72: UNUSUAL VENTRICULAR TACHYCARDIA IN A PATIENT WITH PREVIOUS MYOCARDITIS

Davide Rizzello (a), Antonio Crocamo (a), Gianluca Gonzi (a), Matteo Fioravanti (a), Maria Francesca Notarangelo (a)
(a) AZIENDA OSPEDALIERO-UNIVERSITARIA DI PARMA

Introduction. The 12-lead ECG is crucial in predicting the origin of VT, but it is often missing before ablation. Stored ICD EGMs may be the only documentation of prior VT, that can help localize arrhythmias.

Case description. A 52-y.o. male with dilated cardiomyopathy resulting from acute myocarditis received in 2017 an ICD for primary prevention due to severely reduced left ventricular systolic function. In 2021, the ICD delivered an appropriate shock for VT. Ambulatory Holter-ECG monitoring revealed frequent monomorphic PVCs with negative QRS complex in inferior leads. Betablockers were already prescribed, but amiodarone was contraindicated due to pulmonary fibrosis. The patient was referred for an electrophysiological study and catheter ablation of the VT. As the stored ICD EGMs represented the only clinical documentation of VT upon admission, non-invasive programmed stimulation (NIPS) was conducted via the ICD lead to induce VT, which corresponded to the previously recorded VT (Fig. 1A). In particular, the relative short interval between the VT QRS onset on the far-field to the local activation time on the near-field ventricular EGMs suggested an endocardial and septal site of origin of the VT (Fig 1B). At ECG recorded during NIPS, VT QRS complexes displayed: LBBB morphology, early precordial transition by lead V2, leftward superior axis, R>S in lead V6, monophasic R in lead I, absence of deep Q wave in aVR lead. All these findings were suggestive of VT originating from the posterior septal process (PSP) of LV, while initial R-wave in the inferior leads with maximum deflection index (MDI) value <0.55 supported an endocardial exit site of the VT in this region (Fig. 2A). Electroanatomic voltage mapping ruled out the presence of a myocardial ventricular scar. Mapping/ablation catheter was placed into the LV via transseptal approach, while a 4f decapolar catheter was advanced in the MCV. Local ventricular activation preceded surface QRS onset by 50 ms at the site of the PSP-LV area during VT. Mapping of the PSP-LV from inferomedial right atrium showed a broad ventricular signal earlier than QRS onset and the MCV signal, slightly later than the signal recorded from ablation catheter (Fig. 2B). RF energy at the earliest ventricular activation site suppressed the clinical VT within 2 seconds and no further arrhythmias were induced (Fig. 2C).

Discussion. This case emphasizes the importance of identifying the origin of clinical VT in absence of procedural imaging data before a procedure, to determine the best ablation strategy.

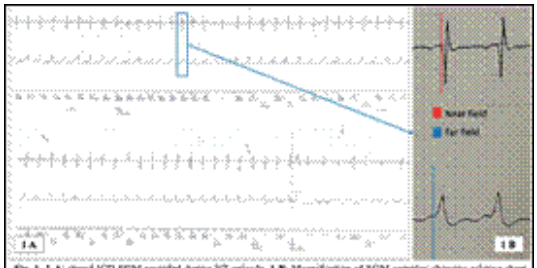

Fig. 1. 1 A: stored ICD EGM recorded during VT episode. 1 B: Magnification of EGM complex showing relative short interval between the VT QRS onset on the far-field ventricular EGM to the local activation time recorded on the near-field ventricular EGM.

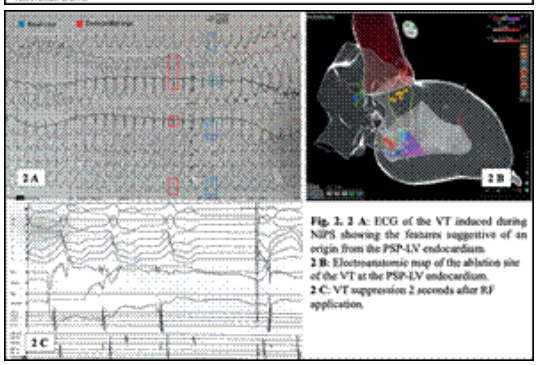

Fig. 2. 2 A: ECG of the VT induced during NIPS showing the features suggestive of an origin from the PSP-LV endocardium.
2 B: Electroanatomic map of the ablation site of the VT at the PSP-LV endocardium.
2 C: VT suppression 2 seconds after RF application.

A73: QT LUNGO CON ARITMIE VENTRICOLARI IN METADONE E CARDIOMIOPATIA ALL'ESORDIO

Edoardo Roagna (b), Filippo Angelini (a), Guglielmo Gallone (a, b), Giuseppe Giannino (b), Alessandro Vairo (a), Matteo Bellettini (a), Pier Paolo Bocchino (a), Andrea Saglietto (a, b), Matteo Anselmino (a, b), Carla Giustetto (a, b), Gaetano Maria De Ferrari (a, b), Veronica Dusi (a, b)
(a) DIVISIONE DI CARDIOLOGIA, DIPARTIMENTO CARDIOVASCOLARE E TORACICO, CITTÀ DELLA SALUTE E DELLA SCIENZA, TORINO; (b) DIPARTIMENTO DI SCIENZE MEDICHE, UNIVERSITÀ DEGLI STUDI DI TORINO

Introduzione. Il metadone è un farmaco dal noto potenziale di prolungamento dell'intervallo QT, con conseguente incremento del rischio di aritmie ventricolari maligne di tipo torsione di punta (TdP), in particolare in presenza di altri fattori favorenti, congeniti o acquisiti. La gestione dei pazienti con prolungamento del QTc e aritmie in corso di metadone è complessa, vista anche l'impossibilità, nella maggior parte dei casi, di sospendere il metadone.

Caso. Un uomo di 39 anni, con storia di passato abuso di cocaina ed eroina, da 13 anni in terapia cronica con metadone, si presenta in pronto soccorso per cardiopalmo e sincopi recidivanti durante la notte dopo recente aumento della dose di metadone da 50 a 130 mg/die. All'ECG di ingresso extrasistolia ventricolare monomorfa bigemina a verosimile origine epicardica dalla parete infero-laterale basale (morfologia a BBDx, concordanza positiva nelle precordiali, DIII e aVF negative) con Fc media 83; QTc non correttamente quantificabile per bigeminismo, ma desumibile marcato prolungamento. Durante l'osservazione plurimi episodi di TdP con necessità di defibrillazione esterna; trattato in acuto con supplementazione di potassio (K+ 3.1 mEq/L), boli di solfato di magnesio (MgSO4) e metoprololo ev. Disposto ricovero in Cardiologia dove viene avviata terapia con nadololo, titolato sino 1 mg/kg/die, e progressivamente ridotta la posologia del metadone fino a 50 mg/die. Eseguiti Holter ECG delle 24 ore a 12 derivazioni e test ergometrico (in corso di metadone 90 mg/die) con evidenza di onde T notched e molto appiattite (con seconda componente dell'onda T a tratti ai limiti elettrocardiografici della definizione di onda U, a tratti di maggior ampiezza della prima) con QTc marcatamente prolungato (>550 ms) e con scarso adeguamento alle variazioni cronotrope. All'ecocardiogramma FE del Vsx 50% con GLS -13% (più marcatamente ridotto a livello dei segmenti inferiore e infero-laterale); finestra elettromeccanica (EMW) marcatamente negativa (-232 ms) e importante dispersione meccanica (+73 ms) Alla risonanza magnetica cardiaca area di late gadolinium enhancement (LGE) non ischemico omosede alle alterazioni della cinesi (parete inferiore e infero-laterale basale). È stato infine condotto il test alla mexiletina (6 mg/kg) con successiva, contemporanea registrazione di elettrocardiogramma ed ecocardiogramma ripetuti nel corso delle 4 ore successive, senza significativa riduzione dell'intervallo QT, dell'EMW o della dispersione meccanica, per cui il farmaco non è stato avviato in cronico. Dopo discussione collegiale e considerando la decisa preferenza del paziente, è stato effettuato impianto di defibrillatore cardiaco endocavitario (ICD) bicamerale. A completamento diagnostico è stata condotta indagine genetica ad ampio spettro per canalopatie e cardiomiopatie (con tecnica NGS e MLPA) risultata negativa. Al follow up di un anno (in corso di metadone 40 mg/die) persistenza di QTc prolungato (580 ms), non recidive aritmiche, NYHA I.

Conclusioni. Il nostro caso descrive l'effetto proaritmico del metadone a medio-alte dosi, associato ad altri fattori predisponenti (ipokaliemia e cardiomiopatia all'esordio), in un quadro di marcato prolungamento dell'intervallo QT con importante corrispettivo di dispersione elettro-meccanica all'ecocardio. Il quadro di bigeminismo ventricolare fisso alla presentazione, del tutto atipico in altre forme di QT lungo acquisito o congenito, è descritto in associazione al metadone e all'effetto del farmaco di inibizione di IK1 oltre che di IKr; nel nostro paziente vi è una correlazione come sede di origine anche alla sede della fibrosi della cardiomiopatia all'esordio.

A74: GRAVIDANZA IN PAZIENTI AFFETTE DA CARDIOMIOPATIA LEGATA A VARIANTI PATOGENE DEL GENE DESMOPLACHINA

Alice Ronsisvalle (a), Riccardo Bariani (a), Kalliopi Pilichou (a), Maria Bueno Marinas (a), Rud Celeghin (a), Paola Veronese (b), Ilaria Rigato (a), Barbara Bauce (a)
(a) DIPARTIMENTO DI SCIENZE CARDIO-TORACO-VASCOLARI E SANITÀ PUBBLICA, UNIVERSITÀ DEGLI STUDI DI PADOVA; (b) UOC OSTETRICIA GINECOLOGIA, AZIENDA OSPEDALIERA DI PADOVA

La cardiomiopatia legata alla presenza di varianti genetiche della Desmoplakina (DSP) è una patologia cardiaca caratterizzata dalla presenza di estesa sostituzione fibrosa epicardica, evidenziata come late-enhancement (LE) alla risonanza magnetica cardiaca (RMC), che può essere associata a dilatazione e/o disfunzione in particolare del ventricolo sinistro (Vsin). Inoltre, sono spesso presenti aritmie ventricolari che possono portare a morte improvvisa. Esistono pochi dati sulle alterazioni emodinamiche indotte dalla gravidanza, dal travaglio, dal parto e dal periodo post-partum nelle pazienti che presentano una cardiomiopatia da DSP. Riportiamo una casistica di 4 pazienti affette da cardiomiopatia da DSP che sono state seguite durante la gravidanza, il parto ed il puerperio. Paziente n.1: diagnosi all'età di 35 anni, alla RM Vsin di normali dimensioni e funzione sistolica lievemente ridotta, LE subepicardico in regione posteriore. All'ECG Holter numerosi BEV realizzanti coppie. A 36 anni gravidanza, terapia con metoprololo 50 mg x 2, decorsa senza complicanze, parto cesareo alla 40ma settimana (peso alla nascita 2780 g). All'ecocardiogramma un anno dopo il parto dimensioni e funzione del Vsin invariati, presenza di TVNS con indicazioni ad impianto di ICD. Paziente n.2: diagnosi all'età di 31 anni, alla RM ventricoli di normali dimensioni e funzione, LE tipo stria subepicardica alla parete inferiore del Vsin. All'ECG Holter frequenti BEV isolati. A 35 anni gravidanza, in terapia metoprololo 25 mg x 2, saltuario cardiopalmo, parto a termine per via vaginale alla 40ma settimana (peso alla

nascita 3020 g). Nel post-partum episodi di cardiopalmo, non aritmie maggiori. Non modificazioni alla RM o all'ECG Holter due anni dopo il parto. Paziente n.3: diagnosi all'età di 22 anni, alla RM ventricoli di normali dimensioni e funzione, LE tipo stria epicardica parete inferiore del Vsin. All'ECG Holter rari BEV. Due gravidanze a 28 e 32 anni decorse senza complicanze in terapia con metoprololo 25 mg x 2 e concluse con parto cesareo (a 38 settimane, peso 2930 e 3080 g rispettivamente). All'ultima RM (42 anni) evidenza di estensione del LE alla parete inferiore ed infero-laterale del Vsin. Paziente n.4: diagnosi a 22 anni, alla RM diagnosi di ACM con severa dilatazione e disfunzione biventricolare (FE Vsin: 35%), IT severa ed esteso LE biventricolare. All'ECG Holter presenza di TVNS, eseguito impianto di s-ICD in prevenzione primaria. Prima valutazione c/o il nostro centro con paziente già in gravidanza, classificata ad alto rischio. Gravidanza decorsa senza complicanze ed in buon compenso emodinamico (NYHA I). Cesareo programmato a 36 settimane, peso alla nascita 2750 g. In 6^ giornata episodio di scompenso cardiaco con ritorno allo stato di compenso tramite terapia diuretica e terapia medica anti-scompenso. In conclusione la gravidanza nelle pazienti con cardiomiopatia da DSP e funzione Vsin normale o lievemente ridotta è stata ben tollerata, mentre nella paziente con interessamento biventricolare e funzione sistolica del Vsin severamente ridotta ha portato a scompenso nel post-partum. In nessun caso sono stati documentati eventi aritmici maggiori o rilevate complicanze fetali o neonatali. I casi documentati sottolineano l'importanza nelle pazienti con Cardiomiopatia legata a varianti di DSP del counseling pre-concezionale e di regolare follow-up nel corso della gravidanza da parte del team cardio-ostetrico, con gestione e terapie "individualizzate" per ciascuna paziente.

A75: TAPSE/PAPS RATIO: SOLID ECHOCARDIOGRAPHIC INDEPENDENT PREDICTOR OF PRECAPILLARY PH AND PROGNOSIS IN HEART FAILURE, HOLDING STEADY IN 1 YEAR FOLLOW-UP IN LEADLESS-PM-IMPLANTED SUBJECTS

Antonella Sabatini (a, b), Nicolò Pellegrini (a), Solange Piccolo (a), Alessandro Varriale (a), Sofia Capocci (a), Luca Tomasi (a), Giacomo Mugnai (a), Elena Franchi (a), Ruggero Tomei (a), Flavio Ribichini (a), Bruna Bolzan (a)
(a) AOUI VERONA UNIV. HOSPITAL - CARDIOLOGY; (b) CARDIOVASCULAR CENTER OF SARASOTA, SARASOTA, FLORIDA, USA

Background. The ratio of tricuspid annular plane systolic excursion (TAPSE)/echocardiographically measured systolic pulmonary artery pressure (PASP), has been recently proposed as surrogate of RV-arterial coupling. In fact, the relationship of TAPSE/PAPS ratio with invasive pressure-volume loop-derived Ees/Ea was previously exploited. Furthermore, TAPSE/PAPS was deemed a powerful independent marker of prognosis in heart failure. Recently, a prognostic cutoff value of 0.30 mm/mmHg has been proposed.
Purpose. To assess whether leadless-PM implanted subjects exhibit a stable TAPSE/PAPS ratio at echocardiographic follow-up, holding steady above the prognostic cutoff of 0.30 mm/mmHg.
Methods. This study is a retrospective, observational research study: 136 consecutive subjects (February 17, 2016 - May 20, 2023), treated in our Center, implanted with Micra VVI/AV leadless-PMs Micra MC1VR01 and Micra AVMC1AVR1, Medtronic, Inc., were evaluated at implant time via transthoracic echocardiography, and at 1-year follow-up period. In 11 subjects the TAPSE/PAPS ratio was assessed.
Results.

Results				
Total Number of Subjects		136		
Total Male		110		81%
Total Female		26		19%
Number of subjects with 1-Year-Follow-up-Echocardiography		36		26%
Number of subjects who underwent TAVI		37		27%
Number Leadless-PM-Implanted Subjects with Remote Monitoring		49		36%
Age (average)		76 ±	9	
Weight (average)		82 ±	19	
Height (Average)		169 ±	19	
BMI (Average)		28 ±	5	
BSA (Average)		2 ±	0,24	
Number of subjects with TAPSE/PAPs index at basal and at F-up		11		8%
Basal TAPSE/PAPs index average		0,78 ±	0,41	
F-Up TAPSE/PAPs index average		0,63 ±	0,28	
General Population Subjects: EF	Basal TTE Echocardiography	56 ±	7	
General Population Subjects: EF	1 Year F-Up TTE Echocardiography	52 ±	9	

Conclusions. The main results from this study show that subjects at higher risk of transvenous pacemaker complications relatively to the right ventricle function evaluation at implant time as compared to 1 year-F-up time, implicating a negligible impact of leadless pacing on the RV function. According to our data, considering the already demonstrated benefits of leadless pacing in subjects at high risk of PM complications, determination should be made to increment the rate of leadless PM implants.

A76: LOW PRECORDIAL QRS VOLTAGE AS A POTENTIAL BIOMARKER OF CARDIO-OBESITY

Antonella Sabatini (a, b, c), Olena Mahneva (b), Mahfouz El Shahawy (b)
(a) AOUI VERONA UNIV. HOSPITAL - CARDIOLOGY; (b) CARDIOVASCULAR CENTER OF SARASOTA, SARASOTA, FLORIDA, USA; (c) BOZEN/BOLZANO REGIONAL HOSPITAL - CARDIOLOGY

Background. Excess epicardial fat volume (EFV), an indicator of cardio-obesity, has been reported as a marker of a cardiovascular disease (CVD) risk.
Purpose. To explore whether there is a link between a low precordial QRS voltage on ECG and excess EFV.
Methods. Total of 2897 subjects were screened; all were 18+ and underwent CVD risk assessment using the Early Cardiovascular Disease Risk Scoring System (ESCVDRS) known as Rasmussen Risk Score (RRS) (previously reported). The ESCVDRS includes 7 vascular and 3 cardiac tests. In addition to the ESCVDRS, waist circumference was also measured. Out of the 2897 subjects, 330 underwent a cardiac CT for EFV determination. Out of 330 subjects, 73 non-obese (waist circumference ≤35in. for F; ≤40 in for M) subjects were further evaluated for the relevance of QRS voltage to EFV. Out of 73 subjects, 31 females were the subjects of this investigation and were further categorized into 2 groups: group 1 (n=21) females with normal EFV (≤90cm^3) and group 2 (n=10) females with excess EFV/cardio obesity (>90cm^3) Both groups were assessed for low QRS voltage on ECG in precordial leads (<1mV in lead V5).
Results. Shown in table below:

	Non-Obese Females: n = 31	
	Group 1: n=21 (68%)	Group 2: n=10 (32%)
Average EFV (cm^3)	65.5 (no cardio obesity)	100 (cardio obesity)
Number of Subjects with ECG with low QRS voltage	10 (47.6%)	7 (70%)

Conclusions. Cardio obese females (those with high average EFV) had statistically higher rates of low precordial QRS voltage on EKG than those with normal EFV ($p<0.05$). From this, low precordial QRS voltage on ECG in the absence of other known causes may be indicative of excess EFV/cardio obesity and may justify further evaluation leading to early treatment. Early detect to protect!

A77: VALIDAZIONE DI UN NUOVO SCORE PRE PREDIRE I PAZIENTI IN RITMO SINUSALE STABILE DOPO SINGOLA PROCEDURA DI ISOLAMENTO DELLE VENE POLMONARI IN PAZIENTI CON FIBRILLAZIONE ATRIALE (FA) RECIDIVANTE

Tania Sacco (b), Gian Paolo Gelmini (a), Tommaso Bignotti (a), Giuseppe Coppola (b), Claudio Pratola (a), Giosuè Mascioli (a)
(a) OSPEDALE DI DESENZANO DEL GARDA (BS); (b) POLICLINICO UNIVERSITARIO "P. GIACCONE", PALERMO

Background. La procedura di ablazione della FA è ormai una procedura standardizzata e con precise indicazioni. Secondo studi presenti in letteratura, la necessità di una seconda procedura ablativa per recidive aritmiche dopo un periodo di blanking di 3 mesi varia dal 20 al 40%. Uno studio condotto su oltre 1000 pazienti ha dimostrato che uno score (APPLE SCORE) basato su semplici parametri (età, funzione renale, tipo di FA, diametro atriale sinistro e frazione d'eiezione sinistra) è in grado di identificare i pazienti a rischio di recidiva entro un anno dalla procedura.
Scopo. Scopo del nostro studio è stato quello di valutare se l'APPLE score conserva il suo valore predittivo aumentando il potere diagnostico di recidiva di FA utilizzando un ILR invece di un Holter a 7 giorni o di un event recorder.
Materiali e metodi. 20 pazienti (18 maschi, età media 58±7 aa) sono stati sottoposti nel nostro Centro ad ablazione con RF e sistema di mappaggio elettroanatomico delle vene polmonari (17 Columbus, EverPace, e 4 EnSite, Abbott). 12 erano affetti da FA parossistica e 8 da FA persistente; la durata mediana della storia dell'aritmia era di 943 giorni (25°-75° percentile 386-2377 giorni). Tutti i pazienti un mese prima della procedura sono stati sottoposti ad impianto di ILR.
Risultati. Dopo un follow-up medio di circa 6 mesi, 11 pazienti (55%) non avevano più avuto recidive aritmiche. L'APPLE score non era in grado di predire nei nostri pazienti la recidiva aritmica, mentre un nuovo score (DESE Score) aveva un elevato potere discriminatorio (AUC 0.96). Attribuendo 1 punto per un BMI>29.99 (obesità), per la storia di FA persistente, per un tempo di attivazione atriale sinistro (misurato come l'intervallo tra segnale atriale sul CS ostiale e sul CS laterale)>25 ms e la presenza di recidive di FA (almeno 1 minuto) durante il periodo di blanking (entro 90 giorni dalla procedura) registrate all'ILR, la mediana dello score era di 1 nel gruppo senza recidive e di 3 nel gruppo con recidive ($p=0.005$ con Mann Whytney U Test a 2 code).
Conclusioni. Il nostro è uno studio molto preliminare, ma dimostra che il successo della procedura ablativa della FA è molto diverso a seconda della strategia di monitoraggio utilizzata per il follow-up. Questo spiega a nostro parere perché l'APPLE score non sia utile nei nostri pazienti. Il dato interessante dello score proposto è quello di unire dati clinici (tipo di FA ed obesità) a dati strutturali atriali (il tempo di attivazione è un surrogato della presenza di fibrosi) e alla corretta identificazione dei pazienti con early recurrences.

A78: RUOLO PREDITTIVO DELL'EVENTO ARITMICO INDICE NELLA CARDIOMIOPATIA ARITMOGENA

Sergio Sorrentino (a), Alberto Spadotto (a), Giulia Massaro (a), Andrea Angeletti (a), Cristian Martignani (a), Matteo Ziacchi (a), Mauro Biffi (a)
(a) POLICLINICO DI SANT'ORSOLA IRCCS, BOLOGNA

Introduzione. i pazienti affetti da cardiomiopatia aritmogena presentano un rischio aritmico significativo e solo modestamente prevedibile. Nell'era contemporanea, la maggiore consapevolezza di malattia e l'anticipo diagnostico determinano una netta prevalenza di scenari clinici di prevenzione primaria e in tale contesto il primo evento aritmico nella storia clinica del paziente è rappresentato dall'attivazione di ICD, che rappresenta un'inevitabile sovrastima dell'effettivo rischio di aritmie cliniche e, tra queste, il rischio di aritmie potenzialmente fatali (LTA).
Obiettivi dello studio. Caratterizzazione del rischio aritmico in una coorte monocentrica di pazienti affetti da cardiomiopatia aritmogena sulla base dell'evento aritmico indice.
Materiali e metodi. All'interno di una popolazione di pazienti con diagnosi certa di ACM riferiti ad un centro di terzo livello tra il 1992 e il 2021, sono stati identificati 43 pazienti (19 ARVC; 10 ALVC; 14 ACM biventricolare; sesso maschile 63%; età mediana 45,5 anni IQR 32-54) che hanno presentato almeno un evento aritmico nel corso della storia clinica. Per ciascun paziente è stato identificato e classificato l'evento aritmico indice (definito come prima aritmia ventricolare clinica non fatale o come prima attivazione appropriata di ICD) e gli eventi aritmici al follow up. Sono stati inoltre definiti gli eventi aritmici potenzialmente fatali (LTA) come aritmie ventricolari con ciclo <300 ms (FC>200 bpm) e l'evento morte improvvisa (SCD).
Risultati. All'interno della coorte di pazienti selezionata l'evento aritmico indice è stato rappresentato in 27 pazienti (62%) da aritmie cliniche non fatali (8 pz: SCA; 7 pz TV sincopali; 10 pz TV non sincopale) e in 16 pazienti (38%) da attivazione appropriate di ICD (6 pz non LTA; 10 pz LTA). Ad un follow up mediano di 5,6 anni (IQR 2,4 – 9,7 anni) dall'evento aritmico indice, la sopravvivenza libera da eventi aritmici è risultata rispettivamente del 26% e del 19% (HR 0,84; CI 0,64 – 1,13) con un tempo mediano all'evento rispettivamente di 1,7 vs 2,04 anni. La sopravvivenza libera da LTA al follow up è risultata rispettivamente del 44% e del 25%. La tipologia di evento aritmico clinico di esordio (SCA; TV sincopale; TV non sincopale) non è risultata significativamente correlata all'incidenza di eventi LTA/SCD. L'incidenza di un evento LTA è risultato predittore di ulteriori eventi LTA/SCD (HR 2,14; CI 1,12-4,07). Nei pazienti con primo evento aritmico non LTA (n.15), si è comunque verificata un'incidenza non trascurabile di eventi LTA (n.7, 46%).
Conclusioni. In una coorte monocentrica di pazienti affetti da ACM l'evento aritmico indice, costituito indifferentemente da un'aritmia clinica non fatale o dalla prima attivazione dell'ICD, è un forte predittore di successivi eventi aritmici. In tal senso l'evento aritmico indice giustifica una strategia più incisiva nella gestione del burden aritmico proporzionale alla severità del quadro clinico. La tipologia di evento aritmico indice è poco informativa sul successivo rischio di LTA/SCD.

A79: ATRIAL FIBRILLATION AND CANCER: A METANALYSIS ON ORAL ANTICOAGULANT THERAPY

Andrea Spangaro (a), Elena Sala (a), Matteo Rocchetti (a), Alessandro Minardi (a), Barbara Conconi (a), Stefano Lucreziotti (a), Alberto Cereda (a)
(a) OSPEDALE SAN CARLO BORROMEO (MILANO)

The coexistence of cancer and atrial fibrillation (AF) is an increasingly reported clinical issue due to a longer life expectancy in the general population along with a higher survival rate of oncological patients. Impaired hemostasis and inflammation represent part of the common pathophysiological ground linking these pathologies. It is known how AF leads to a pro-thrombotic state. Similarly, cancer patients experience higher risks of thrombotic manifestations but are concomitantly exposed to a superior bleeding risk compared to non-oncological populations. In AF, anticoagulation and its management have been extensively studied and optimized; aside from the more classic heparins and vitamin K antagonists (VKAs), a relatively new option is represented by direct oral anticoagulants (DOACs). Despite an impaired coagulation profile, the oncologic population is largely understudied regarding anti-thrombotic therapies. The potential benefit of DOACs appears to be reasonable but not supported by evidence at present times. (2) AIMS AND METHODOLOGY: The purpose of the study is to confirm the benefit of DOACs in cancer patients and evaluate therapy efficacy in terms of stroke reduction compared to major bleeding events. An online search was conducted using the MEDLINE database; searches were updated to February 2023. 11 studies (total amount of 266,865 patients) were finally included. The following meta-analytical variables were considered: ischemic stroke, systemic embolism, venous thromboembolism, major bleeding, minor bleeding, gastrointestinal bleeding, cerebral bleeding, overall mortality in the 1-year follow-up. Number needed to treat (for ischemic events) and the number needed to harm (for bleeding events) were calculated too. (3) RESULTS. The ischemic (5.2%; SD 2.7-7.7) and hemorrhagic (5.2%; SD 4.2-6.2) risk profiles at one year in cancer patients are equally increased. The therapeutic strategy DOACs vs Warfarin determines a reduction in the incidence of ischemic stroke of 27% (OR 0.73 CI 95% 0.52-0.94). An even more important reduction of major bleeding events to 42% (OR 0.58 95% CI 0.45-0.72) can be observed. The reduction in bleeding affects both cerebral and gastrointestinal bleedings. No benefit on overall mortality in this cardio-oncology population (OR 0.86 95% CI 0.57-1.14) has been shown. The reduction in major and minor bleeding appears greater as the percentage of females in the studies increases. The use of antiplatelet agents neutralizes the beneficial effect on the reduction of minor bleeding events but has no relevance to major bleeding events. Patients with higher CHA2DS2-VASc and HAS-BLED scores are those who benefit most from the reduction of bleeding events. The reduction in major bleeding and the even more significant decrease in stroke rates determine a net clinical benefit, quantifiable in terms of the number needed to treat (NNT). For every 100 theoretical patients receiving DOACs, there is a reduction of a stroke event for every 21 patients. Similarly, NNT becomes 45 if the major bleeding covariate is considered. NNT decreases to 14 if we consider together stroke reduction "or" major bleeding event demonstrating the extreme effectiveness of this therapeutic strategy. (4) CONCLUSIONS. The present metanalysis suggests a good safety and efficacy profiles of DOACs in AF cancer patients in terms of stroke reduction and reduction of major bleeding events compared to VKAs. However, further studies will be needed to understand which patients benefit more from this type of anticoagulation strategy.

A80: FLUOROLESS TRANSCATHETER ABLATION OF ATRIOVENTRICULAR NODAL RE-ENTRANT TACHYCARDIA WITH INITIATION BY DUAL (1:2) VENTRICULAR ACTIVATION: A CASE REPORT

Enrico Guido Spinoni (a), Alberto Battaglia (a), Natascia Cerrato (a), Marco Gagliardi (a), Francesco Geuna (a), Andrea Lamanna (a), Sofia Capocci (a), Domenico Caponi (a), Marco Scaglione (a)
(a) DIPARTIMENTO DI ELETTROFISIOLOGIA, OSPEDALE CARDINAL MASSAIA, ASTI

Background. Dual atrioventricular (AV) nodal physiology is a common finding, occurring in10% of patients. A 1:2 or dual ventricular response can occur in patients with dual AV nodal pathways, with possible initiation of atrioventricular nodal re-entrant tachycardia (AVNRT). Pharmacological therapy targeting the AV node conduction (betablockers or calcium-channel blockers, CCBs) is effective in reducing the occurrence of tachycardia recurrences in this population, but with high rate of recurrences. In such cases, transcatheter ablation of the slow-pathway is a valid option in the treatment of this arrhythmia. Nowadays, there is a lack of data on the efficacy and safety of ablation of AVNRT with a dual ventricular response initiation. We present the case of a young man with very frequent episodes of AVNRT with dual ventricular response onset.
Case report. A 16-years old man presented to Our Center symptomatic for recurrent episodes of tachycardia at 170 bpm since the age of 6 years-old. 24-hourse ECG Holter recording showed frequent recurrences of paroxysmal supraventricular tachycardia during the day. The examination of the ECG Holter recording underlined the presence of AVNRT slow-fast triggered by dual ventricular response (Figure 1 – conduction on the fast and slow-pathway with successive dual ventricular response and subsequent retroconduction on the AV node triggering AVNRT). CCBs therapy with Verapamil was started, titrated up to the maximum tolerated dose, which was only partially effective in reducing the rates of the arrhythmia recurrences. Considering the multiple recurrences and the resistance of the pharmacological therapy, elettrophisiology study (EPS) with electroanatomic mapping system (EAM, CARTO3, Biosense Webster) was performed. The EPS confirmed the presence of AV node dual pathway and the inducibility of AVNRT slow-fast with onset by a dual ventricular response (Figure 2). Fluoroless transcatheter ablation with radiofrequency was then performed, targeting the AV node slow-pathway (Figure 3). The procedure was effective and at the end, no arrhythmias were recorded. The day after the procedure the patient was discharged at home without pharmacological therapy. At 3-months follow-up, the patient experienced no relapse and could start non-competitive sport activity.
Discussion and Conclusions. Dual ventricular response in patients with dual AV node pathways triggering AVNRT is not an uncommon findings and can lead to frequent arrhythmia recurrences in this population despite maximal pharmacological therapy. Transcatheter ablation with radiofrequency when feasible, or cryoenergy, performed with the guide of EAM is safe and effective in treating this arrhythmia.

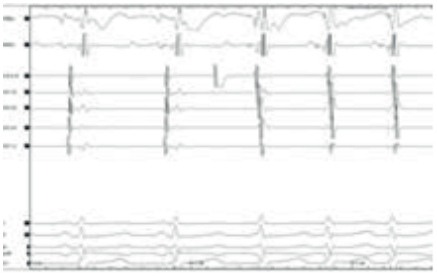

Figure 2

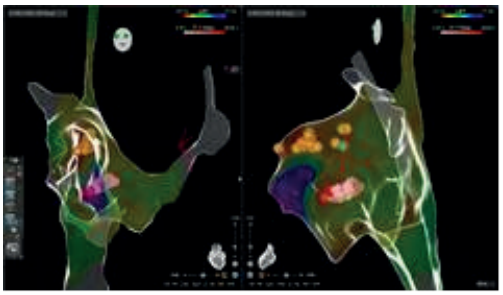

Figure 3

A81: RUOLO PROGNOSTICO A LUNGO TERMINE DELLA RISONANZA MAGNETICA PRE IMPIANTO ICD: STUDIO LONGITUDINALE DI COORTE

Matteo Spoladori (b), Antonio Crocamo (a), Francesco Capoccia (b), Davide Rizzello (b), Rosi Vrenozaj (b), Alberto Bettella (b), Stefano Cavalli (b), Marco De Maria (b), Carlotta Zilioli (b), Luca Bearzot (b), Gian Luca Gonzi (a), Anselmo Alessandro Palumbo (a), Giampaolo Niccoli (a, b), Diego Ardissino (a, b), Maria Francesca Notarangelo (a)
(a) AZIENDA OSPEDALIERO-UNIVERSITARIA DI PARMA; (b) UNIVERSITÀ DI PARMA

Background. Sebbene sia stato dimostrato che la mortalità cardiovascolare aumenti nei pazienti con frazione di eiezione (FE) ridotta, non c'è evidenza che tale parametro identifichi con elevata sensibilità quelli che andranno incontro a morte cardiaca improvvisa (MCI). La risonanza magnetica cardiaca (RMc), mediante caratterizzazione della scar miocardica, può consentire una miglior stratificazione del rischio aritmico di tali pazienti. Obiettivo dello studio è stato identificare i fattori, indipendenti dalla FE, in grado di stratificare il rischio aritmico in una popolazione di pazienti sottoposti ad impianto di ICD.

Materiali e metodi. Trattasi di uno studio osservazionale, retrospettivo, longitudinale, di coorte. Sono stati raccolti dati anagrafici, clinici e radiologici in tutti i pazienti sottoposti ad impianto di ICD tra il 2014 ed il 2021. Sono stati registrati i decessi per tutte le cause e gli eventi aritmici significativi (TVNS, TVS, FV) riscontrati al controllo periodico dei dispositivi e mediante monitoraggio remoto. È stata eseguita un'analisi univariata di Kaplan-Meier per definire il valore prognostico dei vari fattori presi in esame in relazione all'endpoint primario composito, costituito da aritmie ventricolari e mortalità da tutte le cause.

Risultati. 700 pazienti (82% maschi, età media 69 ± 13 anni) sono stati sottoposti ad impianto di ICD (46% VR, 15% DR, 36% CRTD, 3% S-ICD). La RMc preimpianto era disponibile in 354 di essi, 69% impiantati in prevenzione primaria, 52% affetti da cardiopatia non ischemica. Il LGE era presente nel 67% dei pazienti; il 30% di questi lo presentava in meno di 5 segmenti. Al termine del follow up medio di 8 anni il 30.6% dei pazienti risultavano deceduti. I pazienti con LGE hanno mostrato un rischio significativamente aumentato di raggiungere l'endpoint primario rispetto ai pazienti senza LGE (HR=2.17 [1.78-2.60]; p<0.05); tale dato era principalmente guidato dalla differenza di mortalità, poiché la sola incidenza di aritmie ventricolari non variava significativamente tra i due gruppi (HR=0.7 [0.65-1.02]; p=0.23). Nei pazienti con meno di 5 segmenti cardiaci coinvolti da LGE il rischio di raggiungere l'endpoint primario era maggiore rispetto ai pazienti con più di 5 segmenti coinvolti (HR=2.46 [2.09-9.07]; p<0.05).

Discussione. Il LGE è risultato un fattore prognostico in relazione all'incidenza di eventi aritmici e mortalità per tutte le cause. È possibile speculare, pertanto, che la stima della fibrosi miocardica sia un predittore complessivo del futuro andamento clinico del paziente, piuttosto che soltanto di eventi aritmici. La presenza di LGE in meno di 5 segmenti, favorendo una geopardizzazione del substrato, è un fattore prognostico rilevante per la predizione degli eventi aritmici.

Conclusioni. In una popolazione di pazienti con FE depressa la RMc preimpianto può stratificare il rischio aritmico e di mortalità per tutte le cause.

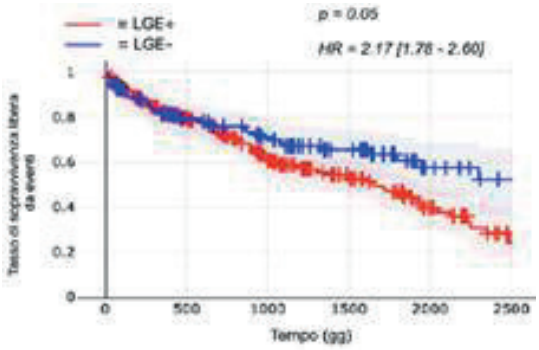

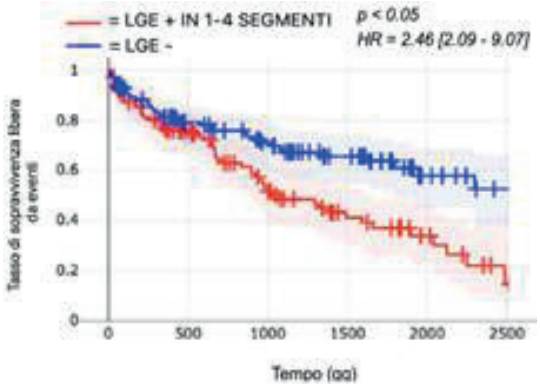

A82: ACHIEVING LEFT BUNDLE BRANCH PACING DESPITE DIFFICUT ANATOMY

Simone Taddeucci (b), Silvia Garibaldi (a), Luca Panchetti (a), Martina Nesti (a), Andrea Rossi (a), Gianluca Mirizzi (a), Umberto Startari (a), Marcello Piacenti (a)
(a) FONDAZIONE TOSCANA GABRIELE MONASTERIO; (b) DIVISION OF CARDIOLOGY, UNIVERSITÀ DEGLI STUDI DI SIENA

A 84-year-old man with chronic ischemic heart disease and heart failure was proposed for upgrading procedure with ablate-and-pace because of atrial fibrillation with uncontrolled heart rate despite optimal medial therapy. A dual chamber Implantable Cardioverter Defibrillator was previously implanted in another hospital 4 years earlier for primary prevention with a right-side implantation. Upgrading procedure to Cardiac Resynchronization Therapy was complicated by the angiographic finding of a sub occlusion of the right subclavian vein in correspondence of its intrathoracic tract (see picture), visible upon administration of iodinated contrast. A first attempt was made to advance a conventional 0.035'' guide, but after several chances it did not overcome the obstruction, requiring the choice of a Balance Middleweigh 0.014'' guide. This hydrophilic wire allowed to overcome the obstruction until the right atrium. By applying serial and progressive dilatations, we overcame the obstruction and a VEGA R58 pacing catheter (Microport ®) was advanced through a dedicated delivery. The HIS signal was identified by the distal dipole and a pacing test demonstrated capture of the conduction system. Advancing the system into the left branch region, a paced "W" morphology was identified in V1 and the catheter was progressively screwed with continuous pacing checks. The final ECG confirmed selective left branch stimulation in the posterior fascicle region (see picture), with selective left branch capture for outputs less than 1 V, non-selective for higher outputs. The s-QRS parameters: 25 ms; V6RWPT: 85ms; RV6/RV1: 35ms suggested left branch stimulation. Final capture threshold was 0.5 V x 0.4 ms, sensing 15 mV and impedance 458 ohm.A CRT-D device was then implanted (GALI SONR CRT-D 2841; Sorin®). After 48 hours from the implantation the patient was stable, electrical parameters and X ray catheters position were unchanged and the patient underwent atrioventricular node ablation and subsequently dismissed. After a 6-month follow-up, the patient had stable parameters and his functional class improved from NYHA class III to class II.

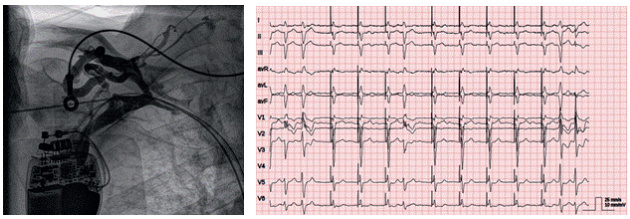

A83: WORSENING OF ATRIO-VENTRICULAR CONDUCTION DUE TO SEVERE ACUTE HYPONATREMIA

Sabrina Testa (a), Sabina Gallina (a), Giulia Renda (a), Fabrizio Ricci (a)
(a) DIPARTIMENTO DI NEUROSCIENZE, IMAGING E SCIENZE CLINICHE

Electrolyte imbalances are recognised for their potential impact on electrical conduction within the cardiovascular system. Hyponatremia, characterised by sodium levels below 135 mmol/L, is the most frequently encountered electrolyte disorder among hospitalised patients. The relationship between hyponatremia and arrhythmias remains inadequately elucidated, with limited available data in the literature. We report the case of a 92-year-old man admitted to the emergency department following an incidental discovery of severe bradycardia. The patient had no prior history of cardiovascular disease. ECG revealed an advanced 4:1 atrioventricular block alternating with intermittent complete atrioven-

tricular block and junctional escape rhythm. Transthoracic echocardiography showed normal biventricular function, with no evidence of regional wall motion abnormalities, and moderate left atrial dilatation. No significant valvular abnormalities were seen. Upon admission, the patient's serum sodium concentration was markedly low at 115 mmol/L, while potassium levels were within normal limits at 4.1 mmol/L. Treatment for hyponatremia involved fluid restriction and the continuous administration of a 3% hypertonic saline solution intravenously. Upon achieving a sodium level of 123 mmol/L, subsequent ECG displayed sinus beats conducted with pre-existent right bundle branch block and left anterior fascicular block. Remarkably, sodium repletion reverted the atrioventricular dissociation. This case emphasises the role of hyponatremia in affecting cardiac electrical activity and highlights how prompt correction of electrolyte disturbances can favourably influence the management of cardiac conduction disorders, especially in the elderly population.

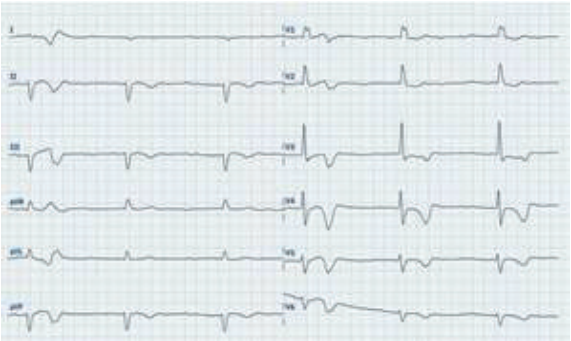

Na+ 115mmol/L

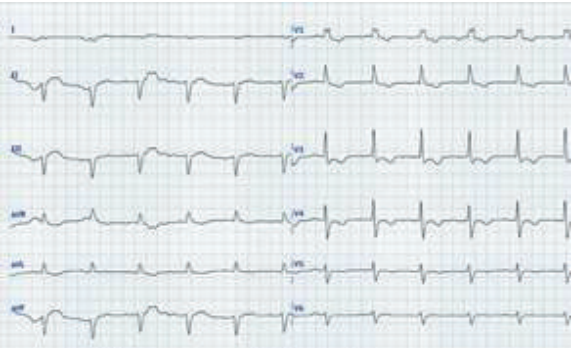

Na+ 123mmol/L

A84: EFFICACIA A MEDIO-LUNGO TERMINE DELLA CARDIONEUROABLAZIONE NELLA MODULAZIONE DELL'ATTIVITÀ PARASIMPATICA CARDIACA NELLA SINCOPE RIFLESSA VASO-VAGALE E NELLA SINDROME BRADICARDIA-TACHICARDIA

Filippo Toriello (a), Massimo Saviano (a), Federica Valli (a), Alberto Vincenzo Pollina (a), Andrea Faggiano (a, b), Filippo Brucato (b), Stefano Carugo (a, b)
(a) UNITÀ OPERATIVA COMPLESSA DI CARDIOLOGIA, FONDAZIONE IRCCS CA' GRANDA OSPEDALE MAGGIORE POLICLINICO - MILANO, ITALIA; (b) DIPARTIMENTO DELLE SCIENZE CLINICHE E DI COMUNITÀ, UNIVERSITÀ DEGLI STUDI DI MILANO - MILANO, ITALIA

Introduzione. La cardioneuroablazione (CNA) è una tecnica inizialmente implementata nel contesto dell'ablazione della fibrillazione atriale (FA). Recentemente, è stata, da alcuni centri, utilizzata nell'ambito del trattamento della sincope riflessa neuro-mediata vasovagale (VVS). Diversi piccoli studi osservazionali, case report e registri multicentrici hanno mostrato un'efficace modulazione dell'iperattività vagale, spesso eliminando la necessità dell'impianto di un sistema di stimolazione definitivo sia in caso di blocco atrioventricolare che di disfunzione del nodo senoatriale funzionali.
Obiettivi. Confermare i precedenti risultati in merito a tale metodica applicata nei pazienti con VVS, attraverso un approccio standardizzato di analisi del segnale e un workflow automatizzato dei software dedicati dei sistemi di mappaggio elettroanatomico (Figura 1). Vogliamo, inoltre, estendere l'applicazione della CNA a soggetti affetti da sindrome bradicardia-tachicardia (BTS), analizzando gli effetti a medio-lungo termine della procedura sull'attività del sistema nervoso parasimpatico a livello cardiaco.
Materiali e metodi. Studio monocentrico retrospettivo in pazienti affetti da VVS o BTS sottoposti a procedura di CNA. I dati clinici, dei parametri elettrocardiografici e intraprocedurali sono stati ottenuti analizzando le cartelle cliniche di ogni singolo paziente. I dati di follow-up sono stati recuperati dalle visite cardiologiche di controllo e dai sistemi di monitoraggio remoto dei monitor intracardiaci impiantabili dei soggetti in studio.
Risultati. La popolazione si è composta di 10 pazienti con età media 52 ± 19 anni. La metà ha sperimentato una o più VVS con documentata disfunzione funzionale del nodo senoatriale, l'altra metà si è composta di individui con BTS sintomatica. La durata media del follow-up è stata di 9 ± 5 mesi. La frequenza cardiaca media (FC) pre-procedurale, la FC acuta post-procedura e i valori medi ai vari intervalli di follow-up sono riportati in Tabella 1. Si è osservato un incremento statisticamente significativo della FC post-procedura e di quella media a tutti i follow-up rispetto ai valori di FC media pre-procedurale (per tutti i parametri citati p<0.05). Non è stata riscontrata nessuna complicanza intra- e periprocedurale e non abbiamo documentato, all'anno di follow-up, alcuna recidiva clinica o strumentale di patologia. Inoltre, nessuna variazione rilevante, in acuto e al follow-up, dell'intervallo PR è stata descritta a seguito dell'intervento.
Conclusioni. I nostri dati confermano l'efficacia a medio-lungo termine della modulazione dall'attività parasimpatica a livello cardiaco mediata dalla CNA nei pazienti con VVS, estendendone la validità anche ai pazienti con BTS e giustificando l'assenza di recidive cliniche e strumentali che abbiamo osservato. La CNA potrebbe, quindi, costituire una reale e valida
alternativa all'impianto di device per la stimolazione definitiva in queste classi di pazienti.

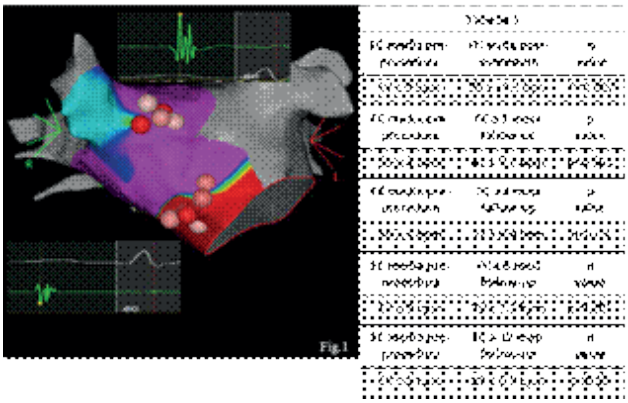

A85: PULSED FIELD ABLATION VERSUS CRYOBALLOON FOR ATRIAL FIBRILLATION ABLATION: A METANALYSIS

Giampaolo Vetta (a, c), Domenico Giovanni Della Rocca (a), Antonio Parlavecchio (c), Rodolfo Caminiti (c), Maria Cespon (a), Michele Magnocavallo (b), Luigi Pannone (a), Alvise Del Monte (a), Lorenzo Marcon (a), Ioannis Doundoulakis (a), Kazutaka Nakasone (a), Ilenia Lombardo (a), Gian Battista Chierchia (a), Carlo De Asmundis (a)
(a) HEART RHYTHM MANAGEMENT CENTRE, POSTGRADUATE PROGRAM IN CARDIAC ELECTROPHYSIOLOGY AND PACING, UNIVERSITAIR ZIEKENHUIS BRUSSEL-VRIJE UNIVERSITEIT BRUSSEL, BRUSSELS, BELGIUM.; (b) CARDIOLOGY DIVISION, ARRHYTHMOLOGY UNIT, S. GIOVANNI CALIBITA HOSPITAL, ISOLA TIBERINA, ROME, ITALY.; (c) CARDIOLOGY UNIT, DEPARTMENT OF CLINCAL AND EXPERIMENTAL MEDICINE, UNIVERSITY OF MESSINA, MESSINA, ITALY.

Background. Pulsed Field Ablation (PFA) is an innovative technology recently adopted for the treatment of Atrial Fibrillation (AF) ablation.
Objective. We performed a meta-analysis to compare the efficacy and safety of PFA with the pentaspline multi-electrode PFA catheter system versus available 2nd generation Cryoballoon technologies (Cryo).
Methods. The primary endpoints were Acute Procedural Success per Vein and per Patient. Safety endpoints were Overall Periprocedural Complications and Major Periprocedural Complications. Secondary endpoints were Procedural Time, Fluoroscopy time and Freedom from Atrial Tachycardias (AT) recurrence at follow up. Random-effects models weighted by inverse variance were used because of clinical heterogeneity.
Results. 15 and 69 studies were included for PFA and Cryo respectively. PFA demonstrated greater Acute Procedural Success per Vein (99.9% vs 99%; p<0.001), Acute Procedural Success per Patients (99.5% vs 98.4%; p<0.001) with lower Overall Periprocedural Complications (3.0% vs 5.7%; p<0.001) and Fluoroscopy Time (14.0 min vs 18.9 min; p=0.02) compared to Cryo. No difference were found between PFA and Cryo for Major Periprocedural Complications (1.2% vs 1.0%; p=0.48), Procedural Time (84.4 min vs 106.2 min; p=0.07) and Freedom from AT recurrence at 1 year (81.8% vs 80.3%; log-rank p=0.98).
Conclusions. PFA proved higher acute efficacy and safety than Cryo with shorter fluoroscopy time and no statistically significant differences in AT recurrence at 1-year follow-up.

A86: PROPENSITY SCORE-MATCHED COMPARISONN AMONG PULSED ELECTRIC FIELD, CRYOBALLOON AND RADIOFREQUENCY FOR PAROXYSMAL ATRIAL FIBRILLATION ABLATION

Domenico Giovanni Della Rocca (a), Lorenzo Marcon (a), Michele Magnocavallo (a), Roberto Menè (c), Luigi Pannone (a), Sanghamitra Mohanty (b), Vasilieios Sousonis (c), Antonio Sorgente (c), Alexandre Almorad (a), Antonio Bisignani (d), Andrej Glowniak (e), Alvise Del Monte (a), Gezim Bala (a), Marco Polselli (d), Sahar Mouram (a), Vincenzo Mirco La Fazia (b), Erwin Stroker (a), Carola Gianni (b), Sarah Zeriouh (c), Stefano Bianchi (d), Juan Sieira (a), Giampaolo Vetta (a), Stephane Combes (c), Andrea Sarkozy (a), Pietro Rossi (d), Serge Boveda (c), Andrea Natale (b), Carlo De Asmundis (a), Gian Battista Chierchia (a)

(a) HEART RHYTHM MANAGEMENT CENTRE, POSTGRADUATE PROGRAM IN CARDIAC ELECTROPHYSIOLOGY AND PACING, UNIVERSITAIR ZIEKENHUIS BRUSSEL-VRIJE UNIVERSITEIT BRUSSEL, BRUSSELS, BELGIUM; (b) TEXAS CARDIAC ARRHYTHMIA INSTITUTE, ST. DAVID'S MEDICAL CENTER, AUSTIN, US.; (c) HEART RHYTHM DEPARTMENT, CLINIQUE PASTEUR, TOULOUSE, FRANCE.; (d) ARRHYTHMOLOGY UNIT, OSPEDALE FATEBENEFRATELLI ISOLA TIBERINA-GEMELLI ISOLA, ROME, ITALY.; (e) DEPARTMENT OF CARDIOLOGY, MEDICAL UNIVERSITY OF LUBLIN, LUBLIN, POLAND.

Background. Pulmonary vein isolation (PVI) is the most effective rhythm control strategy in paroxysmal atrial fibrillation (AF). Pulsed field ablation (PFA) has emerged as a novel, non-thermal energy source to selectively ablate cardiac tissue.

Objective. To report the first multicenter experience on PVI via the pentaspline FarapulseTM PFA system versus thermal-based technologies in a propensity score-matched population of paroxysmal AF patients.

Methods. Propensity score matching was adopted to compare PVI-only ablation outcomes via the FarawaveTM PFA system (Group PFA), cryoballoon ablation (Group CRYO), or focal radiofrequency (Group RF) (PFA:CRYO:RF Ratio=1:2:2).

Results. Among 1572 (mean age: 62.4±11.3 years; 42.5% females) PAF patients undergoing their first time PVI with either PFA (n=174), CRYO (n=655), or RF (n=743), propensity score matching yielded 174 PFA, 348 CRYO, and 348 RF patients. First-pass isolation was achieved in 98.8% of pulmonary veins (PVs) with PFA, 81.5% with CRYO, and 73.1% with RF (p<0.001). Procedural and dwell times were significantly shorter with PFA. Overall complication rates were 3.4% (n=6) with PFA, 8.6% (n=30) with CRYO, and 5.5% (n=19) with RF (p=0.052). The 1-year Kaplan-Meier estimated freedom from any atrial tachyarrhythmia was 79.3% with PFA, 74.7% with CRYO, and 72.4% with RF (log-rank p-value: 0.24). Among 145 repeat ablation procedures, PV reconnection rate was 19.1% after PFA, 27.5% after CRYO, and 34.8% after RF (p=0.01).

Conclusions. PFA contributed to significantly shorter procedural times. Follow-up data showed a similar arrhythmia freedom among groups, although a higher rate of PV reconnection was documented in post-CRYO and post-RF redo procedures.

A87: A RARE CASE OF LEAD EXTRACTION

Angelica Cersosimo (a), Gianmarco Arabia (a), Maria Giulia Bellicini (a), Manuel Cerini (a), Francesca Salghetti (a), Paolo Vinciguerra (a), Emiliano Calvi (a), Luca Bontempi (a), Antonio Curnis (a)

(a) UNIVERSITÀ DEGLI STUDI DI BRESCIA; (b) BOLOGNINI HOSPITAL- BERGAMO

Background. Implantation of a Pacemaker (PM) often requires the implantation of a ventricular lead in the right ventricle or in the coronary sinus. In the case of bioprosthetic tricuspid valves, transvalvular lead placement should be avoided because of the risk of valve damage. Therefore in the event of the need for ventricular pacing the implantation is often done in the coronary sinus. However, lead placement could be challenging in patients with right atrium dilatation (inability to implant, dislodgement), so with the advent of leadless PM, this type of pacing constitutes a valid alternative to intravenous pacing. In our case report, we describe the case of a patient with a tricuspid bioprosthesis that underwent to leadless PM implantation after extraction of an infected PM with a coronary sinus ventricular lead.

Case summary. We report a case of 62-year-old woman affected by rheumatic heart disease with normal biventricular function, a mechanical mitralic, a biological tricuspid prosthetic valves and a PM-DDDR for post-surgical complete atrioventricular block with ventricular lead positioned in the coronary sinus (CS) since 2007. In February 2022 she underwent to replacement of PM generator because of initial battery depletion. Unfortunately in March 2022, she was readmitted to our cardiology department to underwent to extraction of the device for pocket infection. Before the procedure we performed a transesophageal echocardiography (TEE) that confirmed absence of vegetations on valves and leads, and an angiography to check of the venous decourse of the leads that showed poor patency of the left anterior-clavicular-subclavicular venous axis. We proceded to lead extraction. After placing Spectranetics (Philips) Lead Locking Device n.2 (LLD2), we removed the 2007 passive fixation right atrial lead using a mechanical extractors (Cook 7-8.5 Fr). Then after placing Spectranetics (Philips) Lead Locking Device E (LLDE), we removed the CS lead completely using mechanical extractors (Cook 7-8.5 Fr). The procedure was well tolerated and uneventful. After the resolution of the infection a leadless MICRA ™ AV PM was implanted through the use of the 23-F Micra TPS delivery catheter across the tricuspid bioprosthetic valve without any damage to the prothesis.

Discussion. Transvalvular PM implantation in patients with bioprosthetic tricuspidal is controindicated and often these patients are implanted with ventricular lead in coronary sinus. Leadleess PM constitutes a valid alternative to intrevenous pacing.

Conclusions. Leadless PM implantation represents a new technology by eliminate the risks connected with the presence of the lead across the bioprosthetic valve.

A88: THREE-DIMENSIONAL ELECTROANATOMIC MAPPING IN PATIENTS WITH BRUGADA SYNDROME: RESULTS FROM THE CHARISMA BRUGADA STUDY

Federico Ballacci (a), Luca De Francesco (a), Alessia Scipione (a), Gemma Pelargonio (b), Gianluigi Bencardino (b), Francesco Perna (b), Gaetano Pinnacchio (b), Vincenzo Russo (c), Antonio Castro (d), Maria Luisa Loricchio (d), Filippo Crea (a), Maria Lucia Narducci (b)

(a) DIPARTIMENTO DI SCIENZE CARDIOVASCOLARI, UNIVERSITÀ CATTOLICA DEL SACRO CUORE, ROME, ITALY; (b) DIPARTIMENTO DI SCIENZE CARDIOVASCOLARI, FONDAZIONE POLICLINICO UNIVERSITARIO AGOSTINO GEMELLI IRCCS, ROME, ITALY; (c) CARDIOLOGY UNIT, UNIVERSITY OF CAMPANIA "LUIGI VANVITELLI", MONALDI HOSPITAL, NAPLES, ITALY; (d) DIVISION OF CARDIOLOGY, SANDRO PERTINI HOSPITAL, ROME, ITALY

Background andAims. Brugada syndrome (BrS) is an inherited heart disorder characterized by pathognomonic electrocardiographic changes (either at baseline or after provocative tests) and is associated with an increased risk of malignant ventricular arrhythmias (VAs) and sudden cardiac death (SCD). BrS was first described in 1992, and right ventricular outflow tract (RVOT) structural changes have recently been recognized as key features of BrS. This multicentre prospective study aimed to assess the dynamic nature of the electroanatomic scar in BrS patients.

Methods. Patients with definite or suspected BrS were consecutively enrolled in the study and matched with controls undergoing electrophysiology study for AVNRT. In all patients, personal and family history of VAs and SCD were assessed; 12-lead electrocardiogram (ECG) and echocardiogram were performed. Programmed ventricular stimulation (PVS), baseline 3-dimensional electroanatomic unipolar and bipolar mapping (3D-EAM) were performed in all patients. PVS and 3D-EAM were repeated after Flecainide infusion in patients with induced Brugada type 1 ECG pattern.

Results. 40 patients (33 with BrS, 7 controls) were enrolled in the study. BrS ECG pattern was spontaneous in 5 patients (Group 1) and Flecainide-induced (non-diagnostic or intermittent at baseline) in 28 patients (Group 2). Electroanatomic scar area was significantly higher in BrS patients: RVOT scar was absent in all control patients, bipolar scar area was 9.22 cm^2 (interquartile range [IQR]: 7.85-12.70 cm^2) in Group 1 and 5.71 cm^2 (IQR: 3.15-10.15 cm^2) in Group 2 (p=0.001); unipolar scar area was 14.60 cm^2 (IQR: 9.00-18.44 cm^2) in Group 1 and 7.10 cm^2 (IQR: 1.70-11.40 cm^2) in Group 2 (p=0.001). RVOT mean bipolar voltage was significantly lower in BrS patients, whereas unipolar voltage did not show significant differences: RVOT mean bipolar voltage was 3.73 mV (IQR: 3.63-3.79 mV) in the control group, 1.90 mV (IQR: 1.30-2.35 mV) in Group 1 and 1.88 mV (IQR: 0.75-2.55 mV) in Group 2 (p=0.003). RVOT mean unipolar voltage was 4.78 mV (IQR: 4.68-6.71 mV) in the control group, 3.04 mV (IQR: 1.30-4.60 mV) in Group 1 and 4.76 mV (IQR: 3.55-5.35 mV) in Group 2 (p=0.106). 3D-EAM after Flecainide infusion showed a significant reduction in RVOT mean unipolar voltages (mean difference 2.04 mV, 95% confidence interval [CI] 0.71-3.05 mV, p=0.003), whereas differences in bipolar voltages didn't reach the chosen statistical significance threshold (mean difference 0.54 mV, 95% CI -0.06-1.15 mV, p=0.06). No significant differences were observed regarding bipolar and unipolar scar areas.

Conclusions. This study confirms previous observations of electroanatomic scar in the RVOT of BrS patients, and highlights the dynamic changes of the substrate's properties in response to the administration of class Ic antiarrhythmic drugs. Further investigation is warranted to explore potential implications for risk stratification and therapeutic approaches for BrS patients.

A89: COULD DUAL AV NODAL PHYSIOLOGY PREVENT PACEMAKER IMPLANTATION AFTER TAVI?

Marco Busco (a), Francesco Raffaele Spera (b), Andrea Vicere (a), Gemma Pelargonio (a, c)

(a) POLICLINICO UNIVERSITARIO AGOSTINO GEMELLI, ROMA; (b) OSPEDALE SANT'ANDREA, ROMA; (c) UNIVERSITÀ CATTOLICA DEL SACRO CUORE, ROMA

Background. The dual atrioventricular nodal path is a rhythm disorder characterized by the presence of two pathways with different electrophysiological features inside the atrioventricular node. It can be present during sinus rhythm and rarely defines a risk of arrhythmias development.

Case presentation. An 80-year-old man with a recent diagnosis of severe aortic stenosis was referred to our hospital to undergo Transcatheter Aortic Valve Implantation (TAVI). ECG showed sinus rhythm with a normal atrioventricular conduction (PR interval 180 ms) and left bundle branch block (LBBB) with a QRS width of 167 ms. The pa-

tient underwent TAVI without any immediate procedural complications. On the first day after procedure, the rhythm monitoring documented an abnormality in the atrioventricular conduction. Hence a new ECG was performed, and a dual AV nodal physiology was clearly manifest: as we can observe in the figures below, there is a clear succession of a shorter PR with a length of 190 ms and a longer interval of 320 ms. The patient was still asymptomatic, so it was chosen to monitor the patient the following days, avoiding immediate pacemaker implantation. Two days later, the ECG documented the resolution of the atrioventricular alternance of the nodal pathways with persistence of first-degree atrioventricular block (PR 229 ms) and left bundle branch block (QRS 166 ms).

Discussion. Despite high prevalence of LBBB and AV block after TAVI, there is no evidence in literature of the generation of a manifest dual atrioventricular physiology after TAVI. Hence the unicity of this case. The fast path is located in the anterior portion of triangle of Koch, formed anteriorly by the insertion of the septal leaflet of the tricuspid valve and posteriorly by the fibrous tendon of Todaro. The slow path is located in the inferior nodal extension of the compact AV node, in the direction of the coronary sinus along the tricuspid annulus. This different location explains how the fast pathway is more prone to be injured during balloon inflation and valve implantation. We speculate that the alternate conduction through the slow pathway could be allowed by the mechanic or ischemic device interference on the fast-pathway conduction. In this case slow pathway conduction represents an intrinsic backup conduction that help to delay and avoid PM implantation. We hypothesize that retrograde conduction through fast pathway was also injured making nodal reentry circuit difficult to be generated.

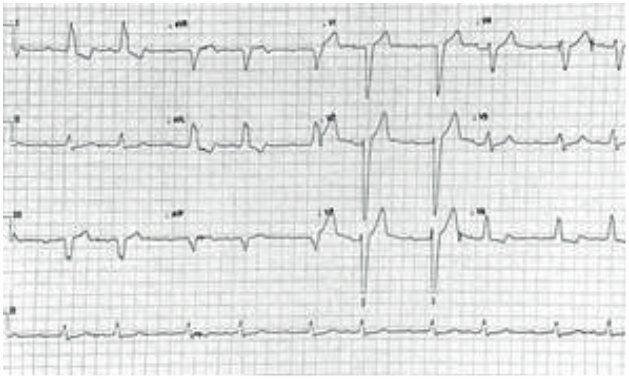

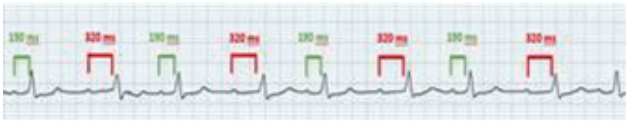

A90: ESTRAZIONE PERCUTANEA DI UN SISTEMA DI STIMOLAZIONE TRANSCATETERE AV MICRA A CAUSA DI UN GUASTO IMPROVVISO NELLA BATTERIA: UN CASO CLINICO

Vincenzo Ezio Santobuono (a), Stefano Favale (a), Marco Matteo Ciccone (a), Cinzia Forleo (a), Paolo Basile (a), Maria Cristina Carella (a), Eugenio Carulli (b), Francesca Pomarico (a), Michele Luca Dadamo (a), Riccardo Memeo (a), Andrea Igoren Guaricci (a)
(a) U.O.C. CARDIOLOGIA UNIVERSITARIA - POLICLINICO DI BARI; (b) U.O.C. CARDIOLOGIA E UTIC - P.O. MADONNA DELLE GRAZIE - MATERA

Introduzione. Il sistema di stimolazione transcatetere Micra AV(TPS) rappresenta un innovativo pacemaker (PM) di seconda generazione senza elettrocateteri, che costituisce un'efficace alternativa ai dispositivi convenzionali in casi selezionati. I dati osservazionali hanno dimostrato la sicurezza e l'efficacia di Micra TPS, con un eccellente tasso di successo dell'impianto. Per contro, i dati relativi agli esiti a lungo termine, ai malfunzionamenti intrinseci di questi dispositivi e al loro recupero sono limitati.

Presentazione del caso: Un uomo di 85 anni, affetto da malattia renale cronica, è stato ricoverato nel nostro reparto nell'agosto 2020 dopo la diagnosi di blocco atrioventricolare completo parossistico (AVB). È stato impiantato un TPS Micra AV. Non si sono verificate complicanze e i parametri del dispositivo sono rimasti stabili per tutta la durata del ricovero. Durante il follow-up, l'interrogazione del PM ha mostrato parametri di stimolazione e rilevamento ottimali, con una longevità stimata della batteria di circa 8 anni. Nel marzo 2022, nel corso del follow-up, non è stato possibile interrogare il device. Il monitoraggio ECG delle 24 ore ha mostrato ulteriori episodi intermittenti di AVB completo senza attività di stimolazione. Un successivo esame fluoroscopico bi-plano ha dimostrato che il dispositivo era in sede e nella posizione appropriata. Pertanto, attraverso un accesso dalla vena femorale, è stato eseguito l'impianto nel ventricolo destro di un nuovo sistema Micra AV. Durante la fluoroscopia, l'esame ispettivo della morfologia e della struttura dei due dispositivi, posti l'uno di fianco all'altro, ha rivelato un'alterazione significativa dell'alloggiamento della batteria del vecchio Micra AV. Pertanto, il vecchio dispositivo è stato estratto e sono state svolte delle indagini sulla causa del suo malfunzionamento. Il recupero del TPS Micra AV è stato eseguito con uno strumento percutaneo. L'ispezione al termine della procedura non ha rivelato anomalie strutturali, aderenze o capsule intorno al TPS Micra recuperato. Non si sono verificate complicanze. Un'indagine tecnica approfondita sul dispositivo recuperato, eseguita dal produttore, ha rivelato una falla nella sacca del separatore catodico, che ha causato un cortocircuito interno e, di conseguenza, un improvviso esaurimento della batteria. La sicurezza e l'efficacia delle LP sono state evidenziate da diversi studi, anche in pazienti anziani. Il Micra TPS è l'unico approvato dalla Food and Drug Administration degli Stati Uniti e ha ottenuto il marchio CE, a causa di un richiamo di sicurezza del dispositivo Nanostim nel 2016, legato a preoccupazioni sulla rottura improvvisa della batteria. Problemi simili nella batteria non sono stati descritti per il Micra TPS. Sono stati descritti diversi casi di malfunzionamento della batteria, ma relativi a soglie di stimolazione elevate.

Discussione e Conclusioni. L'emivita stimata del Micra AV TPS varia da 5 a 15 anni, a seconda della frequenza di stimolazione. La gestione del fine vita di questi dispositivi è ancora dibattuta. Generalmente il dispositivo viene spento e lasciato in situ. Abbiamo deciso di procedere al recupero del dispositivo per questioni di sicurezza e per consentire un'analisi approfondita del dispositivo da parte del produttore. Al meglio delle nostre conoscenze, descriviamo il primo caso di improvviso malfunzionamento della batteria dopo 19 mesi dall'impianto di un TPS Micra AV, che ha richiesto l'estrazione e il posizionamento di un nuovo sistema di stimolazione.

A91: ST-ELEVATION: SEMPRE STEMI?

Ciro Cotticelli (a), Christian Basile (a), Simone Agizza (a), Sara Fontanarosa (a), Stefania Paolillo (a), Paola Gargiulo (a), Federica Ilardi (a), Federica Marzano (a), Antonio Rapacciuolo (a), Pasquale Perrone Filardi (a)
(a) UNIVERSITÀ DEGLI STUDI DI NAPOLI "FEDERICO II"

Introduzione. Sebbene prevalentemente correlate allo STEMI, le alterazioni elettrocardiografiche di tipo "ST-UP" possono rappresentare anche un campanello d'allarme per altre patologie. Presentiamo il caso di una paziente con ST-up all'ECG di superficie che in realtà celava un'emorragia subaracnoidea.

Descrizione del caso clinico. Giunge presso l'Emodinamica della nostra Cardiologia, tramite rete dell'infarto, la paziente BS, donna di 70 anni ipertesa e dislipidemica, per diagnosi di STEMI ed ST-up nelle derivazioni DI ed aVL con speculare sottoslivellamento in sede inferiore. In anamnesi, un primo episodio di fibrillazione atriale parossistica 8 anni prima e un secondo -10 giorni prima - trattato in PS con rate-control e introduzione di anticoagulante orale (edoxaban – CHA_2DS_2-VASc di 3). All'ingresso la paziente presenta nausea, vomito, cefalea e vertigini con ECG sovrapponibile al precedente del 118, all'ecocardiogramma atriomegalia sinistra, insufficienza mitro-tricuspidale e aortica di grado lieve, lieve riduzione della cinesi globale (FE 50%) ed ipocinesia medio-apicale anteriore ed antero-laterale. L'angiografia coronarica mostrava arterie coronariche epicardiche ateromasiche, ma esenti da stenosi emodinamicamente significative. Persistendo la sintomatologia dell'ingresso, veniva effettuata RMN encefalica che evidenziava la presenza di stria iperintensa in FLAIR ed ipointensa in SWAN, interessante i solchi frontale superiore e centrale della convessità fronto-parietale sinistra, quadro compatibile con emorragia subaracnoidea. L'evento veniva gestito con terapia conservativa, sulla base della Angio-TC encefalo, sino a risoluzione dell'infarcimento emorragico. La paziente, previa sospensione della terapia con edoxaban, veniva sottoposta a chiusura percutanea dell'auricola atriale sinistra mediante dispositivo Amplatzer Amulet.

Discussione. Il caso si presta a considerazioni di diagnostica differenziale, l'associazione tra manifestazioni cardiovascolari e patologie cerebrali è nota sin dagli inizi del 1900 quando Cushing descriveva l'aumento della pressione intracranica – in pazienti con lesioni cerebrali - come potenziale causa di ipertensione arteriosa e bradicardia. Bodechtel nel 1938 osservò che le lesioni intracraniche da emorragia cerebrale o subaracnoidea causavano alterazioni elettrocardiografiche, classificate più tardi da Byer, nel 1947, e da Burch, nel 1954. Le alterazioni elettrocardiografiche in corso di emorragia cerebrale o subaracnoidea consistono prevalentemente in inversioni dell'onda T, alterazioni del tratto ST o aritmie. Tra le possibili ipotesi eziopatogenetiche sono da annoverarsi l'attivazione della componente simpatica miocardica nell'ambito dell'ipertono simpatico generalizzato conseguente all'emorragia cerebrale, l'aumento del rilascio di catecolamine - direttamente aritmogene - e la presenza eventuale di lesioni di aree cerebrali a potenziale azione aritmogena (lobi temporo-parietali, frontali, giro angolare, insula, ipotalamo, sostanza grigia).

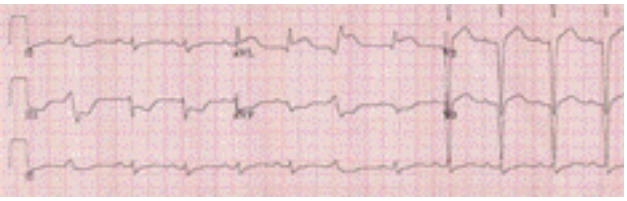

A92: NOVEL INTERSECTION OF BRUGADA AND SOTOS SYNDROMES: A CASE REPORT ON POTENTIAL SHARED MECHANISMS AND RISK OF ARRHYTHMIC SUDDEN CARDIAC DEATH

Simone Pasquale Crispino (a), Andrea Segreti (a, b), Francesco Piccirillo (a), Vito Calabrese (a), Francesca Cocchia (a), Arianna Martucciello (a), Mariagrazia Piscione (a), Vincenzo Nafisio (a), Fiorella Gurrieri (a), Gian Paolo Ussia (a), Francesco Grigioni (a)
(a) FONDAZIONE POLICLINICO UNIVERSITARIO CAMPUS BIO-MEDICO;
(b) DIPARTIMENTO DI SCIENZE MOTORIE, UMANE E DELLA SALUTE, UNIVERSITÀ DEGLI STUDI DI ROMA "FORO ITALICO"

A 21-year-old male presented to the Emergency Department via ambulance following a brief syncopal episode accompanied by head trauma. Past medical history included childhood myoclonus and tics, previously managed with valproic acid. Vital signs were stable: BP 110/70 mmHg, HR 107 bpm, and SpO2 97%. A physical exam revealed scoliosis and distinctive physical features like an elongated face and arachnodactyly without any cardiac abnormality. A neurological exam showed repetitive ocular tics. Initial ECG indicated sinus tachycardia and incomplete right bundle branch block with ST-T elevation in right precordial leads. Blood tests showed mild neutrophilic leucocytosis; high-sensitivity troponin was normal. CT scan and echocardiogram were unremarkable. Intravenous ajmaline infusion elicited a type-1 Brugada ECG pattern. Given the suspected arrhythmic nature of the syncope and ECG findings, a subcutaneous cardiac defibrillator was implanted following 2015 ESC guidelines for the prevention of sudden cardiac death and ventricular arrhythmias. Furthermore, given the young age of the patient, a genetic testing was performed on every individual in his family. Genetic testing revealed an alteration in the NSD1 gene, which is implicated in Sotos syndrome. The patient's brother was also diagnosed with a pharmacologically induced type-1 Brugada ECG pattern but showed no signs of Sotos syndrome. Brugada syndrome is an inherited arrhythmogenic disorder, which is characterized by a definite electrocardiographic (ECG) pattern and is associated with an elevated risk of sudden cardiac death (SCD). Sotos syndrome, on the other hand, is an overgrowth condition characterized by rapid physical development and is often accompanied by learning disabilities. Both syndromes have been independently associated with various cardiac anomalies. However, the simultaneous occurrence of these two syndromes in a single patient has never been reported before. This association raises critical questions about the potential shared pathophysiological mechanisms between these two conditions. The NSD1 gene, responsible for Sotos syndrome, encodes a histone methyltransferase involved in chromatin regulation mechanisms. Given that epigenetic modifications are crucial in cardiac homeostasis and arrhythmias, the NSD1 alteration could potentially influence the Brugada syndrome phenotype. Moreover, the patient also had a heterozygous mutation in the calsequestrin 2 (CASQ2) gene, adding another layer of complexity to the case. CASQ2 is known to be involved in calcium regulation within the sarcoplasmic reticulum and has been linked to arrhythmias. In fact, recessive mutations in the CASQ2 gene are implicated in catecholaminergic polymorphic ventricular tachycardia syndrome, characterized by abnormal Ca2+ release and arrhythmias without structural heart disease. However, the clinical significance of a heterozygous CASQ2 mutation, as observed in the present case, remains undetermined. In conclusion, this is the first report to document an association between Brugada syndrome and Sotos syndrome, thereby opening new avenues for research in genetic and epigenetic mechanisms underlying these conditions. Further studies are warranted to elucidate whether this association is coincidental or indicative of a shared genetic aetiology. This discovery also prompts the need for cardiologists to consider Brugada syndrome as a possible associated cardiac anomaly in patients affected by overgrowth syndromes.

A93: NELL'ERA DELL'ABLAZIONE TRANSCATETERE DELLA FIBRILLAZIONE ATRIALE CON TECNICHE HIGH POWER SHORT DURATION CHI GARANTISCE LA MIGLIOR EFFICACIA A BREVE TERMINE? CONFRONTO TRA TECNICHE VERY-HIGH POWER SHORT DURATION E HIGH POWER SHORT DURATION

Leonardo D'Angelo (a), Campanelli Francesca (a), Yari Valeri (a), Lara Luciani (a), Giovanni Volpato (a), Paolo Compagnucci (a), Laura Cipolletta (a), Quintino Parisi (a), Silvano Molini (a), Agostino Misiani (a), Federico Guerra (b), Michela Casella (b), Antonio Dello Russo (b)
(a) AZIENDA OSPEDALIERO UNIVERSITARIA DELLE MARCHE; (b) UNIVERSITÀ POLITECNICA DELLE MARCHE

Introduzione. L'ingresso di rivoluzionarie tecnologie nel panorama dell'ablazione trans-catetere (ATC) della fibrillazione atriale (FA) offre ai pazienti ed ai clinici nuove soluzioni. Il recente affinamento della terapia ablativa standard con radiofrequenze (RF) permette l'impiego di elevate potenze per pochi secondi, garantendo una miglior efficacia e riducendo il rischio di complicanze termiche. Tali metodiche sono realizzabili grazie ai moderni cateteri d'ablazione QDOT Micro™ (Biosense Webster) con protocollo very high power short duration (v-HPSD) e Tactiflex™ (Abbott) con tecnica high power short duration (HPSD).
Obiettivi. L'obiettivo del nostro studio è confrontare il tasso di recidiva della FA nei pazienti sottoposti ad ATC di FA con tecnica v-HPSD e HPSD.
Materiali e metodi. È stata condotta un'analisi retrospettiva su 85 pazienti afferiti al nostro centro per eseguire l'ATC di FA parossistica e persistente. Il non raggiungimento di un follow up minimo di 6 mesi costituiva il principale criterio di esclusione dallo studio. I pazienti sono stati suddivisi in due gruppi sulla base della tecnica ablativa: 45 pazienti sono stati trattati con protocollo v-HPSD ed i restanti 40 con tecnica HPSD [età media 64, 58-71 genere maschile n=37 (82%) v-HPSD; età media 59, 52-66; genere maschile n=31 (68%) HPSD; p>0.05]. Indipendentemente dalla tecnica, l'obiettivo primario dell'ATC era l'isolamento delle vene polmonari (IVP). Sulla base della mappa di substrato-voltaggio, l'ablazione di foci extra-polmonare è stata eseguita a discrezione dell'operatore. Il protocollo v-HPSD prevedeva l'impiego della modalità QMODE (50W) nelle sezioni anteriori delle vene polmonari e della camera atriale sinistra con ablation index target pari a 500, e della modalità QMODE + (90 W per 4 sec) nelle sezioni posteriori: vene polmonari e parete posteriore. La tecnica HPSD veniva eseguita erogando pulsi di radiofrequenza con potenza pari a 50W per 10 sec nelle sezioni posteriori della camera atriale sinistra e 40W per 20 sec nelle sezioni anteriori dell'atrio sinistro, con contact force sensing oscillante tra 5 e 20 g per ogni lesione. Il follow up è stato condotto attraverso visita ambulatoriale, monitoraggio remoto di dispositivi impiantabili, refertazione di ECG ed Holter delle 24 h e per mezzo di intervista telefonica.
Risultati. Non sono emerse differenze statisticamente significative tra le due popolazioni per frazione di eiezione (55%, 50-60 v-HPSD; 60%, 55-65 HPSD; p=0.491) volume atriale indicizzato sinistro (40 ml/m^2 35-50 v-HPSD, 35 ml/m^2 27-43 HPSD; p=0.327), tipologia di FA (FA persistente n=30, 66% v-HPSD; n=12, 30% HPSD; p=0.683) e pregresse procedure di ATC di FA (n=8, 17% v-HPSD; n=11, 27% HPSD; p=0.283). In tutti i pazienti è stato conseguito l'IVP. Il tasso di recidiva della FA non ha registrato differenze statisticamente significative tra i due gruppi investigati (n=9, 20% v-HPSD; n=7, 17% HPSD p=0.631).
Conclusioni. L'impiego di elevate potenze per pochi secondi si è dimostrato superiore alle tecniche low power long duration di ablazione con RF in termini di fattibilità, efficacia e sicurezza. Limitatamente alla natura retrospettiva del nostro studio, il confronto tra le tecniche v-HPSD e HPSD non ha evidenziato una maggior efficacia di una metodica nel prevenire la recidiva della FA. Un più lungo follow up ed una maggior standardizzazione dello stesso e della terapia farmacologica potrebbero ridurre i bias contribuenti alla recidiva di FA, permettendo un confronto più trasparente tra le due metodiche e la loro efficacia.

A94: SUDDEN CARDIAC DEATH IN A PATIENT AFFECTED BY SISTEMIC SCLEROSIS AND ATRIAL SEPTAL DEFECT

Monica De Gaspari (a), Martina Perazzolo Marra (a), Vito Cianci (b), Barbara Bauce (a), Cristina Basso (a)
(a) DEPARTMENT OF CARDIAC, THORACIC, VASCULAR SCIENCES AND PUBLIC HEALTH, UNIVERSITY HOSPITAL - PADOVA, ITALY; (b) EMERGENCY DEPARTMENT, UNIVERSITY HOSPITAL - PADOVA, ITALY

Background. Systemic sclerosis (SSc, also called scleroderma) is a systemic disease with heterogeneous clinical manifestation. Myocardial, valvular, vascular and pericardial alterations have been described in pathological studies of SSc patients. Myocardial fibrosis is the hallmark of cardiac involvement in SSc, typically independent of coronary artery distribution, and potentially detectable by cardiac magnetic resonance (CMR).
Case presentation. A 46-year-old man was found in cardiac arrest after a low-impact car accident. No sign of trauma was detected on the scene. The first registered rhythm was pulseless electrical activity (PEA), resuscitation was attempted without success. In the emergency department, a nasal swab turned out positive for COVID.
His medical history was remarkable for SSc for which he was in treatment with methotrexate and periodically with rituximab and vasodilators. He was also known to be affected by atrial septal defect (ASD) ostium secundum type, with left-to-right shunt not hemodynamically significant and without indication to surgical or percutaneous closure. Right heart catheterization documented normal pressures in the pulmonary circulation. CMR performed during cardiological follow-up documented a right ventricular (RV) dilatation with mild dysfunction, minimal late gadolinium enhancement at the level of the posterior septum and papillary muscles of the left ventricle.
At autopsy, the following findings were identified after careful cardiac examination:

- ASD ostium secundum type with Chiari network
- Non-significant coronary artery disease
- Mitral valve disease with leaflet and chordal thickening

- Minimal replacement-type fibrosis at the level of papillary muscles of the left ventricle
- Multifocal replacement-type fibrosis in the RV

Although not detected at CMR, RV replacement-type fibrosis possibly caused by RV volume overload was reported as the final cause for sudden cardiac death.

Conclusions. Despite many reports on the wide variety of cardiovascular manifestations in SSc, there still is a growing need to understand the complex interplay of inflammatory, vasculopathic, and fibrotic processes that affect the myocardium. The case herein reported highlights the relevance of the autopsy investigation with clinicopathological correlation, particularly in cases where the diagnostic traditional tools seem to bear limitations in identifying and assess the extent of cardiac involvement.

A95: MALFUNCTIONING SUBCUTANEOUS IMPLANTABLE CARDIOVERTER-DEFIBRILLATOR IN SECONDARY PREVENTION WHEN LEFT-SIDED DEVICE IS NOT FEASIBLE: WHAT IS THE NEXT STEP? A CASE REPORT

Martina De Raffele (a), Francesco Vitali (a), Michele Trichilo (a), Michele Malagù (a), Cristina Balla (a), Matteo Bertini (a)
(a) AZIENDA OSPEDALIERO-UNIVERSITARIA DI FERRARA

Case report. A 70 years-old man with ischemic cardiomyopathy with mildly reduced ejection fraction (two episodes of non-ST-elevation myocardial infarction treated with percutaneous angioplasty and stenting of the right coronary artery), presented to our Emergency Department (ED) for syncope. The ECG showed a sustained ventricular tachycardia (VT) at 200 bpm, with positive concordance in the precordial leads and extreme right axial deviation, treated with an effective electrical cardioversion. Coronary angiography was performed, and good results of the previous revascularizations emerged. The cardiac magnetic resonance (CMR) showed a mildly reduced biventricular ejection fraction and the presence of transmural late gadolinium enhancement (LGE) of the inferior left ventricular wall with involvement of the right ventricular free wall (Fig.1). Several attempts to implant a transvenous ICD for secondary prevention were made, but a phlebography of the left upper limb showed the complete occlusion of the axillary vein in presence of small collateral vessels, unsuitable for positioning of the lead. A subcutaneous ICD (s-ICD) was then implanted, and the secondary vector was chosen. After two months remote monitoring transmissions showed episodes of lead noise. Muscular maneuvers at an ambulance check showed myopotential evocation, correctly recognized by the device. The signals of the primary and alternating vector showed non-optimal signal, so the device programming was not modified. Subsequently, he presented to our ED for recurrency of sustained VT at 150 bpm, with the same morphology of the VT previously documented. The VT was under the detection window from the s-ICD (200 bpm), so a manual shock was delivered. An endocardial catheter ablation of the arrhythmic substrate was performed using high density electroanatomic mapping (EAM): easy inducibility of monomorphic VT alike to the documented VT was detected, originating from the inferior and posterolateral-basal region (where LGE was detected). The cycle of the arrhythmia was mapped, and sinus rhythm was restored during radiofrequency ablation (Fig. 2). The frequency of the s-ICD tachycardia therapy zone limit was lowered at 170 bpm. In the following days, inappropriate shock on lead noise occurred. In consideration of the impossibility to find a better configuration of the device and due to need of anti-tachycardia pacing, the s-ICD was extracted and a right-sided transvenous single chamber ICD with a dual coil lead was positioned, after performing venography of right axillary vein to verify its patency. Induction test with a shock on the T wave was executed, provoking ventricular fibrillation, correctly recognized, and interrupted by the device.

Conclusions. The case, in its complexity, highlights the limits and strengths of different ICD technologies available nowadays, underlines the importance of remote monitoring and emphasizes the role of EAM guided catheter ablation of VT for effective and safe procedures.

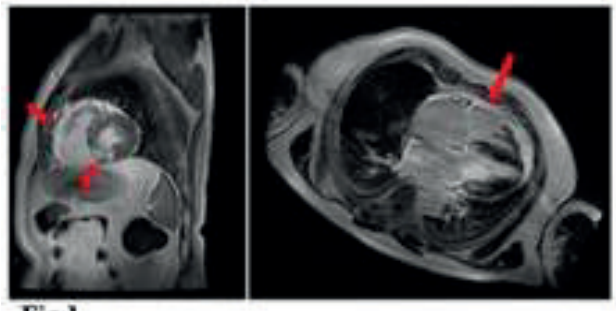

Fig.1

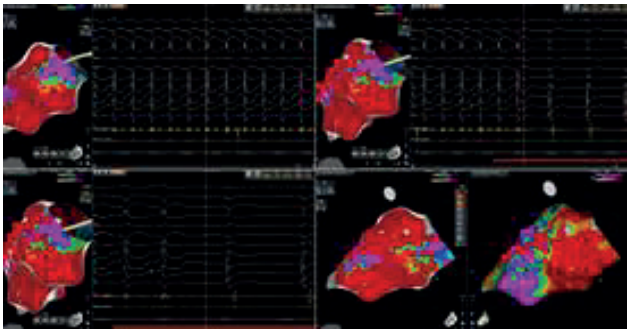

A96: AN UNUSUAL CASE OF TYPICAL COMMON ATRIAL FLUTTER... BUT ATYPICAL

Antonio Taormina (a, b), Guido Del Monaco (a, b, c), Diego Penela Maceda (a, b), Giulio Falasconi (a, b), Carlo Ceriotti (a, b), Paola Galimberti (a, b), Antonio Frontera (a, b)
(a) CARDIO CENTER, HUMANITAS RESEARCH HOSPITAL, 20089, ROZZANO (MI); (b) DEPARTMENT OF ARRHYTHMOLOGY, HUMANITAS RESEARCH HOSPITAL, 20089, ROZZANO (MI); (c) DEPARTMENT OF BIOMEDICAL SCIENCES, HUMANITAS UNIVERSITY, 20090, PIEVE EMANUELE (MI)

A 53-year-old male with a history of hypertension presented to our Emergency Department due to palpitations and was found to have a typical common atrial flutter on the electrocardiogram (ECG). Upon admission, a transthoracic/transesophageal color Doppler echocardiogram was performed, revealing moderate ventricular dysfunction (left ventricular ejection fraction 45%) and the absence of thrombosis in the left atrium. Electrophysiological study confirmed proximal-to-distal activation along the coronary sinus, and entrainment maneuvers from multiple sites confirmed the diagnosis of typical common atrial flutter. Despite numerous ablation attempts using the EPT Blazer catheter (Boston, 65W; 65°C), the macro-reentrant circuit of the flutter could not be interrupted. Consequently, cardioversion was performed to restore normal sinus rhythm (NSR). Stimulation maneuvers confirmed bidirectional block (maximum delay 152 msec straddling the cavo-tricuspid line). The patient was discharged home the following day. Two months later, the patient returned to the Emergency Department with a recurrence of palpitations, and an ECG showed a recurrence of typical common atrial flutter. It was decided to schedule a repeat procedure with the support of a mapping system (RHYTHMIA Mapping System, Boston Scientific, Natick, MA). Entrainment maneuvers were repeated, confirming a macro-reentry circuit in the right atrium, around the tricuspid valve with an isthmus anatomically located at the cavo-tricuspid isthmus. Using a mapping catheter (ORION TM), double potentials were confirmed in the previously ablated region (on the cavo-tricuspid isthmus). Propagation mapping revealed signal jumping laterally to the ablation line of the cavo-tricuspid isthmus, with a reappearance of activation in the interatrial septal region. Entrainment was performed from multiple sites on the tricuspid valve, all showing a post-pacing interval <30 msec, thus confirming a macro-reentry around the tricuspid valve. At a site in the postero-septal region (Figure 1), a unipolar 'QS' signal was observed (as per intramural activation). Our hypothesis was that there is an intramyocardial connection at the level of the cavo-tricuspid isthmus with the emergence of the bundle in the postero-septal region. Therefore, a single radiofrequency (RF) pulse (35W) supported by a long AGILIS introducer was applied to this region, resulting in the restoration of normal sinus rhythm (NSR). There was no recurrence during one-year follow-up.

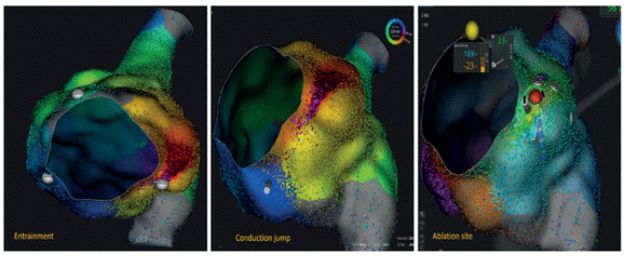

A97: WENCKEBACH CONDUCTION DURING JUNCTIONAL TACHICARDYA

Mario Di Marino (a), Sabrina Testa (a), Davide Pirro (b), Giovanni Pizzoferrato (a), Fabrizio Ricci (a), Giulia Renda (a), Sabina Gallina (a)
(a) NEUROSCIENZE DEPARTMENT, IMAGING AND CLINICAL SCIENCE, "G. D'ANNUNZIO" UNIVERSITY, CHIETI-PESCARA; (b) SAN PIO DA PIETRELCINA HOSPITAL, VASTO, ASL 2 ABRUZZO

An 88-year-old Caucasian woman with a medical history of arterial hypertension and paroxysmal atrial fibrillation—managed with anticoagulant

and propafenone therapy—presented to the Emergency Department experiencing increasing fatigue and intermittent chest pain. The patient disclosed that she had been taking 900 mg of propafenone daily, in the form of three 300 mg tablets, over the past week to address recurring and extended episodes of palpitations. Lab results indicated severe acute kidney injury, with creatinine levels measuring 3.9 mg/dL. ECG showed unidentifiable atrial activity and a pattern of grouped beating with triplets of wide QRS complexes, with the fourth beat completely blocked (Fig.1 and 2). The clinical presentation raised suspicion of an overdose and accumulation of class IC antiarrhythmic drugs due to renal insufficiency. Overdosing on IC drugs may be associated with the phenomenon of atrial standstill, the lack of active electrical and mechanical activity in the atria, typically of a reversible nature. Such intoxication may also lead to the development of junctional or ventricular tachycardias, and potentially ventricular fibrillation. A closer analysis of the ECG revealed junctional ectopic cycle length of 740 ms along with Wenckebach-type 4:3 exit block out of the atrio-ventricular junction. This behavior confirmed the hypothesis of an atrial standstill with junctional tachycardia conducted with aberrant conduction and grouped beating as a hallmark of Wenckebach conduction. The patient was quickly administered intravenous fluids and bicarbonate to mitigate the impact of propafenone. Within several hours, the ECG showed conducted sinus beats, accompanied by a first-degree atrioventricular block and narrow QRS complexes at a rate of 65 bpm. In this clinical context, it is crucial to quickly counteract the effects of class IC drugs. This is accomplished by using bicarbonate to induce alkalinisation, which reduces drug-receptor binding, especially given that excess mortality associated with such intoxications can be as high as 22%.

Figura 1.

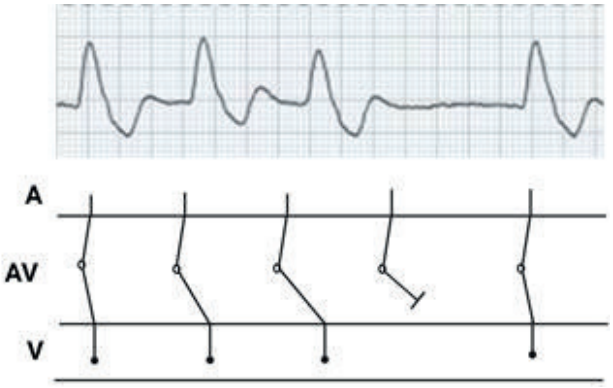

Figura 2.

A98: COPY NUMBER VARIATIONS IN LQTS: NOT SO RARE AFTER ALL

Deni Kukavica (a, b), Mirella Memmi (a), Patrick Gambelli (a), Alessio Guarracino (a), Barbara Colombi (a), Janni Nastoli (a), Alessandro Trancuccio (a, b), Gianluca Pili (a, b), Maira Marino (a), Raffaella Bloise (a), Carlo Napolitano (a, b), Andrea Mazzanti (a, b), Silvia Giuliana Priori (a, b)
(a) IRCCS ICS MAUGERI PAVIA; (b) UNIVERSITÀ DI PAVIA

Background. Long QT Syndrome (LQTS) is a collective term for a group of cardiac electrical disorders characterized by prolonged ventricular repolarization, represented by the QT interval on surface electrocardiogram (ECG), and by the predisposition to develop polymorphic ventricular tachycardia and ventricular fibrillation leading to syncope or sudden cardiac death (SCD). Congenital LQTS is mainly related to point mutations in genes the KCNQ1, KCNH2, and SCN5A genes, and up to 75% of patients can be genotyped by standard DNA sequencing. However, standard genetic testing fails to detect structural genomic rearrangements - including large deletions or duplications of DNA segments - known as copy number variants (CNVs). Previous studies have suggested that CNVs account for less than 5% of genotype-negative cases of LQTS[1-2], but no recent data have been reported.
Purpose. The study aimed to determine the prevalence and spectrum of CNVs in LQTS susceptibility genes in unrelated patients who tested negative for point mutations in a panel of 16 genes associated with LQTS.
Methods. Next-generation sequencing (NGS) was used to screen for CNVs in a cohort of unrelated, clinically affected LQTS patients, and who had undergone standard genetic testing which failed to identify point mutations in any of the 16 genes associated with LQTS. Loss of heterozygosity in LQTS-associated genes was used to assess the presence of CNVs using the software Ion Reporter 1.18 (Thermo Fisher Scientific, Waltham, MA, USA). The multiplex ligation-dependent probe amplification (MLPA) assay was used to confirm the CNVs identified by NGS (SALSA MLPA Reagent Kit - probemix p114 (LQTS) - MRC Holland, The Netherlands).
Results. Our cohort included 63 patients (68% women; mean age 31±19 years, range 3 months to 68 years) with definitive clinical diagnosis of LQTS (mean QTc 490±30 ms) according to the 2022 ESC guidelines[3]. Overall, 9/63 patients (14%, 95% CI 8-25%) had CNVs. Seven of the nine CNVs involved KCNQ1 in the heterozygous state, including four large deletions (exons 3-6, exons 12-15, and exon 16) and three duplications (exon 2, exons 3-6, and exons 3-15), whereas the remaining two probands had a complete KCNH2 deletion. MLPA confirmed all CNVs identified by NGS. Of note, no CNVs were identified in LQTS-related genes whose pathogenicity has been questioned.
Conclusions. We identified structural genomic rearrangements in the KCQN1 and KCNH2 genes in an unexpectedly high proportion of patients with LQTS. Considering the fundamental importance of genotype for diagnosis, prognosis and treatment, screening for CNVs in patients affected by LQTS should be performed to enable personalized treatment strategies.

A99: A PROPOSED INDEX OF MYOCARDIAL STAINING FOR VEIN OF MARSHALL ETHANOL INFUSION: AN ITALIAN SINGLE CENTER EXPERIENCE

Federico Landra (a), Nesti Martina (b), Garibaldi Silvia (b), Gianluca Mirizzi (b), Umberto Startari (b), Luca Panchetti (b), Marcello Piacenti (b), Simone Taddeucci (a), Bruno Antonio Formichi (b), Maurizio Stefani (b), Serena Galiberti (b), Vincenzo Lionetti (b), Paolo Solinas (b), Maria Beatrice Levantesi (b), Chiara Italia (b), Andrea Rossi (b)
(a) DIVISION OF CARDIOLOGY, UNIVERSITY OF SIENA; (b) FONDAZIONE TOSCANA GABRIELE MONASTERIO, PISA

Background. Mitral isthmus(MI) conduction block is a fundamental step in anatomical approach treatment for persistent atrial fibrillation(PeAF). However, MI block is hardly achievable with endocardial ablation only. Retrograde ethanol infusion(EI) into the vein of Marshall(VOM) facilitates MI block. Fluorographic myocardial staining(MS) during VOM-EI could be helpful in predicting procedural alcoholization outcome even if its role is qualitatively assessed in the routine.
Objective. To quantitatively assess MS during VOM-EI and to evaluate its association with MI block achievement.
Methods. Consecutive patients undergoing catheter ablation for PeAF at our Center from February 2022 to May 2023 were considered. Patients with identifiable VOM were included. A proposed index of MS(MSI) was retrospectively calculated in each included patient. Correlation of MSI with low voltage area(LVA) extension after VOM-EI and its association with MI block achievement were assessed.
Results. 42 patients out of 49 (85.8%) had an identifiable VOM. MI block was successfully achieved in 35 patients out of 42 (83.3%). MSI was significantly associated with the occurrence of MI block (OR 1.24 (1.03 – 1.48); p=0.022). A higher MSI resulted in reduced ablation time (p=0.014) and reduced radiofrequency applications (p=0.002) to obtain MI block. MSI was also associated with MI block obtained by endocardial ablation only (OR 1.07 (1.02 – 1.13); p=0.002). MSI was highly correlated with newly formed LVA extension (r=0.776; p=0.001).
Conclusions. In our study cohort, optimal MSI predicts MI block and facilitates its achievement with endocardial ablation only.

A100: RITIRATO

A101: SARS-COV-2 INFECTION'S EFFECTS ON CARDIAC CONDUCTION SYSTEM: A PREVALENCE STUDY

Pietro Oro (a), Massimo Russo (a), Edoardo Navazio (a), Lucy Barone (a), Domenico Sergi (a), Carlo Chiaramonte (a), Francesco Barillà (a)
(a) U.O.C. CARDIOLOGIA POLICLINICO "TOR VERGATA"

Background. In the medical literature of recent years, cardiovascular involvement in SARS-CoV-2 infection has been widely reported. In addition to hypertension, the main manifestation is myocardial damage (19.7%). Less common manifestations include case reports and case se-

ries of total atrioventricular block (AVB) associated with COVID -19 infection. The persistent cardiac involvement of infection seems to be mainly related to the inflammatory response (IL -6, PCR, hyperferritinemia, leukocytosis), direct damage, and microthrombi, whereas it is not clear whether SARS-CoV-2 has a direct and specific affinity for the cardiac conduction system. Apart from case reports and case series, there are currently no statistical data in the literature on changes in the prevalence of AVB and pacemaker (PM) implantation between the pre-COVID and COVID periods.

Methods. We therefore performed a prevalence study to determine whether infection with COVID -19 was associated with a significant increase in cases of II degree AVB or III -degree. For this purpose, we included all patients consecutively referred to our cardiology department from 2017 to 2022 and compared the prevalence of II -degree AVB, III -degree AVB, and PM implantation in the period before COVID (2017-2019) and COVID (2020-2022). We also compared the frequency of risk factors (hypertension, diabetes, dyslipidemia, smoking, and coronary artery disease) in 2017-2019 and in 2020-2022 and their association with II -degree AVB or III -degree AVB. We excluded patients who underwent AVB after TAVI surgery or in the setting of acute myocardial ischemia.

Results. The data obtained showed no statistically significant differences in the prevalence of II -degree AVB (0.55 vs 0.601, z Gauss=0.866, p=0.384) and III -degree AVB (0.445 vs 0.406, z Gauss=0.733, p=0.465) in the two periods studied. However, the analysis of risk factors associated with the PM implantation for II -degree AVB and III -degree AVB, covering the two statistical observation periods, shows the increased frequency of risk factors associated with PM implantation for II -degree AVB, with statistical significance for hypertension (Pre-COVID: z Gauss=2,593, p=0,01; COVID: z Gauss=2,404, p=0,016) and smoking (Pre-COVID: z Gauss=3,143, p=0,0001; COVID: z Gauss 2,703, p=0,007) both in the pre- COVID and COVID periods. It also shows a lower frequency of risk factors in patients undergoing PM implantation for III -degree AVB than for II -degree AVB.

Conclusions. According to the data collected in our study, infection with SARS-CoV-2 does not appear to be associated with a statistically significant increase in AVB. However, there seems to be a greater association between risk factors and PM implantation for II -degree AVB that is not confirmed for PM implantation for III -degree AVB.

A102: BRUGADA SYNDROME AND RV OUTFLOW TRACT DILATATION: A DANGEROUS LIASON

Gianluca Pili (a, b), Deni Kukavica (a, b), Alessandro Esposito (a), Alessandro Trancuccio (a, b), Maira Marino (a), Raffaella Bloise (a), Carlo Napolitano (a, b), Andrea Mazzanti (a, b), Silvia Giuliana Priori (a, b)
(a) IRCCS ICS MAUGERI PAVIA; (b) UNIVERSITÀ DI PAVIA

Background. Mounting evidence exists to support the hypothesis that patients with Brugada Syndrome present morphological and structural anomalies localized to the right ventricle outflow tract (RVOT). However, these findings have yet to be thoroughly investigated within a larger cohort, and their associations with clinical outcomes remain unclear.

Purpose. To investigate the role of echocardiography-derived right ventricular (RV) parameters in a large, single-center cohort of patients with Brugada Syndrome.

Methods. We enrolled consecutive patients with confirmed Brugada Syndrome who underwent a transthoracic echocardiogram during their last at the outpatient clinic visit. Comprehensive 2D and color Doppler evaluation was performed using a standardized institutional protocol. Statistical analysis was performed using RStudio Version 4.1.1 (Boston, MA, USA). The endpoint was the past occurrence of a life-threatening arrhythmic event (LAE: composite of SCD, aborted cardiac arrest, or hemodynamically non-tolerated ventricular tachycardia [VT]). The past occurrence of LAE during life was used as the only outcome variable in a multivariate logistic regression analysis. Continuous data were reported as mean ± standard deviation (SD), or median and interquartile range (IQR), as appropriate. Two-sided p value of <0.05 was considered statistically significant in all analyses.

Results. Our cohort consisted of n=493 consecutive patients (379 males, 77%; 46±14 years old). All patients had normal left ventricular volumes (LV EDV 57±10 ml/m2) and systolic function (LVEF 59±3%). Importantly, 278/493 (56%) of patients presented RVOT dilatation, as assessed by either PLAX (18±2 mm/m2) or PSAX (19±1 mm/m2). Relevantly, no patients had longitudinal (TAPSE 24±3 mm) nor radial (RV FAC 43±6%) RV impairment. Univariate regression analysis showed that RVOT dilatation was associated with an increased probability of past LAE occurrence (odds ratio, OR: 3.9; 95% confidence interval, CI: 1.5-9.6, p=0.016), in addition to the presence of spontaneous type 1 pattern (OR: 4.7, 95% CI: 2.0-10.9, p=0.003) and unexplained syncope (OR: 2.2, 95% CI: 1.0-4.8, p=0.088). Multivariate logistic regression confirmed that at parity of spontaneous type 1 pattern (OR 4.5, 95% CI: 1.9-10.6, p=0.003) and unexplained syncope (OR 2.0, 95% CI: 0.9-4.5, p=0.142), RVOT dilatation (OR 3.5, 95% CI: 1.4-9.0, p=0.025) was independently associated with an increased prevalence of history of life-threatening arrhythmic events.

Conclusions. Our data suggest that a mild degree of RVOT dilatation is relatively prevalent in our cohort of patients with BrS. Importantly, mild RVOT dilatation in absence of RV dysfunction is associated with a higher proportion of past life-threatening arrhythmic events, independently of pattern type or history of syncopal spells.

A103: VT OR NOT VT - THIS IS THE QUESTION: A CASE REPORT OF A WIDE QRS COMPLEX TACHYCARDIA

Enrico Guido Spinoni (a), Alberto Battaglia (a), Domenico Caponi (a), Natascia Cerrato (a), Marco Gagliardi (a), Sofia Capocci (a), Francesco Geuna (a), Andrea Lamanna (a), Marco Scaglione (a)
(a) DIPARTIMENTO DI ELETTROFISIOLOGIA, SC CARDIOLOGIA, OSPEDALE CARDINAL MASSAIA, ASTI

Background. The differential diagnosis of Wide QRS Complex Tachycardia between ventricular and supraventricular tachycardia is often challenging. Many different algorithms have been proposed to guide the physician in the correct diagnosis, the most often used and validated are Brugada algorithm and Verekei algorithm. The presence of P waves dissociations and/or the presence of fusion/capture beats can help the clinician in defining the right diagnosis, but such signs are not always present. We present here the case of a 45-years old man presenting to the ER department for tachycardia with wide QRS complex tachycardia.

Clinical case. A 45-years old presented to the ER department for sudden onset of persistent tachycardia. The ECG recording showed a hemodynamic stable wide QRS complex tachycardia (Figure 1). Adenosine was administered up to 12 mg, without any benefit. Electrical cardioversion with a single DC shock was then performed, restoring sinus rhythm. The patient then refused the hospitalization and left the hospital. He presented recurrences of the tachycardia with ER presentation and termination of the arrhythmia by electrical cardioversion. The patient then accepted the hospitalization in Our Cardiology Department. At careful examination, considering the wide QRS complex morphology the first hypothesis was ventricular tachycardia. During the hospitalization, the patient referred paroxysmal episodes of tachycardia since the age of 15-years old. Considering the clinical data, adenosine test during sinus rhythm with administration up to 18 mg of adenosine was performed, unveiling the presence of a concealed accessory pathway (Figure 2). Fluoroless electrophisiology study was then performed with electroanatomic mapping system (EAM CARTO 3, Biosense Webster) confirming the presence of antidromic Atrioventricular Re-entrant Tachycardia (AVRT) by left lateral accessory pathway. Effective transcatheter ablation with radiofrequency was then performed (Figure 3). The patient was discharged the day after at home without any pharmacological therapy. At 3-months follow-up, he experienced no significative arrhythmic relapses.

Discussion and Conclusions. Differential diagnosis of wide QRS complex tachycardia by 12-lead ECG is often challenging. Careful clinical examination and use of additional test (eg. adenosine administration test during sinus rhythm) can help the physician in this challenging task. In the presence of antidromic AVRT, transcatheter ablation of the accessory pathway is a safe and effective treatment.

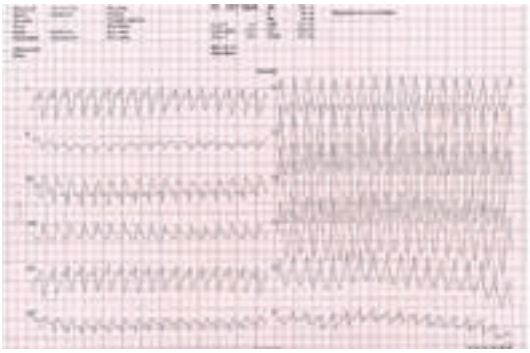

Figure 1.

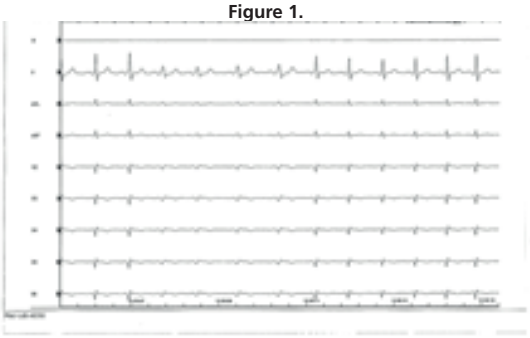

Figure 2.

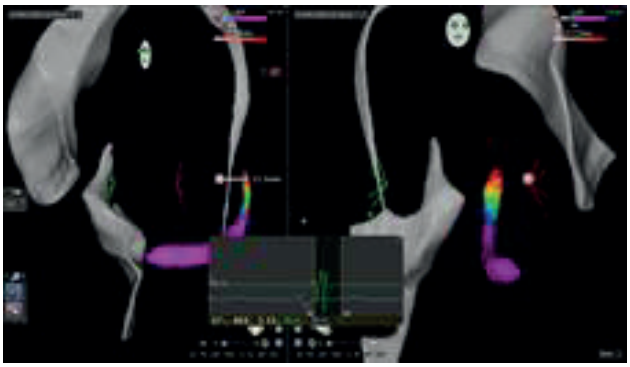

Figure 3.

A104: CATHETER ABLATION OF VENTRICULAR TACHYCARDIA ARASING FROM LEFT VENTRICULAR ANEURYSM BORDER ZONE:A CASE REPORT

Giulia Spiriti (a), Gianluca Guelfand Crignola (a), Giacomo Silvetti (a), Emanuele Marino (a), Federico Baraldi (a), Giulia Garosi (a), Gaetano Tanzilli (a), Carlo Gaudio (a), Concetta Torromeo (a), Raffaele Quaglione (a), Bich Lien Ngugyen (a)
(a) POLICLINICO UMBERTO I

Post-infarction left ventricular aneurysm (LVA) is a serious sequela of an extended transmural myocardial infarction. This can subvert both mechanical and electrical heart properties becoming a serious risk factor for ventricular arrhythmias. The substrate for LVA-related (ventricular tachycardia) VT is usually located in the aneurysm's border zone.
We report a case of a 70-year-old man with a history of ischaemic cardiomyopathy and reduced LV ejection fraction. The patient presented to our emergency department with sustained VT and hemodynamic instability. Recurrent episodes of VT requiring DC shock occurred during the hospitalization. Long QT and the patient's comorbidities brought us to perform a successful VT catheter ablation. By confronting the CRM scan with the 3D electroanatomical mapping made in the EP lab, we were able to identify the LV aneurysm border zone as the main critical isthmus for the genesis and maintenance of the VT. In selected patients, VT catheter ablation may be the most efficient solution to improve patients' quality of life end reduce ICD shock. The presence of LVA should be investigated in all patients. LVA catheter ablation is a high-risk procedure and should be performed only in selected and experienced centers.

A105: LA TERAPIA CON ARNI NELLO SCOMPENSO CARDIACO A FRAZIONE D'EIEZIONE RIDOTTA: IMPATTO A LUNGO TERMINE SU MORTALITÀ ED EVENTI ARITMICI

Matteo Spoladori (b), Antonio Crocamo (a), Francesco Capoccia (b), Davide Rizzello (b), Luca Bearzot (b), Riccardo Sciarroni (b), Andrea Caraffini (b), Gian Luca Gonzi (a), Angela Guidorossi (a), Giampaolo Niccoli (a, b), Diego Ardissino (a, b), Maria Francesca Notarangelo (a)
(a) AZIENDA OSPEDALIERO-UNIVERSTARIA DI PARMA; (b) UNIVERSITÀ DEGLI STUDI DI PARMA

Background. Gli ARNI sono una classe farmaceutica ampiamente utilizzata nel trattamento dello scompenso cardiaco, con numerose evidenze a supporto del loro beneficio in termini di sopravvivenza in questi pazienti. Nel corso degli ultimi anni, diversi studi hanno mostrato come questi farmaci abbiano un impatto anche sulla riduzione dell'incidenza di aritmie ventricolari e morte cardiaca improvvisa. Obiettivo di questo studio è stato valutare l'incidenza di eventi aritmici e morte per tutte le cause in una popolazione "real world" di pazienti con frazione di eiezione ridotta, sottoposti ad impianto di defibrillatore (ICD).
Materiali e metodi. Lo studio in esame è osservazionale, retrospettivo, longitudinale, di coorte. Sono stati raccolti dati anagrafici, clinici e farmacologici in tutti i pazienti sottoposti ad impianto di ICD tra il 2014 ed il 2021. Per tutti i pazienti sono stati registrati i decessi e gli eventi aritmici significativi (TVNS, TVS, FV) riscontrati durante il controllo periodico dei dispositivi e registrati al monitoraggio remoto. È stata eseguita un'analisi univariata di Kaplan-Meier per confrontare i pazienti in trattamento con ARNI rispetto ai pazienti non in trattamento, in relazione all'endpoint primario composito, costituito da aritmie ventricolari e mortalità per tutte le cause.
Risultati. Sono stati arruolati in totale 698 pazienti (82% maschi, età media 69 ± 13 anni), 74% impiantati in prevenzione primaria, 56.8% affetti da cardiopatia ischemica, 36% portatori di CRT-D. Il 10.3% dei pazienti assumeva terapia con ARNI, in questo sottogruppo l'86% era stato impiantato in prevenzione primaria ed il 55% era affetto da cardiopatia ischemica. Durante il follow-up della durata media di 8 anni, 214 pazienti (30.7%) sono deceduti. L'endpoint composito si è verificato nel 27.7% (20/72) dei pazienti in terapia con ARNI e nel 47.9% (300/626) dei pazienti non in terapia, con un Hazard Ratio pari a 0.23 [0.17-0.57], (p=0.007).
Discussione e Conclusioni. Questo studio eseguito in una popolazione "real world" di pazienti sottoposti ad impianto di ICD ha evidenziato due aspetti: 1) i pazienti già portatori di ICD sono sotto-trattati in relazione alla terapia con ARNI; 2) i pazienti che assumono il trattamento hanno un beneficio in termini di riduzione della mortalità totale e degli eventi aritmici.

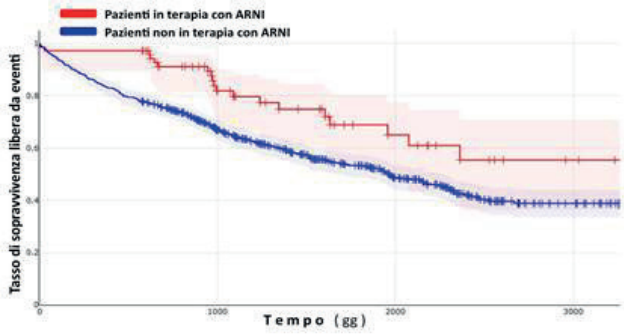

A106: IMPATTO CLINICO DELL'IMPIANTO DI ICD NEGLI ULTRAOTTANTENNI: STUDIO LONGITUDINALE DI COORTE

Matteo Spoladori (b), Antonio Crocamo (a), Francesco Capoccia (b), Davide Rizzello (b), Rosi Vrenozaj (b), Alberto Bettella (b), Anselmo Alessandro Palumbo (a), Stefano Cavalli (b), Marco De Maria (b), Carlotta Zilioli (b), Luca Bearzot (b), Gian Luca Gonzi (a), Giampaolo Niccoli (a, b), Diego Ardissino (a, b), Maria Francesca Notarangelo (a)
(a) AZIENDA OSPEDALIERO-UNIVERSITARIA DI PARMA; (b) UNIVERSITÀ DI PARMA

Background. L'impianto di defibrillatore (ICD) nei pazienti ultraottantenni è sempre più frequente; tuttavia, i dati "evidence based" relativi al reale beneficio clinico in questa popolazione di pazienti sono scarsi e contrastanti. Mentre l'età non sembra influenzare il rischio di mortalità e aritmie negli ultraottantenni impiantati in prevenzione secondaria, tra i pazienti impiantati in prevenzione primaria il beneficio dato dall'impianto di ICD in termini di riduzione di mortalità sembra ridursi all'avanzare dell'età, verosimilmente per l'elevato numero di morti non aritmiche. Obiettivo di questo studio è stato valutare l'incidenza a lungo termine di aritmie ventricolari e mortalità in una coorte real-world di pazienti ultraottantenni sottoposti ad impianto di ICD.
Materiali e metodi. Trattasi di uno studio osservazionale, retrospettivo, longitudinale, di coorte. Sono stati raccolti dati anagrafici, clinici e radiologici in tutti i pazienti sottoposti ad impianto di ICD tra il 2014 ed il 2021. Sono stati registrati i decessi per tutte le cause e gli eventi aritmici significativi (tachicardie ventricolari sostenute e fibrillazione ventricolare) riscontrati al controllo periodico dei dispositivi e mediante monitoraggio remoto. È stata poi eseguita un'analisi univariata di Kaplan-Meier stratificando la popolazione per età in relazione ai due endpoint dello studio: aritmie ventricolari e mortalità da tutte le cause.
Risultati. Su un totale di 700 pazienti 512 sono stati sottoposti ad impianto di ICD prima di 80 anni (età media all'impianto 64±12), mentre 188 sono stati sottoposti ad impianto di ICD dopo gli 80 anni (età media all'impianto 82±3.2). Tra questi due gruppi non vi erano differenze significative rispetto a sesso (82% vs 83% maschi; p 0.12), indicazione all'impianto (74% vs 75% prevenzione primaria; p 0.79) e presenza di LGE alla RM cardiaca (68% vs 77% p 0.14). Gli ultraottantenni erano più frequentemente affetti da cardiopatia ischemica (54% vs 65%; p 0.01) e sono stati trattati più frequentemente con amiodarone (17% vs 24%; p 0.02). Al termine del follow up medio di 8 anni gli ultraottantenni presentavano una mortalità per tutte le cause significativamente più elevata rispetto ai pazienti più giovani (HR=2.35 [1.88-3.16]; p<0.05) con una divergenza delle curve di sopravvivenza a partire da 3 anni dopo l'impianto. Gli eventi aritmici ventricolari invece erano significativamente ridotti nei pazienti ultraottantenni (HR=0.88 [0.87-0.89]; p<0.05).
Discussione e Conclusioni. In una popolazione real-world di pazienti ultraottantenni il beneficio clinico dell'impianto di ICD in prevenzione primaria appare ridotto, in relazione al trade-off tra aritmie ventricolari e mortalità, sia nei pazienti affetti da cardiopatia ischemica che da cardiopatia non ischemica.



A107: THE ANALYSIS OF FAMILY TREES REVEALS AN UNEXPECTED GENOTYPE-SPECIFIC RISK IN PATIENTS WITH DESMOSOMAL MUTATIONS

Andrea Sugamiele (a, b), Kenneth Steele (a), Alessandro Trancuccio (a, b), Deni Kukavica (a, b), Massimo Morini (a), Maira Marino (a), Patrick Gambelli (a), Mirella Memmi (a), Andrea Mazzanti (a, b), Silvia Giuliana Priori (a, b)
(a) IRCCS ICS MAUGERI PAVIA; (b) UNIVERSITÀ DEGLI STUDI DI PAVIA

Background. Arrhythmogenic right ventricular cardiomyopathy (ARVC) is one of the most lethal inherited arrhythmia syndromes causing a relevant proportion of sudden cardiac deaths (SCD) in young individuals. Despite this, the prevalence of SCD in families with a pathogenic or likely pathogenic mutation on one of the four main genes is unknown. Similarly, although previous evidence suggested an association between the presence of a desmosomal mutation (plakophilin-2 [PKP2], desmoplakin [DSP], desmoglein-2 [DSG2], desmocollin-2 [DSC2]) and an increased risk of SCD, the robust data to support a hypothesis of high-risk genotypes is lacking.
Purpose. The study aimed to (1) determine the prevalence of SCD in families with a pathogenic or likely pathogenic mutation on one of the four main genes; (2) evaluate the genotype-specific burden of SCD.
Methods. We retrospectively analyzed the family history data from families with a pathogenic or likely pathogenic mutation on one of the four main genes (PKP2, DSP, DSG2, DSC2). Only families in which at least three generations could be evaluated for the occurrence of SCD were considered for this analysis. We collected the data regarding the number of families with SCD events, the total number of events, as well as patients' demographics at the time of SCD. SCD was defined as an unexplained and unexpected death of an individual younger than 50 years of age. Statistical analysis was performed using RStudio Version 4.1.1 (Boston, MA, USA).
Results. Our cohort included 85 families: 43/85 (51%) families with PKP2 mutation, 26/85 (30%) families with DSP mutation, 13/85 (15%) families with DSG2 mutations and 3/85 (4%) families with DSC2 mutations. Overall, we identified at least one SCD victim in 50/85 (59%, 95% CI: 48-69%) of families investigated, with an overall of 72 victims (63% males, 41±14 years at SCD, 1.4±0.8 victims per family). Importantly, there were significant genotype differences (p=0.0004 for global comparison). Specifically, there was a significant excess of DSP families with at least one SCD victim (23 families with at least one SCD out of 26 DSP families; 88%, 95% CI: 70-96%) as compared to other genotypes: 23/43 (53%, 95% CI: 39-68%) in PKP2 families (p=0.004), 4/13 (31%, 95% CI: 9-61%) in DSG2 families (p=0.0005), and 0/3 (0%, 95% CI: 0-71%) in DSG2 families (p=0.006). Relevantly, also when assessing the overall number of SCD victims, our data support the association of specific genotypes and SCD (p<0.0001). The number of SCD victims was higher in DSP families (38 SCD victims in 90 individuals, 42%, 95% CI: 32-53%) as compared to other genotypes: 29/148 (20%, 95% CI: 14-27%) in PKP2 families (p<0.001), 5/50 (10%, 95% CI: 3-22%) in DSG2 families (p<0.001), and 0/11 (0%, 95% CI: 0-28%) in DSC2 families (p=0.006).
Conclusions. The study of families with a pathogenic or likely pathogenic mutation on one of the four main genes revealed an unexpectedly high burden of SCD. Our data suggest indirectly that DSP mutations may be associated with a higher incidence of SCD, both in terms of families with at least one SCD victim and overall number of SCD victims.

A108: STRATIFICAZIONE DEL RISCHIO ARITMICO NEI PAZIENTI CON PATTERN DI BRUGADA TIPO 1: STUDIO MONOCENTRICO RETROSPETTIVO

Renè Tezze (a), Francesco Vilei (a), Martina Vitali (a), Alberto Sarti (a), Marco Giardino (a), Cristina Balla (a), Michele Malagù (a), Matteo Bertini (a), Martina De Raffaele (a), Assunta Di Domenico (a), Giorgia Azzolini (a), Francesco Vitali (a)
(a) CARDIOLOGY UNIT, AZIENDA OSPEDALIAERO-UNIVERSITARIA DI FERRARA

Background. come già noto i pazienti con pattern elettrocardiografico di Brugada tipo 1 sono soggetti ad un maggior rischio di sviluppare eventi aritmici maligni, tuttavia non tutti i pazienti con tale diagnosi vanno incontro a tale evenienza nel corso della propria storia clinica.
Ipotesi. Analizzare la presenza di eventuali differenze clinici/strumentali ed elettrocardiografiche tra le sottopopolazioni di pazienti con pattern ECG di Brugada tipo 1, potenzialmente utili ad una stratificazione clinica ed elettrocardiografica del rischio aritmico.
Materiali e metodi. Studio monocentrico retrospettivo su 83 probandi affetti da Sindrome di Brugada con evidenza di pattern ECG tipo 1 spontaneo, afferiti al nostro centro di cardiogenetica. La popolazione è stata suddivisa in 2 gruppi a seconda della presenza di eventi aritmici nella storia clinica del paziente. Successivamente sono stati analizzati per ciascuno dei due gruppi parametri clinici/strumentali (età, sesso, test genetico positivo, storia di fibrillazione atriale/flutter, SEF positico, test alla flecainide positivo, RMN positiva per alterazioni strutturali, storia di interventi dell'ICD, terapia con farmacologica antiaritmica, storia familiare di morte improvvisa) e dei parametri elettrocardiografici (frequenza cardiaca basale, durata dell'intervallo PR, presenza di emiblocco anteriore sinistro, pattern di Brugada evidenziabile nelle derivazioni periferiche, presenza di pattern da ripolarizzazione precoce, durata del QRS in D2, presenza di QRS frammentato, durata dell'intervallo QT in D2 corretta con il metodo Bazett, positività agli Tzou criteria (V1R>0.15 mV, V6S>0.15 mV, V6S/R>0.2 mV), presenza di onda S in D1 profonda (≥40 ms and ≥0,1 mV), presenza di avR sign (R'≥0,3 mV)). L'obiettivo della nostra analisi è stato stabilire la presenza di eventuali differenze nella distribuzione delle caratteristiche sopra elencate tra le due sottopopolazioni di pazienti con pattern ECG tipo 1.
Risultati. i dati della nostra popolazione dimostrano come dal punto di vista delle variabili clinico/strumentali non siano evidenziabili differenze statisticamente significative tra le due sottopopolazioni oggetto dell'analisi, eccezion fatta per il raccordo anamnestico di interventi dell'ICD, significativamente più frequente nei pazienti con storia di eventi aritmici maligni (p<0,0001). In particolare, non è emersa un'associazione significativa tra la positività allo screening genetico e la storia di eventi aritmici maligni (p=0.74), evidenziando come l'analisi genetica non abbia tuttora un impatto sulla stratificazione del rischio aritmico di questi pazienti. Per quanto concerne invece le variabili elettrocardiografiche prese in considerazione, emergono alcune differenze significative. Nella nostra analisi, infatti, il gruppo di pazienti con storia di eventi aritmici maligni ha dimostrato una maggior incidenza di QRS frammentato (p=0.047), di positività agli Tzou criteria (p=0.05) e all'avR sign (p=0.007).
Conclusioni. la storia clinica di eventi aritmici maggiori nei soggetti con pattern ECG di Brugada tipo 1 si è dimostrato associata a parametri elettrocardiografici potenzialmente relati ad un aumentato rischio aritmico in tale popolazione di pazienti.

A109: OLTRE L'EFFETTO INODILATATORE: CASO CLINICO SULL'EFFETTO DROMOTROPO DEL LEVOSIMENDAN

Andrea Carmelo Visalli (a, b), Filippo Angelini (a), Daniele Melis (a, b), Alessandro Vairo (a), Francesco Bruno (a), Simone Frea (a), Federico Ferraris (a), Matteo Anselmino (a, b), Gaetano Maria De Ferrari (a, b), Veronica Dusi (a, b)
(a) DIVISIONE DI CARDIOLOGIA, DIPARTIMENTO CARDIOVASCOLARE TORACICO, AOU CITTÀ DELLA SALUTE E DELLA SCIENZA; (b) DIPARTIMENTO DI SCIENZE MEDICHE, UNIVERSITÀ DEGLI STUDI DI TORINO

Introduzione. Il levosimendan è un farmaco calcio-sensibilizzante utilizzato nella gestione dell'insufficienza cardiaca congestizia scompensata per il suo effetto inodilatatore, dal potenziale, seppur modesto, effetto proaritmico ventricolare e atriale. Il farmaco ha anche un effetto sulla conduzione atrioventricolare (AV), ben caratterizzato soltanto nei volontari sani, in cui è stata descritta una riduzione media del periodo refrattario del nodo atrioventricolare (AV) di 40-63 ms (dell'atrio di 22-33 msec e del ventricolo di 5-9 msec). Si descrive un caso di flutter atriale atipico con conduzione AV 1:1 in corso di terapia con levosimendan.
Caso. Uomo di 55 anni, affetto da cardiomiopatia dilatativa a coronarie sane, nota dal 2008. Dal 2016 peggioramento della classe funzionale, frazione di eiezione (FE) 23% con insufficienza mitralica (IM) severa, per cui veniva sottoposto a riparazione percutanea edge-to-edge con singola MitraClip, e residuava IM moderata. In seguito si registravano episodi di tachicardia ventricolare non sostenuta (TVNS) e sostenuta, ed episodi di fibrillazione (FA) e flutter atriale (FLA); rifiutato ICD, veniva avviato amiodarone. Nel 2019 eseguita ablazione di FA e FLA destro e sinistro, con recidive al follow-up, talora con necessità di cardioversione elettrica. Nel 2020 eseguito impianto di dispositivo di resincronizzazione e defibrillazione (CRTD). Ai successivi controlli del device lembi di aritmie atriali lente (Fc atriale media 135 bpm) con prevalente conduzione AV spontanea 2:1 e rarissime fasi di conduzione AV 1:1 durante attività fisica; aumentata Fc minima del CRTD da 60 a 80 ppm. Nel gennaio 2023 veniva ricoverato presso il nostro centro per riacutizzazione di scompenso cardiaco, con profilo wet and cold: avviati unloading e decongestione, mantenuto bisoprololo domiciliare (2.5 mg/die). All'ecocardio FE 23%, VTDi 168 ml/m2, volume atriale sinistro 78 ml/mq, IM severa, ventricolo destro ipocontrattile (FAC 20%), PAPs 54 mmHg; all'ECG stimolazione biventricolare a 80 ppm, sottostante aritmia atriale organizzata alternata a lembi di ritmo sinusale. All'analisi del CRT-D burden aritmico atriale del 12% (Fc media delle aritmie atriali 135-145 bpm, con pacing ventricolare in corso di aritmia), 20 epi-

sodi di TVNS, percentuale di pacing ventricolare 97%. Avviato ciclo di levosimendan a bassa dose (0.05 mcg/kg/min, senza bolo). Dopo circa 24 h dall'avvio, comparsa di cardiopalmo con evidenza al monitoraggio telemetrico di tachicardia a 125-130 bpm, QRS 130 ms con morfologia a blocco di branca destra ed emiblocco anteriore sinistro, compatibile con aritmia atriale con conduzione AV 1:1. Veniva pertanto avviato amiodarone ev (900 mg/die per 48 h, poi sostituito con terapia orale a dose aumentata), con persistenza dell'aritmia atriale, ma progressiva riduzione delle fasi di conduzione AV 1:1. La settimana successiva eseguito studio elettrofisiologico con conferma di FLA atipico, trattato efficacemente con ablazione transcatetere. Non rilevate recidive aritmiche nei successivi 6 mesi di follow-up.

Conclusioni. Il nostro caso, primo riportato nel suo genere, dimostra che il levosimendan può avere un effetto dromotropo positivo clinicamente significativo, in particolare in pazienti con bassa se non nulla protezione offerta dalla terapia betabloccante, come nei casi di scompenso cardiaco instabilizzato. Tale possibilità, sebbene rara, deve essere tenuta in considerazione, soprattutto nei pazienti con storia di aritmie atriali o con aritmie atriali in corso, in quanto potenziale causa di deterioramento emodinamico con scarse opzioni terapeutiche in acuto.

A110: GESTIONE COMPLESSA DI UN CASO DI SHOCK CARDIOGENO E STORM ARITMICO IN CORSO DI TIREOTOSSICOSI

Andrea Carmelo Visalli (a, b), Filippo Angelini (a), Daniele Melis (a, b), Paolo Boretto (a), Pier Paolo Bocchino (a), Alessandro Vairo (a), Carol Gravinese (a), Simone Frea (a), Gaetano Maria De Ferrari (a, b), Veronica Dusi (a, b)

(a) DIVISIONE DI CARDIOLOGIA, DIPARTIMENTO CARDIOVASCOLARE TORACICO, AOU CITTÀ DELLA SALUTE E DELLA SCIENZA; (b) DIPARTIMENTO DI SCIENZE MEDICHE, UNIVERSITÀ DEGLI STUDI DI TORINO

Introduzione. Il Levosimendan è un farmaco calcio-sensibilizzante, dal potenziale, per quanto modesto, effetto proaritmico ventricolare e atriale. Si descrive un caso di tempesta aritmica in corso di verosimile tireotossicosi da amiodarone di tipo 2 (AIT2) trattata con levosimendan, propranololo, terapia tireostatica, e antiaritmici ev.

Caso. Uomo di 70 anni, ex tabagista, iperteso, diabetico e obeso (in esiti di bypass gastrico), affetto da cardiomiopatia dilatativo-ipocinetica familiare geneticamente determinata (variante patogenetica di TNNT2), esordita nel 2004 con edema polmonare acuto; coronarie indenni, FE 30%, ipertensione polmonare, per cui veniva impostata terapia cardioattiva con buona riposta (FE 45% nel 2005). Nel 2018 avviava sacubitril/valsartan per peggioramento clinico-strumentale (FE 38%). Dal 2019 fibrillazione atriale, con plurimi inefficaci tentativi di controllo del ritmo (amiodarone, svariate cardioversioni e 2 procedure ablative tramite radiofrequenza). Nel 2021 episodio sincopale di natura aritmica, per cui veniva impiantato defibrillatore (ICD), con successivi plurimi shock del device su tachicardie ventricolari (TV) rapide sincopali di differenti morfologie. Veniva pertanto eseguita denervazione simpatica cardiaca bilaterale (04/2022), efficace nel ridurre gli interventi del device. Successivamente, per persistenza di extrasistolia ventricolare isolata e ripetitiva monomorfa, effettuato tentativo di ablazione di focus extrasistolico epicardico, inefficace, e upgrading a resincronizzazione (CRT-D, 06/2023). Giunge alla nostra attenzione per storm aritmico associato ad ipertiroidismo di nuovo riscontro (fT4 16 pmol/l, fT3 1.5 pmol/l, TSH 0.04 mU/l), in quadro di shock cardiogeno SCAI-C. All'ecocardiogramma FE 31%, LVOT VTI 8.5 cm, aumentate pressioni di riempimento, insufficienza mitralica moderata, ventricolo destro con contrattilità ai limiti inferiori. Al controllo del device: 61 episodi di pacing anti-tachicardico (ATP) e 7 shock, appropriati ma non necessari, in meno di 2 ore, su TV monomorfe a carattere subentrante, spesso autolimitantisi con rapida ripresa, con Fc media 200-210 bpm. Eseguita riprogrammazione del dispositivo, con aumento dei tempi di riconoscimento ed impostazione di zona VF>231 bpm. Avviata terapia antiaritmica con lidocaina e amiodarone ev e anti-tiroidea con metimazolo. Vista la franca tireotossicosi con elevato rapporto FT4/FT3 si concordava con l'endocrinologo per avvio di terapia con bassa dose di propranololo (per inibizione della conversione di FT4 in FT3), non appena stabilizzata l'emodinamica. Veniva avviata perciò infusione di levosimendan senza carico (0.05 mcg/kg/min). A distanza di 2h dall'avvio dell'inodilatatore, avviato propranololo (1 mg/kg/die). In seguito non più interventi del device, progressiva riduzione del burden aritmico, mantenuta terapia per os con amiodarone e metimazolo. Autoanticorpi antitiroide successivamente risultati negativi, all'ecografia quadro di tiroidite con vascolarizzazione non aumentata (compatibile con AIT2).

Conclusioni. Il nostro caso sottolinea come nella gestione acuta dello storm aritmico sia fondamentale la ricerca delle cause favorenti e l'impostazione di trattamenti specifici, affiancati a terapia di supporto emodinamico. Nello specifico, l'effetto inodilatatore del levosimendan, che non richiede per estrinsecarsi la liberazione dei recettori adrenergici, ha permesso l'avvio ed il mantenimento della terapia con propranololo, farmaco dagli effetti pleiotropici, antiaritmici (beta-bloccante non selettivo e bloccante dei canali del sodio) e tireostatici.

A111: IL BLOCCO DEL GANGLIO STELLATO: PROCEDURA CHIAVE NELLA GESTIONE DELLO STORM ARITMICO

Martina Vitali (a), Francesco Vitali (a), Michele Malagù (a), Cristina Balla (a), Martina De Raffaele (a), Matteo Bertini (a)

(a) U.O. CARDIOLOGIA UNIVERSITÀ DEGLI STUDI DI FERRARA

Background. Lo storm aritmico è definito dell'occorrenza di tre o più episodi di aritmia ventricolare sostenuta nell'arco delle 24 ore, che richiedono o l'intervento dell'ATP o la defibrillazione, e in cui tra un evento e l'altro ci sono almeno 5 minuti. La terapia antiaritmica è la prima linea di trattamento ma risulta spesso inefficace.

Caso clinico. Uomo di 50 anni, senza alcuna comorbidità, allerta i soccorsi per dolore toracico oppressivo e cardiopalmo. Iniziale stabilità emodinamica. Viene riscontrata una tachicardia ventricolare a 200 bpm, non responsiva né ad amiodarone né a cardioversione elettrica con plurimi shock. Il paziente viene pertanto centralizzato per eseguire studio coronarografico, che riscontra una ostruzione cronica della discendente anteriore con circolo collaterale dalla coronaria destra, una stenosi critica dell'arteria circonflessa-ramo marginale ottuso ed un'occlusione acuta trombotica della coronaria destra distale, poi trattate con angioplastica e posizionamento di stent medicati. Nonostante la rivascolarizzazione parziale, persistenza dello storm aritmico per cui si somministrano lidocaina e procainamide con successivo ripristino del RS. All'ecocardiografia il ventricolo sinistro è dilatato (EDV 280 ml) con acinesia di tutti i segmenti ad eccezione della parete antero-laterale basale e una severa riduzione della frazione di eiezione (<20%). Dopo un paio di giorni dall'evento acuto, nonostante la terapia con amiodarone, si verifica un episodio di R su T con successiva FV trattata con singolo DC-shock e rapido ROSC. Il paziente esegue RM cardiaca con riscontro di una cardiopatia ischemica ad evoluzione ipocinetico-dilatativa (EDV 504 ml) con severa riduzione della funzione sistolica ventricolare sinistra (FE 21%) e compromissione anche di quella destra (FE 31%). LGE transmurale a livello della parete inferiore media e nei segmenti apicali. Dopo alcuni giorni nuovo episodio di FV da R su T nonostante terapia antiaritmica e beta-bloccante a dosaggio massimale. Considerato il volume ventricolare sinistro, la severa disfunzione sistolica e l'occorrenza di aritmie ventricolari sostenute anche oltre le 48 h dall'evento acuto si impianta defibrillatore monocamerale. In seguito all'impianto recidiva di storm aritmico. Ripetuto studio coronarografico che risulta invariato. Nonostante la terapia antiaritmica titolata con lidocaina in infusione, mexiletina, amiodarone e propranololo persistenza dello storm, per cui si esegue ablazione di TV epi-endocardica. Quest'ultima procedura risulta complicata da numerosi episodi di TV non emodinamicamente tollerati per cui si esegue il blocco del ganglio stellato con lidocaina e ropivacaina. Dopo tale manovra si verifica un netto calo degli eventi aritmici. Durante la successiva degenza c'è una progressiva riduzione fino alla scomparsa di ulteriori recidive aritmiche e un progressivo miglioramento delle condizioni di compenso.

Discussione. La gestione dei pazienti con storm aritmico è spesso complessa e richiede anche approcci non farmacologici. L'ablazione transcatetere si è dimostrata efficace nel sopprimere la ricorrenza di aritmie ventricolari e nel migliorare la sopravvivenza, nonostante in una prima fase possa rivelarsi pro-aritmogena essa stessa. Il blocco del ganglio stellato, che fa parte delle manovre di modulazione autonomica, è una procedura facile da eseguire, con tasso di complicanze molto basso, associata ad una riduzione significativa del burden aritmico ventricolare. Questo tipo di tecnica, attualmente utilizzata solo in un terzo dei centri, dovrebbe essere implementata, entrando a far parte della pratica cardiologica di gestione dei pazienti in storm aritmico.

A112: CONTEMPORARY MANAGEMENT AND MULTIPARAMETER CHARACTERIZATION OF REAL-WORLD PATIENTS WITH ATRIAL FIBRILLATION: A REPORT FROM A PROSPECTIVE OBSERVATIONAL COHORT STUDY

Marco Vitolo (a), Marta Mantovani (a), Jacopo Francesco Imberti (a), Niccolò Bonini (a), Davide Antonio Mei (a), Luigi Gerra (a), Ilaria Righelli (a), Kevin Serafini (a), Chiara Birtolo (a), Francesca Rampini (a), Benedetta Cherubini (a), Emilia Caliano (a), Enrico Tartaglia (a), Francesco Chiriaco (a), Paolo Cataldo (a), Giuseppe Boriani (a)

(a) UNIVERSITÀ DEGLI STUDI DI MODENA E REGGIO EMILIA, SC CARDIOLOGIA, POLICLINICO DI MODENA

Background and aim. Atrial fibrillation (AF) epidemiology and its clinical management dramatically evolved in the last decades. AF patients progressively became more clinically complex requiring a structured and holistic management. In this analysis, we report the contemporary management, clinical characterization, and long-term outcomes of consecutive real-world AF patients.

Methods. We analyzed consecutive AF patients enrolled in a prospective single-centre observational study. Patients were followed up after 1 month from the enrollment and usually every 6-12 months thereafter. For the purpose of this analysis, patients were classified according to age as follows: (i) "Non-Elderly" (≤64 years old); (ii) "Young-Old" (65-74 years old); (iii) "Middle-old" (75-84 years old) and (iv) "Oldest-old" (≥85 years old). All-cause mortality was the primary end-point of the study.

Results. A total of 1087 AF patients were included (median age 75 [IQR 66-82], CHA_2DS_2VASc score median 4 [2-5], HAS-BLED median 1 [1-2]). Overall, 163/1087 (15.0%) of patients were classified as "Oldest-old", 394/1087 (36.2%) as "Middle-Old", 295/1087 (27.1%) as Young-Old and 235/1087 (21.6%) as "Non-Elderly". "Oldest-old" patients were characterized by a higher prevalence of females (48.5%) and a higher burden of comorbidities such as heart failure, valvular heart disease, and chronic kidney disease (p<0.001) compared to the other groups also as reflected by the highest median CHA_2DS_2VASC score (5 [4-5]). Cognitive impairment was significantly more prevalent in "Oldest-Old patients" (40.5%) with a relatively high prevalence also in the "Middle-Old" group (21.6%). Multimorbidity, defined as the presence of at least two chronic comorbidities, was present in 82.2% of the total cohort, being progressively higher across age-strata (57.4% vs 82.4% vs 91.1% vs 95.7%, p<0.001). Regarding the type of AF, permanent AF was significantly higher in the "Oldest-old" patients (66.3%) while paroxysmal and first detected AF were significantly higher in the "Non-Elderly" group (29.4% and 17% respectively). Oral anticoagulants were used in 89.4% (972/1087) of the patients. Most of the patients were treated with NOACs (76.7%) while the use of VKAs was substantially low (12.7%). After a median follow-up of 600 [IQR 201-1285] days, there were 152/957 (15.9%) deaths with a significantly higher prevalence in "Oldest-old" and "Middle-Old" patients" compared to other groups (30.7% vs 22.0% vs 8.6% vs 4.1%, p<0.001). Kaplan Meier curves for all-cause mortality are shown in the Figure. In light of the high use of OAC, occurrence of any thromboembolism was substantially low (2.1%), without significant differences among age groups.

Conclusions. In a prospective observational contemporary cohort of real-world patients, despite the continuous improvement in clinical management, all-cause mortality remains substantially high reflecting an increasing age-dependent burden of co-morbidities and stressing the need for an integrated and holistic approach of AF patients.

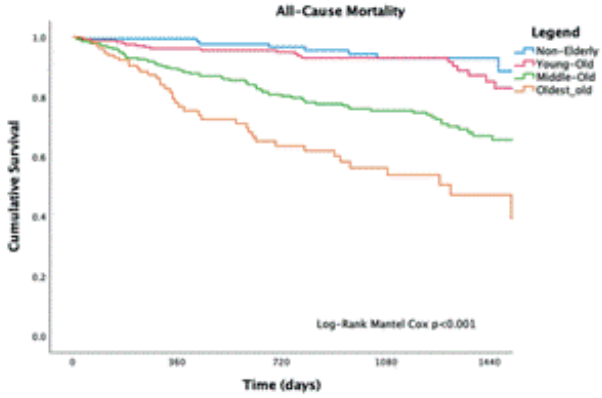

A113: EFFETTI DELLA SEDAZIONE CON DEXMEDETOMIDINA A BASSA DOSE IN PAZIENTI SOTTOPOSTI A STUDIO ELETTROFISIOLOGICO ED ABLAZIONE DI TACHICARDIE SOPRAVENTRICOLARI

Rosi Vrenozaj (a), Nicola De Santis (a), Antonio Crocamo (b), Gian Luca Gonzi (b), Luca Bearzot (a), Angela Guidorossi (b), Giampaolo Niccoli (a), Diego Ardissino (a), Maria Francesca Notarangelo (b)
(a) UNIVERSITÀ DEGLI STUDI DI PARMA; (b) AZIENDA OSPEDALIERO-UNIVERSITARIA DI PARMA

Background. Il mappaggio e ablazione di tachicardie parossistiche sopraventricolari (TPSV) può frequentemente provocare discomfort del paziente, ansia o dolore. La scelta del farmaco sedativo da utilizzare in procedura è condizionata dalla necessità di non interferire con l'induzione e il mappaggio della tachicardia, condizione necessaria alla riuscita della procedura. La Dexmedetomidina (DEX) è un alfa-2 agonista selettivo caratterizzato da un profilo farmacodinamico utile a garantire analgesia e sedazione senza significativa depressione respiratoria. I dati relativi al profilo di efficacia e sicurezza durante ablazione di TPSV dei pazienti adulti sono scarsi e contrastanti. Obiettivo dello studio è stato testare efficacia e sicurezza di DEX a basso dosaggio durante la procedura di mappaggio e ablazione di TPSV in una popolazione adulta, concentrandosi sugli outcomes di tipo elettrofisiologico.

Materiali e metodi. Trattasi di uno studio prospettico monocentrico. Popolazione dello studio è costituita da pazienti consecutivi sottoposti a mappaggio ed ablazione di TPSV da gennaio a settembre 2023 suddivisa nel gruppo DEX (infusione periprocedurale di Dexemedetomidina 0.07-0.11 mcg/kg/h senza dose di carico) e gruppo non DEX (Midazolam 1-2 mg periprocedurale). Per tutti i pazienti sono stati registrati i dati clinici e procedurali, nonché tutte le misurazioni eseguite durante studio elettrofisiologico.

Risultati. La popolazione in studio è stata costituita prevalentemente da donne (60%) di età media pari a 56 anni ± 13.7 anni. Si è verificata ipotensione in un solo paziente del gruppo DEX. Non sono stati osservati casi di desaturazione in entrambi i gruppi. Non sono state registrate differenze significative in relazione a refrattarietà del nodo AV, refrattarietà atriale, conduzione anterograda e retrograda. (Tabella1) L'Isoproterenolo è stato necessario per l'induzione della tachicardia in entrambi i gruppi. L'inducibilità dell'aritmia e l'aberranza in tachicardia non è risultata significativamente influenzata dal DEX. Il fenomeno di jump è stato registrato più frequentemente nel gruppo DEX (86,4% vs 46,7%; p=0.004) La durata media della procedura non differiva tra i due gruppi. Tutti i pazienti sono stati dimessi nella stessa giornata dopo 3 ore di osservazione.

Conclusioni. L'impiego di Dexemedetomidina a basso dosaggio si è rivelato efficace nel migliorare il comfort periprocedurale del paziente, senza alterare l'inducibilità delle aritmie né i principali parametri elettrofisiologici.

	DEX n=13	NON DEX n=15	p
Sesso (femmine)	9 (69,2%)	9 (60%)	NS
Età (anni)	54 ± 11,8	59 ± 14,4	NS
BMI	25,84 ± 6,5	27,5 ± 5,3	NS
Insorgenza di PAS <90mmHg	1 (7,7%)	0 (0%)	NS
Insorgenza di desaturazione	0 (0%)	0 (0%)	NS
Ciclo basale (ms)	838 ± 164	838 ± 164	NS
AH basale (ms)	73 ± 16	90 ± 22	NS
PW retrogrado (ms)	393 ± 62	359 ± 87	NS
PW anterogrado (ms)	353 ± 66	355± 83	NS
Refrattarietà atrio sinistro	237 ± 34	229 ± 17	NS
Refrattarietà nodo AV retrograda	229 ± 44	262 ± 75	NS
Refrattarietà nodo AV anterograda	284 ± 84	269 ± 77	NS
Battiti echo	2 (15,4%)	7 (46,7%)	NS
Jump	11 (84,6%)	7 (46,7%)	0,04
A1H1 (ms)	144 ± 41	152 ± 72	NS
A2H2 (ms)	265 ± 76	251 ± 80	NS
Induzione tachicardia	11 (84,6%)	14 (93,3%)	NS
Singolo extrastimolo atriale (S1600 S2- S1400 S2)	8 (61,5%)	7 (46,7%)	NS
Doppio extrastimolo atriale (S1 600 S2S3- S1 400 S2S3)	1 (7,7%)	4 (26,7%)	NS
Tachicardia non indotta	2 (15,4%)	1 (6,7%)	NS
Isoproterenolo per induzione tachicardia	13 (100%)	14 (93,3%)	NS
Ciclo in isoproterenolo (ms)	532 ± 118	592 ± 132	NS
AH in isoproterenolo (ms)	61 ± 9	65 ± 9	NS
AVNRT (slow-fast)	10 (76,9%)	11 (73,3%)	NS
AVNRT (fast-slow)	0 (0%)	0 (0%)	NS
AVRT	0 (0%)	2 (13,3%)	NS
TA	1 (7,7%)	1 (6,67%)	NS
Ciclo in tachicardia	346 ± 66	362 ± 86	NS
Aberranza in tachicardia	2 (15,4%)	4 (26,7%)	NS
Durata procedura (minuti)	125 ± 25	118 ± 51	NS
Tempo procedura-dimissione (ore)	3 ± 0,96	3 ± 0,96	NS

Tabella 1. Distribuzione delle caratteristiche demografiche, parametri emodinamici e respiratori, risultati dello studio elettrofisiologico nei due gruppi.

A114: THE CLINICAL IMPACT OF IMPLANTABLE LOOP RECORDER IN CHANGING MEDICAL DECISION: A SINGLE CENTER EXPERIENCE

Cristiano Salvatore Zaccaria (a), Andrea Bernardini (a), Margherita Padeletti (a), Alessandro Paoletti Perini (a), Davide Ciliberti (a), Massimo Milli (a), Andrea Giomi (a)
(a) OSPEDALE DI SANTA MARIA NUOVA

Background. Implantable Loop Recorder (ILR) has a wide spectrum of indications for monitoring patients in different clinical settings. The majority of the studies focus on a single indication without comprehensively evaluating the clinical impact of ILR. This study aims to retrospectively review a single experience regarding the clinical impact of ILR.

Methods. Patients were enrolled from March 2015 to April 2023 due to: syncope of unknown etiology, embolic stroke of undetermined source (ESUS), palpitations, monitoring of arrhythmias in Brugada syndrome (BrS), and following a pulmonary vein isolation (PVI). A change in the clinical course (cardiac implantable electrical devices (CIEDs) implantation, start of anticoagulation therapy, execution of an electrophysiologic study, ablation for tachyarrhythmias or PVI ablation) due to an ILR finding was considered as the primary endpoint. An unexpected result was defined as a different clinical finding from the expected for the cause of ILR implantation (i.e. the finding of an atrioventricular block in a patient implanted for ESUS).

Results. 130 patients of which 58 (44%) were females with a mean age of 58 ± 6 years were enrolled. The indication for implant resulted to be ESUS (25/130, 19%), syncope (37/130, 29%), palpitations (18/130 14%), BrS (24/130 28%), or after PVI follow-up (25/130 20%). A change in clinical course was reached in 44 (33%) patients after 12 ± 8 months of follow-up. Ten (8%) patients had a double event. The change of the clinical course was more frequent in female sex than in males (26/58 [45%] vs. 18/45 [25%] patients, p=0.025). In patients with syncope, a CIED was implanted in 7 (24%) patients but interestingly 7 tachyarrhythmias events (5 AF and 2 SVT) were incidentally detected. In the stroke patients group, 6 (24%) started anticoagulation therapy after AF detection, and 3 (12%) CIEDs were implanted due to bradyarrhythmia. ILR allowed the diagnosis of tachyarrhythmia in 4 (22%) patients implanted for palpitation, in particular, arrhythmias found resulted in 3 SVT and 1 AF; all these 3 patients underwent EP ablation. In BrS patients two (8%) implanted CIEDs for sustained ventricular tachycardias and 1 implanted a leadless PM for nocturnal sinus pause. In the syncope and ESUS group, no difference between expected diagnosis and unexpected events was found (syncope 7/38 [18%] vs. 9/38 [24%], p=0.32; ESUS 3/25 [12%] vs. 6/25 [24%], p=0.55).

Conclusions. ILR impacted on clinical pathway in 33% of patients during 12 ± 8 months of follow-up. Despite the reason for its implantation, it remains a useful tool for diagnosing other arrhythmias and the consequent changing of therapeutical approach. ILR had more impact in changing the clinical course in females than in males.

A115: ELETTROGRAMMA E MAPPAGGIO ELETTROANATOMICO: SEGNALI CONTRADDITTORI DI VIA ACCESSORIA. UN CASE REPORT.

Luca Zanarelli (a), Andrea Marrone (a), Ennio Scollo (a), Francesco Vitali (a), Michele Malagù (a), Matteo Bertini (a)
(a) OSPEDALE UNIVERSITARIO DI FERRARA

Background. Raramente le vie anomale mostrano segnali contraddittori agli elettrogrammi e al mappaggio elettroanatomico. Un incompleto studio elettrofisiologico potrebbe condurre a precipitose conclusioni sulla sede anatomica della via anomala. Pochi casi in letteratura testimoniano un elettrogramma da via anomala con segnale ad andamento opposto alla sua reale posizione al mappaggio elettroanatomico.
Caso clinico. In questo report proponiamo il caso di una donna di 28 anni, con nota Sindrome di Wolf-Parkinson-White (WPW) per cui, 10 anni fa, veniva sottoposta ad ablazione di via accessoria laterale sinistra presso un altro centro. Dopo 2 anni di benessere la paziente ricominciava a lamentare episodi di cardiopalmo di alcuni minuti, con cadenza mensile. Alla luce della persistenza dei sintomi si sottoponeva la paziente a nuova procedura di ablazione, nel sospetto di tachicardia da rientro atrio-ventricolare (AVRT). All'elettrocardiogramma (ECG) si evidenziava un ritmo sinusale a 77 bpm, con segni di pre-eccitazione ventricolare sulle derivazioni precordiali da V3 a V6, con presenza di onda delta e PR breve. Allo studio elettrofisiologico, dopo innesco dell'aritmia, il segnale risultava compatibile con via accessoria destra: evidenziando, sul catetere decapolare del seno coronarico (CS), un segnale ventricolare seguito dal segnale atriale decorrente dal dipolo CS 9,10, prossimale all'atrio destro, al dipolo CS 1,2, maggiormente distale, che esplora le sezioni di sinistra. Il mappaggio tramite catetere mappante/ablatore in atrio destro e atrio sinistro ha successivamente permesso di evidenziare la via accessoria a livello dell'atrio di sinistra. Tale contraddizione può essere stata generata dalla presenza di una cicatrice tissutale dovuta alla precedente procedura di ablazione. L'emissione di radiofrequenze sulla via accessoria sulle sezioni di sinistra ha reso l'aritmia non più inducibile, con scomparsa dei segni di pre-eccitazione ventricolare e retrograda e successivo benessere per la paziente.
Discussione. Nei pazienti che devono essere sottoposti ad una seconda procedura di ablazione i normali riferimenti dello studio elettrofisiologico possono venire meno. In particolare precedenti ablazioni possono creare esiti cicatriziali in cui vie anomale determinano segnali fuorvianti a livello del catetere in seno coronarico (CS), che non rispettano la reale anatomia della via anomala. Tali casi sono rari e scarsamente descritti in letteratura. Pertanto è importante procedere ad un completo mappaggio elettroanatomico, tramite gli appositi cateteri, anche nelle sezioni di sinistra, per individuare la reale posizione della via anomala, non soffermandosi esclusivamente sulle prime informazioni provenienti dai segnali dei cateteri in CS e seguendo i corretti protocolli diagnostici e terapeutici dell'elettrofisiologia interveniva.

A116: UN FENOTIPO "PARTICOLARE" PER LA MUTAZIONE DI SCN5A

Chiara Bianchi (a), Giulia Passarini (a), Martina Vitali (a)
(a) U.O. CARDIOLOGIA, UNIVERSITÀ DEGLI STUDI DI FERRARA

Una paziente di 25 anni manifesta un episodio di perdita di coscienza e di polso con successiva ripresa spontanea di una frequenza cardiaca marcatamente bradicardica (circa 33-34 bpm). La paziente è in buona salute, fa attività sportiva a livello agonistico e ha già avuto un episodio simile circa due anni fa. Il suo elettrocardiogramma mostra un blocco atrioventricolare di primo grado (intervallo PR: 280 ms), un blocco di branca destra completo (QRS: 160 ms), l'intervallo QT è nella norma e non vi è evidenza di pattern Brugada. L'ecografia transtoracica e la risonanza magnetica cardiaca risultano prive di anomalie strutturali. La madre della paziente è portatrice di una mutazione del gene SCN5A e ha subìto un impianto di pacemaker in giovane età. Anche la paziente presenta la stessa mutazione della madre. Il quadro elettrocardiografico, l'assenza di una cardiopatia strutturale e la storia familiare depongono per una sincope cardiogena da blocco atrioventricolare parossistico provocata da un disturbo "atipico" del sistema di conduzione cardiaco associato alla mutazione del gene SCN5A, chiamato anche disturbo progressivo familiare della conduzione cardiaca, in cui la conduzione cardiaca viene gradualmente ostacolata nel tempo dalla fibrosi progressiva del sistema His-Purkinje. Si manifesta all'ECG con prolungamento crescente dell'onda P, dell'intervallo PR e del segmento QRS esitando talora in blocchi di branca destra o sinistra e/o blocchi atrioventricolari ingravescenti fino al blocco completo. È una sindrome tipicamente associata a mutazioni "loss of function" del gene SCN5A. Può svilupparsi in alternativa, oppure associarsi, agli altri fenotipi clinici legati a differenti mutazioni di SCN5A come sindrome di Brugada, sindrome del QT lungo, fibrillazione atriale idiopatica, patologia del nodo del seno e cardiomiopatia dilatativa. La paziente è stata trattata mediante l'impianto di un pacemaker bicamerale definitivo.

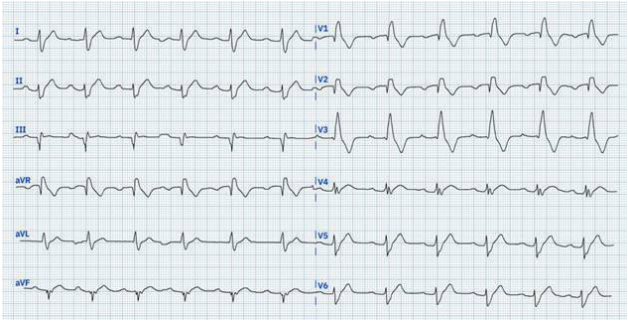

A117: ABLAZIONE EPICARDICA DI RVOT PER IL TRATTAMENTO DI TACHICARDIE VENTRICOLARI IN UN PAZIENTE CON SINDROME DI BRUGADA

Francesca Campanelli (a, b), Leonardo D'Angelo (a, b), Lara Luciani (a, b), Yari Valeri (a, b), Giovanni Volpato (a, b), Paolo Compagnucci (a, b), Quintino Parisi (b), Laura Cipolletta (b), Michela Casella (a, b), Dello Russo Antonio (a, b)
(a) DIPARTIMENTO DI SCIENZE BIOMEDICHE E SANITÀ PUBBLICA, UNIVERSITÀ POLITECNICA DELLE MARCHE, ANCONA, ITALIA; (b) CLINICA DI CARDIOLOGIA E ARITMOLOGIA, AZIENDA OSPEDALIERO UNIVERSITARIA DELLE MARCHE, ANCONA, ITALIA

Background. La Sindrome di Brugada (Br) è una malattia ereditaria caratterizzata da un aumentato rischio di morte cardiaca improvvisa (MCI). Le opzioni terapeutiche di questi pazienti sono limitate all'impianto del defibrillatore o alla terapia farmacologica con chinidina; tuttavia l'ablazione transcatetere (ATC) del substrato aritmico è stata recentemente introdotta come possibile opzione terapeutica con l'ambizione di avere un fine curativo.
Caso clinico. Presentiamo il caso di un ragazzo di 24 anni con storia familiare per morte cardiaca improvvisa e familiarità paterna per sindrome di Br. La sua storia clinica cardiologica esordisce nel 2016 con episodi di cardiopalmo e lipotimia durante esercizio fisico e riscontro di fibrillazione atriale ad elevata risposta ventricolare per cui è stato sottoposto a procedura di crioablazione con isolamento delle vene polmonari. All'ECG il paziente presenta un pattern Br tipo 1 spontaneo e al test genetico risulta portatore di una mutazione patogenetica in eterozigosi del gene SNC5A. Alla luce dei risultati del test genetico viene sottoposto a gennaio 2018 ad uno studio elettrofisiologico con stimolazione ventricolare programmata (SVP) risultato negativo nell'induzione di aritmie ventricolari sostenute; tuttavia la storia familiare e la sintomatologia sospetta (cardiopalmo e lipotimie) portano alla decisione di impiantare un S-ICD. Durante il follow-up si registrano due interventi dell'S-ICD su TVS sintomatiche per cardiopalmo e lipotimia ma ben tollerate emodinamicamente e numerosi episodi di carica del condensatore su eventi inappropriati (tachicardia sinusale) nonostante il tentativo di ottimizzazione dei parametri elettrici del device. Alla luce di questi eventi viene proposta procedura di ATC.
Materiali e metodi. La procedura è stata condotta in anestesia generale, per l'accesso allo spazio epicardico è stato utilizzato un approccio percutaneo mediante tecnica di Sosa. La ricostruzione del substrato epicardico è stata eseguita mediante sistema di mappaggio CARTO3 version7 utilizzando un catetere ablatore SmartTouch e un catetere mappante multipolare Pentaray. La mappa epicardica dei potenziali tardivi ha mostrato la presenza di un'area di potenziali pluriframmentati in corrispondenza della regione basale anteriore del tratto di efflusso ventricolare destro. Successivamente è stata somministrata Flecainide ev al dosaggio di 2 mg/kg in 15 minuti assistendo ad un aumento dell'estensione dell'area patologica. La SVP non ha indotto aritmie ventricolari sostenute per cui si è proceduto all'ATC del substrato aritmico. Per una maggiore sicurezza è stata eseguita una coroTC prima della procedura ablativa, questo ha permesso di mergere le immagini radiologiche del decorso delle coronarie con la mappa elettroanatomica per evitare possibili complicanze a carico dei vasi epicardici. Alla dimissione non vi era più evidenza di pattern Br all'ECG.
Discussione. A tre mesi dalla procedura di ATC il paziente è stato sottoposto a test alla flecainide risultato negativo nell'induzione farmacologica di pattern Br e a più di un anno dalla procedura dall'home monitoring non sono state registrate recidive aritmiche.

A118: RUOLO DELL'ABLAZIONE TRANSCATETERE NELLE CARDIOPATIE A FENOTIPO ARITMICO - UN CASO DI CARDIOPATIA ARITMOGENA DEL VENTRICOLO DESTRO SOTTOPOSTO A DUPLICE ABLAZIONE EPICARDICA

Francesca Campanelli (a, b), Leonardo D'Angelo (a, b), Lara Luciani (a, b), Yari Valeri (a, b), Giovanni Volpato (a, b), Paolo Compagnucci (a, b), Quintino Parisi (a), Laura Cipolletta (a), Michela Casella (a, b), Antonio Dello Russo (a, b)
(a) CLINICA DI CARDIOLOGIA E ARITMOLOGIA, AZIENDA OSPEDALIERO UNIVERSITARIA DELLE MARCHE, ANCONA, ITALIA; (b) DIPARTIMENTO DI SCIENZE BIOMEDICHE E SANITÀ PUBBLICA, UNIVERSITÀ POLITECNICA DELLE MARCHE, ANCONA, ITALIA

Introduzione. Presentiamo il caso di un ragazzo di 26 anni ex sportivo con diagnosi di cardiopatia aritmogena del ventricolo destro (ARVC). Il

paziente riferisce nessuno dei principali fattori di rischio cardiovascolari e nega familiarità per morte cardiaca improvvisa. Al test genetico sono state identificate due mutazioni patogenetiche in eterozigosi di TMEM43 e TNNI3, le stesse riscontrate poi nel padre del paziente. Nel 2018 è stato sottoposto ad una procedura di ablazione epicardica del substrato aritmico dei potenziali tardivi in corrispondenza della porzione basale della parete libera del RV e successivamente, nel 2021, è stato impiantato un S-ICD per recidiva aritmica.
Presentazione. Il paziente si presenta alla nostra attenzione in seguito ad una nuova recidiva aritmica quando, a febbraio 2023, accede in pronto soccorso per shock appropriato dell'S-ICD su una tachicardia ventricolare sostenuta (TVS) e la valutazione aritmologica che seguiva l'evento poneva indicazione ad una nuova procedura di ablazione dell'aritmia ventricolare.
Materiali e metodi. La procedura è stata condotta in anestesia generale previa somministrazione di profilassi antibiotica con Teicoplanina. A causa dell'importante tessuto sottocutaneo del paziente, la tecnica percutanea di Sosa si è rivelata inefficace nel guadagnare l'accesso allo spazio epicardico, ragion per cui si è optato per un approccio chirurgico. Con l'ausilio del cardiochirurgo è stata confezionata una finestra di accesso che ha permesso la puntura dei foglietti pericardici e l'avanzamento del filo guida. Sono stati utilizzati il sistema di mappaggio CARTO e il catetere mappante multipolare Octarey. Il mappaggio elettroanatomico epicardico ha mostrato la presenza di un'area di bassi potenziali e potenziali tardivi pluriframmentati in corrispondenza della parete libera medio-basale RV e la presenza di voltaggi epicardici sani con una demarcazione quasi netta in corrispondenza del LV a dimostrare in questo caso l'esclusivo interessamento del RV. Si è poi passati all'approccio endocardico dove è stata riscontrata un'area di bassi potenziali e potenziali tardivi frammentati a livello della parete libera medio-basale del RV con specularità rispetto al mappaggio epicardico. Successivamente abbiamo fatto una stimolazione ventricolare programmata anche in corso di stimolo adrenergico (isoprotenerolo) senza però ottenere l'induzione di aritmie ventricolari sostenute; per tale motivo è stata eseguita l'ablazione del substrato patologico ottenendo l'abbattimento dei potenziali tardivi frammentati sia sul versante epicardico che endocardico. La procedura si è conclusa senza il riscontro di complicanze e il paziente ha proseguito la degenza in UTIC. Ad oggi non sono state riscontrate recidive aritmiche e il paziente si presenta asintomatico e in buone condizioni cliniche.
Discussione. La peculiarità di questo caso è che si tratta di una seconda procedura di ablazione epicardica, il comportamento clinico e fisiopatologico di queste forme di cardiomiopatia fa si che lo scopo delle procedure ablative non sia quello curativo ma piuttosto palliativo dove l'avanzamento tecnologico e l'approccio combinato endocardico ed epicardico si è dimostrato, come riportato in letteratura, maggiormente efficace nel prolungare il tempo libero da recidive aritmiche e nel ridurre il burden di TV.

A119: ABLAZIONE TRANSCATETERE DI TACHICARDIA DA RIENTRO ATRIOVENTRICOLARE IN GIOVANE SPORTIVO CON FASCIO ACCESSORIO EPICARDICO: ESPERIENZA CON IL NUOVO CATETERE TACTIFLEX

Francesco Cardinali (a, b), Yari Valeri (a, b), Giovanni Volpato (a, b), Paolo Compagnucci (a, b), Laura Cipolletta (b), Quintino Parisi (b), Agostino Misiani (b), Michela Casella (a), Antonio Dello Russo (a, b)
(a) UNIVERSITÀ POLITECNICA DELLE MARCHE, ANCONA; (b) CLINICA DI CARDIOLOGIA E ARITMOLOGIA, OSPEDALI RIUNITI, ANCONA

Premessa. La sindrome di Wolf Parkinson White è un disturbo congenito del sistema di conduzione elettrico del cuore, caratterizzato dalla presenza di uno o più fasci atrioventricolari accessori responsabili di tachicardie parossistiche. L'ablazione con radiofrequenza è la procedura di elezione per i pazienti con sintomi ricorrenti ed invalidanti, scarsamente responsivi alla terapia medica così come per i pazienti con vie accessorie ad alto rischio che vorrebbero praticare sport a livello agonistico.
Obiettivo. Questo studio è mirato alla descrizione delle caratteristiche elettrofisiologiche e degli esiti di una rara ablazione transcatetere di tachicardia sopraventricolare in un giovane paziente sportivo affetto da sindrome di WPW con una via accessoria epicardica per mezzo del nuovo catetere Tactiflex.
Materiali e metodi. "N/A".
Risultati. Un atleta agonista di 13 anni con anamnesi di tachicardie sopra-ventricolari da sforzo, recidivanti e sintomatiche per cardiopalmo tachicardico, è stato ricoverato per eseguire uno studio elettrofisiologico. Durante la procedura veniva indotta una tachicardia a QRS stretto suggestiva di un rientro atrioventricolare ortodromico; il mappaggio elettro-anatomico mostrava VA fuso a livello dell'anello mitralico anterolaterale, in regioni diverse durante stimolazione ventricolare retrograda e durante tachicardia, come da possibile componente accessoria epicardica. Abbiamo dunque erogato impulsi di radiofrequenza con il catetere Tacticath a livello dell'annulus mitralico anterolaterale e del seno coronarico distale, ottenendo la non inducibilità dell'aritmia. Ciò nonostante, nei giorni successivi si sono verificati nuovi episodi di tachicardia, motivo per cui abbiamo optato per un secondo SEF, utilizzando questa volta il catetere TactiFlex, che permette erogazioni "high-power". Successivamente all'erogazione di polsi di radiofrequenza "high-power" sia a livello dell'annulus mitralico anterolaterale che nel seno coronarico distale, veniva registrata dissociazione ventricolo-atriale durante stimolazione ventricolare già con ciclo di 600ms. Durante stimolazione ventricolare programmata non risultava più inducibile alcun tipo di tachiaritmia, sia al basale che durante infusione di isoprotenerolo ad alte dosi e durante wash-out dallo stesso. In un follow-up di 12 mesi non è stata più registrata alcuna tachicardia parossistica sopra-ventricolare ed il paziente non ha più lamentato episodi di cardiopalmo durante lo sforzo.
Conclusioni. L'ablazione attraverso il seno coronarico con il catetere Tactiflex high-power-short-duration appare sicura ed efficace nel trattamento della tachicardia sopra-ventricolare nei pazienti con sindrome di WPW causata da vie accessorie epicardiche.

A120: VALUTAZIONE DEL RISCHIO ARITMICO IN UNA PAZIENTE IN GRAVIDANZA CON SINDROME DEL QT LUNGO: UN CASO DI APPLICAZIONE DEL DEFIBRILLATORE INDOSSABILE

Paolo Basile (a), Maria Cristina Carella (a), Riccardo Memeo (a), Michele Luca Dadamo (a), Nicoletta Resta (b), Ettore Cicinelli (c), Antonella Vimercati (c), Andrea Igoren Guaricci (a), Marco Matteo Ciccone (a), Cinzia Forleo (a)
(a) CARDIOVASCULAR DISEASE SECTION, INTERDISCIPLINARY DEPARTMENT OF MEDICINE (DIM), UNIVERSITY OF BARI ALDO MORO, UNIVERSITY HOSPITAL CONSORTIUM POLYCLINIC OF BARI, BARI; (b) MEDICAL GENETICS UNIT, DEPARTMENT OF PRECISION AND REGENERATIVE MEDICINE AND IONIAN AREA (DIMEPRE-J), UNIVERSITY OF BARI ALDO MORO, UNIVERSITY HOSPITAL CONSORTIUM POLYCLINIC OF BARI, BARI; (c) UNIT OF OBSTETRICS AND GYNAECOLOGY, DEPARTMENT OF BIOMEDICAL SCIENCES AND HUMAN ONCOLOGY, UNIVERSITY OF BARI ALDO MORO, UNIVERSITY HOSPITAL CONSORTIUM, POLYCLINIC OF BARI, BARI

Introduzione. La sindrome del QT lungo (LQTS) è una rara canalopatia cardiaca caratterizzata da un elevato rischio di aritmie letali. Attualmente poche sono le evidenze disponibili in letteratura sulla gestione della gravidanza e del periodo post-partum. Le 40 settimane successive al parto, sono caratterizzate da una maggiore vulnerabilità agli eventi aritmici, soprattutto nelle portatrici della variante LQT2, ma non trascurabile anche per le altre varianti. Pertanto, è necessaria un'adeguata prevenzione, soprattutto in presenza di alcune caratteristiche.
Presentazione del caso. Una donna primigravida di 31 anni alla 36a settimana di gravidanza è stata indirizzata presso il nostro Centro per lo screening della LQTS. La paziente aveva una storia familiare di LQTS (madre e fratello) e di sindrome di Brugada (cugino). L'ECG a 12 derivazioni mostrava un allungamento dell'intervallo QT (QT corretto: 508 msec), mentre l'ecocardiogramma transtoracico risultava nella norma. La paziente ha riferito sporadici episodi di cardiopalmo a riposo e il successivo ECG Holter delle 24 ore ha rivelato un carico molto elevato di aritmie ventricolari polimorfe, con circa 16 mila extrasistoli ventricolari e una tachicardia ventricolare non sostenuta. Pertanto, a causa dell'alto rischio di eventi aritmici pericolosi per la vita della paziente, è stato iniziato il trattamento con metoprololo 25 mg o.d. (betabloccante selettivo con i minori effetti collaterali possibili sul feto) ed è stato fornito un defibrillatore indossabile con monitoraggio remoto. Dopo 3 settimane, è stato eseguito un parto cesareo in analgesia epidurale, gestito da un'équipe comprendente cardiologo, ginecologo, ostetrica e anestesista, in stretto monitoraggio cardiaco. Non si sono verificate complicanze materne o nel neonato, come ipoglicemia o bradicardia. Il defibrillatore indossabile è stato mantenuto anche nel periodo post-partum con una compliance, però, non ottimale in seguito alla difficoltà nell'indossare il dispositivo durante l'allattamento. Dopo tale periodo, la paziente ha iniziato l'assunzione di nadololo con ottima risposta terapeutica.
Discussione e Conclusioni. Nelle pazienti con LQTS a rischio aritmico intermedio-alto in gravidanza, i beta-bloccanti rappresentano l'opzione terapeutica di prima linea, ma non sono in grado di interrompere le aritmie letali in ambito extraospedaliero. Inoltre, bisognerebbe prediligere i betabloccanti non selettivi come nadololo e propranololo, per i quali sono noti i frequenti effetti avversi sul feto, come le restrizioni di crescita, oligoidramnios, ipoglicemia, bradicardia. Il defibrillatore cardiaco impiantabile non è la scelta migliore, a causa delle problematiche legate all'esposizione alle radiazioni e all'anestesia durante la gravidanza. Inoltre, in letteratura sono state riportate trombosi e infezioni associate all'elettrocatetere durante la gravidanza. Il defibrillatore indossabile è l'opzione ideale in questi casi. Si tratta di un dispositivo esterno adatto a periodi transitori ad alto rischio aritmico. Inoltre, consente un monitoraggio remoto delle aritmie che può aiutare i medici a guidare il follow-up e la gestione terapeutica. Uno svantaggio è la necessità di una continua compliance della paziente. Infine, in presenza di queste rare sindromi cardiache è consigliata la presenza di un'équipe cardiaca in gravidanza, dal momento che, lo stress emotivo derivante, può essere un forte trigger aritmico.

A121: ELIGIBILITY OF SUBCUTANEOUS IMPLANTABLE DEFIBRILLATOR OF PATIENTS UNDERGOING TRANSVENOUS IMPLANTABLE CARDIOVERTER-DEFIBRILLATOR EXTRACTION

Andrea Dell'Aquila (a), Angelica Fundaliotis (a), Marina Moretti (a), Edoardo Cantù (a, b), Francesca Filippelli (a), Antonino Pitì (a), Gianmarco Arabia (b), Antonio Curnis (b), Luca Bontempi (a, b)

(a) CARDIAC ELECTROPHYSIOLOGY AND ELECTROSTIMULATION UNIT, CARDIOLOGY DEPT. - ASST BERGAMO EST, BOLOGNINI HOSPITAL OF SERIATE; (b) UNIT OF CARDIAC ELECTROPHYSIOLOGY AND ELECTROSTIMULATION, INSTITUTE OF CARDIOLOGY - ASST SPEDALI CIVILI HOSPITAL OF BRESCIA AND UNIVERSITY OF BRESCIA

Aims. The subcutaneous implantable cardioverter defibrillator (S-ICD) (Boston Scientific Inc., Natick, MA, USA) does not require the insertion of any elements into the cardiovascular system and is an effective alternative to the transvenous ICD for patients not requiring pacing[1,2,3]. The low systemic infection risk of the S-ICD could allow the early reimplantation in pts requiring transvenous lead extraction (TLE) for ICD infection[2,3]. Before S-ICD implantation, the adequacy of sensing is required to be verified through surface electrocardiogram (ECG) screening based on a dedicated ECG morphology tool or an automatic screening tool[4]. In patients undergoing S-ICD implantation at the same extraction procedure of the previous ICD, screening should be performed in advance to allow the planning of the intervention. As possible mismatches between the pre-extraction and post-extraction screening could have a potential impact on the selection of patients suitable for S-ICD, and consequently on detection capability of the implanted S-ICD, the aim of this study is to compare the results of the screening procedure performed before and after the procedure in a population of consecutive pts undergoing transvenous ICD extraction.

Methods. Consecutive ICD patients undergoing TLE at a single center were included. The TLE procedures were performed in accordance with the clinical practice of the center. All patients underwent the automated screening protocol by means of the Model 3120 Programmer (Boston Scientific, Natick, MA). The screening was performed in both supine and standing positions, and it was carried out during inhibited ventricular pacing. A patient was judged suitable for S-ICD if at least one sensing vector passed in both supine and standing positions without changes in the R-wave axis. We performed the screening 1 day before and the day after the TLE and compared the results.

Results. A total of 55 procedures were performed within the observation period in patients implanted with single- or dual-chamber ICDs (n=33) and with cardiac resynchronization therapy (CRT) ICDs (n=22). In the overall group, at least one suitable vector in both postures was identified in 45 (82%) patients before the procedure and in 41 (75%) patients after the TLE procedure. The primary vector most frequently passed the test.

Conclusions. We showed a high rate of S-ICD eligibility in patients who underwent transvenous ICD extraction, in particular in those with no CRT indications. The results obtained at two screening sessions, before and after the extraction procedure, were largely equivalent. Thus, if the decision was considered to switch from a transvenous to a S-ICD, the S-ICD eligibility could be immediately evaluated and there implantation could be included in the same procedure

References

Zeppenfeld K, et al. 2022 ESC Guidelines for the management of patients with ventricular arrhythmias and the prevention of sudden cardiac death. Eur Heart J. 2022;43:3997-4126.
Kusumoto FM, et al. 2017 HRS expert consensus statement on cardiovascular implantable electronic device lead management and extraction. Heart Rhythm. 2017;14:e503-e551.
Knops RE, et al. N Engl J Med. 2020;383:526-536.
Francia P, et al. J Interv Card Electrophysiol. 2018;52:61-67.

A122: STRATIFICAZIONE POST-HOC DEL RISCHIO DI INFEZIONE IN PAZIENTI ESTRATTI

Domenico Maria Carretta (a), Alessia Dentico (a), Alessandra Ferrieri (a), Teresa Altieri (a), Luca Benedetto (a), Francesca Maria Carretta (b), Carlo D'Agostino (a)
(a) A.O.U.C. POLICLINICO DI BARI; (b) UNIVERSITÀ CAMPUS BIO-MEDICO DI ROMA

Introduzione. L'infezione rappresenta una delle complicanze più diffuse e temute delle procedure di impianto di CIED. Il più delle volte questa potrebbe evolvere persino in endocardite su elettrocateteri o shock settico, a tal punto che l'unica terapia salvavita diventa l'estrazione transvenosa di elettrocateteri. Per questo spesso ci si pone il problema di prevenire tali quadri infettivi realizzando una valutazione del rischio infettivo prima dell'impianto così da non incorrere nel tempo in queste complicanze. Questo studio si pone l'obiettivo di stratificare post-hoc il rischio infettivo dei pazienti estratti nel nostro centro così da avvalorare l'introduzione e l'utilizzo di score per la valutazione pre-impianto del rischio infettivo.

Materiali e metodi. Sono stati valutati 163 pazienti sottoposti ad estrazione transvenosa di elettrocateteri, di cui 130 per infezione di tasca/endocardite su elettrocateteri o sepsi. In questi pazienti è stata fatta una valutazione post-hoc del rischio di infezione secondo lo score UPCM, score ideato dall'Università di Pittsburgh. Un valore di score maggiore o uguale a 7 individua i pazienti maggiormente predisposti a sviluppare nel tempo un'infezione. Questo score tiene conto di fattori di rischio come: reintervento precoce, tipo di dispositivo impiantato (CRTD vs ICD/PM), presenza di più di 2 cateteri in loco, sostituzione o revisione del dispositivo, utilizzo di pacing temporaneo, assunzione di corticosteroidi o anticoagulanti orali, funzionalità renale, febbre nelle 24 ore prima dell'impianto, presenza di diabete o scompenso cardiaco, genere maschile. Particolare attenzione abbiamo poi rivolto ai pazienti sottoposti a procedura di upgrade o a coloro che hanno subìto per due volte una procedura di estrazione.

Risultati. Dei 130 pazienti del nostro centro sottoposti ad estrazione per infezione, 112 hanno uno score maggiore o uguale a 7; 18 sono invece coloro con uno score minore di 7. Il valore medio è risultato essere 22,9.

Conclusioni. L'individuazione di uno score valutabile prima della procedura di impianto di CIED può risultare un ottimo aiuto nell'individuazione di pazienti fragili che a lungo o breve termine potrebbero incorrere in quadri di infezione. Così facendo si potrebbero valutare ulteriori alternative all'impianto transvenoso, come ad esempio l'impianto di pacemaker leadless o ICD sottocutaneo in pazienti non PM dipendenti elegibili a ciò.

A123: POLYMORPHIC PREMATURE VENTRICULAR COMPLEXES INDUCED BY EXERCISE IN A YOUNG PATIENT WITH A RYR2 VARIANT OF UNCERTAIN SIGNIFICANCE (VUS) MUTATION: WHAT IS THE BEST DIAGNOSTIC AND THERAPEUTIC APPROACH?

Pietro Desimone (a), Sofia Del Gigante (a), Germana Panattoni (b), Leonardo Calò (b), Francesco Barillà (a), Fabiana Romeo (b), Cinzia Crescenzi (b), Annamaria Martino (b), Paolo Golia (b)
(a) UNIVERSITÀ DEGLI STUDI DI ROMA TOR VERGATA; (b) POLICLINICO CASILINO

Background. Catecholaminergic polymorphic ventricular tachycardia (CPVT) is a heritable cardiac channelopathy that predisposes individuals to sudden cardiac death. It leads to adrenergically mediated syncope or cardiac arrest due to ventricular tachyarrhythmias (VA). Dysfunction of the RYR2 gene results in abnormal Ca2+ leakage from the sarcoplasmic reticulum (SR), which can generate delayed afterdepolarizations, ultimately leading to ventricular arrhythmias. Consequently, RYR2 plays a crucial role in the pathogenesis of various cardiac arrhythmias and cardiomyopathies, including CPVT, idiopathic ventricular fibrillation (VF), atrial fibrillation (AF), and arrhythmogenic cardiomyopathy.

Case presentation. A 23-year-old male presented to our tertiary care hospital, specialized in treating patients at risk of life-threatening ventricular arrhythmias (VA), with evidence of exercise-induced polymorphic premature ventricular complexes (PVCs). His parents were blood relatives, and a significant family history of sudden cardiac death (SCD) was reported (five maternal uncles had died suddenly, and the index case's father had died at age 49 while driving). His 12-lead ECG showed normal sinus rhythm and normal depolarization/repolarization. A 24-hour Holter-ECG revealed a low PVC burden and no tachyarrhythmias. Transthoracic echocardiography (TTE) and cardiac magnetic resonance were normal. He was administered beta-blockers (nadolol 80 mg) and underwent follow-up. The genetic test performed on the index patient revealed a previously unreported variant of the RYR2 gene (heterozygous c.9598A>G, p.Asn3200Asp), classified as a variant of uncertain significance (VUS, class III) following the 2015 American College of Medical Genetics criteria. During cascade screening, the same mutation was found in the patient's sister and her son. However, a year later, the patient experienced syncope at rest, without any emotional stress prior to the event. An insertable cardiac monitor was implanted to evaluate arrhythmic burden after syncope, but since then, no other arrhythmic events have occurred.

Discussion and Conclusions. This case series reports on a rare, potentially pathogenic RYR2 variant, ambiguously classified as a VUS, identified in individuals with a family history of SCD and probable CPVT phenotypes. In our proband, although there has been no documented evidence of ventricular tachycardia during exercise or emotional stress, a CPVT diagnosis can be established based on the expert consensus statement on the diagnosis and management of patients with inherited primary arrhythmia syndromes. Our patient did not experience any new arrhythmic events after starting nadolol therapy, which is the first-line treatment for CPVT. However, the mutation identified in our patient, which is also present in other family members, remains of uncertain significance and has not been previously reported in the literature. Should it receive more attention and be considered significant? New findings demonstrate the importance of considering variable penetrance of the RYR2 mutation and the consequent heterogeneous genotype-phenotype correlation when approaching patients with similar profiles.

A124: DEFICIT DI CATTURA VENTRICOLARE IN UN PAZIENTE PACEMAKER-DIPENDENTE CAUSATO DA ENDOCARDITE SU ELETTROCATETERE DA CARDIOBACTERIUM VALVARUM

Davide Donelli (a), Valeria Dall´ Ospedale (a), Marta Zatti (b), Gianluca Gonzi (a), Antonio Crocamo (a), Daniele Sartorio (a), Giorgia Paoli (a), Giampaolo Niccoli (a), Diego Ardissino (a), Maria Francesca Notarangelo (a)
(a) DIVISIONE DI CARDIOLOGIA, AZIENDA OSPEDALIERO UNIVERSITARIA DI PARMA, PARMA, ITALIA; (b) DIVISIONE DI MALATTIE INFETTIVE, AZIENDA OSPEDALIERO UNIVERSITARIA DI PARMA, PARMA, ITALIA

Introduzione. Cardiobacterium Valvarum è un batterio HACEK estremamente raro e fino ad oggi non erano descritte infezioni di device impiantabili ad esso imputabili.

Caso clinico. Un giovane di 32 anni, sottoposto dieci anni prima a sostituzione di valvola aortica e aorta ascendente secondo Bentall, aortoplastica discendente, e impianto di pacemaker (DDD) a causa di BAV completo postoperatorio, è stato ricoverato per comparsa di episodi di dolore epigastrico associato a palpitazioni intermittenti. Il monitoraggio ECG documentava perdite di cattura ventricolare con pause fino a sei secondi. Al controllo del dispositivo si rilevava aumento di soglia ed impedenza, fino a 1953 ohm e 3,5V x 0,4 ms. Si impiantava pertanto un pacemaker temporaneo costituito da catetere a fissazione attiva per via succlavia destra collegato a un generatore esterno, e impostato in modalità di backup VVI a 40 bpm. Per escludere una frattura del catetere o un malfunzionamento dovuto a perforazione cardiaca è stata eseguita una TC torace che non ha rivelato anomalie a livello cardiaco o periprotesico aortico. Agli esami di laboratorio lieve leucocitosi e rialzo della PCR. Cause otorinolaringoiatriche di mediastinite sono state escluse con fibroscopia, RX con pasto baritato e TC testa e collo. Le emocolture sono risultate positive per Cardiobacterium Valvarum, un raro batterio HACEK, da due campioni. Questo risultato ha suggerito fortemente come possibile diagnosi un'endocardite infettiva batterica. L'ecocardiografia transesofagea ha mostrato una formazione mobile adesa al catetere ventricolare allo sbocco della vena cava superiore. Una PET con (18)F-FDG non ha mostrato aree di elevata attività metabolica. Sono stati soddisfatti i Criteri di Duke per endocardite catetere-correlata. È stata avviata terapia antibiotica con Ciprofloxacina e Ceftriaxone, poi confermata dall'antibiogramma, da proseguire per sei settimane con emocolture seriate. L'estrazione è stata eseguita con tecnica laser ad eccimeri, e un elettrodo epicardico con un generatore addominale è stato impiantato come soluzione ponte. Tale elettrodo ha necessitato di diversi aumenti dell'output prima di ottenere una cattura stabile (fino a 7,5V@1,5ms). Una volta stabilizzata la cattura ventricolare è stato rimosso il pacemaker di backup, e completato il ciclo antibiotico. Le emocolture seriate sono sempre risultate negative. Dopo sei mesi è stato configurato un pacemaker biventricolare impiantando un elettrocatetere sinistro nel seno coronarico (e destro epicardico).
Conclusioni. Questo è il primo caso descritto di endocardite infettiva causata da Cardiobacterium Valvarum determinante disfunzione del catetere e perdita di cattura.

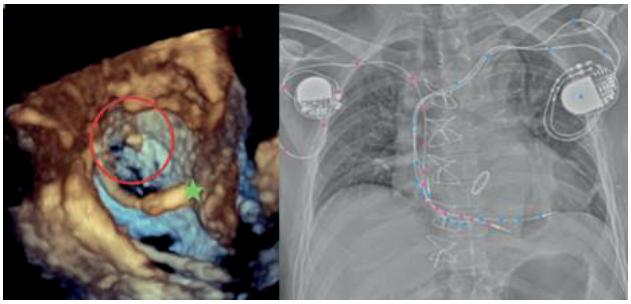

A125: SINDROME DI BRUGADA E CARDIOPATIA ISCHEMICA: UN CASE REPORT DI STORM ARITMICO IN PAZIENTE CON SINDROME DI BRUGADA IN CORSO DI SINDROME CORONARICA ACUTA

Lorenzo Fargione (a), Alessandro Guareschi (a), Guido Pasero (a), Luca Donisi (a), Filippo Toriello (b), Massimo Saviano (b), Alberto Vincenzo Pollina (b), Federica Valli (b), Stefano Carugo (a, b)
(a) DEPARTMENT OF CLINICAL SCIENCES AND COMMUNITY HEALTH, UNIVERSITY OF MILAN, ITALY; (b) DEPARTMENT OF CARDIO-THORACIC-VASCULAR DISEASES, FOUNDATION IRCCS CA' GRANDA OSPEDALE MAGGIORE POLICLINICO, ITALY

Riportiamo il caso di un uomo di 73 anni, senza precedenti cardiologici di rilievo, con plurimi fattori di rischio cardiovascolare, giunto alla nostra attenzione per uno STEMI inferiore con alternanza di fasi di blocco atrioventricolare (BAV) 2:1 e di III grado. Veniva eseguita coronarografia con riscontro di occlusione trombotica della coronaria destra medio-prossimale (lesione culprit) trattata con angioplastica primaria ed evidenza di malattia critica su ramo diagonale (D1) e arteria interventricolare anteriore (IVA) prossimale e distale. All'ingresso in Unità Coronarica (UCIC), per persistenza di BAV 2:1, veniva posizionato pacemaker (PM) temporaneo transvenoso. All'ecocardiogramma si evidenziava acinesia della parete inferiore ed infero-laterale con moderata disfunzione sistolica del ventricolo sinistro. In IV giornata di ricovero, per riscontro alla telemetria di extrasistoli ventricolari (BEV) talora condotte con bigeminismo e brevi run di tachicardia ventricolare non sostenuta (TVNS), si prescriveva terapia con magnesio-solfato, metoprololo e amiodarone endovena (ev). Si impostava, inoltre, PM in modalità di overdrive pacing con transitoria riduzione delle ectopie. Nelle successive 24 ore venivano registrati BEV sempre più precoci con sede di origine pericicatriziale, in seguito evoluti in TV polimorfe, e 4 episodi di arresto cardiocircolatorio da fibrillazione ventricolare innescate da fenomeni di R su T. In considerazione del quadro di storm aritmico, veniva modificata la terapia antiaritmica con introduzione di propranololo e lidocaina ev (al posto di metoprololo e amiodarone). Alla stabilizzazione del quadro aritmico, veniva rimosso il PM temporaneo ed introdotta mexiletina, e si è proceduto a completamento della rivascolarizzazione mediante angioplastica su IVA prossimale, IVA distale e D1. Al monitoraggio ECG prolungato in UCIC si riscontrava la comparsa di pattern Brugada di tipo 2 in corso di episodio febbrile in stato settico, regredito con la defervescenza. Durante il restante periodo di degenza, in corso di terapia con betabloccante e mexiletina, non venivano registrati ulteriori episodi aritmici ventricolari: il paziente veniva trasferito in riabilitazione e protetto dal rischio di morte improvvisa mediante posizionamento di defibrillatore indossabile. A completamento diagnostico si eseguiva, in ricovero successivo, test all'ajmalina che evidenziava la comparsa di pattern Brugada di tipo 1, permettendo la diagnosi di BrS, e si procedeva con l'impianto di defibrillatore transvenoso in prevenzione secondaria. La diagnosi di BrS permette di ipotizzare un'incrementata vulnerabilità aritmica in corso di sindrome coronarica acuta (SCA) mediata da un meccanismo per cui i BEV si instaurerebbero nel contesto di un accorciamento del periodo refrattario del potenziale d'azione, causato da alterazioni delle correnti ripolarizzanti (correnti IKs, delayed rectifiers) tipiche di questa canalopatia. Tali ectopie precoci esiterebbero in fenomeni di R su T (short coupled R-on-T extrasystole) innescando tachiaritmie ventricolari sostenute. L'instabilità aritmica instauratasi a 3 giorni dall'angioplastica primaria, in questo specifico caso, non può essere giustificata completamente solo da un meccanismo da ischemia-riperfusione. Poche sono le evidenze in letteratura in merito ad un'incrementata vulnerabilità aritmica dei pazienti con BrS affetti da SCA. Tuttavia, poco conosciamo in merito all'ottimale gestione personalizzata di queste complicanze: sarebbe da favorire una rivascolarizzazione completa? Sarebbero da prediligere farmaci attivi sulle correnti di potassio ripolarizzanti, come la chinidina? Ulteriori evidenze appaiono necessarie in questo setting clinico.

A126: DENGUE E LYME: DAL SUD EST ASIATICO ALL'ITALIA

Maria Francesca Massara (a, b), Pier Paolo Gironella (a), Leonardo Brugiatelli (b), Andrea Giovagnoli (b), Antonella Lanari (b), Martina Pergolini (b), Josephine Staine (b), Giada Refi (b), Letizia Zappelli (b), Giorgio Di Noto (b), Federico Guerra (a), Antonio Dello Russo (a)
(a) UNIVERSITÀ POLITECNICA DELLE MARCHE; (b) OSPEDALE CARLO URBANI - JESI (AN) - AST2 MARCHE

Background. La febbre Dengue (Flavivirus) e la malattia di Lyme (Borrelia burgdorferi) rappresentano rare malattie infettive tropicali e subtropicali trasmesse da vettori ematofagi (rispettivamente zanzare Aedes e zecche), estremamente rare in Italia. Nei paesi Europei entrambe costituiscono un pericolo in un'ottica di salute pubblica, dato che si manifestano soprattutto come malattie di importazione, il cui incremento è dovuto all'aumentata frequenza di spostamenti di merci e persone dai Paesi a rischio.
Case report. Uomo, originario del Bangladesh, 54 anni. Ricoverato per febbre, dispnea e dolore toracico di tipo pericarditico. Agli esami laboratoristici e strumentali riscontro di insufficienza respiratoria acuta severa secondaria a polmonite lobare inferiore sinistra e contestuale riscontro di versamento pleuro-pericardico. Negava recenti viaggi all'estero. Veniva dunque avviata terapia antibiotica endovena ad ampio spettro e terapia antinfiammatoria nel sospetto di pleuro-pericardite para-pneumonica. Restanti parametri nella norma. Durante la degenza si assisteva a progressivo miglioramento del quadro clinico con riduzione degli indici di flogosi e risoluzione dell'addensamento polmonare per cui veniva dimesso a domicilio dopo due settimane di degenza con terapia antinfiammatoria (ibuprofene e colchicina). A distanza di circa 7 giorni il paziente si ripresenta in Pronto Soccorso, lamentando recrudescenza della sintomatologia associata a profonda astenia. Al monitoraggio elettrocardiografico: riscontro di fasi di BAV 2:1, comparsa di blocco di branca destro completo, emiblocco anteriore sinistro alternato ad emiblocco posteriore sinistro, non evidenti ai precedenti tracciati elettrocardiografici. Nel corso della degenza comparsa di blocco atrioventricolare completo complicatosi con fasi di asistolia prolungate per il quale si è proceduto a posizionamento in urgenza di pacemaker temporaneo per via giugulare destra. Contestualmente si prelevavano esami ematochimici che dimostravano anemizzazione e incremento degli indici di flogosi, della troponina, creatinina, transaminasi, indici di colestasi, lattico deidrogenasi e delle lipasi come a configurare un quadro di MOF. Si escludevano patologie acute o emorragie attive mediante TC total body con mdc. Si prelevavano inoltre emocolture ed esami sierologici per escludere infezione da Trichinella, Mycoplasma, Borrelia, Dengue e altre rare patologie infettive. A causa del progressivo peggioramento clinico di procedeva a trasferimento del paziente presso centro ospedaliero di II livello. Nei giorni seguenti i risultati degli esami laboratoristici documentavano positività per IgG ed IgM per Dengue, senza tuttavia riscontro sierologico di RNA virale, e positività degli anticorpi IgG ed IgM per Borrelia Burgdorferi.
Conclusioni. In Italia l'incidenza di suddette patologie è bassa, e ancor più rara (se non aneddotica) è la loro coesistenza nel medesimo ospite. Non può essere esclusa però la co-infezione in pazienti provenienti da zone dove tali malattie sono endemiche/epidemiche. Clinicamente entrambe le patologie presentano alcune caratteristiche comuni, quali l'interessamento sistemico neurologico, articolare ma soprattutto cardiaco

con comparsa di disturbi della conduzione, che rendono ancora più difficile la diagnosi differenziale. L'aumento degli scambi internazionali di merci e turisti ha ormai cambiato anche in Italia la realtà delle malattie infettive a coinvolgimento cardiologico.

A127: SINDROME DEL QT LUNGO: DIFFERENZE TRA PAZIENTI ASINTOMATICI E SINTOMATICI

Alberto Sarti (a), Francesco Vilei (a), Renè Tezze (a), Martina Vitali (a), Marco Giardino (a), Cristina Balla (a), Michele Malagù (a), Matteo Bertini (a), Martina De Raffele (a), Francesco Vitali (a)
(a) CARDIOLOGY UNIT, AZIENDA OSPEDALIERO-UNIVERSITARIA DI FERRARA

Introduzione. La sindrome del QT lungo (SQTL) è una canalopatia caratterizzata nella maggior parte dei casi da una modalità di trasmissione autonomica dominante e legata a mutazioni (sia di tipo loss che gain of function) di geni che codificano prevalentemente per i canali del sodio e del potassio, con conseguente predisposizione allo sviluppo di aritmie ventricolari.
Obiettivi. Valutare le differenze cliniche e a livello genotipico in pazienti con diagnosi di LQTS sintomatici (pregresso arresto cardio-circolatorio o sincope) e asintomatici.
Materiali e metodi. Abbiamo analizzato retrospettivamente una coorte di 56 pazienti con diagnosi confermata di LQTS (Schwarz score ≥3.5 punti). Tutti i pazienti avevano eseguito un pannello di analisi genica di 180 geni più frequentemente coinvolti in cardiomiopatie/canalopatie. I pazienti sono stati divisi in due gruppi: sintomatici (sincope o ACC) e asintomatici. Abbiamo confrontato i due gruppi in base a criteri anamnestici, criteri clinici, criteri elettrocardiografici e genetici.
Risultati. Il 32% dei pazienti era di sesso maschile. Nei pazienti sintomatici vi era una netta prevalenza del sesso femminile (p=0,04). I pazienti asintomatici sono arrivati alla diagnosi in età più tardiva rispetto a quelli sintomatici (50±18 vs 39±17, p=0,026). I pazienti asintomatici avevano maggior riscontro di mutazione patogenetica (p=0,03) e tra questi il 77% aveva una mutazione di tipo loss of function del gene KCNQ1. Solo nei pazienti sintomatici è stato impiantato un ICD in prevenzione secondaria (p<0,001). La terapia betabloccante era altamente prevalente nei pazienti sintomatici (p=0,07), in questi pazienti il betabloccante di scelta era il propanololo.
Conclusioni. Nella nostra popolazione abbiamo osservato che gli individui di sesso maschile affetti dal LQTS sono più frequentemente asintomatici. Inoltre è più frequente identificare una mutazione chiaramente patogenetica nei pazienti asintomatici rispetto a quello sintomatici. La nostra analisi retrospettiva suggerisce come ad oggi l'analisi genetica, per quanto fondamentale, non sia ancora in grado di identificare pazienti ad elevato rischio aritmico.

A128: UN CASO DI BAV DI II GRADO TIPO 2 E BAV AVANZATO ASSOCIATO AD ABUSO CRONICO DI COCAINA TRATTATO MEDIANTE PACEMAKER LEADLESS

Lucrezia Spagnoli (a), Edoardo Cecchini (a), Fabiana Malci (a), Domenico Sergi (a), Lucy Barone (a), Francesco Barillà (a)
(a) UNIVERSITÀ DEGLI STUDI DI ROMA TOR VERGATA

Introduzione. La cocaina è una sostanza d'abuso con effetti complessi e ancora non del tutto chiariti sul sistema di conduzione del cuore. Agisce come simpaticomimetico causando principalmente tachiaritmie; tuttavia, inibendo i canali del sodio, riduce l'automatismo del nodo SA e la conduzione attraverso il nodo AV. Sono stati segnalati rari casi di blocchi della conduzione AV associati all'uso di cocaina.
Caso clinico. Paziente di 28 anni, fumatore, con storia d'abuso di sostanze stupefacenti e in particolare di cocaina. A seguito di frequenti episodi presincopali eseguiva ECG Holter delle 24 ore documentante ripetute fasi di BAV di II grado tipo Mobitz 2 e di BAV avanzato, con pause significative (>6 secondi). Il paziente veniva pertanto ricoverato presso il nostro reparto di Cardiologia per accertamenti. Al fine di escludere la presenza di sindrome da apnee ostruttive del sonno, eseguiva polisonnografia che documentava una normale attività respiratoria notturna. Veniva poi sottoposto a TC coronarica che escludeva la presenza di reperti patologici a carico del circolo coronarico. Si decideva di completare lo studio mediante RM cardiaca, che non evidenziava reperti patologici. Durante il ricovero si registravano al monitoraggio telemetrico frequenti episodi di BAV di II grado tipo Mobitz 2 e di BAV avanzato, anche sintomatici. In relazione al rischio infettivo legato alla storia di abuso di sostanze stupefacenti, alla storia di parodontopatia, alla scarsa compliance del paziente nell'effettuare eventuali profilassi antibiotiche, alla presenza di dermopigmentazione diffusa su tutto il tronco e che il paziente voleva preservare, alla pratica di sport da contatto a cui non voleva rinunciare, si decideva di optare per l'impianto di un pacemaker leadless (MICRA AV, Medtronic) in assenza di complicanze peri-procedurali.
Conclusioni. Sebbene l'abuso di cocaina sia per lo più associato a tachiaritmie, le prove raccolte attraverso casi clinici dimostrano che le bradiaritmie dovute all'uso cronico di cocaina non sono infrequenti. Il nostro caso clinico sottolinea la possibilità di questa diagnosi e riporta un caso di impianto di pacemaker leadless (PML) piuttosto che di pacemaker tradizionale in una tipologia complessa di paziente, in cui le indicazioni al PML si associano ad una migliore tollerabilità e accettazione del dispositivo da parte del paziente, con effetti benefici sulla qualità della vita.

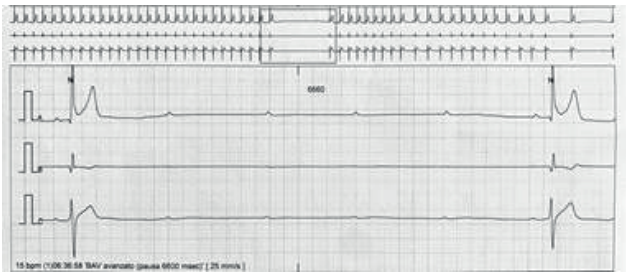

A129: SUDDEN CARDIAC ARREST IN A YOUNG PATIENT AS FIRST PRESENTIATION: A BIG PANDORÀS BOX OF DIFFERENTIAL DIAGNOSIS

Vincenzo Sucato (a), Giuseppe Bosco (a), Antonella Ortello (a), Luca Restivo (b), Rocco Giunta (b), Antonio Bracco (a), Lorenzo Tesè (b), Melania Bonocore (b), Stella Schiaccianoce (b), Giuseppina Novo (a), Carlo Cicerone (b), Alfredo Ruggero Galassi (a)
(a) DIVISION OF CARDIOLOGY, AOU POLICLINICO P. GIACCONE, DEPARTMENT OF PROMISE, UNIVERSITY OF PALERMO; (b) DIVISION OF CARDIOLOGY, AO OSPEDALI RIUNITI VILLA SOFIA-CERVELLO, PO VILLA SOFIA, PALERMO

Background. Sudden cardiac arrest (SCA) is a significant health burden in Europe, with considerable variations in rates across countries. The underlying factors contributing to these variations are multifactorial and complex. This case report highlights the challenges of diagnosis and management of a young patient with sudden cardiac arrest as first presentation.
Case report. We report the case of 25-year-old male collapsed unexpectedly whilst playing soccer. He was brought to the hospital following successful resuscitation for an out of hospital ventricular fibrillation. He had no significant family or past medical history of cardiovascular disease and was a recreational athlete, playing 5 a side soccer regularly. Furthermore, the patient declared he was an active smoker and a consumer of caffeine and tyrosine supplement. In the months leading up to his cardiac arrest, he recalled a single episode of exertional dyspnea whilst playing sports. On admission the first ECG showed sinus tachycardia, RR 'in V1, normal PR interval and QTc. Blood chemistry tests showed hypokalemia (3 mEq/L) and a slight increase of inflammation indices (0,18 mg/dl, WBC: 16000 x10^3/μ). Under these circumstances, we used the ESC algorithm for the evaluation of sudden cardiac arrest survivors. Since the patient had no ST elevation myocardial infarction (or electrical instability after CA (cardiac arrest), we performed echocardiography that revealed normal LV function with normal heart valve and, subsequently, brain and chest CT scan that didn't identify non cardiac causes of CA. Simultaneously we collected blood sample for toxicology and genetic testing. As suggested by the guidelines, we performed coronary angiography that showed unobstructed epicardial vessels and the absence of dissection or coronary anomalies.

Therefore, due to the presence, on the ECG, of RR 'complex with ST segment elevation <1 mm in V1 and V2 leads, a suspicion of Brugada syndrome was made and we performed provocative testing using oral Flecain ide that was negative. During hospitalization no major arrhythmic events were recorded. Finally, cardiovascular magnetic resonance (demonstrated a normal volume and LV ejection fraction [63%] with hypokinesia and thinning of the basal inferior l ateral segment, thickening of the epicardial adipose tissue of the lateral wall in the mid basal tract with signal reduction in the T2 STIR sequence. Moreover, CMR showed subepicardial late gadolinium enhancement (of the mid basal lateral wall. The RV was non dilated with no regional wall motion abnormalities. A diagnosis of arrhythmogenic cardiomyopathy or myocarditis was suspected, and he received a subcutaneous implantable cardiac defibrillator (S- ICD) for secondary prevention. He was discharged on beta blockers (lifestyle advice to limit his exercise intensity, and referred for genetic testing along with a recommendation for clinical screening of his family members.

Discussion. Sudden cardiac arrest is a significant health burden in Europe. Understanding the epidemiology of SCA is essential for the development and implementation of targeted prevention strategies. This case report underlines the importance of following ESC algorithm for the evaluation of sudden cardiac arrest survivors and the value of genetic testing and CMR to differential diagnosis between the different forms of structural cause of cardiac arrest. Moreover, this work emphasizes that triggers play a crucial role in sudden cardiac arrest (SCA) as they can precipitate or contribute to the occurrence of this life-threatening event. Understanding triggers is essential for identifying individuals at risk, implementing preventive measures, and improving overall outcomes.

A130: SICUREZZA ED EFFICACIA DELL'ABLAZIONE TRANS-CATETERE DELL'EXTRASISTOLIA VENTRICOLARE IDIOPATICA NELL'ATLETA VS POPOLAZIONE SEDENTARIA: ESPERIENZA DI UN SINGOLO CENTRO

Yari Valeri (a, b), Paolo Compagnucci (a, b), Giovanni Volpato (a, b), Quintino Parisi (b), Laura Cipolletta (b), Francesca Campanelli (a, b), Leonardo D'Angelo (a, b), Lara Luciani (a, b), Michela Casella (a), Antonio Dello Russo (a, b)

(a) UNIVERSITÀ POLITECNICA DELLE MARCHE, ANCONA; (b) CLINICA DI CARDIOLOGIA E ARITMOLOGIA "OSPEDALI RIUNITI", ANCONA

Introduzione. La prevalenza delle aritmie ventricolari non differisce tra atleti e individui sedentari. I giovani adulti che praticano sport agonistici, in particolare quelli con aritmie ventricolari compresa l'extrasistolia ventricolare, hanno un rischio maggiore di morte cardiaca improvvisa. Non ci sono tuttavia studi sugli esiti dell'ablazione transcatetere dell'extrasistolia ventricolare idiopatica negli atleti rispetto alla popolazione sedentaria.

Obiettivi. L'end-point primario dello studio era la riduzione post-ablazione dell'extrasistolia ventricolare nel gruppo di atleti vs. non atleti. L'end-point secondario era la riduzione post-ablazione dei PVC negli atleti agonisti vs. non agonisti. L'end-point terziari era la valutazione della ripresa dell'attività fisica e del miglioramento soggettivo dei sintomi sia negli atleti agonisti che non agonisti.

Materiali e metodi. Abbiamo selezionato i pazienti ricoverati presso il nostro centro da gennaio 2020 a ottobre 2022 con diagnosi di extrasistolia ventricolare idiopatica (con morfologia apparentemente benigna e assenza di SHD) e indicazione ad ablazione trans-catetere. Sono stati arruolati solo i pazienti che soddisfacevano i criteri di inclusione. Tutti i pazienti hanno eseguito un Holter-ECG nelle 24 ore e una visita ambulatoriale 6 mesi dopo la procedura.

Risultati. Il gruppo dei non atleti era composto da 37 pazienti (53,2 ± 11,2 anni; maschi 23, 62%), mentre il gruppo degli atleti comprendeva 42 pazienti (39 ± 12,8 anni; maschi 27, 64%). Per quanto riguarda le caratteristiche cliniche, il gruppo dei non atleti ha mostrato differenze statisticamente significative in termini di età, con un'età mediana più elevata rispetto al gruppo degli atleti. Non sono state osservate differenze significative nell'uso di farmaci antiaritmici tra i due gruppi. Una differenza statisticamente significativa è stata invece riscontrata nell'uso dei beta-bloccanti, meno frequente tra gli atleti (p<0,001). I pazienti del gruppo 2 sono stati successivamente valutati e divisi in due sottogruppi: atleti non agonisti e atleti agonisti. Il gruppo non agonista era composto da 23 pazienti (442 ± 12,5 anni; maschi 13, 57%), mentre il gruppo agonista comprendeva 19 pazienti (32,9 ± 12,9 anni; maschi 14, 74%). Come previsto, gli atleti competitivi hanno mostrato un numero maggiore di allenamenti a settimana e di ore di allenamento a settimana, statisticamente significativo, rispetto ai non competitivi (3 [IQR 2-3] vs. 4 [IQR 3-5] allenamenti a settimana e 5 [IQR 3-6] rispetto a 9 [IQR 7-12] ore settimanali). Tuttavia, non sono state osservate differenze significative nei sintomi indotti dai PVC tra gli atleti agonisti e non agonisti. La percentuale mediana di diminuzione del numero di extrasistoli ventricolari tra il monitoraggio Holter pre e post-procedura nel gruppo dei non atleti è stata di 96 (IQR 68 – 98) e di 98 nel gruppo degli atleti (IQR 92 – 99). Non è stata trovata alcuna differenza statistica (p=0,08). Considerando gli atleti, la percentuale mediana di diminuzione del numero extrasistoli ventricolari è stata di 98 (IQR 93-99) e 98 (IQR 87-99) rispettivamente nei pazienti non agonisti e agonisti. Non è stata trovata alcuna differenza statistica (p=0,42). Gran parte degli atleti non agonisti (88%) e agonisti (70%) hanno riscontrato un miglioramento dei sintomi dopo l'ablazione.

Conclusioni. L'ablazione trans-catetere si è rivelata efficace e sicura in entrambi i gruppi, riducendo i sintomi e consentendo un ritorno rapido e sicuro all'attività sportiva negli atleti.

A131: NOACS ARE ASSOCIATED WITH REDUCED MDA LEVELS AND LESS COGNITIVE IMPAIRMENT IN HYPERTENSIVE PATIENTS WITH ATRIAL FIBRILLATION

Valeria Visco (a), Francesco Loria (a), Nicola Virtuoso (b), Carmine Izzo (a), Paola Di Pietro (a), Guido Iaccarino (c), Carmine Vecchione (a), Michele Ciccarelli (a, b)

(a) DEPARTMENT OF MEDICINE, SURGERY AND DENTISTRY, UNIVERSITY OF SALERNO, SALERNO, ITALY; (b) CARDIOLOGY UNIT, UNIVERSITY HOSPITAL "SAN GIOVANNI DI DIO E RUGGI D'ARAGONA", SALERNO, ITALY; (c) DEPARTMENT OF ADVANCED BIOMEDICAL SCIENCES, FEDERICO II UNIVERSITY OF NAPLES, NAPLES, ITALY

Background. Atrial fibrillation (AF) represents one of the most subtle and frequent pathologies in elderly patients; in particular, cognitive decline closely links to AF and drastically increases mortality and hospitalization. The oral anticoagulant therapy, vitamin K antagonists (VKA) and new oral anticoagulants (NOAC), has produced a significant improvement in the outcome of patients with AF.

PURPOSE. Despite this improvement, there is still uncertainty about the effect of these drugs on cognitive performance and malondialdehyde (MDA) associated levels. For this reason, we analysed a population of hypertensive patients with AF, receiving VKA, or NOAC.

Methods. We considered 147 patients (age 70.08±1.15 years; 69.93% male), with a history of paroxysmal or permanent AF and arterial hypertension, in therapy with oral anticoagulants and no history of cerebrovascular and/or neurodegenerative diseases. In particular, we divided the population into two groups: VKA and NOAC. We administered an accurate, sensitive, and specific screening test (QMCI) for the assessment of intermediate cognitive decline (MCI), which explores spatial and temporal orientation, immediate and delayed recall, clock design, logical memory and verbal fluency in a concise time (5 min - score 0-100). Moreover, we analysed a blood sample with the MDA kit.

Results. Analysing the clinical parameters, the two groups did not differ in age (VKA 67.44 ± 2.44 vs NOAC 71.85 ± 0.97 years; p 0.06) and in years of education, while a significant difference emerged in total QMCI score (VKA 45.73 ± 1.72 vs. NOAC 59.58 ± 1.28; p<0.0001); specifically, we found that in 5 out of 6 domains the score was higher in patients treated with NOAC (delayed memory recall: VKA 6.98 ± 0.59 vs NOAC 11.16 ± 0.52, p<0.0001; orientation: VKA 9.24 ± 0.16 vs NOAC 9.65 ± 0.09, p 0.02; clock test: VKA 8.05 ± 0.67 vs NOAC 12.44 ± 0.39, p<0.0001; verbal fluency: VKA 7.64 ± 0.41 vs NOAC 10.03 ± 0.38, p<0.0001; logic memory: VKA 9.71 ± 0.62 vs NOAC 12.62 ± 0.51, p<0.0001). Moreover, MDA levels were significantly higher in VKA patients (VKA 463.0±44.0 vs NOAC 612.5±38.0 nmol/ml, p 0.0158).

Conclusions. In conclusion, NOACs appear to preserve cognitive function in hypertensive patients with AF as compared to the VKA group, which shows QMCI average scores significantly lower, compatible with a diagnosis of cognitive decline (QMCItot <50). Moreover, high serum levels of malondialdehyde have already been associated with post-stroke cognitive impairment.

A132: IMPLANTABLE LOOP RECORDER: PERCHÈ, QUANDO E COME ASCOLTARE IL CUORE

Stefano Clò (a), Matteo Bertini (a), Giovanni Orazio (a), Giorgia Azzolini (a), Andrea Capanni (a), Paolo Sirugo (a), Michele Malagù (a)

(a) AZIENDA OSPEDALIERO-UNIVERSITARIA DI FERRARA

Il loop recorder impiantabile (ILR) è un registratore continuo dell'attività cardiaca impiantabile nel tessuto sottocutaneo utilizzato per stabilire una correlazione tra ritmo cardiaco e sintomi del paziente o per documentare eventuali aritmie asintomatiche. Trova indicazione in cinque particolari scenari clinico/patologici: il cardiopalmo, la sincope, l'ictus criptogenetico, la fibrillazione atriale e nell'ambito della cardiogenetica. Per cardiopalmo si intende la percezione cosciente del battito cardiaco accelerato o irregolare; è spesso secondario a molteplici condizioni patologiche ma non meno frequentemente dovuto a battiti ectopici - sopraventricolari o ventricolari. Durante il work up diagnostico del cardiopalmo possiamo avvalerci di metodiche non invasive (ECG a 12 derivazioni o ECG Holter) o dell'ILR, con una drammatica differenza in termini di efficacia diagnostica tra le due strategie - 80% dei casi non giunge a diagnosi con le metodiche non invasive mentre il 72% dei pazienti ottiene una diagnosi con l'ILR. In particolare, l'ILR è raccomandato nei pazienti con palpitazioni ricorrenti che non hanno ottenuto una diagnosi con le tecniche ECG convenzionali e che hanno un periodo libero da sintomi inferiore alle 4 settimane in assenza di criteri di alto rischio. L'ILR può quindi smascherare tachiaritmie sopraventricolari o ventricolari, ed avviare quindi in paziente verso il corretto percorso di cura (farmacologico o interventivo). La sincope si caratterizza come una improvvisa e fugace perdita di coscienza con o senza prodromi; può essere dovuta a molteplici cause - raggruppabili nelle tre macrocategorie di sincope neuromediata, dovuta ad ipotensione ortostatica e cardiaca

- che, con svariati meccanismi fisiopatologici, portano ad una riduzione dell'output cardiaco o delle resistenze periferiche. Difronte ad un quadro di sincope di ndd occorre effettuare una stratificazione del rischio del paziente; nei casi ad alto rischio cardiologico è opportuno considerare già da subito opzioni più invasive (es: SEF o impianto di ICD). Nei pazienti con sintomi frequenti o aritmie sospette a rischio intermedio e basso, invecel'ILR è indicato anche in fase precoce. Vengono, così, spesso smascherate bradi- o tachi- aritmie e può aver inizio il giusto iter terapeutico. L'ictus ischemico è invece definito come una improvvisa interruzione dell'afflusso sanguigno ad una parte dell'encefalo che si associa ad infarto cerebrale permanente e comporta deficit neurologici. Tra le cause principali si ritrovano l'aterosclerosi, la cardio-embolia (FA, endocardite, IMA, ecc.), l'infarto lacunare e la grossa fetta dell'ictus criptogenetico - ictus di cui non è stata riconosciuta la causa. A quest'ultima categoria si attribuiscono dal 20 al 40% degli ictus ischemici e l'ILR ha un potere diagnostico notevolmente superiore all'ECG holter nello smascherare aritmie potenzialmente responsabili del quadro – con particolare riferimento alla FA. Nei pazienti con FA già nota, l'ILR è invece un validissimo strumento per quantificare il burden di FA, gestire al meglio la terapia antiaritmica e monitorare eventuali recidive dopo l'ablazione transcatetere. Anche nell'ambito della cardiogenetica, l'ILR può trovare applicazione in tutte le cardiopatie congenite ereditarie con importante rischio di aritmie maligne improvvise nei pazienti non ad alto rischio di morte improvvisa – che vanno invece direttamente ad impianto di ICD. Le caratteristiche che un loop recorder impiantabile deve avere sono: la possibilità del monitoraggio da remoto, una sufficiente capacità di storaggio dei dati ed una adeguata qualità dei segnali. Riguardo questo ultimo punto, problemi ai quali ci si può trovare difronte sono l'undersensing (incapacità del dispositivo di riconoscere adeguatamente l'attività cardiaca) e l'oversensing (il dispositivo riconosce anche segnali elettrici non cardiaci). I problemi di sensing accelerano la saturazione della memoria; può essere quindi necessario modificare l'ampiezza del segnale di sensing ed utilizzare una soglia di sensibilità adattativa e dinamica ICD-like. Grazie all'home monitoring siamo in grado di cogliere tempestivamente tali problemi nonché eventuali aritmie rilevate dal dispositivo, e di chiamare quindi a rivalutazione cardiologica il paziente in tempi molto brevi. Sebbene risulti di notevole utilità in molteplici scenari clinici, il loop recorder rimane tutt'ora uno strumento sottoutilizzato nella real life, con una discrepanza non trascurabile tra indicazioni e impianti reali - soprattutto nella sincope inspiegata.

A133: REPOLARIZATION DISPERSION MAPPING IN BRUGADA PATIENTS WITH SPONTANEOUS ELECTROCARDIOGRAPHIC TYPE 1 PHENOTYPE: CORRELATION BETWEEN ACTIVATION-RECOVERY INTERVAL AND TPEAK-TEND INTERVAL

Silvia Garibaldi (a), Sara Latrofa (b), Valentina Hartwig (c), Lorenzo Bachi (b), Maria Sole Morelli (d), Nicola Martini (d), Luca Panchetti (a), Umberto Startari (a), Gianluca Mirizzi (a), Martina Nesti (a), Nicola Zaurino (e), Pasquale Notarstefano (f), Giacomo Mansi (g), Nicola Vanello (h), Claudio Passino (b), Michele Emdin (b), Marcello Piacenti (a), Alberto Giannoni (b), Andrea Rossi (a)

(a) FONDAZIONE TOSCANA GABRIELE MONASTERIO ELECTROPHYSIOLOGY UNIT; (b) SANT'ANNA SCHOOL OF ADVANCED STUDIES, ISTITUTO DI SCIENZE DELLA VITA; (c) CNR, ISTITUTE OF CLINICAL PHYSIOLOGY; (d) G. MONASTERIO RT FOUNDATION; (e) BIOSENSE WEBSTER, CLINICAL SUPPORT SPECIALIST; (f) SAN DONATO HOSPITAL OF AREZZO, ELECTROPHYSIOLOGY UNIT; (g) UNIVERSITY OF PISA; (h) UNIVERSITY OF PISA, DIPARTIMENTO DI INGEGNERIA DELL'INFORMAZIONE

Background. preferential prolongation of action potential duration of epicardial cardiomyocytes in the right ventricular outflow tract (RVOT) is the electrophysiological basis for the coved-type ECG in Brugada syndrome (BrS). Activation-recovery interval (ARI) approximates action potential duration. Tpeak-Tend (Tpe) interval is a proven measure to assess ventricular repolarization time; longer Tpe intervals have been linked to a higher arrhythmic risk in BrS patients. To our knowledge, data regarding the characterisation of RVOT repolarization in BrS patients is still limited.

Purpose. we sought to examine ARI values collected by unipolar signals from high-density electroanatomical maps in the RVOT endocardium of patients with a spontaneous type 1 pattern. We aimed to investigate the relation between ARI distribution and Tpe intervals averaged from surface V1, V2 and V3 ECG leads.

Methods. 24 BrS patients with a persistent coved-type phenotype underwent endocardial 3D RV mapping (CARTO 3, Biosense-Webster, Diamond Bar, CA, USA). Data was exported from the CARTO system and converted into MatLab format using OpenEP. Subsequently, a specific region of interest (ROI) comprising of sub- pulmonary RVOT and RV free wall was selected using Paraview. A semi-automated algorithm was used to measure ARI for each point of the ROI using the Wyatt method; these values were then corrected using the "Bazett formula" and interpolated to create ARI maps. Tpe intervals were calculated for V1, V2 and V3 from ECG recordings during the procedure for each patient. T-peak was determined as the maximum positive or negative deflection following the QRS, whereas T-end was calculated using the previously described "tangent method". Each subject's Tpe was averaged on a subset of 20 low-noise sinus beats selected by an automated signal quality scoring algorithm. Tpe intervals were as well corrected for RR using the "Bazett formula". For each patient, we selected the ARI value corresponding to the 75% of the distribution (ARIcQ3) and the mean value of the values above it (meanARIcQ3). ARIcQ3 points were also collected into the mesh and reported as an area visualized into the map.

Results. out of 24 BrS subjects, one patient had appropriate ICD shocks. We calculated an average ARI of 291.39 ms, average ARIc of 306.01 ms, average ARIcQ3 335.08 ms and meanARIcQ3 was 353.14 ms. Average Tpe value was 74.98 ms, with a corrected average Tpe of 78.95 ms. ARIcQ3 and meanARIcQ3 correlated well with corrected average Tpe (respectively: R=0.5776, p=0.0031; R=0.6489, p=0.0006). ARIcQ3 areas are located into the anterior and subpulmonary RVOT.

Conclusions. ARI approximates epicardial action potential duration and correlates with dispersion of the repolarization measured on surface ECG in BrS patients. Longer ARIc are mainly located into the anterior and subpulmonary aspect of RVOT. Further studies are needed to assess the role of such observations in the context of a multiparametric electroanatomic evaluation in risk stratification especially in asymptomatic BrS type-1 pattern.

A134: ABLAZIONE TRANS-CATETERE DI TACHICARDIA VENTRICOLARE IN UN GIOVANE SPORTIVO CON DIAGNOSI DI MIOCARDIO NON COMPATTO

Riccardo Grandin (a, b), Yary Valeri (a, b), Giovanni Volpato (a, b), Paolo Compagnucci (a, b), Laura Cipolletta (b), Quintino Parisi (b), Agostino Misiani (b), Michela Casella (a), Antonio Dello Russo (a, b)

(a) UNIVERSITÀ POLITECNICA DELLE MARCHE, ANCONA; (b) CLINICA DI CARDIOLOGIA E ARITMOLOGIA, OSPEDALI RIUNITI, ANCONA

Introduzione. Il "Miocardio Non Compatto" è una cardiomiopatia ancora non classificata che può potenzialmente condurre a scompenso cardiaco, ictus, aritmie atriali e ventricolari e conseguentemente a morte cardiaca improvvisa. Attualmente vi è un numero limitato di studi riguardanti gli effetti e l'efficacia dell'ablazione transcatetere delle aritmie ventricolari nei soggetti affetti da tale cardiomiopatia.

Obiettivi. L'obiettivo del seguente caso clinico è quello di descrivere le caratteristiche elettrofisiologiche e i risultati dell'ablazione trans-catetere di tachicardia ventricolare in un giovane pallavolista con diagnosi di Miocardio Non Compatto.

Risultati. Un giovane pallavolista professionista di 16 anni effettuava un accesso in Pronto Soccorso per cardiopalmo ed episodio sincopale. In seguito al riscontro ECG-grafico di tachicardia ventricolare con frequenza di 220 bpm e morfologia a blocco di branca sinistra, asse superiore e concordanza negativa nelle derivazioni precordiali, il paziente è stato ricoverato per la prosecuzione dell'iter diagnostico-terapeutico. Durante il ricovero sono stati effettuati un Ecocardiogramma Transtoracico e una Risonanza Magnetica Cardiaca: entrambi gli esami hanno evidenziato la presenza di criteri compatibili con la diagnosi di Miocardio Non Compatto. Il paziente è stato quindi sottoposto ad impianto di S-ICD in prevenzione secondaria. Tre mesi più tardi, l'S-ICD ha correttamente rilevato e interrotto tramite singolo shock due episodi di tachicardia ventricolare monomorfa. È stato quindi proposto ed effettuato uno studio elettrofisiologico. Il mappaggio di substrato evidenziava un'estesa area di scar densa e di potenziali bassi e frammentati a livello della parete antero-laterale e del setto medio-apicale. Tramite stimolazione ventricolare programmata sono state indotte tre forme differenti di tachicardia ventricolare e ne sono stati successivamente mappati e ricostruiti i relativi circuiti aritmici. L'applicazione di polsi di radiofrequenza in corrispondenza dei potenziali "meso-diastolici", a livello del setto IV e della parete medio-basale antero-laterale, in particolare a livello del muscolo papillare antero-laterale, ha permesso la soppressione delle tachiaritmie ventricolari. Si procedeva successivamente all'omogenizzazione delle regioni con potenziali tardivi e frammentati. Alla successiva stimolazione ventricolare programmata, anche durante infusione di isoproterenolo ad alte dosi e al wash-out, non è stata più indotta alcuna forma di TV. Durante 6 mesi di follow-up, l'S-ICD non ha più rilevato eventi aritmici ventricolari.

Conclusioni. In conclusione, l'ablazione transcatetere di tachicardie ventricolari sembra essere una strategia sicura ed efficace per la gestione delle aritmie ventricolari nei pazienti affetti da Miocardio Non Compatto. Nonostante ciò, per valutarne la reale efficacia a lungo termine, si rendono necessari ulteriori studi ed un più lungo follow-up.

A135: UNA GESTIONE EZIOPATOGENETICA DI STORM ARITMICO

Emanuele Marino (a), Federico Baraldi (a), Giulia Spiriti (a), Gianluca Guelfand Crignola (a), Giacomo Silvetti (a), Giulia Garosi (a), Gaetano Tanzilli (a), Carlo Gaudio (a), Concetta Torromeo (a), Bich Lich Nguyen (a)

(a) SAPIENZA POLICLINICO UMBERTO I

Un paziente di 55 anni iperteso, fumatore e con storia di abuso di sostanze (tra cui la cocaina), accedeva al pronto soccorso con dolore toracico tipico, emodinamicamente stabile. L'ECG evidenziava un blocco atrioventricolare avanzato in assenza di anomalie del tratto ST con aumento degli enzimi di cardiomionecrosi. In seguito ad un altro episodio di dolore toracico, l'ECG mostrava fibrillazione atriale a bassa risposta ventrico-

lare e sopraslivellamento del tratto ST in sede inferiore per cui il paziente veniva sottoposto a impianto di 2 stent sull'arteria coronaria destra. Due giorni dopo, il paziente andava incontro ad un primo episodio di torsione di punta che necessitò di DC-shock. Nei giorni seguenti si ripetono altri episodi di torsione di punta defibrillati con persistenza della fibrillazione atriale. Prima di questi eventi, il ritmo di base era sempre una fibrillazione atriale a bassa risposta ventricolare con numerosi BEV e un QTc allungato. La torsione di punta veniva immediatamente preceduta dalla sequenza RR short-long-short e una elevata variabilità dell'intervallo QTc battito-battito. Venivano escluse cause secondarie dell'aritmia e una nuova coronarografia escludeva la necessità di un reintervento. Veniva pertanto impiantato un ICD transvenoso bicamerale per effettuare un pacing ventricolare a VVI 80ppm in modo da rendere più omogeneo l'intervallo QTc battito-battito ed evitare la sequenza RR short-long-short dovuti alla fibrillazione atriale a bassa risposta ventricolare sottostante. La degenza del paziente si è svolta senza ulteriori complicanze ed è stato dimesso dopo 3 giorni di osservazione post-impianto ICD. Al controllo ICD dopo 1 settimana il paziente era tornato in ritmo sinusale normofrequente, senza episodi registrati dal device e veniva programmato in DDD 70ppm. A quasi 1 anno di follow-up, il paziente non ha più avuto episodi, il QTc è rientrato nei valori normali, seppur con la persistenza dei BEV che non inducono più una disomogeneità dell'intervallo QTc. Questo caso ci ricorda che lo storm aritmico è una sindrome che necessita di un trattamento specifico cucito sul singolo paziente.

A136: FOLLOW UP DEI PAZIENTI SOTTOPOSTI AD IMPIANTO DI LEADLESS PACEMAKER POST-ESTRAZIONE

Alessandra Ferrieri (a), Alessia Dentico (a), Teresa Altieri (a), Domenico Maria Carretta (a), Carlo D'Agostino (a), Francesca Carretta (b)
(a) A.O.U.C POLICLINICO DI BARI- U.O.C CARDIOLOGIA OSPEDALIERA;
(b) UNIVERSITÀ CAMPUS BIO-MEDICO DI ROMA

Introduzione. Con l'aumentare delle complicanze associate all'impianto di pacemaker e defibrillatori, è aumentato il numero di pazienti che vanno incontro ad estrazione transvenosa di elettrocateteri in seguito ad infezione degli stessi. Spesso, nei pazienti pacemaker dipendenti vi è il problema di dover effettuare un reimpianto precoce dopo l'estrazione. Questo studio si pone l'obiettivo di valutare l'esito dell'impianto di Micra in pazienti precedentemente sottoposti TLE, confrontandoli con pazienti che presentano un Micra come primo impianto.
Materiali e metodi. Da gennaio 2017 a novembre 2022 nel nostro centro sono state eseguite 190 procedure di impianto di leadless pacemaker. Di questi pazienti 24 sono andati incontro a procedura di estrazione. Per valutare il rendimento tecnico dei leadless pacemaker nei pazienti post-estratti, è stato fatto un confronto tra questi ed i leadless impiantati "de novo", così da valutarne l'efficacia delle specifiche tecniche. In particolare, sono state considerate tutte le caratteristiche di base dei vari pazienti, i dati dell'estrazione e della procedura di impianto. Successivamente, sono stati confrontati i valori dei parametri di sensing, soglia, impedenza e percentuale di stimolazione raccolti nei follow-up eseguiti dai due gruppi di pazienti ad 1 mese dall'impianto, 6 mesi e ogni anno.
Risultati. Una prima analisi del follow-up delle suddette classi di pazienti dal 2017 ad oggi ci fornisce già alcuni dati importanti: nei pazienti che hanno impiantato un leadless pacemaker in seguito ad estrazione in nessun caso si è manifestata una recidiva di infezione; il successo dell'impianto di Micra è stato del 100%. L'analisi delle statistiche dei parametri elettrici, inoltre, ha dimostrato l'assoluta efficacia del dispositivo leadless in entrambe le classi di pazienti messi a confronto, senza mettere in evidenza grandi differenze. Infine, in un'epoca molto attenta alle finanze ospedaliere questo modello operativo consente una riduzione dei tempi di ospedalizzazione e dei conseguenti costi.
Conclusioni. L'impianto di leadless pacemaker in pazienti post-estratti, laddove abbiamo pazienti eleggibili ad impianto di tale dispositivo, si è dimostrato una scelta efficace come alternativa all'impianto di un pacemaker tradizionale, per permettere la riduzione del rischio di complicanze infettive, garantendo comunque una performance ottimale.

A137: "NARROW-WIDE-NARROW" QRS COMPLEX TACHYCARDIA - BEWARE THE SMARTWATCH MONSTERS

Alfredo Mauriello (a), Antonia Ascrizzi (a), Vincenzo Russo (a)
(a) DEPARTMENT OF MEDICAL TRANSLATIONAL SCIENCES, UNIVERSITY OF CAMPANIA "LUIGI VANVITELLI", MONALDI HOSPITAL, NAPLES, ITALY

A young adult patient was referred to our Arrhythmic Unit for palpitations associated with chest pain and lightheadedness. The patient's smartwatch recorded a narrow QRS regular tachycardia triggering a nonsustained phase of wide complex irregular tachycardia; finally, the tachycardia again assumes a wide complex configuration until spontaneous termination occurs some beats later. The interpretation of the "narrow-wide-narrow" QRS complex tachycardia was not univocal, and its nature has been debated. The smartwatch-based single- lead ECG of the patient described was challenging because a concomitance of supraventricular and ventricular tachyarrhythmias has been suspected. A persistent embryonic conduction branch, the so-called dead- end tract, which forms a connection between the AV nodal region and the focus for idiopathic VT, may be the electrophysiological basis of this association. The presence of transition from narrow-complex to wide-complex tachycardia with different cycle lengths and different QRS morphology excluded the possibility of AVNRT conducted over a bystander accessory pathway. The restart of narrow QRS tachycardia with the same cycle length as that before wide complex tachycardia excluded the hypothesis of VT. The electrophysiology study confirmed the diagnosis of AVNRT, the absence of accessory pathway or aberrant conduction, and the non-inducibility of any VT. Finally, we considered the phase of wide irregular QRS tachycardia as an artifact. The present case suggests that attention should be paid to the ECG findings of smartwatches.

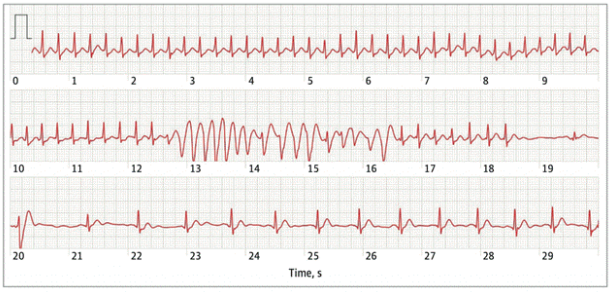

A138: SINCOPE IN PAZIENTE CON FEBBRE E PATTERN DI BRUDAGA DI TIPO 1 SPONTANEO: L'APPARENZA PUÒ INGANNARE

Alfredo Mauriello (a), Mirella Limatola (a), Corina Valentina De Santis Ciacci (a), Vincenzo Russo (a)
(a) DEPARTMENT OF MEDICAL TRANSITIONAL SCIENCES, UNIVERSITY OF CAMPANIA "LUIGI VANVITELLI", MONALDI HOSPITAL, NAPLES, ITALY

Un uomo di 53 anni, senza storia clinica significativa o storia familiare di morte cardiaca improvvisa, si è recato al Pronto Soccorso per una perdita transitoria di coscienza associata a trauma facciale. La perdita transitoria di coscienza si è verificata a riposo, in posizione eretta, senza prodromi e/o trigger specifici. Il paziente non assumeva farmaci o sostanze che potessero spiegare l'evento. Al momento del ricovero la temperatura corporea era di 37,8°C. Gli esami ematochimici e la radiografia del torace hanno posto il sospetto diagnostico di polmonite lobare batterica. L'ecocardiografia transtoracica non ha mostrato nessuna anomalia cardiaca. L'elettrocardiogramma ha mostrato un sopraslivellamento del tratto ST seguito da un'onda T negativa in V1 e V2, compatibile con il pattern di Brugada di tipo 1. Il paziente è stato trasferito nell'Unità di Cardiologia per la stratificazione del rischio aritmico. Dopo 2 giorni di ricovero, a seguito di terapia medica, con la risoluzione dello stato febbrile e la normalizzazione dello stato infiammatorio, si è verificata una transizione dal pattern ECG da Brugada di tipo 1 a quello di tipo 2. Non erano presenti marker di rischio elettrocardiografico per la fibrillazione ventricolare. I potenziali tardivi erano negativi. Al monitoraggio telemetrico intraospedaliero non sono stati registrati eventi aritmici. L'interpretazione clinica della perdita transitoria di coscienza senza prodromi nei pazienti con pattern di Brugada di tipo 1 non è univoca, pertanto il caso è stato approfondito per individuare la natura della perdita transitoria di coscienza (aritmica o meno), e definire la gestione (conservativa o invasiva). Il paziente è stato sottoposto a diversi approfondimenti diagnostici. È stato praticato l'head-up tilt test secondo protocollo italiano che ha mostrato l'induzione di una sincope vasodepressiva senza prodromi, caratterizzata da un improvviso calo della pressione sanguigna con aumento della frequenza cardiaca. Successivamente il paziente è stato sottoposto ad uno studio elettrofisiologico. È stato praticato il mappaggio endocardico tridimensionale (3D) del ventricolo destro utilizzando un sistema di mappatura ad alta risoluzione (Rhythmia Sistema di mappatura Hdx™, Boston Scientific Corporation, Marlborough, MA, USA) con successiva stimolazione ventricolare programmata in due siti, apice ventricolare destro e tratto di efflusso ventricolare destro (RVOT), con un treno di tre extrastimoli, prima e dopo la somministrazione di flecainide 2 mg/kg in 10 min. Il mappaggio non ha mostrano anomalie e la stimolazione ventricolare programmata è risultata negativa per l'induzione di aritmie ventricolari. Infine, alcuni dubbi sono rimasti sull'eziologia della sincope, ed è stato impiantato un Loop Recorder (Biomonitor IIIM, Biotronik, Berlino, Germania). Il paziente è stato dimesso con diagnosi di sincope vasodepressiva con l'indicazione ad eseguire manovre di contropressione fisica e tilt training. A 12 mesi di follow-up, interrogando il Loop Recorder, non si sono verificate aritmie o episodi sincopali. Nel frattempo, il paziente è stato sottoposto ad analisi genetica con tecnica NGS, includendo nell'analisi, la ricerca di mutazioni patologiche a carico del gene SCN5A, risultata negativa per le varianti patogene di sindrome di Brugada.

A139: UN UNUSUAL BRADYCARDIA

Mario Di Marino (a), Irina Bellissario (a), Kristian Galanti (a), Fabrizio Ricci (a), Sabina Gallina (a), Giulia Renda (a)
(a) DEPARTMENT OF NEUROSCIENCE, IMAGING AND CLINICAL SCIENCES, "G. D'ANNUNZIO" UNIVERSITY, CHEITI-PESCARA, ITALY

Caucasian male, 93 years old, was found unconscious in his home in February. Upon arrival at the emergency department, the patient was unresponsive but breathing spontaneously. His Glasgow Coma Scale score was 9, blood pressure was 100/60 mmHg, severe bradycardia was noted (35/min), and oxygen saturation was 93% on room air. The patient's skin was dry and very cold, with an external temperature reading of 32°C and a bladder temperature probe reading of 29°C. An electrocardiogram (ECG) revealed severe sinus bradycardia (35/min), normal atrioventricular conduction, a normal R/S transition, a prominent J wave in precordial leads, prolonged QTc interval (662 ms Bazett, 728 ms Fridericia), low voltages, and highly irregular isoelectric line due to muscle tremor artifacts. Laboratory tests showed a hemoglobin level of 12.3 g/dL, troponin level of 1000 pg/mL, potassium level of 2.7 mEq/L, and creatinine level of 0.97 mg/mL. Arterial blood gas analysis revealed a pH of 7.32, pCO2 of 37.5 mmHg, pO2 of 87 mmHg, and lactate level of 0.9 mEq/L. Echocardiography showed preserved systolic function of the left ventricle with no regional wall motion abnormalities (ejection fraction 55%). The right heart chambers were within normal limits, and no significant valvular abnormalities were detected. The clinical presentation was consistent with severe hypothermia, associated with the development of Osborn J waves, diffuse cardiac dysfunction, and severe hypokalemia. The patient was promptly treated with a heated blanket, bladder lavage using heated fluids, infusion of warmed fluids, and monitoring with a warm touch system, while hypokalemia was corrected with potassium infusion. Once the patient's core temperature returned above 32°C, the Osborn J wave promptly regressed, and the heart rate returned to an acceptable range. The presence of an Osborn J wave is commonly observed in 80% of cases when body temperature falls below 30°C, with its amplitude inversely proportional to body temperature. The slowing of the activation kinetics of the repolarizing Ito current, which involves epicardial but not endocardial cells, achieves an electrical gradient with a spike-and-dome morphology action potential, which finds its electrocardiographic expression in the appearance of a prominent J wave. The J wave is associated with atrioventricular blocks, ventricular arrhythmias, and asystole, but a return to an acceptable core body temperature mitigates this risk. In cases of hypothermia, it is crucial to invasively monitor core body temperature and promptly warm the patient while correcting any concurrent electrolyte imbalances. To aid in the recognition of a suspicious ECG due to hypothermia, we suggest using the acrostic "SLOW" for bradycardia: Shivering (muscle tremor artifacts), Low voltages, Osborn J wave, and Wide QT interval.

A140: UN CASO PARTICOLARE DI TACHICARDIA VENTRICOLARE DURANTE STIMOLAZIONE BIVENTRICOLARE

Nicola Ferrara (a), Irene Scimè (a), Bonanno Salvatore (a), Pasquale Crea (a), Luzza Francesco (a), Gianluca Di Bella (a), Scipione Carerj (a)
(a) DIPARTIMENTO DI MEDICINA CLINICA E SPERIMENTALE, CARDIOLOGIA CON UTIC, UNIVERSITÀ DI MESSINA

La terapia di resincronizzazione cardiaca (CRT), con o senza possibilità di trattamento antitachiaritmico (CRT-D), ha rappresentato un'importante evoluzione nel trattamento dell'insufficienza cardiaca cronica a frazione d'eiezione depressa. Gli studi ne hanno infatti ampiamente dimostrato l'efficacia in termine di riduzione, non solo della mortalità e delle ospedalizzazioni per scompenso cardiaco, ma anche della morte improvvisa, probabilmente grazie ad un effetto favorevole sul remodelling ventricolare e di conseguenza sul rischio di aritmie minacciose per la vita. Nonostante ciò, allo stesso CRT-D è anche associato un effetto proaritmico, tale da determinare in alcuni pazienti ricorrenti ed imprevedibili tachiaritmie ventricolari, spesso refrattarie a terapia farmacologica e associate a deterioramento della funzione ventricolare e a prognosi peggiore. Gli shock erogati dal dispositivo risultano avere infatti un effetto negativo non soltanto sul cuore, ma anche sulla qualità di vita e sulla durata della batteria, soprattutto in caso di eventi ricorrenti, come nel quadro dello storm aritmico. Nel caso clinico di seguito descritto, un'attenta valutazione della tachicardia ventricolare, ci ha permesso di avanzare un'ipotesi alternativa sull'elettrogenesi dello storm aritmico in un paziente portatore di CRT-D e di agire così sull'innesco degli eventi in modo da ottenere l'ottimizzazione della terapia. A.T. è un paziente di anni 63, affetto da cardiomiopatia dilatativa familiare e scompenso cardiaco cronico a frazione d'eiezione ridotta (FE=27%) e portatore di ICD Biotronik dal 2015 con singolo elettrocatetere in sede apicale ventricolare destra e dipolo flottante in atrio destro, e successivo upgrade a CRT-D nel 2019 dopo posizionamento di elettrocatetere in seno coronarico. Viene ricoverato presso la nostra UOC per tre scariche ricorrenti del dispositivo nelle prime ore della mattina, quadro configurabile con quello di storm aritmico. L'evento si presentava come recidivante in quanto negli anni precedenti, il paziente era stato più volte sottoposto a ricovero per episodi tachiaritmici ventricolari (storm aritmici e tachicardie ventricolari sostenute) e a due procedure di ablazione transcatetere, risultate infruttuose. Il paziente praticava già terapia antiscompenso massimale e terapia antiaritmica con Metoprololo 100 mg ½ cp bid, Mexiletina cloridrato 200 mg 1 cp bid, Amiodarone 200 mg qd. Entrato in reparto, si è proceduto all'esecuzione di esami ematochimici, risultati nella norma, e ad interrogazione del dispositivo, con evidenza di eventi di tachicardia ventricolare monomorfa, trattati con ATP e secondaria erogazione di singolo shock a 40J. Osservando gli inneschi, abbiamo potuto verificare che essi si presentavano soprattutto nelle ore notturne, in corso di bradicardia sinusale a freq. di 50 b/m', dopo la comparsa di un battito prematuro, responsabile di un allungamento della lunghezza del ciclo fino al raggiungimento dell'LRI e conseguente stimolazione biventricolare. Ciò fa sì che il battito sinusale seguente non riesca ad essere condotto, motivo per cui emerge una stimolazione del solo ventricolo destro (secondo programmazione del dispositivo Biotronik) e conseguente innesco di tachicardia ventricolare da verosimile circuito di rientro. Vista la terapia medica ottimizzata e le precedenti procedure di ablazione inefficaci, abbiamo optato per l'ottimizzazione della terapia con CRT-D, tramite upgrade con posizionamento di nuovo elettrocatetere in sede auricolare destra e switch della modalità di stimolazione da VDD a DDD, al fine di ridurre il rischio di bradicardia sinusale, responsabile dell'inizio della sequenza aritmica. Durante il follow-up di due mesi, non si sono evidenziati nuovi eventi.

A141: ABLAZIONE TRANSCATETERE DI TACHICARDIA ATRIALE AUTOMATICA IN UNA GIOVANE CICLISTA PROFESSIONISTA

Antonio Dello Russo (a, b), Michela Casella (a), Agostino Misiani (b), Quintino Parisi (b), Laura Cipolletta (b), Giovanni Volpato (a, b), Paolo Compagnucci (a, b), Yari Valeri (a, b)
(a) UNIVERSITÀ POLITECNICA DELLE MARCHE, ANCONA; (b) CLINICA DI CARDIOLOGIA E ARITMOLOGIA, OSPEDALI RIUNITI, ANCONA

Introduzione. La tachicardia atriale automatica è un'aritmia che si caratterizza per una frequenza atriale inappropriatamente rapida. In letteratura non sono descritti molti casi di ablazione di tachicardia atriale ectopica compromettente le prestazioni fisiche di atleti professionisti.
Obiettivi. L'obiettivo di questo lavoro è descrivere l'efficacia dell'ablazione della tachicardia atriale automatica in un'atleta professionista, con conseguente miglioramento significativo dei sintomi correlati all'esercizio e delle performance sportive.
Materiali e metodi. "N/A".
Risultati. Una ciclista professionista di 22 anni è stata ricoverata presso il nostro reparto dopo aver riscontrato al cardiofrequenzimetro, durante gli allenamenti e le competizioni, dei rapidi e inappropriati incrementi della frequenza cardiaca, sintomatici per astenia e cardiopalmo; tali episodi determinavano compromissione delle prestazioni fisiche. Ad una più accurata analisi dei tracciati del cardiofrequenzimetro, veniva riscontrato un rapido incremento della frequenza cardiaca da 130 bpm a 221 bpm, seguito da un ulteriore rapido aumento a 245 bpm nel giro di 50 secondi. È stato quindi eseguito uno studio elettrofisiologico durante il quale è stata indotta, attraverso una stimolazione atriale programmata durante infusione di isoprenalina, una tachicardia sopraventricolare con un ciclo di 290 msec, autolimitantesi, suggestiva alle manovre elettrofisiologiche per tachicardia atriale automatica. Dopo aver mappato il focus ectopico, sono stati erogati impulsi di radiofrequenza a livello postero-settale, anteriormente al seno coronarico. Al termine della procedura nessuna tachicardia atriale risultava più inducibile alla stimolazione atriale programmata, né in condizioni basali, né durante infusione di isoprotenerolo. Veniva quindi impiantato un loop recorder per il monitoraggio longitudinale del ritmo. La ciclista è tornata in attività agonistica, senza più alcun tipo di sintomo né tantomeno la registrazione di nuovi eventi aritmici.
Conclusioni. L'ablazione trans-catetere si è dimostrata sicura nel controllo delle tachicardie atriali automatiche, anche in cuori allenati e con elevata stimolazione adrenergica, come quelli di atleti professionisti. L'eliminazione dell'aritmia ha permesso di migliorare significativamente la sintomatologia e le performance sportive.

A142: SINDROME DI WOLFF-PARKINSON-WHITE ESORDITA CON ICTUS CEREBRI

Gianluca Guelfand Crignola (a), Giacomo Silvetti (a), Giulia Spiriti (a), Emanuele Marino (a), Giulia Garosi (a), Federico Baraldi (a), Giuseppe Pannarale (a), Raffaele Quaglione (a), Gaetano Tanzilli (a), Carlo Gaudio (a), Concetta Torromeo (a), Stefano Strano (a), Bich Lien Nguyen (a)
(a) POLICLINICO UMBERTO I

La sindrome di Wolff-Parkinson-White (WPW) è una condizione caratterizzata dalla persistenza di una via accessoria atrio-ventricolare responsabile della preeccitazione ventricolare, che può portare ad aritmie sintomatiche e potenzialmente gravi. La sua coesistenza con la fibrillazione atriale è ben nota e non rara, con rischio di degenerare in fibrillazione ventricolare quando gli impulsi atriali vengono trasmessi lungo la via accessoria rapidamente. Lo spettro sintomatologico di

questa sindrome è molto ampio e può essere del tutto asintomatica fino ad arrivare alla morte cardiaca improvvisa. Descriviamo il caso di un paziente di 59 anni con storia di ictus cerebri ed episodi di fibrillazione atriale parossistica. Un ECG effettuato successivamente ha evidenziato una preeccitazione ventricolare. Il paziente non aveva mai lamentato sintomi prima del ricovero per ictus. Il paziente è stato quindi sottoposto a studio elettrofisiologico intracavitario, che mostrava facile inducibilità di tachicardia parossistica sopraventricolare e fibrillazione atriale. Veniva pertanto sottoposto ad ablazione della via accessoria medio-settale. Al follow-up, il paziente è rimasto asintomatico, in buone condizioni, non ha più presentato preeccitazione ventricolare né fibrillazione atriale. I pazienti affetti da WPW hanno un rischio aumentato di fibrillazione atriale. I pazienti relativamente giovani affetti da un ictus di verosimile origine cardio-embolica dovrebbero eseguire una valutazione aritmologica per escludere la presenza di fattori aritmogeni predisponenti la fibrillazione atriale, come la presenza di una via accessoria atrio-ventricolare.

A143: ATRIAL FIBRILLATION AND ELECTRICAL REMODELING

Alessia Chiara Latini (a, b), Vincenzo Battaglia (a, b), Giulio Falasconi (a, b), Diego Penela (a), Antonio Taormina (a), Carlo Ceriotti (a), Guido Del Monaco (a, b), Stefano Valcher (a, b), Francesco Villella (b), Paola Galimberti (a), Benedetta Grossi (b), Stefano Pagani (b), Giulio Stefanini (a, b), Gianluigi Condorelli (a, b), Antonio Frontera (a)
(a) HUMANITAS RESEARCH HOSPITAL; (b) HUMANITAS UNIVERSITY

Atrial fibrillation (AF) is the most frequent cardiac arrhythmia, affecting 2% to 4% of the adult population worldwide. This potential progressive arrhythmia is associated with major complications such as stroke and cardiac failure, leading to high morbidity and mortality rates. Currently, AF classification is based on clinical presentation in terms of episode duration: AF is defined paroxysmal when the arrhythmic episodes terminate spontaneously or with intervention within 7 days of onset, and persistent when it was documented at least one episode sustained beyond 7 days. However, this clinically driven classification was proven to poorly correlate to AF burden on long-term monitoring in patients with implantable devices. In the era of personalized medicine, the choice of therapy should be tailored on the patient's individual structural and electrical substrate characteristics rather than on rough categories. For this reason, the interest in characterizing patients according to their degree of atrial remodeling increasing. The term 'atrial remodeling' refers to any modification in the atria which favor the occurrence of trigger activity initiating AF and enhance the formation of a substrate for AF perpetuation. Atrial remodeling can be classified into structural and electrical remodeling. Atrial structural remodeling is a complex phenomenon that results from changes in atrial size, shape, thickness and architecture. At the cellular level, it generates alterations in the cardiomyocytes, fibroblasts, and amount of extracellular matrix (ECM). Moreover, atrial structural remodeling often increases atrial stretch, which has been proven in multiple studies to have a proarrhythmic effect. Whereas atrial structural remodelling is detectable with imaging techniques, atrial electrical remodelling (AER) is difficult to measure, thus making it an open challenge for electrophysiologists. The aim of this review is to summarize the mechanisms underlying AER, their impact on AF initiation and perpetuation and the potential role of a pathophysiologically driven therapeutic target.

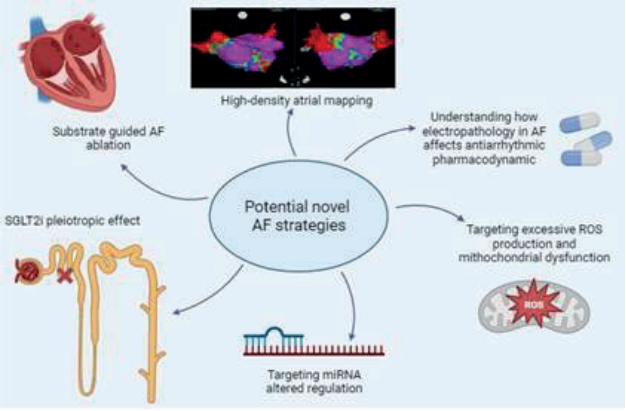

A144: INQUADRAMENTO DIAGNOSTICO IN PAZIENTE CON ARITMIA VENTRICOLARE

Francesco Mautone (a), Maurizio Pesolo (a), Debora Ruggeri (a), Grazia Casavecchia (b), Matteo Gravina (a, b), Natale Daniele Brunetti (a, b)
(a) UNIVERSITÀ DI FOGGIA; (b) OSPEDALI RIUNITI FOGGIA

Introduzione. La Displasia Aritmogena del Ventricolo Destro (ARVD) è una rara forma di cardiomiopatia su base ereditaria autosimica dominante, associata ad aritmie, scompenso cardiaco e morte cardiaca improvvisa. La caratteristica principale di questo tipo di cardiomiopatia è la perdita di tessuto miocardico, maggiormente a carico del ventricolo destro, che viene parzialmente sostituito da tessuto fibro-adiposo.
Caso clinico. Presentiamo il caso clinico di una giovane sportiva di 21 anni, senza nessun di fattore di rischio cardiovascolare noto. Da alcuni mesi la paziente lamentava episodi di cardiopalmo aritmico. ECG di superficie ed ecocardiogramma nella norma. Esami ematochimici e funzionalità tiroidea nella norma. La paziente è stata sottoposta ad ECG Holter delle 24 h con riscontro di costante ritmo sinusale, 15 Extrasistoli sopraventricolari singole e normocondotte ai ventricoli, 7643 extrasistoli ventricolari polimorfe, singole e ripetitive (40 coppie, 9 triplette). Abbiamo eseguito Test da Sforzo al Cicloergometro con riscontro all'apice dello sforzo di BEVs polimorfi, isolati e ripetitivi, alcune coppie e 2 fasi di TVNS di 6 battiti. Si decide di eseguire Risonanza Magnetica Cardiaca che ha documentato fibrosi meso–subepicardica della parete laterale del ventricolo destro in corrispondenza del tratto di efflusso con pattern di distribuzione del Late Gadolinium Enhancement di tipo non ischemico. Quadro RMN riferibile a cardiomiopatia strutturale ed in prima ipotesi a displasia aritmogena del ventricolo destro.
Conclusioni. La risonanza magnetica cardiaca, per le sue caratteristiche di non-invasività e la precisa capacità di caratterizzazione tissutale, sta acquisendo un ruolo chiave nel procedimento diagnostico differenziale delle cardiomiopatie e nella stratificazione prognostica associata a queste patologie.

A145: VALUTAZIONE DEL RISCHIO ARITMICO NELLA CARDIOMIOPATIA IPERTROFICA

Angelo Melpignano (a), Giulia Passarini (b), Matteo Arzenton (a), Gabriele Guardigli (b)
(a) UNIVERSITÀ DEGLI STUDI DI FERRARA; (b) AZIENDA OSPEDALIERO-UNIVERSITARIA DI FERRARA

Paziente di 31 anni, fumatore, svolge vita attiva. Anamnesi familiare e personale negativa per patologie cardiovascolari, non evidenza di casi di morte improvvisa tra i familiari. Accede in PS per episodio sincopale preceduto da prodromi, non associato ad angor o cardiopalmo. Tale evento si verifica mentre il paziente sta eseguendo un blando riscaldamento prima di una sessione di palestra, in una giornata molto calda con contestuale disidratazione. All'ECG sono presenti segni di ipertrofia ventricolare sinistra. Agli esami di laboratorio la troponina HS risulta positiva ($hsTnI_0$ 91 ng/L, $hsTnI_1$ 385 ng/L). Durante il ricovero in Cardiologia viene effettuata ecocardiografia transtoracica con evidenza di ipertrofia ventricolare sinistra asimmetrica, prevalente a livello del setto basale dove raggiunge spessore massimo di 16 mm, in assenza di ostruzione al tratto di efflusso. Visto l'esito degli esami di laboratorio viene eseguita coronaro-TC con evidenza di coronarie esenti da lesioni. Al monitoraggio telemetrico e all'ECG-Holter 24h non si documentano battiti ectopici ventricolari né singoli né organizzati. Viene eseguita ecocardiografia da sforzo durante il quale non si evidenzia gradiente all'efflusso ventricolare sinistro. A completamento viene eseguita RM cardiaca che conferma i reperti ecocardiografici, in assenza di edema o LGE in fase tardiva. Gli esami eseguiti avvalorano il sospetto clinico di cardiomiopatia ipertrofica (HCM). Viene calcolato infine l'HCM Risk – SCD score con il quale si stima un rischio di morte cardiaca improvvisa (SD) a 5 anni del 3,95% sia con lo score dell'ESC (European Heart Association), sia con lo score dell'AHA (American Heart Association), per il quale in entrambi i casi non vi sono chiare indicazioni riguardo l'impianto di defibrillatore cardiaco (ICD). Nel nostro caso, alla luce della storia clinica ed in particolare della scarsa probabilità della natura aritmica della sincope, congiuntamente alla preferenza del paziente, non veniva impiantato ICD in prevenzione primaria. Si consigliava de-training con rivalutazione a sei mesi, si proponevano esami di screening nei familiari di I grado e valutazione genetica.
La cardiomiopatia ipertrofica (HCM) è la cardiomiopatia con più elevata prevalenza, ma potenzialmente trattabile e compatibile con una lunga durata di vita. Nei pazienti con HCM è fondamentale stimare il rischio di aritmie e di SD per identificare prontamente quei pazienti che possono beneficiare dell'impianto di un ICD. L'HCM Risk-SCD è un valido ausilio per la stratificazione dei pazienti in quanto integra dati clinici e anamnestici con parametri derivati dall'imaging. Gli score consigliati dall'ESC e dall'AHA sono simili ma quest'ultimo tiene in considerazione e valorizza nel computo della percentuale di rischio anche reperti come la presenza di LGE all'RM cardiaca, di aneurisma apicale o di FE (frazione di eiezione) inferiore al 50%. Non per ultimo, in particolare nei casi con indicazione borderline, devono essere considerati l'impatto emotivo dell'impianto, nonché i potenziali effetti collaterali nel paziente giovane e attivo.

A146: LOW TO INTERMEDIATE RISK STRATIFICATION IN BRUGADA PATTERNS: WHICH RED FLAGS ARE WE MISSING?

Carla Indennidate (a), Massimo Zecchin (a), Elisabetta Bianco (a), Luca Salvatore (a), Fulvia Longaro (a), Francesca Piccinin (a), Del Monte Giovanni (a), Lorenzo Moschetta (a), Gianfranco Sinagra (a)
(a) CARDIOTHORACOVASCULAR DEPARTEMENT, AZIENDA SANITARIA UNIVERSITARIA GIULIANO ISONTINA (ASUGI), UNIVERSITY OF TRIESTE, ITALY

Brugada syndrome is a rare disease affecting 1 person in 10,000 in Europe; however, the Brugada pattern in electrocardiograms is more fre-

quent than previously thought (1 in 2,000). Preoperative or screening electrocardiograms have increased the number of type 2 or 3 patterns or intermittent type 1 pattern diagnoses. The majority of these patients are asymptomatic and do not have a familial history of sudden cardiac death, syncope, or palpitations. These patients are typically considered intermediate-low-risk patients, according to available risk scores (Shanghai Score, Brugada-Risk), and may be suggested to discontinue follow-up or continue with occasional clinical check-ups. However, risk stratification in these patients cannot be solely based on simplistic score evaluation; there are still many gaps in the evidence. Here, we present the case of a 47-year-old man with no prior cardiac history, who incidentally discovered a Brugada type 2 pattern through a preoperative EKG at the age of 36. At that time, he was asymptomatic, and echocardiography and a stress test showed normal results. A 24-hours Holter revealed sporadic ventricular ectopies and only one polymorphic ventricular couplet. Consequently, a flecainide test was conducted, which yielded a positive result for a type 1 pattern. Then he underwent regular follow-ups every two years and remained asymptomatic until 2019 when he reported sporadic palpitation, and Holter revealed 39 supraventricular extrasystoles (SVE), 37 ventricular ectopies (VE), and 2 ventricular couplets. No therapy was initiated due to his tendency toward bradycardia. In 2023, he experienced brief, rapid palpitations at rest, and a Holter recorded 39 SVE, 128 VE, and 1 non-sustained ventricular tachycardia (13 beats, HR 193 bpm). Subsequently, we scheduled an electrophysiological study, during which normal basic parameters were observed. A polymorphic ventricular tachycardia was induced with two extrastimuli (drive cycle length 500 ms, coupling interval 200 ms). It rapidly degenerated into ventricular fibrillation and was promptly treated with external shocks. A subcutaneous defibrillator was consequently implanted. In accordance with the Shanghai Score, this patient would have received a score of 2, which is non-diagnostic for Brugada syndrome. Similarly, for Brugada-Risk, he did not exhibit any risk features and would have been excluded from follow-ups. What has changed in ten years of follow-up? Which crucial factors are we overlooking? How can we accurately differentiate between low and intermediate-risk patients? Should we begin considering polymorphic ventricular extrasystoles as an indicator of potential progression to a higher-risk profile? Numerous clues must be sought to identify patients at very high risk of sudden cardiac death: symptoms, a history of syncope, familial history, genetic mutations, and EKG patterns (spontaneous type 1 pattern, first-degree AV block, QRS fragmentation, aVR sign, QRS duration over 110 ms, wide and deep S wave in leads I and II, early repolarization). However we need to fill the constellation of accessory red flags to accurately distinguish between intermediate risk and real low risk. The profile of extrasystolic arrhythmia con implement and strengthen our risk-stratification tools.

A147: VALUTAZIONE DELLA FATTIBILITÀ, DELLA SICUREZZA E DELL'EFFICACIA DELLA PROCEDURA DI ABLAZIONE TRANSCATETERE DELLA FIBRILLAZIONE ATRIALE NEI PAZIENTI IN TERAPIA FARMACOLOGICA CON IBRUTINIB

Domenico Laviola (a), Carlo Lavalle (a), Marco Valerio Mariani (a), Nicola Pierucci (a)
(a) SAPIENZA UNIVERSITÀ DI ROMA - POLICLINICO UMBERTO I

La fibrillazione atriale (FA) è l'aritmia sostenuta più comune al mondo colpendo almeno 33 milioni di individui. Studi dimostrano un link bidirezionale tra cancro e FA, guidato da comorbilità quali età avanzata, disturbi metabolici, fluttuazioni elettrolitiche e infiammazione. Inoltre, alcuni farmaci antineoplastici possono intervenire sullo sviluppo della FA. Tra questi vi è Ibrutinib, inibitore della TK di Bruton (BTK) usato in un numero crescente di neoplasie ematologiche. BTK sul cuore regola il pathway di PI3K-Akt, che fisiologicamente protegge il cuore in condizioni di stress. Quando ibrutinib inibisce PI3K-Akt, il cuore è più soggetto a sviluppare FA. L'insorgenza di FA nel corso di terapia antineoplastica porta all'interruzione del trattamento quindi ad un aumento della morbilità in questi pazienti. L'esperienza clinica ha dimostrato che ibrutinib può essere temporaneamente sospeso e quindi reintrodotto se la FA è sotto controllo. Abbiamo dati limitati che analizzino in modo completo il burden di aritmia atriale e ventricolare nei pazienti trattati con ibrutinib e il successivo rinvio alle cure specialistiche, all'uso di farmaci antiaritmici e ai modelli di interruzione del trattamento. Tra questi farmaci alcuni possono alterare la concentrazione di ibrutinib, portando a cambiamenti di efficacia o del profilo degli effetti avversi. Da qui nasce l'attenzione per l'ablazione transcatetere (AbT) verso questi pazienti. Studi hanno evidenziato che la compresenza di neoplasia non ha alcun impatto sulla recidiva di FA dopo AbT con RF. Nonostante stiano aumentando le evidenze su sicurezza ed efficacia delle strategie più aggressive di controllo del ritmo dopo fallimento della terapia medica, ad oggi non ci sono studi che abbiano valutato sistematicamente il ruolo dell'AbT della FA nei pazienti oncologici trattati con TKI. Da ciò nasce il nostro studio pilota, che mira a valutare fattibilità, sicurezza ed efficacia dell'AbT di FA in pazienti in terapia con Ibrutinib.

A148: GENERATION AND PHENOTYPING OF A NOVEL KNOCK-IN MOUSE MODEL OF DESMOPLAKIN-DEPENDENT ARRHYTHMOGENIC CARDIOMYOPATHY

Tania Zaglia (a, b, g), Anna Di Bona (a, b), Arianna Scalco (a, b, g), Riccardo Bariani (a), Nicolas Kuperwasser (c), Pierre David (d), Rudy Celeghin (a), Mila Della Barbera (a), Kalliopi Pilichou (a), Barbara Bauce (a), Stefania Rizzo (a), Gaetano Thiene (a), Mario Pende (c, e, f), Cristina Basso (a), Marco Mongillo (b, g)
(a) DEPARTMENT OF CARDIAC, THORACIC, VASCULAR SCIENCES AND PUBLIC HEALTH, UNIVERSITY OF PADOVA, ITALY; (b) VENETO INSTITUTE OF MOLECULAR MEDICINE, PADOVA; (c) INSTITUT NECKER-ENFANTS MALADES, PARIS, FRANCE; (d) INSTITUT IMAGINE, PARIS, FRANCE; (e) INSTITUT NATIONAL DE LA SANTÉ ET DE LA RECHERCHE MEDICALE, INSERM, PARIS, FRANCE; (f) UNIVERSITÉ PARIS DESCARTES, SORBONNE, PARIS, FRANCE; (g) DEPARTMENT OF BIOMEDICAL SCIENCES, UNIVERSITY OF PADOVA, ITALY

Background. Arrhythmogenic Cardiomyopathy (AC) is a familial cardiac disorder, accounting for most cases of stress-related arrhythmic sudden cardiac deaths (SCD) in the young and athletes. AC is mainly caused by mutations in genes encoding desmosomal proteins. The AC myocardium displays cardiomyocyte (CM) death, inflammation and fibro-fatty lesions, which generate a pro-arrhythmogenic substrate. The AC pathogenesis is still obscure and better understanding of disease mechanisms is urgently needed to develop efficacious therapies to combat this underhand killer. The lexical analogy between 'desmosomes' and 'desmosomal proteins' has originally biased AC research towards 'CMs', the paradigmatic 'desmosome-bearing cells' in heart. However, the myocardium also includes sympathetic neurons, vascular cells and fibroblasts, all expressing desmosomal proteins, albeit in the absence of desmosomes. Notably, AC mutations are transmitted at germline, and thus may manifest in all cell types expressing desmosomal proteins. This might explain why the majority of AC preclinical models, based on CM specific overexpression or deletion of the disease-causing mutation, failed to fully recapitulate the clinical phenotype.
Aim. On these bases, we generated a knock-in (KI) AC mouse model for comprehensively studying AC pathogenesis.
Methods. As Desmoplakin (DSP) mutations occur in a large fraction of the Italian AC population, we generated, with CRISPR/Cas9, a KI mouse strain harboring the Ser-to-Ala point mutation, at the murine ortholog of human S299 (DSP^{S311A}). Functional and structural cardiac phenotype were characterized, at different disease stages, by ECHO, telemetry-ECG, histological, IF, ultrastructural and molecular/biochemical analyses.
Results. We obtained $DSP^{S311A/WT}$ founders, which were viable and fertile. Hearts from both $DSP^{S311A/WT}$ and $DSP^{S311A/S311A}$ mice showed desmosome alterations, particularly evident at advanced ages. $DSP^{S311A/S311A}$ hearts display CM death, tissue inflammation and fibrotic myocardial remodelling, with focal fatty lesions, which were detected in both ventricular walls. Such structural alterations were accompanied to contractile dysfunction, which worsened in time, and increased arrhythmia incidence, in both resting and adrenergic stress conditions. Heterozygous mice showed similar alterations, which only took longer to appear. Male and female mice were similarly affected, and exercise accelerated disease progression and increased the incidence of SD.
Conclusions. Our novel KI mouse strain replicates the clinical phenotype of DSP-linked biventricular AC, and is thus suited for the mechanistic study of AC pathogenesis.

ASSISTENZA CARDIACA IN ACUTO

A149: AMPIEZZA DELL'AREA SPETTRALE (AMSA) DELLA FIBRILLAZIONE VENTRICOLARE COME GUIDA PER UNA DEFIBRILLAZIONE A BASSA ENERGIA NEI PAZIENTI CON ARRESTO CARDIACO EXTRA-OSPEDALIERO

Federico Quilico (a, b), Francesca Romana Gentile (a, b), Alessandro Fasolino (a, b), Lars Vik (c, d), Elisabete Aramendi (e), Iraia Isasi (e), Jon Erik Steen Hansen (f), Baldi Enrico (a), Compagnoni Sara (a, b), Contri Enrico (g), Alessandra Palo (g), Roberto Primi (a), Sara Bendotti (a), Alessia Currao (a), Simone Savastano (a)
(a) IRCCS POLICLINICO SAN MATTEO; (b) UNIVERSITÀ DEGLI STUDI DI PAVIA; (c) OSLO UNIVERSITY HOSPITAL, DIVISION OF PREHOSPITAL EMERGENCY MEDICINE, ULLEVAL HOSPITAL, OSLO, NORVEGIA; (d) PREHOSPITAL CLINIC, OSLO UNIVERSITY HOSPITAL HF, ULLEVAL HOSPITAL, OSLO, NORVEGIA; (e) BIORES GROUP, UNIVERSITY OF THE BASQUE COUNTRY, BILBAO, SPAGNA; (f) DIVISION OF PREHOSPITAL CARE, VESTFOLD HOSIPTAL TRUST, TONSBERG, NORVEGIA; (g) AAT 118 PAVIA, AREU PRESSO IRCCS POLICLINICO SAN MATTEO, PAVIA, ITALIA

Introduzione. Il livello di energia ottimale da utilizzare per la defibrillazione non è ad oggi stato stabilito con precisione ed in assenza di indicazioni specifiche le linee guida raccomandano l'utilizzo della massima energia disponibile. Inoltre, il danno miocardico indotto dalla corrente non deve essere trascurato ed è quindi auspicabile uno sforzo per cercare di selezionare i pazienti che possono rispondere ad energie ridotte.

Scopo. Valutare se l'area dell'ampiezza spettrale (AMSA) della fibrillazione ventricolare possa guidare la scelta della quantità di energia erogata durante la defibrillazione nei pazienti con arresto cardiaco extra-ospedaliero (OHCA).
Materiali e metodi. Il nostro è uno studio multicentrico basato su dati raccolti da alcuni dei più grandi registri sull'arresto cardiaco extra-ospedaliero d'Europa. Arruola 830 pazienti con OHCA che hanno ricevuto almeno uno shock durante le manovre di rianimazione. I valori di AMSA sono stati calcolati analizzando retrospettivamente i dati raccolti dai monitor/defibrillatori Corplus 3 e LIFEPAK 12/15, utilizzando i due secondi di traccia ECG precedenti allo shock.
Risultati. Considerati gli 830 pazienti inclusi, sono stati erogati un totale di 2135 shock, da un livello di energia minimo di 150 J a un massimo di 360 J. I valori AMSA degli shock efficaci erogati a 150 J erano superiori rispetto a quelli degli shock efficaci a 360 J [13,1 (IQR 10,2- 17.1) rispetto a 11.8 (IQR 8.3-15.2) Hz×mV; p<0,01). In un'analisi multivariata corretta per tempo dall'arresto ad ogni shock, sesso, età, somministrazione di amiodarone e centro di studio, i valori di AMSA e non la dose dell'energia dello shock erano significativamente associati alla probabilità di successo dello shock [OR 5,8, (IC 95% 4,7- 7.3); p<0,01]. Dividendo gli shock totali in tre terzili basati sui valori AMSA (T1: 0,8-6,9 Hz×mV; T2: 6,9-11,8 Hz×mV; T3: 11,8-63,2 Hz×mV), il tasso di successo dello shock a energia più basse è stato significativamente più alto nel terzile con valori AMSA più alti (T3: 38% vs T2: 15% vs T1: 5%; p<0,01). In particolare nel terzo terzile, la bassa energia di shock era più efficace rispetto ad uno shock ad alta energia (38% vs 23%, p<0,001).
Conclusioni. Questo è il primo studio a identificare dati che possono aiutare a guidare il processo decisionale in merito ai livelli di energia per la defibrillazione. L'AMSA potrebbe infatti guidare la selezione dell'energia di shock al fine di ottenere una efficace ripresa di circolo spontaneo, riducendo al minimo il danno miocardico legata allo shock.

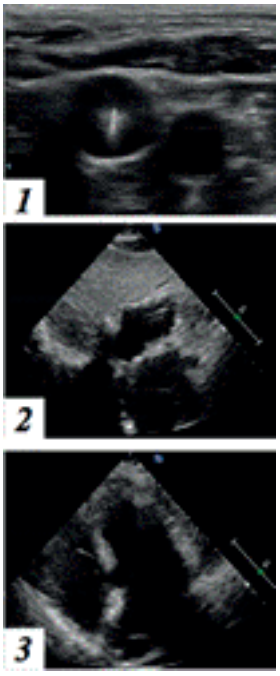

A150: ULTRASOUND-GUIDED TEMPORARY TRANSVENOUS PACING IN THE CARDIAC INTENSIVE CARE UNIT: A SINGLE-CENTER EXPERIENCE.

Cristina Cadonati (a), Caterina Facciolo (a), Alberto Limido (a), Valentina Guida (a), Katia Celentano (a), Riccardo Sgaria (a), Battistina Castiglioni (a), Roberto De Ponti (a)
(a) OSPEDALE DI CIRCOLO

Introduction. Temporary transvenous pacemaker (TTVPM) insertion is the placement of a pacing catheter in right ventricle; it's a lifesaving procedure for hemodynamically unstable patients suffering from severe bradycardia or from tachycardias refractory to medical therapy with indication to overdrive pacing. The gold-standard method of insertion relies on fluoroscopic guidance via the jugular or femoral vein; however, this technique is limited by the latency in activating the catheterization laboratory, the radiation exposure and the need for a highly-trained team. As intensive care advances and ultrasound becomes routine, the bedside ultrasound-guided technique offers a quicker alternative, bypassing traditional challenges and ensuring a timely control of the appropriate placement of the device.
Methods. We conducted a retrospective observational study at the "Ospedale di Circolo" (Varese, Italy) to compare the effectiveness of ultrasound-guided TTVPM implants in emergency settings with traditional fluoroscopic-guided implants. We included patients who underwent TTVPM insertion either with fluoroscopic monitoring in the Cath Lab by Interventional Cardiologists or using ultrasound-guidance in Cardiac Intensive Care Unit by Cardiologists specialized in Intensive. For the ultrasound method, a 5F sheath was first placed into the right internal jugular vein using the Seldinger technique and linear probe ultrasound for guidance (Picture 1). Then, a 5F bipolar electrode balloon catheter was placed in the right ventricular apex under transthoracic echo monitoring performed by a second operator, using subcostal (Picture 2) or apical view (Picture 3).
Results. From January 2021 to June 2023, 23 patients underwent TTVPM implants: 12 with fluoroscopic-guidance and 11 using ultrasound. The median age was 79 (± 9) years, and 11 patients had a cardiological history (7 had atrio-ventricular conduction delay with or without bundle branch block, 9 experiences paroxysmal atrial fibrillation). 18 (78%) implants were indicated for bradycardia: 9 non-responder to high dosage isoprenaline iv, 13 with advanced atrio-ventricular block and 5 with sinus node dysfunction. The remaining 5 patients (22%) required implants due to tachyaritmia. No major periprocedural complication occurred. However, 2 patients needed electrode repositioning after unintended displacement, attributed to patient delirium post-implant; in one case, due to anatomical difficulties, the ultrasound approach was unsuccessful and the fluoroscopic technique was needed. The median length of temporary pacing was 2.7 (1-8) days, and 18 (78%) patients received definitive transvenous pacemaker implant.
Conclusions. In emergency setting, the ultrasound-guided TTVPM implant is a safe and effective technique, that can be performed bedside. Despite it being limited by the need for a clean ultrasound view and two trained professionals, this approach could shorten the implantation time and eliminate the need for radiologic exposure.

A151: PATTERNS OF SCAI STAGES EVOLUTION IN CARDIOGENIC SHOCK PATIENTS

Luca Baldetti (a), Andrea Cesari (a), Matteo Pagnesi (b), Beatrice Peveri (a), Michela Raffo (b), Tommaso De Ferrari (a), Mario Gramegna (a), Vittorio Pazzanese (a), Roberta Rosati (b), Andrea Montisci (b), Sergio Cattaneo (b), Silvia Ajello (a), Marianna Adamo (b), Mara Scandroglio (a), Marco Metra (b)
(a) CARDIAC INTENSIVE CARE UNIT, IRCCS SAN RAFFAELE SCIENTIFIC INSTITUTE, MILAN, ITALY; (b) INSTITUTE OF CARDIOLOGY, DEPARTMENT OF EXPERIMENTAL AND APPLIED MEDICINE, UNIVERSITY OF BRESCIA, BRESCIA, ITALY

Background. Cardiogenic shock (CS) is a dynamic condition, and the Society for Cardiovascular Angiography and Interventions (SCAI) CS stages have been proposed to capture the trends in improvement or worsening after CS diagnosis. However, variations in SCAI CS stages are difficult to interpret when they do not follow a steady improvement or worsening.
Objectives. We sought to characterize the clinical meaning of SCAI stages patterns of evolution within 48 hours from CS admission.
Methods. We reviewed all consecutive CS patients (2020 and 2022) from two tertiary Intensive Care Units (ICU). Patients on SCAI A-stage, post-cardiotomy and obstructive shock were excluded. SCAI stage assessment was performed at the prespecified timepoints of baseline, six, twelve, twenty-four, forty-eight hours from ICU admission. Analyses were performed with RStudio.
Results. We included 90 patients from a total cohort of 117 screened patients. Median age was 74 (63-80) years, 67% were males. CS was caused by ACS in 46%. Upon admission, SCAI class B, C, D and E, were observed in 10%, 67%, 4% and 19%. In-hospital mortality was 33.3%. Median LVEF was 25 (20-35) % and eGFR was 36 (21-56) ml/min/1.73 m^2. Within the prespecified timepoints we identified the following patterns of SCAI stage evolution: any stage improvement ("Impr"; 32.2%), any stage improvement followed by worsening ("Impr>Wors"; 6.7%); any stage worsening followed by improvement ("Wors>Impr"; 31.1%); any stage worsening ("Wors"; 11.1%) and no stage variations ("Still"; 18.9%). These patterns of evolution were associated with different in-hospital mortality (3.4 vs 66.7 vs 35.7 vs 100 vs 29.4%; p<0.001). Notably, Still patients demonstrated strikingly different mortality based on admission SCAI CS stage (admission SCAI B 0%; SCAI C 15.4%; SCAI D NA [no cases observed]; SCAI E 100%). ICU mortality (3.4 vs 50.0 vs 21.4 vs 100 vs 23.5%; p<0.001) and need of tracheostomy (0 vs 33.3 vs 10.7 vs 0 vs 0%; p=0.012) were also different across groups. Finally, a higher proportion of patients experiencing Impr, Impr>Wors and Wors>Impr trajectories received Impella support (10.3 vs 33.3 vs 25.0 vs 0 vs 0; p=0.045). A different hospital stay was observed based on the patterns of SCAI evolution: Impr 20.0 (10.0, 28.5) vs Impr>Wors 52.0 (5.0, 70.0) vs Wors>Impr 21.0 (14.3, 28.0) vs Wors 2.0 (2.0, 5.0) vs Still 17.0 (9.5, 23.0) days; p<0.001.
Conclusions. In patients with CS, different mortality may be expected based on SCAI pattern of evolution within the first 48 hours. Patients who improve early show the least mortality, patients who worsen - from the beginning of after a period of improvement - the highest, patients lingering on the same SCAI CS stage demonstrate high mortality only if in SCAI E stage.

A152: EARLY REPEATED ASSESSMENT TO PREDICT CARDIOGENIC SHOCK PATIENTS' TRAJECTORY

Matteo Pagnesi (b), Michela Raffo (b), Beatrice Peveri (a), Vincenzo Rizza (a), Andrea Cesari (a), Andrè Frias (a), Emiliano Calvi (b), Francesco Ravasio (b), Filippo Cali (b), Carlo Mario Lombardi (b), Marianna Adamo (b), Francesco Calvo (a), Stefania Sacchi (a), Silvia Ajello (a), Luca Baldetti (a), Anna Mara Scandroglio (a)
(a) CARDIAC INTENSIVE CARE UNIT, IRCCS SAN RAFFAELE SCIENTIFIC INSTITUTE, MILAN, ITALY; (b) INSTITUTE OF CARDIOLOGY, DEPARTMENT OF EXPERIMENTAL AND APPLIED MEDICINE, UNIVERSITY OF BRESCIA, BRESCIA, ITALY

Background. The best reassessment intervals of Society for Cardiovascular Angiography and Interventions (SCAI) stage after admission for cardiogenic shock (CS), and their prognostic impact, are still unknown. The element of time for reassessment would be crucial to better understand CS patients' trajectory, intended both as evolution to advanced SCAI stages and in-hospital mortality.
Objectives. Aim of this study was to assess the prognostic implication of early repeated SCAI staging upon CS patients' trajectory and in-hospital mortality.
Methods. We reviewed all consecutive CS patients (2020 and 2022) from two Italian tertiary Intensive Care Units (ICU). Patients on SCAI A stage, post-cardiotomy and obstructive shock were excluded. All clinical, SCAI stage, laboratory, echocardiographic and hemodynamic available data were included in the dataset. These data were collected at the prespecified timepoints of baseline, six, twelve, twenty-four, forty-eight hours after ICU admission. Analyses were performed with RStudio.
Results. Out of 117 screened patients, 90 met study inclusion criteria and constituted the study cohort. Median age was 74 (63-80) years, 67% were males. CS was caused by ACS in 46%. Non-ACS patients were represented by acute decompensated heart failure (38%), de novo-acute heart failure (16%), myocarditis (6%), Tako-Tsubo syndrome (1%) and valvular disease (12%). On admission, SCAI class B, C, D and E, were observed in 10%, 67%, 4% and 19%, respectively. Median LVEF was 25 (20-35) % and eGFR was 36 (21-56) ml/min/1.73 m2. In-hospital death occurred in 27%. Patients who experienced in-hospital death did not differ in terms of hours from CS onset and SCAI-stage at presentation, but were significantly older, with a worse renal function and less frequently received mechanical circulatory support (MCS). The association between increasing SCAI stages and in-hospital death steadily rose across the prespecified timepoints: at multivariate analysis, adjusted for age, sex, eGFR, and MCS use, baseline SCAI stage was not associated with in-hospital death (ORadj 1.12, 95%CI 0.58-2.14, p=0.733), six-hours SCAI stage nearly reached statistical significance (ORadj 1.91, 95%CI 1.00-3.85, p=0.053), the twelve-hours SCAI stage (ORadj 2.13, 95%CI 1.07-4.64, p=0.040), twenty-four (ORadj 5.01, 95%CI 2.16-14.77, p<0.001) and forty-eight hours (ORadj 9.63, 95%CI 3.37-46.69, p<0.001) were associated with in-hospital death. The multivariable model including sex and eGFR, age (ORadj 1.10, 95%CI 1.01-1.22, p=0.006), MCS use (ORadj 0.33, 95%CI 0.02-0.76, p=0.033) and SCAI stage at 48 hours (ORadj 9.63, 95%CI 3.37-46.7, p<0.001) had an excellent discriminatory power (ROC-AUC 93%, 95%CI 88-98%).
Conclusions. In patients with CS, repeated SCAI stage assessments after ICU admission are associated with patients' prognosis. The forty-eight hours timepoint is the most predictive one. Age, MCS use and 48-hours SCAI stage were independent predictors of hospital survival.

A153: LA COMBINAZIONE DI IPOTENSIONE E IPOPERFUSIONE DOPO IL ROSC IN AMBITO PREOSPEDALIERO È ASSOCIATA AD UN AUMENTO DEI LATTATI ALL'INGRESSO IN TERAPIA INTENSIVA E AD UNA MINORE SOPRAVVIVENZA CON BUON OUTCOME NEUROLOGICO A 30 GIORNI

Alessandro Fasolino (a), Alessandro Bagliani (b), Roberto Primi (c), Francesca Romana Gentile (a), Elisa Gianino (a), Emanuele Ambrosini (a), Federico Quilico (a), Sara Compagnoni (a), Alessia Vecchione (a), Alessandra Palo (d), Enrico Contri (d), Enrico Baldi (c), Guido Tavazzi (e), Simone Savastano (c)
(a) UNIVERSITÀ DI PAVIA, PAVIA, ITALIA; (b) IRCCS FONDAZIONE POLICLINICO SAN MATTEO, DIVISIONE DI ANESTESIA E RIANIMAZIONE, PAVIA, ITALIA; (c) IRCCS FONDAZIONE POLICLINICO SAN MATTEO, DIVISIONE DI CARDIOLOGIA, PAVIA, ITALIA; (d) AREU AZIENDA REGIONALE EMERGENZA URGENZA, AAT PAVIA, FONDAZIONE IRCCS POLICLINICO SAN MATTEO, PAVIA, ITALIA; (e) ANESTESIA E RIANIMAZIONE, DIPARTIMENTO DI SCIENZA MEDICO-CHIRURGICHE, DIAGNOSTICHE E PEDIATRICHE, ANESTESIA E RIANIMAZIONE, IRCCS FONDAZIONE POLICLINICO SAN MATTEO, PAVIA, ITALIA

Introduzione. L'indice di perfusione periferica (PI) è un indicatore non invasivo della perfusione periferica ed è definito come il rapporto tra il flusso sanguigno pulsatile e quello non pulsatile nei tessuti periferici, calcolato sull'onda sfigmica ricavata tramite un pulsossimetro standard. Il suo ruolo nella valutazione dell'affidabilità dell'ECG e nella previsione della sopravvivenza in pazienti rianimati da un arresto cardiaco extraospedaliero (OHCA) è già stato evidenziato. Il PI medio (MPI30) viene calcolato come il valore medio del PI in un monitoraggio di 30 minuti dopo il ritorno della circolazione spontanea (ROSC). L'ipotensione arteriosa è comune dopo il ROSC e si associa ad un aumento della mortalità. Abbiamo formulato l'ipotesi che la severità dello shock dopo il ROSC (quantificata dall'innalzamento dei lattati all'ammissione in terapia intensiva) e la sopravvivenza con buon esito neurologico (cerebral performance category <3) a 30 giorni potessero essere predette integrando i valori di MPI e di pressione arteriosa media (MAP) ottenuti durante il monitoraggio preospedaliero.
Materiali e metodi. Abbiamo svolto un'analisi retrospettiva di dati raccolti prospetticamente derivanti dal nostro registro Utstein degli arresti cardiaci. Tra 272 pazienti post-ROSC consecutivi ammessi in terapia intensiva (tra gennaio 2017 e dicembre 2022) i dati di monitoraggio preospedaliero post-ROSC MPI30 e pressione arteriosa erano disponibili in 105 pazienti: 77 (73%) maschi; età mediana 65 anni (IQR 53-75). Il PI è stato misurato automaticamente e continuativamente dal pulsossimetro del monitor/defibrillatore manuale (Corpuls di GS Elektromedizinische Geräte G. Stemple GmbH, Germania); la pressione arteriosa è stata misurata a livello dell'arteria brachiale con un bracciale dedicato. I pazienti sono stati divisi in terzili in base al valore del MPI30 (T1 0.1-0.95, T2 0.98-2.03, T3 2.09-6.78). Per quanto riguarda la pressione arteriosa, i pazienti sono stati definiti ipotesi per valori di MAP inferiore a 63 mmHg in almeno una registrazione.
Risultati. I livelli di lattati nei pazienti con valori bassi di MPI30 (T1) erano maggiori rispetto ai pazienti con valori più alti di MPI30 (T2-T3) [valore mediano 5.1 (IQR 3.5-10) vs 3 (IQR 2-7.1), p<0.05]. I pazienti ipotesi avevano livelli di lattati più alti all'ammissione rispetto ai pazienti normotesi [valore mediano 5.8 (IQR 2.9-9.9) vs 2.8 (IQR 1.7-5.25), p<0.05]. Abbiamo quindi considerato il sottogruppo di pazienti con entrambe queste caratteristiche ad alto rischio (MPI30 in T1 e ipotensione – definito come gruppo "shock") e lo abbiamo confrontato con i pazienti con una sola o nessuna di queste caratteristiche (gruppo "controllo"). I pazienti del gruppo shock mostravano livelli di lattati più alti all'ammissione [valore mediano 7.8 (IQR 4.5-11.7) vs 3.6 (IQR 2-7.2), p<0.05] e una minore sopravvivenza con buon esito neurologico a 30 giorni alla regressione di Cox (HR 2.35, 95% CI 1.27-4.34, p<0.05) rispetto ai pazienti del gruppo di controllo.
Conclusioni. L'associazione di ipotensione e ipoperfusione in ambito preospedaliero identifica un sottogruppo di pazienti con il più alto rischio di iperlattacidemia all'ingresso in terapia intensiva e di scarsa sopravvivenza con buon esito neurologico a 30 giorni.

A154: ANALYSIS OF OUT-OF-HOSPITAL CARDIAC ARRESTS IN THE PROVINCE OF VARESE IN THE 2020-2022 TRIENNIUM

Carlo Arnò (a), Andrea Piemonti (a), Paola Genoni (a), Michele Golino (a), Enrico Baldi (b, c), Simone Savastano (b, c), Roberto De Ponti (a)
(a) UNIVERSITÀ DEGLI STUDI DELL'INSUBRIA, VARESE; (b) UNIVERSITÀ DEGLI STUDI DI PAVIA; (c) FONDAZIONE I.R.C.S.S. POLICLINICO SAN MATTEO DI PAVIA

Background. Out-of-Hospital Cardiac Arrests (OHCAs) are time-dependent medical emergencies with a considerable socioeconomic impact on the various health systems around the globe. A well-structured pre-hospital management is essential to guarantee a prompt intervention, which is then crucial in determining the prognosis of the patient and the possible neurological outcome. Therefore, the main factors affecting the acute survival of people suffering a OHCA must be identified to implement the adequate interventions.
Methods. We extracted data regarding OHCAs occurred in the province of Varese in the years 2020, 2021 and 2022 from the Lombardia Cardiac Arrest Registry (Lombardia CARe), a prospective registry founded in Pavia in 2014, which at the present moment covers a population of more than 4 million people. Next, we analyzed the main characteristics of the population and the factors affecting acute survival, defined as the obtainment of Return Of Spontaneous Circulation (ROSC) during the pre-hospital phase or once at the hospital.
Results. 3263 OHCAs occurred between January 1st, 2020, and December 31st, 2022, in the province of Varese: the population was predominantly male (59%) with a mean age of 78 years [RIQ 66-86]. Overall acute survival was 7.7%, reaching a maximum of 38% in the subgroup of patients in which the event was witnessed and a shockable rhythm was subsequently detected. The mean time of intervention was 13.7 minutes [RIQ 10.9-17]. Resuscitation maneuvers were attempted from the Emergency Medical System (EMS) operators in 65% of the cases, while in the remaining cases patients were declared dead at their arrival. 88% of the events occurred at home. A witness was present in 36% of cases. Bystanders performed Cardiopulmonary Resuscitation (CPR) maneuvers in 24% of cases (phone-guided by an expert EMS operator in 86% of these cases) and used an Automatic External Defibrillator (AED) on 72 (2%) patients, delivering a DC-shock in 23/72 (32%) of these cases. In a multivariate analysis, younger age (OR 0.97 [95% CI: 0.96-0.98], p-value <0.001), occurrence of the OHCA near a public building (OR 1.92 [95% CI: 1.24-2.96], p-value 0.01), presence of a witness (OR 2.65 [95% CI: 1.94-3.61], p-value <0.001), detection of a shockable rhythm (OR 7.04 [95% CI: 5.33-9.28], p-value <0.001) and occurrence outside of the main COVID-19 waves (OR 0.62 [95% CI: 0.48-0.79], p-value 0.002) were all independent factors affecting acute survival. On the other hand, in the subgroup of patients in which resuscitation maneuvers were subsequently started by the EMS once on the scene of the event, delivery of an early AED shock from bystanders was the only independent factor predicting an increase in acute survival (OR 3.14 [95% CI: 1.34-7.36], p-value 0.028).

Conclusions. Pre-hospital management of OHCAs is critical and bystanders' intervention plays a pivotal role. In our analysis, the overall acute survival was relatively low but increased substantially in cases with early detection of the event. Many efforts should be made to further increase the chance of survival of patients suffering OHCAs and they include: training the general population in the recognition of cardiac arrests and teaching them to promptly alert the EMS and to immediately start a valid CPR, creating a denser network of publicly available AEDs, encouraging a more extensive use of AEDs from bystanders.

A155: MITRACLIP PROCEDURE AS EMERGENT AND RESCUE THERAPY IN INTERMACS 2 PATIENT WITH CONTRAINDICATIONS FOR HEART TRANSPLANT/LVAD

Camilla Cirelli (a), Alice Calabrese (b), Luigi Fiocca (b), Andrea Giammarresi (b), Annamaria Iorio (b), Raul Limonta (a), Giovanni Quarta (b), Michele Senni (b), Mauro Gori (b)
(a) UNIVERSITY OF MILANO-BICOCCA; (b) ASST PAPA GIOVANNI XXIII, BERGAMO

Case description. In January 2023, a 60-years-old woman presented to the emergency department of a peripheral hospital with a sub-acute myocardial infarction involving the left anterior descending artery, complicated by cardiogenic shock. The patient had a significant smoking habit and a family history of ischemic heart disease. Transthoracic echocardiography (TTE) showed a left ventricular ejection fraction (LVEF) of 20% and severe functional mitral regurgitation (MR). An urgent coronary angiography was performed, revealing three-vessel coronary artery disease, which was successfully managed through angioplasty. After the procedure, due to the patient's hemodynamic instability, an intra-aortic balloon pump (IABP) was placed in the right femoral artery and she was referred to our hospital, a tertiary center, for evaluation of advanced therapies. Upon admission to our intensive care unit (ICU) the patient was stable in inotropic support with IABP. Physical examination revealed weak pulses in the right lower limb. TTE confirmed severely depressed LVEF (20%) and moderate-severe MR (moderate with IABP on, severe with IABP off). An urgent computed tomography angiography (CTA) revealed diffuse severe peripheral arteriopathy due to severe atherosclerosis. The IABP was replaced with a smaller balloon and introducer due to persistent ischemia in the right limb. Adrenaline 0.05 ug/kg/min and Sodium Nitroprusside 1.34 ug/kg/min were started to maintain adequate perfusion. Considering the CT scan report, the patient was discussed within the Heart Team (HT), and she was excluded from ECMO, LVAD, and HTx. Following 10 days of clinical stability, the IABP was surgically removed, and low-dose inotropic support was continued. The day after IABP removal, the patient encountered a rapid clinical deterioration and emergence of low cardiac output. TTE showed persistently depressed LV systolic function and massive MR due to a defect in leaflet coaptation (Fig 1). Upon escalating the dosage of Sodium Nitroprusside and Adrenaline, TTE promptly revealed a transient significant amelioration in MR. However, the patient remained unstable with progressive worsening of MR, despite intravenous therapy. The patient had advanced HF (INTERMACS 2) and HT decided to proceed to an emergent MitraClip implantation while receiving pharmacological inotropic support. Following the procedure, the inotropic support was gradually tapered without any hemodynamic destabilization. One-month TTE demonstrated an improvement in LV volume and LV function (LVEF 35%) with two mitral clips in place and mild residual MR (Fig 2). Medical therapy for heart failure (HF) was started and after a 60-days hospitalization period, the patient was discharged.

Conclusions. The present clinical case suggests the potential role of MitraClip as destination therapy for advanced HF patients with severe MR who are dependent on inotropic therapy and with contraindications for LVAD/HTx, facilitating weaning from intravenous therapy and achieving clinical stabilization.

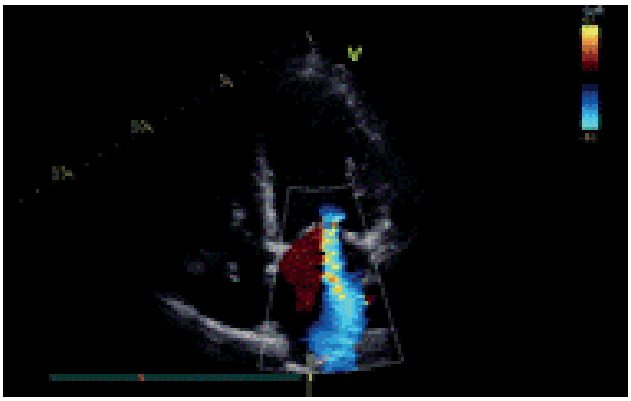

Figura 1.

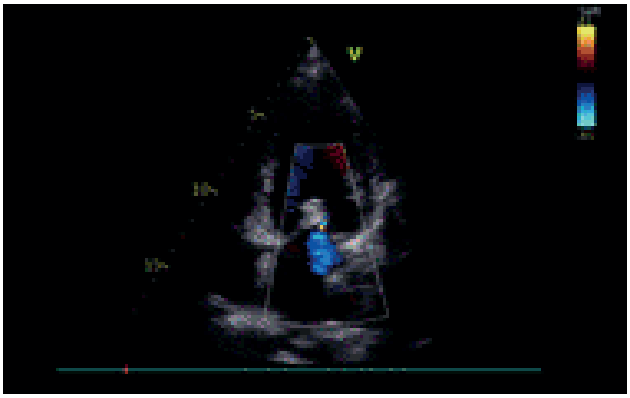

Figura 2.

A156: A RARE CASE OF SPONTANEOUS RETURN OF CIRCULATION AFTER CARDIAC ARREST AND CESSATION OF RESUSCITATION EFFORTS: THE LAZARUS PHENOMENON

Massimo Burelli (a), Virginia Favaretto (a), Federico Angriman (a), Elisabetta Daleffe (b), Gianfranco Sinagra (c), Massimo Imazio (b)
(a) POSTGRADUATE SCHOOL OF CARDIOVASCULAR MEDICINE UNIVERSITY OF TRIESTE; (b) CARDIOTHORACIC DEPARTMENT, CARDIOLOGY DIVISION, AZIENDA SANITARIA UNIVERSITARIA INTEGRATA UDINE; (c) CARDIOVASCULAR DEPARTMENT, CARDIOLOGY DIVISION, AZIENDA SANITARIA UNIVERSITARIA INTEGRATA TRIESTE

Case report. The following case involves a 73-year-old patient with a recent diagnosis of ischemic and tachy-induced heart disease with severe left ventricular disfunction who experienced a cardiac arrest due to ventricular fibrillation during a hospital stay for an infected right pleural effusion. Cardiopulmonary resuscitation (CPR) was immediately initiated following current international protocols (ACLS), with the assistance of an anesthetist who performed orotracheal intubation. A total of four defibrillator shocks, increasing in energy up to 360 J, were administered, along with three doses of adrenaline. Intermittent periods of pulseless electrical activity (PEA) were observed between shocks, but these consistently led to recurrent episodes of VF. After 30 minutes from the start of CPR, due to the absence of vital signs, the decision was made to discontinue resuscitation efforts. The patient was extubated, the absence of vital signs was confirmed once again, and the patient was declared deceased. Nine minutes after, the patient spontaneously regained vital signs. An ECG was performed, documenting the presence of sinus rhythm. During the medical evaluation, the patient spontaneously opened his eyes and responded to verbal cues. He displayed repetitive speech, confabulation, and exhibited amnesia regarding prior events. Furthermore, he exhibited spontaneous movement in all four limbs and responded to verbal commands. The patient was transferred to the Coronary Unit. At the time of the transfer, the patient was indeed alert, oriented in space and time, and cooperative. It was, therefore, decided to proceed with the implantation of an ICD for secondary prevention, a procedure that was conducted once solved the infectious issue. The patient was then discharged with a scheduled Cardiology follow-up in the near future.

Discussion. The Lazarus phenomenon (LP) is a rare event which consists in the spontaneous recovery of circulation after the cessation of the resuscitation maneuvers and the declaration of death. In the literature, 76 cases were described, 6 of whom experienced full neurological recovery. The pathophysiological basis underlying this apparently "miraculous" event is largely unknown but seems to be attributable to different mechanisms, ranging from non-recognized minimal vital signs, alkalosis, hyperkaliemia, late efficacy of administered emergency drugs, auto-PEEP to pulmonary hyperinflation with positive pressure ventilation. There is a significant heterogeneity observed among the 76 cases reported in terms of the time intervals between the initial cardiac arrest, the duration of CPR procedures, and the recovery following the cessation of resuscitation efforts. The shortest documented recovery time was 30 seconds, while the longest was 180 minutes. Additionally, there is considerable variability in the demographics of patients who have experienced LP. According to the literature, 10 cases occurred in children, with the youngest patient being only 9 months old and the oldest being 97 years old. In most of the reported LP cases, the initial rhythms observed during cardiac arrest were non-shockable, such as asystole or PEA. For all these reasons, authors propose a monitoring period ranging from 10 to 20 minutes before establishing a death diagnosis.

A157: CRITICALLY ILL PATIENT WITH DYNAMIC EKG CHANGES: WHEN AND WHY MUST WE THINK OF PROPOFOL INFUSION SYNDROME?

Laura Munaretto (a), Alessio Della Mattia (b), Gloria Marson (c), Tommaso Pellis (c), Gianfranco Sinagra (a), Daniela Pavan (b)
(a) AZIENDA SANITARIA UNIVERSITARIA GIULIANO ISONTINA, DIPARTIMENTO CARDIOTORACOVASCOLARE, TRIESTE, ITALIA; (b) AZIENDA SANITARIA FRIULI

OCCIDENTALE, S.C. CARDIOLOGIA, PORDENONE, ITALIA; (c) AZIENDA SANITARIA FRIULI OCCIDENTALE, S.C. ANESTESIA-RIANIMAZIONE E TERAPIA INTENSIVA, PORDENONE, ITALIA

Case report. The case involves a 64-year-old patient with cardiac history of paroxysmal atrial fibrillation (AF), alcohol abuse and challenging neurological past characterized by a traumatic left frontal intraparenchymal cerebral haemorrhage followed by the development of tonic-clonic epileptic seizures with right hemiparesis, treated with valproic acid. On April 26, 2023, the patient was found unconscious at home, then admitted to the Intensive Care Unit (ICU) due to a comatose state resulting from crush syndrome (elevated CPK and myoglobin levels) and subsequent oligo-anuric acute kidney injury (AKI) with a peak creatinine level of 7.08 mg/dl, hyperkalaemia of 5.5 mmol/l and metabolic acidosis with 6.5 mmol/l pH during hospitalization. After a negative brain CT angiography, the patient underwent endotracheal intubation (IOT) for airway protection. Neurological evaluation and the initial EEG were negative for epileptogenic elements. The patient was sedated with Propofol from the beginning. On April 27, upon discontinuation of sedation, a generalized tonic-clonic epileptic seizure occurred. Deep sedation was started for burst suppression using Propofol and Valproic acid, with dosage adjusted based on serial monitoring of valproate levels, reaching Propofol levels up to 3.6 mg/kg/h extended during the entire duration of hospitalization. Initially hypertensive, from May 1, there was a worsening of the general condition with hemodynamic instability and the need for incremental dosage of vasopressor support with Norepinephrine and Vasopressin. During the night between May 1 and May 2, episodes of non-sustained ventricular tachycardia (TVNS) occurred, culminating in an episode of in-hospital cardiac arrest due to pulseless ventricular tachycardia (PTV) treated with DC shock with immediate return of spontaneous circulation (ROSC) and a shift to wide QRS complex AF and repolarization changes compatible with a coved-shaped type pattern. Hemodynamic instability persisted despite additional DC shocks, leading to the need for maximal inotropic/vasopressor doses and progressive evolution towards refractory hypotension until cardiac arrest (ACC) and subsequent death.

Discussion. The incidence of PRIS (Propofol Infuson Syndrome) is difficult to determine, as there may be substantial underreporting because of unawareness of the syndrome. Its mortality rate ranges from 18 to 30%. Critical illness, most notably neurologic injury, might act as a priming factor for Propofol to trigger PRIS. Occurrence of the syndrome, as well as its severity, appears to be dose dependent, most cases occurring in patients who receive a Propofol dose in excess of 4 mg/kg/hr (80 µg/kg/min) for at least 48 hours. PRIS typically presents as severe rhabdomyolysis, acute kidney injury, hyperkalemia, metabolic acidosis, and hepatomegaly. Myocardial injury may occur in severe forms, presenting with various ECG changes, including Brugada-like pattern and coved-type ST-segment elevations, severe arrhythmias and cardiovascular collapse. PRIS probably occurs as a result of mitochondrial dysfunction. Anyway, PRIS is always a presumed diagnosis, signs and symptoms are nonspecific especially in the absence of a definitive diagnostic test.

A158: UNA SPINA NEL FIANCO: UN CURIOSO CASO DI SINDROME DI TAKO-TSUBO

Lorenzo Nocera (a), Alessandro Galluzzo (b), Silvia Mazzilli (b), Federica Bongiovanni (b), Sara Rettegno (b), Gaetano Maria De Ferrari (a), Maurizio D´amico (b)
(a) DIVISION OF CARDIOLOGY, CARDIOVASCULAR AND THORACIC DEPARTMENT, "CITTÀ DELLA SALUTE E DELLA SCIENZA" HOSPITAL, TURIN, ITALY; (b) REPARTO DI CARDIOLOGIA E TERAPIA INTENSIVA CARDIOLOGICA, OSPEDALE "SANTA CROCE", MONCALIERI, ITALIA

Introduzione. La sindrome di Tako-Tsubo (TTS) è una disfunzione cardiaca dovuta a discinesia segmentaria transitoria del ventricolo sinistro. La presentazione più comune è con angina pectoris, modifiche ECG e aumento dei marker di miocardiocitonecrosi. Il decorso della TTS è caraterizzato da una mortalità intra-ospedaliera comparabile agli STEMI e un tasso di morte per tutte le cause del 5,6% per paziente-anno. Oltre alle forme idiopatiche, è descritta un'associazione con alcune malattie organiche correlate all'ipersecrezione di catecolamine come il feocromocitoma che rientra tra le cause di TTS secondaria.

Caso clinico. Donna di 48 anni con indicazione ad isteroerectomia laparoscopica. In corso di intervento evidenza di crisi ipertensiva con tachicardia sinusale per cui si passava ad induzione da desflurano a sevoflurano e si richiedeva una consulenza cardiologica: all'ecocardiografia transtoracica si osservava severa riduzione di FE (20%) con acinesia medio-apicale e ipercinesia dei segmenti basali, senza ostruzione all'efflusso ventricolare sinistro (LVOTO). L'intervento veniva convertito in laparotomia e concluso senza complicanze. All'arrivo in terapia intensiva cardiologica, quadro di shock cardiogeno SCAI C, all'ECG sopraslivellamento del tratto ST nelle derivazioni precordiali con T negative in V4-6, aumento di troponina (hsTnI 6656ng/L). Avviati quindi cPAP, furosemide ev a 10mg/h, levosimendan 0.05y/kg/min per 24 ore, associato a basse dosi di noradrenalina nei primi 30 minuti. Alla coronarografia evidenza di coronarie indenni e di apical ballooning: posta diagnosi di TTS. Successiva stabilità emodinamica. Durante colloquio clinico, la paziente riferiva la comparsa da alcuni anni, durante i cambi posturali, di episodi lipotimici associati a cardiopalmo di circa 1 minuto. Posto il sospetto diagnostico di feocromocitoma, confermato dal dosaggio delle metanefrine. Alla TC dell'addome evidenza di massa surrenalica sinistra inomogenea 4x4 cm (Figura 1). La paziente veniva dimessa in decima giornata post-operatoria con terapia alfa-litica a basso dosaggio e propranololo al bisogno e surrenalectomia elettiva.

Conclusioni. Il feocromocitoma ha verosimilmente causato uno storm catecolaminergico a seguito dell'intervento operatorio. È inoltre probabile che l'induzione con sevoflurano abbia acuito gli effetti delle catecolamine in quanto sensibilizzante del miocardio all'epinefrina. Avendo escluso LVOTO, la scelta terapeutica è ricaduta sull'uso di levosimendan a basse dosi, monitorando l'ipoperfusione per eventuale upgrade a supporto invasivo. La presenza di LVOTO rappresenta uno snodo decisionale cruciale, in quanto è indicato l'uso di basse dosi di b-bloccante e cauto riempimento volemico. Nel caso specifico, l'utilizzo di β-bloccanti sarebbe controindicato in presenza di feocromocitoma. In ultimo, l'associazione transitoria di noradrenalina, nonostante i vasopressori vadano evitati nelle TTS, ha avuto il razionale di bilanciare l'effetto vasodilatatore iniziale del levosimedan in presenza di severa ipotensione.

Figura 1.

A159: RIGHT-HEART FLOATING THROMBUS IN ACUTE PULMONARY EMBOLISM: MANAGEMENT DILEMMA AND LACK OF EVIDENCES

Stefano Cossu (a), Baldassare Maria Alonzo (a), Gloria Anna Varotto (a), Antonio Deidda (a), Matteo Cau (a), Mattia Casati (a), Enrica Fanni (a), Gesualdo Siracusa (a), Maria Francesca Marchetti (a), Maria Bernardetta Puddu (a), Enrico Mulargia (a), Roberta Montisci (a)
(a) AZIENDA OSPEDALIERO-UNIVERSITARIA DI CAGLIARI - POLICLINICO DUILIO CASULA

Introduction. Free-floating right heart thrombus (RHT) is an extreme medical emergency in the context of acute pulmonary embolism (APE). The optimal treatment of RHT is not established. Management decisions for RHT should be emergent and based on multidisciplinary discussion of the pulmonary embolism response team (PERT).

Case presentation. We report the case of a 32-year-old female, with a history of polycystic ovary syndrome in therapy with ethinyl estradiol/drospirenone, she had difficulty walking due to plantar fasciitis in the prior two months. The patient presented to the emergency department (ED) complaining of left hemithorax pain and syncope at rest. On arrival to the ED she was found haemodynamically stable. Electrocardiogram on admission showed sinus tachycardia, S1Q3T3 pattern, incomplete right bundle branch block. Transthoracic echocardiography revealed signs of right ventricular overload and pulmonary hypertension. Computed tomography angiogram confirmed the diagnosis of massive bilateral pulmonary embolism. Laboratory results were significant for troponin 414.98 ng/mL. Unfractioned heparin infusion was started in the ED and she was admitted in our ICCU with the diagnosis of intermediate-high risk pulmonary embolism. Two days after she performed transthoracic echocardiography which revealed a RHT attached to the tricuspid valve. About thirty minutes later emergent POCUS at bedside did not show the RHT anymore but worsening in RV overload. Immediately following that, the patient became progressively more dyspneic and tachypneic with RR 35/min, HR 150/min and a slight reduction in blood pressure (95/55 mmHg). Arterial blood gas analysis showed increased serum lactates (2.4 mEq/L). The case was discussed collectively and the decision was taken to perform fibrinolysis. The procedure was successful, with gradual improvement of her respiratory status, HR, serum lactates, and echocardiographic signs of right ventricular overload. BP remained stable without the need for vasopressors and oxygen support was slowly weaned down.

Discussion. Optimal therapeutic approach for APE and RHT is still uncertain. Multiple treatment options have been described, including anticoagulation alone, systemic thrombolysis, surgical embolectomy and endovascular catheter-based therapies. Emergent activation of PERT in order to make appropriate individualized management decisions is

mandatory. Since it is difficult to predict when clot could dislodge and move forward into the pulmonary circulation, patients with right heart thrombus should be closely watched in the monitored setting like intensive care unit. Systemic thrombolysis should be available at bedside (unless contraindicated) and be administered readily if patients show any evidence of clinical deterioration due to clot dislodgement into pulmonary circulation (vital signs, respiratory or mental status). Formal guidelines and larger studies are desirable to determine optimal management for these cases.

A160: IMPELLA CP DEVICE AS CRUCIAL SUPPORT IN THE UNSTABLE PATIENT WITH SEVERE LEFT VENTRICULAR DYSFUNCTION CAUSED BY RESPIRATORY FAILURE

Matteo De Carli (a), Mauro Chiarito (a)
(a) HUMANITAS UNIVERSITY

Background. Mechanical circulatory support (MCS) devices, such as the Impella CP, may be necessary to improve the hemodynamic status and respiratory exchanges in patients presenting with cardiogenic shock or undergoing complex and high-risk procedures. However, the role of MCS in patients presenting with severe left ventricular dysfunction secondary to respiratory insufficiency is poorly described.

Case summary. A 58-year-old man with type 2 diabetes, no prior cardiovascular history, presents to the emergency department with acute pulmonary edema due to hypertensive crisis, in turn resulting in acute global respiratory insufficiency. As initial respiratory support, NIV with continuous positive airway pressure (CPAP) was administered, with PEEP 8. Blood pressure (BP) was 220/120 mmHg, heart rate (HR) 140 bpm, SpO2 84% with FiO2 100%. Due to limited benefit of CPAP, bilevel positive airway pressure was administered (PS 10, PEEP 10, FiO2 85%, RR 25-30, with VT 550), but failed to improve hypoxia and hypercapnia: arterial blood gas analysis (ABG) showed a pH of 7.21, pCO2 47, pO2 54, Lac 2.8, with normal range of electrolytes. Urapidil, nitro derivative and a diuretic were started, leading to a reduction of BP to 170/90 mmHg. In light of neurological deterioration, tracheal intubation was performed, resulting in a slow improvement in gas exchange (pH 7.21, pCO2 52, pO2 91). ECG showed sinus tachycardia and Q wave in inferior leads. On echocardiography, severe LV dysfunction was observed, with an ejection fraction (EF) of 10-15%. In few minutes, there was a progressive deterioration of the hemodynamic, and infusion of dobutamine and noradrenaline was initiated with limited improvement of BP. The patient was transferred to the cath lab, with a persistent respiratory failure associated with hemodynamic instability despite inotropic support and vasopressor (LVEDP 23 mmHg, BP 80/50, HR 98). Consequently, an Impella CP was implanted, resulting in a rapid improvement in hemodynamics, with a BP 120/70 and HR 80. After confirming the correct positioning of the device, coronary angiography was performed, revealing triple-vessel disease. Angioplasty was carried out with the implantation of a single drug-eluting stent in the circumflex artery- marginal obtuse vessel with a procedural success and no complications. At the conclusion of the hemodynamic procedure, the patient remained stable with a gradual improvement in respiratory exchange. The post-procedure ABG showed a pH 7.30, pO2 71, and pCO2 41. Four days after the procedure, a significant improvement of left ventricular function was observed, the patient was extubated with progressive weaning from ventilatory support, and after a few hours, the Impella device was removed. One week after the procedure, the patient was asymptomatic, in good cardiovascular and respiratory condition. Pre-discharge echocardiography showed a left ventricular ejection fraction of 42%. Inizio moduloFine modulo

Discussion. In this case, hemodynamic support with the Impella CP device helped to stabilize an intubated patient with severe left ventricular dysfunction due to respiratory failure, limited the risk of PCI performed in such setting, and ensure rapid extubation. The use of hemodynamic support devices allows for left ventricular unloading, limiting wall stress and myocardial oxygen consumption, as well as a decrease in pulmonary congestion, resulting in a significant improvement in respiratory exchange.

A161: DUAL MECHANICAL SUPPORT IN CARDIOGENIC SHOCK: COMBINED USE OF INTRA-AORTIC BALLOON PUMP AND IMPELLA

Jacopo Farina (a), Simone Biscaglia (a)
(a) UNIVERSITÀ DI FERRARA

A 73-year-old man, dyslipidemic, with a history of asymptomatic pulmonary fibrosis and without any previous cardiac history, access to the emergency room for dyspnea and epigastric pain. Symptoms started twenty hours earlier.

Initial work up. At first evaluation patient was hemodynamically stable. The ECG showed: SR,75 bpm, ST elevation in DI, aVL and V7-V9 with ST depression in V1-V3. The first artery blood analysis showed metabolic acidosis (pH 7.2, pO2 84, pCO2 37, sO2 95, BE -8, Lac 5) so NIV was started. At echocardiographic evaluation we found a non dilated left ventricle with reduced ejection fraction (35%), a postero-lateral and apical akinesia with inferior hypokinesia and a severe functional mitralic regurgitation. Therefore the patient was admitted in emergency to our Cardiac Intensive Care Unit for STEMI complicated by pulmonary oedema.

Diagnosis and management. Because of initial hemodynamic instability adrenalin and noradrenalin were started. In Cath Lab: right coronary artery showed a critical stenosis at the middle segment (TIMI 3 flow), left anterior descending artery has a critical stenosis at the middle segment (TIMI 2 flow), the culprit lesion was circumflex artery, obstructed at the ostium by a massive thrombus. Before PCI, IABP was placed via right femoral access and the patient was intubated. Thrombus aspiration and several dilatations were performed, achieving a TIMI flow 2-3 in the cirumflex artery. After the placement of three drug-eluting stents in overlap from the middle-distal segment to the ostium no-reflow phenomenon occurs. Infusion of tirofiban was started. Due to the rapid worsening of patient's conditions, still in cardiogenic shock with acidosis and high lactates levels, we decide to place Impella via left femoral artery. After placement of Impella a TIMI flow 2 was reached. At the end of procedure PA was 85/60 mmHg and artery blood sample analysis showed mixed acidosis (pH 7.1, pO2 72, pCO2 63, HCO3 15, SO2 89%, Lac 8,1).

Follow-up. At echocardiographic control the ejection fraction was poorly reduced (15%), the EKG showed infero-lateral Q waves. We stopped tirofiban infusion because of the evidence at fibroscopy of alveolar hemorrhage. Adrenalin and noradrenalin were still in infusion, Impella had a flow of 3 ml/min and IABP was synchronized 1:1. The patient was completely dependent on Impella and IABP support. Despite a good angiographical result, and an intensive MCS our patient died few hours later. The late presentation caused the shift from hemodynamic to hemometabolic shock, which is testified by the important lactate elevation, in those cases recovery of hemometabolic compensation is unlikely. Another reason was due to a frequently misdiagnosed complication of tirofiban infusion: alveolar hemorrhage. The combined use of Impella and IABP is usually not recommended. Although it is possible to assume an enhanced hemodynamic support with the combined use of IABP and Impella, in particular regarding cerebral and coronary perfusion and the balance of myocardial oxygen demand/supply, we have to consider possible sides effects reported by manufacturer of Impella (Abiomed). There are not enough evidence to determine the clinical weight of the combined use, futher studies will be necessary.

A162: MIXED SHOCK COMPLICATING CARDIOGENIC SHOCK: PREVALENCE, PREDICTORS AND CLINICAL OUTCOMES

Gaia Filiberti (a, b), Luca Baldetti (b), Guglielmo Gallone (d), Luca Pescarmona (e), Andrea Cesari (a, b), Vincenzo Rizza (a, b), Edoardo Roagna (d, e), Beatrice Peveri (b), Lorenzo Nocera (d, e), Lorenzo Cianfanelli (b), Gianluca Marcelli (d, e), Giulia De Lio (d), Paolo Boretto (d), Filippo Angelini (d), Mario Gramegna (b), Vittorio Pazzanese (b), Stefania Sacchi (b), Francesco Calvo (b), Silvia Ajello (b, c), Gaetano Maria De Ferrari (d, e), Simone Frea (d, e), Mara Scandroglio (b, c)
(a) VITA-SALUTE SAN RAFFAELE UNIVERSITY - MILANO; (b) CARDIAC INTENSIVE CARE UNIT - IRCSS SAN RAFFAELE HOSPITAL - MILANO; (c) CARDIOTHORACIC INTENSIVE CARE UNIT - IRCSS SAN RAFFAELE HOSPITAL - MILANO; (d) DIVISION OF CARDIOLOGY, CARDIOVASCULAR AND THORACIC DEPARTMENT, CITTÀ DELLA SALUTE E DELLA SCIENZA HOSPITAL - TORINO; (e) DEPARTMENT OF MEDICAL SCIENCES, UNIVERSITY OF TURIN - TORINO

Patients presenting with cardiogenic shock (CS) are at risk of development of a mixed shock phenotype (MS), characterized by distributive-inflammatory features. We assessed the prevalence, predictors and prognostic relevance of MS complicating CS in two Italian referral centers, based on a newly proposed objective MS definition leveraging on longitudinal changes in hemodynamics and clinical parameters. Two-hundred patients hospitalized with CS (67±13 years, 27% females, 96% SCAI-CS stage ≥C) at two cardiac intensive care units were included. MS complicating CS was defined as an hemo-metabolic shock state secondary to both an ongoing cardiogenic cause, and a distributive-inflammatory phenotype arising at least 12 hours after the initial CS diagnosis. MS complicating CS occurred in 24.5% after 120 (29-216) hours from CS diagnosis. Lower systolic arterial pressure (p=0.043), hepatic injury (p=0.049), and positive microbial cultures (p=0.013) at CS diagnosis were independent predictors of MS development. Hospital mortality (53.1 vs 27.8%; p=0.002) and hospital stay [21 (13, 48) vs 17 (9, 27) days; p=0.018] were higher in the MS cohort. At logistic multivariable analysis, MS diagnosis (OR 3.00; 95%CI 1.39-6.63; p_{adj}=0.006), age (OR 1.06; 95%CI 1.03-1.10; p_{adj}<0.001), admission systolic arterial pressure <100 mmHg (OR 2.41; 95%CI 1.19-4.98; p_{adj}=0.016), and admission serum creatinine (OR 1.61; 95%CI 1.19-2.26; p_{adj}=0.003) conferred higher odds of in-hospital death, while early temporary mechanical circulatory support use (OR 0.36; 95%CI 0.17-0.75; p_{adj}=0.008) reduced the odds of in-hospital death. To conclude, MS complicating CS occur in one fourth of CS patients. Markers of CS severity and inflammatory state at CS diagnosis are predictors of subsequent MS development and indicate a poorer prognosis for hospital mortality. Early targeted treatment for CS is crucial to prevent MS.

A163: THE USE OF PULMONARY ARTERY CATHETER TO GUIDE THE DECISION MAKING IN CARDIOGENIC AND SEPTIC SHOCK: A CLINICAL CASE

Nastasia Mancini (a), Maria Vittoria Matassini (b), Matilda Shkoza (b), Luca Angelini (b), Giulia Pongetti (b), Ilaria Battistoni (b), Matteo Francioni (b), Alessandro Bontempo (c), Roberto Manfredi (c), Martina Benedetti (b), Leonardo Belfioretti (b), Gian Piero Perna (b), Marco Marini (b)

(a) DIPARTIMENTO DI MEDICINA CLINICA E SPERIMENTALE, UOC DI CARDIOLOGIA CON UTIC, UNIVERSITÀ DEGLI STUDI DI MESSINA, MESSINA, ITALIA; (b) DIVISIONE DI CARDIOLOGIA, DIPARTIMENTO CARDIOVASCOLARE, AZIENDA OSPEDALIERO UNIVERSITARIA OSPEDALI RIUNITI DI ANCONA, ANCONA, ITALIA; (c) CLINICA DI CARDIOLOGIA E ARITMOLOGIA, DIPARTIMENTO CARDIOVASCOLARE, UNIVERSITÀ POLITECNICA DELLE MARCHE, ANCONA, ITALIA

A 53 years old man, with history of smoking, arterial hypertension and with no previous cardiovascular events, referred to our emergency department complaining of dyspnoea and weakness for about five days. On the ECG evidence of atrial fibrillation (AF) with high ventricular response and signs of advanced anterior myocardial infarction with persistence of ST segment elevation. After electrical cardioversion onset of cardiogenic shock with multiorgan damage (anuria, spontaneous INR 2.7, lactates 13.6 mmol/l, TnI-hs negative, MAP 78 mmHg). Transthoracic echocardiogram showed severe ventricular dysfunction (EF 20%) with left ventricular thrombosis and severe mitral regurgitation with need for inotropes and vasopressors. The patient was transferred to the Coronary Care Unit. Coronary angiography showed chronic occlusion of the left anterior descending artery and right coronary artery without indication for myocardial revascularization due to lack of myocardial vitality and presence of collateral circles. We decided to use mechanical circulatory support with intra-aortic balloon pump (IABP) and right heart catheterization with Swan-Ganz catheter through right internal jugular vein. Swan-Ganz catheter parameters showed (CI 2 l/min/mq, SVR 1000 dyn; PCWP 20 mmHg, CPO 0.58 W, CPI 0.28 W/mq, PAPi: 1) so we started adrenaline (0.05 y/kg/min) and renal replacement therapy with CVVHD. Despite the progressive clinical improvement with the possibility of IABP removal and discontinuance of CVVHD, the patient experimented increase in inflammation indices, fever, acute respiratory distress with need for orotracheal intubation, hemodynamic instability complicated by electrical storm and increase of lactates (5.4 mmol/l). An abdominal CT scan showed intestinal ischemia in a clinical status of mixed shock (cardiogenic and septic shock) with need of IABP and CVVHD with a specific filter "Cytosorb". Swan-Ganz parameters showed: PVC 18 mmHg, CO 6 l/min, CPO 1 W, PAPi 0,8 with SvCO2: 72%, Delta AV CO2: 9 mmHg, lactates: 2,8 mmol/l. The patient modified shock phenotype from cardiogenic shock to septic shock dominated by severe right ventricular dysfunction. After noradrenaline use in the predominant septic phase of the combined shock, thanks to Swan Ganz parameters, we succeeded in reducing noradrenaline and insert enoximone with rapid clinical improvement after about 24 hours (P/F 440, lactates 2.3 mmol/l, PAPi 1,1, PVC 12 mmHg). With our clinical case we want to demonstrate that hemodynamic parameters obtained with a pulmonary artery catheterization can facilitate clinical decision-making, allow customization of a treatment plan, and guide optimization of therapy; specifically, data show that the greater the number of inotropes and vasopressors used, the worse the outcome in cardiogenic shock.

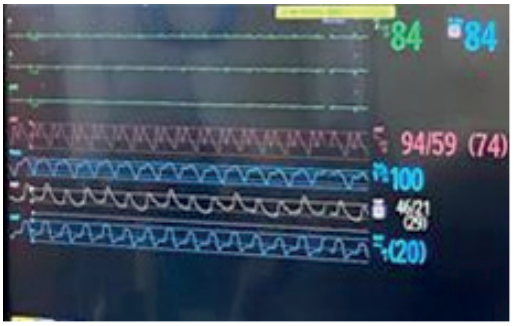

A164: EFFECT OF LEVOSIMENDAN ON WEANING FROM INTRA AORTIC BALLOON PUMP IN HEART FAILURE RELATED CARDIOGENIC SHOCK: A SINGLE CENTER EXPERIENCE

Stefano Pedroli (a), Stefania Sacchi (b), Luca Baldetti (b), Carmine Galdieri (a, b), Giuseppe Barone (a, b), Vincenzo Rizza (a, b), Mario Gramegna (b), Francesco Calvo (b), Silvia Ajello (b), Anna Mara Scandroglio (c), Vittorio Pazzanese (b)

(a) UNIVERSITÀ VITA SALUTE SAN RAFFAELE-MILANO; (b) CARDIAC INTENSIVE CARE UNIT - IRCCS SAN RAFFAELE HOSPITAL- MILANO; (c) CARDIOTHORACIC INTENSIVE CARE UNIT- IRCCS SAN RAFFAELE HOSPITAL- MILANO

Background. Intra-aortic balloon pump (IABP) use for the treatment of heart failure-related cardiogenic shock (HF-CS) is increasing. However, how to best wean patients from IABP is currently unknown. Levosimendan is able to improve ventriculo-arterial coupling (VAC) and may represent the ideal agent in this setting.

Purpose. We aimed to evaluate the effect of Levosimendan upon IABP weaning in HF-CS patients.

Methods. In this single-centre retrospective study, we included 47 patients with HF-CS undergoing IABP and admitted to our Cardiac Intensive Care Unit, between January 2020 and April 2023.

We compared 22 patients (47%) who received Levosimendan before IABP removal (Levo group) with 25 patients (53%) did not (No Levo group). The attending physician did the choice of Levosimendan case by case. For each patient, we analyzed clinical, laboratory and hemodynamic data.

Study primary endpoint was the composite of 30-days overall mortality and necessity of temporary Mechanical Circulatory Support (tMCS) reinsertion. Secondary endpoint were IABP duration, length of stay (in-hospital and in ICU), LVAD implant and major adverse events (vascular and bleeding).

Results. There were no statistical differences in clinical characteristics, except for the younger age (64 ± 16 vs 76 ±7 years, p=0.001) and lower serum creatinine values at pre-weaning (2.19 ± 1.76 vs 1.2 ± 0.48 p=0.025, p=0.025) of Levo group. Although Levo group had a lower LVEF at baseline (18 ± 4.18 vs 26.76 ± 8.1, p=0.001), it reached a non-different value at post-weaning examination (29.3 ± 13 vs 35.7 ± 13.7, p=0.147). Levo group showed a significantly higher rate of right ventricular disfunction at baseline (95% vs 68%, p=0.025); this difference decreased becoming non-different in pre-weaning evaluation (40% vs 36%, p=0.771). Furthermore, Levo group showed a lower PAPs value at pre-weaning examination (32.7 ± 9.1 vs 39.4 ± 10.5, p=0.034), while it was non-different at baseline evaluation (54.5 ± 14.1 vs 48 ± 15.7, p=0.154). There were not statistically significant differences in terms of primary and secondary endpoint between the two groups. The incidence of 30-days mortality was 32% patients in the No Levo and 9% for the Levo group (p=0.078).

Conclusions. Although our study did not achieve primary and secondary endpoint, Levosimendan use had a great effect on reversing the right ventricular failure and decreasing PAPs. This retrospective study may provide a rationale for a levosimendan-based strategy to enhance IABP weaning in HF-CS increasing chances for patients presenting with biventricular dysfunction or worse RV function to become eligible for weaning.

A165: UNA GRAVIDANZA MOVIMENTATA

Tommaso Semino (b), Silvia Tanda (b), Matteo Schettino (b), Alberto Valbusa (a), Andrea Macchione (a), Italo Porto (a, b)

(a) CARDIOVASCULAR DISEASE UNIT, IRCCS OSPEDALE POLICLINICO SAN MARTINO, GENOVA, ITALY; (b) DEPARTMENT OF INTERNAL MEDICINE, UNIVERSITY OF GENOVA, GENOVA, ITALY

Background. Lo scompenso cardiaco sintomatico in gravidanza si associa ad elevata mortalità perinatale e materna, rappresentando una sfida per ginecologo, cardiologo e neonatologo. Descriviamo nel seguente abstract il caso di una donna gravida, che accede presso l'unità di terapia intensiva cardiologica (UTIC) del nostro Policlinico per shock cardiogeno.

Caso clinico. La paziente, donna di 36 anni gravida alla 30° settimana, accede nel Pronto Soccorso del centro spoke per episodi febbrili, insorti da circa un mese, resistenti a I linea di antibioticoterapia avviata al domicilio. In anamnesi riferisce una gravidanza a termine, complicata da pre-e-

clampsia, tre anni prima; non ulteriori precedenti clinici. Trasferita in Ginecologia, esegue gli esami strumentali, laboratoristici, colturali e sierologici di I linea, che risultano negativi per infezione in atto. Durante il ricovero si verifica un episodio di dolore toracico atipico, con accertamenti cardiologici (ECG, ecocardiogramma transtoracico – ETT, ed enzimi cardiaci) negativi. Per persistenza di febbre nonostante II linea di antibioticoterapia, la paziente viene centralizza nel reparto di Ginecologia dell'ospedale hub, dove prosegue la diagnostica infettivologica e ginecologica. Al IV giorno di ricovero, nel tardo pomeriggio, si verifica un episodio di dolore toracico oppressivo con comparsa all'ECG di sopraslivellamento del tratto ST in sede anteriore. I prelievi seriati di HS-TNI mostrano un aumento significativo (a 0h: 26 ng/L, a 2h: 7060 ng/L) e l'ETT riscontra una funzione ventricolare sinistra (FEVS) severamente ridotta (25%) per acinesia dei segmenti medio-basali, con ipercinesia apicale e dei segmenti distali. La paziente viene trasferita in UTIC nel sospetto di dissezione coronarica acuta. Nelle ore successive si assistite a rapido deterioramento emodinamico per cui, vista l'impossibilità di ricorrere a farmaci inotropi per rischio di vasocostrizione placentare, si decide di posizionare contropulsatore aortico (IABP), senza tuttavia beneficio su pressione, clearance lattati e FEVS (15%). Dato il quadro rapidamente progressivo, si opta per espletare nella notte parto cesareo urgente, seguito da posizionamento di ossigenatore a membrana extracorporea (ECMO) veno-arterioso. Il neonato, dopo rianimazione efficace, viene trasferito in terapia intensiva (APGAR al 1'=1, al 10'=8). Il giorno seguente si esegue TC cuore che mostra circolo coronarico pervio e privo di flap di dissezione, in presenza di late iodine enhacement (LIE) subepicardico, nei segmenti basali di setto e parete infero-laterale. Esclusa la dissezione coronarica, la diagnosi differenziale si pone tra cardiomiopatia peripartum, miocardite fulminante e sindrome di Tako-tsubo reverse. Considerando la modalità di presentazione e reperti di LIE, l'ipotesi di miocardite fulminante appare la più probabile. Si inizia, pertanto, terapia steroidea con beneficio sul profilo emodinamico ed ecografico. Alla rimozione del supporto meccanico viene eseguita RM cardiaca, che mostra FEVS 53%, ipocinesia settale medio-basale, edema settale medio-basale, late gadoliunium enhancement subepicardico di parete laterale basale e aumento del segnale T1 di tutte le pareti ai tratti medio-basali, confermando il sospetto di miocardite. La paziente è stata dimessa con terapia anti-remodelling e antinfiammatoria; al follow-up a un mese l'ETT mostra FEVS 55%, senza regionalità.

Conclusioni. In questo abstract abbiamo voluto discutere il ragionamento diagnostico, la gestione della terapia medica e dei supporti meccanici al circolo, in corso di shock cardiogeno in gravidanza, secondario a miocardite fulminante, che ha necessitato di supporto al circolo con IABP, espletamento di parto cesareo urgente e successivo posizionamento di ECMO.

A166: MECHANICAL CARDIOPULMONARY RESUSCITATION DEVICES: EVIDENCE SYNTHESIS WITH AN UMBRELLA REVIEW

Angela Buonpane (a), Carlo De Innocentiis (d), Marco Bernardi (c), Marco Borgi (e), Luigi Spadafora (c), Francesco Burzotta (a), Carlo Trani (a), Giuseppe Biondi Zoccai (b)

(a) DEPARTMENT OF CARDIOVASCULAR SCIENCES, FONDAZIONE POLICLINICO UNIVERSITARIO A. GEMELLI IRCCS, ROME; (b) DEPARTMENT OF MEDICAL-SURGICAL SCIENCES AND BIOTECHNOLOGIES, SAPIENZA UNIVERSITY OF ROME, LATINA; (c) DEPARTMENT OF CLINICAL, INTERNAL MEDICINE, ANESTHESIOLOGY AND CARDIOVASCULAR SCIENCES, SAPIENZA UNIVERSITY OF ROME, ROME; (d) RESPONSIBLE RESEARCH HOSPITAL, CAMPOBASSO; (e) DEPARTMENT OF CLINICAL AND EXPERIMENTAL MEDICINE, POLICLINICO "G. MARTINO", UNIVERSITY OF MESSINA

Background. Sudden cardiac arrest is a significant cause of death worldwide and raises global concern. Prompt and good quality cardiopulmonary resuscitation (CPR) increases the survival of patients with cardiac arrest. Manual cardiopulmonary resuscitation is often ineffective as the rescuer may experience physical and mental fatigue. Mechanical CPR devices are designed to address this issue, providing an automated approach for high-quality CPR. We aimed at summarizing the current evidence base on mechanical CPR devices with a comprehensive umbrella review.

Methods. We searched systematic reviews on mechanical CPR devices in MEDLINE/PubMed (search last updated on September 29, 2023 using the following string: mechanical AND ((cardiopulmonar* AND resuscitat*) OR (cpr)) AND device* AND systematic[sb]). Retrieved reviews were abstracted, appraised for reporting quality and methodological validity, and summarized. Effect estimates were obtained from original reports, including 95% confidence intervals and p values, when applicable and available, focusing on return of spontaneous circulation (ROSC), survival to discharge or 30 days, survival with good neurologic outcome, and CPR-related injuries.

Results. From an initial set of 21 potentially pertinent entries, we shortlisted 7 reviews, including between 5 and 22 studies, and 689 and 18474 patients. AutoPulse, LUCAS, and LUCAS-2 were among the mechanical CPR devices under investigation. Focusing on ROSC, most reviews concluded toward mechanical CPR devices being similar or better than manual CPR (Figure 1). Similar findings were obtained for survival to discharge or 30 days after cardiac arrest. Conversely, some reviews suggested the inferiority of mechanical CPR devices for survival with good neurologic outcome and for CPR-related injuries.

Conclusions. According to available evidence CPR with mechanical devices appears to be similar to manual in terms of achieving ROSC and short-term survival and inferior for CPR-related injuries while there are conflicting results regarding survival with good neurological outcomes. Overall there is a lack of evidence and more randomized controlled trails are still needed in the future to elucidate the role of mechanical devices in CPR.

Findings	ROSC	Survival to discharge / 30 days	Survival with good CNS outcome	CPR-related injuries
Mechanical CPR better	○	○	○	
Mechanical CPR similar	○	○	○	
Mechanical CPR worse			○	○

Figure 1. Summary of results of umbrella review on mechanical cardiopulmonary resuscitation (CPR) devices.
CNS, central nervous system.

A167: UN CASO RARO DI SCHOCK EMODINAMICO OSTRUTTIVO INTRATTABILE A DOPPIO MECCANISMO

Pedro Moraes (a), Dyovane Lopes (a), Mayara Sousa (a)

(a) SCUOLA PAULISTA DI MEDICINA - UNIVERSITÀ FEDERALE DI SAN PAOLO

Un uomo di 35 anni è stato ricoverato al pronto soccorso di un ospedale terziario a causa di perdita di coscienza, tremori muscolari e rilascio dello sfintere. Non aveva comorbilità note, ma da 2 mesi lamentava dolori al petto intermittenti e di breve durata. Si presentava in cattive condizioni generali, in coma (scala di Glasgow 5), FC 115 bpm, PA 85 x 42 mmHg, FR 45 bpm, suoni cardiaci smorzati senza soffi, ingrossamento delle giugulari, auscultazione polmonare normale, senza edema periferico. ECG in ritmo sinusale, complessi QRS a bassa ampiezza e elevazione del segmento ST di 1 mm nelle derivazioni aVR e V1-V3. È stata eseguita prontamente un'intubazione orotracheale, seguita da ecografia portatile mirata alla definizione eziologica dello shock indifferenziato, che ha mostrato un significativo versamento pericardico con segni di collasso delle camere destre e una massa tumorale prolassata tra l'atrio destro e il ventricolo destro. È stata eseguita una pericardiocentesi con drenaggio di 300 ml di liquido ematico, ma il paziente ha continuato a deteriorarsi dal punto di vista emodinamico e ha richiesto vasopressori. Gli esami di laboratorio hanno mostrato Hb 14,6 g/dl, leucociti 22.700 con predominanza di neutrofili, piastrine 280.000, creatinina 2,56 mg/dl, Na 134 mEq/L, K 5,4 mEq/L, pH 6,9 e bicarbonato 10,6 mEq/L. Il paziente è stato quindi sottoposto a una tomografia computerizzata a tutto il corpo, che ha mostrato una massa infiltrante nel mediastino anteriore, che invade le camere cardiache destre, la valvola tricuspide, il seno coronarico e le vene polmonari, oltre a infiltrazione epatica e un nodulo di 2,8 cm nella ghiandola surrenale destra. L'ecocardiogramma ha confermato una massa enorme nell'atrio destro (21 cm2), causando una significativa stenosi tricuspide (gradiente medio di 10 mmHg) e una contrattilità moderatamente ridotta del ventricolo destro. A causa dello stato avanzato, infiltrante e metastatico della neoplasia, associato a un'irresezione tecnica, il team cardiaco ha considerato il paziente inoperabile ed è deceduto 6 ore dopo il ricovero in ospedale.

Discussione. Il caso mette in evidenza una situazione insolita di shock emodinamico ostruttivo con un meccanismo duale: infiltrazione tumorale nelle camere cardiache destre e tamponamento cardiaco. Le neoplasie cardiache sono le più rare nel corpo umano e di solito si verificano a causa di metastasi (polmone, seno, melanoma, tra le altre), ma possono anche essere primarie del cuore (come mixomi, fibromi e sarcomi). Anche senza una diagnosi anatomopatologica definitiva, l'intrattabilità evidenziava il carattere clinico maligno in questo caso.

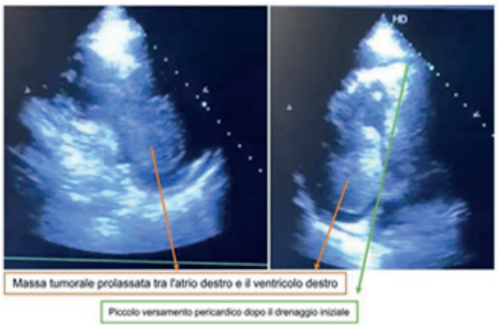

A168: A CASE REPORT OF ECMELLA AS BRIDGE TO RECOVERY IN CARDIOGENIC SHOCK

Andrea Pezzato (a), Enrico Fabris (b), Jacopo Rizzi (a), Andrea Lalario (a), Massimo Zecchin (b), Andrea Perkan (b), Enzo Mazzaro (c), Gianfranco Sinagra (b)
(a) POSTGRADUATE SCHOOL OF CARDIOVASCULAR MEDICINE UNIVERSITY OF TRIESTE; (b) AZIENDA SANITARIA UNIVERSITARIA GIULIANO-ISONTINA - DIVISION OF CARDIOLOGY; (c) AZIENDA SANITARIA UNIVERSITARIA GIULIANO-ISONTINA - DIVISION OF CARDIAC SURGERY

A 32 year-old-man, with positive familiarity for sudden cardiac death and for ischaemic heart disease, presented at the emergency department for severe astenia, worsening dyspnoea and epigastralgia. He started to be symptomatic for palpitation in the last month, in concomitance with an infective episode of the upper respiratory tract. He was admitted to the coronary intensive care unit due to cardiogenic shock with multiorgan failure. The electrocardiogram revealed an atrial tachycardia with 200 bpm and the echocardiogram showed a biventricular dysfunction with severe dilatation of left ventricle (LVEDVi of 117 ml/m2), ejection fraction (EF) of 12% and a restrictive diastolic filling pattern. He has been initially treated with Dobutamine, which was subsequently interrupted due to the worsening of the arrhythmias. Intra-aortic baloon pump (IABP) was placed and was treated with Levosimendan. After transoesophageal echocardiography, electrical cardioversion of the atrial tachycardia was performed, with initial restoration of sinus rhythm but with subsequent multiple paroxysms of atrial tachycardia with haemodynamic impairment. Because of progressive haemodynamic deterioration, an upgrade of the mechanical circulatory support system was decided and IABP was replaced with Impella 2.5. Coronary angiogram showed a normal coronary tree and right ventricular endomyocardial biopsy showed absence of myocardial inflammation but the presence of initial fibrosis replacement, in a setting compatible with dilated cardiomyopathy. For the persistence of severe hemodynamic impairments and multiorgan failure despite support with Impella 2.5, a venoarterial extracorporeal membrane oxygenation (VA-ECMO) was placed from a right subclavian access (considering the potential need of long term support) and from femoral vein. Impella 2.5 was kept in place for unloading of the left ventricle. Due to the presence of continuous sub-entrant paroxysms of atrial tachycardia, a transcatheter ablation of the atrial arrhythmia was performed, which was effective. The effective transcatheter ablation and ECMELLA support allowed a progressive improvement of the systemic condition and left ventricular function until the recovery of multi-organ failure. After 9 days, both Impella 2.5 and ECMO were removed, and the patients was extubated the following day. Despite this benefit, the ICU course was complicated by an upper respiratory tract bleeding, resolved by sphenopalatine artery cauterization, by a right upper limb hypoperfusion syndrome, with edema and hyposthenia, resolved on removal of the ECMO and subclavian vein thrombosis for which anticoagulation was started. Cardiac MRI confirmed the severe left ventricular dilatation and dysfunction (EF 21%, LVEDVi 157 ml/m2) and showed the presence of basal inferior junctional late gadolinium enhancement of non-specific significance and a diffuse increase in T1 mapping values. During the hospitalization, medical therapy was introduced and optimised. At the last follow up after 4 months the patients was in NYHA II, and echocardiogram showed an initial reverse remodelling with EF of 38% and LVEDVi 96 ml/m2, without restrictive diastolic filling and normal right ventricular dimension and function. No ventricular arrhythmias were present at Holter-ECG and during ergometric test. Genetic analysis are still ongoing. This case highlights the importance of mechanical circulatory supports for non-ischemic cardiogenic shock not responsive to medical therapy and highlights the importance of the removal of potential factors contributing to hemodynamic instability in non-ischemic cardiomyopathy.

A169: BLOCCO DEL GANGLIO STELLATO: MONITORAGGIO CLINICO DOPO LA PROCEDURA

Marco Giuranna (a)
(a) SIC

Uomo di 70 anni con cardiopatia ischemica cronica post-infartuale (CABG x 6 nel 2006) in fase dilatativo-ipocinetica. Impianto di ICD in prevenzione primaria nel 2011. Diversi ricoveri per storm aritmico. Intolleranza ad Amiodarone. In lista per ablazione di TV. Giunge a ricovero per TV sostenuta sintomatica per discomfort toracico, trattata con Lidocaina e successiva evoluzione in storm aritmico, non più responsivo a terapia farmacologica e a cardioversione elettrica per cui si è stato praticato il blocco del ganglio stellato sinitro. Previa sedazione con bolo di midazolam ev, è stato utilizzato l'approccio laterale ecoguidato, iniettando 200 mg di Lidocaina e 200 mg di Mepivacaina. Dopo alcuni minuti si è assistito alla comparsa di anisocoria, termotatto differente agli arti superiori, ptosi, disfonia, come effetto degli anestetici locali sulle fibre del sistema nervoso simpatico e sul nervo laringeo ricorrente, in prossimità del ganglio stellato. Tra le complicanze descritte in letteratura (solitamente transitorie) insorte dopo blocco del ganglio stellato per il trattamento di diverse sindromi dolorose croniche o di aritmie ventricolari refrattarie, troviamo: raucedine, stridor, confusione, tosse, ipertensione severa, blocco subdurale/intratecale con arresto respiratorio, perdita di coscienza e paralisi dei quattro arti, crisi epilettiche, locked-in syndrome transitoria, cefalea, allucinazioni visive, mioclono, sindrome di Horner, paralisi diaframmatica (lesione del nervo frenico), reazioni allergiche, sanguinamento e formazione di ematoma, puntura durale, pneumotorace, infezioni locali. Effetti avversi gravi descritti includono casi di decesso o di tetraplegia a seguito di ascesso epidurale. È per tale motivo di fondamentale importanza il monitoraggio dopo la procedura e la disponibilità delle attrezzature necessarie ad una eventuale rianimazione sequele a lungo termine.

A170: DECODING NON-CARDIOGENIC ACUTE PULMONARY EDEMA (NCAPE): CAN THE INFERIOR VENA CAVA UNRAVEL THE MYSTERY AFTER INTRAVENOUS RADIOCONTRAST ADMINISTRATION? A CASE REPORT

Evaluna Perez Guillen (a), Antonio Voza (a)
(a) HUMANITAS RESEARCH HOSPITAL

Background. Pulmonary edema is an uncommon complication associated with the administration of RCM and usually occurs in patients with preexisting cardiac disease. NCPE appears to be a rare occurrence. In a review of the literature, only seven well-described and hemodynamically verified cases of NCPE following RCM exposure were found and were at the beginning thought to be anaphylactoid reactions, therefore wrongly treated.

Case report. A 77 year-old female with a history of COPD and hypertension underwent a CT coronary angiogram. She suddenly developed dyspnea, tachycardia and profuse sweating. Despite receiving three doses of nebulized salbutamol and ipratropium, along with 8 mmol of magnesium sulphate, her condition deteriorated. Suspecting an anaphylactoid reaction, 0,5 mg of adrenaline was administered intramuscularly. Her condition continued to worsen, leading to the initiation of non-invasive ventilation (NIV), followed by 40 mg of furosemide and continuous infusion of nitroglycerin. An hour later, her blood pressure had decreased and arterial blood gas analysis showed improvement. She was subsequently admitted to the cardiology ward.

Conclusions. Recognizing acute pulmonary edema can be straightforward when a patient has a history of heart failure or when initial symptoms and signs suggest it. However, diagnosis becomes challenging when symptoms mimic an allergic reaction. Patients who experienced NCAPE after RCM administration were often presumed to have an anaphylactoid reaction. They were typically treated with antihistamines, corticosteroids, and sometimes adrenaline; but these treatments proved ineffective. For patients who develop NCPE after intravenous contrast agent injection, the primary treatment guidelines are the ABCs: airway, breathing, and circulation. Emergency interventions include oxygen administration with continuous positive airway pressure or invasive ventilation with positive end-expiratory pressure. Distinguishing between NCPE and anaphylaxis, especially in emergency situations, can be challenging. Ultrasonography, particularly inferior vena cava ultrasound measurements, is a non-invasive and readily available tool that can assess intravascular volume status, helping determine whether a patient has NCPE or anaphylaxis.

ASSISTENZA INFERMIERISTICA E TECNICA IN CARDIOLOGIA

A171: TREATMENT OF CARDIOGENIC SHOCK WITH ECPELLA- A CASE REPORT

Simone Amato (a), Andrea Battisti (a)
(a) AZIENDA OSPEDALIERA SAN CAMILLO FORLANINI- ROMA

Aims. A 31-year-old male patient suffering from infective myocarditis that caused a cardiogenic shock (CS) has been treated with a combination of extracorporeal membrane oxygenation (ECMO) and Impella. These mechanical circulation assist devices are useful in order to treat patients with CS with impaired ejection fraction who do not respond to medical treatment. This set-up, commonly referred to in the literature as ECPELLA, involves the management of a multidisciplinary team and careful monitoring of many essential parameters in the postoperative period. Management of mobilization, prevention of bedsores, risk of bleeding, control of blood coagulative parameters and careful monitoring of limb perfusion cover only a few important attentions that the team must carefully monitor to prevent life-threatening complications.

Methods and Results. A PubMed search was conducted for patient management with double mechanical circulation assist combined with the use of hospital protocols. In the absence of complications, a rapid breathing weaning with extubation was performed. Temperature, diameter, and appearance of the four arts were recorded every 6 hours. The mobilization was carried out in collaboration between the nurse and the perfusionist. The patient's coagulating and blood parameters were carefully monitored every 6 hours. In the absence of complications and mechanical assistance, the patient was discharged early from the cardiovascular ICU.

Conclusions. The use of the best scientific evidence applied to the best clinical practice and the cooperation of multi-disciplinary teams have improved clinical conditions without significant complications.

A172: IMPATTO DI UN INTERVENTO DI COACHING INFERMIERISTICO E TELEMONITORAGGIO PER PAZIENTI CON SCOMPENSO CARDIACO DIMESSI A DOMICILIO: PROTOCOLLO DI UNO STUDIO RANDOMIZZATO CONTROLLATO

Ines Basso (a), Erika Bassi (a), Silvia Caristia (a), Mattia Bellan (a), Marco Invernizzi (a), Angela Durante (a), Alberto Dal Molin (a)
(a) UNIVERSITÀ DEL PIEMONTE ORIENTALE

Introduzione. La scarsa capacità di autocura e la ridotta aderenza ai trattamenti farmacologici rappresentano importanti fattori di rischio di riammissione in ospedale per la persona dimessa con scompenso cardiaco. Il coinvolgimento attivo del paziente nella gestione della malattia e un intervento di tele-monitoraggio domiciliare dei parametri vitali potrebbero ridurre i ricoveri ripetuti, migliorando la qualità di vita fisica e psicologica dell'assistito.
Obiettivi. Valutare l'impatto di un programma di coaching telefonico infermieristico con tele-monitoraggio dei parametri vitali nel ridurre le riammissioni per tutte le cause degli anziani ospedalizzati a 180 giorni dalla dimissione. Tra gli obiettivi secondari figurano le riammissioni per scompenso cardiaco, la qualità di vita, la capacità di autocura, la percezione di auto-efficacia, il livello di benessere emotivo e la valutazione dell'accettabilità e aderenza al programma.
Materiali e metodi. Sarà condotto uno studio randomizzato controllato a due bracci paralleli, in aperto, volto a comparare l'assistenza standard rispetto ad un programma di coaching telefonico infermieristico con tele-monitoraggio domiciliare non invasivo. Saranno invitati a partecipare 238 pazienti ultrasessantacinquenni (rapporto 1:2 braccio di intervento e controllo) ricoverati per scompenso cardiaco nei servizi di Cardiologia e Medicina di un'Azienda Ospedaliera Universitaria. Il programma della durata di 6 mesi prevede: 1) Intervento educativo pre-dimissione rispetto ai temi raccomandati dalle linee guida della Società Europea di Cardiologia. Durante tale incontro infermiere e paziente concorderanno gli obiettivi prioritari di salute e definiranno la motivazione al cambiamento, secondo il modello transteorico di Prochaska e Di Clemente; 2) Servizio di coaching telefonico infermieristico bisettimanale; 3) Tele-monitoraggio dei parametri vitali autogestito dalla persona. In caso di evento critico è stato definito un protocollo di intervento multidisciplinare sulla base della gravità delle condizioni manifeste.
Conclusioni. In coerenza con quanto definito dagli obiettivi del PNRR e il DM 77/2022, il progetto si propone di sviluppare e valutare un nuovo modello per lo sviluppo di assistenza territoriale, volto a facilitare l'interazione infermiere-paziente attraverso gli strumenti della teleassistenza. Il programma di teleassistenza potrebbe migliorare gli esiti clinici e assistenziali degli utenti, riducendo il ricorso ai servizi ospedalieri e aumentando l'accessibilità ai servizi sanitari.

A173: NURSING RESPONSIBILITIES IN THE TREATMENT OF PAROXYSMAL SUPRAVENTRICULAR TACHYCARDIA IN THE NEWBORN: THE "DIVING REFLEX"

Anna Bellingrath (a), Vincenzo Pettillo (a)
(a) A.O.R.N DEI COLLI - V. MONALDI

Introduction. Nursing responsibilities during an episode of paroxysmal supraventricular tachycardia (PSVT) in the newborn and in particular, a newborn admitted to the neonatal intensive care unit, are multiple: from electrocardiographic monitoring to the administration of drugs such as adenosine (universally recognized drug for the treatment of supraventricular tachycardias) but his major responsibility lies in the execution of vagal maneuvers and in particular, as regards the newborn/infant, the "diving reflex" maneuvers.
Case presentation. Female patient diagnosed with late fetal arrhythmia, born with spontaneous delivery at 39 weeks of gestation, on the second day of birth was admitted to neonatal pathology and neonatal intensive care unit with heart rate of 250 bpm. ECG monitoring started and cardiological consultation was requested, supraventricular tachycardia was diagnosed and vagal maneuvers started; since the neonatological patient differs from the pediatric and adult patient in terms of physiology and compliance, the classic maneuvers such as the "Valsalva" maneuver or forced aspiration from an occluded straw or the "straining" maneuver are not used, these are replaced with the of "diving reflex", so called because they are maneuvers that cause the patient to hold his breath and exhale slowly in order to stimulate the vagus. These maneuvers are performed by the pediatric nurse by removing the nasogastric tube and/or oro/nasogastric aspiration and finally by applying ice to the face for 10-15 seconds. After a second repetition of the vagal maneuvers, the heart rate stabilized at around 160 bpm, normal for gestational age.
Conclusions. The vagal maneuvers differ according to the patient, based on physiology and compliance, in particular in the neonatology field these are concentrated in the so-called "diving reflex" which, if correctly performed in the appropriate ways and times, can help resolve episodes of supraventricular tachycardia without the use of electrical or pharmacological methods of cardioversion.

A174: HUMANIZATION OF CARE AND FAMILY INVOLVEMENT IN CARDIAC INTENSIVE CARE UNIT: IMPLEMENTATION OF TWO SIMPLE TOOLS

Sergio Calzari (a), Stefania Mauro (a), Marina Andrini (a), Carmen Schirru (a), Patrizia Bulloni (a), Piergiorgio Zini (a), Anna Feliciani (a), Paula Deelen (a), Paola Rusca (a), Lucia Pedrazzini (a), Stefano Bernasconi (a), Valentina Mirto (b), Michele Villa (a), Tiziano Cassina (a)
(a) DEPARTMENT OF INTENSIVE CARE, CARDIOCENTRO TICINO INSTITUTE, ENTE OSPEDALIERO CANTONALE, LUGANO, SWITZERLAND; (b) URGENT CARE DEPARTMENT, INTENSIVE CARE UNIT, ROYAL BERKSHIRE, NHS FOUNDATION TRUST, READING, UNITED KINGDOM

Introduction. A stay in an intensive care unit may have a very important impact on a person's life, who often experiences physical, cognitive and psychological changes, which may lead to PICS (Post Intensive Care Syndrome). Evidence suggests that the use of a diary, which describes what happened around patients while they were sedated, decreases the incidence of psychological issues. Family members have the chance to read what has been written by caregivers and viceversa. In 2020, the implementation of the patient diary started in our unit. In 2021, the 'narrative poster' was also created. Also known in english speaking countries as 'All about me', it is an A3-sized sheet where family members can write information about the person. For example, it is possible to record information about profession, hobbies, food preferences or music preferences. The sheet, which remains at the patient bedside, allows carers to learn something about the life of the hospitalised person. This facilitates the delivery of humanised nursing care based on the information provided. To our knowledge, there are no similar tools in Italian-speaking Switzerland and Italy.
Objectives. The objectives were to implement the patient diary and the narrative poster within the operating unit so that these humanisation tools become an established practice.
Project methodology. A group made of six nurses and a physiotherapist was set up. A number of meetings took place during which, in regards to the diary, the inclusion criteria, the drafting of the cover sheet and the unit protocol were defined. Trainings given was provided to care staff during which the instrument was presented, and a further training regarding safe writing was provided. A 'sample diary' was realised to help with writing. After implementing the diary, the narrative poster was developed. Furthermore, after collecting the information needed, the poster was graphically set up using cartoons. On a daily basis, the working group monitors the presence of the diary at the bedside and its compilation. They also help with the presentation and involvement of the family by also including family members in the poster's writing process.
Results. Three years after implementation, about 150 diaries have been completed and the diary has become an established practice. In 2022, a qualitative study was carried out to evaluate its effectiveness. The diary enabled the provision of personalised care and also improved communication with the patient.
Conclusions. Both the patient diary and the poster proved to be important humanisation tools for the benefit of the patients and their relatives, they shifted the focus of care towards the person. The results of the qualitative study which was performed in our unit, show the importance of this simple narrative nursing tool which proved to help "healing" from the ICU experience. Both tools are inexpensive and easy to implement and have had a major impact on care by promoting family engagement.

A175: INTELLIGENZA ARTIFICIALE IN CARDIOLOGIA: UN FOCUS SU SCENARI ATTUALI E FUTURI

Luca Cardillo (a)
(a) ASL NAPOLI 2 NORD

Il termine Intelligenza Artificiale (AI) definisce una branca dell'informatica impegnata nella progettazione di software capaci di fornire prestazioni che, a un osservatore comune, sembrerebbero essere di pertinenza esclusiva dell'intelligenza umana. Il termine AI, per quanto attualmente in crescente diffusione, nasce parallelamente alla scienza informatica e fu usato per la prima volta nel 1956 dal professor John McCarthy dell'Università di Stanford. Negli ultimi anni numerosi sono gli studi in letteratura che analizzano le potenzialità della AI nelle applicazioni di supporto alla pratica clinica. Negli ultimi anni, tuttavia, numerosi sono gli studi in letteratura che analizzano le potenzialità della AI nelle applicazioni di supporto alla pratica clinica ed in ambito cardiologico. In cardiologia l'AI ha trovato nell'elettrocardiogramma un ottimo substrato. Diversi studi retrospettivi effettuati in contesti sperimentali, hanno evidenziato come l'intelligenza artificiale sia in grado di riconoscere una fibrillazione atriale parossistica da un ECG standard. Un altro studio randomizzato, invece, ha valutato l'efficacia dell'IA-ECG in un contesto di cure primarie per il riconoscimento della disfunzione ventricolare, evidenziandone un'aumentata capacità diagnostica rispetto all'approccio standard. Uno studio di coorte effettuato nel Regno Unito nel 2019 ha utilizzato una nuova tecnica di intelligenza artificiale, nominata XGBoost, che è stata in grado di identificare in maniera più accurata le persone che in seguito hanno subito un infarto del miocardio.

A176: MINDFULNESS E REALTÀ VIRTUALE PER RIDURRE LO STRESS NEI CAREGIVER DI PERSONE CON PATOLOGIE CRONICHE E CARDIOVASCOLARI: INSIGHTS DALLA LETTERATURA

Daniela Ciriaci (a), Marco Di Nitto (b), Angela Cuoco (c), Alberto Dal Molin (d), Ercole Vellone (a), Angela Durante (d)
(a) UNIVERSITÀ DEGLI STUDI DI ROMA TOR VERGATA, ROMA, ITALIA; (b) UNIVERSITÀ DEGLI STUDI DI GENOVA, GENOVA, ITALIA; (c) IRCSS ISTITUTO ORTOPEDICO RIZZOLI, BOLOGNA, ITALIA; (d) UNIVERSITÀ DEGLI STUDI DEL PIEMONTE ORIENTALE "AMEDEO AVOGADRO", NOVARA, ITALIA

Introduzione. Il caregiver informale, nel fondamentale ruolo di supporto umano, sociale ed economico nell'assistenza alle persone con patologie croniche, può sperimentare un'esperienza di stress cronico. Gli alti livelli di vigilanza richiesti, l'imprevedibilità e l'incontrollabilità, proprie delle patologie croniche, soprattutto quelle cardiovascolari (CVD), creano tensione fisica e psicologica per lunghi periodi, con ripercussioni in ambito lavorativo e familiare che determinano il burden inteso come eccessivo peso assistenziale percepito. Per rimuovere gli stressor, la letteratura suggerisce strategie di coping come gli interventi basati sulla Mindfulness. Essi risultano efficaci per fronteggiare il burden, promuovendo un atteggiamento di consapevolezza nel "qui ed ora". Tali interventi, se proposti in modalità online, oltre all'economicità hanno il vantaggio di limitare le problematiche relative agli spostamenti o al poco tempo personale a disposizione del caregiver. Quando erogati con dispositivi di realtà virtuale (VR) potrebbe aumentare l'immersività e favorire il rilassamento anche in un ambiente domiciliare.
Obiettivi. L'obiettivo della presente revisione è duplice: 1) Esplorare quali esiti possono essere migliorati da un intervento di mindfulness nei caregiver informali di persone con malattie croniche; 2) Indagare se la realtà virtuale amplifica l'effetto della mindfulness quando viene utilizzata in modo combinato nell'intervento per i caregiver informali di persone affette da malattie croniche.
Materiali e metodi. È stata condotta una revisione sistematica, secondo il manuale Joanna Briggs Institute, consultando quattro database: PUBMED, CINAHL, PsychINFO e Google Scholar. È stato impostato il limite temporale agli ultimi 5 anni considerando il continuo avanzamento tecnologico nel campo della realtà virtuale. Un primo screening sistematico è stato eseguito tramite l'applicazione online Rayyan®, seguito dalla valutazione dei full text secondo i criteri di eleggibilità, in modo indipendente da parte di due membri del gruppo di ricerca. Sono stati esclusi tutti gli studi qualitativi, con popolazione di caregiver di persone affette da patologia acuta e che non prevedessero un intervento di mindfulness con o senza realtà virtuale.
Risultati. Sono stati inclusi 12 articoli. Dieci avevano un disegno quasi sperimentale e due articoli un disegno sperimentale (RCT). Un articolo ha incluso caregiver di pazienti con ictus, mentre i restanti undici articoli hanno incluso caregiver di pazienti con cancro. Nessun articolo ha effettuato un intervento di mindfulness attraverso l'utilizzo della VR. I risultati mostrano una discordanza sull'effetto della mindfulness per i caregiver di pazienti con patologie croniche. Nello specifico, tra i diversi outcome considerati sette articoli hanno preso in esame la riduzione della depressione, ma solo quattro articoli hanno riportato una riduzione significativa di questa attraverso l'intervento di mindfulness. Inoltre, tre articoli hanno valutato il burden del caregiver, non riportando un miglioramento significativo dopo l'intervento di mindfulness.
Conclusioni. La revisione effettuata propone una panoramica circa gli interventi di Mindfulness e/o VR nei caregiver di patologie croniche, evidenziando benefici rispetto agli interventi educativi tradizionali nei caregiver di persone con demenza, con cancro e in un percorso di cure palliative. Solo uno studio è stato rilevato in riferimento ai caregiver di persone con malattie cardiovascolari. La mancanza di ulteriori studi lascia un quesito aperto circa la loro efficacia e motiva la proposta di un supporto personalizzato considerando la vulnerabilità di questa popolazione specifica.

A177: NURSING MANAGEMENT OF THE PATIENT IN ECMO: SKILLS AND KNOWLEDGE. A LITERATURE REVIEW.

Valeria D'Arrigo (a), Lorenzo Furcieri (a, b), Valentina Roberti (c), Sonia Lomuscio (a, b), Annalisa Alberti (a, b), John Tremamondo (a), Adelina Salzillo (a), Stefania Tinti (a, b)
(a) A.S.S.T. RHODENSE; (b) UNIVERISTÀ DEGLI STUDI DI MILANO; (c) A.S.S.T. MONZA

Introduction. Extracorporeal membrane oxygenation (ECMO) is an external device that uses invasive technique to treat critically ill patients using mechanical support for respiratory and cardiovascular function when all other conventional treatments are ineffective. The management of these patients relies on a multi-specialist team, to which the nurse belongs, and whose members must possess specific knowledge, supported by a programme of continuous training and updating.
Aim. To compile the literature in order to analyse, in depth, what nursing skills are involved in the management of the patient undergoing ECMO and how these may affect the outcome of treatment in these highly complex patients.
Methods. Literature review by consulting the main biomedical banks: PubMed, CINAHL, Cochrane Library, Embase and some peer-reviewed journals, as well as the Extracorporeal Life Support Organisation (ELSO) Guidelines. Inclusion criteria were applied with respect to English and Italian language, age 18 years or older and sample size greater than single unit.
Results. The analysis of the 11 studies included in this narrative review of the literature showed how the caring activity, performed by the nurse, plays a fundamental role in the management of these highly critical patients. Prevention and early detection of patient complications are the key elements of successful nursing care based on careful all-round monitoring. Adherence to existing guidelines and standardisation of procedures implemented by the nurse are key elements, which reduce mortality and improve patient outcomes.
Conclusions. In order to care for patients undergoing ECMO, the nurse practitioner must be adequately trained and specialised. Continuous updating of knowledge and consolidation of skills increase the value of the nurse, who will be able to provide the patient with attentive, precise and informed care, with the aim of improving outcomes.

A178: LEADLESS PACEMAKER VERSUS TRANSVENOUS PACEMAKER: L'ALTERNATIVA MIGLIORE PER IL PAZIENTE POST-ESTRATTO

Alessia Dentico (a), Alessandra Ferrieri (a), Teresa Altieri (a), Francesca Maria Carretta (b), Carlo D'Agostino (a), Domenico Maria Carretta (a)
(a) A.O.U.C. POLICLINICO DI BARI; (b) UNIVERSITÀ CAMPUS BIO-MEDICO DI ROMA

Introduzione. Con l'aumentare delle complicanze associate all'impianto di pacemaker e defibrillatori, è aumentato il numero di pazienti che vanno incontro ad estrazione transvenosa di elettrocateteri in seguito ad infezione degli stessi. Spesso, nei pazienti pacemaker dipendenti vi è il problema di dover effettuare un reimpianto precoce dopo l'estrazione. Questo studio si pone l'obiettivo di valutare l'incidenza di reinfezione e di confrontare il follow-up tra i pazienti post-estratti reimpiantati con leadless pacemaker ed i pazienti post-estratti reimpiantati con device transvenoso.
Materiali e metodi. Da dicembre 2016 ad ottobre 2022 nel nostro centro sono state eseguite 163 procedure di estrazione di elettrocateteri. Di questi pazienti post-estratti, 24 sono stati successivamente impiantati con un leadless pacemaker. Tra i restanti, invece, in 52 sono stati reimpiantati con un device tradizionale (di cui 28 con un pacemaker, 17 con un defibrillatore, 5 con CRT-D). In 11 sono invece stati reimpiantati con S-ICD, 3 con un loop recorder; 73 sono i pazienti che, al contrario, dopo attenta rivalutazione cardiologica, o non hanno reimpiantato un nuovo device o sono stati reindirizzati presso il centro di primo impianto nell'attesa di completare la terapia antibiotica in corso. Per dimostrare la riduzione delle recidive di reinfezione, si è paragonato il follow-up nel post-operatorio dei pazienti reimpiantati con un leadless rispetto a quelli reimpiantati con un pacemaker tradizionale. Fondamentale strumento per questa analisi è stato il monitoraggio remoto, di cui sono stati dotati tutti i pazienti subito dopo l'impianto. Per testare, infine, il livello di gradimento del paziente verso il nuovo dispositivo impiantato, è stato somministrato ai due campioni di pazienti un questionario.
Risultati. Una prima analisi del follow-up delle suddette classi di pazienti dal 2016 ad oggi ci fornisce già alcuni dati importanti: nei pazienti che hanno impiantato un leadless pacemaker in seguito ad estrazione in nessun caso si è manifestata una recidiva di infezione; nei pazienti, invece, che hanno impiantato un dispositivo tradizionale, studiando la storia clinica pregressa, si è visto come alcuni di questi avessero subìto in passato una revisione di tasca o addirittura un'estrazione del dispositivo di primo impianto. Un buon numero sono infatti i pazienti che giungono presso il nostro centro con elettrocateteri abbandonati e con infezione del nuovo dispositivo in corso. Il questionario indice del gradimento ha dimostrato una maggiore accettazione del nuovo dispositivo impiantato ed un migliore rapporto paziente-device nei pazienti reimpiantati con leadless pacemaker rispetto al gruppo reimpiantato con dispositivo tradizionale. Infine, poiché spesso il reimpianto con leadless viene eseguito contestualmente alla procedura di estrazione (soprattutto nei pazienti PM dipendenti), in un'epoca molto attenta alle finanze ospedaliere questo modello operativo consente una riduzione dei tempi di ospedalizzazione e dei conseguenti costi.
Conclusioni. L'impianto di leadless pacemaker in pazienti post-estratti, laddove abbiamo pazienti eleggibili ad impianto di tale dispositivo, si è dimostrato una scelta efficace nel ridurre le recidive di reinfezione rispetto alla popolazione di pazienti reimpiantati con device transvenoso.

A179: LA DIAGNOSI ELETTROFISIOLOGICA DELLO STROKE CRIPTOGENETICO

Luca Benedetto (a), Alessia Dentico (a), Alessandra Ferrieri (a), Teresa Altieri (a), Francesca Maria Carretta (b), Carlo D'Agostino (a), Domenico Maria Carretta (a)
(a) A.O.U.C. POLICLINICO DI BARI; (b) UNIVERSITÀ CAMPUS BIO-MEDICO DI ROMA

Introduzione. In ambito neurologico una delle patologie non ancora completamente chiarite da un punto di vista eziopatogenetico è lo stroke criptogenetico. Questa definizione si applica a tutte quelle forme di ictus in cui le indagini clinico-strumentali non sono state in grado di definire il "primum movens". In letteratura una percentuale significativa di ictus criptogenetico è il risultato fi Fibrillazione Atriale Parossistica (FAP). Attualmente il riconoscimento di forme asintomatiche ed a rapida evoluzione di FA possono essere indagate con l'utilizzo di registratori

elettrocardiografici impiantabili (Loop Recorder o ILR) che aumentano il tasso di riconoscimento della FA rispetto alle indagini standard. I Loop Recorder, monitorando l'attività elettrica del cuore, si attivano automaticamente e registrano l'evento. Questo dato grazie ad un sistema di trasmissione, oltre che essere conservato nella memoria del registratore e quindi essere interrogabile, è inviato ad un server centrale che a sua volta lo trasmette alla control room che memorizza a distanza il paziente e gli eventi. Lo scopo dello studio è quello di diagnosticare attraverso l'impianto dell'ILR con monitoraggio a lungo termine, fino a 36 mesi, la causa dello Stroke criptogenetico.
Materiali e metodi. Tutti i pazienti ricoverati nella Stroke Unit con ictus criptogenetico sono stati valutati con l'ESUS SCORE. I pazienti risultati positivi alla somministrazione dello score sono stati sottoposti all'impianto di Loop Recorder (ILR) per monitoraggio cardiaco prolungato nel sospetto clinico di FAP come causa di ictus criptogenetico. I risultati di tale monitoraggio sono stati documentati insieme alla durata del monitoraggio cardiaco ospedaliero.
Risultati. In tutto sono stati identificati 210 pazienti con diagnosi di ictus ischemico o attacco ischemico transitorio (TIA). Degli ictus, 22 (10,4%) sono stati classificati come criptogenetici. Questi pazienti sono stati sottoposti ad impianto di Loop Recorder e monitorati per 12 mesi. 6 pazienti su 22 (27,2%) sono risultati affetti da fibrillazione atriale e sono stati trattati con Warfarin.
Conclusioni. Il monitoraggio continuo del Loop Recorder ha cambiato il trattamento farmacologico del 27,2% dei pazienti con ictus criptogenetico a causa del rilevamento di FA intermittente nonostante il mancato rilevamento di FA all'elettrocardiografia e al monitoraggio telemetrico ospedaliero.

A180: IL PRIMARY NURSING NEL MONITORAGGIO REMOTO DEI PAZIENTI PORTATORI DI DISPOSITIVI CARDIACI IMPIANTABILI

Alessandro Faraci (a, b), Giuseppe Coppola (a), Egle Corrado (a, b)
(a) A.O.U. POLICLINICO "P. GIACCONE" DI PALERMO; (b) UNIVERSITÀ DEGLI STUDI DI PALERMO

Introduzione. Il trattamento con device delle patologie cardiache ha portato ad un aumento esponenziale di pazienti portatori di dispositivi cardiaci, che necessitano di controlli più frequenti, più attenti, con conseguente aumento del numero e della complessità clinica dei pazienti che afferiscono ai centri di cardiostimolazione.
Obiettivi. Il ricorso al monitoraggio remoto permette alla struttura ospedaliera che ha in carico il paziente di avere un flusso continuo di informazioni relative non solo alla performance del device ma anche ad eventi clinici quali aritmie e scompenso cardiaco senza la necessità del contatto diretto tra paziente ed operatore sanitario, riducendo drasticamente gli accessi inappropriati dei pazienti e al contempo rilevare tempestivamente eventuali criticità che necessitano di interventi in tempi più o meno brevi. I benefici del monitoraggio remoto come si è visto nel corso degli anni, intervengono a più livelli, economico, sociale e clinico.
Materiali e metodi. Numerosi studi hanno dimostrato come il monitoraggio remoto può sostituire i controlli ambulatoriali senza compromettere la sicurezza del paziente, riducendo il consumo delle risorse, pur programmando almeno un follow up ambulatoriale all'anno come raccomandato dalle linee guida internazionali. I dati dei dispositivi impiantati vengono trasmessi ad un sito web protetto del centro di riferimento che ha in carico il paziente. Con l'introduzione della telecardiologia e del monitoraggio remoto nella pratica clinica si sono implementati dei nuovi modelli organizzativi, che armonizzano e codificano l'attività delle diverse figure professionali che intervengono nel processo diagnostico e terapeutico, quali elettrofisiologi, infermieri, tecnici, bioingegneri, cardiologi clinici, specialisti dello scompenso e medici di medicina generale. Questo modello deve garantire una precisa definizione di ruoli e responsabilità, tracciabilità delle azioni, continuità delle cure, basso consumo di risorse, gradimento e accettazione del paziente, integrazione con i tradizionali percorsi di diagnosi e cura ospedalieri ed extraospedalieri. Un modello che racchiude tutte queste peculiari caratteristiche è il PRIMARY NURSE MODEL, che dopo numerosi test in vari studi, viene raccomandato nelle linee guida. Il primary nursing è un sistema di erogazione dell'assistenza basato sulle relazioni e guidato dalle risorse, gli elementi costitutivi sono: attribuzione e accettazione da parte di ciascun individuo della responsabilità personale nel prendere decisioni; assegnazione dell'assistenza quotidiana secondo il metodo dei casi (case method); comunicazione diretta da persona a persona; una persona operativamente responsabile per la qualità dell'assistenza erogata ai pazienti. L'approccio decisionale decentralizzato è fondato su tre concetti base: autorità decisionale di competenza dell'infermiere (authority), responsabilità (responsibility) e assunzione di responsabilità (accountability).
Risultati e Conclusioni. Il vero CORE di questo modello è rappresentato dalla responsabilità per le decisioni assunte ad un unico infermiere, chiamato Primary Nurse o Infermiere di Riferimento. Quindi ogni paziente è assegnato ad un infermiere responsabile della continuità delle cure, i cui compiti includono educazione e addestramento del paziente e del caregiver, inserimento dei dati nel sito web, revisione delle trasmissioni e valutazioni dei casi critici, sottomissione dei casi critici al medico, contatto con il paziente, controllo della compliance del paziente e dei benefici della terapia. Ogni infermiere di riferimento riferisce al medico referente, responsabile del consenso informato, della supervisione e della refertazione delle trasmissioni e della gestione clinica dei problemi emergenti.

A181: NURSE CLINICAL COMPETENCE: LA GESTIONE IN AUTONOMIA DEI LOOP RECORDER IMPIANTABILI, DALL'IMPIANTO AL FOLLOW UP.

Alessandro Faraci (a, b), Egle Corrado (a, b), Giuseppe Coppola (a), Romena Grimaudo (a), Daniele Messana (b)
(a) A.O.U. POLICLINICO "P. GIACCONE" DI PALERMO; (b) UNIVERSITÀ DEGLI STUDI DI PALERMO

Introduzione. Il Loop Recorder Impiantabile (ILR) noto anche come Monitor Cardiaco Impiantabile (ICM) è un dispositivo programmabile in grado di registrare continuamente l'attività elettrica cardiaca di un paziente per periodi di tempo prolungati (fino a 3 anni). Il dispositivo è impiegato nel percorso diagnostico di varie tipologie di disturbo cardiaco, dalla tachicardia e bradicardia ventricolare, alle sincopi di origine inspiegata, all'ictus criptogenetico, come pure per il rilevamento e la gestione della fibrillazione atriale. Inoltre, durante un evento sintomatico o nel periodo immediatamente successivo, il paziente ha la possibilità di attivare il dispositivo in modo da registrare il ritmo cardiaco.
Obiettivi. Grazie alle sue piccolissime dimensioni può essere "iniettato" nel sottocute del torace del paziente attraverso una piccola incisione, utilizzando i kit forniti dalle aziende produttrici che comprendono: tool d'incisione; dispositivo impiantabile precaricato nello strumento d'inserzione; manuale tecnico. Vista la semplicità e la mini invasività (Legge Stabilità, comma 566), questa procedura può essere svolta in piena autonomia dagli infermieri adeguatamente formati che abbiano ricevuto una formazione post-base mirata ed esperti in elettrostimolazione. La procedura viene eseguita in regime di day hospital e può essere effettuata al di fuori della sala operatoria, nonostante ciò, è fondamentale lavorare in un ambiente "pulito", come la sala risveglio.
Materiali e metodi. L'impianto prevede le seguenti fasi: configurazione del dispositivo, preparazione del paziente e del campo sterile, impianto, verifica della qualità del segnale e affidabilità del sensing dell'ampiezza dell'onda R (che deve essere almeno 0,2 mv, altrimenti va riposizionato), programmazione e attivazione della raccolta dei dati. In base all'anatomia del paziente e alla struttura del tessuto corporeo, che devono essere tenuti in considerazione, le sedi consigliate per l'impianto del dispositivo senza bisogno di eseguire una mappatura di superficie preliminare per determinare la qualità del segnale e l'affidabilità del sensing dell'ampiezza dell'onda R sono due:

- (1Best) Sede migliore 4° spazio intercostale a circa 2 cm dal margine sternale sinistro inclinato di 45° rispetto allo sterno, parallelo al vettore cardiaco.
- (2Good) Sede accettabile 4° spazio intercostale a circa 2 cm in parallelo dal margine sternale.

Risultati e Conclusioni. Il coinvolgimento dell'infermiere, dalla fase d'impianto al follow up, ne ha ampliato le competenze professionali. Apportando vantaggi sia per la struttura sanitaria, con riduzione dei tempi e delle liste d'attesa grazie all'incremento del numero di procedure. Sia per il paziente, con la semplificazione della procedura d'inserimento; riduzione della dimensione della ferita; non necessita di restrizioni a letto o di limitazione nei movimenti e quindi riduzione della degenza in ospedale; follow up da remoto, che aumenta comfort e sicurezza garantendo una migliore compliance del paziente.

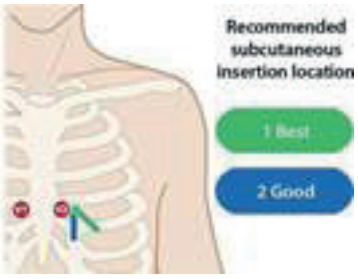

A182: SAFETY LIST FOR A LOW RISK IN CARDIOLOGIA INTERVENTISTICA

Alessandro Faraci (a, c), Giuseppina Novo (c, e), Salvatore Evola (a), Francesca Rocca (b), Daniele Messana (a, c), Romena Grimaudo (d)
(a) A.O.U. POLICLINICO "P. GIACCONE" DI PALERMO U.O. CARDIOLOGIA INTERVENTISTICA; (b) A.O.U. POLICLINICO "P. GIACCONE" DI PALERMO U.O. RISK MANAGEMENT E QUALITÀ; (c) UNIVERSITÀ DEGLI STUDI DI PALERMO; (d) A.O.U. POLICLINICO "P. GIACCONE" DI PALERMO U.O.S. UTIC; (e) A.O.U. POLICLINICO "P. GIACCONE" DI PALERMO U.O.C. CARDIOLOGIA

Introduzione. La sicurezza nei laboratori di Cardiologia Interventistica si contraddistingue per la complessità intrinseca che caratterizza tutte le procedure interventistiche, anche quelle più semplici: complessità dovuta al numero di persone e professionalità coinvolte, alle condizioni acute o gravi dei pazienti, alla quantità d'informazioni richieste, all'urgenza con cui i processi devono essere eseguiti, all'elevato livello tecno-

logico e di alta specialità ed alla molteplicità di punti critici del processo che possono provocare gravi danni ai pazienti. Per tale motivo è stata ideata e redatta una "safety list intraoperatoria per la cardiologia interventistica"

Scopo. L'obiettivo principale di questo documento è finalizzato a: migliorare la qualità e la sicurezza degli interventi chirurgici e delle procedure interventistiche/strutturali, diffusione di raccomandazioni e standard di sicurezza volti a rafforzare i processi pre - intra e post operatori, implementazione degli standard di sicurezza tramite l'applicazione della safety list adattandola alle caratteristiche della propria organizzazione.

Materiali e metodi. La safety list è stata pensata per combinare la "check list" intraoperatoria ad una "scheda infermieristica", raccogliendo le informazioni attinenti alle singole persone assistite, in modo da favorire la continuità e la personalizzazione dell'assistenza, rappresenta una risorsa per la ricerca sull'assistenza infermieristica, per l'analisi della complessità assistenziale e consente la tracciabilità delle azioni svolte. È suddivisa in otto parti che seguono il paziente in tutte le sue fasi, dall'ingresso in sala fino all'uscita, un'altra parte è dedicata al materiale utilizzato per la procedura.

Risultati e Conclusioni. Dopo anni di costanti revisioni e aggiornamenti con la collaborazione dello staff risk management e qualità, la safety list è diventata parte fondamentale del lavoro di sala sostenendo sia i cambiamenti di sistema che quelli individuali rafforzando gli standard per la sicurezza ed i processi di comunicazione, contrastandone i possibili fattori di fallimento.



A183: LA LITOTRISSIA INTRAVASCOLARE CORONARICA IN PAZIENTI AFFETTI DA STENOSI CALCIFICHE DI DIFFICILE TRATTAMENTO.

Alessandro Faraci (a, b), Salvatore Evola (a), Daniele Adorno (a), Daniele Messana (a, b), Romena Grimaudo (a)
(a) A.O.U. POLICLINICO "P. GIACCONE" DI PALERMO; (b) UNIVERSITÀ DEGLI STUDI DI PALERMO

Introduzione. Donna di 72 anni, affetta da cardiopatia ischemica ipertensiva, diabete mellito tipo II con complicazioni circolatorie periferiche e ipercolesterolemia pura. Giunge presso il nostro laboratorio di emodinamica in urgenza tramite RETE IMA/118 per sopraslivellamento del tratto ST (STEMI) infero-laterale in BAV totale parossistico. Si procede con la coronarografia per trattare la lesione culprit. Al quadro coronarografico si riscontra occlusione trombotica all'edge prossimale dello stent precedentemente impiantato in coronaria destra media, la coronaria sinistra mostra lieve ateromasia diffusa in assenza di stenosi angiograficamente significative. Si effettua tentativo di riapertura del vaso con predilatazioni multiple con cateteri a palloncino semicomplianti e non complianti senza ottenere espansione completa. Vista l'impossibilità di impiantare lo stent, si procede alla dilatazione con pallone medicato 2.5x20mm per 1 minuto e si programma utilizzo di litotrissia intravascolare (IVL) Shockwave in seconda battuta.

Materiali e metodi. L'IVL prevede la generazione di onde sonore pulsatili nel sito bersaglio mirata a perseguire il realizzarsi di microfratture del tessuto calcifico, modificando la compliance del vaso, senza però danneggiarlo. Nel dettaglio il sistema è composto da un generatore d'impulsi elettrici, un cavo di connessione e un catetere a palloncino. Dopo la preparazione standard del pallone con una miscela di soluzione salina/mezzo di contrasto si fa avanzare su una guida 0.014" fino a livello della stenosi da trattare.

Risultati. Dopo la preparazione e l'utilizzo del sistema di litotrissia intravascolare (IVL) shockwave con un pallone 2.5x12 mm, sono stati erogati 5 cicli di 10 impulsi per un totale di 50 impulsi. Segue dilatazione con pallone non compliante 2.5x15 mm con ottimale espansione del pallone. Si è quindi proceduto all'impianto dello stent medicato 2.75x16 mm al tratto medio in overlap con lo stent già presente. Ottenendo un buon risultato angiografico finale ed un flusso coronarico adeguato (TIMI 3).

Conclusioni. L'utilizzo della litotrissia intravascolare coronarica ha permesso di ottimizzare il risultato dell'angioplastica precedentemente fallito, perseguendo un ottimo risultato angiografico con rischi contenuti.

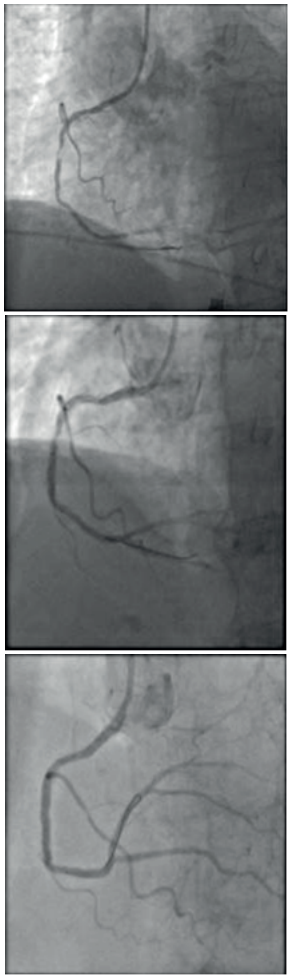

A184: DESCRIZIONE DEI PERCORSI ORGANIZZATIVI E DELLE RISORSE UTILIZZATE NELLA GESTIONE DEL PAZIENTE PORTATORE DI LEFT VENTRICULAR ASSIST DEVICE (LVAD) NEI CENTRI DI RIFERIMENTO ITALIANI

Jessica Gemelli (a), Alessia Trenta (a), Michela Luciani (a), Davide Ausili (a)
(a) UNIVERSITÀ DEGLI STUDI MILANO-BICOCCA

Il progressivo aumento degli impianti di Left Ventricular Assist Device (LVAD) ha portato a un miglioramento della sopravvivenza a breve e medio termine dei pazienti con scompenso cardiaco avanzato. Visti la complessità e l'elevato grado di specializzazione necessari per la presa in carico di questi assistiti, conoscere le modalità con cui vengono organizzati i loro percorsi di cura e le risorse messe a disposizione, potrebbe essere utile per confrontare e rivalutare tali percorsi alla luce di quanto suggerito dalla più recente letteratura. Nonostante la rilevanza del tema, ad oggi non si trovano in letteratura studi che descrivano i percorsi di cura e le risorse in essi impiegate per la gestione del paziente con LVAD in Italia. L'obiettivo di questo studio è stato descrivere i percorsi organizzativi e le risorse utilizzate nella gestione dei pazienti con LVAD nei centri italiani che impiantano il device. È stato condotto uno studio quantitativo osservazionale trasversale. A tal proposito, è stata sviluppata una survey sottoposta al giudizio di esperti e approvata dal Comitato Etico dell'Università degli studi di Milano Bicocca. Sono stati identificati 22 centri specialistici nazionali, ai quali è stata sottoposta la survey. Sui dati raccolti è stata effettuata un'analisti statistica descrittiva. Lo studio ha consentito di descrivere i percorsi organizzativi e le risorse impiegate dai centri italiani nella gestione del paziente portatore di LVAD. Dai dati ottenuti è stato riscontrato che tra i professionisti sanitari maggiormente coinvolti in ogni fase di cura sia presente l'infermiere oltre alla figura essenziale dell'LVAD Coordinator. L'LVAD Coordinator, infatti, risulta avere un ruolo centrale per il paziente e per tutta l'equipe sanitaria specializzata attraverso la gestione delle cure nella loro globalità, garantendone così continuità clinica e assistenziale in tutto il percorso. Tutti i centri, inoltre, sono concordi della rilevanza del caregiver sin dalla fase iniziale di pre-impianto del dispositivo e in generale, in tutti gli aspetti che riguardano il monitoraggio e l'educazione del paziente portatore di LVAD. L'educazione risulta avere, nei centri coinvolti, un ruolo rilevante nella corretta gestione del dispositivo e nella prevenzione delle complicanze connesse, nonostante quanto affermato, solo una parte dei centri afferma di avviare tale attività prima dell'impianto del dispositivo. Un altro aspetto fondamentale emerso da tale ricerca è stata l'assenza di percorsi specifici rivolti alle cure palliative per i pazienti portatori del dispositivo, anche se ad oggi, le più recenti linee guida sul tema sottolineano l'importante di affrontare questo tema prima dell'impianto del dispositivo. Dai dati ottenuti sono state rilevate alcune aree che in futuro sarebbero da approfondire nell'ottica di migliorare l'assistenza al paziente portatore di LVAD, tra cui: lo sviluppo di modalità alternative di educazione e monitoraggio; il potenziamento di una maggior offerta formativa ai professionisti sul territorio non esperti di LVAD ed infine, lo sviluppo di percorsi dedicati alle cure palliative. Partendo da questo studio, potrebbe essere interessante in futuro effettuare confronti con l'obiettivo di rivalutare ed eventualmente modificare alcuni dei servizi offerti a questi pazienti e uniformare così l'assistenza alla persona portatrice di LVAD.

A185: IMPACT OF ANTIHYPERTENSIVE MEDICATION ON SEXUAL HEALTH AMONGST HYPERTENSIVE PATIENTS: A SYSTEMATIC REVIEW

Enrico Maria Gianfranceschi (a), Elisa Nardin (a), Franca Amato (a), Richard Sucapuca (a), Marina Sodano (a), Carla Amigoni (a), Gianfranco Parati (a), Francesca Tagliacarne (a)
(a) ISTITUTO AUXOLOGICO ITALIANO

Background. It is well established, within the scientific community, that anti-hypertensive drugs hold and impact on sexual health. The most frequent symptoms of impaired sexual health in hypertensive patients are reported to be, reduction of sexual drive (libido), impaired orgasmic function, and erectile dysfunctions (male).
Objectives. This systematic review objectives are (1) to clearly define the impact of anti-hypertensive drugs on sexual health, (2) to identify potential correlation between specific medication and sexual health impairment.
Methods. The literature search was conducted through PubMed and Google Scholar. The following key word were used: Arterial Hypertension; Anti-hypertensive Medications; Antihypertensive Agents; Libido Reduction; Sexual Function. Using filters for 10 years and FULL TEXT papers. Twenty-one papers were selected for analysis following the research and were read by 3 independent researchers.
Results. The available evidence confirms a correlation between antihypertensive medications and sexual health impairment. Several medications were found to be correlated with higher sexual health dysfunctions, with only a few identified as neutral, whilst only one was found to have a positive effect purely on male. For those experiencing negative effects, the majority stated to have a reduced compliance to therapy due to its effects on sexual health.
Conclusions. There is a clear correlation between hypertension, anti-hypertensive medication and sexual health. Despite the established important role of sexual health within a person lifestyle, this remain widely underestimated and unconsidered within hypertension clinical practice. In fact, we did not find a univocal definition for "sexual disfunctions" and "sexual health", with the only exception made by male erection disfunctions. Patients suffering of hypertension are more likely to experience sexual health disfunctions, although this is rarely accounted for during clinical visits and therapy planning. Moreover, the use of systemic sexual health screenings and guideline is recognising to be necessary and need urgent implementation. Future studies should focus on sexual health screening and guidelines implementation, particularly focusing on non-heterosexual couples and women.

A186: POST-INTENSIVE CARE SYNDROME AFTER CARDIAC SURGERY: A LITERATURE REVIEW

Francesco Gravante (a), Francesca Trotta (a), Salvatore Latina (a), Ercole Vellone (a), Rosaria Alvaro (a), Silvio Simenone (b), Gianluca Pucciarelli (a)
(a) DEPARTMENT OF BIOMEDICINE AND PREVENTION, UNIVERSITY OF ROME TOR VERGATA, ROME, ITALY; (b) DEPARMENT OF CLINICAL AND EXPERIMENTAL MEDICINE, UNIVERSITY OF CATANZARO MAGNA GRAECIA, CATANZARO, ITALY

Introduction. Post Intensive Care Syndrome (PICS) is a new impartment or an existing worsening in three dimensions: physical, cognitive and mental. There is a lack of knowledge about quality of life (QoL) in Intensive Care Unit (ICU) patients with PICS after cardiac surgery.
Objective. To describe the long-term outcomes and QoL of ICU patients with PICS after cardiac surgery.
Methods. This literature review will follow the Preferred Reporting Items for Systematic Reviews and Meta-Analyses (PRISMA). PubMed, Scopus, Web of Science and CINAHL databases were searched. Eligible studies were quantitative (observational, RCT, cohort and longitudinal study) and qualitative research that reported the long-term outcomes and QoL of ICU patients with PICS after cardiac surgery.
Results. A total of 202 records were generated from the research question. After duplicate removal (n=160), 42 titles and abstracts were screened. Twenty-seven full texts were evaluated, and 6 studies were included. Three studies reported QoL in ICU patients with PICS after cardiac surgery. Off-pump Coronary artery bypass graft patients had improved physical QoL. Physical and mental QoL were independently associated with sleeping quality at 6 months. ICU survivors in the New York Heart Association (NYHA) class I/II reported significantly lower physical function. Depression was a critical outcome reported by ICU survivors with PICS after cardiac surgery.
Conclusions. QoL in ICU survivors after cardiovascular surgery was a significant problem. Future research should investigate the effects of admission to the ICU after cardiac surgery with more extensive studies.

A187: L'IMPORTANZA DEL CORSO ACLS PER L'INFERMIERE DI AREA CRITICA

Vittorio Guiscardo (a)
(a) OSPEDALE SANTA MARIA GORETTI LATINA

Background. Il corso ACLS ha l'obiettivo di formare un team multidisciplinare sia medico che infermieristico nel trattamento di un adulto in una situazione di peri-arresto o di arresto cardiaco, facendo particolare attenzione alle cause reversibili che hanno portato la persona in quella condizione. Una gestione ottimale ALS del paziente in arresto cardiaco o peri-arresto può contribuire in modo determinante a favorire una significativa amplificazione statistica dei risultati ottenuti nella gestione terapeutica del paziente quale la percentuale di dimessi vivi dall'ospedale e senza esiti neurologici invalidanti.
Obiettivi. L'obiettivo della tesi è volto a sensibilizzare l'importanza del corso ACLS, delle procedure insegnate ed i relativi presidi. Nonché l'importanza che determinati corsi come questo vengano imposti e rimborsati dalle aziende e gli enti preposti affinché vi sia un numero maggiore di personale infermieristico adeguatamente formato con le EBN più recenti e non soltanto con le conoscenze del percorso di laurea.
Materiali e metodi. Per l'elaborazione della tesi ho redatto e somministrato digitalmente un questionario di 14 item rivolto al personale infermieristico impiegato nell'ambito dell'area critica. Sono stati inclusi nello studio un totale di 100 infermieri dislocati nelle varie regioni d'Italia. Con lo scopo di andare a valutare le conoscenze teoriche, le motivazioni che hanno spinto quest'ultimi a conseguire o meno il corso e le loro considerazioni riguardo l'utilità.
Risultati e Conclusioni. Dal questionario si evince che l'importanza dell'ACLS sia riconosciuta da quasi tutti gli infermieri che lo ritengono fondamentale per lavorare in area critica, ma in quanto non obbligatorio come requisito le aziende nella maggioranza dei casi non finanziano il corso e soltanto la metà degli infermieri l'ha conseguito autonomamente. Nonostante questo vi è una scarsa conoscenza delle nozioni di base spiegate nel corso dunque un'altra evidenza dell'importanza del corso sopracitato per lavorare in maniera efficace ed efficiente in ambito di area critica.

A188: THE ROLE OF CITIZENS AND NEW TECHNOLOGIES FOR A BETTER MANAGEMENT OF OUT-OF-HOSPITAL CARDIAC ARREST

Guglielmo Imbriaco (a, b), Nicola Ramacciati (c)
(a) CENTRALE OPERATIVA 118 EMILIA EST, OSPEDALE MAGGIORE, AUSL DI BOLOGNA, ITALY; (b) DEPARTMENT OF BIOMEDICINE AND PREVENTION, UNIVERSITY OF ROME "TOR VERGATA", ROME, ITALY; (c) DEPARTMENT OF PHARMACY, HEALTH AND NUTRITIONAL SCIENCES, UNIVERSITY OF CALABRIA, COSENZA, ITALY

Out-of-hospital cardiac arrest (OHCA) is the third leading cause of death in European countries, affecting more than 400,000 people every year. The strategies identified to reduce mortality are, in addition to a timely and effective intervention of prehospital emergency medical services (EMS), the early identification of cardiac arrest and the role of bystanders as potential first responders able to perform cardiopulmonary resuscitation (CPR). Several studies reported that CPR performed by bystanders achieved a percentage of return to a spontaneous circulation in more than 30% of cases, doubling the survival rate of CPR carried out only by EMS providers (9.1% vs 4.3%) (EuReCa1 study, 2014; EuReCa2 study, 2017). This encouraging data led to a general agreement among scientific societies, emphasizing the importance of bystanders and promoting interventions to increase the number of lay people able to perform CPR in case of OHCA. The concept behind this is that engaging laypeople and first responders to perform CPR before the arrival of an ambulance represents a key feature in minimizing the free treatment interval in cardiac arrest patients, reducing the no-flow time and, thus, achieving better outcomes. This participative approach is based on a strict cooperation between EMS dispatch centers and lay people, involving some essential and fundamental elements:

- CPR training for an increasing number of citizens, starting from the school context and from primary school (as provided by the Italian Law 116/2021);
- the availability on the territory of an adequate number of semi-automatic defibrillators (at least 2/km^2), accessible and mapped through computerized systems managed by EMS dispatch centers;
- alert and geolocation of first responders through text messages or applications installed on smartphones;
- the ability of EMS dispatchers to provide instructions to bystanders on how to perform CPR. Dispatcher-assisted CPR instructions can be provided by phone or through video-communication systems, currently available on most smartphones.

The main objective of this lecture is to analyze the state-of-the-art of the literature, the advantages of these innovative strategies, and their potential development in the future. In particular, the different facets of dispatcher-assisted CPR instructions, the interactions between laypeople and EMS dispatchers, and their availability in Italian EMS services (including the use of new technologies) will be discussed.

A189: DAL CORSO GEA AL GEA TEAM: L'IMPORTANZA DELLA FORMAZIONE NELLA PREVENZIONE DELLE COMPLICANZE

Giulia Martinenghi (a), Francesco Reitano (a), Diego Vannini (a), Mariangela Alberti (a)
(a) CENTRO CARDIOLOGICO MONZINO

Introduzione. La gestione dell'emostasi arteriosa è una sfida importante nelle Sale di Emodinamica e nelle Unità Operative. Spesso gli infermieri dei reparti di degenza si trovano a gestire dispositivi di emostasi e complicanze senza una formazione adeguata.
Materiali e metodi. Presso il Centro Cardiologico Monzino (C.C.F.M), la scelta dell'accesso arterioso radiale per eseguire coronarografie è diventata la pratica standard dal 2015. Tuttavia, ci sono diverse complicanze associate a questo tipo di accesso, come l'occlusione vascolare, il sanguinamento, l'ematoma e la sindrome compartimentale. Per gestire queste complicanze e preservare la salute vascolare del paziente, è necessaria una formazione adeguata del personale infermieristico sulla gestione dei dispositivi di emostasi. Il gruppo infermieristico di emodinamica ha quindi creato il corso di formazione sulla gestione dell'emostasi arteriosa (corso GEA), che fornisce conoscenze e competenze sul posizionamento, la gestione e la rimozione del device di emostasi radiale. Il corso include sessioni teoriche, training in sala di emodinamica e simulazioni.
Risultati. Finora, il corso ha formato con successo 90 infermieri presso il C.C.F.M., contribuendo a uniformare i modelli assistenziali e migliorare le abilità tecniche del personale infermieristico. Al C.C.F.M è stato inoltre creato il Team per la Gestione dell'Emostasi Arteriosa (GEA TEAM) per continuare il confronto e l'aggiornamento. È un gruppo di miglioramento che mira ad acquisire competenze avanzate nell'utilizzo di apparecchiature e dispositivi, approfondendo le conoscenze acquisite durante il corso GEA e seguendo le nuove metodiche di intervento. Si ricercano anche nuove evidenze per la gestione dell'emostasi arteriosa e delle complicanze. Il GEA TEAM si riunisce ogni due mesi con la partecipazione di infermieri che hanno completato con successo il corso GEA. Durante gli incontri, vengono condivisi e discussi casi clinici utilizzando una scheda di raccolta dati creata dal gruppo. Questa scheda viene compilata dagli infermieri in caso di emostasi arteriose complesse. Con la creazione del GEA TEAM, gli infermieri diventano punti di riferimento per la gestione delle emostasi complesse, offrendo assistenza, guida e informazioni ai colleghi per garantire una gestione adeguata delle emostasi arteriose.
Conclusioni. Sia il corso GEA che il GEA TEAM mirano a migliorare la gestione dell'emostasi arteriosa e delle complicanze, fornendo un punto di riferimento per gli infermieri e promuovendo la qualità dell'assistenza.

A190: CATETERISMO CARDIACO DESTRO: NUOVA FRONTIERA DIAGNOSTICA MINI-INVASIVA DAL BRACCIO

Antonio Mellino (a), Vannini Diego (a), Francesco Reitano (a), Ivan Consoli (a), Alberti Mariangela (a), Alessia Trenta (a), Giulia Martinenghi (a)
(a) CENTRO CARDIOLOGICO MONZINO

Introduzione. Anche presso il IRCCS Centro Cardiologico Monzino (CCM), nel laboratorio di emodinamica, la procedura cateterismo cardiaco destro si eseguiva tramite una puntura eco-guidata della vena femorale. Da novembre 2022 si è iniziato ad eseguire l'esame mediante la puntura eco-guidata di un vaso venoso superficiale del braccio (vena antecubitale, vena basilica, vena cefalica). Dall'analisi della letteratura sono stati selezionati tre studi, i quali avevano come obbiettivo il confronto tra cateterismo cardiaco destro eseguito da un vaso venoso del braccio (antecubitale) e cateterismo destro eseguito da un vaso venoso di grande calibro (giugulare o femorale). Tutti gli studi hanno dimostrato una riduzione delle complicanze nell'esecuzione della procedura dal braccio e una riduzione della dose di radiazioni assorbita. Sulla base dei dati reperiti si è reputato opportuno effettuare una raccolta dati che voglia confrontare i nostri dati con la letteratura in termini di complicanze vascolari e dose di radiazioni assorbite dal paziente.
Materiali e metodi. Al fine di raggiungere lo scopo verranno raccolti e analizzati i dati dei pazienti che sono stati sottoposti e/o saranno sottoposti per indicazione clinica a cateterismo destro da gennaio 2021. Verrà considerata una coorte retrospettiva di pazienti che sono stati sottoposti a cateterismo destro dalla femorale (gruppo controllo) e una coorte prospettica di pazienti che eseguiranno cateterismo destro da un vaso superficiale del braccio (antecubitale, basilica, cefalica) con il posizionamento di un introduttore 7 FR attraverso una puntura eco-guidata eseguita da un infermiere formato. Sulla base dell'analisi statistica si è definito come numerosità campionaria per le due coorti un numero di 110 pazienti, 55 per la coorte retrospettiva e 55 per la corte prospettica. Sia nel gruppo prospettico che retrospettivo si andranno a controllare le complicanze vascolari il disconfort del paziente e l'esposizione ai raggi x.
Risultati. Nei 55 cateterismi destri della coorte retrospettiva, la complicanza che si è verificata maggiormente è l'ematoma minore con una percentuale del 5,45%. Inoltre, occorre segnalare una perforazione (1,81%) e una puntura accidentale dell'arteria femorale (1,81%). Mentre la media delle radiazioni emanate dalla macchina è risultata essere 1817,56 µgym2. Seppur ancora non completato l'arruolamento dei pazienti della corte prospettica il dato parziale risulta essere già significativo poiché, dei 26 già eseguiti e analizzati, nessuno ha presentato complicanze e la dose media di radiazioni emanate dalla macchina è risultata essere notevolmente inferiore rispetto alla controparte femorale (468,11 µgym2).
Conclusioni. L'indagine svolta, seppur ancora incompleta nell'arruolamento della coorte prospettica, consente di mettere in evidenza come questa nuova tecnica intrapresa dal gruppo infermieristico, sposata dalla componente medica, consenta una riduzione delle complicanze vascolari e una riduzione della dose di radiazioni assorbite dal paziente e degli operatori impegnati nella procedura. Inoltre, non bisogna tralasciare come, mediante la tecnica dal braccio, il confort del paziente risulta notevolmente migliorato vista la mobilizzazione precoce e l'assenza di fastidiose fasciature.

A191: ACCESSO VASCOLARE ECO-GUIDATO

Attilio Montagna (a)
(a) SAN CAMILLO FORLANINI

L'inserimento e la stabilità dell'introduttore arterioso/venoso rappresenta un momento cruciale per la corretta esecuzione e il buon esito di tutte le procedure interventistiche di emodinamica. La tecnica eco – guidata è la metodica che assicura una più elevata percentuale di successo e permette un più sicuro e rapido posizionamento dell'introduttore rispetto alla tecnica convenzionale. Tuttavia l'implementazione di tale metodica è ostacolata dall'assenza di un percorso formativo e di uno specifico training durante i corsi di specializzazione. Esistono evidenti vantaggi dell'incannulazione arteriosa/venosa con tecnica eco-guidata, che hanno dimostrato di essere maggiormente impattanti nel ridurre le complicanze maggiori, il tempo di esecuzione della procedura di inserimento dell'introduttore e la percentuale di successo al primo tentativo riducendo il numero di punture multiple. Le evidenze scientifiche suggeriscono che l'utilizzo della sola palpazione ha una percentuale di successo al primo tentativo inferiore al 70% ma, nonostante questo dato, è tutt'ora la tecnica più diffusa nelle sale di emodinamica. L'inserimento dell'introduttore, attraverso l'orientamento degli ultrasuoni, dovrebbe prevedere un approccio procedurale sistematico volto a migliorare l'appropriatezza della scelta dell'accesso vascolare, in riferimento alla procedura interventistica da effettuare, in modo da ottimizzarne le prestazioni. Inoltre, un processo metodologico di utilizzo degli ultrasuoni, ci permette di attuare la migliore strategia sia in termini di tecnica nella visualizzazione

del vaso sia in termini di tecnica nella visualizzazione dell'ago. La standardizzazione della guida ecografica nella gestione dell'accesso vascolare, per l'inserimento dell'introduttore arterioso/venoso ai fini procedurali, promuove la salute dei vasi e la sicurezza del paziente attraverso l'ottimizzazione del dispositivo e del sito di impianto. La valutazione sistematica della metodologia può essere utilizzata per limitare le variazioni dell'operatore non adeguatamente formato e promuovere l'uso di ultrasuoni come tecnica standard nella pratica clinica attraverso l'istituzione di nuovi percorsi educativi.

A192: L'HOLTER A 12 DERIVAZIONI NEL SOSPETTO PATTERN DI BRUGADA: POSIZIONE DEGLI ELETTRODI PRECORDIALI DI DESTRA E DI SINISTRA

Andrea Rosace (a), Giuseppina Saccà (a), Silvana Calabrò (a), Letteria Bruno (a), Francesco De Luca (a), Lilia Oreto (a)
(a) UNIVERSITÀ DI MESSINA - UOSD CARDIOLOGIA PEDIATRICA

Introduzione. La sindrome di Brugada è una malattia dei canali ionici associata a morte improvvisa. La diagnosi è basata sul riscontro del pattern di Brugada all'elettrocardiogramma a 12 derivazioni. La caratteristica del pattern di Brugada tipo 1 consiste nella presenza di un sopraslivellamento del tratto ST di 2 o più mm al punto J, con morfologia convessa, seguito da un'onda T negativa, nelle derivazioni precordiali destre (V1, V2 e V3). Talvolta il pattern diventa evidente solo spostando gli elettrodi V1 e V2 più in alto, al terzo e al secondo spazio intercostale; questa manovra aumenta quindi la sensibilità diagnostica dell'ECG. Nel sospetto di pattern di Brugada, in età pediatrica è raccomandato (Drago et al, Minerva Pediatrica 2020 February;72(1):1-13) di eseguire un ECG Holter a 12 derivazioni almeno una volta l'anno, preferibilmente posizionando gli elettrodi precordiali V1 e V2 anche al secondo e terzo spazio intercostale, oltre che al quarto come di consueto. Uno dei criteri utili per la diagnosi di pattern di Brugada all'ECG è anche basato sulla durata totale del QRS nelle precordiali destre, che risulta prolungata rispetto alle precordiali sinistre. Per valutare questo aspetto è necessario avere una registrazione simultanea di tutte le derivazioni precordiali.
Metodi e Risultati. Per ottenere questa valutazione anche all'ECG Holter, abbiamo avviato un protocollo di applicazione degli elettrodi precordiali che è una variante rispetto a quella citata dalle raccomandazioni. La variante consiste nel posizionare gli elettrodi V1 e V2 al secondo spazio intercostale, V3 e V4 al quarto spazio intercostale, mentre V5 e V6 mantengono la posizione usuale al quinto spazio intercostale, rispettivamente sulla linea ascellare anteriore e media. Con questa modalità di registrazione, pur dovendo rinunciare alla registrazione relativa al terzo spazio intercostale, viene data la possibilità di avere una registrazione simultanea delle precordiali destre (sia al secondo che al quarto spazio) e sinistre, per evidenziare eventuali differenze nella durata del QRS. Da gennaio a maggio 2023 abbiamo registrato un Holter ECG di 24 ore con questa variante di posizione degli elettrodi precordiali in 10 pazienti con sospetto pattern di Brugada. In 4 pazienti (40%) la durata del QRS nelle precordiali destre è risultata prolungata rispetto alle precordiali sinistre.
Conclusioni. Nel 40% dei casi l'utilizzo di questa variante di posizione degli elettrodi precordiali ha consentito di aggiungere un criterio di valutazione utile per la diagnosi di pattern di Brugada, che non sarebbe stato disponibile con la disposizione delle precordiali solo a destra.

A193: DEATH IN A CARDIOVASCULAR INTENSIVE CARE UNIT, A WAY TO SUPPORT BEREAVED FAMILIES

Annunziata Palermo (a), Dora Gallo-montemarano (a), Tiziano Cassina (a), Paola Rusca-grassellini (a), Lucia Pedrazzini (a), Stefano Bernasconi (a), Michele Villa (a)
(a) CARDIOCENTRO TICINO INSTITUTE, ENTE OSPEDALIERO CANTONALE, LUGANO, SWITZERLAND

Introduction. The loss of a loved one in Intensive Care can be an experience with intimate implications in an individual's life. The impact on families can be significant with anxiety, depression, post-traumatic stress disorder and complicated grief. The grief can induce uneasiness in family members with symptoms that may be underestimated even by healthcare professionals. In order to support relatives a nursing lead bereavement support service has been activated in our cardiovascular intensive care unit, intended as a multiple intervention program, consisting of a condolence letter, a telephone call and a follow up meeting post death (FMPD). Four weeks after the demise a standard sympathy card is sent to every bereaved family. Two weeks afterwards a nurse starts making calls to relatives to express condolences and offering the opportunity for a follow-up meeting face to face or by telephone. The purpose of the analysis is to describe the modality of access to this service and the needs expressed by the families during the meetings.
Methods. Retrospective descriptive analysis of meeting reports from 2007 to 2019.
Results. In 12 years, two nurses in our intensive care unit followed 468 bereaved families with a multiple intervention program. The following results were pointed out: 267 (57.1%) patients agreed for a meeting, 141 (30.1%) in-person and 127 (27.1%) preferred by telephone. Phone calls lasted in averaged 21 min. [16-31], FMPDs in-person 52 min. [40-69]. From the content analysis of the follow-up interview reports, the main topics mentioned during the meetings were sharing the experience of grief (74.9%), obtaining more details about the hospital ICU course (56.6%), and verifying a suffering-free end-of-life (43.4%). Nurses identified the need for further interventions during the interviews, with the following needs: a further meeting with physicians (n=28), support from the family doctor (n=17), psychological and social support (n=10).
Conclusions. This study shows the relevance of an interaction between health staff and bereaved families. Bereaved follow-up program has been appreciated by more than half of the families and has been an opportunity to piece together the picture of events in a colloquial and non-formal environment, which encourages the legitimation of every emotional state. This setting gave the possibility to share what they lived, ask for more information and be free to express eventual disagreements/claims. For team members of ICU these meetings are a feedback on the quality of care provided to cardiovascular acute illness patients.

A194: FABRY DISEASE AND ITS IMPACT ON THE HEART: EMPOWERING NURSES IN ENHANCING CARE AND MANAGEMENT

Gaetano Artiola (a), Vincenzo Pettillo (a)
(a) AORN OSPEDALI DEI COLLI - V. MONALDI

Introduction. Fabry's disease is a rare genetic disorder that affects various organs, including the heart. As a nurse, understanding the impact of Fabry's disease on the heart and providing specialized care for patients with this condition are essential in managing their health effectively. Fabry's disease is caused by a mutation in the GLA gene, resulting in the deficiency of an enzyme called alpha-galactosidase A. This enzyme is responsible for breaking down a specific lipid called globotriaosylceramide (Gb3). In the absence of this enzyme, Gb3 accumulates within cells, leading to cellular dysfunction and damage in various organs, including the heart. Heart is particularly vulnerable to the effects of Fabry's disease. The accumulation of Gb3 within cardiac cells can lead to structural and functional abnormalities. Common cardiac manifestations include left ventricular hypertrophy (LVH), diastolic dysfunction, and arrhythmias. LVH is the thickening of the heart's left ventricle, which can impair its ability to pump blood effectively. Diastolic dysfunction refers to abnormalities in the heart's relaxation phase, leading to impaired filling of the ventricles. These cardiac changes can result in heart failure and life-threatening arrhythmias.
Aim. Increase nurse's training to improve patient quality of life and management. Teach patient management of signs and symptoms. Support for therapeutic adherence.
Methods. Database research and real experiences in the hospital.
Results and Discussion. As a lifelong condition with multi-system involvement, nursers play a pivotal part in coordinating care, educating cases and their families, and addressing both physical and emotional requirements. Also, during medication administration, such as enzyme replacement therapy, ensuring timely administration of these medications and monitoring for any adverse reactions is critical.
Conclusions. As a nurse caring for patients with Fabry's disease, understanding the cardiac implications of this condition and providing specialized care are crucial in improving patient outcomes and enhancing their overall well-being. By actively monitoring cardiac function, managing symptoms, and collaborating with the healthcare team, nurses play a central role in optimizing the care and quality of life for individuals affected by this rare genetic disorder.

A195: ANTIMICROBIAL ENVELOPES AND ENDOCARDITIS: INNOVATIVE SOLUTIONS FOR CIED'S INFECTION

Vincenzo Pettillo (a), Gaetano Artiola (a)
(a) AORN OSPEDALI DEI COLLI - V. MONALDI

Introduction. Endocarditis recurrence in patients with cardiac implantable electronic devices (CIEDs) remains a serious concern, demanding effective preventive measures. There is not always the possibility of extraction with a contralateral implant or the implantation of innovative devices. In recent years, two innovative technologies, TYRX and CanGaroo, have emerged as promising solutions to reduce the risk of endocarditis recurrence and improve patient outcomes. TYRX and CanGaroo are two cutting-edge medical technologies designed to address a critical concern in the management of patients with cardiac implantable electronic devices (CIEDs): the prevention and treatment of infected

pockets. Both TYRX and CanGaroo offer unique approaches to mitigate this risk and improve patient outcomes. The TYRX is composed of a mesh envelope containing two antimicrobial agents, minocycline, and rifampin, that providing local and sustained delivery of antimicrobial agents directly at the device pocket. Instead, the primary function of the CanGaroo is to create a physical barrier between the CIED and the surrounding tissues, reducing the risk of bacterial contamination. The CanGaroo envelope's physical protection is particularly valuable in cases where patients have a higher risk of endocarditis recurrence due to underlying health conditions, compromised immune systems, or previous episodes of infection. By minimizing the direct contact between the CIED and adjacent tissues, the CanGaroo helps reduce the risk of bacterial adherence and biofilm formation.
Aim. Educate the patient and caregiver to recognize signs of infection and avoid contamination. Improve training and education of cardiology nurse specialists for the prevention and recurrence of endocarditis on intra-operative management using these new devices and the post-operative course.
Methods. Database research and field evaluations.
Results and Discussion. TYRX and CanGaroo are groundbreaking technologies that demonstrate the potential to reduce the recurrence of endocarditis in patients with CIEDs. Their innovative designs and positive clinical outcomes highlight their importance as valuable tools in infection prevention strategies for CIED recipients.
Conclusions. Both TYRX and CanGaroo offer innovative approaches to prevent endocarditis recurrence in patients with CIEDs. By utilizing their unique mechanisms, these devices contribute to a multi-pronged infection prevention strategy. The TYRX envelope's localized antimicrobial delivery and the CanGaroo envelope's physical protection complement standard infection control measures during implantation. It is important to note that while TYRX and CanGaroo offer significant advances in infection prevention, they are not standalone solutions. A comprehensive approach, including stringent infection control protocols, patient selection, and diligent post-implantation monitoring, is crucial in reducing the risk of endocarditis recurrence effectively.

A196: FALSI ALLARMI IN TERAPIA INTENSIVA: INDAGINE QUALITATIVA SUL FENOMENO DELL'ALARM FATIGUE

Giulio Ragusa (a)
(a) CDL IN INFERMIERISTICA (ABILITANTE ALLA PROFESSIONE SANITARIA DI INFERMIERE) - CORSO DI LAUREA Q - ASL LATINA (DISTRETTO NORD)

Introduzione. In Terapia Intensiva il personale sanitario e i pazienti devono affrontare quotidianamente una quantità eccessiva di allarmi. Nonostante siano fondamentali per il monitoraggio in un ambiente critico, la maggior parte di questi avvertimenti sono definiti come falsi positivi e spesso clinicamente irrilevanti, causando interruzioni nel flusso di lavoro. Il fenomeno a cui si va incontro è l'alarm fatigue (o affaticamento da allarme) con il conseguente "cry-wolf effect", definito come un sovraccarico sensoriale che può causare gravi effetti negativi sia sul personale sanitario, soprattutto infermieri, che sui pazienti. L'affaticamento da allarme è stato riconosciuto come un vero e proprio problema da organizzazioni come la Joint Commission, l'Emergency Care Research Institute (ECRI) e la Healthcare Technology Foundation, tanto da essere considerato come uno dei pericoli più importanti da gestire nel campo sanitario.
Obiettivi. Il presente studio è stato elaborato partendo da tre obiettivi, ovvero: dimostrare quanto è conosciuto questo fenomeno nelle diverse unità di Terapia Intensiva italiane, osservare a quali problemi va incontro il personale infermieristico e verificare se le eventuali tecniche adottate per ridurre la frequenza dei falsi allarmi corrispondano a quelle derivate dalle evidenze scientifiche.
Materiali e metodi. Per la stesura dello studio è stata effettuata una revisione sistematica della letteratura di articoli correlati all'argomento scelto mediante la banca dati PubMed, usufruendo di parole chiave utili ad indirizzare le azioni di ricerca. Per un'adeguata indagine qualitativa è stato formulato un questionario mediante Google Moduli, il quale è stato condiviso successivamente nei vari social e soprattutto nelle diverse pagine riguardanti la professione infermieristica. Le persone che hanno voluto aderire allo studio hanno risposto alle domande in forma anonima.
Risultati. Attraverso l'indagine qualitativa sono state raccolte 93 risposte. Dall'analisi dei dati si rileva che più della metà (54,8%) del personale infermieristico che ha risposto non ha mai sentito parlare del fenomeno dell'alarm fatigue. Solo il 15,1% è sempre certo che gli allarmi sono effettivamente rilevanti. Il 52,7% e il 43% del campione dà maggior priorità agli avvertimenti provenienti rispettivamente dal monitor multiparametrico e dai ventilatori. Gli infermieri sono fortemente d'accordo (22,6%) e d'accordo (44,1%) sul fatto che i continui allarmi interferiscono con la qualità dell'assistenza generale erogata ai pazienti. Il 38,7%, in merito alla domanda riguardante la sensibilità agli allarmi ha risposto positivamente, affermando come quest'ultima sia diminuita col tempo. Seppur in percentuale minore (21,5%), è importante sottolineare che vi sono stati casi in cui la mancata risposta ai segnali acustici e visivi ha provocato delle ripercussioni, anche gravi, sullo stato di salute del paziente. Infine, il 77,4% ha risposto che adotta tutte le tecniche elencate nell'apposita domanda per ridurre i falsi allarmi.
Conclusioni. Ad oggi l'alarm fatigue è poco conosciuto e poco gestito nelle varie unità di Terapia Intensiva italiane. In conclusione, questo fenomeno dovrebbe essere trattato in maniera più ampia e dovrebbero essere adottate ulteriori strategie per migliorare la sicurezza degli allarmi, specialmente in Rianimazione in cui più dispositivi di monitoraggio sono in uso costante.

A197: IL RUOLO DEL PEER TUTORING NELLO SVILUPPO DELLE COMPETENZE RELATIVE ALL'INTERPRETAZIONE DI UN ECG A 12 DERIVAZIONI: UNO STUDIO QUASI SPERIMENTALE

Elena Giovanna Bignami (a), Rita Romano (b), Matteo Venturini (a), Rachele La Sala (b)
(a) UNIVERSITÀ DEGLI STUDI DI PARMA; (b) AZIENDA OSPEDALIERO-UNIVERSITARIA DI PARMA

Background e obiettivi. L'elettrocardiogramma a 12 derivazioni è uno strumento che ricopre un ruolo di primaria importanza nell'iter diagnostico di patologie cardiache di varia natura, anche in correlazione all'esponenziale aumento dell'incidenza di disturbi cardiovascolari e alla relativa semplicità e velocità di esecuzione; ciò implica che anche il professionista infermiere, che spesso si approccia per primo alla relativa registrazione e a cui è riposta la responsabilità del relativo monitoraggio, dovrebbe possedere una base teorica e una capacità di analisi critica tale da poter riconoscere rapidamente una condizione ad alto rischio per il paziente, contestualizzandola ai segni e sintomi riferiti. La letteratura internazionale sostiene che le capacità di interpretazione per il professionista infermiere risultano essere spesso deficitarie e che la fruizione di corsi specifici sul tema, in associazione ad un costante esercizio, vedono correlazione con migliori capacità di analisi critica. Si va quindi a indagare il livello di conoscenza e di competenza negli studenti di infermieristica frequentanti il corso di laurea triennale iscritti al secondo e terzo anno di studi prima e dopo la fruizione di due differenti strumenti formativi extracurricolari, rispettivamente un corso di elettrocardiografia tenuto da un docente esperto e un corso trattante gli stessi contenuti tenuto da un peer-tutor (ovvero, uno studente di 3° anno avente approfondito gli argomenti trattati) al fine di indagare sul livello di preparazione raggiunto attraverso la sola fruizione delle lezioni e del tirocinio curricolare, sull'efficacia dei due strumenti e sul gradimento nella fruizione degli stessi.
Materiali e metodi. Per raggiungere l'obiettivo su definito è stato condotto uno studio quasi sperimentale. Il campione di studio vede coinvolti 34 studenti iscritti al secondo anno di studi, frequentanti il corso tenuto dal peer-tutor, e 37 studenti iscritti al terzo anno di studi, frequentanti il corso tenuto dal docente esperto. Viene somministrato un questionario validato in italiano in forma anonima, dopo autorizzazione da parte del presidente del CDS in Infermieristica, tramite l'utilizzo di una piattaforma Microsoft Forms, prima e dopo la fruizione dei due corsi. Il questionario si compone di una prima parte di quesiti teorici e di una seconda parte trattante quesiti di interpretazione. I corsi frequentati presentano entrambi una durata di 12 ore e trattano le medesime tematiche, quali le basi della fisiopatologia cardiaca e dell'elettrocardiografia.
Risultati. I due gruppi di studio, seppur appartenenti a coorti diverse, non presentano differenze statisticamente significative al momento del pre-test. Si assiste ad un miglioramento di conoscenze statisticamente significativo per entrambi i gruppi e non si riscontrano differenze significative tra i due gruppi. È stato anche analizzato il gradimento relativo alla partecipazione del corso e il gradimento riguardante gli studenti frequentanti il corso con il peer tutor risulta essere superiore rispetto al gruppo di controllo.
Discussione. Il peer tutoring risulta essere una risorsa formativa che potrebbe vedere maggior impiego nelle realtà universitarie e professionali per via dell'efficacia dimostratasi al pari della formazione proposta del docente; la buona riuscita del corso tenuto dal peer tutor è influenzata da vari fattori (quali, ad esempio, la preparazione dello studente e la capacità espositiva) e, pertanto, si ritiene non possa sostituire la formazione fornita dal docente esperto. Tenendo in considerazione gli svariati benefici apportati dal peer tutoring (come maggior gradimento degli studenti a parità di efficacia del corso), questo potrebbe vedere un maggior impiego relativamente a corsi facoltativi utili all'arricchimento delle conoscenze ottenute tramite la preparazione curricolare.

A198: THE RELATIONSHIP BETWEEN ENGAGEMENT IN PATIENTS WITH HYPERTENTION AND MANAGEMENT OF BLOOD PRESSURE USING SELF-MONITORING PROGRAMMES AND DEVICES. A LITERATURE REVIEW

Rosa Debora (a), Matteo Peverelli (a), Giulia Villa (a), Dulio Fiorenzo Manara (a)
(a) CENTRE FOR NURSING AND INNOVATION, VITA SALUTE SAN RAFFAELE UNIVERSITY, MILAN, ITALY

Background. The increase in life expectancy, together with the reduction in the birth rate, has, in recent decades, resulted in a prevalence of elderly people in the country as in most Western countries with the consequent increase in chronic conditions that have highlighted the need for a substantial revision of the models of care underlying the delivery of clinical and care services. The model of Participatory Medici-

ne and the concept of patient engagement, today, represents the gold standard of response to this new outlined framework. The management of chronic diseases is increasingly relevant as they are directly responsible for 70% of deaths globally, or about 41 million people each year. The chronic disease responsible for most of these deaths is represented by the group of cardiovascular diseases, and among them arterial hypertension emerges.
Methods. The objective of this scoping review was to investigate through Pubmed®, CINAHL®, Scopus® and PsycInfo® databases the present evidence about the relationship between the concept of engagement and the hypertension patient who is a user of self-management programs and a user of devices for self-detection of blood pressure levels at home. The literature review project was conducted between September 2022 and June 2023.
Results. Studies identified from the literature comparison were 569, of which 133 were included after screening by title and abstract; reading the full text verified the eligibility of 15 studies, including 9 primary literature and 6 secondary literature. Analysis of the included studies shows that self-monitoring using digital technologies in a home-based setting (HBPM) is closely related to the level of engagement, blood pressure reduction and control, health behaviors, and improved knowledge of the hypertension condition.
Conclusions. In the era of the mobile revolution, the widespread use of digital technologies, together with the development of smartphone applications, has opened up new perspectives for HBPM based on mobile health (mHealth) technologies. The advantages of mHealth technologies include their affordability and wide accessibility; in fact, they have the potential to provide an efficient, reliable and inexpensive mechanism for health promotion and disease management. Data from the clinical trials included in the review suggest the value of these technologies in improving patient engagement and, consequently, adherence to antihypertensive treatment and the achievement of higher rates of blood pressure control that could ultimately lead to reduced cardiovascular risk.

A199: WHAT ARE THE EXPERIENCES OF OBSTRUCTIVE SLEEP APNOEA PATIENTS AND THEIR PARTNERS? DESCRIPTIVE PHENOMENOLOGICAL STUDY

Debora Rosa (a), Giulia Villa (a), Franca Amato (d), Elisa Cartabia (b), Valeria Storti (b), Carolina Lombardi (c, d), Carla Amigoni (d), Gianfranco Parati (c, d), Duilio Fiorenzo Manara (a), Elisa Perger (d)
(a) CENTRE FOR NURSING AND INNOVATION, VITA-SALUTE SAN RAFFAELE, MILAN, ITALY; (b) OSPEDALE GALEAZZI-SANT'AMBROGIO IRCCS, MILAN, ITALY; (c) DEPARTMENT OF MEDICINE AND SURGERY, UNIVERSITY MILAN-BICOCCA, MILAN, ITALY; (d) ISTITUTO AUXOLOGICO ITALIANO IRCCS, MILAN, ITALY

Background. Obstructive Sleep Apnoea (OSA) is a common chronic sleep-related breathing disorder. It is prevalent in the general population at between 40 and 85 years of age in men compared to women. If untreated, OSA increase the risk of cardiovascular disease such as stroke, hypertension, atrial fibrillation, pulmonary hypertension, and myocardial infarction. There are several therapeutic treatment options for OSA include weight loss, oral appliance devices, surgical procedures and novel pharmacotherapies have been recently proposed, and use of continuous positive airway pressure (CPAP). Bedpartners of OSA patients also use sleep aids such as medication and earplugs. The consequences are relative sleepiness during the day, which contributes to frustration, exhaustion and interference at work. This strains the relationship to the point of sleeping in separate rooms and decreasing intimacy.
Aim. To explore the experience of people with OSA and their partners.
Methods. Study design: descriptive phenomenological study. The authors used descriptive phenomenological approach by van Manen and qualitative thematic analysis by Sundler et al. Patients with a diagnosis of OSA, knowledge and language proficiency and their bedpartners were included in the study. The presence of a clinically relevant cognitive dysfunction was a reason for exclusion for both. Data collection: data collection was carried out through semi-structured in-depth interviews, using video-conferencing software (Skype, Teams, Zoom) (Archibald et al., 2019) or face-to-face interviews.
Results. The following three themes were identified OSA worsens the quality of life, OSA is «our» problem, OSA worsens the couple's quality of life. The last theme was identified only by patients, and the two others by both partners and patients.
Conclusions. Our results seem to highlight that the couple is the fundamental nucleus that determines the diagnosis of the disease, and that can influence adherence to therapy.

A200: NURSING CARE IN HEART FAILURE: THE HELP OF TELEMEDICINE. NARRATIVE REVIEW

Debora Rosa (a), Greta Bianchi (a), Giulia Villa (a), Duilio Fiorenzo Manara (a)
(a) CENTRE FOR NURSING RESEARCH INNOVATION, VITA-SALUTE UNIVERSITY, MILAN, ITALY

Background. Patients with heart failure are one of the most common populations we encounter in cardiology and medicine departments today. Heart failure is a chronic cardiovascular disease that requires self-management based on rest, adequate diet, daily activities, and adherence to a targeted and personalised treatment plan involving considerable healthcare resources. Nurses must closely monitor the patient's progress, adherence to the treatment plan and early change of condition, supporting the patient and caregivers with concerns and the onset of complications. Frequent hospitalisations and prolonged hospital stay therefore entail an extremely high economic cost. To address this health emergency, telemonitoring has been introduced as a potential answer to address these needs. Telemetry technologies offer better and more comfortable care. These advances have created new opportunities to provide care. The nurse should adapt to this scenario to cope with this new way of providing care with the best strategies.
Aim. To analyse the efficacy of telemedicine on the quality of nursing care delivered to patients with heart failure and to identify the benefits of this intervention.
Methods. Narrative review. according to PRISMA Statement guidelines. Electronic databases: PubMed and Cumulative Index to Nursing and Allied Health Literature (CINAHL). Search terms: Heart Failure/diagnosis, Heart Failure/therapy, telemedicine, humans, chronic disease, telenursing, heart failure, Treatment Outcome and nursing assessment. Included were publications from the last 10 years (2013-2023), in English, Italian, population aged 19 years or older with chronic heart disease.
Results. Twenty-one relevant studies were found, all of which were quantitative except for two which were qualitative. The results of the studies provided information on reduction of emergency room admissions, effectiveness of telemonitoring, adherence to therapy, usability, self-care, and the nursing role.
Conclusions. The ability to monitor patients remotely allows earlier detection of changes in vital parameters. Action can be taken more quickly than with routine monitoring, thus drastically reducing re-hospitalisations and emergency room admissions. Moreover, the active involvement of the patient in monitoring and managing his or her health condition can increase awareness of the disease, promoting a healthy lifestyle and better adherence to prescribed therapy. The user-friendliness of such a system also allows it to be adopted by elderly patients. Through daily monitoring, it is possible to prevent the patient from worsening and the need for intravenous drugs.

A201: CARDIOVASCULAR RISK PERCEPTION IN PRIMARY PREVENTION: A CROSS SECTIONAL STUDY PROTOCOL

Debora Rosa (a), Roberta Di Matteo (c), Enrico Gianfranceschi (b), Alessia Martina Trenta (d), Mariangela Alberti (d), Elisabetta Bagnato (e), Concetta Leotta (c), Gianfranco Pistis (c), Mariasilvia Como (c), Francesca Tagliacarne (b), Elisa Nardin (b), Marialuisa De Biaggi (d), José Pablo Werba (d), Monica Giroli (d), Giulia Villa (a), Carla Amigoni (b), Claudio Bassi (d), Duilio Fiorenzo Manara (a), Antonio Maconi (c), Niccolò Simonelli (c)
(a) VITA-SALUTE SAN RAFFAELE UNIVERSITY, CENTRE FOR NURSING RESEARCH AND INNOVATION, MILAN, ITALY; (b) ISTITUTO AUXOLOGICO IRCCS, MILAN, ITALY; (c) AZIENDA OSPEDALIERA SS ANTONIO E BIAGIO E CESARE ARRIGO, ALESSANDRIA, ITALY; (d) CENTRO CARDIOLOGICO MONZINO IRCCS, MILAN, ITALY; (e) POLICLINICO SAN PIETRO, ISTITUTI OSPEDALIERI BERGAMASCHI, PONTE SAN PIETRO, BERGAMO, ITALY

Background. Cardiovascular (CV) disease is the principal cause of mortality in adults, and it has a large impact on global economic status. Subjective judgement of the likelihood of having a CV disease, namely "CV risk perception", is essential for adopting healthy lifestyles.
However, both overestimation and underestimation of the real CV risk are frequent in subjects without a history of CV events. For these reasons, CV primary prevention should be targeted on both to assess the presence of CV risk factors, and to investigate the CV risk perception of individuals.
Aims. Primary aim: to describe the association between subjects' CV risk perception and health provider estimated CV risk. Secondary aims: (a) to estimate the actual CV risk according with the SCORE2; b) to assess the prevalence of risk factors.
Methods. Study design: multicentre observational study. Inclusion criteria: age between 18 and 69 years; signed informed consent. Exclusion criteria: participants with a history CV disease or who have a relevant cognitive debilitation (Six Item Screener score <4). Context and data collection: the enrolment of participants will take place in CV primary prevention events related to World Heart Day 2023 (29 September) led by six hospitals in north of Italy. Data collection from participants will include the following: a) socio-demographic, CV familiarity, current medication, smoking habits, psychological-social and general health status; b) CV risk perception (Perception of Risk of Heart Disease Scale and a Likert-5 scale question); c) plasma level of total cholesterol, HDL-C, triglycerides, LDL-C and glycaemia in capillary blood; d) arterial blood pressure, body mass index and abdominal circumference measured using standardized procedures. Moreover, the Systemic Coronary Risk Estimation version2 (SCORE2) of each participant will be calculated.
Results. Overall, the results of this study will help to know the CV risk perception of Italian population and to identify gaps with their actual CV risk. At a clinical level, the results could stimulate developing interventions to increase the awareness of CV risk in primary care.

A202: PSYCOMETRIC EVALUETION OF TWENTE ENGAGEMENT EHEALTH TECHONOLOGIES SCALE

Debora Rosa (a), Giulia Villa (a), Enrico Gianfranceschi (b), Martino Pengo (b, c), Alessandro Croce (b), Grzegorz Bilo (b, c), Carla Amigoni (b), Duilio Fiorenzo Manara (a), Gianfranco Parati (b, c)
(a) CENTRE FOR NURSING RESEARCH INNOVATION, VITA -SALUTE SAN RAFFAELE UNIVERSITY, MILAN, ITALY; (b) ISTITUTO AUXOLOGICO IRCCS, MILAN, ITALY; (c) DEPARTMENT OF MEDICINE AND SURGERY, UNIVERSITY MILAN-BICOCCA, MILAN, ITALY

Background. Hypertension is a public health issue because it is a major contributor to fatal/non-fatal cardiovascular disease. Recently, both wearable watch-type devices for blood pressure measurement and mobile applications are available to promote engagement. The latter seems to be predictive of electronic health (eHealth) and mobile health (mHealth) interventions. The TWente Engagement with Ehealth Technologies Scale (TWEETS) is based on a systematic review and interviews with users who have used health apps. This instrument is based on the definition of engagement as the combination of behaviour, cognition and affect.
Aim. To validate in the Italian context the TWEETS.
Methods. The validation study was carried out according to the stages indicated by the Brislin model: cultural and linguistic validation, content and face validity, and construct validity.
Results. The first phase consisted of forward, back-translation, evaluation by a panel of five experts to define a final version of the tool. Content and face validity were tested by six experts, on whose evaluations the Content Validity Index (CVI) was calculated. Construct validity was obtained by means of Exploratory Factor Analysis among the 126 hypertensive patients who participated. 54 were women; 56 were retired and 49 employed; the majority (N=67) had a high school diploma.
Conclusions. TWETTS could be considered a quick and reliable tool to identify and foster the engagement of hypertensive patients using devices, if the psychometric properties of the instrument prove to be good.

A203: SISTEMA DI MAPPAGGIO 3D NON INVASIVO

Stefano Santucci (a), Matteo Santucci (b)
(a) AZ. OSPEDALIERO UNIVERSITARIA SANT'ANDREA ROMA; (b) CDC SANTO VOLTO ROMA

Le alterazioni di conduzione elettrica del muscolo cardiaco sono oggetto di studio da alcuni decenni. Per la valutazione ed il trattamento delle aritmie cardiache è necessario effettuare uno studio elettrofisiologico. Lo studio elettrofisiologico è una procedura invasiva che si effettua con l'introduzione di elettrocateteri all'interno delle cavità cardiache. È una procedura che può durare alcune ore e prevede ospedalizzazione; si esegue introducendo gli elettrocateteri per via femorale e può presentare alcune complicanze procedurali. Contestualmente allo studio si può erogare la terapia effettuando una ablazione. In alcune tipologie di pazienti l'individuazione e il trattamento delle aritmie può essere reso controindicato dallo stato di salute del paziente stesso. Il paziente cardiopatico fragile con funzionalità cardiaca compromessa che non può essere sottoposto a studio elettrofisiologico invasivo può trovare giovamento dal nuovo sistema di mappaggio CardioInsight. È un sistema non invasivo che consiste in un gilet prodotto su misura, con 250 elettrodi in grado di rilevare le tracce ECG e, in base ai segnali acquisiti, è in grado di elaborare e mostrare la mappa dei potenziali, la mappa di attivazione, la direzione della mappa di attivazione, il voltaggio delle tracce e lo slow rate. Integrando l'imaging di una TC del cuore acquisita con mezzo di contrasto, il sistema è in grado di ricostruire e mostrare tridimensionalmente il cuore. Sul modello 3D ottenuto con la Tomografia computerizzata il software sovrappone la mappa delle tracce consentendo di ricostruire sul modello la mappatura elettrica della conduzione consentendo così di individuare eventuali anomalie di conduzione. L'utilizzo di tale sistema consente di effettuare lo studio elettrofisiologico in modo del tutto non invasivo consentendo così la prosecuzione e l'ottimizzazione della terapia in pazienti fragili che altrimenti non potrebbero essere sottoposti a studio elettrofisiologico invasivo.
Attualmente questo sistema di mappaggio trova una sua peculiarità in pazienti per i quali è indicata la radioablazione intesa come utilizzo delle radiazioni ionizzanti. Infatti il trattamento ablativo può essere eseguito mediante l'erogazione di elevate dosi di radiazioni utilizzando apparecchiature normalmente destinate al trattamento delle patologie oncologiche.

A204: ROLE OF THE NURSE COUNSELLOR IN PAEDIATRIC CARDIOLOGY

Daniele Selvaggio (a), Marco Roberti (a), Valentina Biagioli (b), Immacolata Dall'Oglio (b), Orsola Gawronski (b), Emanuela Tiozzo (b)
(a) CLINIC AREA OF FOETAL NEONATAL AND CARDIOLOGIC SCIENCE, BAMBINO GESÙ CHILDREN'S HOSPITAL, IRCCS, ROME, ITALY; (b) PROFESSIONAL DEVELOPMENT, CONTINUING EDUCATION AND RESEARCH SERVICE, BAMBINO GESÙ CHILDREN'S HOSPITAL, IRCCS, ROME, ITALY

Evolution of the nursing profession involves the development of advanced clinical skills in line with today's cultural context, continuous updating based on scientific evidence, and the acquisition of relational skills based on emotional intelligence. In paediatric cardiology, it is fundamental to "know how to communicate" with patients and their families, in order to guarantee holistic care aimed at promoting well-being. As such, the Nurse Counsellor provides added value in paediatric cardiology care environments, where the helping relationship, along with advanced competencies, is crucial to provide emotional support for patients with complex chronic conditions in the various phases of the care continuum. In the Bambino Gesù Children's Hospital, IRCCS, the role of the nurse counsellor in paediatric cardiology has been active since 2006. The nursing counselling interventions are oriented towards identifying, exploring, and managing the problem. This is possible through the construction of the Counselor-Family therapeutic alliance, based on the following phases: sharing the goals, defining mutual tasks, and establishing a trusting relationship between the actors in the relationship. In the context of paediatric cardiology, the Nurse Counsellor fits perfectly into the holistic care for patients and their families, facilitating continuity of care. The Nurse Counsellor follows the patient's therapeutic path, identifies the main stressors for the family, and provides emotional support to each member by leveraging the competencies related to the helping relationship. The journey of patients in paediatric cardiology is often long, difficult, and demanding in terms of emotions and internal resources. Nurse-led targeted counselling interventions, along with increased attention to communication and listening dynamics (posture, tone, non-verbal communication) from all nursing staff, can promote well-being and reduce adverse events (aggression, feelings of abandonment). The role of the nurse counsellor should be enhanced in paediatric cardiology care contexts to foster a climate of acceptance, non-judgment, and respect, where active listening is practiced and the potential and strength of everyone, both patient and healthcare professional, is recognized. Moreover, implementing counselling in the context of paediatric cardiology can facilitate the establishment of positive interpersonal relationships and the development of coping skills useful to manage stress and promote well-being, along with facilitating power-sharing and self-actualization processes.

A205: UNA FIGURA SEMPRE PIÙ DETERMINANTE IIN EMODINAMICA: IL TFCPC NELLA VALUTAZIONE DELLA MALATTIA CORONARICA

Tommasa Siragusa (a)
(a) OSPEDALE SANT'EUGENIO

All'interno delle sale di emodinamica trova sempre maggiore spazio una delle figure sanitarie tecniche più complete in questo contesto, ovvero quella del TFCPC. Il Tecnico della fisiopatologia cardiocircolatoria e perfusione cardiovascolare si può occupare, sia come primo attore che come parte integrante dell'equipe, della parte diagnostica e di quella curativa del paziente, lavorando a stretto contatto con il cardiologo, il cardiochirurgo, l'anestesista, l'emodinamista e l'elettrofisiologo.
Nel nostro centro il TFCPC si occupa a 360 gradi del paziente cardiologico ambulatoriale, sottoposto a procedure di elettrofisiologia ed elettrostimolazione e nella fattispecie dei pazienti sottoposti a procedure di urgenza, emergenza ed elezione nella sala di emodinamica. È fondamentale il suo ruolo per la gestione di tutti i parametri vitali, dall'elettrocardiogramma all'ossimetria, dall'emogas analisi alla gestione totale delle apparecchiature per lo studio intracoronarico avanzato quali IVUS, OCT, iFR e FFR. Quest'ultime metodiche sono il gold standard per una valutazione completa e accurata di una malattia coronarica non perfettamente individuabile con le sole immagini angiografiche, data la persistenza di limiti di accuratezza legati alla metodica stessa, e definiscono in maniera chiara se una placca aterosclerotica è funzionalmente critica piuttosto che strutturalmente instabile. Il TFCP si occupa quindi dell'allestimento tecnico, coadiuva gli operatori nell'esecuzione di tecniche invasive di imaging (IVUS e OCT) e di funzionalità coronarica (iFR e FFR) e gestisce le apparecchiature che permettono l'elaborazione finale dei risultati per ogni metodica di valutazione; infine ne interpreta i risultati dando, insieme all'emodinamista, la corretta diagnosi.

A206: CASO CLINICO: PROCEDURA DI ESTRAZIONE CON TECNICA LASER IN PAZIENTE AFFETTA DA INFEZIONE DELL'INTERO SISTEMA CIED E SUCCESSIVO REIMPIANTO DI CRT-D CON CONTESTUALE ANGIOPLASTICA DI UN RAMO POSTERO-LATERALE DEL SENO CORONARICO

Michele Solimene (a)
(a) AOU FEDERICO II

Introduzione. Le infezioni cardiache rappresentano una delle complicanze più gravi associate all'impianto di dispostivi cardiaci impiantabili (CIED), comportando un elevato tasso di morbilità e mortalità nei soggetti colpiti (circa 20-25% a 1 anno e fino al 50% a 3 anni), oltre che un forte incremento della spesa sanitaria. La severità della prognosi aumenta progressivamente al crescere del tempo che intercorre tra l'impianto e la comparsa dell'infezione, che può verificarsi attraverso due meccanismi: la contaminazione della tasca o dei componenti del dispositivo al momento dell'impianto o di reinterventi successivi; un'infezione ematogena in cui la contaminazione degli elettrocateteri può verificarsi durante la batteriemia causata da un focolaio infettivo situato a distanza o dall'ingresso di batteri attraverso cute, mucose della bocca, del tratto gastrointestinale o genito-urinario. L'incidenza del rischio infettivo varia notevolmente se rapportata ai diversi dati presenti in letteratura; nono-

stante ciò, il tasso di incidenza sembra aver subito un forte incremento, legato ovviamente al crescente numero di impianti eseguiti, soprattutto ICD e CRT.
Caso clinico. Il caso clinico in oggetto riguarda una donna di 69 anni, affetta da ipertensione arteriosa e dislipidemia, coronaropatia cronica, già trattata negli anni con PTCA e diversi impianti di stent, arteriopatia periferica multidistrettuale e BPCO. La paziente risulta inoltre affetta da FA cronica, scompenso cardiaco con FE severamente ridotta e stenosi aortica severa, per cui eseguiva in novembre 2022 impianto di CRT-D con conseguente ablazione del nodo AV e successivamente, nel mese di dicembre dello stesso anno, impianto di TAVI. In giugno 2023, la paziente eseguiva PET che evidenziava iperaccumulo a livello della tasca, come da infezione del dispositivo impiantato. Ricoverata presso la nostra struttura, veniva eseguita estrazione dell'intero sistema tramite tecnica laser e successivo reimpianto da destra del CRT-D, in quanto completamente pacemaker dipendente. L'impianto è stato possibile soltanto a seguito di angioplastica di un ramo postero-laterale del seno coronarico, che presentava una stenosi al tratto prossimale impedendo il posizionamento dell'elettrocatetere sinistro.
Conclusioni. La diagnosi di infezione viene stabilita attraverso la combinazione di condizioni cliniche, esami strumentali (TTE+TEE, PET/TC, SPECT/TC) e test di laboratorio. Gli esami colturali, in fase di estrazione, con campione dell'intero catetere o della sola punta da inviare al laboratorio, rappresentano un elemento cruciale nella determinazione dell'agente patogeno di natura infettiva e nella gestione della terapia antibiotica. La decisione di intraprendere una procedura di estrazione deve comunque sempre tenere in considerazione aspetti sia clinici che tecnici, quali caratteristiche del dispositivo (tipologia, numero di elettrocateteri, durata dell'impianto), caratteristiche del paziente, esperienza dell'operatore e del team operatorio, preferenza del paziente e bilancio rischio-beneficio. Nonostante l'utilizzo di misure preventive di diverso tipo e di dubbia efficacia (utilizzo di antisettici cutanei, soluzioni antibiotiche tascabili, somministrazione di antibiotici prolungati post-impianto), l'estrazione dell'intero sistema resta ad oggi l'unico elemento provato per una terapia di successo nel trattamento delle infezioni da CIED.

A207: "TELEHEART" CARE PATHWAY FOR HEART FAILURE AND RARE CARDIAC-RELATED DISEASES: A QUASI-EXPERIMENTAL PILOT STUDY

Roberta Sturaro (a), Clara Occhiena (d), Isabella Santomauro (b), Consolata Bracco (c), Stefano Chirivì (f), Alessandro Girardi (h), Enrica Lonni (f), Patrizia Milazzotto (i), Diego Targhetta Dur (g), Alessandra Truffa (f), Walter Grosso Marra (e)
(a) POLO FORMATIVO UNIVERSITARIO OFFICINA H - ASL TO4; (b) AREA CRITICA ASL TO4; (c) DIPARTIMENTO DI SCIENZE DELLA SANITÀ PUBBLICA E PEDIATRICHE; (d) RESPONSABILE DIPSA ASL TO4; (e) DIRETTORE S.C. CARDIOLOGIA IVREA - ASL TO4; (f) S.C. CARDIOLOGIA IVREA - ASLTO4; (g) DIRETTORE POLO FORMATIVO UNIVERSITARIO OFFICINA H - ASL TO4; (h) DIRETTORE SANITARIO ASL TO4; (i) CENTRO SERVIZI DISTRETTUALE INTEGRATO - ASL TO4

Introduction. The recourse to hospital healthcare in patients with chronic pathologies is high and entails a significant burden for the National Health System. During the Covid-19 pandemic, the need to review the care model was noticed: moving from a "face-to-face" model to a model that could consider the use of technology as a tool for promoting remote self-care. It is therefore about moving performance instead of moving people. The cardiological field was the most explored setting for the creation of innovative care models characterized by teleassistance systems. Early recognition of any complications and/or signs of clinical instability of the person, promoting assistance support even remotely, counselling, and self-care education becomes crucial in taking care of a person with heart failure in the community. Given the prevalence of people affected by heart diseases, it becomes necessary to create a synergy between hospital and community to manage people suffering from heart failure and/or rare cardiac-related diseases to reduce frequent hospitalizations and/or exacerbations of the pathology. In the light of these considerations, a quasi-experimental pilot study will be conducted within the community of Ivrea (TO) pertaining to the Local Health Authority Torino 4 (ASL TO4).
Aim. The objective of this pilot study is to promote care continuity between the hospital and the community through the work of the family and community nurse and the use of telemedicine, to improve the life quality of patients and the quality of care provided.
Methods. The research protocol was drawn up and approved by the Ethics Committee.
A design of a quasi-experimental, non-randomised, monocentric, prospective pre-/post-test pilot study will be conducted in the community pertaining to the Local Health Authority Torino 4 (ASL TO4). The identified population will be made up of patients discharged from the Cardiology Department of Ivrea (TO) with an acute event due to heart failure or rare cardiac-related disease. For the recruitment of the sample, a probability sampling of convenience will be implemented, and the sample size is 15 people. The people involved will be provided with nursing and medical care using telemedicine. The following interventions will be carried out: televisit, teleassistance, telemonitoring and telecontrol, teleconsultation.
Results. The expected results of the study will be as follows: increased adherence and therapeutic compliance, reduced outpatients' access, reduced hospital admissions for heart failure, and reduced inappropriate access to Emergency-Urgency services.
Conclusions. This study will be conducted with consistency and adherence to the three fundamental concepts on which it is based: the importance of hospital-community integration from acuteness in intensive care to returning home, the importance of the caregiver in taking care of a relative suffering from heart failure and/or rare cardiac-related diseases, and the qualities of Tele Nursing and Telemedicine as a support tool and not as a substitute for the help relationship.

A208: CARE PATHWAY FOR HEART FAILURE AND RARE CARDIAC RELATED DISEASES: NEW OPERATING MODEL OF HOSPITAL-COMMUNITY INTEGRATION WITH TELEMEDICINE TOOLS

Roberta Sturaro (a), Clara Occhiena (d), Isabella Santomauro (b), Consolata Bracco (c), Stefano Chirivì (j), Salvatore Di Gioia (i), Enrica Lonni (j), Patrizia Milazzotto (h), Diego Targhetta Dur (f), Alessandra Truffa (j), Walter Grosso Marra (e)
(a) POLO FORMATIVO UNIVERSITARIO OFFICINA H - ASL TO4; (b) AREA CRITICA ASL TO4; (c) DIPARTIMENTO DI SCIENZE DELLA SANITÀ PUBBLICA E PEDIATRICHE; (d) RESPONSABILE DIPSA - ASL TO4; (e) DIRETTORE S.C. CARDIOLOGIA IVREA - ASL TO4; (f) DIRETTORE POLO FORMATIVO UNIVERSITARIO OFFICINA H - ASL TO4; (g) DIRETTORE SANITARIO ASL TO4; (h) CENTRO SERVIZI DISTRETTUALE INTEGRATO ASL TO4; (i) RESPONSABILE SS QUALITÀ - ASL TO4; (j) S.C. CARDIOLOGIA IVREA - ASL TO4

Introduction. The National Outcomes Plan emphasizes how "proper local management of patients with heart failure, also through the definition of appropriate protocols for outpatient management, facilitates the reduction of the progression of the pathology and the prevention of hospitalization". The approach to rare diseases requires the inclusion and sharing of diagnostic therapeutic pathways with all the professionals involved. Such pathways often begin in the hospital or in the acute phase during hospitalization, or in specialist outpatient clinics, but we often forget that the moment of taking charge of chronicity represents a very delicate step, possibly more important than the acute phase itself. An integrated management between community medicine and hospital can offer a better diagnostic-therapeutic path in patients with rare cardiovascular diseases, reducing the recurrence of acute events and therefore the need for hospitalization. Hence there is the need to create new collaborative networks between the different figures involved in the treatment of these patients: the hospital specialist, the cardiological critical area nurse or ward nurse, the outpatients nurse, the family and community nurse, with the aim of bringing the hospital to the patient's home or to the relative health home. In this context, we must take advantage of the opportunities that modern technologies offer us in the field of telemedicine. The aim will be to create a synergy between hospital nurses and community nurses in order to ensure care continuity to the patient, avoiding missed treatments or inappropriate access to hospital.
Objective. The project aims, through a continuous medical training course (ECM), to offer effective nursing skills to take care of people with heart failure and rare cardiac-related diseases both at a hospital and community level and then to experiment with the new operating model in the area of Ivrea (TO).
Methods. The training project will take place from April 2023 to June 2023 with 88 hours in total in which the learners will also be teachers. The lessons will be held with a frontal and laboratory teaching method. Students will be introduced to the pathophysiology, aetiology, and intervention strategies of the management of heart failure and rare cardiac-related diseases, through frontal lessons. Later, during the laboratory activity, students will be presented with clinical cases in which they will be able to experiment, through simulations, with what they have learned during the frontal lessons. The knowledge and skills gained during the laboratory will be evaluated at the end of the lab activity through a final test.
Results. To train healthcare professionals about the topic dealt with and to improve the quality of the current hospital-community management of fragile patients and patients with a possible evolution of hemodynamic instability. Specifically, the objectives for the patients will be:
Improve compliance with polytherapy;
Ensure therapeutic adherence;
Constant monitoring of the health status and treatment needs;
Proceed with pharmacological titration at home;
Maintain or improve autonomy in ADL and IADL.
Conclusions. The development of this training project aims to deal with a relevant issue within Ivrea area, both in a community and hospital context. The objective will be to improve the quality of care for the management of frail patients with heart failure and/or rare cardiac-related diseases. The training project will allow to acquire skills and knowledge for the hospital-community management of the patient in cardiology, critical area, and telemedicine fields.

A209: LA QUALITÀ DI VITA NELLE PERSONE CON LEFT VENTRICULAR ASSIST DEVICE: UNA SCOPING REVIEW

Maria Stella Tombolini (b), Michela Luciani (b),
Davide Luigi Lino Ausili (b), Alessia Martina Trenta (a)
(a) CENTRO CARDIOLOGICO MONZINO; (b) UNIVERSITÀ DEGLI STUDI DI MILANO BICOCCA - FACOLTÀ DI MEDICINA E CHIRURGIA

Background. Lo scompenso cardiaco (SC) è una sindrome clinica complessa con sintomi e segni che derivano da una compromissione a livello cardiaco. L'incidenza di SC in Europa è in aumento e pari a 5 casi su 1000 all'anno nella popolazione adulta. L'evoluzione dello SC porta ad una fase avanzata, trattabile con terapia medica. Se non responsiva, viene affrontata con un trattamento chirurgico. Il trapianto di cuore è il gold standard per il trattamento dello SC avanzato, tuttavia, non sempre è un'opzione possibile, principalmente a causa della scarsità di organi rispetto alla richiesta. Si può dunque ricorrere all'impianto di un Left Ventricular Assist Device (LVAD), cioè una pompa meccanica che viene impiantata chirurgicamente per supportare la funzione cardiaca e il flusso sanguigno. Il numero di individui che vivono con un LVAD è in aumento; pertanto, diventa rilevante esaminare gli esiti psicologici, fisiologici e clinici, come la qualità della vita (QoL). I problemi rilevati nella QoL dei pazienti possono portare a modifiche e miglioramenti nel trattamento e nella cura della persona. Data la lacuna rilevata in letteratura nella definizione della QoL della persona con LVAD, la presente scoping review si pone come obiettivo quello di descrivere la QoL nella persona con LVAD come Destination Therapy (DT-LVAD), e di individuarne i suoi determinanti e facilitatori.
Materiali e metodi. La metodologia utilizzata per condurre la presente scoping review fa riferimento al metodo del Johanna Briggs Institute (JBI). Dalla ricerca su cinque banche dati biomediche sono stati rilevati 727 articoli: a seguito di uno screening per titolo e di uno screening per abstract, di uno screening per full-text, e poi di uno screening delle bibliografie degli articoli di interesse, sono stati inclusi 82 articoli che sono stati analizzati tramite l'ausilio di una tabella di estrazione dati. I risultati ottenuti sono stati descritti tramite la formulazione di cinque aree di interesse che evidenziassero i punti chiave della QoL della persona con LVAD.
Risultati. La prima area è rappresentata dagli aspetti fisici (n=38 articoli): le complicanze e le riammissioni ospedaliere peggiorano la QoL, mentre la regressione della sintomatologia da SC ne determina un miglioramento. La seconda area è rappresentata dagli aspetti emotivi e psicologici (n=30 articoli): le emozioni sono legate alla persona, e hanno una relazione con le aspettative preimpianto; l'ansia, la depressione, lo stress e la fatigue sono frequenti e influenzano negativamente la QoL; pertanto, il team LVAD dovrebbe supportare la persona nel processo di accettazione e adattamento alla vita con il dispositivo. Riguardo gli aspetti cognitivi (n=6 articoli) vediamo un miglioramento nella funzione cognitiva dato il ripristino della perfusione cerebrale, ma questa tematica è poco approfondita in letteratura. La quarta area è rappresentata dagli aspetti sociali (n=19 articoli): la persona con LVAD ha bisogno di un caregiver; tuttavia, è necessario promuovere l'autonomia della persona; vediamo un miglioramento della QoL grazie alla ripresa di un idoneo impiego lavorativo, alla ripresa della socialità e dell'intimità con il proprio partner. Infine, gli aspetti spirituali (n=9 articoli) sono strettamente legati ai vissuti e alle credenze della persona e risultano poco indagati in letteratura.
Conclusioni. La persona con LVAD ha una QoL molto variabile, che dipende strettamente dai campi individuati nella presente scoping review come determinanti. Futuri studi potranno approfondire le aree poco esplorate, cioè gli aspetti cognitivi e gli aspetti spirituali, così come futuri studi potranno sviluppare ed integrare scale di valutazione specifiche che valutino la QoL nella persona con LVAD.

A210: CARDIO ONCOLOGICAL

Cinzia Vece (a)
(a) ASST SANTI PAOLO CARLO

A man with a prominent cancer history came to our attention with typical chest pain.
Cardio-oncological history. Past medical history comprised a hemicolectomy for the presence of large bowel adenocarcinoma pT3 N0 G2 R0 (AJCC, Ed. VIII; 2017) with no sign of metastatic disease at the CT performed before surgery. After eradication the patient underwent adjuvant treatment with Capecitabine (8 cycle) with no complication. Before the beginning of adjuvant treatment, the patient underwent an echocardiogram which showed preserved ejection fraction (EF>65%) with no a wall motion abnormality (WMA) and no relevant valvopathies. Total body CT scan after completion of chemotherapy treatment showed no sign of disease recurrence and patients started regular oncological follow up.
Cardiological history. Soon after the end of adjuvant therapy the patient complained shortness of breath during exercise, basal ECG showed no clear sings of ischemic suffering. The patient underwent an ergometric test, with the appearance of a clear ischemia associated with chest pain at the peak of the stress. Coronary angiography showed a Tri vessel disease with near occlusion of the proximal tract of descending artery, high and intermediate stenosis of the left artery at the proximal and intermediate tract and sub occlusion of the distal tract of the right coronary artery. The patient was therefore presented to the cardio surgery team and underwent bypass graft which improved his condition and currently he is asymptomatic under regular cardiological follow up.
Key point of the clinical case. The patient had a first chest-abdomen CT scan before hemicolectomy and adjuvant therapy with capecitabine (known to increase the risk of suffering from ischemic disease) where coronary and aortic calcifications were clear. Despite the presence of atypical anginal symptoms, the radiological data was neglected. The reassurance of the exercise test further masked the suggestive symptom of CAD. At the second chest CT scan which confirmed the regression of the oncological disease, the significant progression of the aorto-coronary calcific burden was neglected. Only a fortuitously positive exercise test directed clinicians on the right diagnostic path. Coronary/vascular calcium was overlooked and would have allowed for better preventative medical therapy and tragic coronary plaque in stabilization during surgery/chemotherapy. Oncological patients notably follow intense radiological programs. CT scans used for the staging and the follow up of cancer patients can offer with a closer look interesting data about basal coronary artery disease and its possible progression especially during cardiotoxic therapy.
Conclusions. CT scan performed during routine oncological treatments and follow up might offer data not only about the patient's cancer. Our clinical case shows an instance of neglected information which could have been harvested to assess the patients' cardiovascular risk before the appearance of the symptoms. This biomarker might help clinician to assess which patients need a more intense cardiological follow up and preventive therapy. Alongside, calcium score might be used as a frailty index and a more objective mean for assessment coronary artery health.

A211: NURSING-SENSITIVE OUTCOMES AFTER TRANSCATHETER-AORTIC VALVE REPLACEMENT: INCIDENCE AND IMPACT ON RECOVERY

Michele Villa (a), Martino Regazzi (a), Fabio Orsenigo (a),
Fabrizio Demurtas (a), Paolo Lepori (a), Andrea Sansalone (a),
Paola Rusca Grasselini (a), Sivia Giuffrida (a), Alessandro Dell'Avo (a),
Lucia Pedrazzini (a), Stefano Bernasconi (a), Tiziano Cassina (a)
(a) CARDIOCENTRO TICINO INSTITUTE, ENTE-OSPEDALIERO CANTONALE, LUGANO, SWITZERLAND

Introduction. There is an undoubted relationship between nursing care and patient outcomes. Nursing-sensitive outcomes (NSOs) are the measurable changes in the patient's condition attributed to the nursing care. Patients who undergo transcatheter aortic valve replacement (TAVR) are often frail, elderly, and need a high demanding nursing management, which make them very sensitive to the care. Nursing has a great responsibility on the post-operative course and outcomes of this vulnerable patient. The aim of this study is to describe the incidence of NSOs (delirium, pressure injury, pneumonia, fall, health care-associated infection) in patients after TAVR and to explore their impact at 3 months on functional recovery and 1 year survival.
Methods. Retrospective analysis of prospectively collected data, enrolling consecutive patients managed in a cardiac centre, between 1st January 2015 and 31st January 2019.
Results. We enrolled 274 patients, with a mean age of 82±6 years of which 65.8% had full autonomy in activities of daily living (ADL). In 78.1% of patients the procedure was performed with a trans-femoral approach and the median post TAVR hospital stay was 6 days (5-8). 63.9% of the patients did not present any NSO during the hospital stay. The most frequent NSOs were delirium 23.4%, pressure injury 6.6%, pneumonia 5.5%, falls 3.6%, and health care-associated infections 5.5% (catheter-associated urinary tract infection 5.1% and central venous catheter-related bloodstream infections 0.4%). The 3-month follow-up showed that patients who experienced an NSO had a 2.6-fold increased risk of worsening autonomy in ADLs three months after TAVR implantation compared to those without NSO (OR 2.6; 95% CI 1.2-5.5). This risk was also significant after adjustment for complications according to VARC classification (OR 2.4; 95% CI 1.1-5.2). One-year follow-up showed no significant impact of NSOs on survival, log rank test $\chi2(1)=3.21$, $p=0.07$.
Conclusions. Despite high care complexity procedure and frailty, in the post-TAVR course almost two-thirds of elderly patients received effective care without nursing-related complications. Delirium is the most frequent challenge in the post-procedural phase. The follow-up confirms that NSOs can significantly impact on post-procedure quality of life.

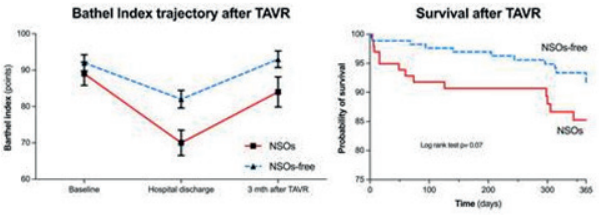

A212: ASSISTENZA AI PAZIENTI CARDIOVASCOLARI E IL BENESSERE ORGANIZZATIVO DEGLI INFERMIERI: UN MODELLO DI EQUAZIONI STRUTTURALI

Francesco Zaghini (a), Jacopo Fiorini (b), Philip Moons (c), Alessandro Sili (b)
(a) DIPARTIMENTO DI BIOMEDICINA E PREVENZIONE UNIVERSITÀ DI TOR VERGATA; (b) DIPARTIMENTO DELLE PROFESSIONI SANITARIE POLICLINICO DI TOR VERGATA; (c) DEPARTMENT OF PUBLIC HEALTH AND PRIMARY CARE KU LEUVEN

Background. I reparti Cardiovascolari sono particolarmente stressanti per gli infermieri, che spesso presentano importanti fattori di depressione, distress, esaurimento emotivo e fisico. La relazione tra lo stress lavoro correlato, la soddisfazione lavorativa e la qualità di vita degli infermieri è stata studiata in precedenti ricerche, ma non in specifici setting clinici quali quello cardiovascolare.
Obiettivi. L'obiettivo principale di questo studio è stato indagare simultaneamente la relazione tra lo stress lavoro correlato, la soddisfazione lavorativa e la qualità di vita degli infermieri cardiovascolari.
Materiali e metodi. È stato condotto uno studio multicentrico, cross-sectional su 1.126 infermieri cardiovascolari provenienti da 10 aziende sanitarie Italiane. Attraverso un questionario composto da scale validate e presenti in letteratura sono stati misurati lo stress lavoro correlato, la soddisfazione lavorativa e la qualità di vita degli infermieri cardiovascolari. Per verificare le ipotesi in studio, sui dati, è stato realizzato un modello di equazioni strutturali.
Risultati. Dai risultati del modello di equazioni strutturali, è stato possibile verificare che, negli infermieri cardiovascolari, lo stress lavoro correlato influenza negativamente la soddisfazione lavorativa (ß=-0.83; p<0.001) e la qualità di vita (ß=-0.31; p<0.001), mentre la soddisfazione lavorativa ha un effetto positivo sulla qualità di vita (ß=0.56; p<0.001). Inoltre, la soddisfazione lavorativa, media parzialmente la relazione tra lo stress lavoro correlato degli infermieri cardiovascolari e la loro qualità di vita (Effetto Totale ß=-0.78 p<0.001; Effetto Indiretto ß=-0.47 p<0.001; Effetto Diretto ß=-0.31 p=0.001). Infine, al test dell'ANOVA con post hoc di Tukey, è stato possibile verificare che gli infermieri che lavorano nelle unità di terapia intensiva cardiovascolare riferiscono più stress (M=2,68; DS=0,42) rispetto ai loro colleghi che lavorano in altri reparti (F=2,591; p=0,033), mentre gli infermieri che lavorano negli ambulatori di cardiologia riferiscono una minore qualità di vita (M=2,69; DS=0,51) rispetto ai loro colleghi degli altri setting clinici (F=5,440; p<0,001).
Conclusioni. I risultati di questo studio, costituiscono un reale valore aggiunto per la comunità scientifica, in quanto sono i primi nel loro genere nell'ambito cardiovascolare. In particolare, è emerso che la relazione negativa tra lo stress lavoro correlato degli infermieri cardiovascolari e la loro qualità di vita, può essere ridotta aumentando la loro soddisfazione lavorativa. Questo significa che implementando attività che aumentino la soddisfazione lavorativa degli infermieri cardiovascolari si potrebbe migliorare la loro qualità di vita. Un infermiere più soddisfatto e con una migliore qualità di vita, agisce migliori performance, pertanto, indirettamente, agendo sula soddisfazione lavorativa, si potrebbe migliore l'assistenza e la sicurezza per i malati. I manager delle aziende sanitarie dovrebbero tenere in seria considerazione i risultati di questo lavoro, in quanto sfruttando queste dinamiche, potrebbero aumentare le performance delle loro ad aziende e rispondere in modo più appropriato agli obiettivi di salute dei malati.

A213: IL BENESSERE ORGANIZZATIVO DEGLI INFERMIERI CARDIOVASCOLARI: UNA REVISIONE SISTEMATICA DELLA LETTERATURA

Jacopo Fiorini (a), Francesco Zaghini (b), Philip Moons (c), Alessandro Sili (a)
(a) DIPARTIMENTO DELLE PROFESSIONI SANITARIE - AZIENDA OSPEDALIERA POLICLINICO DI TOR VERGATA; (b) DIPARTIMENTO DI BIOMEDICINA E PREVENZIONE - UNIVERSITÀ DI TOR VERGATA; (c) DEPARTMENT OF PUBLIC HEALTH AND PRIMARY CARE KU LEUVEN

Obiettivi. Questa revisione sistematica della letteratura ha l'obiettivo principale di individuare e sintetizzare la letteratura esistente circa le variabili del contesto organizzativo che influenzano il benessere degli infermieri cardiovascolari.
Materiali e metodi. Per la revisione sono state seguite le line guida PRISMA e il metodo del Joanna Brings Institute. La ricerca è stata condotta nelle banche dati Medline (via PubMed), CINHAL, Cochrane Library e Scopus fino a tutto il primo dicembre 2022. L'estrazione dei dati e la valutazione critica della qualità è stata realizzata con strumenti standardizzati.
Risultati. Nella revisione sono stati inclusi sei articoli di alta qualità, che hanno evidenziando una scarsa attenzione al benessere organizzativo degli infermieri cardiovascolari. Si tratta principalmente di studi cross-sectional condotti in contesti eterogenei. Dall'analisi degli studi, sono state identificate tre aree tematiche: a) fattori di stress; b) conseguenze dello stress; c) strategie di coping utilizzate dagli infermieri cardiovascolari per affrontare i fattori di stress.

- Tra I fattori di stress individuati ci sono la mancanza di autonomia, conflitti con gli altri professionisti, lo squilibrio casa lavoro, alti carichi di lavoro e la relazione con i familiari e i caregiver dei pazienti.
- Le conseguenze di questi fattori di stress sono principalmente burnout, depressione, irritabilità e disturbi del sono.
- Le strategie di coping utilizzate sono principalmente affrontare direttamente il problema, l'evitamento (scappando o ignorando il problema) e l'aggressività.

Conclusioni. Considerando i dati limitati rintracciati con la revisione, il benessere organizzativo e gli aspetti emozionali e comportamentali degli infermieri cardiovascolari andrebbero ulteriormente studiati. La revisione della letteratura ha messo in evidenza che gli ambienti cardiovascolari sono molto stressanti per gli infermieri e per aumentare il loro benessere organizzativo e le loro performance, i manager delle strutture sanitarie debbono agire strategie di prevenzione per limitare il fenomeno. In particolare, monitorare e intervenire sui fattori di stress nei setting cardiovascolari, rimuovendoli dove possibile, potrebbe migliorare il benessere organizzativo degli infermieri e conseguentemente gli esiti sui malati.

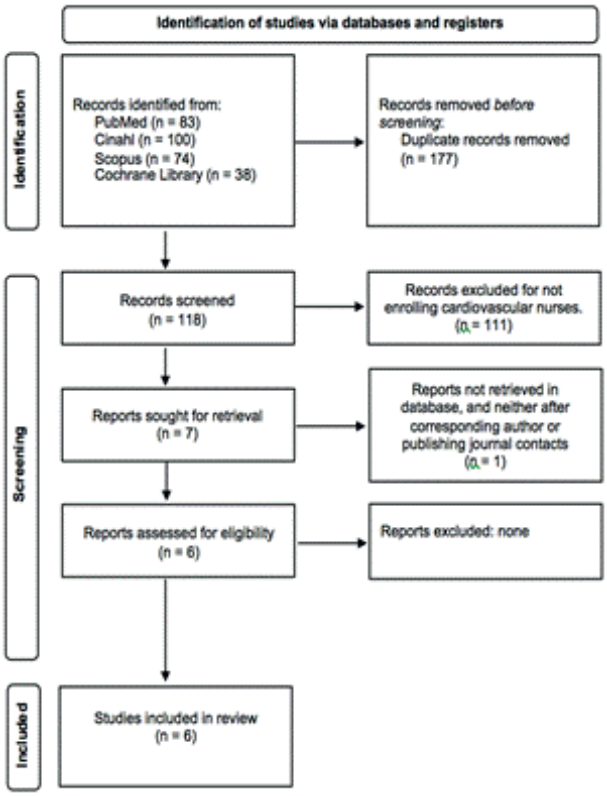

ATEROTROMBOSI

A214: ROLE OF LIPOPROTEIN(A) IN THE INCIDENCE OF CARDIOVASCULAR EVENTS IN PATIENTS WITH ACUTE CORONARY SYNDROMES (RELACS STUDY): CORRELATION BETWEEN LIPOPROTEIN(A) LEVELS AND AGE OF FIRST CORONARY EVENT

Vincenzo Acerbo (a), Arturo Cesaro (a), Gianmaria Scherillo (a), Gianantonio De Michele (a), Giuseppe Raucci (a), Andrea Vergara (a), Giovanni Signore (a), Francesco Scialla (a), Gennaro Porcelli (a), Francesco Paolo Rotolo (a), Marco Tontodonato (a), Domenico Panico (a), Fabio Fimiani (a), Elisabetta Moscarella (a), Felice Gragnano (a), Paolo Calabrò (a)
(a) CARDIOLOGIA - UNIVERSITÀ DELLA CAMPANIA "L. VANVITELLI" - AORN SANT'ANNA E SAN SEBASTIANO, CASERTA

Aim and Methods. The RELACS study is a single-center prospective observational study designed to evaluate the role of Lipoprotein (a) (Lp(a)) in patients with acute coronary syndrome (ACS) and to estimate the Lp(a) impact on coronary artery disease (CAD) complexity (assessed by SYNTAX score and Gensini score) and on the earliness of onset of ACS (assessed as Age of first event).
Results. This analysis concerns 773 consecutive patients with ACS admitted to our intensive cardiac care unit (ICCU) between 2020 and 2021. Before coronary artery angiography (CAG), a blood sample was assessed for lipid and Lp(a) levels. The main baseline characteristics of the population were as follows: 78% male; mean age 63,21 ± 12.63 years; 25.78% with Diabetes Mellitus; 23.92% with previous myocardial infarction (MI);

mean low-density lipoprotein cholesterol (LDL-C) 96.29 ± 44.24 mg/dl; 5.16% with chronic kidney disease (CKD). The variable Lp(a) was divided into tertiles, obtaining 10.4910 and 39.4000 as cut-off values. Three linear regressions were performed for the prediction of Gensini, Syntax score and Age of 1st event with Lp(a) variable in tertiles and with the control variables (age, sex, smoking habit, hypertension, diabetes mellitus, chronic kidney disease, previous percutaneous coronary intervention). The dependent variables considered during the multiple linear regression analysis were Gensini score, Syntax score and, finally, Age of 1st event. Looking at the coefficients of the model, there were no statistically significant variables (p>0.05) for both Gensini Score (p 0.901) and SYNTAX score (p 0.714). Conversely, Age of 1st event proved to be a statistically significant variable (p 0.026) with a B coefficient of -0.593, i.e. for each increase in degree (tertile) of Lp(a), age of first event decreases by 0.593.Other significant variables were also identified: as one year of age increases, the age of the first event increases by 0.940; a female, compared to a male, has the first event about 1.944 years earlier; diabetic patients, compared with non-diabetic patients, have the first event about 1.228 years earlier; patients with CKD, compared with those without CKD, have the first event about 2.093 years earlier; those who have previous PCI, compared with those who do not, have the first event about 6.060 years earlier. From the graph between Lp(a) in tertiles and mean age of first coronary event, it decreases statistically significantly as class increases.

Conclusions. The RELACS study demonstrate a statistically significant correlation between Lp(a) levels and mean age of first coronary event, highlighting the crucial role of Lp(a) as an independent predictor of precocity of ACS. On the contrary, no statistically significant correlation was found between Lp(a) levels and CAD severity.



A215: EFFICACY AND SAFETY OF DIRECT ORAL ANTICOAGULANTS IN OLDER ADULTS WITH ATRIAL FIBRILLATION: A PROSPECTIVE SINGLE-CENTRE COHORT STUDY

Filippo Catalani (a)
(a) PADOVA

Background and Aim. Direct oral anticoagulants (DOACs) are underused in the elderly, regardless the evidence in their favour in this population. The present study aims at evaluating the efficacy and safety profile of anticoagulant therapy with DOACs in two cohorts of old patients with atrial fibrillation (75-84 vs. ≥85 years), and the differences in efficacy and safety according to different dosage regimens (standard vs. reduced dose and on-label vs. off-label dose) in patients aged 85 years and older.

Methods. We prospectively enrolled anticoagulant-naïve patients aged ≥75 years who started treatment with DOACs with atrial fibrillation and stratified them in older adults (aged 75-84 years) and extremely older adults (≥85 years). Only patients who had never been treated with any oral anticoagulant drug whose CHA_2DS_2-VASc score was ≥2 for men and ≥3 for women were enrolled. Enrolled patients were followed up over a period of 12 months or until therapy was discontinued due to death, adverse events, or patient's choice.

Results. We enrolled 518 consecutive patients. They were mostly aged 75-84 years (299 patients; 57.7%) vs. ≥85 years (219 patients; 42.3%). Extremely older adults showed higher incidence of all the endpoints: systemic cardioembolism (HR=3.25 [95%CI: 1.71-6.18]), major bleeding (HR=2.75 [95%CI: 1.77-4.27]), and clinically relevant non-major bleeding (HR=2.13 [95%CI: 1.17-3.92]) vs. older adults, during the first year after starting anticoagulation. In patients aged ≥85 years, no difference in the endpoints was found between those receiving reduced on-label vs. off-label DOACs. In the extremely older adults, chronic kidney disease (CKD), polypharmacy, use of antipsychotics, and DOAC discontinuation correlated with higher rates of thrombotic events. After case-control matching, only CKD (HR=2.97 [95%CI: 1.12-7.9]) and DOAC discontinuation (HR=4.22 [95%CI: 1.48-8.7]) remained statistically significant. In terms of haemorrhagic complications, a history of bleeding, Charlson Index ≥6, use of reduced DOAC dose, absence of a caregiver, use of non-steroidal anti-inflammatory drugs (NSAIDs), and HAS-BLED score ≥3 were associated with major bleedings. After case-control matching, only previous bleeding (HR=1.77 [95%CI: 1.04-3.01]), use of NSAIDs (HR=2.02 [95%CI: 1.01-3.98]), and high HAS-BLED score (HR=2.0 [95%CI: 1.18-3.44]), remained statistically significant.

Conclusions. In conclusion, our study shows that anticoagulant-naïve patients aged 85 years and older who started a DOAC for AF are at higher risk of thrombotic and bleeding events compared to those aged 75-84 years during the first year of therapy. Main modifiable drivers for thrombotic events in extremely older patients are the presence of CKD and DOACs discontinuation. History of bleeding, use of NSAIDs, and HAS-BLED score ≥3 is associated with higher rates of major bleeding.

A216: DUAL PATHWAY INHIBITION ELIGIBILITY IN PATIENTS WITH ATHEROSCLEROSIS: DATA FROM TWO OBSERVATIONAL REGISTRIES

Claudio Laudani (a), Antonio Greco (a), Matteo Cavallo (a), Antonio Bulla (a), Giuseppe Sangiorgio (a), Alessia Giaquinta (a), Piera Capranzano (a), Valeria Calvi (a), Gaetano Isola (a), Eugenio Pedullà (a), Rocco De Pasquale (a), Maurizio Giacinto Uva (a), Antonio Di Cataldo (a), Pierfrancesco Veroux (a), Corrado Tamburino (a), Davide Capodanno (a)
(a) UNIVERSITÀ DEGLI STUDI DI CATANIA

Background. The VOYAGER PAD and COMPASS trials established the benefit of dual pathway inhibition (DPI) with aspirin and low dose rivaroxaban for eligible patients with peripheral artery disease (PAD) undergoing revascularization and for those with PAD or chronic coronary syndromes (CCS), respectively. However, in-hospital implementation of DPI remains slow in clinical practice, also due to eligibility uncertainties.

Aims. To assess the eligibility to DPI among contemporary patients hospitalized in cardiology and vascular surgery units, and to evaluate clinical outcomes of patients presenting with revascularized PAD according to their eligibility to the DPI strategy.

Methods. We analyzed data from patients with revascularized PAD included in the prospective institutional RAPID (RivAroxaban for PerIpheral artery Disease) and applied the VOYAGER PAD criteria to identify patients eligible to DPI and the frequency and distribution of exclusion criteria. To explore the residual potential for DPI applicability in clinical practice, COMPASS criteria were also applied to a contemporary CCS cohort from the institutional registry enrolling coronary artery disease patients undergoing invasive management, and the frequency and characteristics of DPI eligibility between PAD and CCS were compared.

Results. From May 2021 to May 2023, 196 patients (mean age 70.8±10.1 years, 75.5% male) were included in the RAPID registry. Based on VOYAGER PAD eligibility criteria, 98 patients (50.0%) were eligible to DPI. Main reasons for exclusion were oral anticoagulation (12.2%), prior stroke or transient ischemic attack (8.2%), high bleeding risk (49.5%), or concurrent indications for dual antiplatelet therapy (1.5%). In the CCS registry, 2,014 patients were enrolled in the same period (mean age 71.5±11.1 years, 68.7% male). CCS patients who were eligible to DPI were 162 (8.0%). Main reasons for exclusion were concurrent need for dual antiplatelet therapy (27.1%), high bleeding risk (41.0%) and need for oral anticoagulation (19.3%).

Conclusions. Approximately half of patients with revascularized PAD and only one out of twelve patients with CCS undergoing invasive management were eligible to DPI. According to these results, unlike candidates to the VOYAGER PAD strategy, candidates to the COMPASS strategy are more likely to be identified in an outpatient than hospital setting.

A217: COMPARATIVE EFFECTS OF DIFFERENT ANTIPLATELET STRATEGIES IN CARRIERS OF CYP2C19 LOSS-OF-FUNCTION: A NETWORK META-ANALYSIS

Mattia Galli (a), Stefano Benenati (e), Renzo Laborante (b), Giovanni Occhipinti (c), Marco Toselli (a), Paolo Sbarzaglia (a), Roberto Nerla (a), Fausto Castriota (a), Dominick Angiolillo (d)
(a) MARIA CECILIA HOSPITAL GVM CARE AND REASERCH, COTIGNOLA; (b) UNIVERSITÀ CATTOLICA DEL SACRO CUORE, ROMA; (c) UNIVERSITÀ DI CATANIA, CATANIA; (d) UNIVERSITY OF FLORIDA COLLEGE OF MEDICINE - JACKSONVILLE, USA; (e) UNIVERSITÀ DI GENOVA, GENOVA

Background. Carriers of cytochrome P4502C19 (CYP2C19) loss of function (LoF) alleles are associated with reduced levels of clopidogrel active metabolite, leading to high platelet reactivity (HPR), a marker of thrombotic events. This condition affects nearly 30% of clopidogrel treated patients, representing a clinical conundrum. Several alternative antiplatelet therapies have been proposed to overcome HPR in these patients, but their comparative effects remain poorly explored.

Methods. Randomized controlled trials (RCTs) and observational studies comparing different oral antiplatelet therapies in patients' carriers of CYP2C19 LoF alleles were included. A frequentist network meta-analysis to estimate the posterior mean effect was conducted. The primary outcome was the rate of HPR, and the secondary outcome was platelet reactivity as assessed by VerifyNow. Multiple sensitivity (i.e., selectively including RCTs, or excluding patients homozygotes for CYP2C19 LoF) and subgroup analyses (i.e., Asians versus non-Asians and acute versus chronic coronary syndromes) were performed to investigate sources of heterogeneity.

Results. A total of 23 studies were included, 15 RCTs and 8 observational, testing 5 alternative strategies (i.e., additional cilostazol, high-dose clopidogrel, ticagrelor, prasugrel and low-dose prasugrel). Compared with clopidogrel, all the tested strategies were associated with a reduction in the primary endpoint that was greater with prasugrel (OR 0.14, 95% CI 0.03-0.76) and more modest with high dose clopidogrel (OR 0.62, 95% CI 0.23-1.65). A statistically significant reduction in platelet reactivity was found with all alternative antiplatelet strategies except for cilostazol. Results were consistent at secondary analyses.

Conclusions. Our findings support that among carriers of CYP2C19 LoF alleles, alternative antiplatelet strategies are associated with variable effects in platelet reactivity, compared with clopidogrel. High dose clopidogrel and cilostazol may be less effective than other strategies to overcome HPR in these patients.

A218: CORRELATION BETWEEN HIGH DENSITY LIPOPROTEIN (HDL), PARAOXONASE -1 (PON-1) AND SCAVENGER RECEPTOR BETA -1 (SRB-1) LEVELS AND CORONARY ARTERY DISEASE

Marco Alfonso Perrone (a), Manish Kumar (b), Kusum Yadav (b), Akshyaya Pradhan (c), Sergio Bernardini (d), Wahid Ali (b)
(a) DIVISION OF CARDIOLOGY AND CARDIOLAB, DEPARTMENT OF CLINICAL SCIENCES AND TRANSLATIONAL MEDICINE, UNIVERSITY OF ROME TOR VERGATA; (b) DEPARTMENT OF PATHOLOGY, KING GEORGE MEDICAL UNIVERSITY, LUCKNOW, INDIA; (c) DEPARTMENT OF CARDIOLOGY, KING GEORGE MEDICAL UNIVERSITY, LUCKNOW, INDIA; (d) DEPARTMENT OF EXPERIMENTAL MEDICINE, UNIVERSITY OF ROME TOR VERGATA

Background. Coronary artery disease (CAD) is the leading cause of death worldwide. High density lipoprotein (HDL) is well-established marker associated with CAD. Present study was carried out with the primary objective to determine serum levels of two HDL associated markers, Paraoxonase -1 (PON-1) and Scavenger Receptor Beta -1 (SRB-1) in CAD patients vs. controls.
Methods. This case control study included total 92 subjects (65 male and 27 female), with angiographically proven CAD cases (69), and healthy control (23). Based on the disease severity, CAD patients were further divided into categories (CAT-I, II and III). Serum PON-1 and SRB-1 level were measured and compared between patient and control groups.
Results. Level of PON-1 and SRB-1 (32.6 ng/mL and 12.49 ng/mL) were significantly lowered in CAD patients vs healthy control (60.36 ng/mL and 15.85 ng/mL) respectively (both $p<0.001$). Further intergroup comparison showed statistically significant difference between the CAT-I vs III for PON-1 ($p<0.025$), CAT-I vs III and CAT-II vs III for SRB-1 ($p<0.001$). Receiver operating characteristic (ROC) curve showed a cut off values 48.20 ng/mL and 14.90 ng/mL for PON-1, SRB-1.
Conclusions. The current study showed that serum levels of HDL associated PON-1 and SRB-1 are significantly lower in CAD patients and were also inversely related to the increasing severity of coronary artery disease. This inference implies that serum PON-1 and SRB-1 could be used for non-invasive tool for identification of coronary atherosclerosis and risk assessment in CAD patients.

A219: APPLICATION OF THE ACADEMIC RESEARCH CONSORTIUM HIGH BLEEDING RISK CRITERIA IN PATIENTS TREATED WITH CORONARY BIORESORBABLE POLYMER EVEROLIMUS-ELUTING STENTS: INSIGHTS FROM THE POEM TRIAL

Carlo Andrea Pivato (a, k), Luca Testa (b), Antonio Popolo Rubbio (b), Damiano Regazzoli (a), Raffaele Piccolo (c), Giovanni Esposito (c), Carmine Musto (d), Andrea Pacchioni (e), Carlo Briguori (f), Luigi Lucisano (g), Leonardo De Luca (d), Federico Conrotto (h), Francesco Tartaglia (a), Alessia Latini (a), Kamil Stankowski (a), Mauro Chiarito (a), Gennaro Sardella (i), Ciro Indolfi (j), Bernhard Reimers (a), Gianluigi Condorelli (a, k), Giulio Stefanini (a, k)
(a) IRCCS HUMANITAS RESEARCH HOSPITAL; (b) IRCCS SAN DONATO; (c) FEDERICO II, NAPOLI; (d) OSPEDALE SAN CAMILLO-FORLANINI; (e) OSPEDALE DI MIRANO; (f) MEDITERRANEA CARDIOCENTRO; (g) OSPEDALE S. GIOVANNI EVANGELISTA; (h) OSPEDALE LE MOLINETTE; (i) POLICLINICO UMBERTO I; (j) UNIVERSITÀ MAGNA GRECIA; (k) HUMANITAS UNIVERSITY

Background. Previous studies have investigated a 1 to 6-month short dual antiplatelet therapy (DAPT) after percutaneous coronary intervention (PCI) with modern drug eluting-stents to reduce bleeding events.
Objectives. To investigate cardiovascular outcomes in patients at high bleeding risk (HBR) according to the Academic Research Consortium for High Bleeding Risk (ARC-HBR) criteria after PCI with the Synergy bioresorbable-polymer everolimus-eluting stents.
Methods. We applied ARC-HBR criteria in the population of the prospective, single-arm, multicenter POEM (Performance of Bioresorbable Polymer-Coated Everolimus-Eluting Synergy Stent in Patients at HBR Undergoing Percutaneous Coronary Revascularization Followed by 1-Month Dual Antiplatelet Therapy) trial. The primary endpoint was a composite of cardiac death, myocardial infarction, or definite or probable stent thrombosis at 12 months.
Results. The original POEM cohort included 356 patients (80.4%) fulfilling ARC-HBR criteria. Oral anticoagulant use and age ≥75 years were the most frequent major and minor ARC-HBR criteria, respectively. The ARC-HBR group was mainly represented by men (71.1%), with 74.4±9.3 years and a high burden of cardiovascular risk factors. DAPT was prescribed in 79.3%, and single antiplatelet with oral anticoagulant in 18.7%. 12-month follow-up was completed in 96.2%. The primary endpoint occurred in 5.2% (95% CI 3.29-8.10) of patients. Bleeding Academic Research Consortium type 3-5 occurred in 2.7% (95% CI, 1.39%-5.05%).
Conclusions. Previous results of the POEM trial showed positive outcomes regarding ischemic and bleeding events with a 1-month DAPT regimen after Synergy bioresorbable-polymer everolimus-eluting stents. These results are also confirmed in sub-group analysis when ARC-HBR criteria are applied.

A220: KAWASAKI DISEASE: RIDING SHOTGUN WITH ATEROSCLEROSIS?

Davide Sorice (a), Nunzia Simona Borrelli (a), Giancarlo Scognamiglio (a), Flavia Fusco (a), Massimiliana Abbate (a), Giovanni Domenico Ciriello (a), Diego Colonna (a), Anna Correra (a), Emanuele Romeo (a), Rosaria Barracano (a), Nicola Grimaldi (a), Michela Palma (a), Assunta Merola (a), Maria Giovanna Russo (b), Berardo Sarubbi (a)
(a) ADULT CONGENITAL HEART DISEASE UNIT, AORN "OSPEDALI DEI COLLI", MONALDI HOSPITAL, NAPLES, ITALY; (b) PEDIATRIC CARDIOLOGY UNIT, DEPARTMENT OF TRANSLATIONAL MEDICAL SCIENCES, UNIVERSITY OF CAMPANIA "LUIGI VANVITELLI", NAPLES, ITALY

Introduction. Kawasaki disease (KD) is a systemic inflammatory disease that mainly affects children younger than 5 years of age. The main clinical manifestations are high fever, bilateral conjunctivitis, later cervical lymphadenomegaly, and polymorphous exanthema. The most common complications are myocarditis and coronary aneurysm formation.
Clinical case. We present the clinical case of a 25-year-old patient with severe obesity and mixed dyslipidemia, with previous diagnosis of KD which resulted in aneurysms in both coronary arteries and inferior myocardial infarction. In May 2022, he presented with transient reduction in cardiac ejection fraction following SARS-CoV2 infection. Coronary CT showed severe coronary calcifications, numerous aneurysmal dilatations, calcific plaque at the right coronary artery with apparently severe stenosis, and a hypodense plaque at the proximal tract of LADA (Left Anterior Descending Artery) determining moderate-severe stenosis. He was therefore admitted and underwent coronary examination with PTCA of a critical stenosis on proximal LADA; a collateralized chronic occlusion of the right coronary artery was also revealed. At discharge, the patient was referred to a bariatric surgery pathway.
Discussion. Inflammation of myocardium and coronary artery wall from KD exposes patients to risk of heart failure and myocardial ischemia, therefore identification and follow-up of coronary lesions is essential. Additional cardiovascular risk factors complexify the recognition of the specific role of the syndrome in the development of significant coronary artery stenosis. Indeed, the role of KD as a risk factor for atherosclerotic disease in adulthood is still under debate, but there is evidence of proatherogenic alteration of the lipid profile and increased arterial wall stiffness. Coronary CT has proven to be a useful technique for the identification and follow-up of coronary artery lesions, using coronarography for the treatment of high-risk lesions.

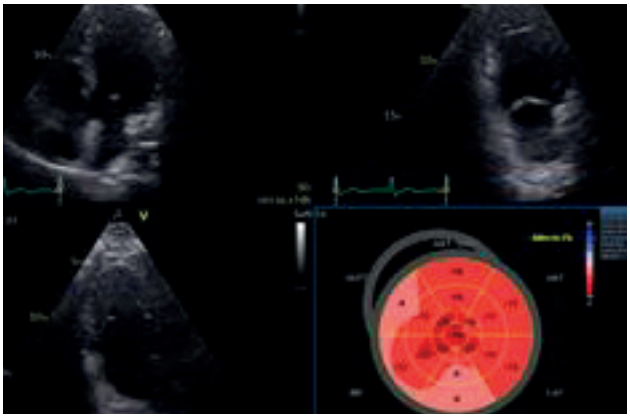

A221: INCREASED PREVALENCE OF HIGH-RISK CORONARY PLAQUES DETECTED BY COMPUTED TOMOGRAPHY CORONARY ANGIOGRAPHY AMONG PATIENTS WITH NON-ALCOHOLIC FATTY LIVER DISEASE

Ovidio De Filippo (a), Gianluca Di Pietro (c), Marco Nebiolo (a, b), Davide Giuseppe Ribaldone (a), Marco Gatti (b), Francesco Bruno (a), Guglielmo Gallone (b), Angelo Armandi (b), Elisabetta Bugianesi (b), Gaetano Maria De Ferrari (b), Fabrizio D´ascenzo (b)
(a) A.O.U. CITTÀ DELLA SALUTE E DELLA SCIENZA DI TORINO; (b) DIPARTIMENTO DI SCIENZE MEDICHE, UNIVERSITÀ DI TORINO; (c) DIPARTIMENTO DI SCIENZE CLINICHE INTERNISTICHE, ANESTESIOLOGICHE E CARDIOVASCOLARI, UNIVERSITÀ DI ROMA "LA SAPIENZA"

Background. Non-alcoholic fatty liver disease (NAFLD) is associated with an increased risk of coronary artery disease (CAD). Computed Tomography Coronary Angiography (CTCA) can assess both the extent and the features of coronary plaques. We aimed to gather evidence about the prevalence and features of coronary plaques among NAFLD patients.
Methods. PubMed, Scopus, and Google scholar databases were searched for randomised controlled trials and adjusted observational studies assessing the prevalence and features of coronary plaques by means of CTCA in NAFLD patients as compared with a control group. The prevalence of coronary stenosis (defined as>30% and>50% diameter of stenosis), of increasing coronary artery calcium (CAC) score and of high-risk features (namely low-attenuation plaques (LAP), napkin ring sign, spotty calcification, and positive remodeling (PR)) along with in NAFLD patients were the endpoints of interest. The protocol was registered on PROSPERO (temporary ID: 453172).
Results. Study search identified 1095 deduplicated results. 24 observational studies encompassing 302765 patients (103694 NAFLD and 190752 non-NAFLD) were included. NAFLD was associated with an increased prevalence of critical coronary stenosis compared with controls (OR 1.54, 95%CI 1.23-1.93). Increased values of CAC score were observed in NAFLD patients compared with controls (OR 1.35, 95%CI 1.02-1.78 and OR 2.26, 95%CI 1.57-3.23 for CAC score 0-100 and>100, respectively). An increased risk of "high-risk" coronary plaques was observed in NALFD patients compared with controls (2.13, 95%CI 1.42-3.19). As high-risk features plaques, a higher prevalence of PR and spotty calcification characterise NAFLD patients (OR 2.92, 95%CI 1.79-4.77 and OR 2.96, 95%CI 1.22-7.20).
Conclusions. Patients with NAFLD are at increased risk of developing critical coronary stenosis and coronary plaques characterized by high-risk features as detected by CTCA.

A222: IMPACT OF ETHNICITY ON ANTIPLATELET TREATMENT REGIMENS FOR BLEEDING REDUCTION: A SYSTEMATIC REVIEW AND PRE-SPECIFIED SUBGROUP ANALYSIS

Mattia Galli (a), Renzo Laborante (b), Giovanni Occhipinti (c), Andrea Zito (b), Luigi Spadafora (d), Giuseppe Biondi-Zoccai (d), Roberto Nerla (a), Fausto Castriota (a), Domenico D'Amario (e), Davide Capodanno (c), Young-Hoon Jeong (f), Takeshi Kimura (g), Roxana Mehran (h), Dominick Angiolillo (i)
(a) MARIA CECILIA HOSPITAL GVM CARE AND REASERCH, COTIGNOLA; (b) UNIVERSITÀ CATTOLICA DEL SACRO CUORE, ROMA; (c) UNIVERSITÀ DI CATANIA; (d) UNIVERSITÀ LA SAPIENZA DI ROMA; (e) UNIVERSITÀ DEL PIEMONTE ORIENTALE; (f) CHUNG-ANG UNIVERSITY GWANGMYEONG HOSPITAL, GWANGMYEONG, REPUBLIC OF KOREA; (g) HIRAKATA KOHSAI HOSPITAL, OSAKA, JAPAN; (h) ICAHN SCHOOL OF MEDICINE AT MOUNT SINAI, NEW YORK, USA; (i) UNIVERSITY OF FLORIDA COLLEGE OF MEDICINE - JACKSONVILLE, FLORIDA, USA

Background. Randomized controlled trials (RCTs) testing bleeding reduction strategies using antiplatelet treatment regimens (BRATs) have shown promising results, but many of them have been conducted in East Asian (EA) patients, limiting the generalizability of these findings given their different ischemic-bleeding risk profile compared to other ethnicities.
Methods and Results. RCTs comparing a BRATs versus standard 12-month dual antiplatelet therapy (DAPT) in patients with an acute coronary syndrome (ACS) undergoing percutaneous coronary intervention (PCI) were selected. Twenty-six RCTs testing seven different BRATs were included. The only strategy associated with a trade-off in MACE was "upfront unguided de-escalation" in the subgroup of non-EAs (RR 1.16, 95% CI 1.09-1.24). All but aspirin monotherapy-based strategies (i.e., "short and very short DAPT followed by aspirin") were associated with reduced bleeding compared with standard DAPT in both EA and non-EA patients. There were no significant differences between subgroups, but the lack of RCTs in some of the included strategies and the difference in the certainty of evidence between EA or non-EA patients revealed that the evidence in support of different BRATs in ACS undergoing PCI is influenced by ethnicity. Moreover, absolute risk reduction estimation revealed that some BRATs might be more effective than others in reducing bleeding according to ethnicity.
Conclusions. Most BRATs are associated with reduced bleeding without any trade-off in hard ischemic endpoints regardless of ethnicity. However, the supporting evidence and relative safety profiles of different BRATs might be significantly affected by ethnicity, which should be considered in clinical practice.

A223: IMPACT OF ETHNICITY ON PLATELET REACTIVITY PROFILES IN PATIENTS ON CLOPIDOGREL TREATMENT

Salvatore Giordano (a, b), Francesco Franchi (a), Fabiana Rollini (a), Latonya Been (a), Tala Al Saleh (a), Ekin Uzunoglu (a), Andres M. Pineda (a), Siva Suryadevara (a), Daniel Soffer (a), Martin M. Zenni (a), Madeline Mahowald (a), Dominick J. Angiolillo (a), Luis Ortega-Paz (a)
(a) DIVISION OF CARDIOLOGY, UNIVERSITY OF FLORIDA COLLEGE OF MEDICINE, JACKSONVILLE, FL, USA; (b) DEPARTMENT OF MEDICAL AND SURGICAL SCIENCES, DIVISION OF CARDIOLOGY, "MAGNA GRAECIA" UNIVERSITY, CATANZARO, ITALY

Background. African Americans (AAs) undergoing percutaneous coronary intervention (PCI) have an increased risk of major adverse cardiac events (MACE) compared to non-AA patients. Among patients treated with clopidogrel, AAs have worse clinical outcomes, even after accounting for traditional risk factors. The potential role of differential platelet inhibition profiles in this observed MACE disparity remains undetermined.
Methods and Results. This is an individual participant data pooled analysis of patients with atherosclerotic cardiovascular disease (ASCVD) on chronic treatment with clopidogrel (≥14 days), enrolled in 7 pharmacodynamic (PD) studies. PD profiles were investigated with VerifyNow $P2Y_{12}$, reported as PRU; light transmittance aggregometry (LTA) following ADP 5 μM and 20 μM stimuli reported as MPA%; whole-blood VASP assay, reported as PRI. CYP2C19 genotyping was performed to determine CYP2C19 allele status (*1,*2,*3,*17). High platelet reactivity (HPR) status was defined according to standard definitions: PRU>208, ADP 20-μM MPA>59%, ADP 5-μM MPA%>46%, and PRI>50%. A total of 346 patients were included, with 36% self-reported AA. The prevalence of HPR, defined by PRU, was 31.2%. PRU and PRI levels were significantly higher in the AA compared to non-AA patients, without difference in LTA 20- and 5- μM. AA patients had a higher prevalence of HPR according to PRU and PRI than non-AA, without differences in LTA (Table). On multivariate analysis, AA ethnicity (Odds Ratio [OR] 3.54, 95%CI 1.77-7.06, p<0.001), CYP2C19 loss-of-function (LOF) alleles (OR 2.27, 95% CI 1.11-4.65, p=0.024), and history of cerebrovascular accident (CVA) (OR 2.99, 95%CI 1.26-7.08, p=0.013) were associated with an increased risk for HPR. Conversely, higher hemoglobin levels were associated with a reduction of HPR (OR 0.60, 95%CI 0.45-0.77, p<0.001). There was a significant interaction between AA ethnicity and CYP2C19 LOF alleles ($p_{interaction}$=0.044).
Conclusions. In patients with ASCVD on chronic clopidogrel therapy, 1 out 3 patients exhibited a suboptimal PD response. AA ethnicity was an independent risk factor for HPR, which could be partially explained by a higher prevalence of CYP2C19 LOF alleles in AAs than in non-AAs.

	African Americans (n=125)	Non-African Americans (n=221)	p-value
PRU	195±77	157±68	<0.001
HPR (%)	60 (48.0)	48 (21.7)	<0.001
ADP 20μM	51±21	51±18	0.997
HPR, (%)	42 (33.9)	71 (32.6)	0.806
ADP 5μM	37±22	35±16	0.713
HPR, (%)	36 (29.0)	47 (21.6)	0.121
PRI	71±21	57±25	<0.001
HPR, (%)	77 (82.8)	117 (67.6)	0.008

Table. On-clopidogrel platelet reactivity profiles according to ethnicity.

A224: SEVERE ATHEROSCLEROTIC PATIENTS TREATED WITH RIVAROXABAN: AN ECHOCARDIOGRAPHIC STUDY

Velia Iadevaia (a), Martina Pucci (a), Adelaide Iervolino (a), Vittoria Gammaldi (a), Daniele Paoletta (a), Luca Capece (a), Maria Teresa Pontoriero (a), Vittoria Cuomo (a), Domenico Sciascia (a), Marina Iacono (a), Roberta Esposito (a)
(a) DEPARTMENT OF CLINICAL MEDICINE AND SURGERY, FEDERICO II UNIVERSITY HOSPITAL, NAPLES, ITALY

Background. The COMPASS Trial has demonstrated a reduction of the risk of myocardial infarction, stroke, or cardiovascular death in subjects with coronary artery disease (CAD) or peripheral artery disease (PAD) in patients treated with rivaroxaban 2.5 mg twice daily (bid) + aspirin 100 mg once daily (od) compared with aspirin 100 mg od. Little is known about the change in ventricular function using noninvasive imaging in patients taking asa and rivaroxaban 2.5 bid.
Objectives. Our study performed an echocardiographic evaluation of patients affected by CAD and PAD in therapy with rivaroxaban 2.5 mg twice daily (bid) + aspirin 100 mg once daily (od) at baseline and after three months.
Methods. We performed a prospective review of 10 patients out of the 17 evaluated at baseline, admitted at our EchoLab in the last year, who underwent echocardiogram prior starting therapy with rivaroxaban 2.5

mg twice daily (bid) + aspirin 100 mg once daily (od). Echo-Doppler assessment was realized according to the standards of the European Association of Cardiovascular Imaging (EACVI) standardization of the echo report. Continuous normally distributed variables were compared by using the student t-test. A probability value <0,05 was considered statistically significant. Analyses were performed with SPSS version 25 (IBM Corporation, Somers, New York).
Results. We observed an improvement of echocardiographic variables at three months compared to baseline: higher ejection fraction (EF) (56,80 ± 4,04 vs 54,80 ± 2,25, p-value: 0,044) and higher Global Longitudinal Strain (GLS) (19,55 ± 3,34 vs 17,91 ± 3,48, p-value: 0,026); those two variables were statistically significant. There is no worsening of diastolic function: E/E' ratio (10,24 ±3.58 vs 10.65 ± 2.89, p-value 0.372), pulmonary artery systolic pressure (PAPS) (27.6 ± 7.46 vs 26.4 ± 7.19, p-value 0.736) and tricuspid annular plane systolic excursion (TAPSE) (21.4 ± 3.59 vs 22.4 ± 3.41, p-value 0.311).
Conclusions. COMPASS trial has demonstrated a lower rate in adverse events through the addition of rivaroxaban 2.5 mg twice daily to ASA, particularly stroke and cardiovascular mortality, whereas severe bleeding events were less frequent and had less impact. Despite the small number of patients enrolled, the reported data indicate a clinical and echocardiographic improvement of patients affected by CAD and PAD treated with the COMPASS protocol.

A225: UN CRISTALLO MINACCIOSO: L'ATEROEMBOLISMO CLASSICO COME CONSEGUENZA DOPO IL CATETERISMO CARDIACO

Pedro Moraes (a), Dyovane Lopes (a), Anita Fragoso (a), Verônica Barreto (a)
(a) SCUOLA PAULISTA DI MEDICINA - UNIVERSITÀ FEDERALE DI SAN PAOLO

L'embolia di cristalli di colesterolo è spesso sottodiagnosticata a causa della sua diversa presentazione clinica e si verifica nel 2% degli individui dopo una cateterizzazione cardiaca, con prognosi e trattamento diversi rispetto al tromboembolismo correlato. Giorno 0: Un uomo di 56 anni si presenta con infarto del miocardio senza elevazione del tratto ST. Sottoposto ad angiografia coronarica con angioplastica dell'arteria discendente anteriore sinistra. Giorno 4: Dolore, cianosi e freddo agli arti (terzo dito e alluce degli arti inferiori sinistri). Giorno 14: Peggioramento delle lesioni agli arti con alterazione della funzione renale (velocità di filtrazione glomerulare stimata di 25 ml/min). Giorno 16: Uremia refrattaria, iperkaliemia e necessità di emodialisi. Giorno 25: Dimissione dall'ospedale con miglioramento della funzione renale. Giorno 81: Visita ambulatoriale con miglioramento delle lesioni cutanee e velocità di filtrazione glomerulare stimata di 50 ml/min.
Caso clinico. Un uomo di 56 anni, con ipertensione, dislipidemia e fumatore, è stato ammesso in un ospedale terziario a causa di una sindrome coronarica acuta. Dopo una coronarografia e angioplastica dell'arteria discendente anteriore sinistra, ha presentato dolore intenso, freddo e cianosi al terzo dito e alluce degli arti inferiori sinistri. Gli esami hanno mostrato leucocitosi con eosinofilia, peggioramento della funzione renale e iperkaliemia con acidosi metabolica. L'ecocardiogramma ha rivelato riduzione della frazione di eiezione e placche ateromatose nelle arterie. È stato fornito trattamento di supporto, corticosteroidi, statine e dialisi. Dopo la dimissione ospedaliera, si è osservato un miglioramento delle lesioni cutanee e della funzione renale.
Discussione. L'ateroembolismo è una malattia multisistemica caratterizzata da cianosi distale, lesione renale acuta ed eosinofilia. I cristalli di colesterolo derivanti dalle placche aterosclerotiche causano occlusione arteriosa e ischemia degli organi terminali. Il trattamento è principalmente di supporto, con l'uso di statine per prevenire future embolizzazioni. La terapia anticoagulante è controversa e i corticosteroidi possono essere benefici nella fase acuta. Nei casi associati a malattia arteriosa periferica, può essere necessaria la rivascolarizzazione.
Conclusioni. Il riconoscimento precoce dell'ateroembolismo è fondamentale per fornire cure adeguate.

Figura 1. Lesioni cutanee al quattordicesimo giorno dopo la cateterizzazione cardiaca.

A226: TUTTA COLPA DEL CALABRONE?

Carmine Romano (b), Ailia Giubertoni (a), Martina Solli (a), Lidia Rossi (a), Giuseppe Patti (a, b)
(a) SCDU CARDIOLOGIA-OSPEDALE MAGGIORE DELLA CARITÀ-NOVARA; (b) UNIVERSITÀ DEGLI STUDI DEL PIEMONTE ORIENTALE AMEDEO AVOGADRO

Introduzione. La sindrome di Kounis è definita come la concomitante presenza di una sindrome coronarica acuta (SCA) ed una reazione allergica. Può essere caratterizzata da presenza di vasospasmo in pazienti con coronarie normali (tipo I), rottura o erosione di placca vulnerabile pre-esistente (tipo II), trombosi di stent o morte cardiaca improvvisa con esame istologico indicativo di infiltrazione eosinofilo-mastocitaria in prossimità dello stent (tipo III).
Caso clinico. Una donna di 75 anni, con multipli fattori di rischio cardiovascolare, veniva ricoverata presso la nostra divisione con diagnosi di infarto miocardico con sopraslivellamento del tratto ST (STEMI) inferiore accaduto in seguito ad una puntura di calabrone all'arto superiore destro, che provocava comparsa dopo pochi minuti di sudorazione profusa associata a dispnea e dolore toracico. La paziente era nota per pregresso STEMI inferiore trattato tramite angioplastica ed impianto di uno stent medicato su coronaria destra prossimale 5 anni prima. Durante il trasporto venivano somministrati antistaminico e cortisone, inefficaci nella risoluzione del dolore e delle anomalie elettrocardiografiche. Veniva quindi sottoposta in urgenza a coronarografia che evidenziava una trombosi intrastent (Fig.1) ed eseguita ricanalizzazione con pallone medicato in seguito alla quale si evidenziava una stenosi critica per verosimile sottoespansione dello stent, che non si risolveva mediante utilizzo di palloni non complianti (Fig.2). Dopo 3 giorni, a stabilizzazione clinica raggiunta, veniva quindi eseguito controllo angiografico che confermava, mediante tomografia a coerenza ottica, sottoespansione dello stent e presenza di placca fibrocalcifica. Veniva quindi eseguita angioplastica efficace con cutting balloon e litotripsia intravascolare. La successiva degenza della paziente risultava regolare con dimissione a domicilio.
Conclusioni. La sindrome di Kounis rappresenta una forma particolare di SCA, con suoi meccanismi fisiopatologici peculiari. Nel caso descritto è verosimile che la reazione allergica scatenata dalla puntura dell'insetto abbia giocato un ruolo nello scatenare la trombosi coronarica a livello dello stent. Tuttavia, dopo la risoluzione della trombosi, si è evidenziata una sottoespansione dello stent stesso che ha rappresentato il meccanismo favorente la trombosi proprio in tale sede. Nella nostra paziente è quindi realistico ipotizzare che vi sia stato un meccanismo sindrome di Kounis tipo III su un substrato favorevole rappresentato dalla sottoespansione dello stent.

Figura 1.

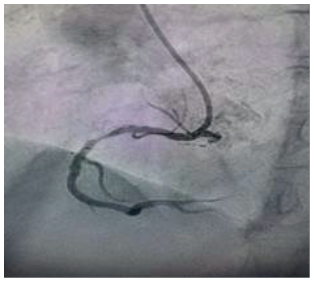

Figura 2.

A227: E-CYG INDUCES A PRO-ATHEROTHROMBOTIC PHENOTYPE IN HUMAN ENDOTHELIAL CELLS VIA EXPRESSION OF FUNCTIONAL TISSUE FACTOR

Gisella Titolo (a), Mariarosaria Morello (a), Laura Marra (c), Gennaro De Rosa (b), Giuseppe Nicoletti (b), Vincenzo Ercolano (b), Akhmetzhan Sugraliyev (d), Giovanni Cimmino (a), Plinio Cirillo (b)
(a) DEPARTMENT OF TRANSLATIONAL MEDICAL SCIENCES, SECTION OF CARDIOLOGY, UNIVERSITY OF CAMPANIA "LUIGI VANVITELLI", NAPLES, ITALY; (b) DEPARTMENT OF ADVANCED BIOMEDICAL SCIENCES, SECTION OF CARDIOLOGY, UNIVERSITY OF NAPLES "FEDERICO II", NAPLES, ITALY; (c) SC CELL BIOLOGY AND BIOTHERAPY, ISTITUTO NAZIONALE TUMORI IRCCS, FONDAZIONE G. PASCALE, NAPLES, ITALY; (d) KAZAKH NATIONAL MEDICAL UNIVERSITY, DEPARTMENT OF INTERNAL DISEASE, ALMATY, KAZAKHSTAN

Background. In the last few years, the use of e-cigarettes (E-CYG) is increasing because they are considered less dangerous of the regular tobacco. However, several in vitro and in vivo studies have demonstrated that E-CYG might exert several deleterious effects such as DNA damage, oxidative stress, macrophages activation, inflammation, and endothelial dysfunction. It is well known that dysfunctional endothelial cells (ECs) express Tissue Factor (TF) on their surface, triggering coagulation cascade, and finally leading to intravascular thrombosis. To date, it remains unknown the link between E-CYG and thrombosis. Thus, the aim of the present study was to investigate whether E-CYG might promote a prothrombotic phenotype in ECs by inducing TF expression.
Methods. Human Umbelical Vein Endothelial Cells (HUVEC) were incubated with increasing doses of E-CYG (commercially available and mix of propylene glycol/vegetable glycerine/nicotine 18mg/mL) up to 1.8mg/mL. TF gene expression and protein levels were assessed at different ti-

me points by Real Time PCR and western blot, respectively. TF surface expression and activity were also measured by FACS analysis and coagulation assay. Finally, to evaluate a possible mechanism of action of the E-CYG on TF expression, NF-kB translocation assay was investigated.
Results. E-CYG significantly increased TF expression at both gene and protein levels in a time and dose dependent manner. Surface expression and procoagulant activity were increased as well. The NF-κB pathway seems involved in the modulation of these phenomena.
Conclusions. Data of the present study, although in vitro, indicate that E-CYG might cause endothelial dysfunction by shifting ECs to a pro-thrombotic phenotype via expression of functional TF. These observations permit to speculate that, in contrast to current thought, E-CYG might represent a potential risk factor for developing acute cardiovascular thrombotic events.

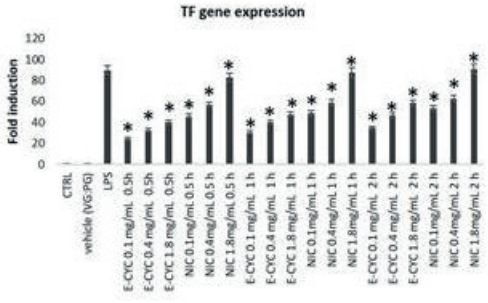

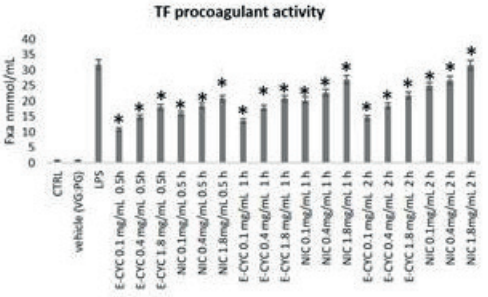

A228: ROLE OF NATURAL ANTIOXIDANTS IN GUT MICROBIOTA ALTERATIONS SUBSEQUENT TO HIGH FAT DIET: IMPLICATIONS FOR CARDIOMETABOLIC RISK ASSESSMENT

Rocco Mollace (b), Roberta Macri (a), Federica Scarano (a), Cristina Carresi (a), Vincenzo Musolino (a), Micaela Gliozzi (a), Jessica Maiuolo (a), Annamaria Tavernese (a), Massimo Federici (b), Francesco Barillà (b), Vincenzo Mollace (a)
(a) UNIVERSITY "MAGNA GRAECIA" OF CATANZARO; (b) UNIVERSITY OF ROME "TOR VERGATA"

Evidence exists that the gut microbiota contributes to the alterations of lipid metabolism associated with high-fat diet (HFD). Moreover, the gut microbiota has been found to modulate the metabolism and absorption of dietary lipids, thereby affecting the formation of lipoproteins occurring at the intestinal level as well as systemically, though the pathophysiological implication of altered microbiota composition in HFD and its role in the development of atherosclerotic vascular disease (ATVD) remain to be better clarified. Recently, evidence has been collected indicating that supplementation with natural polyphenols and fibres accounts for an improvement of HFD-associated intestinal dysbiosis, thereby leading to improved lipidemic profile. This study aimed to investigate the protective effect of a bergamot polyphenolic extract (BPE) containing 48% polyphenols enriched with albedo and pulp-derived micronized fibres (BMF) in the gut microbiota of HFD-induced dyslipidaemia. Rats that received an HFD over a period of four consecutive weeks showed a significant increase in plasma cholesterol, triglycerides and plasma glucose compared to a normal-fat diet (NFD) group. This effect was accompanied by body weight increase and alteration of lipoprotein size and concentration, followed by high levels of MDA, a biomarker of lipid peroxidation. Treatment with a combination of BPE plus BMF (50/50%) resulted in a significant reduction in alterations of the metabolic parameters found in HFD-fed rats, an effect associated with increased size of lipoproteins. Furthermore, the effect of BPE plus BMF treatment on metabolic balance and lipoprotein size re-arrangement was associated with reduced gut-derived lipopolysaccharide (LPS) levels, an effect after improved gut microbiota as expressed by modulation of the Gram-negative bacteria Proteobacteria, as well as Firmicutes and Bacteroidetes. This study suggests that nutraceutical supplementation of HFD-fed rats with BPE and BMP or with their combination product leads to restored gut microbiota, an effect associated with lipoprotein size re-arrangement and better lipidemic and metabolic profiles.

ATTIVITÀ FISICA E CARDIOLOGIA DELLO SPORT

A229: APPLICATION OF THE INTERNATIONAL CRITERIA FOR THE INTERPRETATION OF THE ATHLETE'S ECG TO A PAEDIATRIC POPULATION

Francesca Graziano (a, b), Laura Manfrin (a), Edoardo Oscar Genta (a), Dorottya Balla (b), Hajnalka Vago (b, c), Alessandro Zorzi (a), Domenico Corrado (a), Laura Brusamolin (d), Franco Giada (e)
(a) DEPARTMENT OF CARDIAC, THORACIC AND VASCULAR SCIENCES AND PUBLIC HEALTH, UNIVERSITY OF PADOVA, ITALY; (b) HEART AND VASCULAR CENTER, SEMMELWEIS UNIVERSITY, BUDAPEST, HUNGARY; (c) DEPARTMENT OF SPORTS MEDICINE, SEMMELWEIS UNIVERSITY, BUDAPEST, HUNGARY; (d) SPORTS MEDICINE UNIT, AULSS6 EUGANEA, PADOVA, ITALY; (e) SPORTS MEDICINE AND CARDIOVASCULAR REHABILITATION UNIT, CARDIOVASCULAR DEPARTMENT, AULSS3 NOALE, ITALY

Background. In Italy, the starting age for pre-participation screening (PPS) is defined by the single sports federation and sometimes includes individuals under the age of 12. Current International Criteria for ECG interpretation in athletes are recommended for subjects between 12- and 35-year-old.
Purpose. To define the prevalence of ECG alterations (normal, borderline, abnormal) in the ≤12 years population compared to older athletes, and to define which of these are training related. To assess the applicability of the 2017 International Criteria to a population 12-year-old.
Methods. Athletes of both sexes, aged 7-18 years, undergoing PPS in the period 2019-2022, regardless of the sport discipline, were retrospectively enrolled. The screening protocol for competitive athletes is defined by Italian law. The ECG was interpreted according to the recommendations of the 2017 International Criteria.
Results. The final population was composed by 2140 athletes (mean age 12.5±2.61 years, 60% ≤12 years, 40%>12 years). No statistically significant differences were found in the percentage of normal (98% vs 97%, p=0.4), borderline (1.8% vs 1.5%, p=0.5) and abnormal (0.5% vs 1.2%, p=0.06) alterations in the group ≤12 years compared to>12 years. The most frequently observed ECG abnormalities were incomplete right bundle branch block (iRBBB, 22.8%), early repolarization (14.8%) and left ventricular hypertrophy (13.8%). When comparing the two age groups, a statistically significant difference was found in the prevalence of sinus bradycardia (SB, 0.6% vs 8.2%, p<0.001), 1st degree atrio-ventricular block (AVB, 0.2% vs 1.6% p<0.001) and T-wave inversion in V1-V3 (7.3% vs 2.3%, p<0.001) (Figure 1). Furthermore, in the younger age group, there was no correlation between the prevalence of these ECG changes and the level of training.
Conclusions. SB and 1st degree AVB are extremely rare in athletes ≤12 years and do not appear to be training-related, and therefore should be considered as abnormal findings in the pediatric population. Furthermore, in both groups, complete RBBB, 2nd degree Mobitz 1 AVB and the presence of one premature ventricular beat on ECG should also be classified as abnormal. The results highlight the limitations of International Criteria for the interpretation of the athlete's ECG in young people under 18 years, and particularly under 12.

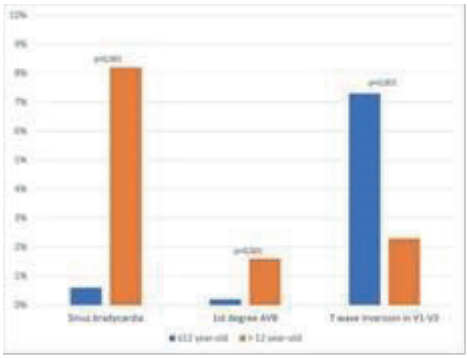

Figure 1. Prevalence of electrocardiographic alterations with statistically significant difference between the two age groups. AVB, atrio-ventricular block.

A230: PREVALENCE OF LOW VOLTAGES AND QRS FRAGMENTATION IN ADOLESCENTS AND CHILDREN PRACTICING SPORT

Francesca Graziano (a, b), Edoardo Oscar Genta (a), Laura Manfrin (a), Alessandro Zorzi (a), Domenico Corrado (a), Laura Brusamolin (c), Franco Giada (d)
(a) DEPARTMENT OF CARDIAC, THORACIC AND VASCULAR SCIENCES AND PUBLIC HEALTH, UNIVERSITY OF PADOVA, ITALY; (b) HEART AND VASCULAR CENTER, SEMMELWEIS UNIVERSITY, BUDAPEST, HUNGARY; (c) SPORTS MEDICINE UNIT, AULSS6 EUGANEA, PADOVA, ITALY; (d) SPORTS MEDICINE AND CARDIOVASCULAR REHABILITATION UNIT, CARDIOVASCULAR DEPARTMENT, AULSS3 NOALE, ITALY

Background. Low QRS Voltages (LQRSV) and QRS fragmentation (FQRS) are a possible sign of myocardial fibrosis and cardiomyopathy, but they

are not included in the 2017 International Criteria for the interpretation of athlete's ECG.
Purpose. To investigate the prevalence of LQRSV and FQRS and the main determinants of precordial and limb QRS voltages in a cohort of athletes aged 7-18 years.
Methods. Athletes of both sexes, aged 7-18 years, undergoing preparticipation screening (PPS) in the period 2019-2022, regardless of the sport discipline practiced, were retrospectively enrolled. The screening protocol for competitive athletes is defined by Italian law. The ECG was interpreted according to the recommendations of the 2017 International Criteria. R- and S-waves in V1, V5 and V6 and maximum QRS amplitudes in limb leads were measured. Fragmented QRS morphologies were coded and detected in each individual lead and then grouped into five patterns (Figure 1).
Results. The final population was composed by 2140 athletes (mean age 12.5 ±2.61 years, 60% ≤12 years, 40%>12 years, 48% males). QRS voltages were found to be significantly dependent on sex and age: in males, precordial voltages tend to increase with age; in females, both precordial and limb voltages decrease with age. There was a weak negative correlation between precordial (r=-0.057; p=0.009) and peripheral (r=-0.047; p=0.03) voltages and BMI. In male athletes, there was a weak correlation between training level and precordial voltages (r=0.135, p<0.001), but only in the>12-year-old group. Multivariate analysis showed that age and BMI were the factors influencing precordial voltages in both sexes, whereas peripheral leads were influenced by BMI in males and age in females. Five athletes (0.002%, 2 ≤12 years, 3/5 males) presented LQRSV in the limb leads, none in the precordial leads. The leads with the highest FQRS prevalence were V1 (24%), V2 (12%), DIII (1.5%), aVR (68%) and aVL (15.6%), with most frequent RSR' morphology in V1-V2. Ten athletes (0.004%, 3 ≤12 years, 8/10 males) showed a FQRS pattern in ≥2 continuous leads other than V1-V2 and aVR.
Conclusions. QRS voltages resulted to be influenced by gender, age, BMI and, in athletes>12 years, weakly by training level. Detecting LQRSV and FQRS in at least two continuous leads is rare in athletes aged 7-18 years. Future studies are needed to determine their clinical and prognostic value.

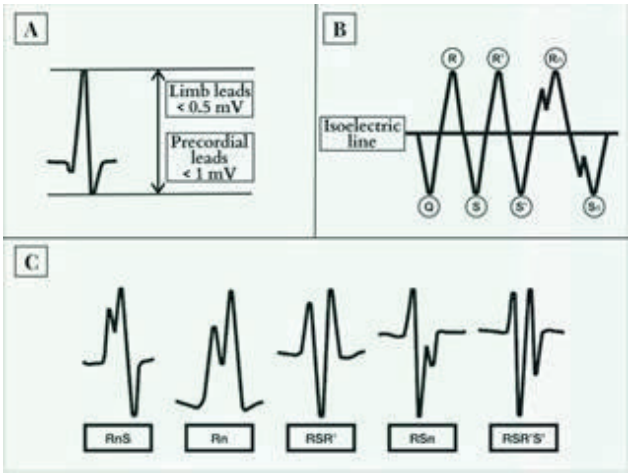

Figure 1. Peak-to-peak measurement of QRS voltage and definition of low voltages in limb and precordial leads (A). Rules for coding the different waves of the QRS complex (B). Classification of the five patterns of QRS fragmentation (C).

A231: PREVALENCE OF ATHEROSCLEROTIC CORONARY ARTERY DISEASE IN MASTER ATHLETES WITH VENTRICULAR ARRHYTHMIAS ON EXERCISE TESTING: IMPLICATIONS FOR PREPARTECIPATION SCREENING

Francesca Graziano (a), Antonella Millin (a), Elena Cozza (a), Giulia Mattesi (a), Valeria Pergola (a), Raffaella Motta (b), Alessio Micchi (c), Roberto Filippini (c), Carmelo Cicciò (d), Francesco Zamboni (c), Alessandro Zorzi (a)
(a) DEPARTMENT OF CARDIAC, THORACIC, AND VASCULAR SCIENCES AND PUBLIC HEALTH, UNIVERSITY OF PADOVA, PADOVA, VENETO, ITALY; (b) UNIT OF ADVANCED CLINICAL AND TRANSLATIONAL IMAGING, DEPARTMENT OF MEDICINE, DIMED, UNIVERSITY OF PADOVA, PADOVA, VENETO, ITALY; (c) SPORT UNIT, IRCCS SACRO CUORE DON CALABRIA HOSPITAL, NEGRAR DI VALPOLICELLA, ITALY; (d) DIVISION OF RADIOLOGY, DEPARTMENT OF IMAGING, IRCCS SACRO CUORE DON CALABRIA HOSPITAL, NEGRAR DI VALPOLICELLA, ITALY

Background. The leading cause of sudden cardiac death in master athletes (≥35 years) is coronary atherosclerotic disease (CAD). During pre-participation screening (PPS), the primary indication for investigating CAD in this population is ST-segment depression at exercise test (ET); a second most debated indication is represented by high-risk premature ventricular beats (PVBs), which are considered another potential marker of ischemic heart disease. However, the prevalence of coronary artery disease in master athletes with PVBs is still unknown.
Objective. The aim of this study was to evaluate the prevalence of CAD in master athletes who underwent coronary computed tomography (CCT) due to high-risk PVBs during PPS (emerging indication), and to compare this population to age-, gender- and risk factors-matched group of athletes who underwent CCT due to ST segment depression during ET (traditional indication).
Methods. We retrospectively enrolled master athletes with no baseline ECG abnormalities and no previous history of heart disease who underwent CCT due to non-common PVBs during PPS. We compared them with a control group of athletes (matched by age, sex, risk factors and type of sport) with ST-segment depression during PPS. The entity of the disease was assessed using the CAD-RADs scoring system (0=no plaque, 1=minimal stenosis 1-24%, 2=mild stenosis 25-49%, 3=moderate stenosis 50-69%, 4A=severe stenosis 70-99%, 4B=severe stenosis 70-99% left main stem>50% or 3 vessels ≥70%, 5=total occlusion).
Results. The population resulted to be composed by 70 Caucasian athletes, median age 53 (44-59 years, 88% male), 73% practiced endurance sports. Thirty-five of them underwent CCT for ST-segment depression and 35 for high-risk PVBs. A CAD-RADs of 0 was detected in 63% of athletes, 1-2 in 25.6%, 3 in 5.7%, and 4A-4B in 5.7%. A CAD was found in 37% of athletes investigated for PVB at ET and the same prevalence was found among subjects with ST-depression (p=0.8). Between athletes with moderate-severe CAD, 75% had one or more cardiovascular risk factors, while 25% had no risk factors.
Conclusions. The prevalence of CAD in master athletes resulted to be equivalent in case of PVBs and ST-segment depression and, in the majority of cases, was a mild disease. Despite a coronary artery stenosis>50% was detected just on 12% of athletes who underwent CCT for these indications, however in both groups (PVB and ST-segment depression) the severity of CAD increased with the rise of cardiovascular risk factors. Therefore, the systematic execution of CCT among master athletes with non-common PVBs does not seem justified, but the indication should be reserved for selected cases with cardiovascular risk factors.

A232: IMPATTO DELLA FITNESS SUL TEST CARDIOPOLMONARE NELLA CARDIOMIOPATIA IPERTROFICA: CONOSCERLO PER PRESCRIVERE ADEGUATAMENTE L'ESERCIZIO FISICO

Alex Boncompagni (a), Luna Cavigli (a), Gian Luca Ragazzoni (a), Francesca Vannuccini (a), Matteo Cameli (a), Marta Focardi (a), Giulia Elena Mandoli (a), Serafina Valente (a), Marco Bonifazi (a), Iacopo Olivotto (b), Flavio D'Ascenzi (a)
(a) DIPARTIMENTO DI BIOTECNOLOGIE MEDICHE, DIVISIONE DI CARDIOLOGIA, UNIVERSITÀ DEGLI STUDI DI SIENA; (b) CARDIOMIOPATIE UNIT, AZIENDA OSPEDALIERO UNIVERSITARIA CAREGGI, UNIVERSITÀ DEGLI STUDI DI FIRENZE

Introduzione. Recenti evidenze suggeriscono che l'attività fisica aerobica moderata ad intensità controllata possa avere un effetto favorevole sul rimodellamento cardiovascolare e nella prevenzione delle comorbidità legate alla sedentarietà anche nei pazienti con cardiomiopatia ipertrofica (CMI), in assenza di eventi avversi aritmici di rilievo. Il test cardiopolmonare rappresenta uno strumento fondamentale per la determinazione dell'intensità di esercizio, che varia molto fra un soggetto e l'altro in base alla prima e seconda soglia ventilatoria (VT1 e VT2). Pertanto, abbiamo effettuato questo studio con l'obiettivo di confrontare, tramite una valutazione con test da sforzo cardiopolmonare, i pazienti con CMI fisicamente attivi e sedentari, nell'ottica di giungere ad una prescrizione dell'esercizio fisico personalizzata, basata sui dati del singolo individuo.
Materiali e metodi. I pazienti con CMI, dopo aver eseguito valutazione cardiologica completa comprensiva di elettrocardiogramma, ecocardiogramma e Holter ECG delle 48 ore a 12 derivazioni, sono stati sottoposti a test da sforzo cardiopolmonare. I pazienti sono stati suddivisi in due gruppi: fisicamente attivi e sedentari, in base alla quantità di attività fisica praticata a settimana e negli anni passati.
Risultati. Sono stati valutati 71 pazienti (età media 39±14 anni): 33 pazienti fisicamente attivi e 38 pazienti sedentari. I dati del test cardiopolmonare hanno mostrato che i pazienti fisicamente attivi hanno raggiunto un carico di lavoro maggiore (p<0.0001), maggiori valori di consumo di ossigeno (VO2 max indicizzato, p<0.0001) e maggiori valori rispetto al predetto (p=0.01) nel confronto con i pazienti sedentari. Inoltre, i pazienti attivi hanno mostrato maggiori valori sia rispetto alla VT1 (p<0.01) che rispetto alla VT2 (p=0.001) nel confronto con i pazienti sedentari. I pazienti attivi hanno anche raggiunto una frequenza cardiaca (FC) maggiore sia alla VT1 (99 vs 94 bpm) che alla VT2 (136 vs 125 bpm, p<0.05). I pazienti sedentari hanno mostrato valori significativamente peggiori di efficienza ventilatoria (VE/VCO2 slope, 30 vs 27, p<0.01) e di carico di lavoro sia alla VT1 (81 vs 99 W, p=0.01) che alla VT2 (150 vs 186 W, p=0.001). Non si sono verificati eventi avversi significativi.
Conclusioni. I pazienti con CMI fisicamente attivi hanno mostrato una capacità cardiopolmonare funzionale migliore rispetto al gruppo dei pazienti sedentari, in assenza di eventi aritmici di rilievo. I valori di riferimento di FC per prescrivere un'appropriata intensità di esercizio sono risultati significativamente diversi fra i pazienti con CMI attivi e quelli sedentari. Pertanto, una valutazione funzionale completa con una stima oggettiva dell'intensità di esercizio appare fondamentale per prescrivere l'esercizio in maniera adeguata.

Variabile	CMI sedentari	CMI attivi	P value
VT1, ml/min	1081.1±357.9	1255.9±375.1	0.04
VT1, indicizzato mL/min/kg	13.4±4.9	16.1±5.2	0.004
VT2, ml/min	1788.5±475.8	2170.1±503.8	0.002
VT2 indicizzata, ml/min/kg	21.7±6.9	27.8±7.5	0.001
VE/VCO_2, massima	33.9±5.9	29.5±4.2	0.001

Variabile	CMI sedentari	CMI attivi	P value
Carico max, watt	178.7±44.8	223.2±45.9	≤0.0001
METS max	7.2±2.1	9.4±2.1	≤0.0001
VO_2 max, ml/min	2053.5±587.1	2569.7±516.2	0.01
VO_2 massimo indicizzato, ml/min/kg	25.2±7.4	32.9±7.4	≤0.0001
VO_2 max rispetto al predetto %	73.6±16.5	92.0±22.0	0.01

A233: PROGETTO SPREAD: LA PRATICA SPORTIVA E GLI EFFETTI SULLA BICUSPIDIA VALVOLARE AORTICA

Luna Cavigli (a), Guido Claessen (b), Emeline Van Craenenbroeck (c), Elena Cavarretta (d), Antonello D´andrea (e), Maria Sanz De La Garza (f), Thijs Eijsvogels (g), Martin Halle (i), Daniele Andreini (j), Antonella Moreo (k), Bibi Schreurs (g), Laura Stefani (l), Antonio Pelliccia (m), Flavio D'Ascenzi (a)
(a) DIPARTIMENTO DI BIOTECNOLOGIE MEDICHE, DIVISIONE DI CARDIOLOGIA, UNIVERSITÀ DI SIENA; (b) DEPARTMENT OF CARDIOVASCULAR SCIENCES, UNIVERSITY HOSPITALS LEUVEN; (c) DEPARTMENT OF CARDIOLOGY, ANTWERP UNIVERSITY HOSPITAL; (d) DEPARTMENT OF MEDICAL SURGICAL SCIENCES AND BIOTECHNOLOGIES, SAPIENZA UNIVERSITY, LATINA; (e) DEPARTMENT OF CARDIOLOGY, UMBERTO I HOSPITAL, LUIGI VANVITELLI UNIVERSITY; (f) CARDIOVASCULAR INSTITUTE, IDIBAPS, UNIVERSITY OF BARCELONA; (g) RADBOUD INSTITUTE FOR HEALTH SCIENCES, NIJMEGEN; (h) DEPARTMENT OF CARDIOLOGY, SPORTS MEDICINE CENTER, MADRID; (i) DEPARTMENT OF PREVENTION AND SPORTS MEDICINE, UNIVERSITY HOSPITAL KLINIKUM RECHTS DER ISAR, MUNICH; (j) CENTRO CARDIOLOGICO MONZINO, MILANO; (k) CARDIO CENTER DE GASPERIS, NIGUARDA HOSPITAL, MILANO; (l) SPORT MEDICINE CENTER, UNIVERSITU OF FLORENCE; (m) INSTITUTE FOR SPORTS MEDICINE AND SCIENCE, ITALIAN OLYMPIC COMMITTEE, ROMA

Introduzione. La valvola aortica bicuspide (BAV) è una condizione congenita cardiaca comune nella popolazione generale e negli atleti. Può associarsi a progressiva dilatazione aortica e a stenosi e/o insufficienza aortica. L'esercizio fisico intenso potrebbe avere un impatto negativo sulle dimensioni aortiche e sulla funzione valvolare a causa dello stress emodinamico sull'aorta durante l'esercizio. Tuttavia, i dati in letteratura sono pochi e discordanti.
Obiettivo. Lo scopo di questo studio multicentrico è stato quello di analizzare l'impatto dello sport sulle dimensioni aortiche e sulla funzione valvolare nei soggetti con BAV.
Materiali e metodi. Sono stati valutati tre gruppi: atleti con BAV, atleti con valvola aortica tricuspide (TAV) e controlli sedentari con BAV. Abbiamo valutato la morfologia e il grado di stenosi e/o insufficienza aortica, le dimensioni aortiche e le caratteristiche del ventricolo sinistro tramite ecocardiogramma. Gli individui con stenosi/insufficienza aortica moderata-severa o con dilatazione aortica marcata (>45 mm negli uomini,>41 mm nelle donne) sono stati esclusi dallo studio.
Risultati. La popolazione dello studio era costituita da 504 soggetti:186 atleti con BAV (84% maschi; età media 30±11 anni), 193 atleti con TAV (82% maschi; età media 30±11 anni), 125 controlli sedentari con BAV (82% maschi; età media 34±10 anni). I diametri aortici a livello dei seni di valsalva, della giunzione senotubulare e dell'aorta ascendente, sia in valore assoluto che indicizzati, erano minori negli atleti con TAV rispetto ai soggetti con BAV (p<0.005), ma non si sono riscontrate differenze statisticamente significative fra gli atleti con BAV e i controlli sedentari con BAV. I volumi e la massa del ventricolo sinistro erano maggiori negli atleti con BAV rispetto agli altri due gruppi (p<0.005). Inoltre, gli atleti con BAV avevano gradienti transvalvolari aortici maggiori rispetto ai controlli sedentari (p<0.005).
Conclusioni. Questo studio multicentrico ha dimostrato che gli atleti con BAV hanno diametri aortici maggiori degli atleti con TAV. Tuttavia, non si sono riscontrate differenze significative fra atleti con BAV e i controlli sedentari, suggerendo che l'esercizio fisico non ha un impatto significativo sulla dilatazione aortica. Tuttavia, la pratica sportiva sembra influenzare la funzione valvolare negli atleti con BAV, con un conseguente impatto sulla geometria del ventricolo sinistro che tende ad essere più dilatato e ipertrofico negli atleti con BAV rispetto agli altri gruppi.

A234: AORTIC ROOT DIAMETER IN HIGHLY-TRAINED COMPETITIVE ATHLETES: REFERENCE VALUES ACCORDING TO SPORT AND PREVALENCE OF AORTIC ENLARGEMENT

Emanuele Monda (a), Michele Lioncino (a), Fernando Di Paolo (b), Francesco Ferrara (c), Olga Vritz (c), Paolo Calabrò (a), Eduardo Bossone (d), Antonio Pelliccia (b), Giuseppe Limongelli (a)
(a) INHERITED AND RARE CARDIOVASCULAR DISEASES UNIT, DEPARTMENT OF TRANSLATIONAL MEDICAL SCIENCES, UNIVERSITY OF CAMPANIA "LUIGI VANVITELLI", NAPLES, ITALY; (b) INSTITUTE OF SPORT MEDICINE, ROME, ITALY; (c) HEART DEPARTMENT, UNIVERSITY HOSPITAL OF SALERNO, SALERNO, ITALY; (d) DEPARTMENT OF PUBLIC HEALTH, UNIVERSITY OF NAPLES "FEDERICO II" NAPLES, ITALY

Background. Studies exploring the extent of aortic root dilation across the different types of sport are limited. We aimed to define the physiological limits of aortic remodelling in a large population of healthy elite athletes in comparison to non-athletic controls.
Methods. 1995 consecutive athletes evaluated at the Institute of Sports Medicine (Rome, Italy) and 515 healthy controls underwent a comprehensive cardiovascular screening. The aortic diameter was measured at the level of the sinuses of Valsalva. The 99th percentile from the mean of the aortic diameter in the control population was used to define an abnormally enlarged aortic root dimension.
Results. Athletes showed a larger aortic root diameter (30.6 [±3.3] vs. 28.1 [±3.1] mm, p-value <0.001) than controls. The difference was evident in male and female athletes regardless of sport predominant component and level of intensity. The 99th percentile value for aortic root diameter in control males and females was 37 mm and 32 mm, respectively. Based on these values, 50 (4.2%) male and 21 (2.6%) female athletes would have been diagnosed with an enlarged aortic root. However, aortic root diameter of clinical relevance, i.e., ≥40 mm, was observed in only 17 male athletes (0.85%), and did not exceed>44 mm.
Conclusions. Athletes show a mild, although significant, increased aortic dimension in comparison to healthy controls. The degree of aortic enlargement varies in relation to type of sports and sex. Eventually, only a small minority of athletes exhibited a markedly enlarged aortic diameter (i.e., ≥40 mm) in a range of clinical relevance.

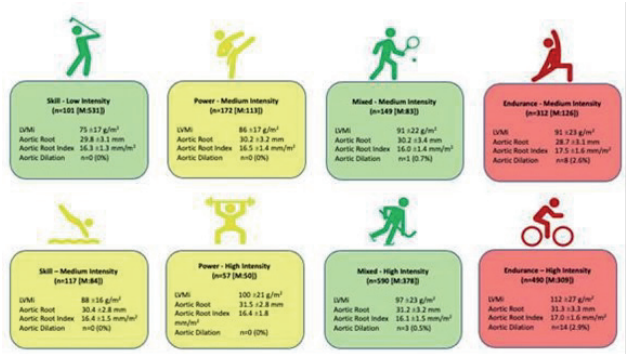

Figure. Cohort distribution and clinical characteristics according to the 2020 ESC Guidelines on sports cardiology classification based on the predominant component (skill, power, mixed and endurance) and intensity of exercise.

A235: IPERTRABECOLATURA DEL VENTRICOLO SINISTRO IN ATLETI DI ELITE:CARDIOPATIA STRUTTURALE O RIMODELLAMENTO CARDIACO FISIOLOGICO?

Sara Monosilio (a, b), Alessandro Spinelli (a), Silvia Prosperi (a, b), Erika Lemme (a), Ruggiero Mango (a), Giuseppe Di Gioia (a), Gianfranco Gualdi (a, b), Giovanni Tonti (c), Gianni Pedrizzetti (d), Maria Rosaria Squeo (a), Antonio Pelliccia (a), Viviana Maestrini (a, b)
(a) ISTITUTO DI MEDICINA E SCIENZA DELLO SPORT, CONI, ROMA; (b) SAPIENZA UNIVERSITÀ DI ROMA; (c) UNIVERSITÀ DI CHIETI; (d) UNIVERSITÀ DI TRIESTE

Background. La risonanza magnetica cardiaca (RMC), gold standard per la valutazione morfo-funzionale del cuore d'atleta, consente lo studio avanzato della funzione del ventricolo sinistro (VS) con nuovi software.
Obiettivi. Valutare la funzione del VS con RMC in atleti con ipertrabecolatura.
Materiali e metodi. 40 atleti Olimpici con ipertrabecolatura del VS sono stati suddivisi in due sottogruppi sulla base della positività dei criteri di Petersen per miocardio non compatto (Pet–/Pet+). Sono stati arruolati 20 atleti Olimpici senza ipertrabecolatura (NI) e valutate le differenze fra i tre gruppi di dimensioni e funzione ventricolare mediante parametri avanzati: strain longitudinale e circonferenziale e forze emodinamiche (HDFs, direzione apice-base, latero-settale e rapporto fra le due) mediante software dedicato.

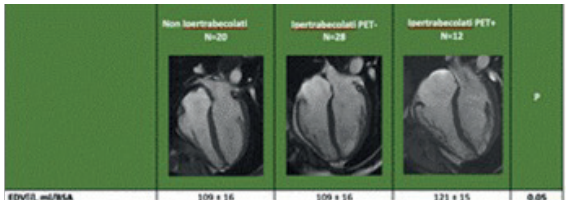

EDV, ml/BSA	109 ± 16	109 ± 16	121 ± 15	0.05
ESV, ml/BSA	47 ± 11	47 ± 9	54 ± 9	0.126
SV, ml/BSA	60 ± 8	62 ± 8	68 ± 8	0.05
EF, %	56 ± 4	57 ± 4	56 ± 3	0.448
Mass, g/BSA	67 ± 16	68 ± 18	77 ± 14	0.206
LVWT max, mm	10 ± 1	10 ± 2	10 ± 2	0.491
Sphericity Index, %	39 ± 5	41 ± 11	42 ± 11	0.379
T2 Mapping, ms	50 ± 3	51 ± 4	53 ± 3	0.174
T1 Native Myocardial Mapping, ms	945 ± 29	948 ± 30	937 ± 24	0.712
GLS, %	-22 ± 3	-22 ± 4	-23 ± 3	0.723
GCS, %	-29 ± 4	-31 ± 4	-30 ± 3	0.113
HDF AB entire, %	21 ± 4	23 ± 5	22 ± 4	0.440
HDF LS entire, %	3 ± 1	3 ± 1	3 ± 0.5	0.836
HDF ratio entire, %	14 ± 3	14 ± 4	14 ± 3	0.730
HDF AB sistole, %	35 ± 7	37 ± 7	34 ± 9	0.476
HDF LS sistole, %	4 ± 1	4 ± 1	3 ± 1	0.653
HDF ratio sistole, %	11 ± 3	11 ± 3	11 ± 4	0.717
HDF AB diastole, %	10 ± 3	12 ± 4	15 ± 8	0.035
HDF LS diastole, %	2 ± 1	3 ± 1	3 ± 1	0.827
HDF ratio diastole, %	26 ± 11	22 ± 6	20 ± 5	0.086

Risultati. Dei 40 atleti con ipertrabecolatura (25±4 anni, uomini 70%, power 17.5%, mixed 12.5% ed endurance 70%), 28 (70%) appartenevano al gruppo Pet - e 12 (30%) al Pet +. Dal confronto fra i tre gruppi sono emerse differenze riguardo dimensioni e funzione VS (Tabella): gli atleti Pet + hanno valori più elevati di volume telediastolico e stroke volume del VS, ai limiti della significatività statistica (p=0.05) e valori di HDFs apice-base in diastole più elevati (p=0.035), con rapporto diastolico più basso, seppur senza raggiungere la significatività statistica (p=0.086).
Conclusioni. Lo studio dimostra che gli atleti con ipertrabecolatura Pet + mostrano un trend per un rimodellamento ventricolare maggiore, caratterizzato da aumento volumetrico della camera e migliore funzione diastolica. Lo studio avanzato della funzione del VS potrebbe aiutare nella diagnosi differenziale tra rimodellamento fisiologico e patologico.

A236: ARITMIE VENTRICOLARI NEGLI ATLETI: CARATTERISTICHE E IMPLICAZIONI PER LO SPORT

Gian Luca Ragazzoni (a), Luna Cavigli (a), Alex Boncompagni (a), Matteo Silvestri (a), Chiara Fusi (a), Giulia Elena Mandoli (a), Maria Concetta Pastore (a), Serafina Valente (a), Matteo Cameli (a), Flavio D'Ascenzi (a)
(a) UNIVERSITÀ DI SIENA, DIPARTIMENTO DI BIOTECNOLOGIE MEDICHE, DIVISIONE DI CARDIOLOGIA

Premessa. I battiti ventricolari prematuri (BPV) sono un reperto relativamente frequente nei giovani atleti. La loro interpretazione è talvolta impegnativa perché, se da una parte possono essere presenti in soggetti sani, dall'altro posso rappresentare uno dei primi segni di patologia cardiaca. Pertanto, raccogliere ed interpretare i dati disponibili sulle caratteristiche delle BPV che correlano con patologie cardiache nella popolazione di giovani atleti appare fondamentale.
Obiettivi. Questo studio si poneva l'obiettivo di indagare le caratteristiche, la risposta all'esercizio e la distribuzione in differenti fasce d'età delle BPV in atleti agonisti afferiti al nostro centro di Cardiologia dello Sport, a seguito di riscontro di BPV durante la visita di idoneità agonistica.
Materiali e metodi. Sono stati arruolati 209 atleti afferiti al nostro centro per il riscontro di BPV durante la visita annuale per l'idoneità agonistica. Tutti i pazienti sono stati sottoposti ad esame obiettivo, ECG, monitoraggio Holter a 12 derivazioni comprensivo di seduta di allenamento ed ecocardiografia. Ulteriori indagini, tra cui la risonanza magnetica cardiaca, sono state eseguite in caso di risultati anomali alla prima valutazione o per caratteristiche specifiche dei BPV. I soggetti sono stati suddivisi in 3 fasce d'età: 0-15, 16-25 e>25 anni.
Risultati. L'età media alla prima valutazione era di 25,2±13,6 anni, 58 sportivi (27,8%) erano nella fascia 0-15 anni, 69 (33%) nella fascia 16-25 anni e 82 (39,2%) avevano più di 25 anni. La maggior parte (51,8%) degli atleti presi in esame presentava BPV con pattern di tipo non comune. Gli atleti con tale pattern si trovavano prevalentemente nella fascia di età superiore ai 25 anni (0-15: 25,5%; 16-25: 26,5%;>25: 48%). La maggioranza dei soggetti con diagnosi finale di cardiopatia strutturale (75%) presentavano una morfologia di tipo non comune. Nei pazienti di età inferiore a 25 anni più frequentemente abbiamo osservato una soppressione delle BPV sotto sforzo (72,6%, p<0.005).
Conclusioni. La morfologia prevalente nei soggetti con BPV da sforzo è di tipo non comune. Questa morfologia è tipicamente stata osservata nei soggetti che poi hanno avuto una diagnosi finale di patologia cardiaca. La prevalenza di aritmie non comuni aumenta con l'aumentare dell'età. Pertanto, il riscontro di aritmie ventricolari con caratteristiche non comuni, in particolar modo nella fascia d'età>25 anni, comporta indagini approfondite, al fine di escludere la presenza di patologia a rischio.

A237: VALUTAZIONE DEL T1 E DEL T2 MAPPING CON RISONANZA MAGNETICA CARDIACA IN UNA COORTE DI ATLETI OLIMPICI

Silvia Prosperi (a, b), Sara Monosilio (a, b), Alessandro Spinelli (a), Erika Lemme (a), Domenico Filomena (a, b), Marco Penza (c), Lucia Ilaria Birtolo (a, b), Ruggiero Mango (a), Giuseppe Di Gioia (a), Gianfranco Gualdi (a), Maria Rosaria Squeo (a), Antonio Pelliccia (a), Viviana Maestrini (a, b)
(a) ISTITUTO DI MEDICINA E SCIENZA DELLO SPORT - CONI - ROMA; (b) LA SAPIENZA - UNIVERSITÀ DI ROMA; (c) ISTITUTO DI MEDICINA SPORTIVA - MILANO

Background. La caratterizzazione tissutale senza mezzo di contrasto in risonanza magnetica cardiaca (RMC), mediante tecniche di Mapping, rappresenta uno strumento per lo studio del rimodellamento cardiaco. Ad oggi vi sono pochi dati in popolazioni di atleti.
Obiettivo. Descrivere i valori T1 e T2 mapping in una coorte di atleti olimpici e valutare l'eventuale influenza del genere e della disciplina sportiva.
Materiali e metodi. 300 atleti olimpici (13% skill, 20% power, 25% mixed, 42% endurance, 57% maschi) con screening cardiovascolare negativo e 42 controlli-sedentari sono stati sottoposti a RMC. Gli atleti sono stati divisi in base al genere e alla disciplina sportiva secondo la classificazione ESC.
Risultati. Gli atleti di endurance presentano valori più bassi di T1 Mapping nativo (p<0.001). Non vi sono differenze di T2 Mapping tra atleti e sedentari (0.472). Gli atleti uomini con massa indicizzata del ventricolo sinistro (LV-Massi) più elevata mostrano valori più bassi T1 Mapping nativo (p=0.006) e valori di T2 Mapping non differenti significativamente (p=0.150). Le atlete con LV-Massi più elevata non presentano differenze significative (T1 Mapping nativo p=0.053; T2 Mapping p=0.438).
Conclusioni. Nel gruppo degli atleti, il T1 Mapping nativo ha mostrato differenze significative in base al genere e alla disciplina sportiva, a conferma che il rimodellamento miocardico fisiologico si associa ad un relativo decremento della quota miocardica extracellulare. Il T2 Mapping sembra essere meno influenzato da queste variabili.

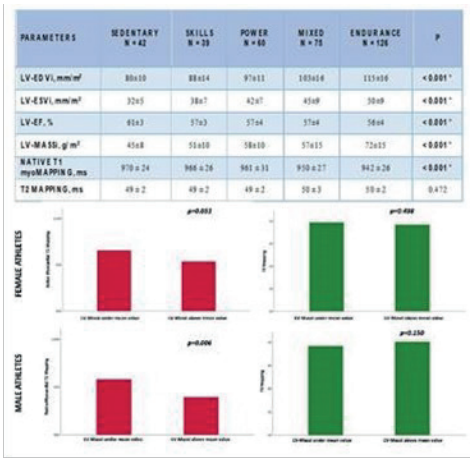

PARAMETERS	SEDENTARY N = 42	SKILLS N = 30	POWER N = 60	MIXED N = 75	ENDURANCE N = 125	P
LV-EDVI, mm/m²	80±10	88±14	97±11	103±16	115±16	<0.001*
LV-ESVI, mm/m²	32±5	38±7	42±7	45±8	50±9	<0.001*
LV-EF, %	61±3	57±3	57±4	57±4	56±4	<0.001*
LV-MASSi, g/m²	45±8	51±10	58±10	57±15	72±15	<0.001*
NATIVE T1 myoMAPPING, ms	970 ± 24	966 ± 26	961 ± 31	950 ± 27	942 ± 26	<0.001*
T2 MAPPING, ms	49 ± 2	49 ± 2	49 ± 2	50 ± 3	50 ± 2	0.472

A238: ESERCIZIO FISICO E SCOMPENSO CARDIACO: RELAZIONE TRA AUMENTO DEI CARICHI ALLENANTI E PROGNOSI

Barbara Barra (a), Flaviano Giorgiano (a), Laura Merlo (a), Cinzia Pegoraro (a), Teresina Vessella (a), Giulia Meneguzzo (a), Lisa Munari (a), Alessandra Patelli (a), Matteo Pizzolato (a), Mauro Ramigni (b), Patrizio Sarto (a)
(a) U.O.C. MEDICINA DELLO SPORT, AULSS2 MARCA TREVIGIANA, CENTRO DI RIFERIMENTO REGIONALE PER LO SPORT NEI GIOVANI CON CARDIOPATIA; (b) UOSD EPIDEMIOLOGIA AULSS2 MARCA TREVIGIANA

Obiettivi. Lo scopo di questo lavoro era valutare se l'aumento del carico di allenamento aerobico avesse un impatto sulla prognosi in un gruppo di pazienti con scompenso cardiaco cronico (SCC) sottoposti a un programma di allenamento supervisionato.
Materiali e metodi. Nel periodo 2009-2023 abbiamo sottoposto ad un periodo di training supervisionato (3 sedute a settimana per 8 settimane), un gruppo di 83 pazienti (89% maschi, età media 59.8 ± 11.6 anni) affetti da disfunzione ventricolare sinistra (FE<50%). Per la determinazione del carico allenante è stata utilizzata la relazione tra la concentrazione di acido lattico capillare e la frequenza cardiaca durante sforzo. Il training aerobico è stato eseguito ad un'intensità corrispondente a 2-2,5 mmol/L di acido lattico ed è stato valutato l'adattamento all'allenamento seduta per seduta (aumento di carico a parità di lattato). Infine, è stato registrato il numero di eventi cardiovascolari maggiori o trapianto cardiaco avvenuti durante un follow-up di 3.5 anni.
Risultati. I "responder" rispetto ai "NON responder" sono più giovani (età media di 57.8 vs 66.7 anni; p=0.02) e hanno una capacità funzionale migliore (VO2 di picco di 17.1 vs 13.2 ml/kg/min; p=0.003). I soggetti classificati come "responder" presentano un incremento medio dei carichi allenanti di 15.6 ± 6.6 Watt, mentre i soggetti definiti come "NON responder" di 1.35 ± 2.1Watt (p<0.001). Dopo follow-up di 3.5 anni, i "NON responder" hanno una prognosi peggiore (Fig.1), con un rischio di evento di 11 volte superiore (p<0.001).
Conclusioni. La mancata risposta adattativa all'aumento dei carichi allenanti rappresenta un ulteriore fattore prognostico negativo nei pazienti affetti da SCC e può aiutare a discriminare i pazienti che necessitano di una rivalutazione, anche finalizzata all'indicazione a trapianto cardiaco.

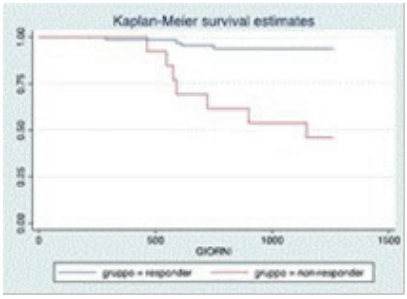

Figura 1. Curva di sopravvivenza

A239: RIMODELLAMENTO CARDIACO ESTREMO IN ATLETI OLIMPICI DI ENDURANCE: ANALISI DELLA DEFORMAZIONE MIOCARDICA E DELLE FORZE EMODINAMICHE

Sara Monosilio (a, b), Silvia Prosperi (a, b), Alessandro Spinelli (a), Erika Lemme (a), Ruggiero Mango (a), Giuseppe Di Gioia (a), Gianfranco Gualdi (a, b), Giovanni Tonti (c), Gianni Pedrizzetti (d), Maria Rosaria Squeo (a), Antonio Pelliccia (a), Viviana Maestrini (a, b)
(a) ISTITUTO DI MEDICINA E SCIENZA DELLO SPORT, CONI, ROMA; (b) SAPIENZA UNIVERSITÀ DI ROMA; (c) UNVIERSITÀ DI CHIETI; (d) UNIVERSITÀ DI TRIESTE

Background. La deformazione miocardica (MD) del ventricolo sinistro e la stima delle forze emodinamiche (HDFs) sono degli strumenti diagnostici emergenti. Non esistono dati sulla popolazione di atleti, in particolare di endurance, il cui rimodellamento cardiaco può presentare problemi di diagnosi differenziale con le cardiomiopatie.
Obiettivi. Descrivere la MD e HDFs negli atleti olimpici di endurance e le possibili relazioni con la geometria del ventricolo sinistro.
Materiali e metodi. 109 atleti olimpici di endurance (62% maschi; 26±5 anni) con screening cardiovascolare negativo e 21 soggetti sedentari sono stati sottoposti a Risonanza Magnetica Cardiaca. Le immagini SSPF-Cine sono state post-processate per il calcolo dello strain longitudinale e circonferenziale (GLS e GCS) e delle HDFs mediante un software dedicato. Gli atleti sono stati suddivisi in base all'indice di sfericità 3D (<40% or ≥40%).
Risultati. 61 (56%) atleti hanno mostrato un indice di sfericità ≥40%, volumi ventricolari maggiori e frazione di eiezione più bassa rispetto a quelli con indice di sfericità <40% e ai controlli (Figura). Non vi sono state differenze tra atleti e controlli nel GLS e GCS e nella distribuzione delle HDFs; gli atleti con ventricolo più globoso hanno mostrato un rapporto diastolico paragonabile a quello degli atleti con indice di sfericità inferiore e dei controlli.
Conclusioni. I parametri di deformazione miocardica e le forze emodinamiche non differiscono tra atleti e sedentari e tra atleti con e senza alterata geometria. I parametri avanzati di funzione cardiaca sono un potenziale strumento per differenziare il rimodellamento cardiaco fisiologico e patologico.

PARAMETRI	CONTROLLI SEDENTARI N = 21	ATLETI CON INDICE DI SFERICITA' <40% N = 48	ATLETI CON INDICE DI SFERICITA' ≥40% N = 61	P
LVEDVI, ml/m2	81±11	109±15	119±16	<0,001
LVESVI, ml/m2	31±5	47±9	52±9	<0,001
LVEF, %	61±3	57±3	56±4	<0,001
LV-GLS, %	-23 ± 5	-22 ± 3	-22 ± 3	0,356
LV-GCS, %	-33 ± 4	-31 ± 4	-30 ± 4	0,103
LS/AB HDFs ratio entire,-	14,3 ± 4,1	14,7 ± 2,9	14 ± 3	0,456
LS/AB HDFs ratio systole,-	11,5 ± 2,8	11,6 ± 3,7	10,6 ± 3,2	0,284
LS/AB HDFs ratio diastole,-	21 ± 10	23 ± 8	23 ± 7	0,619

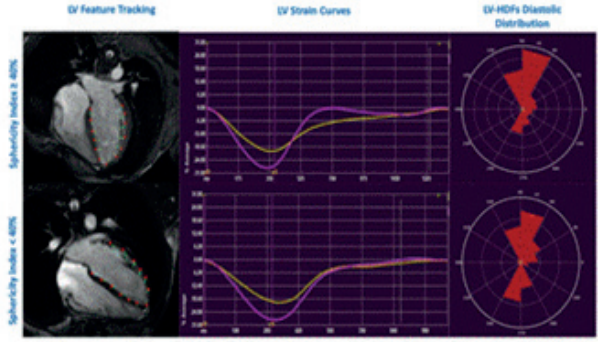

A240: ANALISI DELL'ADATTAMENTO DEL VENTRICOLO DESTRO ALL'ALLENAMENTO DI ALTA INTENSITÀ IN ATLETI OLIMPICI MEDIANTE RISONANZA MAGNETICA CARDIACA

Sara Monosilio (a, b), Silvia Prosperi (a, b), Alessandro Spinelli (a), Erika Lemme (a), Giuseppe Di Gioia (a), Ruggiero Mango (a), Gianfranco Gualdi (a, b), Gianni Pedrizzetti (d), Giovanni Tonti (c), Maria Rosaria Squeo (a), Antonio Pelliccia (a), Viviana Maestrini (a, b)
(a) ISTITUTO DI MEDICINA E SCIENZA DELLO SPORT, CONI, ROMA; (b) SAPIENZA UNIVERSITÀ DI ROMA; (c) UNIVERSITÀ DI CHIETI; (d) UNIVERSITÀ DI TRIESTE

Background. I dati disponibili sulla deformazione miocardica riguardano principalmente il ventricolo sinistro. I dati sul ventricolo destro (VD) sono pochi e non vi sono valori di riferimento specifici negli atleti.
Obiettivi. Descrivere la deformazione del VD con risonanza magnetica cardiaca (RMC) in atleti Olimpici e valutare le possibili differenze in base al genere e alla disciplina sportiva.
Materiali e metodi. 265 atleti olimpici (15% skill, 19% power, 25% mixed, 41% endurance; 58% maschi) con screening cardiovascolare negativo e 21 controlli-sedentari sono stati sottoposti a RMC. Le immagini SSFP-Cine sono state post-processate per valutare lo strain longitudinale globale (GLS) del VD mediante un software dedicato. Gli atleti sono stati suddivisi in base al sesso, alla classificazione ESC degli sport e all'ingrandimento del VD (RVEDV/LVEDV>1 o ≤1).
Risultati. Gli atleti di endurance mostrano un rimodellamento maggiore del VD rispetto agli altri sport ed ai sedentari (Figura). Non vi sono differenze nella frazione di eiezione tra le diverse categorie di sport, ma solamente tra atleti e controlli. Il GLS del VD è minore tra gli atleti di endurance e i controlli-sedentari. Infine, le atlete mostrano valori più negativi di GLS del VD rispetto agli atleti maschi. Non sono state osservate differenze di GLS tra atleti con e senza dilatazione del VD (Figura).
Conclusioni. Gli atleti di endurance mostrano un maggiore rimodellamento del ventricolo destro e valori più bassi di GLS dell'intera popolazione atletica e dei sedentari, rientrando comunque nel range dei valori normali. Non sono state osservate differenze tra atleti con RV dilatato e non dilatato.

PARAMETRI	SEDENTARI N = 21	SKILL N = 39	POWER N = 51	MIXED N = 66	ENDURANCE N = 109	P
RV-EDVI, mm/m²	88 ± 16	88 ± 16	98 ± 12	101 ± 19	115 ± 17	< 0,001*
RV-ESVI, mm/m²	31 ± 10	38 ± 9	43 ± 7	45 ± 10	51 ± 11	< 0,001*
RV-EF, %	62 ± 4	57 ± 4	56 ± 4	56 ± 4	56 ± 4	< 0,001*
RV-GLS, %	-25 (-28;-22)	-24 (-21;-26)	-23 (-21;-26)	-23 (-21;-27)	-22 (-24;-20)	0,039*

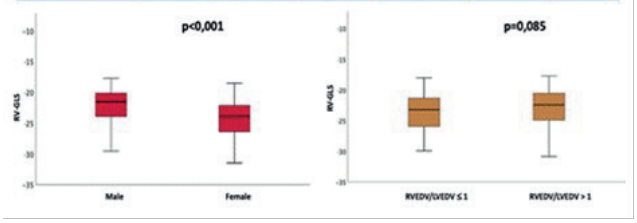

A241: UN CASO DI AORTA QUADRICUSPIDE IN GIOVANE ATLETA

Paolo Alberto Gasparini (c), Eleonora Rodighiero (a, b), Elisa Lodi (a, b), Maria Grazia Modena (a, b)
(a) CENTRO P.A.S.C.I.A. (PROGRAMMA ASSISTENZIALE SCOMPENSO CARDIACO, CARDIOPATIE DELL'INFANZIA E A RISCHIO); (b) AOU POLICLINICO DI MODENA - UNIVERSITÀ DI MODENA E REGGIO EMILIA - SCUOLA DI SPECIALIZZAZIONE IN MEDICINA DELLO SPORT E DELL'ESERCIZIO FISICO; (c) AOU POLICLINICO DI MODENA - UNIVERSITÀ DI MODENA E REGGIO EMILIA

Introduzione. La valvola aortica quadricuspide (VAQ) è una condizione congenita rara riscontrata molto meno frequentemente rispetto alla valvola aorta bicuspide o unicuspide. La maggior parte dei casi viene diagnosticata incidentalmente durante interventi chirurgici o studi autoptici ove l'incidenza riportata è <0.01%. Il miglioramento delle tecniche di imaging probabilmente condurrà ad una sempre maggior incidenza di tale reperto. Dal punto di vista anatomico, la classificazione di Hurwitz e Roberts distingue sette varianti anatomiche di VAQ a seconda della morfologia e delle dimensioni delle cuspidi. Nella maggioranza dei casi la VAQ rappresenta una anomalia congenita isolata, seppur talvolta possa associarsi ad anomalie delle arterie coronarie, del diametro del vaso aortico e della funzione della valvola aortica stessa. Uno studio morfo-funzionale evolutivo risulta dunque indicato nei soggetti con VAQ. Le implicazioni prognostiche di suddetto riscontro possono talvolta suscitare dubbi nei genitori e nel pediatra, soprattutto in merito alla possibilità per il bimbo di eseguire attività fisica, la frequenza del follow-up e la necessità di profilassi antibiotica.
Presentazione del caso. Giungeva alla nostra attenzione un ragazzo di dieci anni, maschio, inviato dal medico dello sport ad eseguire visita cardiologica pediatrica per il riscontro di battiti ectopici sopraventricolari al test da sforzo eseguito per rilascio di idoneità alla pratica sportiva agonistica (pallavolo). Non elementi di rilievo alla anamnesi personale e familiare, ottimale il compenso cardiocircolatorio. All'ecocardiogramma transtoracico riscontro di VAQ, normofunzionante, regolare il diametro dell'aorta toracica ove esplorabile, osti coronarici normoposizionati, non elementi morfo-funzionali di rilievo a carico dei restanti apparati valvolari e delle camere cardiache. A completamento diagnostico veniva eseguito HolterECG con documentazione di extrasistolia sopraventricolare isolata in assenza di forme aritmiche complesse. Il soggetto non aveva mai lamentato alcuna sintomatologia, veniva quindi rilasciata idoneità alla pratica sportiva anche agonistica con indicazione a follow up ecocardiografico periodico.
Conclusioni. Il riscontro di VAQ isolata rappresenta un evento tanto raro quanto interessante nella pratica clinica. Tale riscontro, non preclude lo svolgimento di attività fisica anche agonistica in caso di buona funzionalità cardiaca e mancanza di difetti associati di per sé controindicanti l'attività sportiva. Non è generalmente indicato alcun trattamento farmacologico terapeutico e/o profilattico. Vista la natura congenita della anomalia e la potenziale evolutività risulta comunque prudente eseguire screening nei familiari di primo grado e follow-up clinico-strumentale del soggetto affetto.

A242: TROPPO SPORT FA MALE? UN CASO DI ALLUNGAMENTO DEL QT CORRELATO ALL'ECCESSIVA ATTIVITÀ FISICA IN ATLETA D'ELITE.

Davide Avenoso (a, b), Federica De Vecchi (a), Gabriele Dell´era (a), Chiara Ghiglieno (a), Matteo Santagostino (a), Giuseppe Patti (a, b)
(a) AOU MAGGIORE DELLA CARITÀ DI NOVARA; (b) UNIVERSITÀ DEGLI STUDI DEL PIEMONTE ORIENTALE 'AMEDEO AVOGADRO'

Introduzione. Negli ultimi anni la pratica sportiva è in aumento. I cardiologi italiani, per valutare l'idoneità degli atleti, si attengono al protocollo del COCIS e alle linee guida europee. Entrambi i documenti segnalano come non idonei alla pratica sportiva gli atleti con allungamento del QT all'ECG. Tale reperto è una condizione patologica associata ad aritmie ventricolari maligne e arresto cardiaco. Le cause di QT allungato possono essere congenite, le cosiddette sindromi del QT allungato (LQTS), o indotte da farmaci, patologie o disionie.
Case report. Ragazzo di 37 anni senza fattori di rischio ne famigliarità per morte improvvisa. Sempre asintomatico per cardiopalmo o sincopi, eseguiva periodicamente visite per ottenere l'idoneità sportiva. Praticava attività fisica a livello agonistico con allenamenti intensi (nuoto, corsa e ciclismo per un totale di più di 10 ore/settimana). Durante l'ultima valutazione riscontro all'ECG di QT allungato (>500msec). Escluse cause iatrogene (disionie, farmaci o disfunzione epato-renale e tiroidea), si richiedeva Test Ergometrico e Holter ECG a 12 derivazioni. AL TE costante presenza di valori di QTc allungati che non si normalizzavano durante sforzo e all'Holter si confermava il QT allungato soprattutto nelle ore notturne. Ecocardiogramma nella norma. Veniva quindi costretto a un completo detraining e si avviava bassa dose di nadololo, titolato alle successive visite. Venivano inoltre eseguiti prelievi per la ricerca di mutazioni genetiche. Tre mesi dopo si è assistito a normalizzazione dei valori di Qtc. Alla luce della negatività delle ricerche genetiche e dell'assenza di altre cause è stata proposta graduale ripresa dell'attività fisica con attenta monitorizzazione inizialmente con ECG Holter e test ergometrico e successivamente con impianto di loop recorder (Biomonitor III-Biotronik) con monitoraggio remoto e calcolo del OT mensilmente al termine dell'allenamento. Attualmente il Qtc si mantiene in range. Il paziente è asintomatico, in terapia con nadololo e pratica allenamenti trisettimanali non superando le 8 ore a settimana.
Discussione. L'allungamento del QT può essere para-fisiologico negli atleti d'élite. Un QTc compreso tra 480 e 500 msec rappresenta la zona grigia tra patologico e fisiologico. In questi casi fondamentale è la storia familiare ed eventuale sintomatologia sincopale. Quando il Qtc risulta maggiore di 500msec, una volta escluse le cause farmacologica e genetica, la gestione deve sposare la necessità di prevenire aritmie con la capacità di non patologizzare persone sane. Attualmente la gestione di questi pazienti prevede il de-training e il watch and wait. Nel nostro caso, vista la completa normalizzazione del valore e l'assenza di una causa precisa se non l'eccessivo stress fisico, abbiamo concesso la ripresa controllata e graduale dell'attività fisica con un monitoraggio costante. Sulla base di studi che hanno dimostrato come il Qtc calcolato dall'EGM registrato tramite un Biomonitor III si sovrapponibile a quello ottenuto con un ECG tradizionale, abbiamo optato per eseguire l'impianto di tale dispositivo così da ridurre i controlli eseguiti in office, ma ottenendo valori di QT in tempo reale. Contemporaneamente il loop recorder ci permette di monitorizzazione possibili aritmie. Nei casi di QT allungato correlati ad intensa attività fisica questa potrebbe dimostrarsi una strategia vincente.

A243: LACK OF EXPECTED CARDIAC REMODELLING IN ELITE ENDURANCE ATHLETES: A PARAMETER FOR TAILORED TRAINING AND POTENTIAL PERFORMANCE IMPROVEMENT?

Giuseppe Di Gioia (a), Simone Pasquale Crispino (b), Sara Monosilio (a), Viviana Maestrini (a), Antonio Nenna (b), Maria Rosaria Squeo (a), Erika Lemme (a), Antonio Pelliccia (a)
(a) ISTITUTO DI MEDICINA E SCIENZA DELLO SPORT, COMITATO OLIMPICO NAZIONALE ITALIANO, C.O.N.I.; (b) FONDAZIONE POLICLINICO CAMPUS BIO-MEDICO, ROMA

Introduction. Cardiac remodelling varies according to sports discipline, with endurance typically leading to eccentric hypertrophy (EH). However, a subset of endurance athletes does not exhibit the acknowledged remodelling, raising concerns about suboptimal fitness and training programmes.
Aim. To identify elite endurance athletes who lack specific cardiac remodelling and introduce echocardiographic remodelling as a parameter to assess training status.
Methods. 1,738 elite athletes participating in various sports disciplines were enrolled and submitted to clinical evaluation, ECG, echocardiogram and exercise stress test within three months before international events.
Results. EH was found to be the most prevalent type of remodelling, particularly among endurance athletes, in both males (67%, p=0.001) and females (68.5%, p=0.001). A significant proportion of endurance athletes exhibited normal geometry (98 athletes, 31.4%) associated with peculiar morphological differences, including reduced left ventricular size, lower ventricular mass and wall thickness. Concordant remodelling was observed in the right heart sections and reduced functional parameters were noted at stress tests, including lower maximum Watts and higher heart rates.
Conclusions. These results highlight the high proportion of elite endurance athletes with a lack of expected eccentric hypertrophy, emphasizing the complex relationship between cardiac remodelling, functional parameters, and athletic performance. The absence of expected cardiac remodelling among endurance athletes may serve as a guiding factor for personalized training programs. By integrating echocardiographic cardiac parameters with athlete performance and training data, a comprehensive evaluation can be achieved, facilitating the implementation of targeted training strategies to optimize athletic performance.

A244: RUOLO DEL COUNSELLING MEDICO SULLA CONSAPEVOLEZZA ED ADERENZA DEL PAZIENTE\EX-ATLETA AFFETTO DA CARDIOPATIA

Teresina Vessella (a), Cinzia Pegoraro (a), Laura Merlo (a), Flaviano Giorgiano (a), Giulia Meneguzzo (a), Barbara Barra (a), Alessandra Patelli (a), Matteo Pizzolato (a), Patrizio Sarto (a)
(a) UOC MED SPORT AULSS2 TREVISO. CENTRO DI RIFERIMENTO REGIONALE PER LO SPORT NEI GIOVANI CON CARDIOPATIE

Introduzione. La diagnosi di una patologia cardiovascolare rappresenta un importantissimo stressor nella vita di un paziente. Negli atleti però, oltre la diagnosi, il motivo principale di stress è spesso rappresentato dalla conseguenza più visibile e più immediata che questa diagnosi comporta: la non idoneità all'agonismo. Comprendere ed accettare questa nuova realtà rappresenta un tassello fondamentale per l'aderenza di questi pazienti. Per questo motivo il counselling medico è una tappa fondamentale all'interno del nostro progetto "Il secondo tempo di Julian Ross".
Casi clinici. Presentiamo la storia di due ciclisti, il primo affetto da cardiomiopatia ipertrofica ed il secondo affetto da cardiomiopatia aritmogena. Al momento della nostra valutazione, ad entrambi era stata comunicata la diagnosi presso altra sede. Durante il colloquio, i due atleti mostravano scarsa consapevolezza della patologia di cui erano affetti e soprattutto, entrambi, erano estremamente resistenti nell'accettare i limiti sull'attività fisica da praticare, perché non ne avevano compreso le motivazioni e perché da sempre asintomatici. Il nostro counselling, durato circa un'ora, ha determinato per entrambi il passaggio da una fase precontemplativa ad una fase contemplativa. Il paziente con cardiomiopatia ipertrofica è subito passato ad una successiva fase di azione riuscendo ad adattare i suoi allenamenti alle indicazioni fornite. Anche nel follow-up ha confermato la sua aderenza tramite l'invio mensile delle schede dettagliate delle sue uscite in bici attraverso dispositivo Polar. Il secondo paziente, dopo un iniziale rifiuto e un mese circa di fase di determinazione, ci ha contattati per iniziare il percorso supervisionato presso la nostra struttura, comunicandoci di aver deciso di acquistare una bici elettrica (strategia di adattamento identificata al counselling), supportato nella decisione dagli amici che avevano deciso di fare altrettanto (importanza del supporto sociale).
Conclusioni. La nostra esperienza e questi due esempi nello specifico, ci dimostrano che un corretto counselling può determinare una migliore consapevolezza del paziente, creare una sinergia medico-paziente ed una base per una migliore aderenza e per la determinazione di schemi di allenamenti compatibili con la patologia e graditi all'ex atleta.

A245: INFLUENCE OF THE TYPE OF DISABILITY AND SPORTING DISCIPLINE ON LIPID PROFILE IN A COHORT OF ITALIAN PARALYMPIC ATHLETES

Giuseppe Di Gioia (a), Federica Coletti (b), Lorenzo Buzzelli (b), Viviana Maestrini (a), Sara Monosilio (a), Andrea Segreti (b), Maria Rosaria Squeo (a), Erika Lemme (a), Antonio Nenna (b), Antonio Pelliccia (a)
(a) ISTITUTO DI MEDICINA E SCIENZA DELLO SPORT, COMITATO OLIMPICO NAZIONALE ITALIANO, C.O.N.I.; (b) FONDAZIONE POLICLINICO CAMPUS-BIO MEDICO, ROMA

Introduction. Dyslipidemia is the most frequent cardiovascular risk factor in able-bodies athletes and is frequently undertreated, resulting in an underestimated risk of atherosclerosis-related diseases. Data on lipid profile in Paralympic athletes are lacking.
Objective. To identify the prevalence of dyslipidemia and the influence of disability type and sporting discipline in Paralympic athletes.
Methods. We evaluated 289 athletes who participated at Paralympic Games from London 2012 to Beijing 2022. All athletes underwent: clinical\physical evaluation, blood tests and body composition analysis. They were divided into different groups based on sports disciplines and disability type (spinal and non-spinal cord injuries, respectively SCI and NSCI).
Results. Among Paralympic athletes, 34.6% had low-density lipoprotein (LDL) ≥115 mg/dL. They were older (38.1±9.2 vs 30.6±9.6, p=0.001) and with higher cardiovascular risk. SCI athletes showed similar total cholesterol (TC) and triglycerides (TG), higher LDL (110.9±35.2 vs 102.7±30.6 mg/dL, p=0.03) and lower high-density lipoprotein (HDL) (53.6±13.6 vs 60.5±15.4 mg/dL, p=0.001) compared to NSCI. Endurance athletes had lower LDL, the highest HDL and the lowest TG and LDL/HDL ratio compared to other sports disciplines. A mean follow-up of 61.5±30.5 months was available in 47% athletes and 72.7% of the dyslipidemic athletes continued to present altered LDL values at follow-up.

Conclusions. Dyslipidaemia is the most common cardiovascular risk factor in Paralympics, affecting 35% of athletes, with only mild lipid changes over a medium-term time. Type of disability and sporting discipline impact on lipids, improving HDL and reducing LDL, with a better profile observed in NSCI and endurance athletes, respectively.

A246: CARDIOPULMONARY CAPACITY EVALUATION AFTER AN ATHLETE'S INJURY

Andrea Segreti (a, b), Chiara Fossati (b), Maria Tea Mulè (a), Valerio Fanale (a), Simone Pasquale Crispino (a), Federica Coletti (a), Francesco Rosario Parisi (c, d), Biagio Zampogna (c, d), Sebastiano Vasta (c, d), Elena Mannacio (e), Rocco Papalia (c, d), Raffaele Antonelli Incalzi (f), Fabio Pigozzi (b), Francesco Grigioni (a)
(a) UNIT OF CARDIOVASCULAR SCIENCES, FONDAZIONE POLICLINICO UNIVERSITARIO CAMPUS BIO-MEDICO; (b) DEPARTMENT OF MOVEMENT, HUMAN AND HEALTH SCIENCES, UNIVERSITY OF ROME "FORO ITALICO"; (c) RESEARCH UNIT OF ORTHOPAEDIC AND TRAUMA SURGERY, DEPARTMENT OF MEDICINE AND SURGERY, UNIVERSITÀ CAMPUS BIO-MEDICO DI ROMA; (d) RESEARCH UNIT OF ORTHOPAEDIC AND TRAUMA SURGERY, FONDAZIONE POLICLINICO UNIVERSITARIO CAMPUS BIO-MEDICO; (e) CENTRE FOR EXERCISE SCIENCE AND SPORTS MEDICINE, UNIVERSITY OF ROME "FORO ITALICO"; (f) UNIT OF GERIATRICS, FONDAZIONE POLICLINICO UNIVERSITARIO CAMPUS BIO-MEDICO

Background. An athlete's career inevitably goes through periods of forced physical exercise interruption like a knee injury. The period elapsing after the injury provides an ideal model for evaluating the effects of decreased physical activity on the pulmonary and cardiovascular systems.
Methods. We evaluated 20 competitive and non-competitive athletes aged 18-65 (mean age 35.7±13.4), involved in prevalently aerobic or alternate aerobic/anaerobic sports activities, affected by a knee pathology requiring surgery. The enrolled patients' demographic characteristics and resting vital signs are reported in the Table. In particular, the athletes were evaluated before surgery at rest by trans-thoracic echocardiography, including global longitudinal strain (GLS) and myocardial work (MW) assessments, and during exercise by cardiopulmonary exercise testing (CPET).
Results. The percent-predicted peak oxygen consumption (peak VO_2%) was 84.5±14.7%, the mean respiratory exchange ratio was 1.17 ± 0.07, and the mean ventilation/carbon dioxide (V_E/VCO_2) slope was 25.0 ± 3.4. Furthermore, peak VO_2% positively correlated with percent-predicted forced vital capacity (r=0.699, p=0.001) and forced expiratory volume in the first second (r=0.582, p=0.007). Moreover, peak VO_2% negatively correlated with GLS (r=-0.534, p=0.015) and positively correlated with global wasted work (r=-0.468, p=0.038). Finally, we found a positive correlation between global work efficiency and V_E/VCO_2 slope during exercise (r=-0.611, p=0.004). The Figure depicts the correlations between MW and CPET parameters.
Conclusions. Our study evidenced that, in deconditioned athletes before knee surgery, maximal CPET is a feasible assessment and allows a comprehensive functional evaluation. In addition, we evidenced that the MW indices obtained at rest could predict exercise capacity and ventilatory efficiency as evaluated by CPET. Therefore, these data open significant possibilities in evaluating athletes in the detraining and retraining phases after an injury.

A247: VALUTAZIONE CLINICA ED ECG TRAMITE UTILIZZO DI DEEP LEARNING PER ABILITAZIONE AGONISTICA: VALETUDO TRIAL

Davide Marchetti (a), Matteo Schillaci (a), Michele Gallazzi (a, b), Riccardo Terzi (a, b), Edoardo Conte (a, b), Daniele Andreini (a, b)
(a) IRCCS OSPEDALE GALEAZZI-SANT'AMBROGIO; (b) UNIVERSITÀ DEGLI STUDI DI MILANO

Si tratta di uno studio monocentrico, osservazionale, prospettico. Prevediamo di arruolare una popolazione consecutiva di 966 atleti (138 della coorte di validazione e 828 del set di allenamento) presso i centri dove opera l'equipe di Cardiologia dello Sport afferente all'IRCSS Ospedale Galeazzi Sant'-Ambrogio, per accertamenti in merito al rilascio dell'idoneità agonistica. Tali soggetti formeranno la popolazione di calibrazione del test. Il modello AI richiede un allenamento per poter essere calibrato. Ci sarà quindi una prima fase di allenamento del sistema. Gli atleti saranno valutati secondo le linee guida attuali e il COCIS con i test diagnostici richiesti caso per caso. Al termine della valutazione cardiologica gli atleti potranno essere considerati "idonei" o "non idonei" all'attività agonistica. Sottoporremo gli ECG degli atleti "idonei" e "non idonei", discriminati secondo questi due gruppi, a un algoritmo di deep learning per allenare il sistema di intelligenza artificiale. Sarà poi reclutata una popolazione di atleti consecutivi per formare il set di validazione del test. Sottoporremo al modello di intelligenza artificiale gli ECG degli atleti del set di validazione per valutare accuratezza, sensibilità, specificità, valore predittivo positivo, valore predittivo negativo e AUC nel discriminare gli atleti giudicati "idonei" da quelli giudicati "non idonei" all'attività agonistica dopo gli approfondimenti cardiologici. Per la popolazione di validazione verranno effettuati follow up telefonici a 6 e 12 dall'arruolamento. Sono previsti benefici indiretti per la prevenzione cardiovascolare degli atleti che potrebbero beneficiare di un algoritmo di intelligenza artificiale che possa aiutare i clinici nella valutazione per l'idoneità agonistica e riconoscere precocemente segni di malattia cardiaca. Non sono previsti ne rischi ne benefici diretti sui soggetti arruolati in questo studio osservazionale in quanto i soggetti arruolati seguono i protocolli attuali di valutazione medica per idoneità agonistica.

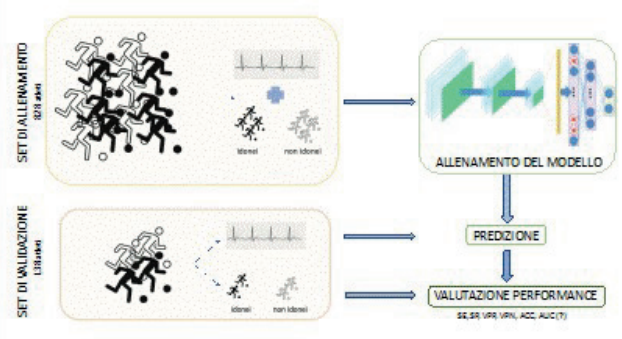

A248: CORONARY ARTERY DISEASE IN ATHLETES: A CHALLENGING DIAGNOSIS IN PEOPLE WHO CHALLENGE

Simona Minardi (a, b), Francesco Ceravolo (b), Alessandro Appetecchia (c), Arianna Di Molfetta (b), Marco Cesario (b), Pasquale Mollo (b), Giancarlo Di Ruzza (b), Luigi Sciarra (a), Silvio Romano (a), Maurizio Menichelli (b)
(a) UNIVERSITY OF L'AQUILA, L'AQUILA, ITALY; (b) CARDIOLOGY DEPARTMENT, FABRIZIO SPAZIANI HOSPITAL, FROSINONE, ITALY; (c) UNIVERSITY BIOMEDICAL CAMPUS, ROME, ITALY

Introduction. Physical activity is effective to prevent coronary artery disease (CAD) by means of several mechanism among which by reducing the incidence of common cardiovascular risk factors. Anyway, CAD is still the first cause of sudden cardiac death among athletes, especially over 35-years old (master athletes). MI type I, typically associated with atherosclerosis is just one of the possible mechanisms. Other common causes of MI in athletes include plaque erosion, spontaneous coronary artery dissection, chest trauma, abnormalities of the coronary arteries, coronary artery spasm, hypercoagulability, left ventricular hypertrophy, and anabolic steroids use. We present the case of a 50-year-old male amateur athlete, no traditional risk factors, or a family history of CAD, who experience a myocardial infarction (MI) after intense exercise, likely due to the erosion of a not significant atherosclerotic plaque of the left anterior descending coronary artery.
Case report. A 50-years-old male amateur athlete was evaluated for an acute chest pain occurred in the morning after a long cycling (135 km). He was on therapy with acetylsalicylic acid since a PFO closure for paradoxical embolism and proton pump inhibitors for gastroesophageal reflux, no history of cardiovascular diseases, no cardiovascular risk factors. A first electrocardiogram (ECG), performed by ambulance, showed sinus rhythm, normal atrioventricular and intraventricular conduction, borderline ST-elevation in V5-V6. Arrived in ER the pain was almost totally regressed as well as the ECG abnormalities. Arterial pressure was 160/100 mmHg, so a nitrate therapy was set. Echo-fast showed heart chambers of normal size and function, LVEF 60% without regional contractility abnormalities. He denies any pain under exertion, even that morning. The first cardiac troponin dosage was slightly increased and remained stable at the second and third determinations. The patient, now in good general condition, did not complain any recurrence of pain. Doubts arose that troponin increase could be secondary to strenuous exercise and pain of non-cardiac origin. Anyway, considering the alterations, albeit minimal, of the ECG during pain, the patient was admitted to cardiology department and the day after he underwent coronary angiography that showed an ulcerated plaque on proximal left anterior descending coronary artery. A percutaneous coronary artery intervention with a drug eluting stent implantation was successfully performed. The patient, asymptomatic started a double antiplatelet, hypolipidemic and antihypertensive therapy and continued observation the absence of complications.
Conclusions. Although less common than in the general population, MI is a possible occurrence especially among master athletes. Possible mechanisms of MI, other than type I, include several situations not necessarily associated to common cardiovascular risk factors. Furthermore, due to the possible atypical presentation and confounding factors, the disease identification may be challenging in this cohort of patients. It is necessary to keep all this in mind in order not to miss an important diagnosis.

A249: DUE ANNI DI ESPERIENZA DEL CENTRO REGIONALE PER LO SPORT NEI GIOVANI CON CARDIOPATIE. ANALISI DI CRITICITÀ E BARRIERE

Teresina Vessella (a), Laura Merlo (a), Flaviano Giorgiano (a), Cinzia Pegoraro (a), Barbara Barra (a), Giulia Meneguzzo (a), Giovanna Biasi (a), Vanessa Cavasin (a), Lisa Munari (a), Alessandra Patelli (a), Matteo Pizzolato (a), Patrizio Sarto (a)

(a) UOC MED SPORT AULSS2 TREVISO. CENTRO DI RIFERIMENTO REGIONALE PER LO SPORT NEI GIOVANI CON CARDIOPATIE

Introduzione. Questo studio ha l'obiettivo di identificare le criticità del nostro programma di presa in carico clinica-psicologica-sportiva di giovani pazienti/ex-atleti giudicati non idonei allo sport agonistico a seguito della diagnosi di patologie cardiache potenzialmente a rischio di morte improvvisa (MI).

Casistica. In questi due anni sono afferiti al nostro Centro 92 pazienti (30 dichiarati non idonei presso il nostro servizio) con età media 28 aa +\- 17. Di questi 71 (76%) hanno deciso di aderire al percorso. Tra i pazienti che hanno seguito il percorso, 7 hanno abbandonato il programma di prescrizione al follow up.

Le criticità maggiormente riscontrate sono le seguenti:

- **Psicologiche e motivazionali**
  - Difficoltà nel raggiungere una completa consapevolezza della patologia
  - Problematiche psicologiche connesse con la diagnosi e la non idoneità
  - Difficoltà nell'accettazione della terapia quando necessaria
  - Aderenza alla prescrizione da parte del paziente
  - Mancato gradimento dell'attività fisica prescritta
- **Cliniche**
  - Difficoltà da parte del medico nella comunicazione di diagnosi e prognosi
  - Difficoltà nella corretta determinazione delle intensità di allenamento
  - Influenza dell'orario della terapia sulle frequenze di allenamento
  - Difficoltà nel Monitoraggio dell'attività prescritta
- **Organizzative**
  - Difficoltà nel testare e monitorare tutti i tipi di attività prescrivibili
  - Resistenza da parte delle società sportive ad accettare il rientro di questi ex atleti senza il certificato agonistico

L'identificazione di questi "limiti" ci ha permesso di adattare e modificare in itinere le fasi del progetto riducendo nell'ultimo anno il numero di mancate adesioni e dropout.

Conclusioni. La prescrizione dell'esercizio fisico negli atleti affetti da patologie a rischio di morte improvvisa rappresenta una sfida per il futuro. Oltre ad una conoscenza dettagliata delle patologie cardiache ed una corretta stratificazione del rischio, è tuttavia fondamentale lavorare sulla consapevolezza del paziente e considerare una serie di aspetti psicologici, motivazionali, logistici atti ad ottimizzare l'aderenza di questi ex-atleti, per evitare che la lettera di prescrizione non si traduca in qualcosa di non attuabile, non compreso e quindi non seguito.

CARDIOLOGIA INTERVENTISTICA, CORONARICA E STRUTTURALE

A250: HOW TO PREVENT LVOT OBSTRUCTION IN VALVE IN RING PROCEDURE: THE TRANSSEPTAL BATMAN PROCEDURE

Matteo Saccocci (a), Paolo Denti (a), Nicola Buzzatti (a), Pamela Gatto (a), Guido Ascione (a), Davide Margonato (b), Eustachio Agricola (b), Francesco Maisano (a)
(a) HEART VALVE CENTER -DEPARTMENT OF CARDIAC SURGERY - IRCCS SAN RAFFAELE HOSPITAL, MILAN (IT); (b) DEPARTMENT OF CARDIOVASCULAR IMAGING - IRCCS SAN RAFFAELE HOSPITAL, MILAN (IT)

g A middle-aged woman, who underwent CABG and mitral valve annuloplasty 14 years ago, was admitted to our hospital due to worsening heart failure symptoms. She was affected by chronic renal failure, polivasculopathy, and porcelain aorta. Due to paroxysmal atrial fibrillation, she needed LAA occlusion because of contraindication to anticoagulant therapy. She had a history of Hodgkin Lymphoma treated with chemotherapy and radiotherapy. After Heart Team multidisciplinary discussion, she was proposed for transcatheter ViR. Preoperative CT-Scan and echocardiography highlighted a high risk of LVOT obstruction (LVOT-O) due to a prominent septum and an unfavorable mitro-aortic angle. To avoid complex and demanding procedures, as LAMPOON, we decide to perform a trans-septal double-wire BATMAN valve in ring implantation, a procedure that as to date been performed only transapically. The procedure was carried out under general anesthesia, with TEE and fluoroscopic guidance. To maintain hemodynamic stability, an IABP was employed. An inferior-posterior transseptal puncture was performed to advance an Agilis NxT Mid curve (Abbott- Chicago, IL, US) and an MP catheter into the left atrium. Under echocardiographic guidance, the center of the anterior leaflet was perforated using an electrified standard 0.035" straight tip guidewire. The MP catheter was pushed into the LV and replaced with a 7F-90cm sheath over a BackUp Meier supportive guide. The 7F-sheath was then used to advance a second BackUp Meier wire in LV. Over one of the supportive wire, a 14F PTA balloon (Armada 14F-Abbott, Chicago, IL, USA) was used to perform septostomy and then was parked in the left atrium (LA) ready to perform anterior leaflet traslocation. Over the second BackUP Meier a Sapien 3 Ultra (Edwards Lifesciences Inc, Irvine, USA) delivery system was advanced in the inferior vena cava, over the septum, reaching the LA. The anterior leaflet was predilated with the Armada Balloon; the S3 delivery system was advanced through the anterior leaflet under stable hemodynamics, and the valve was successfully delivered under rapid pacing. The AML's engagement, ballooning, and translocation were clearly visible on echo and fluoro imaging. 3D and 2D echocardiography were used to continuously monitor LVOT obstruction. The TEE pictures revealed a THV that engaged the LVOT with the stent almost in touch with the septum but with no LVOT-O thanks to the free-flow region created by the completely translocated AML. This is case confirms the efficacy of BATMAN procedure in preventing LVOTO. The Transseptal approach that we present, permits a less complex and invasive procedure. The use of two parallel guidewires across the AML (buddy wire BATMAN) permits a smooth transition between anterior leaflet ablation and THV insertion while maintaining hemodynamic stability and avoiding the need for mechanical extracorporeal support.

A251: LEFT VENTRICLE STRAIN PATTERNS AND REMODELLING AFTER TRANSCATHETER AORTIC VALVE REPLACEMENT-INDUCED LEFT BUNDLE BRANCH BLOCK

Dario Tino Bertolone (a, b, d), Monika Shumkova (a), Giulia Botti (a), Marta Belmonte (a, b, e), Michele Mattia Viscusi (a, b), Emanuele Gallinoro (c), Pasquale Paolisso (b, c), Chiara Valeriano (a, b), Esposito Giuseppe (b), Matteo Spreca (d), Sofie Verstreken (a), Jozef Bartunek (a), Martin Penicka (a), Francesco Luigi Rotolo (d), Francesco Monti (d), Emanuele Barbato (e), Marc Vanderheyden (a)
(a) CARDIOVASCULAR CENTER OLV AALST, BELGIUM; (b) DEPARTMENT OF ADVANCED BIOMEDICAL SCIENCES, UNIVERSITY OF NAPLES, FEDERICO II; (c) DIVISION OF UNIVERSITY CARDIOLOGY. IRCCS OSPEDALE GALEAZZI SANT'AMBROGIO. MILAN, ITALY; (d) SAN PIETRO FATEBENEFRATELLI HOSPITAL, ROME, ITALY; (e) DEPARTMENT OF CLINICAL AND MOLECULAR MEDICINE, SAPIENZA UNIVERSITY OF ROME, ITALY

Background and Aim. Transcatheter aortic valve replacement (TAVR) is known to potentially lead to conduction abnormalities, including the development of left bundle branch block (LBBB). Recently a staging classification, based on strain patterns has identified 4 distinct patterns of left ventricle (LV) remodeling and dysfunction in patients with LBBB and septal flash (SF). In this study we assess the LV strain patterns in patients with newly developed LBBB following TAVR and investigate how these patterns evolve during follow-up. We also aim to determine the correlation between these strain patterns and the extent of LV remodeling and dysfunction.

Methods. We included all consecutive patients diagnosed with severe aortic stenosis who developed new-onset LBBB following TAVR, admitted to the Cardiovascular Center at OLV Hospital in Aalst, Belgium, between January 2018 and May 2022. Baseline echocardiography was performed to assess conventional echocardiographic parameters and to calculate the LV strain pattern. These assessments were repeated at discharge after valve implant and during the follow-up period to evaluate any changes after the development of TAVR-induced LBBB.

Results. A total of 52 patients with available strain analysis data at baseline, discharge, and FU were included in the study. The patients were divided into two groups based on their LBBB strain patterns, those with a non-changing or improving pattern (LBBB-pattern=/+) [N=42], and those with a worsening pattern (LBBB-pattern -) [N=10]. At baseline, patients in the LBBB-pattern - versus the LBBB pattern=/+ exhibited larger LVEDVi (76.52 ± 29.50 vs 56.19 ± 18.82; p=0.009), and LVESVi (39.28 ± 20.90 vs 26.18 ± 15.40; p=0.029), higher E/e ratio (28.32 ± 18.59 vs 19.0 ± 8.76; p=0.027), higher levels of NT-pro-BNP (6234.5 ± 7043.62 vs 2310.95 ± 2009.12; p=0.009), and lower LVEF (46.80 ± 9.77 vs 54.02 ± 9.77; p=0.041). During the follow-up echocardiographic evaluation, no statistically significant differences were observed between the two groups in terms of LVEDVi, LVESVi, LV mass index, E/e ratio and LVEF. However, patients in the LBBB-pattern - group had a significantly lower proportion of patients with LVEF>50% [4 (40.0) vs 34 (81.0); p=0.016] and exhibited reduced GLS (-13.2 ± 2.90 vs -17.5 ± 2.96; p=0.001) compared to patients in the LBBB-pattern=/+.

	LBBB-pattern - (N=10)	LBBB-pattern =/+ (N=42)	p-value
LVEDVi	76.52±29.50	56.19±18.82	0.009
LVESVi	39.28±20.90	26.18±15.40	0.029
LV mass index	150.53±40.90	131.18±41.48	0.190
E/e'	28.32±18.59	19.0±8.76	0.027
NT-proBNP	6234.5±7043.62	2310.95±2009.12	0.009
LVEF	46.80±9.77	54.02±9.77	0.041
LVEF>50%	3 (30.0)	31 (73.8)	0.022
GLS	-13.08±4.50	-16.04±4.73	0.075

Baseline characteristics of patients with stable/improving LBBB-pattern and patients with worsening LBBB-pattern from discharge to follow-up.

	LBBB-pattern – (N=10)	LBBB-pattern =/+ (N=42)	p-value
LVEDVi	63.40±26.15	60.36±20.49	0.702
LVESVi	34.88±21.62	26.75±15.12	0.184
LV mass index	123.89±25.46	117.83±26.58	0.545
E/e'	22.67±8.31	19.77±7.75	0.310
LVEF	47.8±12.86	53.43±8.60	0.099
LVEF>50%	4 (40.0)	34 (81.0)	**0.016**
GLS	-13.2±2.90	-17.5±2.96	**0.001**

FU echocardiographic characteristics of patients with non-chancing/improving LBBB-pattern and patients with worsening LBBB-pattern from discharge to FU.

LBBB-patterns progression between discharge and follow-up.

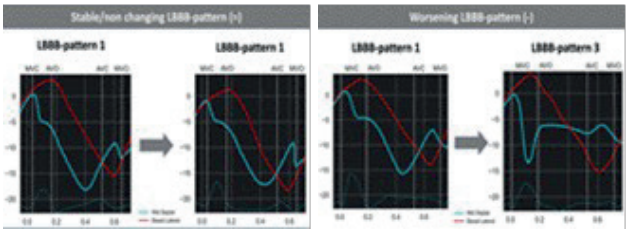

Stable/non changing and worsening LBBB strain patterns.

Conclusions. In patients with severe AS who develop persistent LBBB after TAVR, those with impaired baseline echocardiographic characteristics, are more likely to exhibit a worsening LV strain pattern at follow-up. However, despite the association between a worse LV strain pattern and a higher risk of adverse remodeling and LV dysfunction, our study population did not experience this outcome. This suggests that TVAR is effective and that TAVR-induced LBBB has a relatively benign nature. However closely monitoring of patients with a worsened LV strain pattern through regular echocardiographic follow-up is advisable to detect early signs of adverse remodeling and progression of LV dysfunction.

A252: BEYOND THE DECADE: LONG-TERM OUTCOMES OF PFO CLOSURE FROM THE ITALIAN PROLONG REGISTRY

Carlo Gaspardone (a, b), Lorenzo Zaccaria (a, b), Paolo Costa (b), Davide Antonio Morciano (a, b), Gianluca Ricchetti (a, b), Michele Morosato (a, b), Matteo Montorfano (c), Antonio Mangieri (d), Antonio Colombo (d), Achille Gaspardone (e), Cosmo Godino (a)
(a) CARDIOLOGY UNIT, SAN RAFFAELE HOSPITAL, MILAN, ITALY; (b) VITA-SALUTE SAN RAFFAELE UNIVERSITY, MILAN, ITALY; (c) INTERVENTIONAL CARDIOLOGY UNIT, SAN RAFFAELE HOSPITAL, MILAN, ITALY; (d) CARDIO CENTER, IRCCS HUMANITAS RESEARCH HOSPITAL, ROZZANO, MILAN, ITALY; (e) CARDIOLOGY UNIT, OSPEDALE SANT'EUGENIO, ROME, ITALY

Background. Despite the rising employment of transcatheter device closure for Patent Fossa Ovalis (PFO) in prevention of cryptogenic stroke or Transient Ischemic Attack (TIA), limited data exist on its long-term outcomes. Given this context, the aim of the present national registry is to shed light on the long-term (>10 years) clinical outcomes of patients who have undergone PFO closure.

Methods. We conducted a multi-center retrospective cohort study, enrolling consecutive adult patients who underwent PFO device closure from 2004 to 2013 form the italian PROLONG (PFO tRanscatether Occlusion Long-term Outcomes National Group) registry, involving 18 tertiary centers in Italy. We collected demographic, clinical, procedural, and follow-up data from electronic health records and telephone interviews.

Results. Our study included 249 patients (mean age 48±13 years; 45% female) with a mean follow-up (FU) duration of 14.3±1.7 years (all patients had at least ten years FU). Cryptogenic stroke was the predominant indication for PFO closure (52% of patients), followed by TIA (41%). Successful device implantation was achieved in 98% of cases, with the Amplatzer Septal Occluder (77%) being the most used device. Four cases of intra-procedural atrial fibrillation (AF) and two device embolization were reported, but no procedure-related deaths occurred. Recurrent stroke and/or TIA were reported in 13 patients (5.2% of patients). Patients who experienced recurrent events were older and had a higher rate of cardiovascular risk factors than those who did not. The presence of residual shunt was not a predictor of recurrent events. Eleven new onset cases of AF were documented during follow-up, four of which occurred within three months post-procedure. Remarkably, 79% of patients with migraines reported symptom improvement during follow-up.

Conclusions. Transcatheter PFO closure is an effective strategy with high success rates, low complications, and favorable long-term outcomes for prevention of recurrent embolic events.

Follow-up in progress. Our present findings account for 249 patients. The process of gathering complete follow-up data is ongoing. We anticipate presenting the full dataset, which is expected to include around 400-500 patients, at the upcoming SIC Congress.

A253: EFFICACY OF "PHYSIOLOGY-GUIDED PCI" USING PRESSURE CATHETER IN COMPARISON TO CONVENTIONAL PRESSURE WIRES: A MULTICENTR RETROSPECTIVE ANALYSIS

Gianluca Anastasia (a, b), Domenico Galante (c, d), Simone Biscaglia (e), Rocco Vergallo (a, b), Federico Di Giusto (h), Stefano Migliaro (g), Edoardo Petrolati (c, f), Andrea Viceré (c, f), Davide Scancarello (e), Andrea Marrone (e), Filippo Maria Verardi (e), Giorgia Campaniello (c), Chiara Giuliana (c, f), Ciro Polio Benvenuto (c, f), S. Todisco (c, f), V. Viccaro (c, f), Francesco Burzotta (c, f), Cristina Aurigemma (c, f), Enrico Romagnoli (c, f), Carlo Trani (c, f), Italo Porto (a, b), Gianluca Campo (e), Antonio Maria Leone (c, d)
(a) DIPARTIMENTO DI MEDICINA INTERNA, UNIVERSITÀ DI GENOVA; (b) UNITÀ DI MALATTIE CARDIOVASCOLARI, IRCCS POLICLINICO SAN MARTINO GENOVA; (c) UNIVERSITÀ CATTOLICA DEL SACRO CUORE ROMA; (d) CENTRO DI ECCELLENZA IN SCIENZE CARDIOVASCOLARI OSPEDALE FATEBENEFRATELLI ISOLA TIBERINA, GEMELLI ISOLA ROMA; (e) UNITÀ DI CARDIOLOGIA AZIENDA OSPEDALIERO UNIVERSITARIA DI FERRARA; (f) DIPARTIMENTO DI SCIENZE CARDIOVASCOLARI, FONDAZIONE POLICLINICO AGOSTINO GEMELLI IRCCS ROMA; (g) AURELIA HOSPITAL ROMA; (h) OSPEDALE C. E G. MAZZONI ASCOLI PICENO

Background. Emerging data support the use of physiological assessment after PCI in order to detect suboptimal results, guide optimization manoeuvres and finally reduce cardiovascular events. However, its routine use is still limited for the perception of an increased complexity of the procedure.

Aims. We tested if the use of a monorail pressure catheter on a workhorse wire by reducing the complexity of the procedure can increase the actual number of post-PCI physiological assessments and finally the physiological and clinical result in comparison to conventional pressure wires.

Methods. From the PROPHET-FFR and Ferrara registries we extrapolated patients in which PCI was physiologically indicated. Patients were divided in two groups: the pressure catheter group (PC) and the pressure wire group (PW). Primary endpoint was the rate of post-PCI functional evaluation. Secondary endpoints are the number of optimizations, the final FFR value. A propensity score matching based analysis was also performed to reduce the possible effect of demographic bias.

Results. A total of 460 patients and 479 lesions were available for the analysis. Rate of post-PCI physiological assessment was significantly higher in the PC group (84.7% vs 40.9% PW, p<0.01) as well as the number of optimization manoeuvres (53.4% PC vs 28.8% PW, p<0.01). This resulted in higher final FFR and ΔFFR values in the PC group in comparison to the PW group (0.90±0.04 vs 0.88±0.04, p=0.056, 0.15±0.09 vs 0.11±0.06 p<0.01). These results were confirmed at propensity score matching based analysis. Explorative clinical follow-up showed better trend free-survival MACE KM in PC group (p=0.07) and significative better clinical outcome in patients with final FFR value ≥0.86 (median follow-up 12 months, p=0.04).

Conclusions. The use of pressure catheters appears to provide procedural advantages, resulting in increased rates of post-PCI physiological reassessments, physiology-guided optimizations and finally to an improved physiological result compared to conventional pressure wires.

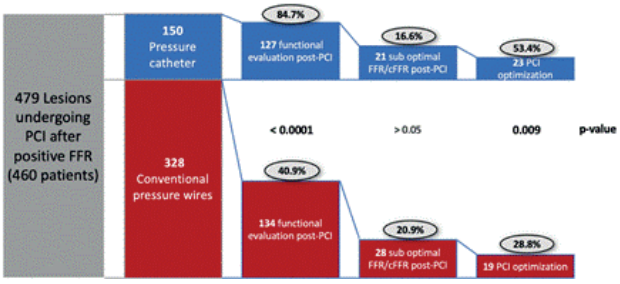

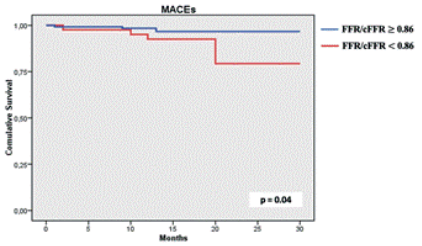

A254: COMPREHENSIVE ASSESSMENT OF EPICARDIAL AND MICROVASCULAR CORONARY DISEASE THROUGH ANGIOGRAPHY, WITH CORRELATION TO NON INVASIVE MYOCARDIAL STRESS IMAGING

Francesco Della Mora (a), Leonardo Portalan (a), Stefano Andreaggi (a), Marco Biasin (a), Gabriele Pesarini (a), Domenico Tavella (a), Elvin Tafciu (a), Caterina Maffeis (a), Giovanni Benfari (a), Dimitrios Terentes Printios (c), Antonio Maria Leone (b), Flavio Luciano Ribichini (a), Roberto Scarsini (a)
(a) UNIVERSITÀ DI VERONA; (b) POLICLINICO UNIVERSITARIO GEMELLI; (c) UNIVERSITY OF ATHENS

Introduction. There is a significant difference between coronary angiography and non-invasive myocardial stress imaging (NSI) when it comes to detecting myocardial ischemia in patients with clear coronary arteries. However, the potential of a comprehensive angiography-based assessment, which considers both the epicardial and microcirculatory aspects of the heart, in characterizing myocardial ischemia, as defined by NSI, remains unexplored. This research aims to determine if a detailed examination of heart blood vessels, encompassing both surface and deep vessels, can provide a better understanding and diagnosis of heart muscle issues such as reduced blood supply, compared to standard evaluations.
Methods and Results. In a retrospective analysis across multiple centers, 917 coronary vessels within 319 patients underwent both invasive coronary angiography (CA) and NSI. Quantitative Flow Ratio (QFR) and angiography-derived Index of Microcirculatory Resistance (IMRangio) analyses were conducted offline to estimate coronary epicardial and microcirculatory function. NSI detected myocardial ischemia in 76.5% of cases. IMRangio values were elevated (36 [22-50] vs. 29 [21-41], p<0.001), and QFR values were reduced (0.92 [0.78-0.99] vs. 0.97 [0.91-0.99], p<0.001) in vessels supplying ischemic myocardial territories. The diagnostic accuracy of QFR was moderate (AUCROC 0.632 [95% CI 0.589-0.674], p<0.0001). However, it substantially improved in patients with normal microcirculatory function (AUCROC=0.726 [95% CI 669-784], p<0.0001; p-value for AUCROC comparison=0.009).
Conclusions. The combined assessment of QFR and IMRangio outperforms separate evaluations, effectively identifying the primary cause of myocardial ischemia in most patients with positive NSI. This method could help us better understand myocardial ischemia.

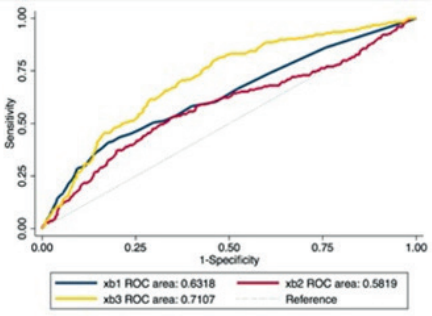

Figure 1. Incremental diagnostic performance of combined epicardial and microvascular assesment.

A255: PERCUTANEOUS CORONARY INTERVENTION FOR LEFT MAIN DISEASE IN HIGH BLEEDING RISK: OUTCOMES FROM A SUBANALYSIS OF THE DELTA 2 REGISTRY

Giulia Botti (a), Francesco Federico (a), Emanuele Meliga (b), Joost Daemen (c), Fabrizio D´ascenzo (d), Davide Capodanno (e), Didier Tchetche (f), Nicolas Van Mieghem (c), Sunao Nakamura (g), Corrado Tamburino (e), Roxana Mehran (h), Matteo Montorfano (a, i), Alaide Chieffo (a, i)
(a) UNIVERSITÀ VITA-SALUTE SAN RAFFAELE; (b) OSPEDALE CARDINAL MASSAIA, ASTI; (c) THORAXCENTER, ERASMUS UNIVERSITY MEDICAL CENTER, ROTTERDAM; (d) A.O.U CITTÀ DELLA SALUTE E DELLA SCIENZA, TORINO; (e) A.O.U. POLICLINICO G. RODOLICO-SAN MARCO, CATANIA; (f) CLINIQUE PASTEUR, TOULOUSE; (g) NEW TOKYO HOSPITAL, MATSUDO; (h) ICAHN SCHOOL OF MEDICINE AT MOUNT SINAI, NEW YORK; (i) IRCCS OSPEDALE SAN RAFFAELE, MILANO

Introduction. High bleeding risk (HBR) can represent a challenge, especially in patients with complex coronary lesions undergoing PCI. This study aims at investigating the prevalence of HBR in a wide and comprehensive cohort of patients undergoing left main (LM) PCI, describing their clinical phenotype, and reporting their procedural outcomes.
Methods. The analysis was performed on data from the DELTA (Drug Eluting Stent for Left Main Coronary Artery) 2 Registry, which prospectively included patients who underwent LM PCI at 19 centers worldwide. The patients were defined to be at HBR if ≥1 Major Criteria or ≥2 Minor Criteria from the Academic Research Consortium (ARC) were met. The primary endpoint was a composite of all-cause death, myocardial infarction (MI) or stroke at median follow-up.
Results. A total of 1531 patients were included, the rate of HBR was 65.8%. Besides the different clinical characteristics embedded in the ARC definition, HBR had higher prevalence of acute coronary syndrome (ACS) at presentation (49.2% vs 26.8%, p<0.001), and experienced higher in hospital mortality (1.8% vs 0.2%; p=0.029) and MI (5.0% vs 2.1%, p=0.009). The median follow-up was 473 days. The rate of the primary endpoint was more than three times higher in HBR patients (20.8% vs 6.1%; HR 3.3; 95% CI: 2.2-4.8), and significantly driven by all cause death (16.2% vs 4.6%; HR: 3.3; 95% CI:2.2-5.1) and MI (5.8% vs 1.9%; HR 2.9; 95% CI: 1.5-5.7). Conversely no significant difference was reported in terms of target lesion revascularization (TLR) probable or defined stent thrombosis.
Conclusions. HBR patients undergoing LM PCI experienced higher rates of all cause death and MI at follow-up; similar outcomes were also reported in-hospital.

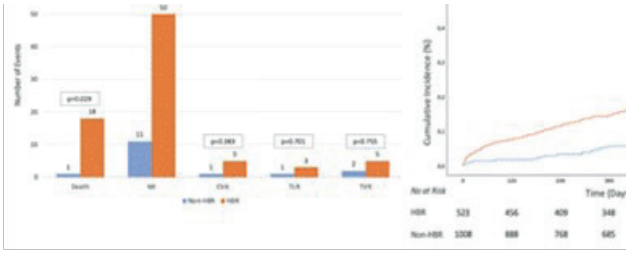

A256: PSYCHIATRIC DRUG USE AND CORONARY MICROVASCULAR DYSFUNCTION: ARE WE FACING A NOVEL RED FLAG?

Giulia Botti (a), Michele Mattia Viscusi (b), Marta Belmonte (b), Dario Tino Bertolone (b), Emanuele Gallinoro (c), Eric Wyffels (b), Bernard De Bruyne (b), Emanuele Barbato (d), Alaide Chieffo (a, e), Marc Vanderheyden (b)
(a) UNIVERSITÀ VITA-SALUTE SAN RAFFAELE, MILANO; (b) CARDIOVASCULAR CENTER AALST, OLV CLINIC, AALST; (c) OSPEDALE GALEAZZI, MILANO; (d) UNIVERSITÀ LA SAPIENZA, ROMA; (e) IRCCS OSPEDALE SAN RAFFAELE, MILANO

Background. Chronic Psychosocial Stress (CPS) is a recognized non-traditional risk factor for ischemia with non-obstructive coronary artery disease (INOCA). The use of psychiatric drugs (PDs) could be a surrogate to identify affected patients. The aim of this study is to investigate the prevalence of PD use among INOCA patients and to analyze association with INOCA endotypes and recurrence of angina at follow up (FU).
Methods. All consecutive patients admitted to a single center for INOCA invasive workup were retrospectively included in this study (Fractional Flow Reserve-FFR>0.8) and screened for use of PDs. Patients underwent invasive microvascular dysfunction investigation with continuous thermodilution and were eventually diagnosed with Coronary Microvascular Dysfunction (CMD), defined as Coronary Flow Reserve (CFR) <2.5. Consultation reports were screened for recurrent angina complaints at FU.
Results. 171 patients were included in the analysis, the prevalence of PD use was 29.8%. Patients taking PDs were more frequently female (54.9% vs 38.3%, p=0.045), and were more often already treated with first line antianginal drugs (58.8% vs 26.7%, p<0.001). Upon invasive microvascular workup, patients taking PDs had a lower CFR (2.47 ± 0.74 vs 2.81 ± 0.83, p=0.012) and were more frequently diagnosed with CMD (58.8% vs 42.5%, p=0.049). At FU, recurrence of angina was comparable between the two groups.
Conclusions. Consistently with available data on CPS, patients taking PDs were more likely to be affected by CMD. However, the use of such medications was not associated with a reduction of angina recurrence at follow-up.

	Psychiatric Drugs n=51 (29.8)	No Psychiatric Drugs n=120 (70.2)	p-Value
Hemodynamic Parameters			
Resting Flow	87.1 ± 31.8	81.6 ± 27.5	0.248
Resting Resistance	1084.6 ± 410.0	1141.7 ± 384.9	0.385
Hyperemic Flow	203.6 ± 62.1	219.7 ± 71.1	0.162
Hyperemic Resistance	431.7 ± 154.5	393.6 ± 130.7	0.100
FFR	0.86 ± 0.04	0.85 ± 0.04	0.346
CFR	2.47 ± 0.74	2.81 ± 0.83	**0.012**
MRR	2.83 ± 0.84	3.27 ± 0.98	**0.006**
CMD	30 (58.8)	51 (42.5)	**0.049**

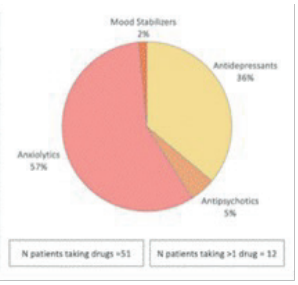

A257: UN COMPLESSO CASO DI INOCA IN CATH LAB

Marcello Cosenza (a), Riccardo Colombi (a), Federico Biondi (d), Eustachio Agricola (a, d), Massimo Slavich (c), Andrea Cesari (a), Matteo Montorfano (a, b)
(a) UNIVERSITÀ VITA-SALUTE SAN RAFFAELE, MILANO, IT; (b) UNITÀ OPERATIVA DI EMODINAMICA E CARDIOLOGIA INTERVENTISTICA, IRCCS OSPEDALE SAN RAFFAELE, MILANO, IT; (c) UNITÀ OPERATIVA DI CARDIOLOGIA CLINICA, IRCCS OSPEDALE SAN RAFFAELE, MILANO,IT; (d) UNITÀ DI IMAGING CARDIOVASCOLARE, IRCCS OSPEDALE SAN RAFFALE, MILANO, IT

Donna di 63 anni, dislipidemica. Giunge per storia di dolore toracico oppressivo a irradiazione tipica, con episodi sia a riposo che da sforzo, esacerbati al mattino dopo il risveglio e "a frigore". In passato Test da sforzo al cicloergometro negativo per sintomi e positivo per modificazioni del tracciato ECG diagnostiche di ischemia inducibile, per il quale era stata sottoposta a coronarografia presso altro Centro risultata negativa per coronaropatia ostruttiva. Nel sospetto di malattia del microcircolo coronarico (MVD) era stata impostata terapia antianginosa empirica con Ranolazina, con parziale beneficio sui sintomi. Si presentava nel nostro Centro per visita cardiologica e dato il persistere della sintomatologia veniva titolata la terapia con Ranolazina (750 mg x 2/die) e si introduceva in terapia Verapamil (40 mg x 3/die) nel sospetto di associata componente vasospastica suggerita dal dato anamnestico. In tale occasione veniva richiesto ECG Holter delle 24 ore con riscontro successivo di molteplici episodi di sottoslivellamento orizzontale del tratto ST (max 3 mm), per lo più al risveglio, in assenza di aritmie significative. Si decideva pertanto di sottoporla a nuova coronarografia per lo studio della fisiologia coronarica. All'angiografia veniva confermata l'assenza di coronaropatia ostruttiva epicardica con riscontro contestuale di multiple fistole ad origine dal sistema coronarico sinistro e comunicanti con la cavità ventricolare sinistra (Figura 1). Dopo induzione di iperemia massimale si confermava il sospetto clinico di malattia del microcircolo coronarico (FFR 0.95; CFR 1.3, IMR 33, RRR 1.7) (Figura 2). Veniva effettuato anche test provocativo per vasoreattività con acetilcolina intracoronarica (2–20–100–200 mcg) che, compatibilmente con il sospetto clinico di angina vasospastica, è risultato positivo per comparsa di spasmo epicardico a carico di IVA medio–distale, concomitante angor e alterazioni ischemiche ECG (sottoslivellamento del tratto ST). Regressione con somministrazione di nitrati intracoronarici. Dato il quadro clinico–strumentale, si poneva diagnosi di angina mista per combinazione di tre meccanismi: malattia del microcircolo, vasospasmo epicardico, fenomeno di furto coronarico per estesa fistolizzazione coronarica. Terapia finale con Ranolazina e Dilitiazem con beneficio clinico.

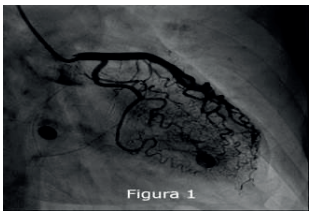

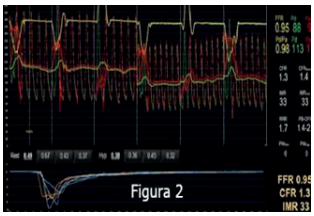

A258: TAKOTSUBO SYNDROME: DEMOGRAPHIC, CLINICAL AND ANGIOGRAPHIC CHARACTERISTICS FINDINGS IN A UNIVERSITY HOSPITAL

Dyovane Lopes (a), Paula Santiago Teixeira (a), Carolina Suzuki (a), Joyce Yamamoto (a), José Augusto Marcondes (a), Adriano H. P. Barbosa (a), Gustavo Rocha Feitosa Santos (a), Adriano Caixeta (a)
(a) ESCOLA PAULISTA DE MEDICINA - UNIVERSIDADE FEDERAL DE SÃO PAULO

Introduction. Takotsubo syndrome (TTS) or stress cardiomyopathy is an acute cardiac syndrome resulting from an increase in circulating catecholamines after physical or emotional stress situations. Approximately 1-3% of suspected cases of acute coronary syndrome undergoing angiography are identified with TTS. However, TTS is still a poorly described disease in the form of case series in our setting.
Objectives. To describe the demographic, clinical, and angiographic characteristics findings of patients with TTS in a university hospital.
Methods. A retrospective and prospective data of patients with TTS were collected from 2009 to 2023.
Results. 23 patients with TTS (83% women, mean age 62.85 ± 13.4 years) were included. Regarding associated comorbidities, 52% presented hypertension, 10% diabetes, 17% depression, 10% atrial fibrillation (AF), and 13% oncologic disease. As a triggering factor, 26% presented physical stress as the origin, 22% emotional stress, and 40% had an undetermined trigger. According to the classification of the international Takotsubo registry (InterTAK), type I represented 22%, IIa 22%, IIb 3%, and III 53% of cases. Apical involvement predominated, followed by midventricular. Of the total of 23 patients, 17 required ICU admission, 4 mechanical ventilation, 10 vasoactive drugs, 1 intra-aortic balloon pump, and 3 antiarrhythmic drugs. There was 1 patient who died during hospitalization due to non-cardiovascular cause. There were no other ischemic complications such as reinfarction, stroke, or the need for revascularization. As complications, 2 patients presented new AF, 2 developed left ventricular thrombus, 1 ventricular tachycardia, and 1 had cardiac arrest. The average length of hospital stay was 8 days. In the one-year clinical follow-up, 1 patient had a stroke, and another was hospitalized for heart failure.
Conclusions. In this small case series, TTS predominated in postmenopausal women and presented higher rates of cardiovascular complications than the historical series of patients with acute myocardial infarction of atherothrombotic cause.

A259: IMPACT OF DIABETES ON EPICARDIAL REPERFUSION AND MORTALITY IN CONTEMPORARY STEMI POPULATION UNDERGOING MECHANICAL REPERFUSION: INSIGHTS FROM THE ISACS STEMI COVID-19 REGISTRY

Renata Malivojevic (a), Enrico Ponti (b), Monica Verdoia (c), Matteo Nardin (d), Elvin Kedhi (e), Harry Suryapranata (f), Gennaro Galasso (g), Giuseppe De Luca (h)
(a) UNIVERSITÀ DEGLI STUDI DI VERONA; (b) UNIVERSITÀ DEGLI STUDI DI SASSARI; (c) OSPEDALE DEGLI INFERMI DI BIELLA; (d) OSPEDALE CIVILE DI BRESCIA; (e) ERASMUS HOSPITAL, UNIVERSITÈ LIBRE DE BRUXELLES; (f) RADSOUD UNIVERSITY MEDICAL CENTER; (g) UNIVERSITÀ DEGLI STUDI DI SALERNO; (h) UNIVERSITÀ DEGLI STUDI DI MESSINA

Background. Diabetes has been shown in last decades to be associated with a significantly higher mortality among patients with ST-segment elevation myocardial infarction treated with PCI. The aim of current study was to evaluate the impact of diabetes on times delays, reperfusion and mortality in a contemporary STEMI population undergoing primary angioplasty, including the COVID pandemic.
Objectives. The ISACS-STEMI COVID-19 is a large-scale retrospective multicenter registry involving primary PCI centers from Europe, Latin America, South-East Asia and North-Africa, including patients treated from 1st of March until June 30, 2019 and 2020). Primary study endpoint of this analysis was in-hospital mortality. Secondary endpoints were postprocedural TIMI 3 flow and 30-day mortality.
Results. Our population is represented by 16083 STEMI patients. A total of 3812 (23,7%) patients were diabetic patients. They were older, more often males as compared to non-diabetes. Diabetic patients were less often active smokers and had less often a positive family history of CAD, but they were more often affected by hypertension and hypercholesterolemia, with higher prevalence of previous STEMI and previous CABG. Diabetic patients had longer ischemia time, had more often anterior MI, cardiogenic shock, rescue PCI, multivassel disease. They had less often out-of-hospital cardiac arrest and in-stent thrombosis, received more often a mechanical support, received less often a coronary stent and DES. The COVID pandemic had a significant impact on mortality. Diabetes was associated with a significantly impaired postprocedural TIMI flow ($p<0.001$) and higher mortality ($p<0.001$) as compared to non-diabetes, particularly during the pandemic. The results were confirmed after adjustment for all baseline and procedural confounders, the period of treatment and the propensity score.
Conclusions. Our study showed that in a contemporary STEMI population undergoing primary angioplasty, diabetes is significantly associated with impaired epicardial reperfusion that translates into higher in-hospital and 30-day mortality, particularly during the pandemic.

A260: A REAL-WORLD COMPARATIVE ANALYSIS OF SURGICAL AND TRANSCATETHER APPROACHES TO TRICUSPID REGURGITATION

Gaspardone Carlo (b, d), Federica Gramegna (c, d), Michele Morosato (a, d), Laura Vetrugno (d), Francesca Braccischi (d), Vincenzo Rizza (a, d), Davide Antonio Morciano (a, d), Alessandro Fuga (a, d), Gabriele Paci (a, d), Caterina Mula (a, d), Paolo Denti (c), Nicola Buzzatti (c), Alberto Margonato (b, d), Eustachio Agricola (d, e), Francesco Maisano (c, d), Cosmo Godino (b)
(a) CARDIOTHORACIC DEPARTMENT, IRCCS SAN RAFFAELE SCIENTIFIC INSTITUTE, MILAN, ITALY; (b) CARDIOLOGY UNIT, IRCCS SAN RAFFAELE SCIENTIFIC INSTITUTE, MILAN, ITALY; (c) CARDIAC SURGERY UNIT, IRCCS SAN RAFFAELE SCIENTIFIC INSTITUTE, MILAN, ITALY; (d) VITA-SALUTE SAN RAFFAELE UNIVERSITY, MILAN, ITALY; (e) CARDIAC IMAGING UNIT, IRCCS SAN RAFFAELE SCIENTIFIC INSTITUTE, MILAN, ITALY

Background. The management of severe tricuspid regurgitation (TR) remains a challenge due to significant associated morbidity and mortality, compounded by limited treatment options. We aimed to compare the demographic traits, echocardiographic features, and clinical outcomes of patients undergoing transcatheter tricuspid valve repair (TTVR) versus those undergoing isolated surgical tricuspid valve repair or replacement (STVR).
Methods. We conducted a retrospective analysis of consecutive adult patients treated for severe TR using TTVR or STVR at our institution between 2017 and 2023. Baseline and follow-up data were obtained from electronic health records and through telephone interviews.
Results. Among the 79 TTVR patients and 80 STVR patients, the TTVR group was significantly older (76 vs. 65 years, $p<0.001$), had higher prevalence of coronary artery disease (31% vs. 14%, $p=0.02$) and atrial fibrillation (79% vs. 57%, $p=0.007$), and were more symptomatic (NYHA class III/IV, 59% vs. 37%, $p=0.01$). Moreover, a higher TRI-SCORE was ob-

served in the TTVR group compared to the STVR group (5.03 vs. 3.04, p=0.007). While there was no significant difference in baseline TR severity, functional TR etiology was more common in the TTVR group (86% vs. 63%, p=0.003). This group also exhibited worsened right ventricle (RV) function and RV ventriculo-arterial coupling (TAPSE/PASP<0.36, 35% vs. 15%, p=0.01). At a median follow-up of 1.14 years (IQR 0.41-1.50), the primary endpoint incidence (including death, TV surgery, or heart failure hospitalization) and mortality rates were similar in both groups (HR for primary endpoint 0.91; 95% CI, 0.50 to 1.65; p=0.75) (HR for death 0.77; 95% CI, 0.33 to 1.84; p=0.56). Nevertheless, when we employed a landmark analysis at the discharge time, STVR patients experienced a three-fold increase in in-hospital mortality rates (HR 3.01; 95% CI, 0.62 to 14.46; p=0.15), but a three-fold decrease in post-discharge mortality rates (HR 0.29; 95% CI, 0.09 to 0.97; p=0.04) when compared to TTVR patients.

Conclusions. This real-world retrospective study underscores the different characteristics of patients between TTVR and STVR. Despite a higher surgical risk and comorbidity burden among TTVR patients, midterm clinical outcomes were similar to STVR. However, more extensive research within large-scale randomized control trials is required to validate these findings.

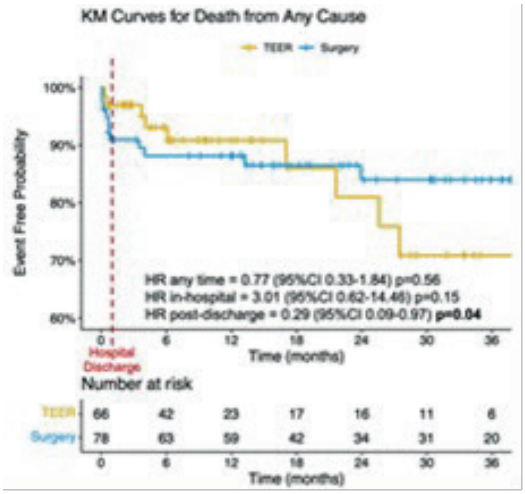

A261: IL VALORE DELL'APPROCCIO FULL PHYSIOLOGY IN UN CASO DI ANGINA RICORRENTE

Giovanni Orazio (a), Stefano Clo (a), Matteo Arzenton (a), Paolo Cimaglia (a), Gianluca Campo (a)
(a) AZIENDA OSPEDALIERA UNIVERSITARIA DI FERRARA

Un paziente di 71 anni, iperteso e dislipidemico, con storia di episodi di dolore toracico sotto sforzo presenti da un paio d'anni, eseguiva una valutazione cardiologica per il peggioramento di tali sintomi negli ultimi 3 mesi. In passato aveva già eseguito ECG ed ecocardiogramma risultati entrambi nei limiti di norma, ed una miocardioscintigrafia risultata negativa per ischemia inducibile. Alla visita cardiologica si indicava esecuzione di coronaro-TC. All'esame strumentale si evidenziavano piccole calcificazioni al tratto prossimale di arteria interventricolare anteriore (IVA), determinanti piccola stenosi del lume (<25%), mentre al tratto medio si rilevava presenza di ponte miocardico profondo 3 mm, esteso longitudinalmente per circa 22 mm, determinante riduzione del calibro del vaso di circa il 50% in fase diastolica e del 75% in fase telesistolica. In considerazione del quadro clinico e strumentale si poneva indicazione a studio coronarografico. All'esame coronarografico si evidenziava, oltre al già noto decorso intramiocardico di circa 2 cm al tratto medio di IVA, un albero coronarico esente da lesioni angiograficamente significative. Per tale motivo si procedeva alla valutazione funzionale completa al fine di dirimire il quadro clinico. Dapprima si riscontrava assenza di malattia del microcircolo con un indice di resistenza microvascolare (IMR) pari a 15 ed una riserva di flusso coronarico (CFR) pari a 2,2. Si procedeva quindi ad ulteriore valutazione tramite test provocativo all'acetilcolina che, al secondo step, risultava positivo per dolore toracico, alterazioni ECGgrafiche con tratto ST rigido in sede anteriore, riduzione della resting full-cycle ratio (RFR=0,61) ed evidenza angiografica di spasmo a livello del ponte intramiocardico, con riduzione del calibro del vaso maggiore del 90%. Alla luce di tale reperto, si concludeva per un quadro suggestivo di vasospasmo a livello del decorso intramiocardico al tratto medio di IVA, e si modificava la terapia di conseguenza, impostando verapamil 120 mg come nuovo farmaco, associato ad acido acetilsalicilico 100 mg ed alla rosuvastatina 10 mg che il paziente già assumeva. In letteratura è stata descritta una forte correlazione tra la presenza di ponte miocardico ed il vasospasmo coronarico. È stato infatti ipotizzato che il persistente effetto compressivo-rilassante, operato dal ponte sulle coronarie, possa indurre disfunzione endoteliale, con una conseguente maggiore reattività vascolare locale agli stimoli vasocostrittori. Inoltre questa associazione condurrebbe ad una maggior incidenza di angina ricorrente, come nel caso del paziente in questione. Tale caso clinico mette in risalto la rilevanza di un approccio "full-physiology" alla coronarografia, tale per cui, ad oggi, è sempre più importante non interrompere la procedura una volta evidenziata l'assenza di malattia aterosclerotica significativa, bensì proseguire con la valutazione funzionale utilizzando tutti gli strumenti a disposizione per chiarire il quadro clinico. In questo particolare caso, per esempio, si è potuto comprendere che la sintomatologia del paziente derivava soprattutto dal quadro di vasospasmo coronarico, più che dalla presenza di ponte miocardico. Di conseguenza è stato possibile impostare una terapia specifica ed evitare l'utilizzo di beta-bloccanti (classe di farmaci controindicati nell'angina vasospastica), ottenendo così un netto miglioramento della sintomatologia, riferito dal paziente alla visita di follow-up ad un mese.

A262: CHIUSURA PERCUTANEA DI DOTTO ARTERIOSO PERVIO IN NEONATI E LATTANTI DI PESO INFERIORE AI 5 KG

Francesco Prati (a), Biagio Castaldi (a), Elena Cuppini (a), Domenico Sirico (a), Giovanni Di Salvo (a)
(a) UNIVERSITÀ DEGLI STUDI DI PADOVA

Introduzione. La persistenza del dotto arterioso (PDA) in neonati pretermine è associata ad un peggiore outcome, sia dal punto di vista respiratorio, che di mortalità. La terapia farmacologica basata sull'utilizzo di inibitori delle ciclo-ossigenasi è considerata la terapia di prima linea, in caso di fallimento, si può considerare la chiusura del dotto mediate legatura chirurgica o chiusura percutanea.

Obiettivi. Valutare l'efficacia della chiusura percutanea di PDA in termini di fattibilità, di sicurezza procedurale e di efficacia in neonati pretermine e a termine con importanti comorbidità, di peso inferiore ai 5 Kg.

Materiali e metodi. Dal 01/01/2022 al 10/06/2023 sono state eseguite 8 procedure di chiusura percutanea di PDA in pazienti con peso inferiore ai 5 kg. La valutazione preoperatoria e intraoperatoria si è basata su ecocardiografia transtoracica. La valutazione post-operatoria a 24 ore dalla chiusura eseguita con ecocardiografia trans toracica ha preso in considerazione la presenza di shunt residuo e l'eventuale interferenza del device con il flusso di sangue sia in aorta che nel ramo dell'arteria polmonare sinistra. I dispositivi utilizzati, scelti in base alle caratteristiche biometriche ed anatomiche dei pazienti sono stati: Amplazer Piccolo™ Occluder e Occlutech PDA Occluder.

Risultati. Quattro pazienti avevano un peso al momento della procedura <2 kg (media peso 1,37 kg, media S.G. 24,95), gli altri 4 un peso compreso tra i 3-5 kg (media peso 3,9 kg, media S.G.36,5). I pazienti prematuri sono stati sottoposti a chiusura percutanea più precoce (34,7 vs 109,2 giorni). Nel 100% dei neonati con età gestazionale<a 30 S.G. è stata provata la chiusura farmacologica prima della chiusura percutanea con l'utilizzo di più cicli farmacologici (media cicli n=3). La procedura è stata efficace in tutti i pazienti arruolati, a 24 ore non era presente shunt residuo, né interferenza con il flusso sul versante polmonare e aortico. Il device Amplazer Piccolo™ è stato utilizzato in 6 pazienti (75%); Occlutech PDA Occluder in 2 pazienti (25%). Nel 75% dei casi l'approccio è stato solo venoso, negli altri due casi arterioso e venoso.Il rapporto diametro disco dispositivo/diametro minimo misurato ecograficamente è risultato 1,22 per il gruppo peso<2 kg mentre 1,96 per il gruppo 3-5 kg (p<0.01). La differenza in quantità nell'utilizzo del mezzo di contrasto iodato è risultata significativa nei diversi gruppi di peso: 3,75ml gruppo <2kg; 22ml gruppo3-5kg (p<0.01). Tutti gli 8 pazienti sono stati dimessi, con follow-up cardiologico non complicato.

Conclusioni. Nel prematuro, l'utilizzo del Amplazer Piccolo™ Occluder permette di utilizzare solo l'approccio venoso con introduttore 4Fr, minimizzando il rischio trombotico, di danno vascolare, con un rapido recupero della capacità respiratoria. In pazienti con comorbidità (ex prematuri, ernia diaframmatica corretta, bronco-displasia), la ridotta compliance polmonare può richiedere una correzione precoce. In virtù delle comorbidità, la chiusura percutanea è da preferire ad una toracotomia. Nei pazienti di peso>2 kg, è richiesto un rapporto device/diametro PDA più alto per ottenere una adeguata stabilità; per quanto riguarda la tecnica di impianto interamente intra-duttale è da ponderare caso per caso.

A263: BETTER SAFE THAN SORRY: A CASE OF GIANT CORONARY ARTERY ANEURYSM EXCLUSION

Massimo Russo (a), Francesco Valenti (a), Gianluca Massaro (a), Benedetto Daniela (a), Massimiliano Macrini (a), Saverio Muscoli (a), Gaetano Chiricolo (a), Giuseppe Massimo Sangiorgi (a), Francesco Barilla´ (a)
(a) U.O.C. CARDIOLOGIA POLICLINICO "TOR VERGATA"

Introduction. Giant coronary artery aneurysm (GCAA), defined as a coronary artery aneurysm with a diameter>8 mm according to a scientific statement from the American Heart Association, is an extremely rare abnormality of varying origins with an incidence of 0.02% but with life-threatening complications.

Case summary. This case report concerns a 72-year-old Caucasian man, heavy smoker, suffering from hypertension, dyslipidemia, and COPD.

In history Bentall surgery with re-implantation of native coronary arteries and aortic valve replacement with a mechanical valve and prior PCI with DES implantation on marginal branch (OM) and right coronary artery (RCA); angiographic examination also described ectatic disease of anterior descending artery (LAD) and voluminous aneurysm of circumflex artery (Cx). The patient was admitted in the ED of our hospital for oppressive chest pain radiating to the left arm. On admission ECG no signs of ongoing acute ischemia; the echocardiogram showed hypokinesis of the mid-basal segments of the posterolateral wall (EF 50%); on blood tests increased enzymes of myocardiocytosis. The patient was admitted to our CICU with a diagnosis of NSTE-ACS and underwent coronary angiography, via right femoral arterial access, showing ectasic LAD at the proximal middle tract, free of angiographically significant stenosis, RCA diffusely ectasic from proximal to distal tract in the absence of intrastent restenosis or angiographically significant de novo stenosis and Cx characterized by voluminous circular aneurysm with likely exclusion of downstream circulation and previously implanted stent on first OM not visualizable either by anterograde flow or by retrograde flow even after occlusion of Cx by occluding balloon. An angio-CT showed an increase in the size of the Cx aneurysm compared with the previous control. The case was discussed in Heart Team and due to the high surgical risk it was given indication for percutaneous closure of the GCAA. The next day, the patient underwent PCI via left humeral surgical vascular access with implantation of a 7 mm x 27 mm covered stent on left main-LAD; angiographic follow-up showed exclusion of the aneurysm of the Cx. During hospital stay, the patient performed a follow-up coronary CT scan in which patency of covered stent on left main-LAD and absence of Cx opacification was documented. On pre-discharge echocardiogram, known hypokinesis of the mid-basal segments of the posterolateral wall was confirmed. The patient was discharged in good general clinical condition, asymptomatic for angor; with an indication to take DAPT (ASA+clopidogrel) and warfarin for one month.

A264: A NIGHTMARISH NIGHT ON CALL

Tarek Shail (a), Enrico Cerrato (b), Ferdinando Varbella (b), Giuseppe Patti (a)

(a) AOU MAGGIORE DELLA CARITÀ DI NOVARA; (b) AOU SAN LUIGI GONZAGA E OSPEDALE DEGLI DI INFERMI DI RIVOLI

Razionale. L'imaging intracoronarico può essere un grande alleato anche nell'ambito delle situazioni d'emergenza come lo STEMI, dove la sola angiografia non è dirimente nel definire con certezza la natura dell'occlusione coronarica, e dove le prime manovre interventistiche come il wiring con filo guida o la predilatazione con pallone risultano inefficaci nel ripristinare il flusso coronarico. E nel caso in cui la procedura di emergenza di angioplastica primaria in corso di STEMI venga complicata da dissezione iatrogena, diventa fondamentale per un rapido e preciso intervento che garantista un ottimo risultato finale.

Risoluzione tecnica. Il caso mostra uno STEMI inferiore giunto durante una reperibilità notturna. Fin dal primo approccio si ha difficoltà durante l'incanulamento della coronaria destra (Cdx) per take off sfavorevole, riuscito solo con catetere guida e guida coronarica, coadiuvati da sistema child in mother con Guideliner. Il wiring con guida coronarica è risultato inefficace nel ripristinare il flusso, per cui si tenta con sistema tromboaspiratore Export, ugualmente inefficace nel ripristinare il flusso. Per cui si procede con predilatazioni multiple con pallone SC, al controllo angiografico risultata inefficace e seguita da dissezione iatrogena della Cdx ostio-prossimale. Con microcatetere Sasuke si esegue tip injection per controllare la distalità del vaso e confermare la presenza intraluminale della guida coronarica, e dopo dilatazioni multiple dalla distalità all'ostio, nonostante l'instabilità clinica, si decide di valutare la coronaria con imaging IVUS, in modo da eseguire una esatta valutazione della dissezione e per meglio definire la natura della persistente occlusione distale. Data la conferma della natura trombotica dell'occlusione al tratto distale coinvolgente la biforcazione, si procede con impianto di stent distale, e impianto di stent dopo complicata valutazione del sizing per presenza di importante ematoma subintimale, al tratto ostio-prossimo-medio, con ottimo risultato angiografico e IVUS finale, e al controllo angiografico a 12 mesi.

Implicazioni cliniche. L'utilizzo dell'imaging intracoronarico rappresenta sempre più uno strumento fondamentale per la valutazione della strategia interventistica e l'ottimizzazione degli interventi di angioplastica. Caratteristiche che anche nei setting di intervento meno appetibili come gli interventi in emergenza per STEMI, l'utilizzo durante le reperibilità notturne o in corso di complicanze intraprocedurali possono, contrariamente a quanto ancora oggi percepito, rendere le procedure più veloci, sicure, diminuire la necessità di mezzo di contrasto e garantire al paziente il miglior risultato possibile.

Prospettive. Definire e valutare i criteri di utilizzo dell'imaging intracoronarico valutando gli outcomes anche nel contesto di emergenza e complicanze, dato che sempre più si conferma essere uno strumento rapidamente utilizzabile e capace di fornire all'operatore informazioni fondamentali che possono ridurre e ottimizzare i tempi di intervento.

A265: BPA AS A TREATMENT IN PATIENTS WITH CTEPH: INITIAL EXPERIENCE OF BPA PROGRAM AT CHIETI REGIONAL CENTER FOR PH

Marco Addari (b), Livio Giuliani (a), Paolo Ciarelli (b), Federica De Donno (b), Maria Vittoria Caprio (b), Serena Rossi (a), Sabina Gallina (b)

(a) EMODINAMICA E CARDIOLOGIA INTERVENTISTICA, OSPEDALE SS. ANNUNZIATA, CHIETI; (b) DEPARTMENT OF NEUROSCIENCE, IMAGING AND CLINICAL SCIENCES, G. D'ANNUNZIO UNIVERSITY OF CHIETI-PESCARA

Introduction. Chronic thromboembolic pulmonary hypertension (CTEPH) is caused by the obstruction of the pulmonary arteries with non-resolving, organized fibrotic clots leading to elevated pulmonary vascular resistance (PVR), severe pulmonary hypertension (PH), right heart failure and, ultimately, death. Pulmonary endarterectomy (PEA) remains the recommended treatment for patients with operable CTEPH. However, about 40% of CTEPH patients are ineligible for surgery due to distal lesions or the presence of comorbidities. Today, balloon pulmonary angioplasty (BPA), an endovascular procedure to widen narrowed or obstructed pulmonary arteries, is an emerging and established treatment option for patients with inoperable CTEPH or persistent/recurrent PH after PEA, as indicated in the last 2022 ESC/ERS Guidelines for the diagnosis and treatment of pulmonary hypertension. We report the experience of BPA at our Regional Reference Centre for Pulmonary Hypertension (Abruzzo, Chieti University, SS. Annunziata Hospital), where a BPA program started in November 2022.

Diagnostic work-up and procedure's planning. All inoperable patients referred to our center with diagnosis of CTEPH underwent a complete diagnostic work-up. Medical history and comorbidity were assessed; blood gases on room air and serum level of NT-pro-BNP were evaluated; a spiral computed tomography was performed. Hence, a complete right heart catheterization and a diagnostic pulmonary angiography were scheduled, for a complete definition of patient's PH and a complete planning of BPA procedure. An accurate choosing of target lesions, according with the angiographic classification (type A, ring-like stenosis; type B, web lesions; type C, subtotal lesions; type D, total occlusion lesions, and type E, tortuous lesions) and assessing the number of BPA sessions needed for achieve complete revascularization were carefully performed.

Procedure's steps and possible complications. Before the index procedures the patient was informed about the potential risks and benefits of this interventional procedure and provided written informed consent. Pulmonary artery was approached trough the right femoral vein using peripheral guiding sheats (Destination Terumo 6F). A 6F guiding catheter (multipurpose or Amplatzer left) was advanced in the target vessels; a 0.014 inch guidewire was used to cross target lesions. Usually a 2.0 mm balloon catheter is used as first choice for the dilation of the lesions. A dose of UFH was administered to maintain ACT on 200-250 msec values. The most frequent complication of BPA is pulmonary artery injury (wire perforation is the most common pulmonary artery injury and is usually caused by deep insertion of a guide wire into peripheral small branches). Pulmonary artery injury can lead to signs and symptoms such as coughing (not necessarily accompanied by bloody sputum), hemoptysis, an increase in heart rate and PAP, and hypoxia, although it can be asymptomatic in some cases. Other complications include pulmonary artery dissection and pulmonary artery rapture. Pulmonary artery dissection can result from deep intubation of the guiding catheter, whereas an oversized balloon, or in case of lesions with a large amount of organized thrombi, balloon dilation itself may cause excessive extension of the pulmonary vascular wall, likely resulting in vascular injury or even rapture.

Our experience as a BPA Center: training and numbers. Since November 2022, our center became a BPA center (the second in all over Italy). Before starting to perform BPA procedures, two interventional cardiologists of our center experienced a period of remote proctoring with Professor Matsubara (Department of Clinical Science and Department of Cardiology, National Hospital Organization Okayama Medical Center, 1711-1 Tamasu, Kita-ku, Okayama, 701- 1192, Japan), who is one of the first BPA performers in the world. The first BPA procedure we made was previously discussed and planned with him, and then was performed according with his advice. Nowadays in our BPA program seven patients were enrolled. All of them underwent three sessions of revascularization. We didn't observed any intraoperative complication in the cath lab. One of the patients experienced an acute renal failure with a rise of creatinine serum levels, probably due to a large amount of contrast media needed during the procedure, promptly solved with only three more days of hospitalization. An improvement in values of mean pulmonary artery pressure and pulmonary vascular resistance was observed in all our patients, with a good response in relief of symptoms (primarily fatigue and exertional dyspnoea). Some of them will need adjunctive BPA sessions, in order to achieve complete revascularization.

Conclusions. Balloon pulmonary angioplasty is a novel type of treatment for inoperable CTEPH patients. It could be challenging and also dangerous, with a lot of possible complications. A learning curve is needed for achieve a good level in performing this type of invasive procedure. We consider becoming a BPA center a very important step for ensuring our patients the best level of care.

A266: A CASE OF TRANSCATHETER AORTIC VALVE IMPLANTATION IN A PATIENT WITH A BIFURCATED AORTIC ARCH

Antonio Bellantoni (a), Fabiola Boccuto (a), Alessandro Lucchino (a), Giovanni Martino (a), Martina Spinali (a), Alessandra Panarello (a), Filippo Bova (a), Vincenzo D'Ambrosio (a), Concetta Filardo (a), Filippo Fabio Valenti (a), Sabato Sorrentino (a), Alessandro Caracciolo (a), Antonio Di Virgilio (b), Ciro Indolfi (a), Annalisa Mongiardo (a)
(a) DIVISION OF CARDIOLOGY, UNIVERSITÀ MAGNA GRAECIA, CATANZARO, ITALY; (b) CARDIOVASCULAR SURGERY UNIT, UNIVERSITÀ MAGNA GRAECIA, CATANZARO, ITALY

A 71-year-old male patient with a history of hypertension, dyslipidemia and Parkinson's Disease, presented with repeated episodes of dyspnea on exertion over the course of the last few months. His cardiologist performed an echocardiogram, that showed a severely calcified aortic valve causing severe valve stenosis (valve area 0.8 cm^2, mean gradient 46 mmHg, max gradient 75 mmHg), augmented wall thickness and a left ventricular ejection fraction of 57%. After a multidisciplinary evaluation, considering the comorbidities and overall clinical state of the patient, the possibility of a surgical replacement was excluded and a transcatheter aortic valve implantation (TAVI) was suggested instead. Consequently, the patient underwent an angio-CT scan for a better evaluation of the valve annulus, the aorta and the peripheral arteries. Surprisingly, the exam showed evidence of a bifurcated aortic arch that enveloped the patient's trachea and esophagus, with normal ascending and descending aorta. A double aortic arch is the most common type of vascular ring, a group of congenital defects affecting about 1 in 10000 people. Given its restricted diameter and its closeness to the airways, such an anatomy might pose a challenge for the endovascular deployment of the prosthesis' delivery system. The anterior arch had a diameter of 20 mm, while the posterior one was 22.7 mm wide. The aortic annulus was 22.6 mm wide, and the ascending aorta had an average diameter of 31.9 mm. After careful evaluation, the patient was considered eligible for TAVI using a 27 mm Abbott Navitor self-expandable valve. The right femoral artery was the main access site, and it was used to insert the valve delivery system through a Safari2 Extra-Small 0.035" guidewire (positioned into the left ventricle with the help of an Amplatz L1 catheter). Through the left radial artery, instead, the operators positioned a 5F pigtail catheter in the non-coronary cusp, which was used for the angiographies. Interestingly, the delivery system reached the heart through the posterior superior branch of the aortic arch, while the devices inserted through the secondary access were conducted into the anterior inferior arch because of the peculiar origin of the left subclavian artery. After pre-dilatation of the native valve with a 25-20-25 x 40 mm Valver balloon, the bioprosthetic device was implanted successfully through a 15F delivery sheath. Hemostasis of the right femoral artery was successfully achieved using a 18F Manta vascular closure device. The post-interventional echocardiogram showed the successful positioning of the valve, with a significant reduction of transvalvular gradients (mean gradient 7 mmHg) and only mild aortic regurgitation. To the best of our knowledge, this is the first case of TAVI performed in a patient with this challenging anatomy. It demonstrates the importance of a correct pre-procedural planning, integrating CT scans, echocardiographic and angiographic techniques. After a complete evaluation of the patient's aortic valve, aorta and peripheral arteries, the procedure was carried out successfully, and the bioprosthetic valve was deployed without immediate complications.

A267: SHORT TERM FOLLOW-UP RESULTS IN SAME DAY DISCHARGE PERCUTANEOUS CORONARY INTERVENTION: IS IT THE RIGHT TIME TO SPREAD THIS PRACTICE?

Giorgia Benzoni (a), Davide Sala (b), Giuseppe Verolino (b), Gianfranco Parati (a, b), Roberto Brambilla (b), Paolo Sganzerla (b)
(a) UNIVERSITY MILANO-BICOCCA - CARDIOVASCULAR DISEASE RESIDENCY PROGRAM; (b) IRCCS ISTITUTO AUXOLOGICO ITALIANO- SAN LUCA HOSPITAL, MILAN

Background. Percutaneous Coronary Intervention (PCI) is a minimally invasive procedure which implies hospital admission. Previous studies have already suggested the safety and feasibility of Same Day Discharge (SDD) after elective PCI; however, this practice is still challenging and meets with skepticism due to logistical and organizational issues.
Aims. The purpose of this study was to share the positive experience of our center, pointing out the feasibility of this approach and spreading this practice in other PCI centers.
Methods. We retrospectively analyzed a total of 46 patients affected by chronic coronary artery disease who underwent elective PCI from 2016 to 2023, who had 6 hours post procedural in-hospital observation, a telephonic follow-up at 24 hours and at 30 days after PCI. As adverse events we considered: vascular complications, bleeding from radial vascular access, new onset acute coronary syndrome, new myocardial revascularization, death. Correct assumption of dual antiplatelet therapy (DAPT) as prescribed at discharge was also verified.
Results. All patients had chronic coronary syndrome and 67.3% of our population had a previous acute coronary syndrome. Mean age was 66.7 years and 93.4% of patients were male. 42 patients were affected by a single vessel artery disease, 4 patients had a double vessel disease: 31 patients treated left coronary artery (11 left anterior descendant artery, 20 circumflex artery), 16 patients treated right coronary artery (RCA), 1 intermediate branch. All the procedures were conducted by radial vascular access and all the patients were previously on DAPT. At angiography evaluation of lesions treated, 55.1% were B2-C complex lesions according to ACC/AHA classification. Clinical parameters were: Left Ventricular Ejection Fraction (mean values 61.2%), eGFR (mean values 81.7 ml/min/1.73m^2), 28% of patients were diabetic. During in-hospital observation we registered 2 minor bleeding events (type 2 under BARC classification) treated with compressive medication. Twenty-four hours and 30 days follow- up was available in 100% of population with no cases of death, acute myocardial infarction, new myocardial revascularization, or bleeding from radial access. Only one patient has been re-hospitalized after 22 days from PCI for gastrointestinal bleeding.
Limits. Our study is conducted by retrospective analysis and with a limited number of patients, all previously on DAPT.
Conclusions. Our data confirmed the feasibility and the safety of SDD PCI in carefully selected patients, showing good clinical outcome especially in the first 24 hours after discharge with no adverse events reported. By spreading our experience, we wish to increase and strengthen this approach in most PCI centers so that it can become the standard of care in this kind of patients, improving hospital costs and resources for elective PCI without impact on procedural complications.

A268: SINGLE CENTER EXPERIENCE WITH DRUG COATED-BALLOON IN STEMI PATIENT

Andrea Bottardi (a), Gabriele Venturi (b), Gabriele Facci (a), Antonio Mugnolo (b), Alberto Zamboni (b), Francesco Bacchion (b), Margherita Fabroni (a), Luigi Alberto Iossa (a), Giorgio Morando (b)
(a) UNIVERISTÀ DEGLI STUDI DI VERONA; (b) OSPEDALE MATER SALUTIS DI LEGNAGO

Background. Percutaneous coronary intervention (PCI) with drug-eluting stents (DES) is currently recommended as first choice in patient with AMI. However, bleeding's risk due to dual antiplatelet therapy and increased by acute setting and the risk for early and late in stent restenosis (ISR) still raise some concerns in some particular settings. Drug coated ballons (DCB), represent a possible alternative which could overcome these concerns and have gained discrete popularity in ISR, small vessel desease and bifurcation lesions. The aim of the present abstract was to show safety and outcome of DCB in the treatment of acute coronary syndrome with particular focus on STEMI patients.
Methods. We retrospectively investigated our internal registry between february 2019 and January 2023 to retrieve data about STEMI treated with drug coated balloon. Indication to DCB instead of stent depended on operators' preferences, based mostly on vessel diameter or anatomy complexity. Culprit lesions were prepared with tromboaspiration when trombus was visible after lesion crossing, followed by adeguate predilatation. The objective of the study was to show procedural success and 6 months outcome in term of major cardiac adverse events, target vessel revascularization, target lesion revascularization and target lesion thrombosis.
Results. Between May 2018 and May 2023 11 patients with myocardial infarction and ST elevation were treated with primary pci and DCB: four de novo lesions and six ISR. One patient with de novo lesion shifted to a stenting bailout strategy due to coronary dissection, leading to an overall procedural success rate of 90.9%. For all the remaining patients final angiography showed good result od DCB angioplasty with 3 TIMI flow. In-hospital survival was obtained by 10 out of 11 patients (90.9%): death occurred in only one patient with ISR and complex past medical history with three vessel coronary artery disease for cardiogenic shock the day after procedure. No MACCES occurred at last available follow-up for the 10 patients (90.9% MACCEs free survival). No target lesion revascularization and no target vessel revascularization were reported.
Conclusions. Among our single center experience, DCB proved to be an effective strategy for AMI culprit lesion revascularization, with overall good procedural success and mid-term outcome. However, when applied in the contest of de novo lesion, dissection and late restenosis can occur. This register presents the limitations of a small sample and a short period of follow up, therefore needing further validation.

A269: PERCUTANEOUS RENAL DENERVATION IN ECTOPIC KIDNEY

Andrea Carbone (a), Vincenzo Riverso (a), Jessica Ielapi (a), Angelo Leone (c), Daniela Chiappetta (c), Federico Battista (c), Saverio Alberti (c), Francesco Greco* (c), Alberto Polimeni* (b, c)
(a) DIVISION OF CARDIOLOGY, MAGNA GRAECIA UNIVERSITY, 'R. DULBECCO' HOSPITAL, CATANZARO, ITALY; (b) DEPARTMENT OF PHARMACY, HEALTH AND NUTRITIONAL SCIENCES, UNIVERSITY OF CALABRIA, COSENZA, ITALY; (c) DIVISION OF CARDIOLOGY, 'ANNUNZIATA' HOSPITAL, COSENZA, ITALY

Background. Neurohumoral dysfunction and vascular abnormalities as well as renal nervous plexus irregularity play a key role in pathogenesis of refractory resistant arterial hypertension. We report a case of right ectopic pelvic kidney in a 66-years-old man candidate to percutaneous renal artery denervation (RDN). His clinical history included chronic kidney disease, diabetes mellitus, permanent atrial fibrillation, and chro-

nic obstructive pulmonary disease. Radiofrequency catheter-ablation was planned. At index procedure, after successfully left RDN, there were some troubles in right renal artery cannulation and procedure was interrupted. Subsequently, abdominal computed tomography was performed, and the scan showed the right ectopic kidney in the pelvic region arterially supplied by a main branch with acute angle take-off from left common iliac artery and an accessory inferior polar artery originating from the right common iliac artery (Fig 1). Thus, right RDN was deferred.
Technical resolution. Intravenous anxiolytics and narcotics was administered to manage intraprocedural diffuse visceral pain. The Symplicity Spyral multi-electrode catheter (Medtronic) was selected as the ablation device. Since the acute angled origin, the main branch artery was cannulated with internal mammary artery catheter and with microcatheter (SuperCross 90°). Then the denervation catheter was advanced and positioned into the renal artery with the aid of a supportive guidewire (Hi-Torque Powerturn) and a guide catheter extension system (GuideLiner) (Fig. 2a, Fig. 2b). The spiral was expanded to allow good electrodes contact to the vessel wall and was connected to a radiofrequency generator, allowing for sequential four-electrodes set low-level radiofrequency energy ablation (Fig.3). During energy delivery, temperature raised abnormally, exceeding security threshold, and heart rate dropped until marked asymptomatic pauses appeared. The procedure was safely interrupted without neither complication nor patient discomfort. Even though suboptimal ablation was performed, ambulatory blood pressure monitoring follow-up measurements showed mild but stable decrease, so medical therapy was optimized with MRA down-titration in accordance with patient renal impairment.
Conclusions. The abnormal position of the ectopic kidneys may result in vascular malformations and renovascular hypertension secondary to an anomalous blood supply. In this setting preoperatively CT scan is mandatory and percutaneous RDN may be technical challenging. In this kind of patient, the effectiveness of procedure is barely achievable too. Proper evaluation of renal vasculature and fiber-ganglionic mass can quite successfully predict procedural and clinical outcomes.

Fig. 1

Fig. 2a

Fig. 2b

Fig. 3

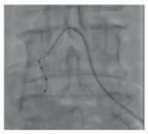

A270: PRE-PROCEDURAL PLANNING IN TAVI: THE RISK OF SUBOPTIMAL CT QUALITY

Gabriele Carciotto (a), Giampiero Vizzari (a), Giuseppe Andò (a), Francesco Costa (a), Francesco Patanè (b), Fabrizio Ceresa (b), Tommaso D'Angelo (c), Antonio Micari (a)
(a) DIPARTIMENTO DI MEDICINA CLINICA E SPERIMENTALE, CARDIOLOGIA CON UTIC, UNIVERSITÀ DI MESSINA; (b) AZIENDA OSPEDALIERA PAPARDO; (c) AZIENDA OSPEDALIERA UNIVERSITARIA POLICLINICO G. MARTINO

The transcatheter heart valve (THV) embolization is a rare but challenging complication in transcatheter aortic valve implantation (TAVI). It occurs almost exclusively during or immediately after TAV deployment and is mainly caused by sizing error, device malpositioning or pacing failure (for balloon-expandable TAV implantations). We report a case of a 64 years old woman, with hypertension, dyslipidemia, type 2 diabetes mellitus, severe obesity (body mass index>40 kg/mq) that presented to the cardiology department complaining of syncope and dyspnea. Transthoracic echocardiography (TTE) showed a mildly reduced EF (45%) and a severe aortic stenosis (meanG 42 mmHg). According to 2021 ESC guidelines, considering an intermediate risk of in-hospital mortality evaluated with EuroScore II risk score (6.7%), The Heart Team decided to proceed with transfemoral TAVI given the severe obesity, using an Allegra NVT, a valve composed of a self-expanding, nitinol stent frame with a sewn-in supra-annular bovine pericardial heart valve. CT-scan, performed in another facility, showed an aortic annulus perimeter of 73.3 mm, a perimeter derived of 23.3 mm, an ascending aorta of 31.6 mm, a LVOT of 23.9 mm and acceptable coronary ostia's height (RCA 14.7 mm; LCA 9.6 mm). Currently, there are three sizes of Allegra available (23 mm, 27 mm and 31 mm), and based on the CT results and the data sheet of the valve, an Allegra 27 mm implant was planned. Although the CT images were low quality due to high HR of the patient during the exam that led to a sub-optimal ECG synchronization. Transcatheter aortic valve implantation was performed under conscious sedation in the hybrid operating room. Having obtained vascular access (the right femoral artery was used as main access, prepared with 2 Pro-glide systems for pre-closure technique and a 18F sheath was inserted; the left femoral artery was used as backup access), the THV was advanced and positioned within the aortic annulus. After a valvuloplasty, mandatory for the Allegra valve, rapid pacing had started and the device was released with an optimal result: the angiography showed no leaks and patent coronary arteries. Unfortunately, a few minutes later, the ECG monitor showed ST-segment elevation. A 10F sheath was rapidly re-inserted in the main access through the Terumo wire kept inside for protection and the angiogram showed no coronary arteries and the embolization of the device in the ascending aorta (we were able to cannulate the left main below the TAVI device). Due to hemodynamic instability our bailout strategy was to quickly retrieve the prosthesis in the descending aorta with two snare systems. The procedure was concluded with a result of a mild-moderate aortic stenosis (meanG 25 mmHg; Peak Vel. 3 m/sec), a mild aortic regurgitation, no aortic dissection and patent coronary arteries and a second staged TAVI was planned. In conclusion, suboptimal CT planning can lead to severe complications, due to errors in sizing, such as prosthesis embolization, a serious and life-threatening complication that requires prompt and effective management. Overall management of this complication should include repositioning the first THV, modified implantation of the second THV, and an adequate THV evaluation after the second implantation. CT-scan has a key role in pre-procedural TAVI workup, representing the gold standard for annular sizing and transcatheter heart valve selection, and a suboptimal CT planning can lead to severe complications, such as prosthesis embolization. Does border-line CT measures require further investigations for a correct annulus sizing?

A271: SUPPORTO VENTRICOLARE PERCUTANEO IN CORSO DI ANGIOPLASTICA AD ALTO RISCHIO

Vittorio Taglialatela (a), Gerardo Carpinella (a), Davide D´andrea (a), Fulvio Furbatto (a), Federica Serino (a), Fulvio La Rocca (a), Aniello Di Donato (a), Valentina Capone (a), Ciro Mauro (a)
(a) AORN A.CARDARELLI CARDIOLOGIA UTIC ED EMODINAMICA

La complessità dei pazienti che si presentano presso le nostre strutture comporta l'utilizzo di sistemi tecnologici avanzati e di una attenzione alle plurime comorbidità di cui soffrono. Il caso clinico che presentiamo riguarda un paziente di 65 anni ex-fumatore, affetto da diabete mellito tipo 2, ipertensione arteriosa, ipercolesterolemia, cardiopatia ischemica cronica (pregresse angioplastiche di coronaria destra e ramo circonflesso due anni prima, con nota occlusione totale cronica - CTO - dell'arteria interventricolare anteriore - IVA), giunto alla nostra osservazione con un NSTEMI in corso di sepsi a partenza dalle vie urinarie. Alla risoluzione del quadro infettivo, dati la riduzione severa della funzione cardiaca (FE 30% con acinesie fibrotiche in territori inferiore e anterosettale) e l'elevato incremento della troponina, viene effettuata coronarografia che mette in evidenza CTO della coronaria destra e dell'IVA (entrambe parziale circolo di riabitazione), una restenosi subocclusiva intrastent del ramo circonflesso e malattia critica del tronco comune. Attivato l'heart team, il cardiochirurgo non considera il paziente candidabile al bypass aortocoronarico per l'anatomia coronarica e per la presenza di fibrosi miocardica nei territori delle occlusioni croniche. Vista l'esclusione al trattamento chirurgico, in considerazione della presenza di estese aree necrotiche non favorevoli per un recupero sostanziale della funzione contrattile, viene proposto al paziente dapprima l'impianto di un ICD bicamerale e poi l'angioplastica di tronco comune e ramo circonflesso, che entrambe vengono accettate dopo esser stato ben edotto dei rischi/benefici. Trattandosi di una procedura complessa su last remaining vessel in paziente con severa disfunzione ventricolare sinistra, si programma l'angioplastica con l'ausilio di iVAC-2L p-VAD, un dispositivo di assistenza ventricolare totalmente percutaneo che viene posizionato in ventricolo sinistro attraverso accesso arterioso femorale 18 French. Tale dispositivo, utilizzato in questo caso per la prima volta assoluta in Campania, consente di ottenere un sostegno emodinamico stabile, assicurando una gittata di 2 L/min e determinando un aumento della pressione arteriosa media. Il buon supporto emodinamico ci ha permesso di portare a termine l'angioplastica senza alcun problema di instabilità emodinamica, effettuando in sicurezza tutte le predilatazioni necessarie alla preparazione delle lesioni ed il successivo impianto con post-dilatazione di stent medicati 3.5 x 22 mm sul tronco comune e 3.0 x 18 mm e 2.5 x 18 mm in overlap sulla restenosi intrastent del ramo circonflesso. L'emostasi femorale dell'accesso si ottiene con successo mediante un device a sistema di chiusura biomeccanica Manta, come documentato anche dalla angiografia di controllo. A distanza di 3 giorni dalla procedura, con decorso clinico ottimale in assenza di complicanze cliniche e laboratoristiche, il paziente viene dimesso in ottimo compenso emodinamico, con il massimo della terapia farmacologica tollerata (doppia antiaggregazione con ticagrelor, glifozina, antialdosteronico, furosemide, betabloccante, ivabradina, statina, ezetimibe, terapia antidiabetica) e con appuntamento programmato presso il nostro ambulatorio di scompenso cardiaco.

A272: HEMODYNAMIC RESPONSE OF PULMONARY CIRCULATION AFTER TRANSCATHETER AORTIC VALVE REPLACEMENT IN PATIENTS WITH SEVERE AORTIC STENOSIS AND PULMONARY HYPERTENSION

Francesca Ciliberti (a)
(a) DIPARTIMENTO DI NEUROSCIENZE, IMAGING E SCIENZE CLINICHE, UNIVERSITÀ DEGLI STUDI DI CHIETI-PESCARA, 66100 CHIETI, ITALY; (b) EMODINAMICA E CARDIOLOGIA INTERVENTISTICA, OSPEDALE SS. ANNUNZIATA, 66100 CHIETI, ITALY

Background. In accordance with the latest European Society of Cardiology (ESC) guidelines on Valvular Heart Disease (VHD), thanscatheter aortic valve implantation (TAVI) is strongly recommended (Class 1A) for patients with severe aortic stenosis (AS) who are high operative risk or, for

those with low-to-intermediate surgical risk, aged ≥75 years. The 2022 ESC/European Respiratory Society (ERS) Clinical Guidelines on Pulmonary Hypertension (PH) advocate for right heart catheterization as the gold standard for diagnosing and classifying PH, with its prevalence observed in up to 65% of severe AD patients. Successful TAVI, by reducing afterload, demonstrate the potential to amplify cardiac output and facilitate reverse structural and hemodynamic remodelling in the left heart, pulmonary circulation, and right chambers. Notably, the reversibility of PH post-TAVI has been correlated with reduced mortality. However, it is underscored that existing studies often focus on systolic or mean pulmonary pressures, neglecting the crucial measurement of pulmonary vascular resistances (PVR).

Purpose. The objective of this study is to investigate the short and mid-term effects of TAVI on PVR among individuals with severe AS and PH. The investigation aims to assess the prevalence of pulmonary vascular disease, specifically defined as PVR exceeding 2 Wood Units (WU), in patients with severe AS and PH who undergo TAVI. Additionally, the study intends to analyse the influence of TAVI on Mitral Regurgitation (MR) in a subset of patients with an initial MR severity of more than mild (≥2+ grade).

Methods. This is a prospective, observational, multi-centre study of 150 patients with severe AS referred to Heart Valve Clinics. The patients will undergo comprehensive assessments for concomitant PH, and those deemed suitable by the local Heart Team will undergo TAVI following current clinical guidelines. The study entails scheduled follow-up assessments at three specific time points: early follow-up (≥24 hours post-TAVI), mid-term follow-up (3 to 6 months post-TAVI), and late follow-up (1-year post-TAVI).

Results. The preliminary results from November 2021 through September 2022 show that a total of 52 patients underwent transfemoral TAVI at out institution. The average age was 82 ± 5 years, with 37% male. Aortic Valve Area (AVA) and Indexed AVA (AVAi) averaged 0,65 ± 0,16 cm^2 and 0,36 ± 0,08 cm^2/m^2, respectively, with 69% exhibiting high gradients (>40 mmHg). In baseline echocardiography, 57% had an intermediate-to-high probability of PH; 10 met inclusion criteria. Baseline invasive hemodynamics showed elevated mean Pulmonary Artery Pressure (mPAP 30 ± 7, normal values ≤20 mmHg) and right atrial pressure (9 ± 6). PVRs were 3,3 ± 0,9 and 2,9 ± 0,8, calculated using the Cardiac Output (CO) method. Post-TAVI, PVR showed a non-significant trend towards reduction, while both Cardiac Output (CO) and Cardiac Index (CI) significantly improved before discharge. A significant positive linear correlation was observed between MR Regurgitant Volume (MR RVol) and MR Regurgitant Fraction (MR RF) (Pearson r=0,66, CI 95% 0,052 to 0,91, p value=0,0378 for MR RVol; Pearson r=0,70, CI 95% 0,12 to 0,92, p value=0,0242 for MR RF).

Conclusions. TAVI represents a valid alternative therapeutic modality to surgical aortic valve replacement (SAVR) for patients with symptomatic severe AS. TAVI is often offered to patients with several comorbidities, among which PH frequently coexists with severe AS. Numerous studies have demonstrated that baseline PH is correlated with increased mortality and unfavorable outcomes in patients undergoing TAVI. TAVI induces significant and rapid hemodynamic changes, contributing to improved prognosis and symptom relief. Despite these positive effects, Pulmonary Vascular Resistances (PVRs), recognized as a surrogate endpoint for more substantial outcomes, do not show improvement post-TAVI according to recent literature.

A273: MANAGEMENT AND OUTCOMES OF CORONARY INSTENT RESTENOSIS IN CONTEMPORARY PRACTICE: INSIGHTS FROM A TERTIARY REFERRAL CENTER

Caterina Da Pozzo (a), Dario Calderone (b), Jacopo Andrea Oreglia (c), Francesco Stefano Soriano (c), Stefano Nava (c), Giuseppe Esposito (c), Irene Bossi (c), Emanuela Piccaluga (c), Michele Galasso (d), Andrea Munafò (e), Fabrizio Oliva (c), Daniele Andreini (a, f), Claudio Montalto (c)

(a) SCHOOL OF MEDICINE AND SURGERY, UNIVERSITY OF MILAN, MILAN, ITALY; (b) EMODINAMICA, OSPEDALE SAN LUCA, IRCCS ISTITUTO AUXOLOGICO ITALIANO, MILAN, ITALY; (c) DE GASPERIS CARDIO CENTER, INTERVENTIONAL CARDIOLOGY UNIT, GRANDE OSPEDALE METROPOLITANO NIGUARDA, MILAN, ITALY; (d) SCHOOL OF MEDICINE AND SURGERY, UNIVERSITY OF MILANO-BICOCCA, MILAN, ITALY; (e) FONDAZIONE IRCCS POLICLINICO SAN MATTEO, UNIVERSITY OF PAVIA, PAVIA, ITALY; (f) IRCCS OSPEDALE GALEAZZI-SANT'AMBROGIO, MILAN, ITALY

Background. While intracoronary stent restenosis (ISR) is significantly less frequent with the use of drug-eluting stents (DES) compared to bare-metal stents (BMS), the high volume of stent implantations in interventional procedures and the persistent risk of restenosis over time means that the treatment of ISR remains an important clinical challenge.

Objective. The aim of this study was to assess cardiovascular risk factors in a population with ISR, after DES implantation, as well as therapeutic management and clinical outcome, to better understand the mechanisms that lead this population to have adverse events during follow up.

Methods. In the study, 145 patients with DES-ISR were enrolled. The angiographic diagnosis of restenosis was followed by PCI to restore adequate coronary flow. Clinical outcomes were considered up to 1500 days (4.10 years) of follow up.

Results. ISR is frequent in patients with cardiovascular risk factors such as male, overweight, hypertension, dyslipidaemia, and reduced kidney function. In 50% of cases the clinical presentation of ISR was acute coronary syndrome (n=72). The use of intracoronary imaging techniques (IVUS or OCT) allows better characterization of lesions and better dimensioning of devices: in the population where, intracoronary imaging has been performed, the devices used to treat restenosis, DCB or DES, were larger and longer than the non-imaging population (DCB diameter p=0,018; DES diameter p=0,002; DES length p=0,05). DCB were the main strategy used to treat ISR (70%, n=101), especially in cases where debulking techniques were used to prepare the lesion optimally (86%, n=59). Considering the follow-up, the risk of death in the enrolled population is about 10% at 1500 days (figure 1 curve A), with most deaths due to cardiovascular causes. The risk of adverse events is higher, it has been estimated of approximately 55% at 1500 days of follow up (figure 1 curve B). A multivariate analysis showed that a preserved glomerular filtration rate is an independent predictive factor of better clinical outcome (HR 106,685, p=0,840).

Conclusions. Patients with ISR have a high frequency of adverse events and mortality during the follow up. Considering the complex management of these patients, further studies are necessary to identify which risk factor are independent predictor of better clinical outcome, in order to reduce the risk of adverse events.

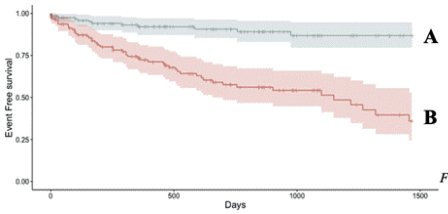

Figure 1 curve A: all-cause death; curve B: composite endpoint

A274: FLUOROSCOPY TIME AS A NEW PREDICTOR OF SHORT - TERM OUTCOMES AFTER TRANSCATHETER AORTIC VALVE REPLACEMENT

Maurizio D'Alessandro (a), Fortunato Iacovelli (a), Francesco Spione (b), Alessandro Xhelo (a), Daniele De Feo (a), Francesca Sturdà (a), Alessandro Cafaro (c), Chiara Palmitessa (a), Marco Matteo Ciccone (a), Alessandro Santo Bortone (a)

(a) POLICLINICO UNIVERSITY HOSPITAL - BARI; (b) "MONTEVERGINE" CLINIC - MERCOGLIANO; (c) "VITO FAZZI" HOSPITAL - LECCE

Background. Transcatheter aortic valve replacement (TAVR) is a cine-fluoroscopic guided procedure and the amount of radiation used during the procedure is potentially dangerous for both operators and patients because of its stochastic and deterministic adverse effects. This is strictly related with fluoroscopy time (FT) that has been demonstrated to be associated with outcomes and complexity of procedure in percutaneous coronary interventions. To date, no study has investigated the association between FT and short-term prognosis after TAVR, thus, the aim of our study is to demonstrate in a large population their relationship.

Methods. Patients' population (1797 patients) was divided according to FT (minutes) tertiles: 1st group 13.94±2.93 min, 2nd group 21.31±1.99 min and 3rd group 38.31±18.83 min (no statistically significant differences were found in terms of preprocedural characteristics like patients' characteristics, previous cardiovascular history, comorbidities, and mortality risk scores). The composite endpoint of early safety was adjudicated according to Valve Academic Research Consortium (VARC)-2 and -3 consensus documents and the composite endpoints of device success and technical success according to VARC-3 criteria.

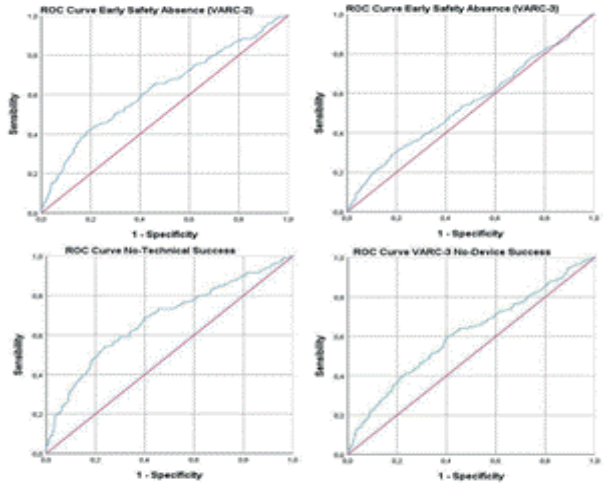

Variable	Early Safety (VARC-3)		p	T-statistic
	Yes	No		
Fluoroscopy Time min (unmatched)	23.58±1.80	28.23±1.80	<0.001	23.58±1.80
Fluoroscopy Time min (matched after PSM*)	24.09±3.17	28.23±3.17	0.035	24.09±3.17
	Device Success (VARC-3)		p	T-statistic
	Yes	No		
Fluoroscopy Time min (unmatched)	23.70±1.93	31.95±1.93	<0.001	4.27
Fluoroscopy Time min (matched after PSM*)	22.83±2.76	32.23±2.76	0.007	3.41
	Technical Success		p	T-statistic
	Yes	No		
Fluoroscopy Time min (unmatched)	23.82±2.32	37.99±2.32	<0.001	2.58
Fluoroscopy Time min (matched after PSM*)	22.01±4.23	37.99±4.23	0.001	1.90
	Early Safety (VARC-2)		p	T-statistic
	Yes	No		
Fluoroscopy Time min (unmatched)	33.72±2.05	23.72±3.05	<0.001	4.87
Fluoroscopy Time min (matched after PSM*)	33.72±3.10	22.11±3.10	0.046	3.74

Results. According to VARC-3 criteria, higher FT was significantly associated with lower technical success (TS) and device success (DS) (p<0.001 and p=0.021 respectively) and higher absence of early safety (ES) (p=0.013). Also considering VARC-2 criteria, the absence of ES was significantly associated with the FT (p<0.001).
Conclusions. Longer FT during TAVR is related to more complex procedure and so to possible complications; short-term outcomes after TAVR are related with FT and this association persists after PSM; the cut-offs identified after ROC analysis have sufficient accuracy to detect VARC-3 TS and VARC-2 ES. A FT duration of more than 30 minutes has an adequate accuracy in identifying VARC-3 technical failure and VARC-2 ES absence. In conclusion, FT, an easily available parameter during TAVR, appears to be an independent predictor of short-term TAVR-related post-procedural complications.

A275: PROGNOSTIC ROLE OF CORONARY ARTERY ECTASIA IN PATIENTS WITH NON-OBSTRUCTIVE CORONARY ARTERY DISEASE

Mattia De Gregorio (a), Filippo Luca Gurgoglione (a, b), Marco Covani (a), Emilia Solinas (b), Giorgio Benatti (b), Luigi Vignali (b), Iacopo Tadonio (b), Andrea Denegri (b), Elia Indrigo (a), Gianluca Signoretta (a), Diego Ardissino (a, b), Giampaolo Niccoli (a, b)
(a) UNIVERSITÀ DEGLI STUDI DI PARMA; (b) AZIENDA OSPEDALIERO-UNIVERSITARIA DI PARMA

Introduction. Coronary artery ectasia (CAE) is not an innocent angiographic finding, being associated with the occurrence of adverse events in patients with non-obstructive coronary artery disease (NOCAD). However, previous studies focused on patients with CAE and ischemia or angina and no-obstructive coronary arteries (INOCA/ANOCA) and the relationship between CAE and myocardial infarction with NOCAD (MINOCA) has been poorly investigated. In our study we aimed at assessing differences in clinical, angiographic and prognostic features among patients with CAE and MINOCA vs INOCA/ANOCA presentation.
Methods. Patients with angiographic evidence of CAE and NOCAD were enrolled at the University Hospital of Parma between January 2013 and December 2022 and divided into two study groups according to MINOCA vs INOCA/ANOCA presentation. Clinical and quantitative coronary angiography informations were recorded in each patient and the incidence of major adverse cardiovascular events (MACE) was assessed at follow-up.

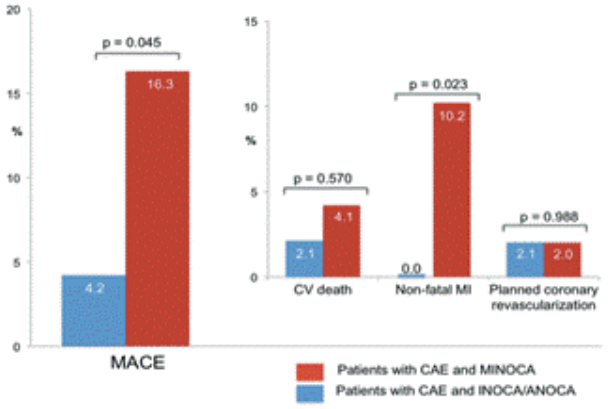

Figure 1. Clinical outcomes in the overall population according to ACS vs CCS presentation.

Results. We enrolled a total of 97 patients, 49 [50.5%]) with MINOCA and 48 [49.5%] with INOCA/ANOCA presentation. Patients with CAE and MINOCA had a higher frequency of inflammatory diseases (10 [20.4%] versus 3 [6.2%], p=0.041) and multivessel CAE (26 [53.1%] versus 15 [31.2%], p=0.030) along with a higher prevalence of TIMI flow <3 (23 [46.9%] versus 11 [22.9%], p=0.013) and thrombus in the dilated segment (11 [22.4%] versus 3 [6.2%], p=0.023) as compared to patients with CAE and INOCA/ANOCA. At a median follow-up of 38 [23; 65] months, patients with CAE and MINOCA had a significantly higher incidence of MACE compared to those with CAE and INOCA/ANOCA (8 [16.3%] vs. 2 [4.2%], p=0.045), mainly driven by a higher rate of non-fatal MI (5 [10.2%] vs. 0 [0.0%], p=0.023) (figure 1). Finally, comparison of the Kaplan–Meier curves by log-rank test showed that patients with CAE and MINOCA had also a lower MACE-free survival (p=0.026) compared to those with CAE and INOCA/ANOCA.
Conclusions. Among a cohort of patients with CAE and NOCAD, the presentation with MINOCA pinpoints a subgroup of patients with a worse outcome, maybe attributable to the higher inflammatory status and the more extensive CAE along with pro-coagulative features as compared to those with CAE and INOCA/ANOCA.

A276: DETERMINANTS OF 1-YEAR MORTALITY IN PATIENTS UNDERGOING PERCUTANEOUS TRANSCATHETER AORTIC VALVE IMPLANTATION: A PROSPECTIVE COHORT STUDY

Carlo Fumagalli (a, b), Giulia Nardi (a), Giacomo Credi (a, c), Nazario Carrabba (a), Francesco Meucci (a), Renato Valenti (a), Pierluigi Stefano (a, c), Alfredo Cerillo (a), Valentina Scheggi (a), Carlo Di Mario (a), Samuele Baldasseroni (a), Raffaele Marfella (b), Niccolò Marchionni (c), Andrea Ungar (a, c)
(a) CAREGGI UNIVERSITY HOSPITAL, FLORENCE, ITALY; (b) UNIVERSITY OF CAMPANIA, L. VANVITELLI, NAPLES, ITALY; (c) UNIVERISTY OF FLORENCE, FLORENCE, ITALY

Background. Transcatheter aortic valve implantation (TAVI) has originally been launched as the preferred therapeutic option in older patients with aortic stenosis (AS) not amenable for open heart surgery. Guidelines recommend surgical scores such as the Society of Thoracic Surgeons (STS) for risk stratification. However, the long-term predictive power of these scores in older patients is limited. Aim of this study was to assess the association of the comprehensive geriatric assessment (CGA) with all-cause mortality at 1 year after the procedure to guide screening for futility.
Methods. Consecutive patients>80 years referred to TAVI from January 2019 to January 2022 at our tertiary care institution were prospectively screened for frailty through a CGA based on physical function and the Multidimensional Prognostic Index (MPI). The MPI is a three-level score used to stratify frailty and risk of mortality (low, intermediate, or high risk) based on eight key domains for frailty assessment (functional and cognitive status, nutrition, mobility, and risk of pressure sores, multimorbidity, polypharmacy and co-habitation). Frailty was defined by an intermediate-high MPI while disability was defined as loss of>2 basic activities of daily living (BADL) Patients were also analyzed by STS score (<4%: low risk; 4-8%: intermediate risk;>8%: high risk). All patients were prospectively called at 1 year post TAVI.
Results. Overall, 354 patients were enrolled in 3 years (mean age 83+4 years, women N=209 (59%). Average STS score was 4.2±2.7 (low risk: 49%; intermediate: 39%, high risk: 12%). A total of 223 (62.9%) patients belonged to the MPI-low risk group, while 131 (37.1%) to the intermediate – high MPI risk group. Median peak aortic gradient (GPeak) was 72 [58-86] mmHg, median aortic valve area (doppler, AVAi) was 0.45 [0.37-0.59] cm2 and median pulmonary arterial pressure (sPAP) 43 [37-49] mmHg. Forty-two (11.8%) patients died at 1 year. While the STS score had only a trend towards higher mortality risk (Odds Ratio [OR] 1.228, 95% CI [0.757-1.994], p=0.068), male gender (OR: 3.987, 95% CI [1.961-8.106], p=0.009), MPI (OR: 3.557, 95% CI [1.870-7.028], p<0.001) and sPAP (OR: 1/180, 95% CI [1.118-1.244], p<0.001) were associated with worse outcome. Among the MPI components, disability in the basic activities of daily living was the most important risk factor (OR: 3.999, 95% CI [2.788-5.701], p=0.009].
Conclusions. In a prospectively enrolled cohort of old TAVI candidates, frailty status was able to identify patients at higher risk of 1-year mortality irrespective of STS risk score. Disability in the basic activities of daily living was one of the strongest predictors of outcome together with signs of pulmonary hypertension. Screening for frailty and disability could be a useful tool, coupled with other scores, for early detection of high-risk patients thus preventing the futility of the TAVI procedure.

A277: BALLOON AORTIC VALVULOPLASTY PREDILATATION REDUCES THE RISK OF PARAVALVULAR LEAK IN PATIENTS WITH SEVERELY CALCIFIED AORTIC VALVES UNDERGOING TAVR WITH IMPLANTATION OF NEWER-GENERATION SELF-EXPANDABLE PROSTHESES

Germano Junior Ferruzzi (a), Angelo Silverio (a), Michele Bellino (a), Mario Ferraioli (a), Cristina Sasso (a), Francesco Vigorito (b), Cesare Baldi (b), Tiziana Attisano (b), Carmine Vecchione (a), Gennaro Galasso (a, b)
(a) DEPARTMENT OF MEDICINE, SURGERY AND DENTISTRY, UNIVERSITY OF SALERNO, BARONISSI, SALERNO, ITALY; (b) INTERVENTIONAL CARDIOLOGY UNIT, UNIVERSITY HOSPITAL SAN GIOVANNI DI DIO E RUGGI D'ARAGONA, SALERNO, ITALY

Background. The volume of calcium present at the native aortic valve (aortic calcium volume, ACV) has been associated with the risk of developing paravalvular leak (PVL) after transcatheter aortic valve replacement (TAVR). However, this evidence derives from studies on older generation

prostheses. Also, the role of balloon aortic valvuloplasty predilatation (BAVp) on the mechanistic pathophysiological association between ACV and PVL is still poorly investigated.
Aim. To determine the association between ACV and the risk of significant PVL in patients with severe aortic stenosis undergoing TAVR using newer-generation self-expandable aortic prostheses, and to evaluate the potential influence of preliminary BAVp.
Methods. This study included consecutive patients with symptomatic severe aortic stenosis undergoing TAVR with newer-generation self-expandable aortic prosthesis from 2019 to 2023. The ACV was quantified from pre-procedural contrast enhanced multi-slice computed tomography (MSCT) images using the reading software OsiriX (OsiriX-MD v.2.8.2 64-bit). PVL was quantified by transthoracic echocardiography and defined significant if ≥2+/5+. Patients were divided into two groups: those who underwent BAVp and those who did not. The propensity score technique was employed to account for potential selection bias between patients undergoing or not BAVp.
Results. This study included 174 patients (median 81 years, 31.6% males); of them, 122 (70.1%) patients underwent BAVp. BAVp patients showed significantly higher values of left ventricular ejection fraction (LVEF, p=0.012), mean aortic valve gradient (p<0.001), and ACV (p<0.001) than patients who did not undergo BAVp. Significant PVL after TAVR was reported in 28 (16%) patients. Overall, there was a significant association between ACV and the risk of developing significant PVL after TAVR both at unadjusted (OR: 1.001; 95% CI: 1.000-1.001, p=0.014) and at propensity score adjusted logistic regression analysis (adjusted OR: 1.001; 95% CI: 1.000-1.001; p=0.033). Among the prespecified subgroups of interest, the association between ACV and the risk of developing PVL≥2+ after procedure was confirmed in patients who did not undergo preliminary BAVp (adjusted OR: 1.001; 95% CI: 1.000-1.001, p=0.035) but not in the BAVp group (adjusted OR: 1.002; 95% CI: 1.000-1.003, p=0.635).
Conclusions. This real-world study including patients with severe aortic stenosis undergoing TAVR using newer-generation self-expandable aortic prostheses, confirmed a strong significant association between ACV and the risk of developing significant PVL after procedure. Preliminary BAVp may mitigate the detrimental effect of ACV on the risk of developing PVL in this TAVR population.

A278: GENDER-RELATED DIFFERENCES IN PATIENTS UNDERGOING PERCUTANEOUS CORONARY INTERVENTION AND PRIOR INTERNAL MAMMARY ARTERY BYPASS GRAFTING

Domitilla Gentile (a), Marco B. Ancona (a), Luca Ferri (a), Barbara Bellini (a), Filippo Russo (a), Ciro Vella (a), Giulia Ghizzoni (a), Tommaso De Ferrari (c), Alaide Chieffo (a, b), Matteo Montorfano (a, b)
(a) INTERVENTIONAL CARDIOLOGY UNIT, IRCCS SAN RAFFAELE SCIENTIFIC INSTITUTE, MILAN, ITALY; (b) VITA SALUTE SAN RAFFAELE UNIVERSITY, MILAN, ITALY; (c) DEPARTMENT OF BIOMEDICAL AND DENTAL SCIENCES AND MORPHOFUNCTIONAL IMAGING, SECTION OF CARDIOLOGY, UNIVERSITY OF MESSINA, MESSINA, ITALY

Background. Internal mammary artery graft (IMA) is the preferred conduit for coronary artery bypass surgery. Although these grafts have good patency rates, it is known that they could occasionally fail, needing a second revascularization procedure. Few studies focused on IMA graft failure and analyzed predictors and long-term outcomes.
Methods. The aim of this study was to investigate the main predictors of long-term mortality in patients affected by internal mammary artery graft failure or a progression of disease of the native vessel (left anterior descending artery-LAD) at or distal to the anastomosis, focusing on gender differences among our population. We retrospectively analysed 575 consecutive patients with percutaneous coronary intervention (PCI) on IMA or LAD from February 2008 to February 2020 at our hospital. From this population, we selected only those with angioplasty performed on IMA or LAD at or distal to the anastomosis. Our final study population was represented by 203 patients.
Results. Women represented 13.8% of the population. Female patients had a shorter IMA failure/LAD progressive disease timing with 17.9% of women between one and twelve months and 3.6% before the first month, while men experienced them mostly after 12 months (94.8%, p=0.02). Consequently, there was a gender-related difference in time between CABG and PCI procedure: women underwent a procedure earlier than men, 5.5±6.1 years vs 9.5±6.5 respectively (p=0.002). The location of the affected vessel portion was equally distributed among men and women, with a great number of patients with a progressive disease involving LAD after anastomosis (77.8%). Women had a better left ventricular ejection fraction at discharge (54.7±9.8% vs 50.7±11.2%, p=0.04). The mean follow-up time was 82 months and a minimum of 1-year follow-up was available for 166 patients. Multivariate models of the whole population pointed out age (OR [95% CI]=1.08 [1.04-1.12]) and EF (OR [95% CI]=0.93 [0.91-0.96]) as independent prognostic factors and sex (OR [95% CI]=2.25 [1.02-4.95]) and time between CABG and PCI procedure (OR [95% CI]=1.09 [1.04-1.41]). Different results could be found if the analysis is performed according to female gender, where none of them are independent prognostic factors in multivariate models. Males had acute coronary syndrome at presentation (OR [95% CI]=2.47 [1.14-5.36], p=0.022) and time from CABG to PCI procedure (OR [95% CI]=1.09 [1.04-1.14], p<0.001) as independent prognostic factors at multivariate analysis.
Conclusions. IMA graft failure or a progressive disease on LAD at or distal to anastomosis is a rare condition after CABG. The time between CABG and PCI has been shown as a new main predictor of these conditions. IMA graft failure or a progressive disease on LAD at or distal to anastomosis occurred in the female population with a different temporal distribution, suggesting a gender-specific response to arterial graft and patency.

A279: CORRELATION BETWEEN HEPARIN NEUTRALIZATION BY PROTAMINE AND BLOOD TRANSFUSION IN CARDIAC SURGERIES: A SYSTEMATIC REVIEW

Dyovane Lopes (a), Lais Da Silva Pereira-rufino (a), Antonio Alceu Dos Santos (a), Carlos Eduardo Panfilio (a), Isabel Cristina Céspedes (a)
(a) ESCOLA PAULISTA DE MEDICINA - UNIVERSIDADE FEDERAL DE SÃO PAULO

Introduction. Blood transfusions have been a crucial part of medicine since the 17th century but also carry risks for patients. Cardiac surgeries often necessitate transfusions due to bleeding during the procedure. To minimize transfusions, efficient use of heparin and protamine is essential. However, the ideal ratio between these medications has not been established. This study conducted a systematic review to explore the correlation between heparin neutralization by protamine and the reduction in blood transfusions in cardiac surgeries.
Methods. Thirty-nine studies (9,830 patients) related to cardiac surgeries, heparin, protamine, and blood transfusions were analyzed. Various parameters, including the type of surgery, heparin and protamine dosage, activated clotting time, and others, were assessed. Statistical analysis included Spearman correlations, Kruskal-Wallis tests, and linear regression.
Results. The analysis revealed a variety of heparin-to-protamine ratios used, with an average protamine dosage of 3.29 mg/kg ± 0.09 and an average heparin dosage of 326 IU/kg ± 7.3. Among these cases, there was an average of 205 units of Red Blood Cells transfused, followed by 157 units of Platelet Concentrates and 143 units of Fresh Frozen Plasma. Cardiopulmonary bypass time averaged 111 minutes ± 8.3 and Activated Clotting Time (ACT) averaged 451 seconds ± 37.4. While a strong positive correlation between heparin and protamine and the quantity of red blood cells and platelet concentrates transfused was observed (Rho=0.677; p<0.001), no significant differences were found in the analyzed ratios and other variables such as hemoglobin, cardiopulmonary bypass, and ACT. Linear regression analyses also did not show significance for the predictors studied.
Discussion. Previous studies suggest that precise control of the protamine/heparin ratio can reduce blood loss and the need for transfusions. However, the lack of consensus and the limited number of publications on the subject indicate the need for further research to guide clinical practices.
Conclusions. Based on the results, it was not possible to identify an ideal ratio between protamine and heparin that significantly reduces the need for blood transfusions in specific cardiac surgeries. This underscores the importance of careful administration and precise monitoring of these medications to optimize blood coagulation and minimize transfusions, enhancing the safety and outcomes of patients undergoing these surgical procedures.

A280: POSTPARTUM CONCOMITANT SEIZURES AND CARDIAC ARREST: A RARE CLINICAL CASE OF MULTIDISTRICT SPONTANEOUS ARTERIAL DISSECTION

Jessica Luchetti (a), Marcello Marchetta (b), Giulia Pugliese (a), Giulio Russo (a), Saverio Muscoli (a), Francesco Barillà (a), Giuseppe Sangiorgi (a)
(a) UNIVERSITÀ DEGLI STUDI DI ROMA TOR VERGATA; (b) UNIVERSITÀ DEGLI STUDI DI MESSINA

Spontaneous arterial dissection associated with pregnancy is a rare complication occurring in less than 1% of pregnant patients, especially in the postpartum period. During pregnancy, oestrogen has negative effects via release of matrix metalloproteinase leading to fragmentation of reticular fibers, disorganization of elastic fibers, hypertrophy and hyperplasia of smooth muscle cells, creating a substrate for hypertension in pregnancy which may be responsible for vascular dissections. We present a rare clinical case of combined spontaneous coronary artery dissection (SCAD) of left anterior descending artery (LAD), causing cardiac arrest (CA), and bilateral internal carotid arteries (ICA), causing seizures, in a young woman at 10th day postpartum. A 38-year-old woman, gravida 2, para 2, without any previous cardiac history, affected by peripartum hypertension came to our emergency department because of seizures and cardiac arrest occurring at home ten days postpartum. Upon arrival of the emergency team, 6 DC shocks for ventricular fibrillation, prolonged mechanical compressions and IOT were performed. On arrival in the emergency department laboratory values were normal, except for Troponin I hs (15033 ng/L) values. The electrocardiogram showed signs of extensive anterior subepicardial ischemia. The echocardiogram (TTE) showed aki-

nesia of the apex, the anterior wall and the anterior IVS (left ventricular ejection fraction, LVEF, 43%). The patient underwent cranial CT, documenting bilateral dissection of the middle distal extracranial ICAs with patency of the lumen, without caliber reduction. Coronary angiography showed dissection in the middle-distal LAD with TIMI flow 1, also confirmed by coronary angio-CT. Considering the clinical stability of the patient, a conservative strategy was opted. The day after the patient was extubated. She performed cardiac MR documenting extended area of ischemia at the apex and the anterior portion of the IVS. Nowadays there are no clear guidelines regarding the treatment of SCAD. In the two largest SCAD registries, it was demonstrated that PCI was appropriate and safe for patients with SCAD with high-risk features such as cardiogenic shock, active/ongoing ischemia, hemodynamic instability, ventricular arrhythmias, ST-segment elevation myocardial infarction and high-risk anatomy. On the other side, conservative approach may be suitable for other clinical presentations. Similarly, ICA dissection is generally managed conservatively, and interventions are generally reserved for recurrent ischemia despite antithrombotic therapy. Regarding our patient, she had neither high-risk clinical features for emergency PCI, nor the criteria for interventions on ICA's dissection. So, after multidisciplinary discussion with vascular surgeons, interventional radiologists and neurologists, a conservative strategy and follow-up with serial TTE (showing residual akinesia of apex - LVEF 50%) and cranial angio-CT (documenting unchanged extension of bilateral ICA's dissection) was chosen.

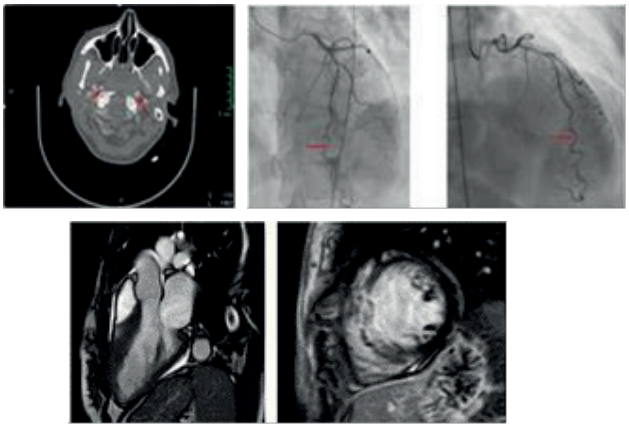

A281: NON C'È DUE SENZA TRE

Maria Francesca Massara (a, b), Francesca Campanelli (a), Giulia Stronati (a), Giorgio Di Noto (b), Michela Casella (a), Federico Guerra (a), Antonio Dello Russo (a)
(a) UNIVERSITÀ POLITECNICA DELLE MARCHE; (b) OSPEDALE CARLO URBANI - JESI - AST2 ANCONA

Background. L'impianto di pacemaker è una procedura routinaria sebbene non scevra da complicanze, alcune delle quali mortali.

Case report. Donna, 84 anni, cardiopatia ipertensiva, fibrillazione atriale in terapia anticoagulante (dabigatran), veniva sottoposta a impianto di pacemaker (29.09.22) per malattia del nodo del seno in seguito ad episodio sincopale. Il giorno dopo l'impianto, veniva eseguito RX torace che mostrava un PNX apicale sinistro, senza indicazione a drenaggio chirurgico. In seguito al peggioramento delle condizioni cliniche per la comparsa di dispnea, desaturazione e dolore all'emitorace sx, veniva eseguita TC torace (03.10.22) con riscontro di idropneumotorace massivo per cui veniva posizionato in sala operatoria un drenaggio toracico. Ripetuta la TC toracica di controllo dopo 5 giorni (09.10.2022) mostrava quasi completo riassorbimento del PNX ma documentava abbondante falda di versamento pericardico circonferenziale (3cm) "meritevole di rivalutazione specialistica cardiologica"; nel frattempo la paziente si manteneva stabile sotto il profilo emodinamico. Al controllo ecocardiografico: presenza di versamento pericardico (15mm) non tamponante. In seguito alla rivalutazione delle immagini TC da parte del Cardiologo evidenza di sospetta perforazione miocardica, dunque veniva centralizzata la Paziente d'urgenza c/o Ospedale Regionale delle Marche. All'eco-transesofageo evidenza di falda di versamento pericardico (19mm) con iniziali segni di impatto emodinamico e visualizzazione dell'elettrocatetere sporgente nel sacco pericardico di 15mm. La paziente veniva sottoposta (11.10.22) in sala operatoria ibrida aritmologica e cardiochirurgica ad intervento di estrazione dell'elettrocatetere ventricolare in sternotomia mediana e reimpianto di catetere epicardico.

Conclusioni. La perforazione cardiaca e il PNX sono due complicanze gravi ma rare dell'impianto PM con una incidenza rispettivamente di 0,1% e 1%, ma solo aneddoticamente descritte insieme in letteratura. L'iniziale riscontro del PNX a cui era stata attribuita la sintomatologia è stato un fattore confondente che ha ritardato la diagnosi della perforazione miocardica. Inoltre la non disponibilità di un programmatore per l'interrogazione del device non ha permesso di documentare precocemente l'alterazione dei parametri elettrici. Infine, nella prima TC del 03.10 non erano segnalati versamento pericardico né perforazione miocardica, ma da una analisi retrospettiva le immagini erano già suggestive mentre non lasciano dubbi nel secondo esame radiologico.

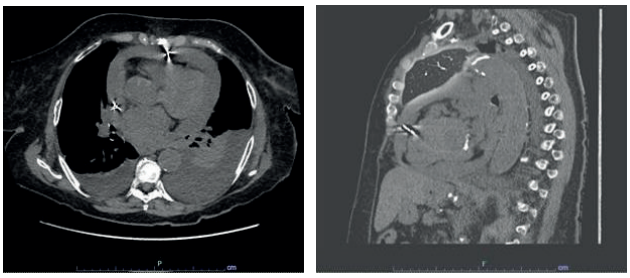

A282: CORONARY EMBOLISM IN PATIENT WITH PROSTHETIC AORTIC VALVE: LOOKS CAN BE DECEIVING

Alfredo Mauriello (a, b), Beatrice D'Arco (c), Fabrizia Terracciano (a), Biagio Liccardo (a), Alfonso Desiderio (b), Antonello D´andrea (a, b)
(a) DEPARTMENT OF MEDICAL TRANSLATIONAL SCIENCES, UNIVERSITY OF CAMPANIA "LUIGI VANVITELLI"- MONALDI HOSPITAL, NAPLES - ITALY; (b) DEPARTMENT OF CARDIOLOGY, UMBERTO I HOSPITAL, NOCERA INFERIORE - ITALY; (c) DEPARTMENT OF MEDICINE, SURGERY AND DENTISTRY, NEUROSCIENCE SECTION, UNIVERSITY OF SALERNO, BARONISSI - ITALY

Case presentation. A 68-year-old woman was admitted to the Emergency Department for chest pain onset for 90 minutes. The ECG showed an upward ST segment elevation in DII, DIII, aVF, with specular downward ST segmentation in DI and aVL, compatible with ACS-STEMI. The patient was referred to cath-lab. Coronary angiography showed a proximal embolic occlusion of the right coronary artery. Vessel patency was obtained spontaneously, with the help of BMW and Runthrough ES guidewires and with residual distal stenosis, achieving clinical stability. The atherosclerotic plaques was absent. The blood tests revealed increased CK-MB mass levels and cTnI, D-Dimer levels was in the normal range. The patient was referred to Cardiology Unit for subsequent management. The past medical history showed recent aortic valve replacement with bioprosthesis Inspiris Resilia 19 mm (about three months ago) and prior atrial fibrillation ablation (about ten years ago). The family history showed a thrombophilic trait of the son who had thrombophilic gene mutations: PAI-I 4G/4G in homozygosity, MTHR A1298C in homozygosity, Factor V Leiden G1691A in heterozygosity. For identify any embolic sources, TTE and TEE performed. TTE did not show alteration of the bioprosthesis in the presence of preserved left ventricular impairment (EF 55%) with ipokinesia of the inferior wall. TEE did not show PFO or atrial septal aneurysm, atrial and left atrial appendage thrombosis or prosthetic valve thrombosis or lesions compatible with endocarditis. The presence of extracardiac shunts with echocardiography with bubble study and Doppler and deep vein thrombosis was excluded. The test panel for inherited thrombophilias including deficiencies of antithrombin, protein C and protein S, factor V Leiden and prothrombin 20210 mutation was perfomed. Finally, an implantable loop recorder (Biomonitor IIIM Biotronik) was implanted.

Discussion. The evaluation of coronary embolism in patients with ACS represents a challenging issue; since a differential diagnosis from coronary embolism and atherosclerotic forms is mandatory to optimize the clinical management. The clinical management must reduce the recurrent thromboembolic disease. Indeed, on long-term follow-up, 10% of patients had recurrent thromboembolic disease. The patient had acquired risk factors for thrombophilia: prior atrial fibrillation and prosthetic valve. Prosthetic thrombosis was excluded by performing TEE. There was no way to rule out an episode of AF, therefore it was decided to implant the ILR. Although it increases the risk of venous thromboembolism, it was no increased risk of arterial thromboembolism in long-term cohort studies of patients with inherited thrombophilia. The management of patients with coronary thrombosis is questionable. She was discharged with DOAC associated with ASA and evaluation after 3 months, to decide based on the interrogation of the ILR whether or not to continue oral anticoagulant therapy.

Conclusions. Coronary embolism represents a challenging clinical issue. A careful comprehensive evaluation aiming to identify embolic sources and thrombophilic risk factors should be considered in the care centered on patients with coronary embolism.

A283: PERCUTANEOUS TECHNIQUES FOR THE TREATMENT OF CORONARY BIFURCATIONS: PROVISIONAL STENTING AND OPTIMIZATION WITH POT-SIDE-POT VERSUS KISSING BALLOON INFLATION

Maria Sara Mauro (a), Sofia Maria Tomasi (a), Simone Finocchiaro (a), Davide Capodanno (a)
(a) DIVISION OF CARDIOLOGY, AZIENDA OSPEDALIERO UNIVERSITARIA POLICLINICO "G. RODOLICO - SAN MARCO", UNIVERSITY OF CATANIA, CATANIA, ITALY

Background. Provisional stenting has been recommended as the default technique for most bifurcation lesions. However, the optimal postdilata-

tion strategy post provisional stenting is under investigation and often its choice depends on the decision of the operator according to his experience.
Aim. The aim of this study is to compare two postdilatation technique, kissing balloon Inflation (KBI) and POT-side-POT strategy, in patients with bifurcation lesions underwent provisional stenting.
Methods and Results. In total, 178 patients with bifurcation lesions who underwent provisional stenting technique were included, 46 in the KBI group and 132 in the POT-side-POT group. The primary endpoint was MACE at 1 year, a composite of cardiac death, myocardial infarction (MI) and target lesion failure (TLF). The secondary endpoint included the single components of the primary endpoint, cardiovascular hospitalization, and major bleedings according to the BARC definitions 3-5. At 1 year follow-up there were not significative differences between the two groups in terms of MACE ((KBI 9 [19.6%] vs. POT-side-POT 33 [25.0%]; P=0.59)). A greater risk of major bleedings was associated to the KBI strategy ((KBI 4 [11.1%] vs. POT-side-POT 2 [1.8%]; P=0.04)). These results were confirmed after the adjustment for confounding factors.
Conclusions. Study results demonstrated that both techniques are valid options for optimization after provisional stenting, although POT-side-POT strategy showed a lower incidence of major bleedings and therefore could be used with greater safety in patients as an alternative to KBI. However, further randomized studies are needed to confirm our findings in larger populations.

A284: META-REGRESSION ANALYSIS ON THE IMPACT OF MEDICAL THERAPY ON LONG-TERM OUTCOME IN PATIENTS AFFECTED BY SPONTANEOUS CORONARY ARTERY DISSECTION.

Erika Tabella (a), Marco Mele (b), Raffaele Capasso (a), Adriano Grillo (a), Simone Puglisi (a), Andrea Cuculo (b), Francesco Santoro (a), Antonietta Mele (c), Antonella Liantonio (c), Paola Imbrici (c), Natale Daniele Brunetti (a)
(a) DEPARTMENT OF MEDICAL AND SURGICAL SCIENCES, UNIVERSITY OF FOGGIA, FOGGIA, ITALY.; (b) CARDIOTHORACIC DEPARTMENT, POLICLINICO RIUNITI UNIVERSITY HOSPITAL, FOGGIA, ITALY.; (c) DEPARTMENT OF PHARMACY AND DRUG SCIENCE, UNIVERSITÀ ALDO MORO, BARI, ITALY.

Introduction. Spontaneous coronary artery dissection (SCAD) is a relatively rare condition that mainly affect young adults, with a prevalence of female sex. Over the last years, the reported incidence rates of SCAD have been variable but increasing. The best management choice in SCAD is not yet defined and not based on evidence both in the acute phase but above all in the long term. However, as SCAD affects relatively young patients, long-term management is a major challenge. Our aim was therefore to evaluate the impact of the medical therapy usually used for coronary artery disease on the long-term outcome in patients with SCAD.
Methods. We performed a meta-regression analysis including all studies on long-term outcome of patients with SCAD. Studies not reporting the percentage at least one cardiovascular drug on discharge were excluded. We used long-term mortality, recurrent SCAD, hospitalization for angina, and major adverse cardiovascular events (MACE: mortality, myocardial infarction, ischemic stroke, hospitalization) as dependent variables, and the rates of beta-blockers, statins, renin- angiotensin-aldosterone system inhibitors, aspirin, dual antiplatelet therapy (DAPT), nitrates and calcium channel blockers at discharge as independent variables; the regression was weighted by study size.
Results. Fourteen observational studies with a long-term follow-up of 3.48±1.69 years were included. What we have noticed is that there is no statistically significant relationship between medical therapy (beta-blockers, statins, calcium channel blockers, nitrates, renin-angiotensin-aldosterone inhibitors) and mortality, MACE, hospitalization for angina, re-SCAD. Nonetheless, aspirin was shown to have a statistically significant positive impact on hospitalization for angina ($p<0.05$), although no statistically significant association with mortality, MACE, and re-SCAD was identified. DAPT, on the other hand, showed a borderline association with a higher rate of re-SCAD ($p<0.068$).
Conclusions. This analysis showed that aspirin is associated with a positive impact on the long-term hospitalization rate for angina. We observed a trend for a harmful impact of DAPT on re-SCAD rates. In general, regarding the remaining drug therapy usually used for the treatment of coronary artery disease, there appears to be no impact with the long-term prognosis of SCAD patients.

A285: SHAPING THE ANESTHETIC APPROACH TO TRICVALVE IMPLANTATION: INSIGHTS FROM A CASE SERIES

Sara Dormio (a, d), Marina Pieri (a, d), Michele Morosato (b, d), Alessandro Belletti (a), Dario Silvestri (c), Matteo Montorfano (c, d), Fabrizio Monaco (a)
(a) DEPARTMENT OF CARDIOTHORACIC AND VASCULAR SURGERY, IRCCS SAN RAFFAELE SCIENTIFIC INSTITUTE, MILAN, ITALY; (b) CARDIOTHORACIC DEPARTMENT, IRCCS SAN RAFFAELE HOSPITAL, MILAN, ITALY; (c) INTERVENTIONAL CARDIOLOGY UNIT, IRCCS SAN RAFFAELE HOSPITAL, MILAN, ITALY; (d) VITA-SALUTE SAN RAFFAELE UNIVERSITY, MILAN, ITALY

Introduction. The TricValve System presents a novel, minimally invasive strategy for managing severe tricuspid regurgitation (TR) in high-risk patients unsuitable for surgical or transcatheter orthotopic tricuspid valve (TV) repair or replacement. This case series aims to assess the anesthetic management challenges and outcomes associated with this procedure, seeking to generate insights that can inform and refine anesthetic protocols.
Methods. We conducted a retrospective review of patients who underwent TricValve implantation from December 2021 to March 2023 at San Raffaele Hospital, Milan. A systematic approach of pre-procedural planning and post-procedural debriefing was integrated to the management process. Pre-anesthesia setup involved establishing two large-bore peripheral venous accesses and an invasive radial arterial line. A fast-track general anesthesia protocol, utilizing propofol or midazolam for induction and sevoflurane for maintenance was implemented. Intra-operative management involved anesthesia depth monitoring, real-time guidance via transesophageal echocardiography (TEE) and regular arterial blood gas analysis. Hemodynamic stability was maintained through an emphasis on adequate perfusion pressure, and additional anesthesia or neuromuscular blocking agents were administered when required. Pain management was achieved via intravenous paracetamol, with additional opioid analgesics administered as needed.
Results. Eight patients with of symptomatic severe TR successfully underwent TricValve implantation during the study period, with a mean procedure duration of 112±44 minutes. Six patients had undergone previous cardiac procedures, and all had a history of atrial arrhythmia, including atrial fibrillation and atrial flutter. There were no anesthesia-related or implantation-related complications. Median hospital stay was four days, whereas brief Intensive Care Unit (ICU) monitoring was needed for one patient. Intravenous paracetamol served as the primary analgesic except for one patient with allergy, in which tramadol was administered. Post-operative right shoulder pain was reported by 50% of the patients, which was managed with morphine bolus administration (average dose 4,75±3.6 mg). Post-operative transthoracic echocardiograms confirmed correct device positioning in all patients. Upon discharge, none of the patients required outpatient analgesic therapy.
Conclusions. Our study demonstrates the potential of TricValve implantation in effectively managing severe tricuspid regurgitation, with no procedure-related complications and a 100% survival rate. A collaborative, interdisciplinary approach and targeted anesthesia management proved crucial for this success. Postoperative shoulder pain emerged as a frequent complication, whose pathogenesis is still not clear, and was successfully managed using targeted analgesic therapy.

A286: UN ARRESTO CARDIACO "ANOMALO"

Lorenzo Nocera (a), Lorenzo Brignone (a), Francesco Bruno (a), Fabrizio D´ascenzo (a), Gaetano Maria De Ferrari (a)
(a) DIVISION OF CARDIOLOGY, CARDIOVASCUAR AND THORACIC DEPARTMENT, "CITTÀ DELLA SALUTE E DELLA SCIENZA" HOSPITAL, TURIN, ITALY

Introduzione. Le anomalie delle arterie coronarie (CAA) sono un gruppo di condizioni congenite caratterizzate da un'origine o un decorso anomalo di una delle 3 arterie coronarie epicardiche principali. Sebbene le CAA siano state identificate come una condizione di base comune nei giovani atleti con morte cardiaca improvvisa, l'uso diffuso dell'imaging coronarico invasivo e non invasivo ha portato a un maggiore riconoscimento delle CAA tra gli adulti. I correlati clinici e le implicazioni prognostiche delle CAA rimangono poco conosciuti in questo contesto e le scelte terapeutiche raccomandate dalle linee guida sono supportate da un basso livello di evidenza scientifica. Diversi studi hanno esaminato se la valutazione dell'ischemia miocardica correlata alle CAA possa migliorare la stratificazione del rischio in questi pazienti, suggerendo che l'imaging multimodale e i test funzionali possono essere fondamentali nella gestione delle CAA.
Caso clinico. Riportiamo il caso di un uomo di 45 anni, sportivo agonista in regolare follow-up medico annuale, senza precedenti cardiologici che si presenta con arresto cardiocircolatorio (ACC) in corso di fibrillazione ventricolare come prima manifestazione clinica occorsa nella fase di riposo a seguito di attività fisica podistica della durata di circa un'ora con ottenimento di ROSC dopo 7-8 minuti. All'ECG eseguito dopo ACC assenza di evidenza di sovraslivellamento del tratto ST con preservata funzionalità ventricolare all'ecocardiografia TT. Esclusione alla TC encefalo e toracica di cause extracardiache di ACC. Alla coronarografia eseguita tre giorni dopo l'evento indice, riscontro occasionale di origine anomala della coronaria di destra. All'ulteriore approfondimento diagnostico con coro-TC (Figura) evidenza di decorso interarterioso associato ad anomalie anatomiche ad alto rischio dell'ostio della coronaria di destra. A seguito di tale reperto il paziente veniva indirizzato ad intervento cardiochirurgico correttivo con anastomosi termino-laterale dell'arteria mammaria interna di destra (AMID) al tratto medio della coronaria destra e legatura della stessa all'origine.
Conclusioni. Nel caso preso in esame, la coronarografia non è stata la prima scelta dal momento che, seppur la cardiopatia ischemica rappresenti il principale motivo di ACC, non vi erano evidenze di STEMI all'ECG post ROSC. Di conseguenza il procrastinare tale indagine ha permesso di concentrarsi su eventuali altri cause life-threating (extracardiache/tossicologiche). In ultimo, la coro-TC ha avuto il fondamentale ruolo di caratterizzare il tipo di anomalia classificandola come "ad alto rischio" per

ACC. In virtù di ciò e della presentazione clinica si soprassedeva ad ulteriori indagini di tipo funzionale. Per la stessa ragione, in considerazione della reversibilità della causa, non è stato proposto l'impianto di ICD. Il paziente verrà monitorato con appropriati test di ischemia e di controllo del burden aritmico per la valutazione dell'idoneità all'attività sportiva di tipo agonistico.

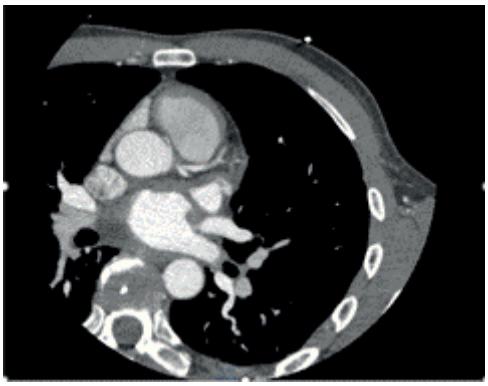

A287: PROGNOSTIC SIGNIFICANCE OF TRISCORE IN PATIENTS UNDERGOING TRANSCATHETER TRICUSPID VALVE INTERVENTION: INSIGHTS FROM THE TRIVALVE REGISTRY

Edoardo Pancaldi (a), Marianna Adamo (a), Matteo Pagnesi (a), Marco Metra (a)
(a) DIPARTIMENTO DI SPECIALITÀ MEDICHE E CHIRURGICHE, SCIENZE RADIOLOGICHE E SALUTE PUBBLICA, UNIVERSITÀ DI BRESCIA

Background. Data on the prognostic role of TRISCORE in patients undergoing transcatheter tricuspid valve intervention (TTVI) are limited.
Objectives. The aim of this study was to evaluate the performance of TRISCORE in predicting clinical outcomes at early and mid-term follow-up in large cohort of patients undergoing TTVI.
Methods. TriValve is a a large multicenter multinational registry including patients undergoing TTVI by using multiple devices. The TRISCORE is a risk model recently proposed to predict in-hospital mortality after tricuspid valve surgery. TriValve population was stratified based on TRISCORE tertiles. Outcomes of interest were all-cause death, all-cause death or heart failure hospitalization and changes in NYHA class.
Results. Among 634 patients included, 223 patients (35.2%) had a TRISCORE between 0 and 5, 221 (34.8%) had 6 or 7, and 190 (30%) had>8 points. As expected, patients with higher TRISCORE had more comorbidities. Post-procedural blood transfusion, acute kidney injury, new atrial fibrillation and in-hospital mortality were more frequent in the highest TRISCORE tertile. Post-procedure length of stay increased with TRISCORE increase. TRISCORE>8 was associated with an increased risk of 30-day all-cause mortality, and mid-term (median follow-up 186 days) all-cause mortality and composite endpoint (OR 3.00, 95% CI [1.38-6.55]; HR 2.17, 95% CI [1.78-4.13]; HR 2.08, 95% CI [1.57-2.74] respectively) even after adjustment for procedural success and EuroSCORE II or STS-PROM. Improvement in NYHA class were observed regardless of TRISCORE.
Conclusions. In the TriValve registry, a TRISCORE>8 is associated with an increased risk of early and mid-term clinical events after TTVI.

A288: PREVALENCE AND PROGNOSTIC SIGNIFICANCE OF MALNUTRITION IN PATIENTS WITH SECONDARY MITRAL REGURGITATION UNDERGOING TRANSCATHETER EDGE-TO-EDGE REPAIR

Elisa Pezzola (a), Marianna Adamo (a), Daniela Tomasoni (a), Matteo Pagnesi (a), Marco Metra (a)
(a) UNIVERSITÀ DEGLI STUDI DI BRESCIA - SPEDALI CIVILI DI BRESCIA

Background andAims. Malnutrition is associated with poor prognosis in several cardiovascular diseases; however, its role in patients with secondary mitral regurgitation (SMR) is poorly known. The aim of this study is to evaluate the impact of nutritional status, assessed using different scores, on clinical outcomes in patients with SMR undergoing transcatheter edge-to-edge repair (TEER) in a real-world setting.
Methods and Results. A total of 658 patients with functional MR and complete nutritional data were identified from the MIVNUT registry. Nutritional status has been assessed using the Controlling Nutritional Status Index (CONUT), the Prognostic Nutritional Index (PNI), and the Geriatric Nutritional Risk Index (GNRI) scores, revealing any degree of malnutrition in 79.4%, 16.7% and 47.9% of patients respectively, and moderate to severe malnutrition in 24.7%, 16.7% and 25.6% of patients respectively. At a median follow-up of 2.2 years, 212 patients (32,2%) died. Moderate-severe malnutrition was associated with a higher rate of all-cause mortality (HR 2.46 [95% CI 1.69-3.58], HR 2.18 [95% CI 1.46-3.26], HR 1.97 [95% CI 1.41-2.74] for CONUT, PNI and GNRI scores respectively). The combined secondary endpoint of all-cause mortality and HF rehospitalization occurred in 306 patients (46,5%). Patients with moderate-severe malnutrition had a higher risk of the composite endpoint (HR 1.56 [95% CI 1.20-2.28], HR 1.55 [95% CI 1.01-2.19], HR 1.36 [95% CI 1.02-1.80] for CONUT, PNI and GNRI scores respectively). After adjustment for multiple confounders, moderate-severe malnutrition remained independently associated with clinical outcomes.
Conclusions. Moderate-severe malnutrition was common in patients with SMR undergoing TEER. It was independently associated with poor prognosis regardless of different scores used.

A289: EFFICACIA E SICUREZZA DEI DISPOSITIVI DI CHIUSURA VASCOLARE PER ACCESSI DI TIPO VENOSO NEI PAZIENTI SOTTOPOSTI A CHIUSURA PERCUTANEA DELL'AURICOLA SINISTRA E DI FORAME OVALE PERVIO

Gianluca Pillitteri (a), Pierluigi Merella (a), Giovanni Lorenzoni (a), Giuseppe Talanas (a), Cristiana Denurra (a), Gavino Casu (a)
(a) AOU SASSARI

Introduzione. I dispositivi di chiusura vascolare hanno dimostrato una significante riduzione delle complicanze post-procedurali legate alla sede di accesso venoso e una rapida ripresa alla deambulazione, con conseguente riduzione dei giorni di ricovero.
Materiali e metodi. Nel nostro centro, è stato condotto uno studio prospettico ed osservazionale nel periodo tra gennaio e settembre 2023. Sono stati arruolati pazienti sottoposti ad intervento di chiusura percutanea dell'auricola sinistra o chiusura del forame ovale. L'accesso vascolare è stato ottenuto con supporto ecografico e la successiva emostasi è stata raggiunta utilizzando il dispositivo Perclose Prostyle.
Risultati. Sono stati reclutati 71 pazienti con un'età media di 69.09 anni (± 15.7). Il campione è formato per il 61% (n=43) di pazienti di sesso maschile. La chiusura percutanea dell'auricola sinistra è stata eseguita in 51 pazienti (71.8%), affetti da fibrillazione atriale (FA) con un'età media di 77.5 anni (± 7.01). All'interno di questo gruppo, 41 pazienti (80%) sono stati sottoposti alla procedura per FA ad alto rischio di sanguinamento, 8 pazienti (16%) per FA ad alto rischio trombotico, 2 pazienti (4%) per FA associata a malformazioni artero-venose o angiopatia amiloide. I dispositivi utilizzati sono stati: Amplatzer Amulet (n=27, 53%), Watchman FLX (n=11, 21.5%), LAmbre (n=11, 21.5%) e Omega (2 pazienti, 4%). La chiusura, per via percutanea, del forame ovale è stata eseguita in 20 pazienti (28%), con un'età media di 47.55 anni (± 9.9). In questo gruppo, 12 pazienti (60%) ha avuto un ictus ischemico, mentre 8 pazienti (40%) hanno riportato un'episodio di attacco ischemico transitorio (TIA). I dispositivi di chiusura vascolare sono stati efficaci, garantendo un'emostasi immediata, nel 92% (n=65). Nell'8% dei casi (n=6) è stato registrato un fallimento del dispositivo. In 5 pazienti è stato necessario eseguire una medicazione compressiva per raggiungere l'emostasi, mentre in un singolo caso è stata necessaria la realizzazione di un punto "ad 8". La mobilizzazione dei pazienti è avvenuta nel 56% dei casi (n=40) nelle prime 12 ore. Nel restante 44% dei casi (n=31) è stata, comunque, ottenuta nel corso delle 24 ore successive alla procedura. Complicanze potenzialmente associate al dispositivo di chiusura vascolare sono state registrate in soli 3 casi (4%): un caso di severa anemizzazione con necessità ad eseguire emotrasfusioni, un caso di stenosi vascolare in corrispondenza della sede di accesso vascolare ed un caso di vasto ematoma. I giorni medi di ospedalizzazione nei pazienti sottoposti a tali procedure interventistiche sono stati di 3.28 giorni.
Conclusioni. Sulla base della nostra esperienza, l'utilizzo di dispositivi di chiusura vascolare, utilizzati per le procedure percutanee con accesso vascolare di tipo venoso ha permesso il raggiungimento di una rapida emostasi con un basso tasso di complicanze vascolari.

A290: CHIUSURA PERCUTANEA DI DIFETTI INTERATRIALI MULTI-FENESTRATI IN ETÀ PEDIATRICA

Francesco Prati (a), Elena Cuppini (a), Biagio Castaldi (a), Domenico Sirico (a), Giovanni Di Salvo (a)
(a) UNIVERSITÀ DEGLI STUDI DI PADOVA

Introduzione. I difetti interatriali (DIA) sono una delle più comuni patologie riscontrabili all'interno delle cardiopatie congenite. La chiusura percutanea di tali difetti risulta oggigiorno la tecnica di scelta, in quanto ha dimostrato di avere buoni risultati in termini di efficacia ed un numero di complicanze inferiori se rapportata alla chiusura chirurgica.
Obiettivi. Valutare l'efficacia, in termini di shunt residui, e la sicurezza, in termini di complicanze procedurali e post procedurali, della chiusura di DIA multi-fenestrati, con singolo device e con doppio device.
Materiali e metodi. Nel centro di cardiologia pediatrica di Padova dal 1/01/2020 al 31/05/2022 sono state eseguite 110 procedure di chiusura di difetti interatriali per via percutanea. La valutazione pre-operatoria dei pazienti è stata basata su ecocardiografia trans-toracica e trans-esofagea 2D e 3D. In fase intra-operatoria è stata eseguita sia una valutazione basata su ecocardiografia trans-esofagea 2D e 3D che fluoroscopica. La valutazione post-operatoria, basata su ecocardiografia trans-toracica 2D, ha preso in considerazione la presenza di shunt residui valutati a 24 ore e dopo 6 mesi dal posizionamento dei device. I device usati, singoli o multipli, scelti in base alle caratteristiche anatomiche e del paziente sono stati: GORE® Cardioform ASD Occluder (GCA), GORE® Cardioform Septal Occluder (GSO), Occlutech ASD Occluder e Amplatzer™ Septal Occluder.

Risultati. La procedura è stata efficace in tutti i 110 pazienti arruolati. È stato utilizzato un device Amplatzer™ Septal Occluder in 17 casi, Occlutech ASD Occluder in 24 casi, GORE® Cardioform Septal Occluder in 33 e GORE® Cardioform ASD Occluder in 36 pazienti. Il setto risultata multi-fenestrato in 16 casi (14,5%). Per la chiusura di tali difetti si è utilizzato un doppio device in 4 casi (GCA+GSO nel totale dei casi). Nei restanti 12 pazienti si è ottenuta una occlusione con singolo device (GCA 5 casi 41,7%; nei restanti 7 casi GSO 58,3%) mediante sovradimensionamento rispetto al sizing del difetto principale. A 24 ore la prevalenza di shunt residuo era 18,75% nei multifenestrati vs 97% nei difetti singoli, a sei mesi non vi erano shunt residui in entrambi i gruppi.
Conclusioni. In età pediatrica i DIA multi-fenestrati sono relativamente frequenti. Quando questi vengono trattati in età pre-adolescenziale, le dimensioni assolute del setto permettono la chiusura completa dei difetti con un singolo dispositivo in circa il 75% dei casi. Viceversa se ciò non risulti fattibile, l'utilizzo di un secondo dispositivo di piccole dimensioni si è dimostrato essere una strategia, valida, sicura ed efficace a correggere tale difetto.

A291: USO DEL CATETERE AMPLAZER TORQVUE LP PER L'IMPIANTO DI STENT CORONARICI IN DOTTI ARTERIOSI DI NEONATI CON CARDIOPATIE CONGENITE DOTTO-DIPENDENTI

Francesco Prati (a), Biagio Castaldi (a), Domenico Sirico (a), Gioavanni Di Salvo (a)
(a) UNIVERSITÀ DEGLI STUDI DI PADOVA

Il posizionamento percutaneo di stent coronarici nel dotto arterioso pervio (PDA) è una procedura palliativa neonatale, alternativa al posizionamento di shunt chirurgici, consolidata utilizzata sia in cardiopatie congenite semplici che complesse con dotto-dipenenza polmonare. Nella pratica clinica vengono generalmente utilizzati stent coronarici, che richiedono un basso profilo, un introduttore 4 Fr o un catetere guida 5 Fr. In Letteratura sono descritte varie tecniche d'impianto: nudo, con l'ausilio d'Introduttore lungo, o di un catetere guida 5 Fr. La scelta tra minor supporto e maggior invasività dell'accesso vascolare è sempre cruciale, in quanto da un lato si aumenta il rischio di fallimento procedurale, dall'altro si incrementa il rischio di danno vascolare, in soggetti di basso peso che saranno sottoposti a numerosi altri cateterismi cardiaci durante il corso della loro vita. Scopo dello studio è valutare la fattibilità dell'utilizzo del catetere Amplatzer™ TorqVue LP™ (catetere LP) per l'impianto di stent coronarici in dotti arteriosi con anatomie complesse.
Materiali e metodi. Nel centro di cardiologia pediatrica di Padova dal 01/05/2023 al 09/09/2023 sono state eseguite 2 procedure di impianto di stent coronarici con l'ausilio del catetere LP in neonati affetti da cardiopatia congenita con circolazione polmonare dotto dipendente e complessa anatomia duttale. La valutazione preoperatoria si è basata su ecocardiografia trans toracica mentre la fase operatoria si è svolta presso la sala di emodinamica con guida fluoroscopica. La valutazione post operatoria a 24 e 48 ore dal posizionamento dello stent si è composta sia di valutazione clinica che ecocardiografica: dal punto di vista clinico si è considerato il valore della saturazione percentuale di ossigeno nel sangue misurata tramite posizionamento di saturimetro al piede sinistro del paziente; mentre dal punto di vista ecografico è stato considerato corretto posizionamento dello stent in termini di: flusso di sangue intra stent, ostruzione del flusso o presenza di accellerazioni o turbolenze di nuova insorgenza del flusso sanguineo sul versante aortico e sul versante polmonare. I dispositivi coronarici scelti in base alle caratteristiche biometriche ed anatomiche dei pazienti sono stati Rebel™ Stent.
Risultati. Entrambi i pazienti avevano un peso <3.5kg al momento della procedura. Le PGE1, avviate alla nascita, sono state sospese 4h prima della procedura interventistica. La procedura è stata eseguita da arteria femorale in un caso, dalla carotide sinistra nell'altro. La morfologia era tortuosa per entrambi. Le misure degli stent (Rebel®) utilizzati sono stati: 4x20mm; 3.5x16mm. Alle valutazioni post operatorie a 24 e 48 ore l'ecocardiografia mostrava stent ben posizionati nei margini duttali con flussi laminari al loro interno e non ostruzione ai flussi aortico e polmonare, il controllo saturimetrico mostrava ottime saturazioni compatibili con la cardiopatia di base.
Conclusioni. Nella nostra esperienza, l'utilizzo di un catetere Torque LP coniuga le esigenze di supportività e di basso profilo sull'accesso vascolare ed in definitiva una minore traumaticità sul vaso. Un ulteriore vantaggio è data dalla possibilità di un'esecuzione seriata o contestuale all'impianto di stent di angiografie, il che può garantire tempi di esecuzione procedurale rapidi e un più fruibile controllo della posizione dello stent stesso. In aggiunta nel caso di anatomie duttali complesse l'utilizzo del catetere LP e microcatetere con tecnica "mother in child" può rendere possibile l'impianto anche in pazienti dove le altre tecniche non lo permetterebbero.

A292: CORONARY FLOW AT REST AND CLINICAL OUTCOMES IN DILATED CARDIOMYOPATHY

Alessandra Roccabruna (a), Leonardo Portolan (a), Eleonora Bonvicini (a), Roberto Scarsini (a), Martina Setti (a), Luca Ciceri (a), Matteo Pilan (a), Paolo Springhetti (a), Giovanni Benfari (a), Flavio Luciano Ribichini (a), Gabriele Pesarini (a), Margherita Fabroni (a), Stefano Andreaggi (a)
(a) U.O.C CARDIOLOGIA, AZIENDA OSPEDALIERA UNIVERSITARIA INTEGRATA DI VERONA

Background and Objectives. Reduced coronary flow reserve (CFR) was described in dilated cardiomyopathy (DCM). In fact, to match increased metabolic demand from the myocardium, resting coronary flow (rCF) increases with consequent CFR exhaustion. Whether an increased rCF causing a reduction of CFR is associated with worse clinical outcomes in DCM remains debated. In this study, we aim to assess the prognostic role of rCF evaluated at the invasive coronary angiography (ICA) performed per standard clinical practice at the time of diagnosis at long-term follow-up in dilated cardiomyopathy.
Methods. This is a retrospective analysis of a prospective cohort of patients with idiopathic DCM under medical management enrolled in the Verona Heart Failure registry (University Hospital of Verona) between 01/2012 and 12/2022. RCF is inversely correlated to the resting mean transit time (mtt) required for blood to pass through the coronary artery. A reliable surrogate of mtt is the ratio n frames/frame rate where n frames are the number of frames required for the dye to reach standard distal landmarks of coronary arteries and frame rate is the frame rate acquisition. RCF was calculated offline based on ICA performed at the time of diagnosis as RCF=1/(n frames/frame rate). The primary endpoint of the study was a composite of cardiovascular death, rehospitalization for heart failure, resuscitated cardiac arrest, hemodynamically unstable ventricular arrhythmias, appropriate implanted cardiac defibrillator (ICD) intervention and cardiac transplantation due to advanced heart failure.
Results. Overall, 110 patients with idiopathic DCM were enrolled in the study. Fifteen patients (13.6%) met the primary endpoint at a median follow-up time of 42 months (IQR 18-71). At the ROC curve analysis RCF predicted the primary endpoint with an AUC of 0.728 (0.599-0.858, p=0.005). The ROC derived best RCF cut-off was 2.32 with sensitivity, specificity, negative predictive value and positive predictive value of 73.3%, 69.5%, 94.3% and 27.5% respectively. Patients suffering the primary endpoint tended to be older (66 years [60-74] vs 59 years [51-69], p=0.060) and were characterized by an increased rCF (3 [1.87-3.75] vs 1.87 [1.36-2.5]). Patients with rCF <2.32 suffered the primary endpoint more frequently when compared to patients with rCF ≥2.32 (27.5% vs 5.7%, log rank test p=0.007).
Conclusions. Increased resting coronary flow is associated with worse clinical outcomes at long term follow-up in idiopathic dilated cardiomyopathy. Whether coronary microvascular dysfunction plays a prognostic role in patients with DCM remains to be explored in dedicated prospective studies.

A293: EARLY ATRIAL FIBRILLATION (AF) AFTER PERCUTANEOUS PATENT FORAMEN OVALE (PFO) CLOSURE: CORRELATION WITH PFO ANATOMY AND RESIDUAL SHUNT

Claudia Rubino (a), Giovanni Taverna (a), Simona Ceratti (a), Giuseppe Certo (a), Nastasia Mancini (a), Vincenzo Calabrese (b), Pasquale Crea (a), Giampiero Vizzari (a), Maurizio Cusmà Piccione (a), Francesco Costa (a), Scipione Carerj (a), Gianluca Di Bella (a), Giuseppe Andò (a), Antonio Micari (a), Concetta Zito (a)
(a) DEPARTMENT OF CLINICAL AND EXPERIMENTAL MEDICINA-CARDIOLOGY UNIT-UNIVERSITY OF MESSINA, MESSINA, ITALY; (b) UNIT OF NEPHROLOGY AND DIALYSIS, DEPARTMENT OF CLINICAL AND EXPERIMENTAL MEDICINE, UNIVERSITY OF MESSINA, MESSINA, ITALY

Introduction. The foramen ovale is a communication in the interatrial septum that is physiologically present during intrauterine development of the fetus. In approximately 75% of individuals this communication spontaneously undergoes closure within the first few years of life, but in 25% of the population this does not occur, resulting in the condition known as a patent foramen ovale (PFO). In most cases it does not pose a danger to patient survival, but percutaneous closure is currently performed in patients with paradoxical embolism, cryptogenic stroke, decompression sickness, and pulmonary disease associated with hypoxemia. Despite the safety of treatment, a potential adverse event appears to be early (1-6 months) occurring atrial fibrillation (AF) after device implantation.
Methods. In this prospective cohort study, we included 113 patients who underwent percutaneous PFO closure, according to recent GL, between July 2020 and August 2023. Among these, 45% patients suffered from hypertension, 43% from dyslipidemia, 7% from diabetes, 32% were smokers. Our study aims to correlate the incidence of post-procedural AF (evaluated with in-hospital FUP, phone clinical interview and a 24-hour ECG Holter 1 month after procedure) with age, PFO anatomy [particularly PFO size and tunnel length (mm)], presence and severity of residual shunt (0 no shunt, 1 1-20 MES, 2>20 MES) and device features (small, medium and large device) in a 6-month follow-up. We split sample into two groups, based on the AF events for 6 months follow-up. Group A included patients without AF events (n=104), and group B included patients who manifested AF events (n=8).
Results. Age (50±12 vs 62±10, p=0.01), tunnel length (12 [9-12] vs 15 [12/24], p=0.07), PFO size (3.25 [2.65/1.13] vs 5 [4/6.5], p=0.01) and residual shunt (0.0 [0.0/1.0] vs 0.5 [0.0/2.0], p=0.04) appeared to be significant different between Group A and Group B. Correlation analysis showed a significant direct correlation between AF and age (Rho=0.27; p=0.01), PFO size (Rho=0.30; p=0.01), tunnel length (r=0.24; p=0.07) and residual shunt (Rho=0.20; p=0.04). On the logistic regression mo-

del, residual shunt at 6 months increased the risk of AF (OR=2.66, 95%IC 1.13/6.29, p=0.03).
Conclusions. According to the recent literature, the incidence of onset AF in our sample of patients after PFO closure was low (<5%). Moreover, it was possible to confirm that older patients and more complex PFO anatomy are associated with a higher prevalence of AF events during follow-up. Finally, a residual shunt seems to increase the likelihood of new onset AF. Nevertheless, further studies are needed to verify/compare our results.

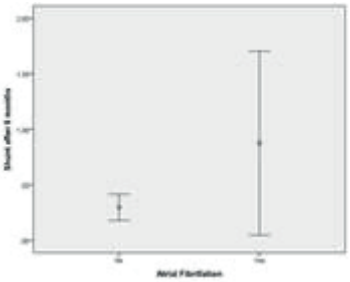

A294: BALLOON FRACTURE IN TAVR: A CASE REPORT OF DELIVERY SYSTEM RECAPTURE USING FULL ENDOVASCULAR TECHNIQUE

Massimo Russo (a), Enrica Mariano (a), Marco Di Luozzo (a), Benedetto Daniela (a), Marchei Massimo (a), Gaetano Chiricolo (a), Giuseppe Massimo Sangiorgi (a)
(a) U.O.C. CARDIOLOGIA POLICLINICO "TOR VERGATA"

Introduction. Transcatheter aortic valve implantation (TAVI) is a promising technique for high-risk or inoperable patients who are not candidates for conventional surgical aortic valve replacement because of old age and other comorbidities and severe fragility. Rupture of the aortic balloon during TAVI is a rare complication that can be observed during valvuloplasty just before valve deployment or balloon-expandable device implantation.
Case summary. This case report concerns a 74-year-old Caucasian male affected by hypertension, dyslipidemia, diabetes and obesity. In December 2020 he was hospitalized for an episode of heart failure following diagnosis of hypokinetic dilated heart disease, complicated by atrial fibrillation with rapid ventricular response. During hospitalization, concomitant aortic stenosis was documented. Subsequently, in 2021 a coronary CT scan was performed because of angina showing the absence of significant coronary artery plaques. In January 2023, during a cardiological check-up, a TTE showed mild concentric LV hypertrophy with dyssynergia and mild hypokinesia of the interventricular septum (estimated EF 50%); tricuspid aortic valve with calcific-degenerative changes leading to mild-moderate insufficiency and severe-grade stenosis (G med 49 mmHg, G max 70 mmHg). The case was discussed in the Heart Team and indication for TAVI was posed. In June 2023 the patient was admitted to our cardiology department and underwent Edwards Sapien 3 29 mm prosthetic valve implantation procedure. Preprocedural planning was prepared with computed tomography. The procedure was anesthesia-free. After standard aortic valve crossing, when the valve was released, the inflation pressure decreased rapidly due to the balloon bursting. The balloon catheter was immediately pulled back into the descending aorta. Its two edges had the shape of two facing parachutes. Although the proximal could be easily withdrawn into the sheath, the distal one prolapsed over the sheath edge and could not be further retracted back into the delivery system. After several attempts of snaring, the balloon was captured in a contralateral Dryseal 18 F introducer after positioning two Prostyles in the left femoral artery, using a double loop, and cutting the catheter shaft to allow reintroduction into its dilator. No complications occurred after the procedure. The patient was discharged asymptomatic after five days.
Conclusions. Balloon fracture during TAVR is a nightmare complication that is to be managed with care, avoiding some worst consequences like emergency cardiosurgical intervention. The knowledge of the exact internal structure of the delivery balloon is crucial to provide the chance of a complete endovascular solution to this complication.

A295: CASO DI SHOCK CARDIOGENO IN IMA AD ARRIVO TARDIVO: APPROCCIO INTEGRATO DI GESTIONE DEL PAZIENTE CRITICO TRA CENTRO SPOKE E CENTRO HUB

Stefano Siliano (a), Francesco Bruno (a), Fabrizio D´ascenzo (a), Gaetano Maria De Ferrari (a)
(a) DIVSION OF CARDIOLOGY, CARDIOVASCULAR AND THORACIC DEPARTMENT "CITTÀ DELLA SALUTE E DELLA SCIENZA" HOSPITAL, TURIN, ITALY

Lo shock cardiogeno (CS) è uno stato emodinamico complesso caratterizzato da una disfunzione cardiaca che può essere provocata da varie cause, nella maggior parte dei casi l'evento scatenante è un infarto miocardico acuto (IMA). In alcuni scenari lo shock cardiogeno può essere accompagnato da uno stato settico severo, andando a configurare un quadro di shock misto.
Caso clinico. Uomo di 46 anni con CAD nota bivasale esordita con IMA, noto diabete mellito di tipo II complicato da piede diabetico, fumatore attivo. Si presentava in DEA per dispnea ingravescente da tre giorni (NYHA IV); all'arrivo paziente in CS SCAI C associato a componente settica a partenza da ulcere degli AAII. All'ECG tachicardia sinusale a 120 bpm e fibrosi inferiore. All'ecocardiogramma TT severa disfunzione biventricolare (FE15%), LVOT VTI 7 cm, insufficienza mitralica (IM) di grado severo, VCI dilatata, LUS score 3. Avviato trattamento con dobutamina, diuretico ev e NIV con beneficio clinico; decorso complicato da EPA ipoteso. Condotto in sala di emodinamica per posizionamento di IABP tramite accesso femorale destro; seguiva studio coronarografico con riscontro di CTO di CDx II con circolo collaterale omo ed etero-coronarico, Cx subocclusa distalmente, RI di calibro importante con stenosi serrata prossimale, IVA diffusamente critica e calcifica. Successiva stabilità emodinamica. In considerazione dell'inotropo-dipendenza e della necessità di rivascolarizzazione percutanea ad alto rischio con supporto meccanico, il paziente veniva trasferito presso il nostro Centro di III livello. Tramite accesso femorale sinistro e previo posizionamento di due Proglide, eseguito impianto di Impella CP. Procedura IVUS guidata con iniziale stenting di Ramo Intermedio (RI) ostiale; successiva predilatazione con palloni NC e litotrissia intracoronarica su lesione di IVA prossimale. Durante l'erogazione di shockwaves evidenza di perdita di pulsatilità aortica per un minuto circa con linea arteriosa piatta e completa dipendenza da Impella che apportava un flusso di 3.8 l/min. Successivo impianto di stent in overlap su asse TC-IVA; eseguita POT su asse TC/IVA e rewiring di RI con successivo kissing balloon su TC-IVA e RI. Evidenza all'IVUS di guida del RI fuori dalle maglie dello stent di TC per cui eseguita Re-POT e succesivo re-wiring di RI nelle maglie dello stent, confermato anche all'IVUS, per cui si procedeva a FKB e POT finale. Emodinamica stabile in corso di Impella CP con residua CTO di Cdx e Cfx distale. Successivo svezzamento da supporto meccanico in III giornata e lenta introduzione di terapia anti-scompenso. FE alla dimissione 22%.Si dimetteva il paziente presso struttura di riabilitazione cardiologica con indicazione a successiva rivalutazione della strategia di rivascolarizzazione di CTO di Cdx e Cfx.
Conclusioni. Il caso clinico ha mostrato come la connessione fra centro Spoke e Hub sia fondamentale, dalla stabilizzazione in fase acuta del paziente critico nel centro inviante alla successiva centralizzazione dei pazienti. Si sottolinea l'importanza del supporto meccanico in pazienti con necessità di angioplastiche complesse ed alta probabilità di perdita di pulsatilità. In ultimo, l'importanza dell'imaging intracoronarico come strumento per caratterizzazione dell'estensione di placca, nella guida dell'operatore nella scelta del corretto sizing dei palloni e stent verificandone il risultato finale a seguito del loro utilizzo, infine strumento di verifica nei numerosi passaggi delle varie tecniche di rivascolarizzazione, specialmente in quelle riguardanti le biforcazioni.

A296: CORONARY ARTERY FISTULA IN THE CONTEXT OF ACUTE CORONARY SYNDROME: INNOCENT BYSTANDER OR CULPRIT?

Roberto Tarantini (a), Mario Bollati (b), Marco Spagnolin (a), Jayme Ferro (b), Fausto Roccasalva (b), Vincenzo Ercolano (b), Dario Colombo (b), Pietro Mazzarotto (b)
(a) UNIVERSITÀ DEGLI STUDI DI PAVIA, PAVIA, ITALIA; (b) OSPEDALE MAGGIORE DI LODI, LODI, ITALIA

Aims. Coronary artery fistulas (CAFs) are anomalous communication between a coronary artery and a chamber of the heart or any segment of the systemic or pulmonary circulation bypassing the myocardial capillary bed. CAFs are diagnosed incidentally using echocardiography or coronary angiography because they are usually small without any symptoms. On the other hand, a large CAF is approximately three times the size of a normal calibre of a coronary artery and could be responsible for the presence of angina due to steal of coronary artery.
Clinical case. A 50-year-old man without history of cardiovascular disease was admitted to the emergency department for typical chest pain. Electrocardiography showed no ST alteration suggestive of ischemia, but there was a progressive rise in troponin I levels (16>28 ng/ml). Echocardiography revealed preserved LVEF without major regional wall motion but only mild dilatation of the right atrium. Considering the symptom and the troponin rise, the patient was sent to the Cath Lab to undergo coronary angiography (CAG). The examination revealed no obstructive lesions or significant coronary stenosis but showed a giant fistula between the circumflex artery and right atrium. Suspecting inducible ischemia, the patient underwent dobutamine stress echocardiography, but it was negative. Cardiac computed tomography (CT) was performed in order to better characterize the fistula and confirmed the communication between the circumflex artery and right atrium. Finally, right heart catheterization showed no pulmonary hypertension with normal wedge pressure, cardiac output (5.7 L/min) and pulmonary output (Qp/Qs 1.15).
Conclusions. Our case showed a potential cause of coronary ischemia; therefore, multimodality evaluation of this condition is mandatory to define the best management for the patient. There are no specific recommendations about surgical correction or transcatheter intervention: however, these techniques require several conditions such as favourable anatomy of the fistula. In this case, the patient was sent to follow-up considering the first episode and absence of inducible ischemia.

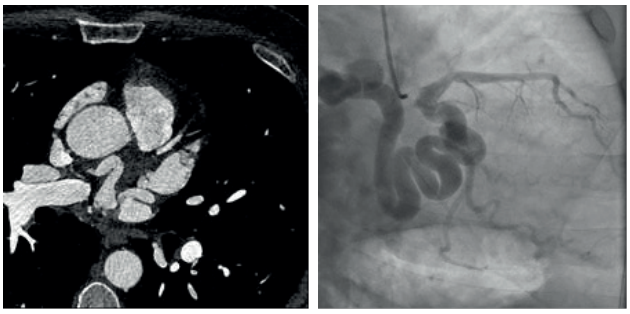

A297: MPV ECG RISK SCORE PREDICTING EARLY OCCURRENCE OF ATRIAL FIBRILLATION (AF) IN PATIENTS AFTER PATENT FORAMEN OVALE (PFO) PERCUTANEOUS CLOSURE

Giovanni Taverna (a), Claudia Rubino (a), Pasquale Crea (a), Lilia Oreto (b), Nastasia Mancini (a), Giampiero Vizzari (a), Simona Ceratti (a), Vincenzo Calabrese (c), Maurizio Cusmà Piccione (a), Francesco Costa (a), Scipione Carerj (a), Gianluca Di Bella (a), Giuseppe Andò (a), Antonio Micari (a), Concetta Zito (a)
(a) DEPARTMENT OF CLINICAL AND EXPERIMENTAL MEDECINE-CARDIOLOGY UNIT-UNIVERSITY OF MESSINA, MESSINA, ITALY; (b) DEPARTMENT OF CLINICAL AND EXPERIMENTAL MEDECINE-UOSD PAEDIATRIC CARDIOLOGY-UNIVERSITY OF MESSINA, MESSINA, ITALY; (c) DEPARTMENT OF CLINICAL AND EXPERIMENTAL MEDECINE-NEPHROLOGY AND DIALYSIS-UNIVERSITY OF MESSINA, MESSINA, ITALY

Introduction. The Patent foramen ovale (PFO) is a common embryologic remnant which allows for right to left shunting. Nowadays percutaneous closure is reserved to selected patients. Although the safety of the treatment, a potential adverse event seemed to be early atrial fibrillation (AF), often underestimated. The incidence of new-onset AF after PFO closure was reported in several studies but predictors of the increased risk after device closure are not well investigated.
Our study aims to evaluate predictive power of the MPV (Morphology-Voltage-P wave duration) ECG risk score on occurrence of AF in patients who underwent percutaneous closure.
Methods. We selected 102 patients (aged 18-65 years) who underwent percutaneous PFO closure, according to the current guidelines' indication, between July 2020-August 2023. The aim of the study was to evaluate the ability of MVP ECG risk score, calculated before and after PFO closure to predict post-procedural AF (evaluated with in-hospital FUP, phone clinical interview and a 24-Hour Holter ECG 1 month after procedure) at six-month FUP. This risk score included three P-wave variables: morphology in inferior leads (II-III-aVF), voltage in lead I, and P-wave duration.
We split sample into two groups, based on the AF events. Group A included patients without AF events (n=97), and group B included patients with early AF after PFO closure (n=5).
Results. Patients risk factors were hypertension (n=48), dyslipidemia (n=42), diabetes (n=6), smokers (n=34). MVP ECG risk score resulted significantly different between Group A and Group B (1.0[1.0/2.0] vs 3.0[2.5/4.0], p=0.001) before percutaneous PFO closure. The variables related to AF occurrence and ECG risk score were age (Rho=0.163, p=0.10), PFO dimension (Rho=0.241, p=0.047), and tunnel lenght (r=0.367, p=0.005). These variables were considered as confounding and included in the multivariate models. Multivariate logistic regression analysis showed only MVP risk score resulted in an adj OR of 2.71 (p=0.049), and the cox analysis showed an adj HR of 2.40 (p=0.001). Moreover, post hoc analysis showed a significant variation in PR length, comparing pre-procedure PR intervals, at 4th day post-procedure and at the 1-month follow up, with an increase of 43±15 ms in patients who suffered by paroxysmal AF (p=0.004).
Conclusions. The incidence of new-onset AF in our sample of patients after PFO closure was low (<5%) as reported in recent literature. MPV ECG risk score was the only independent predictor of early AF occurrence in patients undergoing percutaneous PFO closure. Nevertheless, further studies are needed to confirm our results.

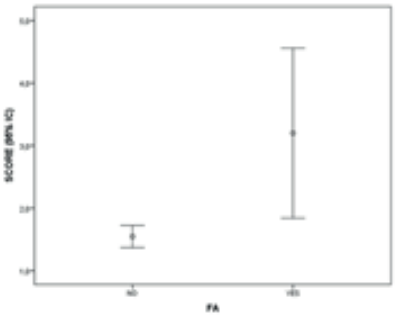

A298: CASE SERIES OF TRANSCATHETER EDGE-TO-EDGE REPAIR IN ACUTE MITRAL VALVE REGURGITATION DUE TO ACUTE PAPILLARY MUSCLE RUPTURE

Francesco Torlone (a), Matteo Della Torre (a), Luca Paolo Alberti (a), Davide Tavano (a), Elena Viganò (a), Flavio Airoldi (a), Roberto Franco Enrico Pedretti (b)
(a) INTERVENTIONAL CARDIOLOGY UNIT, MULTIMEDICA IRCCS, SESTO SAN GIOVANNI, MI; (b) CARDIOVASCULAR DEPARTMENT, MULTIMEDICA IRCCS, SESTO SAN GIOVANNI, MI

Introduction. Acute papillary muscle rupture (aPMR) is a rare complication of acute myocardial infarction (AMI) with high mortality and morbidity. The treatment of choice is surgery, but is burdened by a high perioperative mortality. Mitral valve transcatheter edge-to-edge repair (M-TEER) has emerged as an important therapeutic strategy for patients with severe and symptomatic mitral regurgitation (MR); however, data in patients with post-aPMR are limited.
Case summary. Two patients with acute MR due to aPMR associated with STEMI with delayed presentation successfully underwent M-TEER using MitraClip system at our centre.
Case report 1. A 66-year-old male was hospitalized for inferior STEMI with delayed presentation (24h after onset of symptoms); the echocardiogram performed in the emergency room showed a moderate LVEF reduction and a moderate functional MR. A Primary PCI+DES on right coronary artery (RCA) was performed; then there was a sudden intraprocedural deterioration: transesophageal echocardiography (TE) showed a massive MR due to posteromedial PMR. The perioperative mortality was high (Euroscore II 33%); given the high bleeding risk (patient already in DAPT), and the possibility of blood transfusion requirements the surgery was refused by relatives and patient himself (through advance healthcare directives) for religious cause. During the urgent Heart Team discussion, it was decided to perform a M-TEER. The procedure was completed successfully with no major complications, two MitraClip G4 XTW in medial and centromedial position was implanted. At 6- and 12-months follow-up the patient was asymptomatic (NYHA I functional class), with mild LVEF reduction and a residual mild to moderate MR.
Case report 2. A 82-year-old woman was hospitalized for anterior STEMI with delayed presentation; a primary PCI+DES on left anterior descending artery was performed; there was a residual proximal RCA stenosis. On the second post-operative day there was a hemodynamically deterioration with the development of cardiogenic shock. A TE was performed showing a massive MR due to anterolateral papillary muscle partial rupture. The emergency rescue cardiac surgery was burdened by a high perioperative mortality (Euroscore II 62.1%). Our Heart Team decided to perform a M-TEER: the procedure was completed successfully with no major complications, a single MitraClip G4 XTW in central position was implanted. Following TEER the MR significantly improved to moderate. In the follow up the patient completed the revascularization and went well.
Discussion. We have presented two clinical cases where, for different reasons, it was decided to perform the percutaneous intervention instead of the surgical approach. PMR is a rare and often fatal complication of AMI; it is described in 1% to 3%. Without surgical treatment, post-AMI acute PMR mortality can reach 80%; surgery is recommended as class I indication in guidelines; however, many patients are not treated due to excessively high mortality. M-TEER is a well-established therapeutic modality for stable patients with chronic MR, but patients with acute condition were excluded from clinical trials and most registries and data are limited to case studies. Our results show that M-TEER is feasible, safe and effective in the setting of aPMR; it could be considered as a destination therapy in patients unfit for surgery or as a bridge therapy to surgery. Dedicated registries and trials are needed to confirm the role of the procedure and to assess long-term results.

A299: A SUSPICIOUS ECG AND THE HELPFUL GUIDE OF INTRAVASCULAR IMAGING DURING ACUTE CORONARY SYNDROME

Michele Trichilo (a), Simone Biscaglia (a), Andrea Erriquez (a), Antonella Scala (a), Gianluca Calogero Campo (a)
(a) AZIENDA OSPEDALIERO-UNIVERSITARIA DI FERRARA

Clinical case. A 48 years-old woman with multiple cardiovascular risk factor (hypertension, dyslipidemia, active smoker) presented to our Emergency Department with ongoing chest pain. Electrocardiogram (ECG) showed ST segment elevation in DI and aVL and ST segment depression in inferior leads; the ECG pattern was consistent with South African Flag sign though an antero-lateral ST segment depression was observed in precordial leads. The patient was diagnosed with anterior ST segment elevation myocardial infarction (STEMI) and an emergent coronary angiography was performed. Right coronary artery (RCA) was first studied and revealed a long critic disease at the proximal tract, suspicious for spontaneous coronary artery dissection or vasospasm. Giving more relevance to the ECG left coronary system was studied and, since no critic lesion was identified, intracoronary imaging adopting Optical Coherence Tomography (OCT) was performed on Left Anterior Descending artery (LAD) and on first diagonal (DI). The OCT revealed an ulcerated plaque with apposed thrombus affecting the bifurcation involving LAD and DI, so that bifurcation stenting by means of mini-crush technique along wi-

th final kissing balloon and proximal optimization therapy was performed. Final angiographic result was evaluated with a further run of OCT, showing a good expansion and apposition; no post-procedural complications due to stenting such as medial dissection was identified. Finally, intracoronary nitrates were administered into the right coronary artery with subsequent restoration of the lumen caliber. The patient was then discharged with the diagnosis of a type I anterior STEMI.

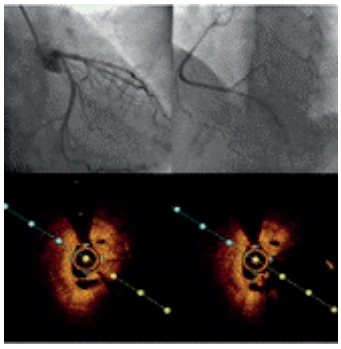

Discussion. Intracoronary imaging and in particular OCT has been emerging over the last years as a helpful tool to optimize percutaneous coronary intervention (PCI) and to identify culprit lesion in ambiguous clinical scenario, such as the one discussed in this clinical case. The ECG indeed suggested a culprit lesion located in the LAD or in the DI, though the ST segment depression in the antero-lateral precordial leads could have represented the presence of a coronary lesion located in the right coronary system. The coronary angiography suggested the presence of a critic lesion in the RCA, while the left coronary system seemed not affected by any critic atherosclerotic lesion. The use of OCT then revealed the location of the culprit lesion. The increasing role of OCT during acute coronary syndrome will allow interventional cardiologist to identify culprit lesions easier and to better optimize PCI, thus resulting in more favorable outcome with respect to an angiography-guided procedure.



A300: USE OF CANGRELOR IN STEMI TREATED WITH PPCI, PLUS DCB OF NON-CULPRIT OSTIAL LAD

Lorenzo Volpe (a), Fabiola Boccuto (a), Giovanni Martino (a), Chiara Messina (a), Alessandro Caracciolo (b), Annalisa Mongiardo (b), Sabato Sorrentino (a), Daniele Torella (a), Ciro Indolfi (a), Salvatore De Rosa (a)

(a) CARDIOLOGY DEPARTMENT, MAGNA GRAECIA UNIVERSITY, CATANZARO, ITALY; (b) CARDIOLOGY DIVISION, UNIVERSITY HOSPITAL, RENATO DULBECCO, CATANZARO, ITALY

Rationale: DAPT with ASA and oral P2Y12 receptor inhibitor represents the standard of care for patients with ACS treated with PCI. Cangrelor is the only currently available i.v. P2Y12-receptor inhibitor; it is characterized by potent, predictable and rapidly reversible antiplatelet effects, and it can be used in patients presenting without pre-treatment to briefly achieve a proper antiplatelet effect during PCI. The use of DCB is recently growing for multiple reasons, including those clinical settings where a minimization of antiplatelet treatment is desirable. The present case describes the usefulness of both cangrelor and DCB in a patient requiring major orthopedic surgery with clinical evidence of significant worsening of CAD.

Technical resolution. We present the case of a 72-yo man referred to our ED with the diagnosis of "STEMI in lateral region". Previous medical history included: PCI/DES in LAD artery and ID branch (three years previously), HTN, dyslipidemia, DM type 2, carotid atheromasia previously treated by TEA of the right ICA, COPD and right hip arthrosis for which the patient was already scheduled for arthroplasty surgery. Since home therapy did not include any antiplatelet drugs, interrupted for scheduled non cardiac surgery, we performed emergency ICA by administering ASA i.v. and cangrelor in addition to UFH. ICA revealed intra-stent occlusion of I D branch (culprit lesion) treated by pPCI with POBA with good final angiographic result. Moreover, ISR was observed in the site of previous stenting of LAD artery. At the end of the procedure the patient was transferred to our ICCU. At admission, blood tests showed a marked increase in myocardial necrosis markers. EKG showed partial improvement in ST elevation in the lateral leads, in line with the reported clinical improvement. TTE showed LVEF 40% Q; akinesia of the apex, middle segment of the anterior wall and posterolateral wall; increased wall thicknesses; mild MR. During hospitalization the patient had complete resolution of symptoms and a downward trend of necrosis markers. Continuous EKG monitoring detected NOAF during the 3rd day of hospitalization. In presence of ISR of LAD at the proximal edge of the stent, need for arthroplasty and NOAF, the planned staged PCI of the LAD ostium was performed by means of DCB with good final angiographic result. At discharge, therapy included PPIs, sacubitril-valsartan, metoprolol, spironolactone, dapagliflozin, rosuvastatin/ezetimibe, clopidogrel and rivaroxaban for one month.

Clinical perspectives. Cangrelor represents an ideal choice in ACS patients arriving at catheterization without antiplatelet therapy. As opposed to oral P2Y12-inhibitors, cangrelor has the pharmacokinetic advantage of reducing platelet reactivity within minutes of administration and returning normal platelet function within 30–60 min after treatment discontinuation due to a relatively short half-life. Such pharmacologic properties allow to overcome limitations of oral P2Y12 inhibitors characterized by inevitable delay in their onset of action, which is enhanced in high-risk short-term settings in which their gastrointestinal absorption is further compromised. DCB releases an anti-proliferative drug during balloon dilation. This strategy has shown promising results to counteract restenosis, while minimizing the invasiveness of revascularization not adding additional metal caging. Despite the clinical setting being an ACS, the used of DCB on the proximal LAD in this specific case offers the advantage of minimizing the risk of stent thrombosis, should a de-escalation of the antiplatelet treatment needed for clinical reasons.

A301: PRESENTAZIONE INUSUALE IN PAZIENTE INUSUALE: UN CASO DI CORREZIONE DI FORAME OVALE PERVIO

Valentina Bogini (a), Pietro Martinucci (a), Francesca Sani (a), Valentina Tozzetti (a)

(a) OSPEDALE SAN GIOVANNI DI DIO FIRENZE

La sindrome platipnea-ortodeossia è una rara sindrome clinica caratterizzata da dispnea e desaturazione arteriosa indotta dalla stazione eretta e risolta in posizione supina. L'ipossia è stata attribuita alla commistione di sangue deossigenato venoso con quello arterioso ossigenato attraverso uno shunt, che può essere causato da anomalie intracardiache, extracardiache o da più elementi combinati. Un forame ovale pervio (FOP) con shunt destro-sinistro è tra le cause più comuni sottostanti questa sindrome. Più raramente può essere causata dalla somma di più difetti anatomici. Descriviamo il caso di una donna di 83 anni affetta da sindrome platipnea-ortodeossia con forame ovale pervio e lipomatosi del septum secundum. A gennaio 2023 una donna di 83 anni è stata ricoverata presso il reparto di Medicina Interna, per dispnea e febbre presenti da un mese; in anamnesi remota encefalopatia cronica su base vascolare. Non erano presenti fattori di rischio cardiovascolare. All'esame obiettivo erano presenti dispnea per sforzi lievi e crepitii bibasali. La SpO2 era 95% in maschera Venturi 50%. All'ECG ritmo sinusale, agli esami vi era incremento degli indici di flogosi. All'emogas arteriosa era presente insufficienza respiratoria di tipo 2. Un'Angio TC polmonare ha descritto embolia polmonare segmentale e subegmentale, e polmonite interstiziale; la funzione sistolica era conservata. È stata intrapresa quindi terapia anticoagulante ed antibiotica. Durante la successiva degenza la paziente ha continuato ad essere dipendente dall'ossigenoterapia, con peggioramento dell'insufficienza respiratoria; sono state escluse in diagnosi differenziale connettiviti, miositi, ed infezioni polmonari virali. Risolto lo stato infettivo polmonare, è stata trasferita presso un instituto per eseguire fisioterapia respiratoria, ma a marzo 2023 è stato necessario un secondo ricovero per peggioramento dell'insufficienza respiratoria. Alla valutazione strumentale e laboratoristica erano assenti segni di infezione polmonare e fenomeni tromboembolici. Un'ecocardiogramma ha descritto un aneurisma del setto interatriale, sollevando il sospetto di FOP come causa dello scenario clinico. Si è confermata la presenza di sindrome platipnea-ortodeossia valutando la saturazione arteriosa in clinostatismo ed ortostatismo e sono state condotte ecocardiografia transtoracica e transesofagea con somministrazione intravenosa di mdc alle microbolle, sia in posizione declive che in ortostatismo, dimostrando marcata lipomatosi del septum secundum e FOP associato a shunt destro-sinistro in posizione supina, minimo in condizioni basali e massivo dopo manovra di Valsalva, con simultanea desaturazione; in clinostatismo

lo shunt destro-sinistro era massivo tanto a riposo quanto dopo manovra di Valsalva. Escluse malformazioni aterovenose con AngioTC, è stata posta indicazione a correzione dello shunt intracardiaco e chiusura del FOP mediante device posizionato per via percutanea, procedura eseguita alcuni giorni dopo, assistendo alla scomparsa dello shunt destro-sinistro all'ecocardiografia transesofagea intraoperatoria. Nell'immediato post-operatorio i valori di SaO2 erano costantemente 97% in ortostatismo ed in clinostatismo. Alla visita di controllo a 30 giorni la paziente si presentava eupnoica in aria ambiente, con valori di SpO2 pari a 97%. È stata in grado di condurre un Six minutes walking test senza sintomatologia respiratoria e mantenendo valori di saturazione superiori a 94%, senza ossigenoterapia. All'ecocardiografia di controllo è stato confermato il corretto posizionamento del device e l'assenza di shunt residuo al mdc con microbolle tanto al basale quanto sotto manovra di Valsalva.

A302: CHARACTERISTICS AND IN-HOSPITAL OUTCOMES OF PATIENTS WITH PERIPHERAL ARTERY DISEASE UNDERGOING TRANSFEMORAL TRANSCATHETER AORTIC VALVE REPLACEMENT.

Federica Bruno (a), Sabato Sorrentino (a), Assunta Di Costanzo (a), Alessandra Panarello (a), Antonio Bellantoni (a), Concetta Filardo (a), Vincenzo D'Ambrosio (a), Filippo Bova (a), Filippo Fabio Valenti (a), Alessandro Caracciolo (a), Carmen Anna Maria Spaccarotella (b), Concetta Procopio (a), Antonio Pilo (a), Adriano Signorelli (a), Annalisa Mongiardo (a), Ciro Indolfi (a)

(a) UOC CARDIOLOGIA EMODINAMICA UTIC, AOU DULBECCO, UNIVERSITÀ DEGLI STUDI MAGNA GRAECIA DI CATANZARO; (b) UOC CARDIOLOGIA, DIPARTIMENTO DI SCIENZE BIOMEDICHE AVANZATE, UNIVERSITÀ DI NAPOLI FEDERICO II

Background. Peripheral artery disease (PAD) is associated with an elevated risk of cardiovascular mortality and frequently coexists as a comorbidity in patients referred for transcatheter aortic valve replacement (TAVR) due to shared risk factors. This study aims to examine the evolving patterns of transfemoral (TF) TAVR utilization in its early and contemporary phases and assess the associated outcomes in patients with PAD.

Methods. In this retrospective study, we examined 611 patients with severe aortic stenosis undergoing TF-TAVR at our institution from September 2008 to December 2022. Patients were categorized based on the presence or absence of PAD. The definition of PAD included claudication or>50% diameter stenosis in any peripheral artery, prior amputation due to arterial vascular insufficiency, prior vascular reconstruction, peripheral bypass surgery, or percutaneous peripheral vascular intervention. We compared the clinical characteristics of these groups using Student's t-test or χ^2 test as appropriate. Peri-procedural complications and outcomes were recorded following the Valve Academic Research Consortium-3 criteria. We used cross-sectional logistic regression analysis to investigate the independent association between baseline clinical and procedural variables and the occurrence of outcomes.

Results. Out of the 611 patients in the study, 82 (13.4%) had PAD. Patients with PAD were older (81.5 vs. 79.9 years old, p<0.01) and exhibited a higher prevalence of dyslipidemia, current smoking, and prior cerebrovascular events. The PAD cohort was associated with a significantly higher EuroSCORE (8.0% vs. 5.0%, p<0.001). There were no differences between the groups in terms of the type of valve device implanted (self-expandable or balloon-expandable) and valve size. Interestingly, when considering secondary access, contralateral femoral access was more commonly used among patients with PAD compared to radial access, as well as sutures instead of plug-based devices for hemostasis at the main access site. The length of hospitalization and the time spent in the intensive care unit were similar between the groups. In-hospital rates of stroke, life-threatening or major bleeding, and mortality were comparable between the groups, while patients with PAD experienced higher rates of major vascular complications compared to those without. After adjusting for clinical and procedural variables, logistic regression analysis confirmed that PAD [OR 1.92 (95% CI 1.04-3.51), p=0.035] was an independent predictor of in-hospital vascular complications.

Conclusions. In our patient population, those with PAD continue to face an increased risk of access site complications. Importantly, these complications do not appear to affect the duration of hospitalization or in-hospital mortality. Further research is warranted to develop specialized approaches for managing access site issues and to assess long-term outcomes in this patient group.

A303: A SUCCESSFUL CASE OF STENT RETRIEVER USE AS BAIL-OUT REPERFUSION STRATEGY OF AN RCA THROMBOTIC OCCLUSION

Antonia Luisa Buongiorno (a), Riccardo Scalamera (a), Marco Palmieri (a), Sofia Hassan (a), Paolo Archetti (a), Gianluca Anastasia (a), Rocco Vergallo (a), Italo Porto (a)

(a) CARDIOLOGY UNIT, IRCCS OSPEDALE SAN MARTINO, GENOVA

Background. Stent retrievers are devices commonly used during thrombectomy as first-choice neuroradiological treatment in case of ischemic stroke. Their role in interventional cardiology is emerging as bail-out treatment in patients with ST-segment elevation myocardial infarction (STEMI) in presence of high thrombus burden.

Clinical case. A 63 years-old male with multiple cardiovascular risk factors (hypertension, dyslipidemia, smoke, family history of coronary artery disease) was admitted due to infero-postero-lateral STEMI with symptoms onset <24 h. Urgent coronary angiography showed proximal thrombotic occlusion of a dominant right coronary artery (RCA) (TIMI 0, thrombus grade 5). After successful vessel wiring using a BMW Universal, we performed gentle predilation with a 2.0 mm semi-compliant balloon and multiple manual thrombus aspiration passes (Eliminate 6F) without any significant improvement of the coronary flow. Additional multiple predilatation using larger balloons (2.5 mm, 3.0 mm, 3.5 mm semi-compliant balloons) were performed, followed by administration of intracoronary Abciximab, leading to incomplete thrombus dissolution. As the occlusion remained unresolved and the patient was still symptomatic with unchanged ST elevation at the EKG monitoring, we decided to use the stent retriever Envast 4.5 x 46 mm followed by device removal with guiding catheter extension and vacuum-assisted aspiration. Flow restoration Washington achieved (TIMI II) and we proceeded to stent implantation (everolimus eluting stent 4.0 x 48 mm and 4.0 x 18 mm in overlap from mid to proximal RCA. After stenting, due to distal embolization of residual thrombus in the posterior descending artery (PDA) branch, multiple thrombus aspiration passes were performed in the IVP, followed by adenosine and nitroprussiate intracoronary infusion, with optimal angiographic result (TIMI III) and ST resolution. The hospitalization in Intensive Care Unit was complicated by hypotension and complete atrioventricular (AV) block which led to temporary pacemaker (PM) placement, which was removed after sinus rhythm restoration. At discharge, transthoracic echocardiography showed a mildly reduced left ventricular systolic function (LVEF 45%) in presence of akinesia of the mediobasal septum and hypokinesia of the posterior wall. The right ventricle seemed enlarged, although its global function was almost preserved (TAPSE 16 mm).

Discussion. The case that we present points out multiple unresolved contemporary aspects of coronary percutaneous interventions: 1) the frequently discussed role of manual thrombectomy as reperfusion strategy in presence of coronary acute thrombotic occlusion, 2) the occurrence of "no-reflow" phenomenon and the different options to approach it, 3) the use of stent retriever device as bail-out technique. To date, one small prospective, multicenter, in-human study has tested stent retriever's safety and efficacy in patients with STEMI with large thrombus burden. Larger prospective, randomized studies are needed to support its usage. Currently, two large trials testing the role of stent retrievers in patients with STEMI are ongoing, the NATURE study and the RETRIEVE-AMI study, which will shed light on this topic.

A304: DRUG-COATED BALLOON VERSUS DRUG-ELUTING STENT FOR TREATING DE NOVO LESIONS IN NON-SMALL VESSELS: A SYSTEMATIC REVIEW AND META-ANALYSIS OF 12 STUDIES INVOLVING 3043 PATIENTS

Rodolfo Caminiti (a, d), Alfonso Ielasi (d), Giampaolo Vetta (a, b), Antonio Parlavecchio (a), Domenico Giovanni Della Rocca (b), Massimo Siviglia (c), Giampiero Vizzari (a), Scipione Carerj (a), Antonio Micari (a)

(a) CARDIOLOGY UNIT, DEPARTMENT OF CLINICAL AND EXPERIMENTAL MEDICINE, UNIVERSITY OF MESSINA, ITALY; (b) HEART RHYTHM MANAGEMENT CENTRE, POSTGRADUATE PROGRAM IN CARDIAC ELECTROPHISIOLOGY AND PACING, UNIVERSITAIR ZIEKENHUIS BRUSSEL-VRIJE UNIVERSITEI BRUSSEL, EUROPEAN REFERENCE NETWORKS GUARD-HEART, BRUSSELS, BELGIUM; (c) INTERVENTIONAL CARDIOLOGY UNIT, GRANDE OSPEDALE METROPOLITANO, REGGIO CALABRIA, ITALIA; (d) CARDIOLOGY DIVISION, IRCCS OSPEDALE GALEAZZI-SANT'AMBROGIO, MILANO, ITALY

Introduction. Drug-coated balloon (DCB) has been an attractive option in de novo vessels. A systematic review and meta-analysis were conducted to evaluate the efficacy and safety of DCB vs. Drug Eluting Stent (DES) for treating de novo lesions in non-small vessels.

Methods. We systematically searched Medline, Embase and Cochrane electronic databases up to August 30th, 2023, for studies that compared the efficacy and safety of DCB and DES for treating de novo lesions in non-small vessels (≥2.5 mm) reporting at least one clinical outcome of interest. The outcomes analysed were Cardiovascular Death (CVD), Myocardial Infarction (MI), Target Lesion Revascularization (TLR), All Cause Death (ACD) and Late Lumen Loss (LLL) at follow-up. The effect size was estimated using a random-effect model as Risk Ratio (RR) and Mean Difference (MD) and relative 95% Confidence Interval (CI).

Results. A total of 12 studies (6 RCTs and 6 observational studies) with 2,610 patients (DCB n=1,195; DES n=1,394) were included in this meta-analysis following our inclusion criteria. DCB resulted non inferior to DES for CVD (RR 0.56; 95% CI [0.26-1.23]; p=0.15), MI (RR 0.51; 95% CI [0.16-1.64]; p=0.26), TLR (RR 0.89; 95% CI [0.51-1.56]; p=0.68), ACD (RR 0.79; 95% CI [0.53-1.18]; p=0.14) and LLL (MD –0.12; 95% CI [–0.28-0.05]; p=0.18) in the setting of de novo large CAD PCI.

Conclusions. Our metanalysis showed that DCB might provide a promising way on de novo non-small coronary artery disease compared to DES.

A305: VALVE-IN-VALVE TRANSCATHETER AORTIC VALVE IMPLANTATION FOR A DEGENERATED STENTLESS BIOPROSTHESIS IN A VERY YOUNG PATIENT: IS IT TIME FOR A TREATMENT PARADIGM SHIFT?

Mihail Celeski (a), Annunziata Nusca (a), Valeria Cammalleri (a), Elisabetta Ricottini (a), Fabio Mangiacapra (a), Paolo Gallo (a), Rosetta Melfi (a), Nino Cocco (a), Raffaele Rinaldi (a), Federica Coletti (a), Alessandro Appetecchia (a), Francesco Grigioni (a), Gian Paolo Ussia (a)

(a) UNIT OF CARDIOVASCULAR SCIENCE, FONDAZIONE POLICLINICO UNIVERSITARIO CAMPUS BIO-MEDICO, ROMA

Background. Young and middle-aged patients with aortic valve disease represent a challenging population given their long-life expectancy. A concern with the increasingly implanted bioprosthetic valves is the potential for an upcoming pandemic of prosthesis failure, particularly as younger patients are more frequently treated with bioprosthetic valves. Valve-in-Valve (ViV) transcatheter aortic valve implantation (TAVI) has emerged as a less-invasive alternative to conventional redo surgery for bioprosthetic valve disfunction, but it is mostly recommended for elderly patients with high operative risk. Furthermore, ViV-TAVI is a safe and reliable treatment option, but its use in the setting of stentless bioprosthesis degeneration is more demanding as it is associated with technical challenges and potential procedural complications.

Case summary. Here, we present a case of 45-year-old man with a history of major surgical aortic coarctation repair (1983) admitted to our emergency department for dyspnea. Twenty years ago, he underwent an aortic valve and root replacement with a stentless Freestyle 27 heterograft for annulo-aortic dilatation and severe aortic regurgitation (AR) in a bicuspid valve. Trans-thoracic echocardiography (TTE) showed structural bioprosthetic degeneration with mean gradient values of 63 mmHg, acceleration time>100 msec, Doppler velocity index of 0.24, and predominant severe aortic regurgitation. According to VARC-3 criteria, severe hemodynamic valve deterioration was diagnosed. Coronary angiogram did not reveal any significant coronary stenosis. Despite the intermediate risk (Euroscore II 5.34%), given the high complexity, morbidity, and mortality associated with redo root replacement and the patient's preferences, a ViV-TAVI was chosen during heart team discussion. The pre-operative computed tomography (CT) showed slight aortic isthmus narrowing, appropriate coronary height, and a perimeter-derived diameter of 22 mm. Considering the stentless type of prosthesis, the valve's morphology, and the young age, a self-expandable supra-annular open-frame valve (ACURATE Neo2 L) was chosen. As there is a lack of radiographic and anatomic landmarks in stentless valves, transesophageal echocardiography was used to guide the transfemoral biological valve implantation. The valve was successfully released, with minimal AR and no evidence of paravalvular leaks during aortography. The post-procedural TTE showed normal trans-prosthetic gradients (mean gradient 19 mmHg), no pericardial effusion and no patient-prosthesis mismatch. After a year since discharge, the patient had a better quality of life, no significant symptoms, and no major adverse cardiovascular or cerebrovascular events.

Discussion. In patients with previous aortic root replacement and a degenerated stentless bioprosthetic valve, ViV-TAVI can be performed with a low risk of complications despite the presence of unique technical challenges. However, detailed pre-procedural planning is essential, along with multislice CT scanning and operative knowledge of the previous stentless aortic root operation, to facilitate valve selection and deployment accuracy and minimize coronary obstruction. In addition, age and surgical risk should not be the only parameters; a multitude of clinical, anatomical factors and patients' preferences need to be meticulously evaluated to determine candidacy and the feasibility of ViV-TAVI. However, unanswered questions of durability, coronary access, and risk of redo TAVI still remain in young patients, but priority should be given to the lifetime management of patients with aortic stenosis.

A306: OPTICAL COHERENCE TOMOGRAPHY FOR GUIDING IN-STENT RESTENOSIS AND STENT THROMBOSIS MANAGEMENT

Francesca Ciliberti (a), Livio Giuliani (b)

(a) DIPARTIMENTO DI NEUROSCIENZE, IMAGING E SCIENZE CLINICHE, UNIVERSITÀ DEGLI STUDI DI CHIETI-PESCARA, 66100 CHIETI, ITALY; (b) EMODINAMICA E CARDIOLOGIA INTERVENTISTICA, OSPEDALE SS. ANNUNZIATA, 66100 CHIETI, ITALY

Introduction. Optical coherence tomography (OCT) has been increasingly used to guide the revascularization of in-stent restenosis (ISR). Several underlying pathological mechanisms contribute to the development of ISR, such as stent under- expansion, non-overlapping stents, stent fracture, edge dissection, and increased plaque accumulation at the stent edge. With its high resolution (10-15 µm), OCT allows for the assessment and management of mechanical irregularities that predispose to stent thrombosis. Current ESC/EAPCI guidelines provide a class IIA recommendation for diagnostic intracoronary imaging using OCT to evaluate stent failures. However, this approach has not been utilized in large-scale multi-center prospective studies.

Methods. A network meta-analysis was conducted to synthesize both direct and indirect evidence from relevant trials. Data sources included PubMed, Cochrane Library Central Register of Controlled Trials, and Embase for trials involving the use of optical coherence tomography in the context of in- stent restenosis.

Results. To comprehend the clinical implications of OCT findings during percutaneous coronary intervention (PCI), several trials have reported post-stent optimization. In CLI-OPCI I and II, optimization occurred in 35% and 31% of cases, respectively. In ILUMIEN IV, the OCT-guided group achieved a larger minimum stent area compared to the angiography-guided group (difference 0.36 mm^2, p<0.001). Before the introduction of OCT, the mechanisms underlying stent restenosis were completely identified in only 12% of patients. To assess the efficacy of OCT in exploring the characteristics and mechanisms of stent thrombosis, we considered various trials, including the national PESTO (Morphological Parameters Explaining Stent Thrombosis Assessed by OCT) French registry. In this study, OCT identified underlying morphological abnormalities in 87% of patients, with strut malapposition being the most frequent cause, prevalent across all ST types. The percentage of patients with 'unidentified' mechanisms decreased from 48% without OCT to 13% with OCT, and these differences were statistically significant (p<0.001). In the PRESTIGE registry (Prevention of Late Stent Thrombosis by an Interdisciplinary Global European Effort), a cause of stent restenosis was identified in all cases. In the Bern registry, OCT findings impacted patient management in 66% of cases (810). In the diagnostic setting, OCT findings influenced patient management in 74% of cases. In 52% of OCT-guided cases, post-stent OCT revealed potentially significant findings, leading to additional intervention for stent optimization or changes in medical therapy.

Conclusions. Summarizing the findings from published studies, it becomes evident that intravascular imaging facilitates the identification of the fundamental mechanisms responsible for ISR and stent thrombosis. This information can be useful in the formulation of treatment strategies.

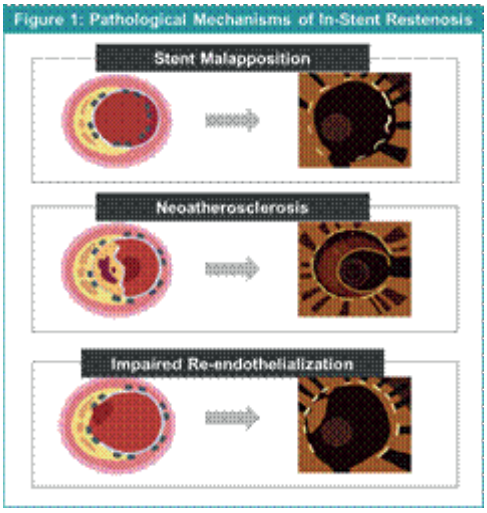

A307: STUDIO OSSERVAZIONALE RETROSPETTIVO SUI PREDITTORI DI RIGURGITO MITRALICO RESIDUO A UN ANNO DALL'IMPIANTO DI MITRACLIP

Marco Fabio Costantino (a), Luisiana Stolfi (a), Gianpaolo D´addeo (a), Francesca Cortese (c), Maria Luigia Tucci (d), Giacinto Calculli (c), Giangiuseppe Cappabianca (b), Giampaolo Luzi (a)

(a) DIPARTIMENTO CARDIOVASCOLARE - AOR "SAN CARLO" - POTENZA; (b) DIPARTIMENTO DI CARDIOCHIRURGIA - OSPEDALE DI CIRCOLO E FONDAZIONE MACCHI -VARESE; (c) UNITÀ DI CARDIOLOGIA - PRESIDIO OSPEDALIERO MADONNA DELLE GRAZIE - MATERA; (d) UOC DI CARDIOLOGIA - UNIVERSITÀ DEGLI STUDI DI FOGGIA

Razionale. Questo studio individua i parametri predittivi di rigurgito mitralico (MR) residuo e i risultati a breve termine dell'impianto di MitraClip nella nostra esperienza monocentrica.

Materiali e metodi. 48 pazienti con MR moderato-severo (grado 3-4+/4) di tipo funzionale sono stati sottoposti a riparazione della valvola mitrale utilizzando la tecnologia MitraClip e sono stati seguiti ecocardiograficamente a 3, 6 e 12 mesi.

Risultati. 26 pazienti hanno presentato a un anno un MR residuo=1, i restanti 22 un MR residuo ≥2. All'analisi multivariata l'unica misura preprocedurale predittiva di MR ≥2 è risultata l'altezza del lembo posteriore (PLH), la frazione di eiezione (LVEF) è risultata quasi significativa. Il grado di MR nell'immediato decorso postprocedurale (IPOMR) è risultato associato alla presenza di MR ≥2 a un anno. La predittività di questi tre parametri PLH e LVEF e IPOMR è stata valutata utilizzando le curve ROC per stimare l'area sotto la curva (AUC) e il miglior cut-off per ciascun valore. I 3 cut-off sono stati reinseriti nel modello multivariato per prevedere un MR a un anno ≥2, ottenendo i seguenti risultati: PLH ≥11, LVEF ≥36%, e IPOMR ≥2. La presenza di MR ≥2 dopo un anno è associata a parametri ecocardiografici peggiorati e ad a un peggioramento della classe New York Heart Association (NYHA) a un anno.

Conclusioni. La presenza di MR ≥2 nell'immediato decorso postprocedurale è un forte predittore di persistenza di MR ≥2 a un anno ed esito clinico ed ecocardiografico peggiore dopo riparazione con MitraClip. Un'area valvolare mitralica maggiore porta a maggiore riduzione dell'area valvolare, dei diametri e dei volumi ventricolari. Maggiori pressioni polmonari preprocedurali portano a riduzione di queste e dei volumi dell'atrio sinistro. Il PLH ≤11 è il principale fattore predittivo preprocedurale del fallimento della riparazione con MitraClip (1 anno MR ≥2).

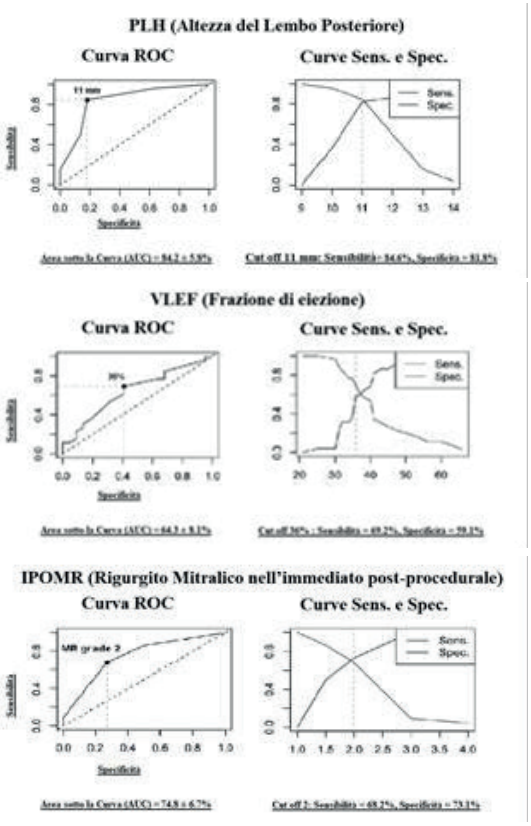

A308: LA TAVI-VIV: NUOVA EL DORADO O EXIT STRATEGY

Marco Fabio Costantino (a), Luisiana Stolfi (a), Davide Pietrafesa (c), Francesca Cortese (b), Gianpaolo D'Addeo (a), Giacinto Calculli (b), Giampaolo Luzi (a)
(a) DIPARTIMENTO CARDIOVASCOLARE AOR "SAN CARLO" - POTENZA; (b) UNITÀ DI CARDIOLOGIA PRESIDIO OSPEDALIERO "MADONNA DELLE GRAZIE" - MATERA; (c) DIPARTIMENTO DI BIOLOGIA UNIVERSITÀ DI ROMA "TOR VERGATA" - ROMA

Razionale. Questo studio valuta dal punto di vista clinico ed ecocardiografico l'outcome immediatamente postoperatorio e a un anno della procedura di impianto valvolare aortico transcatetere valve in valve (TAVI-ViV) in caso di disfunzione di protesi biologica in sede aortica.

Materiali e metodi. 17 pazienti con stenosi (64.71%) o insufficienza (35.29%) valvolare aortica sono stati sottoposti a procedura TAVI-ViV (6 per via transapicale e 11 per via transfemorale) e sono stati seguiti ecocardiograficamente a 3, 6 e 12 mesi. Le valvole impiantate (10 di 20 mm, 5 di 23 mm, 1 di 26 mm e una di 29 mm di diametro) erano di tipo Sapien XT in 4 pazienti e Sapien 3 in 13 casi (di cui 3 Ultra).

Risultati. Si riporta la curva di Kaplan-Meier riferita alla mortalità a un anno in presenza/assenza di malattia coronarica [Fig. 1]. La degenerazione delle bioprotesi nei pazienti che al momento dell'impianto avevano un'età ≤70 anni è avvenuta mediamente in 10.89±2.98 anni, nei pazienti con età>70 anni in 7.88±2.23 anni dall'intervento. Si è calcolata la variazione media del volume telediastolico (VTD) tra il valore al basale (129.9±37.1 ml), immediatamente post-TAVI-ViV (117.5±36.3 ml) e al follow up a un anno (86.9±40.7 ml) [Fig. 2]. Sui pazienti che presentavano difunzione della bioprotesi con stenosi si è calcolata la variazione del gradiente transvalvolare medio (Gm) al basale (42.4±10.0 mmHg), immediatamente post-procedurale (21.4±8.0 mmHg) e a un anno (25.2±11.1 mmHg) [Fig. 3] e del Doppler Velocity index (DVi) al basale (0.238±0.056), immediatamente post-TAVI-ViV (0.380±0.051 ml) e al follow up (0.390±0.055) [Fig.4].

Conclusioni. I parametri ecocardiografici analizzati sono risultati migliorati in seguito a TAVI-ViV sia nell'immediato post-procedurale che al follow up.

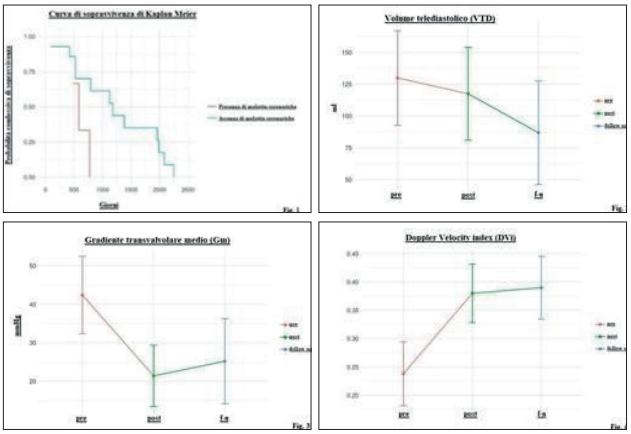

A309: POTENTIAL ROLE OF CARDIOPULMONARY EXERCISE TESTING IN EVALUATING FUNCTIONAL IMPROVEMENT AFTER TRANSCATHETER EDGE-TO-EDGE TRICUSPID VALVE REPAIR

Luca Cumitini (a, b), Ailia Giubertoni (b), Marco Mennuni (b), Anna Degiovanni (b), Simona De Vecchi (b), Giuseppe Patti (a, b)
(a) DEPARTMENT OF TRANSLATIONAL MEDICINE, UNIVERSITY OF EASTERN PIEDMONT, VIA SOLAROLI 17, 28100 NOVARA, ITALY; (b) DEPARTMENT OF THORACIC AND CARDIOVASCULAR DISEASES, MAGGIORE DELLA CARITÀ DI NOVARA, VIA MAZZINI 18, 28100 NOVARA, ITALY

Case report. A 77-year-old woman was admitted to our Institution for several years of heart failure symptoms. Transthoracic echocardiography (TTE) showed normal right and left systolic ventricular functions and severe right atrium enlargement. Severe tricuspid regurgitation (TR) was detected at color flow Doppler examination. Transoesophageal echocardiography (TEE) confirmed severe TR, with prolapse of the septal leaflet, rupture of a septal cord and dilated tricuspid annulus. To assess patient's functional capacity, a cardiopulmonary exercise testing (CPET) was performed, showing a mildly reduced functional capacity with peak oxygen uptake (VO_2) of 12 ml/kg/min (82% predicted), reduced peak O_2 pulse of 6.2 ml/beat (66% predicted) and normal peak oxygen uptake to work rate slope (VO_2/WR, 11 ml/min/watt) and anaerobic threshold. Right heart catheterization showed combined pre- and post-capillary pulmonary hypertension and a reduced cardiac index of 2.1 liters/minutes/m^2 was found. Because of subsequent, progressive right-side heart failure and high surgical risk, the decision to perform transcatheter edge-to-edge tricuspid repair using the PASCAL Ace® system was taken by our Heart Team. A PASCAL Ace® device was implanted between anterior and septal tricuspid leaflets and after the intervention a reduction of TR from severe to mild was achieved (Figure 1). One month later the patient reported marked subjective symptoms improvement. TTE demonstrated mild TR. CPET was performed using the same ramp protocol than the pre-procedure one and it showed normalization of functional capacity, with a peak VO_2 of 14.4 mL/kg/min (102% predicted) and peak O_2 pulse of 8.2 ml/beat (85% predicted). VO_2/WR slope and anaerobic threshold were approximately unchanged.

Discussion. The presence of severe TR has prognostic relevance and novel percutaneous tricuspid valve repair systems have emerged in the last years. Detecting functional capacity improvement after transcatheter edge-to-edge repair for severe TR can be challenging, and CPET may arise as a promising tool to help these purposes.

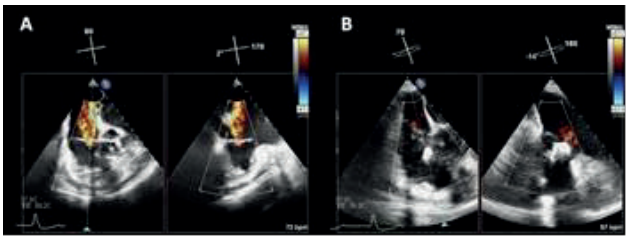

Figure 1. Peri-procedural TEE (A). Tricuspid regurgitation before the procedure and (B) after the procedure.

A310: ISCHEMIA WITH NON-OBSTRUCTIVE CORONARY ARTERY DISEASE (INOCA): A SINGLE CENTER EXPERIENCE

Salvatore Monaco (a), Luigi Di Serafino (a), Carlo Carbone (a), Maria Luisa De Rosa (a), Francesco Saverio Rea (a), Lucia Mitrano (a), Luca Ciaramella (a), Giovanni Esposito (a)
(a) UNIVERSITÀ DEGLI STUDI DI NAPOLI FEDERICO II

Background. Myocardial ischemia with non-obstructive coronary arteries (INOCA) is a chronic coronary syndrome condition that is associated with recurrent clinical presentations with chest pain, impaired functio-

nal capacity, reduced quality of life, myocardial infarction and heart failure. INOCA is usually under-recognized and under-diagnosed precisely. We report our experience for endotype characterization, tailored therapy and short term follow up.
Methods. Twenty-four patients presenting with clinical presentation of chronic ischemic heart disease, requiring coronary angiography for diagnosis, who referred to our department between October 2022 and September 2023 were included. All patients with clinical presentation of acute coronary syndrome (ACS), previous artery bypass grafting (CABG), presence of obstructive CAD (at least coronary artery stenosis>70% or FFR <0.80), sever valvular heart disease and left ventricular systolic dysfunction as EF <40%, were excluded. All patients were clinically evaluated and subjected to validated questionnaires to characterize angina and quality of life. Laboratory tests, ECG and echocardiogram were also carried out. Subsequently, functional coronary angiographic evaluation was carried out, through the bolus thermodilution method, using adenosine, including a study of the epicardial district, with evaluation of the fractional flow reserve (FFR), and the determination of coronary flow reserve (CFR), what investigates both epicardial and microvascular disease, and the index of microvascular resistance (IMR), specific for the microvascular district, independent of epicardial stenosis. Finally, acetylcholine test, with incremental doses, to evaluate the presence of any epicardial and microvascular vasospasm, symptoms, and ECG changes. Based on the results of these evaluations, 4 endotypes of INOCA can be identified: microvascular dysfunction (CMD), vasospastic angina (VSA), both CMD and VSA and non-cardiac chest pain. Based on the endotype, the optimal medical therapy will then be prescribed in that specific patient.
Results. The majority of patients were female (62.5%), presenting with hypertension (92%), hyperlipidemia (96%) and diabetes (21%). The majority of patients presented with typical angina (87%) and half of them (54%) undergone provocative ischemia tests (85% tested positive). Following functional coronary angiographic evaluation, 54% patients had a diagnosis of INOCA, of these 31% microvascular dysfunction (CMD), 31% vasospastic angina (VSA), 38% both CMD and VSA. The acetylcholine test was performed in all patients, resulting positive in 9 out of 24 (37.5%). For patients with CMD the mean FFR was 0.92, IMR 39, CFR 2.5. For patients with VSA the mean FFR was 0.86, IMR 12.66, CFR 5.56. Finally, for patients with both CMD and VSA the mean FFR was 0.89, IMR 34.66, CFR 3.26. Each patient was prescribed a personalized therapy. Short term follow-up was performed with a general improvement in symptoms following optimized medical therapy.
Conclusions. INOCA is a heterogeneous nosological entity, underdiagnosed and often poorly treated. Invasive functional angiography is helpful to identify endotypes and appropriate therapy with a significant clinical benefit.

A311: TO CUT OR NOT TO CUT: CUTTING BALLOON FOR LESION PREPARATION BEFORE DRUG COATED BALLOON ANGIOPLASTY

Gabriele Facci (a), Andrea Bottardi (a), Gabriele Venturi (b), Antonio Mugnolo (b), Alberto Zamboni (b), Francesco Bacchion (b), Giorgio Morando (b)
(a) DIVISION OF CARDIOLOGY, DEPARTMENT OF MEDICINE, AZIENDA OSPEDALIERA UNIVERSITARIA INTEGRATA, VERONA, ITALY; (b) DIVISION OF CARDIOLOGY, MATER SALUTIS HOSPITAL, LEGNAGO (VR), ITALY

Background. There are limited data on the use of DCB in calcified lesions. Evidence regarding the use of cutting balloon before DCB angioplasty is scarce.
Methods. We retrospectively analyzed our internal registry between May 2017 and May 2023 to retrieve intrastent restenosis angioplasty performed with DCB. We divided our population according to the use of cutting balloon as debulking technique before DCB. The objective of the study was to compare the two population in term of procedural success (primary endpoint defined as absence of flow-limiting dissection or residual stenosis>30% or bail-out to stent strategy) and 6 months target lesion revascularization (secondary endpoint).
Results. Between May 2017 and May 2023 one hundred and six (106) ISR were treated with DCB-angioplasty at our center: twenty-four were prepared with cutting-balloon, mostly because of high calcification burden, while eighty-two only with conventional NC balloon before DCB strategy. Procedural success was achieved in all patients analyzed (100%). Therefore, there were no differences in procedural success between the two groups. In the cutting balloon group, mainly for unstable angina, a new angiography was performed for 4 patients: one underwent target vessel revascularization (4.1%) while three target lesion revascularizations (12.5%). In the second group, seven out of 82 presented stable angina and needed new angiography resulting in target lesion revascularization (9,1%) due to severe ISR (two underwent surgical revascularization, five percutaneous with DCB). Therefore, cutting balloon was not associated with increased TLR (HR 2.7; 95% CI 0.70–10.52; p 0.147).
Conclusions. Lesion preparation with cutting balloon represent a valid strategy in the setting of in stent restenosis before DCB angioplasty in term of procedural success and 6 months risk for target lesion revascularization. Our monocentric registry presents the limitation of a small number which did not allow for any adjustment and a short follow up period but provides an overview of a real-world experience.

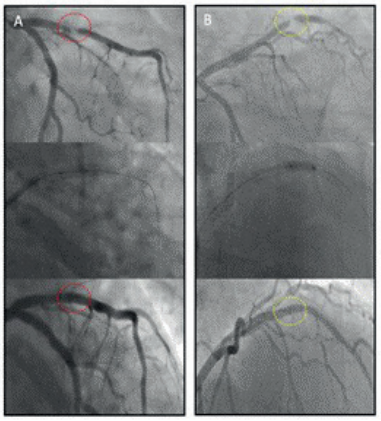

Figure 1. (A) A serie showing focal ISR of proximal LAD resulting into sub occlusive disease, a lesion successfully prepared with cutting balloon and treated with DCB delivery. Last frame shows an optimal angiographic result. (B) Another LAD mid ISR successfully treated with cutting balloon followed by DCB delivery.

A312: ACCURATEZZA DELL'AREA LUMINALE MINIMA INDICIZZATA DEL VASO PER IDENTIFICARE UNA STENOSI SIGNIFICATIVA DEL TRONCO COMUNE DELLA CORONARIA SINISTRA

Vincenzo Alessandro Galiffa (a), Matilde Villa (a), Leonardo Grisafi (a), Marco Giovanni Mennuni (a), Martina Solli (a), Domenico D'Amario (a, b), Roberta Rosso (a), Alessandro Carli (a), Tarek Shail (a), Giuseppe Patti (a, b)
(a) AOU MAGGIORE DELLA CARITÀ; (b) UNIVERSITÀ DEL PIEMONTE ORIENTALE

Background. La malattia del tronco comune (TC) della coronaria sinistra (LMCA) rappresenta la lesione a maggior rischio nel contesto della patologia coronarica e, in presenza di una lesione definita di grado intermedio (25-60%) all'angiografia, è raccomandata una più approfondita valutazione morfo-funzionale, tramite misurazione di FFR e iFR e/o definizione dell'MLA con IVUS. Attualmente, la rivascolarizzazione del TC è indicata in tutti i casi di MLA≤6 mm^2. Tuttavia, studi più recenti sembrerebbero dimostrare la sicurezza di una soglia più bassa differendo la rivascolarizzazione in pazienti con MLA≥4.5 mm^2. Tali osservazioni sono state fatte prendendo in considerazione una coorte di pazienti di etnia asiatica, in cui era stata dimostrata la presenza di arterie coronarie di dimensioni inferiori rispetto a quelle dei soggetti caucasici. Alla luce di suddette evidenze, risulta quindi poco chiaro se un valore fisso di MLA, indipendente da caratteristiche antropometriche e anatomiche cardiovascolari, sia indicativo per definire la significatività funzionale di una lesione del TC della LMCA.
Obiettivo dello studio. Il nostro studio vuole indagare se un valore di MLA indicizzato sia più accurato rispetto a un valore di MLA fisso per definire la significatività funzionale di una stenosi del TC. L'end-point primario dello studio è il confronto tra un valore di MLA fisso rispetto a una soglia di MLA indicizzato per BSA. Gli end-points secondari dello studio sono il confronto del valore di MLA fisso con l'MLA indicizzato per l'altezza del paziente e per la massa ventricolare sinistra.
Metodi. Lo studio è di tipo osservazionale prospettico multicentrico e prevede l'arruolamento di 80 pazienti con diagnosi di stenosi intermedia non complicata del TC evidenziata all'angiografia coronarica. Tali pazienti sono sottoposti sia a valutazione funzionale con FFR e iFR sia a studio morfologico con IVUS per una valutazione più accurata prima di effettuare qualsiasi eventuale trattamento di rivascolarizzazione, stabilito a discrezione dell'operatore sulla base delle valutazioni eseguite.
Risultati. Dal 31/05/2021 al 7/06/2023 sono stati arruolati 33 pazienti e lo studio è ancora in corso. Le analisi effettuate mediante curva ROC evidenziano una correlazione non statisticamente significativa tra valori di MLA e il BSA che, tuttavia, si avvicina molto al limite della significatività statistica (p=0.06) e una correlazione statisticamente significativa con la massa del ventricolo sinistro (AUC di 0.85, IC 95% 0.66 – 1.00, p=0.002). Il modello di regressione lineare applicato per testare il valore predittivo indipendente dei valori di FFR per i valori di MLA indicizzato per la massa del ventricolo sinistro identifica una correlazione statisticamente significativa con un coefficiente di determinazione R^2=0.2394 e p 0.0071.
Conclusioni. Le analisi ad interim dello studio sembrerebbero dimostrare che l'uso di un valore di MLA indicizzato sia superiore rispetto a un valore di MLA fisso per stabilire la necessità di rivascolarizzazione di una stenosi intermedia non complicata del TC, definita come significativa alla valutazione funzionale invasiva. Il parametro che finora ha dimostrato la maggior correlazione con i valori di MLA sembrerebbe essere la massa del ventricolo sinistro. I risultati ottenuti dovranno essere successivamente confermati su una coorte di pazienti più ampia.
FFR, fractional flow reserve; iFR, instantaneous wave-free ratio; MLA, area luminale minima; IVUS, ecografia intravascolare; BSA, area di superfice corporea.

A313: CORONARY ACCESS AFTER TRANSCATHETER AORTIC VALVE REPLACEMENT (TAVR): A SYSTEMATIC REVIEW AND METANALYSIS OF OBSERVATIONAL STUDIES

Federico Giacobbe (a), Arianna Morena (a), Bruno Francesco (a), Marco Nebiolo (a), Yasser Odeh (a), Gianluca Di Pietro (b), Ovidio De Filippo (a), Federico Conrotto (a), Pierluigi Omedè (a), Fabrizio D'Ascenzo (a), Gaetano Maria De Ferrari (a)
(a) AOU CITTÀ DELLA SALUTE E DELLA SCIENZA DI TORINO, DIPARTIMENTO DI SCIENZE MEDICHE, UNIVERSITÀ DEGLI STUDI DI TORINO; (b) DIPARTIMENTO DI SCIENZE CLINICHE, SCIENZE ANESTESIOLOGICHE E CARDIOVASCOLARI,UNIVERSITÀ DELLA SAPIENZA DI ROMA, ROMA

Introduction. Over the past two decades, transcatheter aortic valve replacement (TAVR) has transformed the management of aortic stenosis, initially for high-risk surgical candidates and subsequently for low-risk patients. However, with the expanding indications for TAVR to younger, lower-risk patients, it is crucial to assess not only the short-term clinical outcomes but also the long-term considerations for future interventions. The prevalence of coronary artery disease (CAD) in TAVR patients is relevant, and the optimal timing of percutaneous coronary intervention (PCI) remains a question, given the technical challenges associated with coronary access in TAVR patients.
Methods. We conducted a systematic literature review and meta-analysis according to Cochrane Collaborations and PRISMA guidelines. We included 19 eligible trials involving 1533 patients who underwent coronary angiography after TAVR. The primary endpoint was the incidence of successful selective coronary re-access. Secondary endpoints included semi-selective and non-selective access rates. The analysis was stratified by balloon-expandable (BEVs) and self-expandable valve (SEVs) types.
Results. Successful coronary access after TAVR was feasible in the majority of patients, with a higher success rate observed for the left main coronary artery (LM) compared to the right coronary artery (RCA). Balloon-expandable valves demonstrated the highest success rates in coronary ostia cannulation, achieving nearly 100% success for both LM and RCA. Among self-expandable valves, the Evolut R/PRO showed superior success rates in selective coronary access (76,85% [95%CI 53,34-100%] for LM and 57,27% [95%CI 32,8-81,74%] for RCA) compared to the CoreValve (45,62% [95%CI 0-92,78%] for LM and 49,19% [95%CI 0-100%] for RCA). Notably, the majority of coronary angiograms were performed due to acute coronary syndrome, primarily non-ST-segment elevation myocardial infarction (NSTEMI) and unstable angina (UA), 26,5% for NSTEMI and 23,4% for UA, respectively.
Conclusions. Selective coronary engagement after TAVR is generally achievable, with BEVs demonstrating superior success rates compared to SEVs. Among self-expandable valves, the Evolut R/PRO showed better outcomes than the CoreValve. These findings provide valuable insights into post-TAVR coronary access feasibility, reducing concerns about valve selection based on this criterion.

A314: FUNCTIONAL OR ANATOMICAL STENOSES, COULD PHYSIOLOGY WIN THEM ALL?

Alessandro Laschera (a), Daniele Torella (a), Sabato Sorrentino (a), Alessandro Caracciolo (a), Francesco Caggiano (a), Alessandro Lucchino (a), Vincenzo Riverso (a), Salvatore De Rosa (a)
(a) DIVISION OF CARDIOLOGY, DEPARTMENT OF MEDICAL AND SURGICAL SCIENCES, MAGNA GRAECIA UNIVERSITY, CATANZARO, ITALY

Background. Functional assessment of coronary arteries is often essential to disentangle apparently enigmatic clinical pictures, particularly in case of macroscopic discrepancy between the clinical phenotype and angiographic findings. The simple visualization of a myocardial bridge or coronary kinking often doesn't suffice to identify its clinical relevance. In this context, functional assessment offers useful diagnostic clues. The functional relevance of myocardial bridging and/or kinking depends on several variables, including the length of the segment, the heart rate, the severity of systolic obstruction, LV end-diastolic pressure and many others. To add further complexity, patients have a large spectrum of clinical severity, from the absence of symptoms to dreadful clinical events, let alone the frequently atypical symptoms. The achievement of a proper diagnosis is not a trivial exercise, as effective pharmacological treatments are available. An optimal medical therapy including beta blockers, calcium channel blocker, which might potentially relieve symptoms.
Case description. We presented the case of a 50 years old female which come to our attention for recurrence of typical chest pain and diagnostic evidence of inducible myocardial ischemia of the anterior and antero-septal wall at myocardial SPECT. We assessed hemodynamic state of coronary vessel involved by abnormal course by performing Functional invasive measurement (RFR and IMR). We found a hemodynamically significant impairment of RFR (=0,88) downstream of intramyocardial segment, with non-pathological values upstream (RFR=0,97), without any impairment of the index of microvascular resistance (IMR=15). Hence, medical treatment was optimized by adding a betablocker (Nebivolol). Five months later the clinical status of the patient improved: no further episode of chest pain nor novel hospitalizations were reported at the follow up.
Conclusions. Invasive functional test can modify clinical management of patients with normal epicardial vessel. In the case of INOCA, patients with normal epicardial vessels, hemodynamic functional tests allow to evaluate the severity and type of INOCA, to exclude microvascular causes and to identify the hemodynamic severity of a myocardial bridge in the blood flow impairment. This strategy allows to choose the most correct medical therapy in order to prevent future adverse events and improve patients' quality of life. Future implementation of diagnostic algorithm based on an Artificial Intelligence system combining angiographic, EKG, Bioumoral and clinical data will allow a faster and accurate detection of patients candidate to a specific therapy.

A315: NON FLOW-LIMITING DISSECTIONS IN DCB PCI: ANY PROGNOSTIC ROLE AT MID AND LONG TERM FOLLOW-UP?

Alessia Chiara Latini (a, b), Francesco Gioia (a, b), Antonio Mangieri (a), Damiano Regazzoli (a), Angelo Oliva (a, b), Mauro Gitto (a, b), Laura Novelli (a, b), Ottavia Cozzi (a, b), Giulio Giuseppe Stefanini (a, b), Bernhard Reimers (a), Antonio Colombo (a), Alessandro Sticchi (a, b)
(a) HUMANITAS RESEARCH HOSPITAL; (b) HUMANITAS UNIVERSITY

Background. The use of drug coated balloons (DCBs) during angioplasty is steadily increasing in daily practice. The outcomes associated with vessel dissections after DCB use are still largely unknown due to lack of large cohort studies or limited follow-up time.
Aim. We aim to explore the outcomes in patients with or without dissection at the end of percutaneous coronary intervention (PCI) with a DCB at mid- and long-term follow-up.
Study design. We reported the single-centre data from a tertiary CathLab centre in Northern Italy with a dedicated experience in PCI treatment using DCB. Data were collected between May 2018 and September 2022. Any dissection during the index procedure was collected, evaluated and stratified according to type 1-2 or type 3 or more.
Outcomes and measures. The primary endpoint was the occurrence of MACE, defined as the composite of death from any cause, cardiovascular (CV) death, target vessel (TV) myocardial infarction (TVMI), TV revascularization (TVR) and target lesion revascularization (TLR). Secondary outcomes included any component of the primary outcome, a composite of CV death and TVMI, as well as any revascularization during follow-up. Clinical features at baseline and procedural characteristics were assessed to identify significant prognostic predictors.
Results. A total of 576 patients who had undergone a PCI using DCB during the study period were included. Mean age (SD) was 70.0 ± 10.0 years, 17.4% were female and 25.2% had an acute clinical presentation (ACS); specifically, 33.1% had an ST-elevation ACS. Patients in the dissection group presented higher rate of STE/ACS (18.5 vs 7.1%, p-value 0.002) and suffered less frequently from hypertension (64.6% vs 82.0%, p-value 0.001) and diabetes (26.2% vs 40.0%, p-value 0.03); for what concerns plaque characteristics, they presented more de novo (78.5% vs 50.0%, p-value <0.0001) and bifurcation lesions (23.1% vs 12.7%, p-value 0.02) compared to the no-dissection group. No difference in lesion preparation with pre-dilatation or debulking technique was noticed between the groups. After a median follow-up of 229 (1-582) days, the primary endpoint occurred in 7 patients with previous dissection (10.8%) and 76 patients without previous dissection (14.9%) during the PCI.

A316: A VERY LATE ATRIAL SEPTAL EROSION AFTER AN OSTIUM SECUNDUM PERCUTANEOUS CLOSURE

Francesca Lofrumento (a), Maurizio Cusmà-piccione (a), Francesco Costa (a), Silvia Perfetti (a), Gianluca Di Bella (a), Concetta Zito (a), Scipione Carerj (a), Fabrizio Ceresa (b), Francesco Patanè (b), Antonio Micari (a)
(a) DEPARTMENT OF CLINICAL AND EXPERIMENTAL MEDICINE, UNIVERSITY OF MESSINA, AOU POLYCLINIC G. MARTINO, CARDIOLOGY UNIT, MESSINA; (b) DIVISION OF CARDIAC SURGERY, DEPARTMENT OF CARDIO-THORACO-VASCULAR SURGERY, PAPARDO HOSPITAL, MESSINA

Introduction. Complications after device closure of ostium secundum defects are rare but possible. We present a very late erosion of the interatrial septum following a percutaneous closure of an ostium secundum defect (OSD).
History of presentation. A 37-year-old woman was referred to her cardiologist for a recent history of headache and palpitations.
Past medical history. At age of 25, she underwent a percutaneous closure of an OSD. Adequate device positioning was confirmed by transthoracic echocardiography (TTE) performed yearly. Only two events need to be reported: a recent pregnancy followed by a very strong, long-lasting cough due to Covid-19 infection.
Differential diagnosis. The differential diagnosis included a long-Covid-19 syndrome or a new onset atrial tachyarrhythmia, related to the atrial septal device.
Investigations. A TTE was performed for the above-mentioned symptoms with new findings: the device appeared more prominent in the left atrial cavity with a suspected left-to-right color Doppler flow at the lower rim of the device. Then, transesophageal echocardiography (TEE) shown a paper-thin atrial septal aneurysm waving incessantly between the two atrial disks with a severe left-to-right shunt at the lower rim of the device (Fig. 1), where an atrial septal erosion was detected with TEE multiplanar reconstruction (Fig. 2).

Management. Considering shunt severity and initial device instability, a surgical approach was chosen. So, the device was removed and closure of the atrial septal defect (ASD) with an autologous pericardial patch was then successfully performed.
Discussion. Iatrogenic erosion of the septum primum after percutaneous closure of an ASD is a very rare event. Although it might not be considered immediately life-threatening, device instability could be associated to a theoretical risk of device embolization, as well as paradoxical embolism recurrences and long-term hemodynamic impairment due to the novel defect. In this case, the anatomical characteristics of the interatrial septum combined with potential cause of volume (pregnancy) and/or pressure (cough) cardiac overload, might have been a trigger for a very late erosion of the septum primum. So, clinical and echocardiographic hallmarks might inform the suspicion and the rapid identification of this condition avoiding other worse events related to it.
Conclusions. Iatrogenic erosion of the septum primum, resulting in a new atrial septal defect, after a percutaneous ASD closure, is a very rare but potentially relevant complication which can also occur very late. So, a longer-term echocardiographic follow up is essential for a timely diagnosis and treatment of this condition.

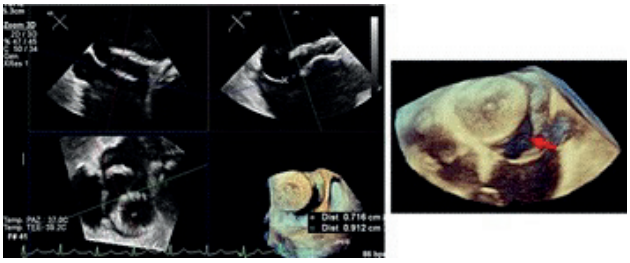

Figure 1.

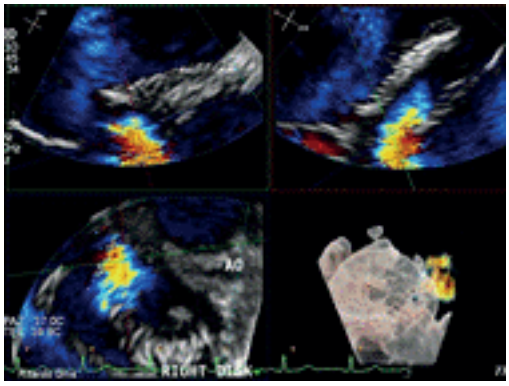

Figure 2.

A317: A WINNING COMBINED PERCUTANEOUS APPROACH TO SOLVE A CHALLENGING CASE OF SIGNIFICANT TRICUSPID REGURGITATION

Giandomenico Mancini (a), Katya V. Lucarelli (b),
Riccardo Inchingolo (c), Vito Casamassima (b), Vincenzo Bellomo (b),
Federica Troisi (b), Francesca Lombardi (d), Massimo Grimaldi (b)
(a) U.O.C. CARDIOLOGIA UNIVERSITARIA - A.O.U. CONSORZIALE POLICLINICO DI BARI; (b) U.O.C. CARDIOLOGIA - ENTE ECCLESIASTICO OSPEDALE GENERALE REGIONALE F. MIULLI; (c) U.O.S.D. RADIOLOGIA INTERVENTISTICA - ENTE ECCLESIASTICO OSPEDALE GENERALE REGIONALE F. MIULLI; (d) U.O.C. ANESTESIA E RIANIMAZIONE - ENTE ECCLESIASTICO OSPEDALE GENERALE REGIONALE F. MIULLI

Background. Tricuspid regurgitation (TR) is a common valvular pathology that impairs quality of life and survival, irrespective of its etiology and despite optimal medical therapy. Tricuspid transcatheter edge-to-edge repair (t- TEER) has recently become available as a treatment option for patients not eligible for tricuspid valve surgery and has shown promising potential. However, there remains several uncertainties such as timing of intervention in relation to clinical status, RV function, pulmonary artery pressure and many comorbidities that are often overlooked.
Case summary. A 80-year-old man with secondary dilated cardiomyopathy, persistent atrial fibrillation and biventricular implantable cardioverter-defibrillator (ICD), was admitted to our centre for signs and symptoms of congestive heart failure (CHF). Transthoracic and transoesophageal echocardiography showed massive TR (4+/5+), severe right heart dilatation, increased systolic pulmonary artery pressure, severely dilated inferior vena cava (IVC) and hepatic veins with systolic flow reversal. We also found an uncommonly high blood flow coming to the right atrium from the IVC, due to an anomalous vascular communication between an intrahepatic portal branch and a hepatic vein, a so-called intrahepatic portosystemic venous shunt (IPSVS). Although these relatively rare shunts are usually not treated unless symptomatic, after a collective careful evaluation, we decided to proceed to the embolization of the IPSVS with a vascular plug, in order to make the t-TEER less challenging, safer and more durable.
In better general conditions, after 2 months, the patient underwent the transcatheter tricuspid procedure with a single XTW TriClipä (Abbott). At 3 months follow-up, the patient showed noticeable improvements in QoL, CHF signs and symptoms, echocardiographic parameters and exercise capacity.
Discussion. Appropriate timing of t-TEER and careful comprehensive evaluation of patient's comorbidities are crucial not only to avoid irreversible RV damage and organ failure, but also to increase the success rate of the procedures. In this case we observed that the IPSVS treatment contributed significatively to improve the patient's clinical status and to reduce the right heart volume overload before attempting the t-TEER. This combined approach facilitated the technical success of tricuspid procedure, that was itself challenging due to the ICD leads in the right chambers.
Conclusions. Patients' selection and timing of percutaneous TR treatment are not clearly defined. This case shows that a winning strategy to approach challenging TR is to solve. before the tricuspid treatment, all the potentially treatable comorbidities that could negatively interfere with the technical success of the procedure itself and with the durability of TR reduction.

A318: DRUG COATED BALLOON TO IMPROVE RECANALIZATION OF A CORONARY CHRONIC TOTAL OCCLUSION FAILED ANGIOPLASTY: THE IMPROVED CTO TRIAL

Giorgio Marengo (a), Ignacio Jesus Amat Santos (b),
Gaetano Maria De Ferrari (a)
(a) DIVISION OF CARDIOLOGY, CARDIOVASCULAR AND THORACIC DEPARTEMENT, CITTÀ DELLA SALUTE E DELLA SCIENZA, TURIN ITALY; (b) CARDIOLOGY DEPARTMENT, HOSPITAL CLINICO UNIVERSITARIO, VALLADOLID, SPAIN

Background. Chronic total occlusion (CTO) plaque modification (CTO-PM) is often used for unsuccessful CTO interventions.
Methods. Multicenter, prospective study including consecutive patients with failed CTO recanalization. At the end of the failed procedure, patients received either DCB or CB for CTO-PM and underwent new attempt of CTO recanalization ~3 months later.
Results. 55 patients were enrolled (DCB: 22; CB 33), with a median age of 66 years. Median J-score was 3.0 and CCS angina class III-IV was present in 40% of the patients. After the first CTO-PCI attempt no in hospital cardiac deaths were registered, with 3.6% rates of in-hospital MI. The success rate of the second CTP PCI attempt was 86.8%, with very low periprocedural complication rates (5.7%) and without difference between DCB and CB groups. In the DCB group, the second CTO-PCI had at shorter fluoroscopy time (33 vs 60 min, p<0.001), lower contrast volume (170 vs 321 cc, p<0.001) and lower radiation dose (1.7 vs 3.3 Gy, p<0.001) compared with CB group. Incidence of in-hospital outcomes were comparable between the 2 groups, along with outcomes at 1 year follow up.
Conclusions. CTO-PM is a safe technique and warrant high success rates when 2nd attempt is performed. A DCB strategy for CTO-PM does not seem to ensure higher success rates or better clinical outcomes, but its use was associated with shorter procedures, requiring less contrast and radiation.

A319: LASER CORONARY ATHERECTOMY AND POLYMERIC CORONARY WIRES IN UNCROSSABLE LESIONS - A WORD OF CAUTION

Giorgio Marengo (a), Ignacio Jesus Amat Santos (b),
Gabriele Gasparini (c), Gaetano Maria De Ferrari (a)
(a) DIVISION OF CARDIOLOGY, CARDIOVASCULAR AND THORACIC DEPARMENT, CITTÀ DELLA SALUTE E DELLA SCIENZA, TURIN, ITALY; (b) CARDIOLOGY DEPARTMENT, HOSPITAL CLINICO UNIVERSITARIO, VALLADOLID; (c) CARDIOLOGY DEPARTMENT, IRCCS, HUMANITAS RESEARCH HOSPITAL, MILAN ITALY

Background. Excimer laser coronary atherectomy (ELCA) represents one of the last available options in case of balloon uncrossable lesions but no bench testing or clinical experience has been reported with polymeric wires. We aimed to assess whether ECLA use can disrupt or melt the cover and coating of coronary wires.
Methods. A total of 22 wires (10 polymer-jacketed and 12 hydrophilic non polymeric) were tested in an uncrossable lesion model. Two ELCA tests were performed over each wire at 8 and 4 cms from the tip with low and high settings, respectively. Microscopic analysis was performed at baseline images and after each test. Wire disruption was classified as Grade 1 (superficial scratches), Grade 2 (coil damage or solution of continuity of the polymeric cover) and Grade 3 (wire rupture/core disruption or de-coiling).
Results. After 44 ELCA simulations, wire disruption occurred in 16 cases (36.3%). Overall, events were more common for polymer-jacketed than for hydrophilic wires (12 vs 4, p=0.004). No grade 3 events occurred. Grade 2 events occurred in 9 cases (20.5%) and were more frequent with polymer-jacketed wires (8 vs 1, p=0.006). With low ELCA settings only polymer-jacketed wires suffered disruption (5 vs 0, p=0.009). With higher settings 11 events occurred (7 of Grade 2 and 4 of Grade 1) and incidence of grade 2 events was higher for polymer-jacketed wires (6 vs 1, p=0.02).

Conclusions. ELCA might be a safe option for coronary uncrossable lesions but its use with high settings over polymer-jacketed wires is discouraged.

A320: ULTRASOUND VASCULAR FEATURES IN FAILED TRANSRADIAL ACCESS FOR PERCUTANEOUS CORONARY PROCEDURE

Simona Minardi (a, b), Alessandro Sciahbasi (d), Francesco Starnazzi (a), Alessandro Bocci (c), Nicolò Salvi (d), Cristian Di Russo (d), Roberto Patrizi (d), Maria Cera (d), Silvio Fedele (d), Luigi Sciarra (a), Silvio Romano (a), Antonino Granatelli (d)
(a) UNIVERSITY OF L'AQUILA, L'AQUILA, ITALY; (b) CARDIOLOGY DEPARTMENT, FABRIZIO SPAZIANI HOSPITAL, FROSINONE, ITALY; (c) DIVISION CARDIOLOGY, DEPARMENT OF CLINICAL AND MOLECULAR MEDICINE, FACULTY OF MEDICINE AND PSYCOLOGY, SANT'ANDREA, SAPIENZA UNIVERSITY, ROME, ITALY; (d) DIVISION CARDIOLOGY, SANDRO PERTINI HOSPITAL, ROME

Background. International guidelines recommend Trans-radial approach (TRA) as routinary vascular access for percutaneous coronary intervention (PCI) since the demonstrated reduction in access-site vascular complication and improvement of patient comfort compared to transfemoral access. Anyway, TRA failure and crossover to a different access account up to 10% of procedures. Data about clinical factors predisposing to crossover are lacking as well as information about anatomical features of failed approach. Aim of our study is to evaluate echographic characteristics of wrist arterial vessels after primary TRA failure. Then, demographic and anthropometric characteristics, vascular parameters and complication rates of patients who underwent crossover or non-crossover procedures were compared.

Methods. All patients who underwent to percutaneous coronary diagnostic or interventional procedures through TRA that necessitated of vascular crossover after TRA failure were included in this prospective observational study. A control group of consecutive patients with TRA without crossover was included (with a 2:1 rate compared to crossover). All patients were checked 24-hour post procedure to perform wrist vessels ultrasound (US) and to evaluate possible vascular complications and bleeding. Diameter, perimeter, area, intimal thickness and distance from the subcutaneous were measured in short axis, doppler parameters such as peak systolic velocity (PSV), end-diastolic velocity (EDV), resistance index (RI=(PSV-EDV)/PSV) were measured in long axis.

Results. A total of 183 patients were enrolled in the study, 61 crossover (70% right TRA failure, 30% left TRA failure) and 122 controls. After failure of TRA, the crossover was performed: to contralateral radial 48% (n.29), to trans-femoral access (TFA) 44% (n.27), to trans-ulnar access 6% (n.4) and to trans-humeral access 2% (n.1). The crossover was mainly due to tortuosity (44%, n.27) and failed puncture (34%, n. 21), more rarely due to thin caliber (8%, n.5), vasospasm (7%, n.4), anatomical variant (5%, n.3) and subclavian stenosis (2%, n.1). In the crossover group females were significantly more than in the control group (49% vs 30%, p 0.02). Crossovers were also significantly older than the cases (71±10 years-old vs 67±11 years-old, p=0.003), shorter in stature (165±11 mm vs 170±8 mm, p<0.001) and had lighter in body weight (68±15 kg vs 77±14 Kg, p 0.04). Comparing ultrasound data, diameter, and perimeter of the failed TRA were significantly smaller than the control TRA (2.8±0.09 mm vs 2.9±0.08 mm, p=0.05 and 9.3±0.24 mm vs 9.6±0.21 mm, p=0.007). Area of the failed TRA was smaller than the corresponding TRA in the control group (7±0.2 mm^2 vs 8±0.10 mm^2) although statistical significance was missed (0.12), maybe due to the small sample size. No significant differences were found in doppler parameters. Radial dissections were the only vascular complications observed and were significantly more frequent among crossovers than controls (5% n.3 vs 0, p=0.03). No major bleeding was observed, anyway, vascular access hematomas rate was significantly more frequent among crossovers (16% n.10 vs 6% n.5, p=0.01).

Conclusions. In our study, radial US evaluation after TRA failure showed a smaller calibre of the artery associated with patients' older age, female sex, shorter height and lighter body weight compared to controls. Moreover, crossover is associated with higher rate of vascular complications. Larger sample size is necessary to confirm our results.

A321: IMPACT OF CUSP OVERLAP TECHNIQUE ON CONDUCTION DISTURBANCES AFTER TAVI USING SELF-EXPANDING VALVES: A CT-BASED SINGLE-CENTER STUDY

Silvia Crescenzia Motta (a), Giuliano Costa (a), Orazio Strazzieri (a), Elena Dipietro (a), Valentina Frittitta (a), Alessandro Comis (a), Mariachiara Calì (a), Sofia Sammartino (a), Marco Barbanti (a), Corrado Tamburino (a)
(a) POLICLINICO G. RODOLICO CATANIA

Aims. Conduction disturbances (CDs) remain an important limitation of transcatheter aortic valve implantation (TAVI) therapy, particularly with the self-expanding Evolut device. The introduction of the "cusp overlap technique" (COT) demonstrated to reduce the rate of permanent pacemaker implantation (PPI) in patients undergoing Evolut implantation. The aim of this analysis was to assess the efficacy of COT in reducing the rate of CDs after Evolut implantation by performing a granular analysis of post TAVI computed tomography angiography (CTA).

Methods and Results. Forty-six consecutive patients undergoing TAVI with the Evolut platform deployed using the COT and post-procedural CTA were compared with a historical cohort of Evolut patients in which COT was not used. Pre-TAVI CTA assessment included the length of membranous septum and the distribution of cusp calcium volume. Post-TAVI CTA assessment included the implantation depth. Implantation depth was also measured by angiography. At 30-day PPI rate was numerically lower among the COT group (6.5% vs. 15.2%, p=0.315). At CTA analysis, implantation depth did not differ between the 2 groups [9.0mm (IQR 6.5-10mm) vs. 10.5mm (IQR 5.8-12mm), p=0.58, COT vs. no-COT, respectively]. The length of membranous septum (p=0.65), the implantation depth (p=0.75) and the cusp calcium volume (right cusp, p=0.07; left cusp, p=0.72; non coronary cusp, p=0.98) were not associated with 30-day PPI after TAVI. The only factor associated with 30 days PPI was the presence of pre-procedural right bundle branch block (odds ratio 7.52, 95% confidence interval 1.28-43.94, p=0.012).

Conclusions. In a high-volume TAVI centre, the use of COT for self-expanding TAVI deployment yield to a numerical reduction of PPI rates, whilst not leading to higher implantation depth. This latter result can be explained by a more tailored implantation depth applied during TAVI. Larger, prospective, real-world studies involving patients treated by expert TAVI operators are required to confirm these findings.

A322: TAVI NELLO SHOCK CARDIOGENO: DAL SIZING IN URGENZA ALL'ASSISTENZA VENTRICOLARE MECCANICA

Ludovico Rossetto (a), Salvatore Evola (a), Daniele Adorno (b), Alessandro D'Agostino (a), Daniela Di Lisi (a), Oreste Fabio Triolo (a), fabio Balasus (a), Sebastiano Castrovinci (b), Salvatore Torre (b), Vincenzo Argano (b), Giuseppina Novo (a)
(a) U.O.C DI CARDIOLOGIA-DIPARTIMENTO PROMISE-AZIENDA OSPEDALIERA POLICLINICO PAOLO GIACCONE- UNIVERSITÀ DEGLI STUDI DI PALERMO;
(b) U.O.C DI CARDIOCHIRURGIA-AZIENDA OSPEDALIERA UNIVERSITARIA POLICLINICO PAOLO GIACCONE PALERMO

Caso clinico. Un paziente di 78 anni, iperteso, dislipidemico, diabetico ed affetto da insufficienza renale cronica V stadio veniva ricoverato presso l'U.O di Cardiochirurgia con diagnosi di scompenso cardiaco acuto. All'elettrocardiogramma si riscontrava un ritmo sinusale con segni di ipertrofia ventricolare sinistra. All'ecocardiogramma trans-toracico: ipertrofia parietale concentrica con funzione sistolica lievemente ridotta (FE biplana 52%); al Doppler emergeva un quadro compatibile con stenosi aortica severa (gmed 73 mmHg; gmax 104 mmHg) e di insufficienza aortica lieve-moderata. L'area valvolare calcolata mediante equazione di continuità era pari a 0,6 cmq- 0,33 cm/mq. In quarta giornata di ricovero si verificava un arresto cardiaco secondario ad asistolia che veniva risolto con successo dalle manovre di rianimazione cardio-polmonare. Il paziente veniva successivamente intubato ed alla luce del quadro conseguenziale di shock cardiogeno ostruttivo, venivano somministrati inotropi. La coronarografia in urgenza non mostrava anomalie significative. L'ecocardiogramma di rivalutazione metteva in evidenza un peggioramento della funzione sistolica (da 52% a 28%) mentre le sezioni destre apparivano normali per dimensioni e funzione sistolica. In considerazione del quadro clinico di shock ostruttivo, si optava per l'esecuzione di una sostituzione valvolare aortica trans-catetere (TAVI) in urgenza. Per la difficoltà logistica dell'esecuzione di un studio TC cardio sincronizzato mirato, veniva effettuato un ecocardiogramma trans-esofageo con integrazione 3 D. Il diametro dell'annulus aortico in 2 D era pari a 19 mm. La misurazione dell'annulus aortico in 3 D con ricostruzione multiplanare (MPR) mostrava un diametro maggiore di 2.42 cm, un diametro minore di 1,83 cm ed un'area pari a 4.05 cm^2. Veniva pertanto pianificato l'impianto di una protesi auto-espandibile numero 26 mm. La procedura veniva eseguita con il supporto emodinamico dell'ECMO veno-arterioso garantendo un flusso di 3,5 L/min. Confermato il sizing con un pallone da 20 mm, veniva impiantata con successo una protesi auto espandibile (Medtronic Evolut PRO + 26 mm). Il weaning dall'ECMO veniva effettuato subito dopo la procedura in assenza di ripercussioni emodinamiche.

Conclusioni. La valvuloplastica aortica è gravata da un'elevata mortalità e da un rischio significativo di complicanze. Alcuni dati in letteratura suggeriscono che la TAVI è sicura ed efficace nel setting di pazienti con shock cardiogeno. La TC cardio sincronizzata è fondamentale nella pianificazione del sizing, tuttavia la misurazione dell'annulus aortico mediante ecocardiografia trans-esofagea tridimensionale, con MPR, consente di ottenere valori accurati. I dati ottenuti dall'ecocardiografia in 2D avrebbero indotto ad una sottostima del reale sizing protesico. Nonostante le evidenze in letteratura sull'utilizzo dell'ECMO durante TAVI, siano contradditorie, nel nostro caso l'utilizzo di tale dispositivo ci ha consentito di operare in un contesto di stabilità emodinamica. L'impiego dell'ecocardiografia tridimensionale, dei dispositivi di assistenza ventricolare, la pianificazione e l'esecuzione procedurale nell'ambito dell'Heart Team rappresentano elementi fondamentali per la riuscita della TAVI nel setting ad alto rischio dei pazienti con shock cardiogeno.

A323: EFFICACIA DI PRODOTTI AD AZIONE LOCALE NELLA PREVENZIONE DI COMPLICANZE NEI DISPOSITIVI CARDIACI IMPIANTABILI

Maria Grazia Ricci (a), Fabiana Malci (a), Lucy Barone (a), Edoardo Cecchini (a), Matteo Rizzuto (a), Domenico Sergi (a), Carlo Chiaramonte (b), Francesco Barilla´ (a, b)
(a) POLICLINICO TOR VERGATA; (b) UNIVERSITÀ DEGLI STUDI ROMA "TOR VERGATA"

Le due complicanze più comuni in seguito all'impianto di un CIED (Cardiac Implantable Electronic Devices) sono gli ematomi e le infezioni (Cardiac Implantable Electronic Devices Infection, CIEDI). In pazienti con malattie cardiovascolari molteplici fattori, quali l'età avanzata, l'IRC, la presenza di coagulopatie, la terapia antitrombotica influiscono sia sullo sviluppo di CIEDI che di ematoma di tasca. L'uso di dispositivi rilascianti antibiotico direttamente nella tasca si è dimostrato efficace nel ridurre le CIEDI; in particolare nel trial WRAP-IT, l'impiego di un involucro rilasciante minociclina e rifampicina (TYRX™, Medtronic), ha portato ad una riduzione significativa dei casi di CIEDI in pazienti ad alto rischio. Inoltre, un recente studio retrospettivo ha dimostrato una riduzione del tasso di infezione ed ematoma di tasca e del tasso delle singole complicanze con l'utilizzo di una matrice di collagene di origine bovina impregnato con gentamicina (COLLATAMP® G, Schering-Plough). Per quanto riguarda l'emostasi, tra gli agenti topici, l'impiego di una matrice di collagene di origine bovina con trombina di derivazione umana ad elevata concentrazione (Floseal® (Baxter Healthcare Corporation) è stato valutato in pazienti in doppia terapia antiaggregante sottoposti ad impianto di CIED. Nei pazienti trattati con Floseal il tasso di ematoma è risultato significativamente inferiore rispetto al gruppo di controllo. Attualmente non ci sono dati in letteratura che hanno confrontato questi differenti tipi di approcci per ridurre l'incidenza di complicanze da impianto di CIED.

Obiettivi. L'obiettivo del nostro studio è valutare l'impatto dell'utilizzo di Collatamp versus TYRX e Floseal sull'incidenza di CIEDI e/o ematomi di tasca.

Materiali e metodi. Nel periodo compreso tra gennaio 2023 e giugno 2023, sono stati arruolati retrospettivamente 25 pazienti, di cui 16 uomini (64%) e 9 donne (36%) di età media di 76 ±6.1 anni che sono stati sottoposti a impianto o sostituzione di PMK (36%), ICD (16%) o CRT (44%). In 13 pazienti (52%) è stato utilizzato TYRX e Floseal, in 12 pazienti (48%) è stato utilizzato solo il Collatamp. Per ogni paziente è stato considerato il livello di rischio di CIEDI secondo l'UPMC score e il rischio emorragico secondo l'HAS-BLED e sono stati raccolti i dati sulle caratteristiche cliniche. Tutti i pazienti sono stati sottoposti a controllo clinico con un follow up medio di 3.6±2mesi; ad ogni visita veniva valutata la presenza o meno di ematomi e/o infezioni della tasca.

Risultati. Dall'analisi statistica è emerso che i fattori di rischio considerati per il calcolo dell'UPMC score sono maggiori nel gruppo sottoposto a utilizzo di TYRX più Floseal (p-value 0,0025) rispetto al gruppo con solo Collatamp. I due gruppi sono stati confrontati considerando anche altre variabili, tra cui l'HAS-BLED, l'uso di TAO/DOAC, la terapia antiaggregante, la presenza di diabete e di IRC. Dal test della mediana si evince che per solo tre variabili (creatinina, p-value 0,001; IRC, p-value 0,1; sesso maschile, p-value 0,05) c'è una differenza statisticamente significativa tra i due gruppi. Le altre variabili, invece, si presentano del tutto sovrapponibili tra i due gruppi. Sulle complicanze registratesi nel primo mese di follow up, nel gruppo TYRX e Floseal un solo paziente ha sviluppato ematoma della tasca (7.7%) e un solo paziente del gruppo Collatamp (8.3%) ha sviluppato la stessa complicanza. Nessun paziente ha sviluppato CIEDI con un follow up medio di 3.6±2 mesi.

Conclusioni. I dati del nostro studio, seppur limitato dalla bassa numerosità del campione e dal breve periodo di follow up, mostrano che non c'è differenza tra i due approcci (TYRX e Floseal vs Collatamp) sul rischio di ematoma e di infezione. Sono dunque necessari studi futuri prospettici e più ampi per confrontare l'efficacia di questi prodotti nella prevenzione delle complicanze da CIED.

A324: TRANSCATHETER BICAVAL VALVLE SYSTEM IMPLANTATION: EYES OPEN AND HANDS READY

Massimo Russo (a), Pietro Oro (a), Valerio Maffi (a), Massaro Gianluca (a), Di Luozzo Marco (a), Marchei Massimo (a), Gaetano Idone (a), Gaetano Chiricolo (a), Giuseppe Massimo Sangiorgi (a)
(a) U.O.C. CARDIOLOGIA POLICLINICO "TOR VERGATA"

Introduction. TricValve is a system consisting of two biological valves made of bovine pericardium sutured to a stent made of self-expandable nitinol used in the treatment of patients with tricuspid regurgitation for hemodynamic relief with reflux in the vena cava. This system is particularly suitable for use in high-risk patients, improving liver congestion and peripheral edema, increasing the stroke volume of the RV in the pulmonary circulation, and improving CO.

Case summary. This case report concerns an 81-year-old Caucasian female patient with no relevant cardiac history and with previous partial gastric resection due to a neuroendocrine tumor, with repetitive lesions of the liver, currently in follow-up. In November 2022, she was admitted to our cardiology department because of worsening peripheral edema and new-onset atrial fibrillation and was treated with intravenous diuretic therapy, anticoagulant therapy, and optimization of heart rate control. The initial TTE showed enlarged right sections, torrential tricuspid regurgitation with leaflet immobility and dilated inferior vena cava non-collapsible with inspiration, with the presence of reverse flow. The next step was a thoracoabdominal CT angiography, which excluded the possibility of pulmonary embolism and revealed bilateral pleural effusion and cardiomegaly. She performed also coronary angiography and right heart catheterization, which documented that the coronary arteries were free of angiographically significant stenosis and mean pulmonary pressure was normal with increased pulmonary vascular resistance. The case was discussed in the Heart Team and it was decided to percutaneously implant the TricValve in light of the clinical picture, the unfavorable valve architecture and the dilated RV. The system was implanted via right femoral venous access with a 24F introducer. At the end of the procedure, when the vascular accesses were closed, there was high pressure bleeding from the right femoral venous access, with an ineffective attempt at tamponade from the contralateral access by inflating a 12 x 40 mm balloon through a 6F introducer. After having found contralateral arterial access and performed arterial and venous angiography of the right iliac-femoral axis, a diagnosis of arterio-venous fistula between the deep femoral artery and femoral vein was made, resolved by positioning a covered stent. Subsequently, she performed vascular surgery videat with ECD showing patency of the common femoral artery and deep femoral artery, previously stenting site.

Conclusions. In conclusion the implantation of TricValve requires the ability to manage large-caliber accesses that can present unexpected complications.

A325: DON'T LET THE SHOCK GO DOWN ON ME

Riccardo Scalamera (a), Antonia Luisa Buongiorno (a), Sofia Hassan (a), Paolo Archetti (a), Gianluca Anastasia (a), Italo Porto (a, b), Rocco Vergallo (a, b)
(a) DIPARTIMENTO DI MEDICINA INTERNA (DIMI), UNIVERSITÀ DI GENOVA, GENOVA; (b) UNITÀ OPERATIVA DI CARDIOLOGIA, DIPARTIMENTO CARDIO-TORACO-VASCOLARE (DICATOV), OSPEDALE POLICLINICO SAN MARTINO IRCCS - IRCCS CARDIOVASCULAR NETWORK, GENOVA

Introduction. We present two clinical cases of patients with ST-elevation acute myocardial infarction (STEMI) complicated by cardiogenic shock (CS) treated successfully with implantation of a percutaneous left ventricular assist device (Impella CP) and primary percutaneous coronary intervention (pPCI).

Case 1. A 64 years-old man was admitted with an extensive antero-lateral STEMI complicated by CS and incessant polymorphic ventricular tachycardia/ventricular fibrillation requiring multiple DC shocks and adrenaline infusion. After placement of an Impella CP pump (within 7 minutes) and temporary backup pacemaker during cardiopulmonary resuscitation, emergency coronary angiography (CA) was performed. This showed three-vessel coronary artery disease with acute thrombotic occlusion of the ostial left anterior descending coronary artery (LAD) and further sub-totally occlusive disease in the left circumflex (LCx)-obtuse marginal (OM) bifurcation of a left dominant coronary system. PPCI with two drug-eluting stents (DES) implantation was performed. After reperfusion, there was a gradual recovery of cardiac pulsatility on invasive pressure monitoring. Weaning was successfully performed after 2 days. This case highlights the hemodynamics of recovery from CS after complete revascularization of a patient with STEMI, with real-time left ventricular pressure tracings continuously recorded with the Impella CP system.

Case 2. A 79 years-old man was admitted with an infero-lateral STEMI. Emergency CA showed three-vessel disease. Shortly after the start of the procedure, however, he arrested in asystole. Following intubation, implantation of Impella CP and the activation of temporary pacing, electrical and haemodynamic stabilization was achieved. Finally, pPCI was performed implanting two DES to LCx-OM1 and three DES to left main-LAD. Cangrelor was administered throughout the procedure. Because haemodynamic stabilization had been achieved, the Impella pump was removed afterwards ensuring prompt haemostasis.

Conclusions. Percutaneous mechanical circulatory supports are valuable tools in the context of acute myocardial infarction complicated by cardiogenic shock. Impella CP ensures rapid and powerful left ventricular support, and proved to be of utmost importance to stabilize the patients and successfully complete the procedures in the presented cases.

A326: DISSEZIONI CORONARICHE SPONTANEE: TO DO OR NOT TO DO?

Tarek Shail (a), Alessandro Carli (a), Enrico Cerrato (b), Ferdinando Varbella (b), Giuseppe Patti (a)
(a) AOU MAGGIORE DELLA CARITÀ DI NOVARA; (b) AOU SAN LUIGI GONZAGA E OSPEDALE DEGLI INFERMI RIVOLI

Razionale. Le dissezioni spontanee restano ancora oggi una sfida difficile, dove l'approccio nel cathlab può variare dagli aspetti diagnostici (valutazione angiografica? Imaging?), quelli interventistici (approccio conservativo? Wait and see? O angioplastica?) a quelli terapeutici farmacologici (singola terapia anti-piastrinica/SAT? O doppia terapia anti-piastrinica/DAPT?).

Risoluzione tecnica. Il caso mostra una paziente che a 43 anni, senza fattori di rischio cardiovascolare, nel 2010 esordiva con uno STEMI anteriore per dissezione coronarica spontanea (SCAD) della discendente anteriore (IVA) medio distale e della coronaria destra (CDx) prossimale e distale trattato con impianto di stent BMS sull'IVA medio distale e sulla Cdx prossimale. Nel 2018 nuova recidiva con NSTEMI con evidenza alla coronarografia di dissezione spontanea del tratto distale della discendente posteriore (IVP) trattata con strategia conservativa. Nuovamente nel settembre 2019 NSTEMI con evidenza alla coronarografia di dissezione spontanea del tratto distale della Cdx e del ramo posterolaterale (PL) trattata con approccio conservativo e follow up con coro TC. A novembre 2019 per dolore toracico atipico ennesimo controllo angiografico con evidenza di buon esito delle pregresse angioplastiche su IVA e Cdx, ma durante la procedura diagnostica si evidenza un improvviso ristagno di mezzo di contrasto nel tronco comune (TC) con sopraslivellamento del tratto ST. Si procedeva a dilatazioni multiple con pallone NC su asse TC-IVA senza ripresa del flusso per cui con guida Sion Blue al tratto medio di IVA si perfora l'ematoma subintimale con ripresa di flusso. Alla valutazione OCT si riscontro immagine di dissezione del TC e dell'IVA prossimale media limitata nella sua evoluzione, per fortuna della paziente, dallo stent impiantato nel 2010 sull'IVA medio distale.
Implicazioni cliniche e prospettive. I pazienti con SCAD nella loro storia clinica spesso presentano plurimi episodi recidivanti, che possono portare a plurimi studi coronarografici anche per eventi sfumati, come l'ultimo episodio della nostra paziente con dolore toracico atipico. Gli scenari che si possono incontrare possono implicare difficili scelte della strategia terapeutica, con valutazioni rischio-beneficio complicate, o possono essere portati da complicanze intra-procedurali fin dalla fase diagnostica, con rapida degenerazione del quadro clinico e gestioni intra-procedurali complicate. Sicuramente i criteri per la scelta terapeutica contrapposta tra approccio conservativo ed interventistica restano la sfida principale da definire. L'avvento delle nuove tecnologie di imaging, come la coro TC, possono rappresentare un valido ausilio se non per la diagnosi sicuramente per il follow up, limitando le temute complicanze intra-procedurali. Non da meno la scelta della miglior terapia antipiastrinica post evento, data la scarsità di letteratura per la rarità della SCAD.

A327: UNA LUNGA INFUSIONE DI CANGRELOR

Donatella Tansella (a), Marta Tansella (b), Davide Betta (b), Anna Carrer (b), Nicola Gasparetto (b)
(a) UNIVERSITÀ DEGLI STUDI DI PADOVA; (b) OSPEDALE CA' FONCELLO - TREVISO

Il Cangrelor è un antagonista del recettore piastrino P2Y12 con una cinetica molto rapida. Presentiamo il caso di una donna con infarto miocardico acuto in corso di colecistite, sottoposta a rivascolarizzazione miocardica percutanea e, dopo poche ore, a colecistectomia laparotomica gestita con infusione di Cangrelor per una durata totale di 9 giorni. La paziente accedeva in PS per dolore addominale: veniva posta diagnosi di colecistite acuta litiasica perforata, con indicazione ad intervento chirurgico urgente. L'ECG evidenziava sopraST anterosettale. Veniva sottoposta a coronarografia urgente che mostrava subocclusione dell'arteria discendente anteriore al tratto medio; si decideva di eseguire PCI su DA in corso di infusione di Cangrelor (bolo di 30 µg/kg + infusione continua a 4 µg/kg/min).

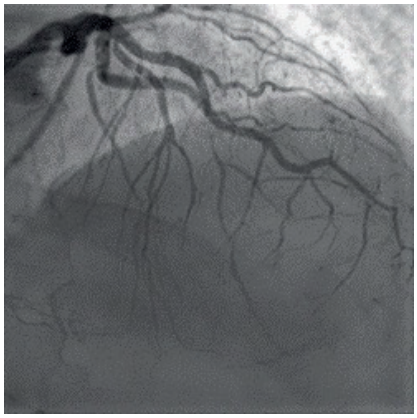

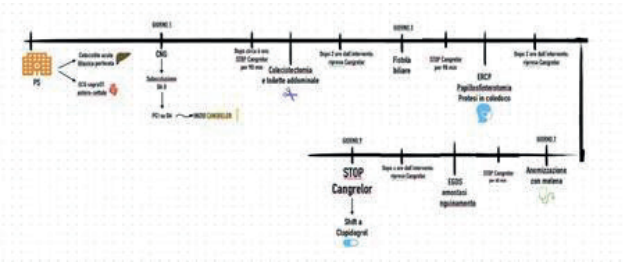

Dopo alcune ore di osservazione, si sospendeva il Cangrelor per 90 min, e la paziente veniva sottoposta a colecistectomia e toilette addominale. Dopo 2 ore dall'intervento chirurgico, veniva ripresa l'infusione di Cangrelor al dosaggio bridge (0.75 µg/kg/min). Due giorni dopo si constatava la presenza di fistola biliare con necessità di ERCP, papillosfinterotomia e posizionamento di protesi metallica in coledoco, sospendendo nuovamente l'infusione di Cangrelor. Nei giorni successivi anemizzazione (Hb 8 mg/dL) con melena, quindi, la paziente veniva sottoposta a EGDS con riscontro di sanguinamento attivo in sede di recente sfinterotomia, si procedeva ad emostasi in sospensione di Cangrelor (da un'ora prima a 6 ore dopo la procedura). Dopo 9 giorni dalla rivascolarizzazione miocardica si sospendeva l'infusione e si eseguiva shift a Clopidogrel. La somministrazione di Cangrelor, in associazione ad Aspirina, è indicata in pazienti sottoposti a PCI che non hanno ricevuto un inibitore orale del P2Y12. È indicata una durata dell'infusione di almeno due ore o per tutta la durata dell'angioplastica senza superare 4 ore. Le ultime linee guida ESC consigliano il suo utilizzo anche nei pazienti ad alto rischio ischemico, recentemente sottoposti a PCI, che vanno incontro a interventi chirurgici maggiori non differibili. La durata massima sperimentata è di 7 giorni. Nel nostro caso si è resa necessaria un'infusione di farmaco più prolungata, a causa delle complicanze post chirurgiche, che ha permesso di risolvere tali complicanze riducendo il rischio emorragico in una paziente ad alto rischio ischemico, cosa che non sarebbe stata possibile con gli inibitori orali del P2Y12.

A328: PROGNOSTIC ROLE OF PHYSIOLOGICAL GUIDED PCI IN PATIENTS WITH DIABETES MELLITUS

Domenico Galante (b), Stefano Migliaro (c), Federico Di Giusto (a), Gianluca Anastasia (a), Edoardo Petrolati (a), Andrea Viceré (a), Giuseppe Zimbardo (d), Pio Cialdella (d), Chiara Giuliana (a), Ciro Pollio Benvenuto (a), Vincenzo Viccaro (a), Simona Todisco (a), Enrico Romagnoli (a), Cristina Aurigemma (a), Francesco Burzotta (a), Carlo Trani (a), Filippo Crea (a), Antonio Maria Leone (b)
(a) UNIVERSITÀ CATTOLICA DEL SACRO CUORE - POLICLINICO GEMELLI IRCSS - ROMA; (b) OSPEDALE FATEBENEFRATELLI ISOLA TIBERINA - GEMELLI ISOLA; (c) AURELIA HOSPITAL; (d) POLICLINICO CASILINO - ROMA

Background. Emerging data showed that Physio-guided PCI (which incorporates functional assessment before and after the procedure) is associated with a reduced risk of adverse cardiovascular events. However, its role to predict outcome in patients with diabetes mellitus is not well established.
Aims. We investigated the prognostic ability of Physio-guided PCI to predict outcomes in patients with or without diabetes mellitus.
Methods. This is a sub-study of the PROPHET-FFR registry. Patients were divided in two groups according to the presence of diabetes mellitus; each subgroup was then stratified into three groups based on the results of invasive physiological assessment (IPA): Control group comprising patients for whom PCI was deferred based on a IPA; Angio-Guided PCI group comprising patients undergoing PCI based on an IPA but without a post-PCI IPA; Physio-guided PCI group comprising patients undergoing PCI based on an IPA and an IPA after PCI; The primary endpoint was the rate of major adverse cardiac events (MACEs), defined as a composite of death from any cause (AD), myocardial infarction (MI) and target vessel revascularization (TVR) at 36-months.
Results. A total of 1322 patients and 1591 lesions were available for the analysis. At Kaplan-Meier analysis with log-rank test the rate of MACEs was significantly higher in the Angio-guided PCI Group both in non-diabetic (8.9% in Control Group, 16.2% in Angio-guided PCI Group, 9.0% Physio-guided PCI Group, $p<0.01$) and diabetic patients (11.9% in Control Group, 27.1% in Angio-guided PCI Group, 7.2% Physio-guided PCI Group, $p<0.01$). A significant benefit of Physio-guided PCI over Angio-guided PCI was observed in patients with diabetes mellitus (MACEs, 27.1 Angio-guided PCI Group, 7.2% Physio-guided PCI Group $p<0.01$), driven principally by TVR (12.9 Angio-guided PCI Group, 4.3% Physio-guided PCI Group $p=0.07$) and AD (14.3 Angio-guided PCI Group, 1.4% Physio-guided PCI Group $p<0.01$). This was less evident in non-diabetic patients (MACEs, 16.2 Angio-guided PCI Group, 9.0% Physio-guided PCI Group $p=0.105$).
Conclusions. Physio-guided PCI confirmed its ability to predict outcomes in patients with or without diabetes mellitus. This benefit was consistently observed when compared to Angio-guided PCI only among patients with diabetes mellitus. These findings support the potential clinical utility of physio-guided PCI, particularly in patients with diabetes mellitus.

A329: PREDICTIVITY OF CORONARY MICROVASCULAR DYSFUNCTION (CMD) BY TIMI FRAME COUNT (TFC) WITH BOLUS AND CONTINUOUS THERMODILUTION IN PATIENTS WITH ANGINA AND NON-OBSTRUCTIVE CORONARY ARTERIES (ANOCA)

Michele Mattia Viscusi (a, b), Dario Bertolone (a, b), Marta Belmonte (a, b), Giulia Botti (a), Monika Shumkova (a), Angelo Ratti (a), Pasquale Paolisso (a, b), Emanuele Barbato (a, c), Marc Vanderheyden (a), Bernard De Bruyne (a), Emanuele Gallinoro (a)
(a) OLV CARDIOVASCULAR CENTER, AALST, BELGIUM; (b) DEPARTMENT OF ADVANCED BIOMEDICAL SCIENCES, UNIVERSITY OF NAPLES FEDERICO II, NAPLES, ITALY; (c) DEPARTMENT OF CLINICAL AND MOLECULAR MEDICINE, SAPIENZA UNIVERSITY, ROME, ITALY

TIMI Frame Count (TFC)≥27 as a surrogate of coronary slow flow has been historically used as a predictor of coronary microvascular dysfun-

ction (CMD) in patients with angina and non-obstructive coronary arteries (ANOCA). However, multiple recent evidence revealed a substantial inaccuracy of slow flow in detecting CMD, particularly when performing bolus thermodilution (BTD) with ectatic vessels, since slow flow does not necessarily correspond to low flow and high microvascular resistance. In such cases, continuous thermodilution (CTD) have been proposed to overcome this limitation. Therefore, the aim of the present study is to assess the predictivity and correlation of CMD by TFC with both BTD and CTD. 105 patients with ANOCA underwent full physiological assessment with BTD/CTD and, subsequently, TFC calculation. Of them, 11 patients revealed CMD according to BTD criteria (coronary flow reserve [CFR]<2.5 and index of microcirculatory resistance [IMR] ≥25), whereas 34 CMD patients have been diagnosed with CTD criteria (CFR<2.5 and microvascular resistance reserve [MRR]<2.5). TFC showed a strong predictivity of CMD with BTD (AUC: 0.734 [95% confidence interval (CI): 0.607-0.861], p=0.011) and a moderate correlation with IMR (r=0.253, p=0.009); conversely, it exhibited a poor diagnostic accuracy in predicting CMD with CTD (AUC: 0.470 [95% confidence interval (CI): 0.346-0.593], p=0.615) and no correlation with MRR (r=0.048, p=0.630).

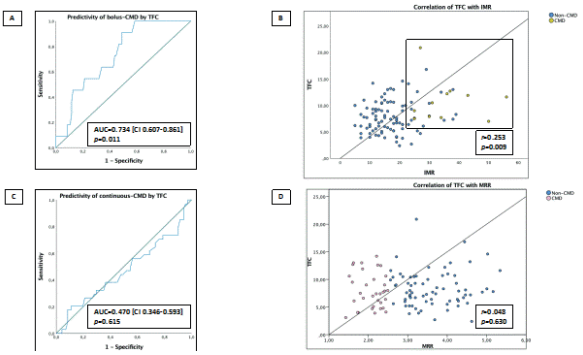

TFC is highly predictive of CMD with BTD. However, when assessing more accurately coronary microvascular status with CTD to overcome the multiple technical and anatomical limitations of BTD, the diagnostic performance of TFC decrease significantly since it poorly predicts MRR and, therefore, CMD.

A330: IMPACT OF CORONARY MICROVASCULAR DYSFUNCTION (CMD) ON THE DIAGNOSTIC PERFORMANCE OF QUANTITATIVE FLOW RATIO (QFR) IN PREDICTING INVASIVE FRACTIONAL FLOW RESERVE (FFR)

Michele Mattia Viscusi (a, b), Dario Bertolone (a, b), Marta Belmonte (a, b), Giulia Botti (a), Monika Shumkova (a), Angelo Ratti (a), Pasquale Paolisso (a, b), Bernard De Bruyne (a), Emanuele Barbato (a, c), Marc Vanderheyden (a), Emanuele Gallinoro (a)
(a) OLV CARDIOVASCULAR CENTER, AALST, BELGIUM; (b) DEPARTMENT OF ADVANCED BIOMEDICAL SCIENCES, UNIVERSITY OF NAPLES FEDERICO II, NAPLES, ITALY; (c) DEPARTMENT OF CLINICAL AND MOLECULAR MEDICINE, SAPIENZA UNIVERSITY, ROME, ITALY

Quantitative Flow Ratio (QFR) is a novel wire-free technique developed to assess the functional significance of coronary stenoses by utilizing 3-dimensional quantitative angiography (3D-QCA) and frame counting. However, since QFR is derived from computational analysis of angiographic data and thus requiring fixed reproducible standardized conditions to precisely predict invasive fractional flow reserve (FFR), the presence of coronary microvascular dysfunction (CMD), as defined accordingly by an abnormal microvascular resistance reserve (MRR), may alter this prespecified hemodynamic profile. As a consequence, potential discrepancies between the QFR and FFR may be attributed to the status of the subtended coronary microcirculation. Therefore, we aimed to evaluate the impact of CMD on the diagnostic accuracy of QFR. This is an observational, single-center, study involving 169 patients with both obstructive and non-obstructive coronary artery disease (CAD) undergoing FFR measurement and a comprehensive microvascular assessment of absolute flow (Q) and resistance (R) with continuous thermodilution. The study population has been grouped according to the underlying microcirculatory status defined by MRR. Particularly, the presence of CMD has been defined by an abnormal MRR (<2.5). The impact of CMD on the diagnostic performance of QFR has been assessed using FFR as reference. In the overall cohort, the diagnostic efficiency of QFR (area under the receiver-operating characteristics curve [AUC]) were high (AUC: 0.864 [95% confidence interval (CI): 0.792-0.936]). However, when assessed according to microcirculatory status, a significantly lower AUC of QFR were found in the CMD group as compared with the non-CMD group (AUC: 0.67 [95% CI: 0.43 to 0.89] vs. 0.93 [95% CI: 0.87 to 0.97]; p<0.05). According to the multivariate analysis, independent predictors of disagreement between QFR and FFR were MRR<2.5 and the (%) diameter stenosis (p=0.042 and p=0.011, respectively). CMD decrease the diagnostic performance of QFR in predicting FFR and represent an independent predictor of disagreement between the two techniques.

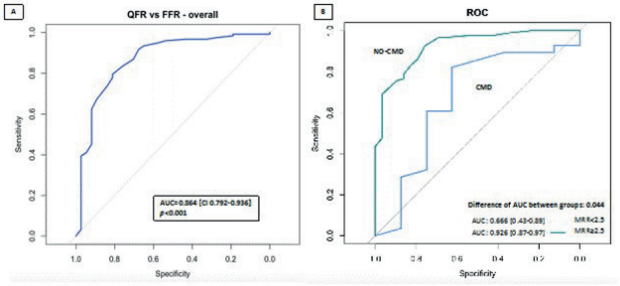

A331: VENTRICULAR FIBRILLATION AND TRANSIENT ST ELEVATION AFTER RIGHT CORONARY ARTERY PCI

Margherita Zanoletti (a), Sofia Hassan (a), Roberta Della Bona (b), Corinna Giachero (b), Andrea Macchione (b), Alberto Valbusa (b), Italo Porto (a, b)
(a) UNIVERSITÀ DEGLI STUDI DI GENOVA; (b) IRCCS OSPEDALE POLICLINICO SAN MARTINO

A 64-year-old man with several cardiovascular risk factors (active smoking, hypertension, family history for CAD, and peripheral arterial disease) was admitted to our cardiology ward for elective coronary angiography due to the presence of severe proximal stenosis of right coronary artery (RCA) at coronary computed tomography. He was asymptomatic and underwent coronary CT as pre-operative assessment for vascular surgery. Inducible myocardial ischaemia at stress SPECT in the posterior descending artery territory was also present. Echocardiography showed a preserved ejection fraction. Coronary angiography confirmed the presence of critical stenosis of proximal RCA, while there was no obstructive disease in the left coronary artery. Angiography also showed the presence of coronary-cameral fistulae. Percutaneous coronary intervention (PCI) with direct stenting of the proximal RCA was performed uneventfully. He was then transferred to ordinary cardiological ward for monitoring. After few minutes he developed recurrent ventricular fibrillation (VF) requiring cardiopulmonary resuscitation, epinephrine and amiodarone administration, and three direct current shock before return of spontaneous circulation. He showed high lactate levels at EGA, ST elevation from V1 to V3 at EKG, and no significant change in echocardiography. He underwent transfemoral coronary angiography control and an occlusion of small-sized conus artery was found. He was transferred to ICU for monitoring where no other ventricular arrythmias were developed and the ST-elevation resolved in about one hour. Anterior ST elevation due to occlusion of a right ventricular RCA branch has been reported previously[1] and is thought to be a mirror image of right ventricular ischemia. This case shows the correlation between conus branch and the development of transient ST elevation in V1-V3 and the occurrence of VF. These changes can remind of a Brugada syndrome-like electrocardiogram and in fact it is known that conus artery infuses right ventricular outflow tract[2]. It is possible that similar pathogenetic mechanisms are involved. It is important to pay attention to the conus artery ischemia due to occlusion or spasm during RCA angiography.

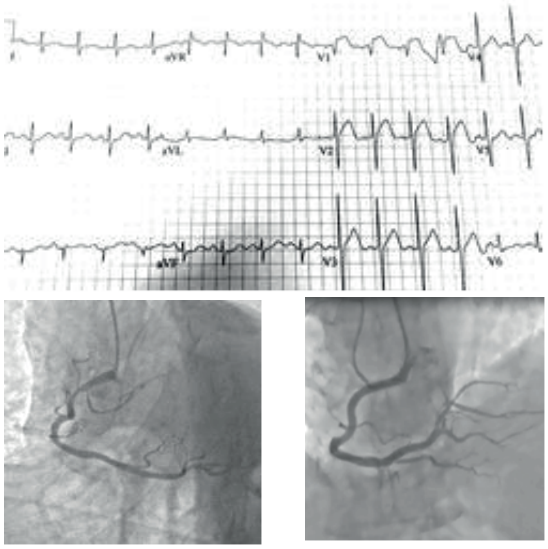

References
Kagiyama et al. Transient Precordial ST Elevation by a Spasm of the Conus Artery during Right Coronary Angiography.
Schlesinger, Zoll, e Wessler, The Conus Artery; a Third Coronary Artery.

A332: 1-YEAR IMAGING FOLLOW-UP OF COMPLETE REVASCULARIZATION WITH BIORESORBABLE VASCULAR SCAFFOLDS IN YOUNG PATIENTS. MAGMARIS CASE SERIES

Andrea Agbariah (a), Ilaria Armani (a), Francesca Rubino (a), Sara Maisenti (a), Gabriele Facci (a), Concetta Mammone (a), Mattia Lunardi (a), Roberto Scarsini (a), Valeria Ferrero (a), Simone Fezzi (a), Gabriele Pesarini (a), Domenico Tavella (a), Flavio Luciano Ribichini (a)
(a) DIVISION OF CARDIOLOGY, CARDIO-THORACIC DEPARTMENT, UNIVERSITY HOSPITAL OF VERONA, VERONA, ITALY

The resorbable magnesium scaffolds (RMSs) have demonstrated safety and efficacy in clinical practice. The preservation of coronary anatomy and vasomotor tone is an attractive goal, especially in young patients with multivessel disease, in which further invasive strategies remain open and long-term complications can be minimized. We report three cases of young patients undergoing complete revascularization with RMSs and clinical and angiographic 1-year outcomes. A 55-year-old man was admitted to our department with non-ST elevation myocardial infarction (NSTEMI). Invasive coronary angiography (ICA) documented a critical stenosis in the distal segment of the right coronary artery (RCA) and diffuse critical disease of the left anterior descending artery (LAD). After adequate lesion preparation, a 3.0×25 mm RMS, Magmaris, Biotronik AG, Buelach, Switzerland, was implanted on the RCA. The LAD was treated with three Magmaris (3.0x25 mm, 3.5x15mm and 3.5x25 mm) in a staged IVUS-guided procedure. Post-dilation with non-compliant (NC) balloons was performed in both vessels. One year later, the patient underwent an elective ICA and intravascular imaging with optical coherence tomography (OCT) showing a complete reabsorption of the RMSs with positive remodeling and luminal enlargement of the vessels. The patient was asymptomatic with good performance status. A 66-year-old man, smoker and overweight, presented to our department with NSTEMI. ICA documented critical stenoses in the mid-proximal segment of the LAD and in the mid-segment of the RCA. The two lesions were treated with an OCT-guided procedure (3.0×25 mm on the LAD and 3.0x20 mm on the RCA). Pre-dilatation and post-dilation were carefully performed in both vessels. At 12-month follow-up, elective ICA and OCT, showed a non-complete reabsorption of the RMSs. The LAD showed an intermediate ostial stenosis involving the proximal edge of the previous Magmaris. Another intermediate stenosis was found in the proximal-mid segment of the RCA. Coronary physiology assessment revealed non hemodynamic significance of both lesions (Fractional Flow Reserve (FFR) 0.84 and instantaneous wave-free ratio (iFR) 0.9 in the LAD; FFR 0,94, iFR 1 in the RCA). The patient was asymptomatic with a good performance status. A 59-year-old man with multiple cardiovascular risk factors and chronic kidney disease (CKD EPI eGFR 42 ml/min) was admitted to our department with unstable angina. ICA documented a critical bifurcation lesion of LAD, a critical stenosis in the proximal segment of the obtuse marginal (OM) branch and a critical stenosis in the mid-proximal RCA. A 3.5x20 mm Magmaris was implanted on LAD and two 3.5x20mm and 3.0x20mm RMSs were implanted on RCA with IVUS-guided procedure. The MO branch was treated with a drug-eluting balloon. One year later, the patient underwent an elective ICA, that showed good angiographic results of the lesions treated. He was asymptomatic with a good performance status. According to our experience, coronary revascularization with RMSs (Magmaris) may be a good option for young patients, especially with multivessel coronary disease, to avoid permanent metallic devices and regenerate the vessels. The latest European Society of Cardiology Guidelines on myocardial revascularization (2018) recommends the use of bioresorbable scaffolds only in research settings and clinical controlled registries. However, given the recent data and the promising perspective of the current studies, this indication could change.

A333: UNEXPECTED FINDING OF ANOMALOUS ORIGIN OF THE RIGHT CORONARY ARTERY FROM THE PULMONARY ARTERY (ARCAPA) IN LATERAL ST ELEVATION MYOCARDIAL INFARCTION DURING PRIMARY CORONARY ANGIOPLASTY: WHAT IS THE CULPRIT?

Giulio Montefusco (a), Luca Arcari (a), Giovanni Camastra (a), Salvatore Donato Musaro´ (a), Francesco Marino (a), Bruno Pironi (a), Francesca Fanisio (c), Massimiliano Danti (b), Claudia Malerba (a), Marco Centioni (a), Stefano Sbarbati (b), Luca Cacciotti (a)
(a) UNITÀ DI CARDIOLOGIA, OSPEDALE VANNINI, ROMA; (b) UNITÀ DI RADIOLOGIA, OSPEDALE VANNINI, ROMA; (c) UNITÀ DI CARDIOLOGIA, POLICLINICO CASILINO, ROMA

A 58-year-old man presented to the emergency department with sweating and chest pain started 90 minutes before. He did not have a past medical history. Physical examination showed chest pain and no clinical signs of heart failure (Killip class I). 12 leads electrocardiogram (EKG) at admission revealed sinus rhythm with persistent ST elevation in lateral leads (DI and aVL). A transthoracic echocardiogram (TTE) showed a normal left ventricular ejection fraction (LVEF 50%) with lateral and inferolateral left ventricular walls hypokinesia. The patient was diagnosed as having an acute ST elevation myocardial infarction and he was referred to the cathlab for emergency coronary angiography. Coronary angiography was performed showing a sub occlusive stenosis of the proximal portion of the ramus intermedius artery (RIA). Despite efforts, it was not possible to cannulate the right coronary artery (RCA), however, an extensive collateral circulation between the left and the right hypoplastic coronary artery was observed from the septum branches of the left anterior descending artery. Moreover, we found a retrograde filling of the right hypoplastic coronary artery towards the pulmonary artery (PA). Considering the ECG findings and the course of the intermediate branch in the absence of further stenosis, we identified the RIA as the culprit vessel. Therefore, a primary angioplasty was performed. After the procedure we observed a complete symptoms relief and the EKG showed regression of ST-segment elevation with T waves inversion in lateral leads. To better assess the suspected anomalous origin of RCA, we performed a cardiac computed tomography angiography (CCTA). This confirmed the origin of the hypoplastic right coronary artery from the PA with and good patency of the DES on the RIA. The anomalous origin was observed in the CCTA arterial phase, the retrograde filling of the pulmonary artery became evident in the venous phase. A diagnosis of Anomalous origin of the right coronary artery from the pulmonary artery (ARCAPA) was established. Given the absence of symptoms attributable to ARCAPA in our case, in the presence of a hypoplastic RCA we chose a conservative strategy. The patients was then discharged on day 7, no adverse events were recorded at a 6-months follow-up. ARCAPA is a rare coronary anomaly that affects approximately 0.12% of all congenital heart disease (CHD) cases and may progress into adulthood without symptoms. The identification of the culprit lesion in an acute setting can be challenging in the presence of a previously unknown coronary artery origin anomaly, especially when the culprit lesion and the coronary artery with abnormal origin supply the same ventricular wall. Selective engagement of anomalous coronary arteries often requires multiple catheters, plus increased contrast volume and radiation exposure. Moreover, the inability to engage the ostium of anomalous coronary artery can led to a wrong diagnosis of culprit lesion. ARCAPA should be suspected in the presence of RCA dilatation, retrograde flow through the RCA, direct flow between pulmonary artery and RCA and collateralization between LCA e RCA. Revascularization strategy has to consider the complex pathophysiological balance between anomalous RCA, collateral vessels and culprit lesion on coronary dominant artery, especially in ACS setting.

A334: TAVI ED ANGIOPLASTICA: PIANIFICAZIONE PRIMA DI TUTTO

Paolo Archetti (a), Matteo Vercellino (b), Italo Porto (b, c)
(a) UNIVERSITÀ DEGLI STUDI DI GENOVA; (b) DICATOV - DIPARTIMENTO CARDIO TORACO VASCOLARE, IRCCS SAN MARTINO; (c) DIPARTIMENTO DI MEDICINA INTERNA, UNIVERSITÀ DEGLI STUDI DI GENOVA.

Di seguito viene descritto il caso di un paziente uomo di 79 anni con stenosi aortica severa e concomitante coronaropatia critica calcifica, nello specifico la pianificazione di TAVI e successiva angioplastica. Per insorgenza di dispnea da sforzo, il paziente effettuava una visita cardiologica con riscontro ecocardiografico di stenosi aortica severa. In seguito il paziente si presentava in pronto soccorso per peggioramento improvviso della dispnea da insorgenza di tachiFA, veniva quindi ricoverato. In preparazione a discussione collegiale in heart team veniva eseguita coronarografia con riscontro di una lunga stenosi calcifica di coronaria destra ed una malattia intermedia del ramo discendente anteriore, alla TC torace presenza di arco aortico severamente calcifico. Con questi dati in sede di HT veniva posta indicazione a procedura per via percutanea. Per il labile stato di compenso e per la severità della valvulopatia si optava per rivascolarizzazione differita. Nonostante la necessità di riaccesso coronarico, data la severa calcificazione del tratto di efflusso del ventricolo sinistro, veniva impiantata una bioprotesi valvolare aortica autoespandibile 29mm. Per favorire l'accesso coronarico si verificava l'allineamento commissurale della bioprotesi, testando con successo il riaccesso coronarico a termine procedura. Il paziente accedeva in reparto in regime di elezione per angioplastica di CDx: la procedura veniva effettuata tramite accesso arterioso femorale 7Fr e catetere guida AL 0.75 7Fr, successivamente scambiato con catetere JR4 7Fr per impossibilità nel selettivare CDx con il precedente. Si utilizzava fin da subito un estensore di catetere Guideliner 7Fr, e tramite filo guida BHW si guadagnava l'ostio di CDx con buon supporto. Veniva posizionato un ulteriore filo guida Sion Blue ES, scambiato con una guida GrandSlam tramite microcatetere FineCross. Si eseguiva valutazione IVUS (pullback automatico) per pianificare la procedura ed affrontare le severe calcificazioni coronariche: si optava per multiple predilatazioni con palloni ad elevate pressioni e non complianti. L'impianto del primo DES (4.0x38 mm) al tratto mediodistale avveniva senza complicanze, ma al posizionamento del secondo DES (4.0x30 mm) al tratto medio si evidenziava una significativa dissezione subavventiziale e di immagine sospetta per perforazione coronarica. Veniva posizionato il DES al tratto medio e successivamente si eseguiva una valutazione IVUS che dimostrava la buona apposizione degli stent, confermando la presenza di vasto ematoma subavventiziale. Si procedeva a multipli tentativi di emostasi con gonfiaggio prolungato di palloni NC; ai controlli angiografici successivi si evidenziava estensione della dissezione al tratto prossimale del vaso, veniva posizionato un ulteriore DES (4.5x22 mm) a tale livello. La dissezione si estendeva ulteriormente rendendo necessario il posizionamento di un DES (4.5x12 mm) fino all'ostio del vaso. Il risultato angiografico finale era soddisfacente con buon flusso a valle degli stent ed in presenza di una significativa riduzione dell'impregnazione di contrasto al di fuori del vaso. Il paziente si manteneva emodinamicamente stabile per tutta la procedura e per il resto della degenza. Questo caso è esemplificativo delle difficoltà che devono esse-

re affrontate nella rivascolarizzazione dopo esecuzione di TAVI, partendo già dalla scelta della bioprotesi. Per lesioni estese e severamente calcifiche, ed in condizioni di riaccesso difficoltose, gli strumenti necessari per effettuare la procedura, come l'estensore di catetere e guide coronariche molto supportive, pur rimanendo fondamentali, possono presentare insidie e difficoltà tecniche e possono determinare complicanze significative.

A335: IMAGING INTRACORONARICO PER FAR LUCE SU UN'ANGIOGRAFIA INCERTA

Paolo Archetti (a), Andrea Macchione (b), Italo Porto (b, c)
(a) UNIVERSITÀ DEGLI STUDI DI GENOVA; (b) DICATOV - DIPARTIMENTO CARDIO TORACO VASCOLARE, IRCCS SAN MARTINO; (c) DIPARTIMENTO DI MEDICINA INTERNA, UNIVERSITÀ DEGLI STUDI DI GENOVA

Di seguito viene descritto il caso di un paziente uomo di 69 anni con sindrome coronarica cronica sottoposto a controllo angiografico, nello specifico il ruolo dell'imaging intracoronarico nella definizione di un'immagine angiografica di significato incerto. La storia cardiologica di questo paziente, affetto da ipertensione arteriosa, dislipidemia ed ex-fumatore, inizia nel 2014, quando a seguito di dolore toracico contattava il 112: all'ECG riscontro di STEMI anteriore. In sala di emodinamica riscontro di occlusione aterotrombotica acuta di discendente anteriore al tratto medio e stenosi critica di coronaria destra al tratto medio in biforcazione con ramo per il ventricolo destro. Veniva eseguita angioplastica primaria ed impianto di stent medicato (DES everolimus, 2.75 x 28 mm) su IVA media e successiva angioplastica di completamento intraricovero con PCI ed impianto di DES (everolimus, 2.75 x 23 mm) su CDx media in biforcazione con ramo per il ventricolo destro. A seguito dell'impianto di DES veniva eseguito "Rewiring" del side-branch, "Kissing-Balloon" e successive dilatazioni multiple a livello della biforcazione per persistenza di stenosi ostiale del SB. Il paziente rimaneva asintomatico per gli anni successivi, nel 2023 a seguito di test ergometrico di follow-up positivo per alterazioni ECG, veniva programmata coronarografia in regime di elezione. All'esame si osservava buon risultato della pregressa PCI + DES su IVA, il controllo angiografico della coronaria destra mostrava pervietà dello stent precedentemente impiantato in presenza di un'immagine di minus all'edge prossimale dello stesso, sospetta per malapposizione. Veniva quindi eseguita valutazione OCT che confermava il posizionamento del filo guida all'interno dello stent, in presenza di ipoespansione (MSA 3.2 mm2) e marcata malapposizione all'edge prossimale dello stesso. Gli strut dello stent malapposto mostravano parziale sviluppo di neointima e immagine sospetta per apposizione trombotica. Veniva quindi eseguita POT con pallone NC 4.0 x 6 mm, a seguire "wiring" del ramo secondario; si procedeva a "Kissing-Balloon" con palloni NC 2.0 x 15 mm nel SB e 3.5 x 15 mm in CDx. A questo punto veniva eseguita un'ulteriore valutazione con OCT che dimostrava buona espansione (MSA 6.8 mm2) ed apposizione dello stent. In conclusione, per risultato subottimale a livello dell'ostio del ramo per il ventricolo destro, ulteriore KB con palloni NC 2.5 x 15 mm nel SB e 3.5 x 15 mm in CDx. Il paziente rimaneva asintomatico per la durata della procedura e veniva dimesso il giorno successivo con indicazione a proseguire la DAPT per almeno 6 mesi, in aggiunta alla terapia domiciliare abituale. Il caso è esemplificativo di come l'angioplastica e stenting in biforcazione debba essere eseguita seguendo attentamente gli step previsti dalla metodica scelta, rimanendo aggiornati su eventuali modifiche e pubblicazioni di consensus sul tema. In aggiunta evidenzia il ruolo insostituibile dell'utilizzo di una metodica di imaging intracoronarico: sebbene il paziente fosse sostanzialmente asintomatico e gli stent angiograficamente pervi, l'utilizzo di OCT ha permesso di caratterizzare con precisione una problematica significativa ed angiograficamente indefinita, di pianificare la procedura in sicurezza confermando il corretto wiring dello stent, e di valutare il risultato dei provvedimenti intrapresi. Nel caso descritto, analizzando le immagini angiografiche del 2014, si può supporre che nell'eseguire stenting secondo tecnica Provisional, non sia stata eseguita l'ottimizzazione del tratto prossimale dello stent (POT) prima del "ReWiring" del side branch, compromettendo tutte le fasi successive dell'angioplastica per passaggio del filo guida fra la parete del vaso e le maglie dello stent.

A336: INCIDENCE AND DETERMINANTS OF PACEMAKER IMPLANTATION AFTER TRANSCATHETER AORTIC VALVE REPLACEMENT

Antonio Bellantoni (a), Sabato Sorrentino (a), Alessandra Panarello (a), Assunta Di Costanzo (a), Federica Bruno (a), Alessandro Caracciolo (a), Filippo Bova (a), Vincenzo D'Ambrosio (a), Filippo Fabio Valenti (a), Concetta Filardo (a), Carmen Anna Maria Spaccarotella (b), Antonio Pilò (a), Adriano Signorelli (a), Concetta Procopio (a), Annalisa Mongiardo (a), Ciro Indolfi (a)
(a) DIVISION OF CARDIOLOGY, UNIVERSITÀ MAGNA GRAECIA, CATANZARO, ITALY; (b) DIVISION OF CARDIOLOGY, DEPARTMENT OF ADVANCED BIOMEDICAL SCIENCES, UNIVERSITÀ FEDERICO II, NAPLES, ITALY

Background. Conduction disturbances requiring permanent pacemaker (PPM) implantation are among the most common adverse events in patients undergoing transcatheter aortic valve replacement (TAVR). However, the impact of different periprocedural risk factors is still up for debate. In this analysis, we aimed to investigate the incidence and determinants of permanent pacemaker implantations after TAVR.
Methods. Patients who underwent TAVR at our Institution from September 2008 to December 2022 were included in this analysis. Patients with previous PPM/ICD implantation or receiving only balloon angioplasty were excluded, as well as unsuccessful procedures. The subjects were divided in two groups according to the necessity of PPM implantation after the procedure. The independent association between baseline clinical and procedural variables and the occurrence of PPM implantation was investigated with cross-sectional logistic regression analysis.
Results. A total of 570 patients were included in the analysis, with a mean age of 80.1±5.8 years old; 59.1% were women, 91.9% of patients had hypertension, 37% had diabetes, 62.6% had dyslipidemia, and 25.2% had chronic kidney disease. A self-expandable device was used in 425 (74.6%) patients, and a new generation device implanted in the 83% of the patients. After TAVR, 118 patients (20.7%) required in-hospital permanent PM implantation. After adjustment, the logistic regression analysis showed that diabetes, QRS duration and self-expandable valves were significantly associated with PPM implantation after TAVR, while the risk of PPM implantation was lower among patients treated with new generation devices.
Conclusions. The necessity for a permanent pacemaker is a well-known possible adverse effect after TAVR. In our analysis, diabetes, QRS duration and self-expandable valves were strong predictors of PPM implantation after TAVR, while the risk of PPM implantation was lower among patients treated with new generation devices. For instance, determining whether the reduction in pacemaker implantation was due to the introduction of new devices or the simultaneous development of new implantation techniques requires further and ad-hoc studies.

A337: LONG-TERM OUTCOME OF PERCUTANEOUSLY MANAGED CORONARY PSEUDOANEURYSM CAUSED BY STENT FRACTURE

Emiliano Bianchini (a), Francesco Bianchini (a), Francesco Burzotta (a), Carlo Trani (a)
(a) POLICLINICO UNIVERSITARIO AGOSTINO GEMELLI

Background. A 68-year-old man was referred to our attention in 2019 for chest pain at exertion. The patient had an ischemic cardiomyopathy with reduced left ventricular ejection fraction (left ventricular ejection fraction: 27%). He underwent multiple PCIs of left anterior descending and right coronary (RCA) arteries for recurrent acute coronary syndromes and a transvenous cardioverter defibrillator was implanted in primary prevention in 2018.
Case presentation. The patient underwent coronary computed tomography angiography which showed a mid-RCA pseudoaneurysm secondary to a fracture of a previously implanted coronary stent. He was advised to undergo coronary artery bypass graft surgery but opted for percutaneous revascularization. Coronary angiography confirmed the RCA pseudoaneurysm with proximal in-stent restenosis. PCI of the RCA was performed. In order to better track and safely control the advancement of the guidewire tip through the diseased segment, a Finecross microcatheter was employed. The lesion was successfully crossed with a workhorse guidewire (BMW universal). A guiding catheter extension was delivered in order to track the angioplasty balloons. Multiple balloon inflations were performed with semi-compliant and non-compliant balloons, then a covered stent (Bregraft 3.5 x 24 mm) was successfully advanced and implanted. A drug-eluting stent (Xience 4 x 23 mm) was then implanted at the proximal RCA segment in overlap with the covered one and multiple post-dilatations with high-pressure balloon inflations achieved good stent expansion and total exclusion of the pseudoaneurysm. After two years, the patient came back to our attention due to mild shortness of breath (NYHA class II) associated with atypical chest pain and underwent a CCTA and a coronary angiography control which documented the patency of the implanted stent with a complete exclusion of the thrombosed pseudoaneurysm and no residual leak. 4 years later, the patient underwent another coronary angiography for atypical chest pain episodes and it documented a long-lasting RCA patency.
Conclusions. Coronary pseudoaneurysm is a rare complication after stent implantation. This case illustrates how such complications can be safely managed with optimal long-term outcomes with a percutaneous approach, after having considered technical aspects and patient's preference.

A338: TRANSCAVAL ACCESS FOR TRANSCATHETER AORTIC VALVE REPLACEMENT

Gianmaria Calamita (a), Angelo Oliva (a), Damiano Regazzoli Lancini (a), Federico De Marco (b), Giuseppe Ferrante (a), Giulio Giuseppe Stefanini (a), Gianluigi Condorelli (a), Antonio Colombo (a), Bernhard Reimers (a), Antonio Mangieri (a)
(a) CARDIO CENTER, IRCCS HUMANITAS RESEARCH HOSPITAL, 200087 ROZZANO-MILAN, ITALY; (b) CENTRO CARDIOLOGICO MONZINO, IRCCS, MILAN, ITALY

Introduction. Transfemoral vascular access is considered the routine vascular access for most patients undergoing transcatheter aortic valve replacement (TAVR). Transaxillary, subclavian and transcarotid are alternative approaches for patients deemed unsuitable for femoral artery access; however, these vascular routes often require the surgeons support and are associated with higher rate of complications. Recently, access has been proposed as an alternative to enable fully percutaneous TAVR in patients who are not suitable for transfemoral access. The aim of transcaval access

is to create pinhole in inferior vena cava (IVC) and aortic wall to be progressively enlarged until the TAVR introducer sheath from femoral vein can be advanced across the retroperitoneal space into the aorta.
Case presentation. An 86-year-old woman was referred to our institution for acute heart failure due to aortic stenosis. She had history of coronary and peripheral artery disease, chronic lung disease and a previous pacemaker implantation for high-grade atrio-ventricular block. Echocardiography showed severe aortic stenosis (Gmed=46 mmHg, Gmax=70 mmHg, V max=4,2 m/s, A=0,8 cm2). Patient was deemed at prohibitive surgical risk for her history of severe pneumopathy. Angio-CT excluded the feasibility of transfemoral access, neither transaxillary nor subclavian routes due to high risk of peripheral ischemia. Thus, TAVR via transcaval vascular access was planned. The procedure was performed under general anesthesia. After ultrasound-guided puncture of right femoral vein, a coaxial system composed of a 0.014-inch microcatheter Finecross (Terumo), a 0.035-inch microcatheter NaviCross (Terumo), a 7Fr internal mammary catheter and the steerable introducer Agilis M (Abbott Vascular) was advanced into IVC. An electrified Astato XS 20 wire (Asahi Intecc Medical) was used for puncture and crossing from the IVC into the abdominal aorta. A single-loop snare (Amplatz Goose Neck), loaded into a 7Fr guiding catheter (JR4) and previously positioned in the aorta, was used to snare the guidewire and to advance it to thoracic aorta. After transfemoral crossing of the coaxial system, a 0.035-inch Extra-Stiff Lunderquist was exchanged and a 18Fr DrySeal introducer sheath was advanced smoothly from right femoral vein to IVC and then into the aorta. After a predilatation, an Evolut PRO+ 23mm valve was deployed achieving a good periprocedural success (mean gradient 4 mmHg). Iatrogenic aortic hole was closed with the Amplatzer Duct Occluder 10/8, and hemostasis was optimized with an aortic low-pressure inflation of a 14mm balloon. The final abdominal aortography showed the presence of a benign aorto-caval fistula, that harmlessly decompressed extravasation into the nearby caval venous hole. The patient was extubated at the end of the procedure, without any adverse event. The hospitalization was uneventful, and the patient was subsequently discharged.
Discussion. Transcaval aortic access is a relative safety derives from the presence of a hydrostatic pressure gradient in the retroperitoneal space between aorta, interstitial space, and IVC. For this reason, after puncture and transcaval crossing, any possible arterial bleeding might decompress into the nearby caval venous hole. To date, transcaval access has been performed in thousands of patients for transcatheter aortic valve replacement and represents a safe and effective alternative for percutaneous TAVR when femoral route is not suitable.

A339: WHO WATCHES THE WATCHMAN? A CASE OF RECURRENT STROKES AFTER TRASNCATHETER LEFT ATRIAL APPENDAGE CLOSURE

Nello Cambise (b), Fabiana Cozza (a), Matteo Pernigo (a), Giovanni Troise (a), Domenico Pecora (a), Marco Luciano Luigi Berti (a), Antonio Maggi (a)
(a) FONDAZIONE POLIAMBULANZA ISTITUTO OSPEDALIERO; (b) UNIVERSITÀ CATTOLICA DEL SACRO CUORE

A 76 years-old male patient was admitted to our hospital with a diagnosis of spontaneous intracranial hemorrhage without a reversible cause. During hospitalization, he had episodes of paroxysmal atrial fibrillation. MRI showed cortical and cerebellar microbleeds suggesting the diagnosis of cerebral amyloid angiopathy. The patient underwent left atrial appendage closure with Watchman FLX 27 mm and transcatheter ablation of atrial fibrillation (AF). Seven months later he presented to the emergency department with an ischemic stroke of embolic origin. TEE revealed Watchman FLX displacement in absence of thrombosis. After three months, the patient had another ischemic stroke and TEE showed thrombotic formation in the inner surface of the occluder. A trial of intravenous unfractionated heparin with a target aPTT at the lower limits of the therapeutic range was initiated. After a week, TEE showed dramatic reduction of the thrombotic burden with no longer mobile component. Given the long time since implantation, the possibility of percutaneous device removal was ruled out and cardiac surgery was proposed with the aim of manually removing the device or covering it with a pericardial patch in case of appendage perforation. The device was successfully removed and the left atrial appendage was surgically closed. During the same procedure pulmonary vein isolation was performed with the Atricure system.

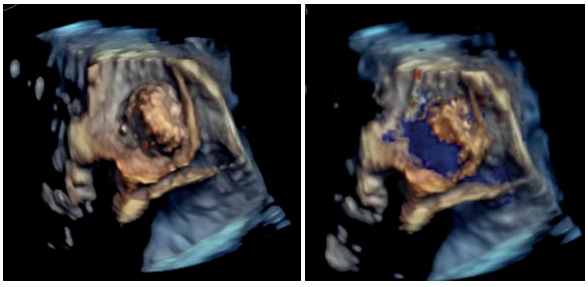

A340: TWO IS BETTER THAN ONE: SAFETY AND FEASIBILITY OF BAIL OUT DEPLOYMENT OF A BALLOON EXPANDABLE VALVE AFTER POP-UP OF A SELF EXPANDABLE AORTIC VALVE

Clelia Cappelli (a), Chiara Benedetti (a), Sabina Gallina (a), Livio Giuliani (a), Fabrizio Ricci (a), Giulia Renda (a)
(a) DIPARTIMENTO DI NEUROSCIENZE, IMAGING E SCIENZE CLINICHE

An 85-years old woman with a history of arterial hypertension and previous breast cancer treated by surgery and radiotherapy presented to the cardiology department complaining of dyspnea on mild exertion (NYHA III). Transthoracic echocardiogram showed a NF-HG severe aortic stenosis (peak gradient 65 mmHg, maximum velocity 4,2 m/s, mean gradient 40 mmHg, indexed aortic valve area 0,5 cm2/m2), preserved ejection fraction (60%). Coronary angiography revealed not obstructive coronary artery disease. After Heart Team discussion TAVR was performed. The patient underwent TAVR under total anesthesia via transaxillary approach for severe peripheral artery disease. A self expandable CoreValve Pro + 26 mm was positioned under fluoroscopy and the deployment started into appropriate implanting position (3-5 mm under aortic annulus) and the valve was correctly implanted. During the removal of delivery system the valve got displaced above the aortic valve plane into ascending aorta. We unsuccesfully tried valve repositioning by snare traction via transfemoral approach. The decision to deploy a second CoreValve was quickly made but it was not possible to cross the implanted valve with the delivery system. So we decided to deploy an Edwards Sapien 3 Ultra 23 mm which has a smaller delivery system which allowed us to cross the displaced valve. At the end of the procedure both valves were stable and the second valve was functional, with no sign of coronary obstruction or paravalvular leaks. The hospital stay was regular and after a few days the patient was discharged.

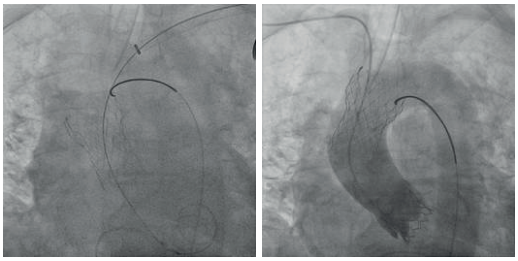

A341: FEASIBILITY OF IMPLANTATION OF SELF-EXPANDABLE AORTIC VALVE DURING CARDIAC ARREST

Clelia Cappelli (a), Chiara Benedetti (a), Livio Giuliani (a), Sabina Gallina (a), Fabrizio Ricci (a), Giulia Renda (a)
(a) DIPARTIMENTO DI NEUROSCIENZE, IMAGING E SCIENZE CLINICHE

An 86-years old woman with a history of arterial hypertension, dyslipidemia, chronic kidney disease, bilateral moderate carotid stenosis and anemia underwent cardiology consultation for an acute pulmonary edema. Transthoracic echocardiography revealed a normal flow-high gradient severe aortic stenosis (GM 45 mmHg; AVAi 0,6 cm2/m2). Coronary angiography demonstrated single vessel disease involving circumflex artery. The patient was referred to our center to perform TAVR and concomitant coronary angioplasty, according to our clinical practice. TAVR via right femoral approach using a 29 mm self-expandable (SE) valve aortic bioprosthesis was planned. Preoperatory computed tomography showed severe valve calcification. After aortic valve crossing with pigtail, there was a sudden decrease of arterial pressure and the patient rapidly deteriorated to cardiac arrest. Acute left main bifurcation occlusion due to embolization was promptly recognized. Primary angioplasty was successfully performed with an elective two stent technique (TAP) and the SE valve deployed. Meanwhile, Advanced life support was continously administered until return of spontaneous circulation (ROSC) occurred after valve release. Aortography showed underfilled valve and severe paravalvular leak, so we perfomed ad hoc final post dilatation with balloon 23x40 mm. Final aortography showed coronary ostia patency and mild paravalvulvar leak. At the end of procedure a IABP was placed and the patient was admitted to ICU. TAVR is usually performed in elective setting; this case proves that is possibile to perform in emergency setting in critical ill patients.

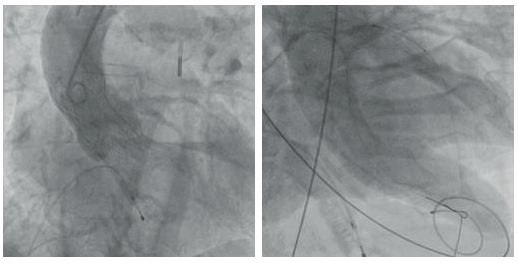

A342: ANGIOPLASTICA PRIMARIA IN ETÀ AVANZATA

Fulvio Furbatto (a), Gerardo Carpinella (a), Davide D´andrea (a), Federica Serino (a), Fulvio La Rocca (a), Aniello Di Donato (a), Vittorio Taglialatela (a), Salvatore Rumolo (a), Fabio Marsico (a), Ciro Mauro (a)
(a) AORN A.CARDARELLI CARDIOLOGIA ED EMODINAMICA

Uomo di anni 90 con storia di ipertensione arteriosa, dislipidemia, k colon trattato chirurgicamente e in attuale chemioterapia. Giunge in PS tramite 118 Rete IMA con diagnosi di IMA anteriore e toracoalgia iniziata circa 2 ore prima. All'arrivo in PS il paziente si presenta ancora sintomatico con all'ecg ritmo sinusale con FC 70 bpm, BBD con segni di infarto anteriore acuto. All'osservazione ecocardiografica si evidenza ventricolo sinistro di normali dimensioni cavitarie ed ipertrofico con moderata riduzione della cinesi globale (FE 40%), acinesia apice in toto, assenza di versamento pericardico. Visto il quadro di infarto miocardico anteriore acuto di presentazione viene proposto al paziente esame coronarografico in emergenza. In ambulanza era già stato praticato flectadol ev. All'angiografia coronarografica evidenza di stenosi subocclusiva al tratto medio distale di IVA e stenosi significativa distale di esile ramo IVP di coronaria destra per cui si decide per PTCA in emergenza di IVA medio distale. Si effettua predilatazione con pallone 2.0 mm e si impianta un primo DES 2.5 x 26 mm a 12 atm e per evidenza di ulteriore stenosi critica più a valle si impianta ulteriore DES 2,25 x 22 mm a 12 mm. Al controllo angiografico subito dopo impianto del secondo stent evidenza di immagine da rottura perivasale con stravaso di mdc. Viene immediatamente gonfiato pallone a monte del tratto interessato, allertato ecocardiografista e preparato kit per eventuale pericardiocentesi. Viene prontamente preparato stent ricoperto 2.5 x 20 mm rapidamente posizionato a livello del tratto coinvolto dallo stravaso dopo aver rimosso il pallone gonfio. All'angiografia si assiste a totale risoluzione dello stravaso ed al controllo ecocardiografico si evidenza lieve falda di versamento pericardico in assenza di segni di tamponamento e con ottimo compenso emodinamico con P.A. 150/85 mmHg, FC 80 bpm e SO2 97%. Si effettua monitoraggio in sala dei parametri emodinamici e vitali e ripetizione di ecocardiogramma a 15 minuti senza evidenza di complicanze. Si ottimizza pertanto la PTCA postdilatando con pallone 2.5 NC ottenendo un ottimo risultatofinale. Viene quindi effettuato carico di Clopidogrel 600 mg ed il paziente viene trasferito in UTIC per il prosieguo della degenza. Gli ecocardiogrammi seriati nei giorni successivi evidenziavano minimo scollamento pericardico non emodinamicamente significativo. La degenza non ha evidenziato criticità con decorso regolare in assenza di complicanze con paziente stabile ed asintomatico tale da consentire dimissione in quarta giornata in terapia con pantoprazolo 40 mg; ramipril 5 mg; bisoprololo 1.25 mg; ASA 100; Clopidogrel 75 mg; Ezetimibe 10 mg; Atorvastatina 80 mg. All'ecocardiogramma in predimissione FE circa 45% ed ipocinesia apice e setto medio con minimo scollamento pericardico non significativo. Al follow up a 3 settimane il paziente riferisce con buon compenso clinico ed emodinamico in assenza di sintomi e con ecocardiogramma sostanzialmente sovrapponibile al quadro riscontrato in dimissione. Il caso clinico in questione evidenza come le complicanze intra procedurali possano presentarsi in qualsiasi contesto procedurale anche in assenza di apparenti criticità angiografiche in particolar modo in alcuni subset di pazienti come in questo caso di paziente acuto e grande anziano la cui gestione tempestiva e coordinata da parte di tutta l'equipe ne ha consentito la pronta e completa risoluzione.

A343: ANGIOPLASTICA COMPLESSA IN NSTEMI AD ELEVATO RISCHIO EMORRAGICO

Gerardo Carpinella (a), Fulvio Furbatto (a), Davide D´andrea (a), Federica Serino (a), Fulvio La Rocca (a), Vittorio Taglialatela (a), Alessandro Bellis (a), Aniello Di Donato (a), Ciro Mauro (a)
(a) AORN A.CARDARELLI CARDIOLOGIA UTIC ED EMODINAMICA

I pazienti ad elevato rischio emorragico rappresentano un sottogruppo sempre più crescente di pazienti da sottoporre ad angioplastica percutanea. Le comorbidità, l'età, le alterazioni ematologiche, la storia di interventi chirurgici o di sanguinamento hanno un impatto sfavorevole sulla prognosi di questi pazienti. Il caso che presentiamo riguarda un maschio di 68 anni, giunto in ospedale con sincope su base cardiogena associata ad importante anemizzazione necessitante emotrasfusioni (Hb ingresso 7.5). Viene posta diagnosi di NSTEMI, con importante elevazione della troponina I (10 ng/ml) ed ipocinesia dei territori inferoposterolaterali. Il paziente è affetto da ipertensione arteriosa, e presenta una recente diagnosi di rettocolite ulcerosa, che ha dato manifestazione di sè in corso di terapia con NAO per trattamento di tromboembolia polmonare associata a pregressa infezione SARS COV2. Una volta ottenuta la stabilizzazione del quadro ematologico, dopo circa 2 settimane, in assenza di sanguinamenti evidenti e con la negatività degli esami endoscopici del tratto gastrointestinale, viene eseguito esame coronarografico che mostra una severa coronaropatia calcifica della coronaria destra, determinante stenosi critica con una estensione di calcio circonferenziale. Discusso col paziente della necessità di trattamento interventistico, dopo introduzione di doppia antiaggregazione con acido acetilasalicilico e clopidogrel e tenendo comunque presente il rischio emorragico elevato, si programma procedura di debulking con catetere per litrotrissia intracoronarica Shockwave (3.5 x 12 mm, 4 cicli), impiantando 2 stent medicati in overlap Resolute Onyx 4.5 x 26 mm, con corsa IVUS pre e post impianto. L'elevatissimo rischio emorragico del paziente ha obbligato ad una vigilanza attiva sulla problematica intestinale ed ad una attenta programmazione e strategia interventistica. L'esecuzione della angioplastica con l'ausilio dell'imaging intracoronarico ed il debulking con litrotrissia intracoronarica ha consentito di impiantare gli stents in maniera corretta, anche nell'ottica di ridurre al minimo le probabilità di restenosi e trombosi di stent, in particolar modo in un paziente così delicato, che necessita di una antiggregazione quanto più breve possibile. La disponibilità di devices dedicati per il trattamento delle lesioni calcifiche è fondamentale per poter approcciare le procedure ormai sempre più complesse cui dobbiamo far fronte nei laboratori di emodinamica. Il successo procedurale è strettamente connesso alla scelta del device giusto per il singolo paziente. La scelta di stents adatti in contesti di alto rischio emorragico e di device appropriati per il debulking consentono un trattamento interventistico ottimale in condizioni cliniche ed anatomiche complesse.

A344: TRATTAMENTO LASER INTRACORONARICO IN PAZIENTE CON NSTEMI

Gerardo Carpinella (a), Davide D'Andrea (a), Fulvio Furbatto (a), Federica Serino (a), Fulvio La Rocca (a), Rossella Gottilla (a), Alfredo Madrid (a), Vittorio Taglialatela (a), Aniello Di Donato (a), Ciro Mauro (a)
(a) AORN A.CARDARELLI CARDIOLOGIA UTIC ED EMODINAMICA

Le procedure complesse diventano sempre più frequenti, date l'estensione della malattia aterosclerotica con componente calcifica e la diffusione del trattamento interventistico. Un maschio di 55 anni affetto da ipertensione arteriosa, diabete mellito tipo 2 in terapia orale, cardiopatia ischemica cronica (pregresse angioplastiche su coronaria destra e discendente anteriore nel 2004 e 2005), dislipidemia, accede al nostro pronto soccorso con dolore toracico tipico e diagnosi di NSTEMI, con evidenza di acinesia e fibrosi della parete inferoposterolaterale ed innalzamento della troponina alla seconda rilevazione (1.48 ng/ml). Nella procedura index, si rilevano occlusione totale cronica intrastent della coronaria destra, malattia critica lunga del ramo circonflesso, trattata con angioplastica ed impianto di 2 stent medicati in overlap, e malattia critica calcifica dell'arteria discendente anteriore a monte degli stents preesistenti, con restenosi critica. Si programma procedura per arteria discendente anteriore con debulking, dal momento che è risultato impossibile il crossing della lesione con il catetere IVUS. Si opta per l'utilizzo del catetere laser intracoronarico, ottenendo un perfetto debulking ed il corretto posizionamento di uno stent medicato in overlap con quello preesistente, valutato anche mediato corsa IVUS post-impianto. Il trattamento unico per questo paziente a nostro avviso può essere solo di tipo interventistico, dal momento che la riabitazione per la coronaria destra è pressochè assente, e la distalità dell'arteria discendente anteriore non consentirebbe il confezionamento dell'anastomosi con un graft arterioso, così come indicato anche dal consulente cardiochirurgo. La scelta del debulking con il laser intracoronarico risulta mandatoria in caso di lesioni incrossabili, e nel caso specifico, il rischio per utilizzo di altre tecniche di debulking, come l'aterectomia rotazionale, sarebbe gravata da una elevata probabilità di complicanze, per la preesistenza di uno stent al tratto medio del vaso. La disponibilità di devices dedicati per il trattamento delle lesioni calcifiche è fondamentale per poter approcciare le procedure ormai sempre più complesse cui dobbiamo far fronte nei laboratori di emodinamica. Il successo procedurale è strettamente connesso alla scelta del device giusto per il singolo paziente. Nel nostro caso clinico, la preesistenza dello stent e l'incrossabilità della lesione hanno indirizzato verso l'utilizzo del laser intracoronarico, che si è dimostrato sicuro, e ci ha consentito di ottenere un ottimo risultato angiografico, come dimostrato anche dall'imaging intracoronarico.

A345: FAST-TRACK IN ACS:12 MESI DI FOLLOW-UP

Davide D'Andrea (a), Gerardo Carpinella (a), Fulvio Furbatto (a), Aniello Di Donato (a), Fulvio La Rocca (a), Vittorio Taglialatela (a), Valentina Capone (a), Fabio Marsico (a), Salvatore Rumolo (a), Ciro Mauro (a)
(a) UOSC CARDIOLOGIA CON UTIC, AORN A. CARDARELLI, NAPOLI

The 2021 ESC guidelines for cardiovascular disease prevention in clinical practice recommend an LDL cholesterol treatment goal of a 50% reduction or <50 mg/dL for patients with ACS (and <40 mg/dL in those with recurrent events). The addition of more potent LDL-lowering therapy with proprotein convertase subtilisin/kexin type 9 (PCSK9) inhibitors has shown a clinical benefit in patients with prior ACS or atherosclerotic cardiovascular disease who have persistently high LDL cholesterol despite the use of statins. In these landmark trials, a PCSK9 inhibitor was initiated after several months to years from the ACS event presentation and only in those patients with persistently elevated LDL despite high-dose statin therapy. The ODYSSEY OUTCOMES trial found a significant reduction in death from coronary heart disease, myocardial infarction, ischemic stroke, and unstable angina requiring hospitalization in patients who had an acute coronary syndrome (ACS) 1-12 months prior and were treated with (PCSK9) inhibitor alirocumab versus placebo. In the EVOPACS trial, evolocumab reduced LDL cholesterol by 40.7% in ACS pa-

tients with elevated LDL cholesterol. In the EVACS trial, a single dose of evolocumab was given to non-ST-segment elevation acute coronary syndrome patients, and LDL cholesterol was lower in this group at 1 month. Intracoronary imaging trials of patients with ACS have demonstrated evidence of plaque stabilization and regression with both evolocumab and alirocumab when started early after ACS. In the PACMAN-AMI trial, alirocumab resulted in greater coronary plaque regression and stabilization compared with placebo on a background of rosuvastatin 20 mg daily in non-infarct-related arteries at 52 weeks (REF). EPIC STEMI adds to the results of these trials, as it evaluates the initiation of PCSK9 inhibitors routinely in STEMI patients before primary PCI, irrespective of baseline LDL cholesterol levels or prior statin use. To determine if strategy of PCSK9 administration as soon as possible (fast-track) followed by long-term therapy is translated into a reduction in major cardiovascular events we have considered many indicators, both clinical and procedural as age, familiarity, previous IMA, previous PCI, previous CABG, clinical presentation, BMI, smoke, hypertension, dyslipidemia, IDDM, EF, PCI-related culprit vessel, stent length and diameter. We analyzed results in 75 consecutive patients where PCSK9i were given less than 24 hrs from cardiac event on top of LLT with high intensity statins plus ezetimibe; patients were treated when basal LDL>140 mg/dl or multiple events regardless of LDL levels or in lipid lowering therapy (LLT) not at target. Follow-up and data have been collected at 30 and 180 days. Results showed that in a population of 80% males, 57.4 yo (range 27-79), with BMI 27.9 (range 22.16-42.45) over 90% of patients were adherent to therapy; more than 90% had LDL levels at target, going down from 138.4 mg/dl pre- to 30.3 mg/dl at 30 days post-cardiac event, with 60% of patients discharged with EF improved (median from 43.9% pre- to 47,6% post PCI). Most remarkable finding was only one re-hospitalization for unstable angina in a in stent restenosis of an ostial circumflex in a double stent-treated distal left main PCI of 5 months before. Sooner (in-hospital) and faster (less than 24 hrs form cardiac event) PCSK9i use resulted in a totally safe and effective (>90% LDL targets level reached) immediate reduction of more than 75% of LDL levels, with only one symptoms driven re-hospitalization in a 6 months follow-up with very high adherence.

A346: PROGNOSTIC ROLE OF POLYMER-FREE DES IN PATIENTS WITH INSULIN-DEPENDENT DIABETES MELLITUS UNDERGOING PCI

Mattia De Gregorio (a), Marco Covani (a), Filippo Luca Gurgoglione (a, b), Emilia Solinas (b), Giorgio Benatti (b), Luigi Vignali (b), Iacopo Tadonio (b), Andrea Denegri (b), Diego Ardissino (a, b), Giampaolo Niccoli (a, b)
(a) UNIVERSITÀ DEGLI STUDI DI PARMA; (b) AZIENDA OSPEDALIERO-UNIVERSITARIA DI PARMA

Introduzione. I pazienti affetti da diabete mellito (DM), in particolare insulino-dipendente, e malattia aterosclerotica coronarica (CAD), presentano una maggior necessità di rivascolarizzazione coronarica percutanea (PCI) e una maggior incidenza a distanza di failure di PCI. Recentemente, gli stent medicati senza polimero (PF-DES) hanno dimostrato fornire vantaggi in termini meccanicistici comparati ai DES con polimero permanente (PP-DES) o biodegradabile (BP-DES). Tuttavia, studi di outcome hanno fornito risultati contrastanti nei pazienti privi di DM e nella popolazione con DM. Obiettivo del presente studio è comparare l'efficacia dei PF-DES vs PP/BP-DES, in una coorte di pazienti affetti da DM insulino-dipendente, ovvero la coorte di pazienti a maggior rischio di failure di PCI.
Metodi. Abbiamo condotto uno studio osservazionale monocentrico retrospettivo-prospettico, includendo tutti i pazienti consecutivi affetti da DM insulino-dipendente e concomitante CAD e sottoposti a PCI con impianto di DES presso il Laboratorio di Emodinamica dell'Azienda Ospedaliero-Universitaria di Parma da gennaio 2018 a marzo 2023. La popolazione in studio è stata suddivisa in due gruppi a seconda del tipo di DES adoperato: PF-DES vs PP/BP-DES. Di tutti i pazienti sono stati raccolti i dati clinico-laboratoristici, angiografici e l'anamnesi farmacologica al momento dell'ospedalizzazione ed è stato effettuato un follow-up tramite colloquio telefonico e/o controllo clinico. L'endpoint primario è stato l'incidenza di target vessel failure (TVF), endpoint composito che comprendeva le morti per cause cardiovascolari (CV), l'occorrenza di infarto miocardico (IMA) non fatale e le rivascolarizzazioni nel vaso target (TVR).
Risultati. Abbiamo incluso un totale di 132 pazienti, di cui 44 (33.3%) pazienti sono stati inclusi nel gruppo PF-DES, 88 (66.7%) nel gruppo PP/BP-DES. Al follow-up mediano di 34 mesi, il TVF è stato riscontrato in 24 [18.2%] pazienti. Nel dettaglio, si sono verificate 8 [6,1%] morti per cause CV, 14 [10.6%] IMA non fatali e 16 [12.1%] TVR. Non sono state riscontrate differenze riguardo l'endpoint primario di TVF nei due gruppi in studio (11.4% nel gruppo PF-DES vs 21.6% nel gruppo PP/BP-DES; p=0.151), mentre il gruppo PF-DES si associava ad un minor incidenza di TVR (4.5% nel gruppo PF-DES vs 15.9% nel gruppo PP/BP-DES; p=0.047) (figura 1). Infine, la comparazione delle curve di Kaplan-Meier mediante log-rank test ha mostrato che il gruppo PF-DES presentava un trend verso una maggior libertà da TVF (p=0.055) rispetto al gruppo PP/BP-DES e una maggior libertà da TVR (p=0.025) rispetto al gruppo PP/BP-DES.
Conclusioni. Il nostro studio ha dimostrato che, all'interno di una coorte di pazienti affetti da DM insulino-dipendente e concomitante CAD sottoposti a PCI, la strategia PF-DES, comparata con i PP/BP-DES, si associa ad una riduzione della TVR al follow-up e ad un trend verso una riduzione del TVF.

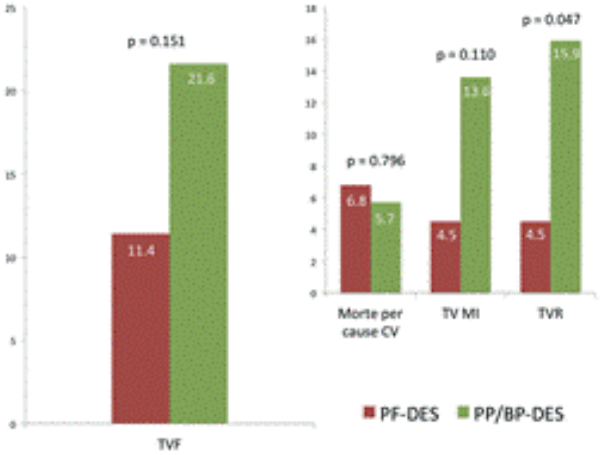

Figura 1. Dati di outcomes al follow-up nei due gruppi di studio.

A347: INCIDENCE AND DETERMINANTS OF ACCESS-SITE COMPLICATIONS IN PATIENTS UNDERGOING TRANSCATHETER AORTIC VALVE REPLACEMENT

Assunta Di Costanzo (b), Sabato Sorrentino (b), Alessandra Panarello (b), Antonio Bellantoni (b), Federica Bruno (b), Vincenzo D'Ambrosio (b), Filippo Bova (b), Filippo Fabio Valenti (b), Concetta Filardo (b), Antonio Pilò (b), Adriano Signorelli (b), Concetta Procopio (b), Carmen Anna Maria Spaccarotella (a), Alessandro Caracciolo (b), Annalisa Mongiardo (b), Ciro Indolfi (b)
(a) DIVISION OF CARDIOLOGY, DEPARTMENT OF ADVANCED BIOMEDICAL SCIENCES, UNIVERSITY OF NAPLES FEDERICO II, ITALY; (b) DIVISION OF CARDIOLOGY, UNIVERSITY MAGNA GRAECIA, CATANZARO, ITALY

Background. Access site complications remain a significant source of morbidity and mortality in patients undergoing transcatheter aortic valve replacement (TAVR), despite substantial improvements in device technology and implantation techniques.
Objectives. This study aimed to assess the incidence and determinants of femoral access-site complications in patients undergoing TAVR.
Methods. This is an observational single-site registry, including patients with severe aortic stenosis undergoing TAVR from September 2009 to December 2022. Major and minor vascular complications related to TAVR were defined according to the Valve Academic Research Consortium definitions (VARC-3). The independent association between baseline clinical and procedural variables and the occurrence of vascular complications was investigated with logistic regression analysis.
Results. A total of 611 patients undergoing TAVR were included in the final analysis. The overall mean age was 80.2±5.7 years old, with 58.1% females, 35.7% patients with diabetes, 62.7% with dyslipidemia, 13.4% with peripheral arterial disease (PAD), 26.2% with chronic kidney disease, mean left ventricular ejection fraction of 52.8%, and Euro score II of 5.4±5.1. Vascular complications occurred in 95 (15.9%) patients, of which 9.4% were classified as major. After adjusting for clinical and procedural characteristics, women and patients with PAD were at a substantially higher risk of experiencing vascular complications overall. Conversely, the utilization of ultrasound-guided cannulation (UGC) for the femoral artery significantly reduced the incidence of these complications.
Conclusions. Despite the introduction of increasingly safe devices and significant improvements in implantation techniques in clinical practice, site access complications still represent one of the most common adverse events in patients undergoing TAVR. Interestingly, female sex and PAD are associated with a higher rate of vascular complications, while the use of UGC significantly decreases this risk. Larger and ad-hoc studies are warranted to better define indicators and strategies to optimize site access management and related complications.

A348: FIRST CASE OF PERCUTANEOUS ATRIAL APPENDAGE CLOSURE IN A PATIENT WITH ACQUIRED VON WILLEBRAND SYNDROME AND ATRIAL FIBRILLATION

Alessandro Giaj Levra (a)
(a) HUMANITAS UNIVERSITY

Introduction. Atrial fibrillation (AF) increases thromboembolic risk, requiring continuous anticoagulation. Percutaneous left atrial appendage closure (LAAC) is an option for high bleeding risk patients. Acquired von Willebrand syndrome (AvWS) secondary to monoclonal gammopathy of undetermined significance (MGUS) is a rare disease that carries an elevated bleeding risk because of increased clearance of von Willebrand factor (vWF) and monoclonal antibodies complexes. This is the first reported AF patient with AvWS from MGUS treated with LAAC.

Case description. A 74-year-old male presented with palpitations. The ECG revealed atrial fibrillation. His CHADS-VASC score of 4 prompted anticoagulation therapy. Prior history included Von Willebrand disease (vWD) and recurrent gastrointestinal bleeds, despite factor VIII (FVIII)/vWF treatment. Persistent low levels in FVIII and vWF activity during the hospitalization raised suspicion for AvWS. MGUS was discovered with protein electrophoresis. AvWS secondary to MGUS was diagnosed by measuring a rapid decline of FVIII/vWF shortly after supplementation. Intravenous immunoglobulin (IVIG) therapy was started and good coagulation parameters were achieved. Due to the increased bleeding risk carried by AvWS secondary to MGUS, closure of the left atrial appendage (LAAC) preferred over oral anticoagulants (OAC) for stroke prevention. LAAC using a WATCHMAN FLXTM™ 24mm was performed successfully. The patient was discharged with daily low-dose aspirin for three months and bi-weekly IVIG. At 9-month follow-up, the patient reported no embolic or hemorrhagic events.
Discussion. In this case, a patient with AvWS developed AF, leading to a complex balance between hemorrhagic and thrombotic risks. Given the heightened bleeding risk, LAAC emerged as the preferred stroke prevention strategy. A WATCHMAN FLX™ 24mm was successfully implanted, and the patient was discharged with a three-month regimen of daily low dose aspirin. Optimal management of AF in AvWS patients remains underexplored. LAAC can be a promising therapeutic option in patients with underlying hemostatic disorders. It avoids the increased bleeding risk carried by both OACs and the hemostatic disease while preventing the embolic risk carried by AF. To our knowledge, this is the first case of LAAC in an AvWS secondary to MGUS IgG subtype and AF. LAAC has been extended to some hemostatic conditions like hemophilia, congenital vWD, and myelodysplastic syndromes. Studies detail LAAC successes in congenital vWD patients, utilizing desmopressin preoperatively and employing varying antiplatelet regimes post-procedure. Similar cases include LAAC in hemophilia A and B patients, with factor VIII and IX pre-operative administration respectively, and low-dose aspirin or clopidogrel post-procedure. These cases underscore LAAC's feasibility in populations with hemostatic disorders. Procedural success depended on preoperative management, device choice, and postoperative therapy. Reported complications mainly stem from GI bleeding secondary to transesophageal echocardiography.
Conclusions. Patients with AvWS and AF have a heightened bleeding and thromboembolic risk. LAAC offers a viable antithrombotic alternative for those unsuitable for lifelong anticoagulation.

A349: A GIANT CORONARY PSEUDOANEURYSM: A CLINICAL CASE

Cecilia Gobbi (a), Andrea Zuffi (b), Luca Mircoli (a), Lucia Barbieri (a), Gabriele Tumminello (a), Federico Colombo (a), Stefano Carugo (a)
(a) FONDAZIONE IRCCS CA GRANDA OSPEDALE MAGGIORE POLICLINICO DI MILANO; (b) HOPITAL PRIVE SAINT-MARTIN, CAEN (FR)

Introduction. A 68-year-old man was admitted to our cardiology division due to an incidental chest computed tomography (CT) finding of a giant saccular coronary pseudoaneurysm of the left anterior descending (LAD) (57 mm x 50 mm) with circumferential marginal thrombus, discovered while staging a gastric adenocarcinoma. His past medical history revealed a chronic ischemic heart disease treated with a previous percutaneous coronary intervention (PCI) with an Everolimus-Eluting stent (SYNERGY 3.0x23 mm) on the LAD. Coronary angiography was performed and confirmed a giant saccular pseudoaneurysm of middle segment of LAD as well as an in-stent total occlusion.
Technical resolution. After antegrade crossing of the in-stent occlusion with a dedicated guidewire, selective injection by a guide catheter extension was used to delineate the full extension of the coronary artery pseudoaneurysm and of the LAD distal lumen, assessing a possible landing zone for stent implantation. Due to the considerable length of the aneurysmal segment, a long drug eluting stent (DES) was needed to cover the full length of the aneurysm and to reduce the risk of stent migration (Everolimus-Eluting stent Synergy 3.0 x 38 mm). Subsequently, four covered stents (PK Papyrus) were implanted to exclude the coronary pseudoaneurysm completely.
Clinical Implications. The pathogenesis of coronary artery pseudoaneurysm is still not fully understood. In this case, two hypotheses have been proposed, considering the patient's medical history. The first was an iatrogenic origin, following the previous complex PCI with rotational atherectomy (that the patient underwent 2 years before) and/or the concurrent DES implantation (due to the impaired intimal healing effects of the antiproliferative agents). Second, a potential infectious origin due to a recent bacteremia for S. Aureus, that the patient suffered from 2 months before the index procedure, was postulated. Moreover, due to the lack of randomized trials regarding pseudoaneurysms management, the optimal approach is still controversial and include medical treatment, surgical excision, and percutaneous coronary interventions (PCI) with covered stent or coil embolization. The treatment modality must be individualized according to high-risk clinical or anatomic features.
Perspectives. Coronary artery pseudoaneurysms are rare and their management is still challenging. Future perspectives are needed to clarify the underlying pathophysiology of the disease. Randomized trials are necessary to better define the optimal treatment strategy.

A350: A CASE OF A SPONTANEOUS CORONARY ARTERY DISSECTION IN A YOUNG WOMAN IN TREATMENT WITH HORMONAL THERAPY

Jessica Ielapi (a), Vincenzo Riverso (a), Andrea Carbone (a), Angelo Leone (c), Daniela Chiappetta (c), Roberto Caporale (c), Francesco Greco* (c), Alberto Polimeni (b, c)
(a) DIVISION OF CARDIOLOGY, MAGNA GRAECIA UNIVERSITY, "R. DULBECCO" HOSPITAL, CATANZARO, ITALY; (b) DEPARTMENT OF PHARMACY, HEALTH AND NUTRITIONAL SCIENCES, UNIVERSITY OF CALABRIA, COSENZA, ITALY; (c) DIVISION OF CARDIOLOGY, ANNUNZIATA HOSPITAL, COSENZA, ITALY

Background. Spontaneous coronary artery dissection (SCAD) is a condition characterized by the non-traumatic and non-atherosclerotic separation of the inner layer of the coronary artery from the underlying vessel wall.
Case presentation. We present the case of a 43-year-old woman who was brought to the emergency department due to retrosternal chest pain that began a few hours after an argument with her husband. The patient reported elevated blood pressure along with her symptoms. Her medical history included a smoking habit and hypertension. She had also undergone hormonal therapy (chorionic gonadotropin and clomiphene citrate) for fertility purposes up to eight months prior to the current presentation. Additionally, she had recently undergone a uterine polypectomy and was receiving prednisone at a daily dose of 25 mg since the procedure. The patient was afebrile upon admission, with a blood pressure reading of 190/95 mmHg and a heart rate of 102 beats per minute. Initial blood tests revealed a highly elevated troponin I HS level of 64326.6 ng/l (normal range <14 ng/l). An electrocardiogram performed upon admission showed ST elevation in the antero-lateral leads, indicating a myocardial infarction with ST elevation (STEMI). Consequently, the patient was promptly taken for emergent coronary angiography. Aspirin, prasugrel with a loading dose, nitroglycerin, and heparin were promptly administered, and a coronary angiography was performed, revealing the presence of a type IIb SCAD in the mid anterior descending coronary artery, resulting in vessel occlusion (TIMI flow 0-1). The SCAD lesion was successfully treated with percutaneous coronary intervention using plain old balloon angioplasty in the affected segment, resulting in an excellent angiographic outcome (TIMI 3) and complete resolution of symptoms and ST-elevation. A follow-up coronary angiography performed after ten days confirmed the favorable angiographic outcome.
Discussion. It has been observed that nearly 80% of patients diagnosed with SCAD are middle-aged women. Risk factors for SCAD include fibromuscular dysplasia, pregnancy, postpartum state, multiple pregnancies, hormonal therapy (as in the case of our patient), connective tissue disorders, and systemic inflammatory diseases. SCAD can be triggered by intense physical exercise, the Valsalva maneuver, childbirth, recreational drug use leading to a hypersympathetic response, or extreme emotional stress (as experienced by our patient). The presence of estrogen and progesterone receptors in the coronary arteries may contribute to changes that weaken the vessel wall, leading to arterial rupture and the development of intramural hematoma (IMH). Currently, there are no consensus guidelines for the management of SCAD. In the acute phase, the primary objective of management is to restore or maintain myocardial perfusion. A conservative approach to the acute management of SCAD is preferred whenever feasible, as it has the potential to reduce arterial shear stress, promote healing, and decrease the risk of long-term recurrence. Revascularization procedures should be reserved for cases with clinical instability or high-risk anatomical features, such as proximal vessel dissection with a significant reduction in coronary perfusion.
Conclusions. The management of SCAD remains a subject of ongoing debate, and we present this case report to underscore the significance of individualized therapeutic approaches in this condition. Furthermore, it emphasizes the importance of evaluating risk factors, such as hormonal therapies, in order to prevent the recurrence of this phenomenon.

A351: POST PROCEDURAL FEVER AFTER TRANSCATHETER AORTIC VALVE IMPLANTATION: A RETROSPECTIVE, SINGLE CENTRE STUDY

Valentina Scheggi (a), Stefano Del Pace (a), Francesco Meucci (a), Silvia Menale (a), Carlo Fumagalli (b), Giulia Nardi (a), Francesca Di Muro (a), Elena Pisani (a), Valeria Setti (b), Veronica Speranza Vitiello (b), Renato Valenti (a), Alfredo Cerillo (a), Pierluigi Stefano (a, b), Carlo Di Mario (a, b), Niccolo´ Marchionni (b)
(a) CARDIOTHORACOVASCULAR DEPARTMENT, AZIENDA OSPEDALIERO UNIVERSITARIA CAREGGI AND UNIVERSITY OF FLORENCE, FLORENCE, ITALY;
(b) DEPARTMENT OF EXPERIMENTAL AND CLINICAL MEDICINE, UNIVERSITY OF FLORENCE,FLORENCE, ITALY

Background. The pathogenesis, prevalence and outcome of fever occurring during the first 72 after transcatheter aortic valve implantation (TAVI) are not well understood. In particular, it is not clear if it is the consequence of a systemic inflammatory response syndrome (SIRS) or an infectious phenomenon. We report our experience in a high-volume center.
Methods. We retrospectively enrolled 483 consecutive patients approved for TAVI by the Heart-Team of our hospital between December 2018 and July 2022. Data retrieved from electronic hospital charts included demographics, comorbidities assessed by Charlson's Comorbidity Index (CCI), NYHA functional class, Multidimensional Prognostic Index (MPI),

EUROSCORE II and STS mortality score, pre- and post-procedural echocardiographic data, and procedural details. Fever was defined as temperature>37.5°C.
Results. The prevalence of fever post TAVI was 28% and, in most cases, (76%) without documented infection. Most febrile episodes occurred early (within 48 hours) after the procedure and were short in duration (single measurement and lasting less than 1 day). The occurrence of fever was associated with interventricular septum thickness, pre-procedural anaemia, and the persistence more than 1 day of a central venous catheter or a delivery sheath. We observed a significant increase of CRP (C Reactive Protein) in patient with fever. We did not find differences in mortality and incidence of infective endocarditis in patients with or without fever.
Conclusions. Fever after TAVI is common and mostly sustained by a non-infectious inflammatory response. A watchful waiting strategy in an otherwise stable TAVI patient with a brief and isolated fever measurement could be reasonable.

A352: GENDER DISPARITIES IN PATIENTS UNDERGOING TRANSCATHETER AORTIC VALVE REPLACEMENT: INSIGHTS FROM REAL-WORLD PRACTICE

Alessandra Panarello (a), Sabato Sorrentino (a), Assunta Di Costanzo (a), Federica Bruno (a), Antonio Bellantoni (a), Vincenzo D'Ambrosio (a), Filippo Bova (a), Concetta Filardo (a), Filippo Fabio Valenti (a), Carmen Anna Maria Spaccarotella (b), Antonio Pilo (a), Adriano Signorelli (a), Concetta Procopio (a), Alessandro Caracciolo (a), Annalisa Mongiardo (a), Ciro Indolfi (a)
(a) DIVISION OF CARDIOLOGY, UNIVERSITY MAGNA GRAECIA CATANZARO, CATANZARO, ITALY; (b) DIVISION OF CARDIOLOGY, DEPARTMENT OF ADVANCED BIOMEDICAL SCIENCES, UNIVERSITY OF NAPLES FEDERICO II, NAPLES, ITALY

Background. Up to 50% of patients undergoing transcatheter aortic valve replacement (TAVR) are women. Despite remarkable advancements in TAVR procedures in recent years, gender-based disparities in outcomes persist. Our objective was to examine the evolving patterns of TAVR utilization in its early and contemporary phases and evaluate the outcomes of TAVR in female versus male patients.
Methods. This is an observational, single-site registry, including patients with severe aortic stenosis undergoing TAVR from September 2009 to December 2022. Baseline demographic, clinical, and echocardiographic variables were compared between these groups using an independent-sample Student's t-test for continuous variables (presented as mean±SD) and the chi-square test for categorical or binary variables (presented as the number and percentage). In-hospital outcomes included vascular complications, bleeding, stroke, pacemaker implantation, and mortality defined according to the Valve Academic Research Consortium 3 (VARC-3) criteria.
Results. Out of 620 patients, 359 were women (57.9%). No differences in age and common cardiovascular risk factors were observed, except for a higher prevalence of hypertension (88.5% vs. 94.2% – P=0.01), as well as a lower body surface area (1.85 vs. 1.73 m2 – P<0.01), previous percutaneous coronary interventions (27.6% vs. 15.0% – P<0.01), prevalence of chronic obstructive pulmonary disease (30.7% vs. 14.2% – P<0.01), and prevalence of smokers (31.0% and 5.9% – P<0.01) observed among women. The operative risk was similar between the groups, and no differences were observed among procedural variables, including valve-in-valve procedures, type of valve device implanted (self-expandable vs. balloon-expandable), secondary access preferred (femoral or radial), or closure device used (suture vs. plug-based devices). The length of the hospital stay was similar between the groups, even though women required a longer time in the intensive care unit (63.4±58.0 vs. 77.2±78.9 hours). In-hospital rates of stroke, pacemaker implantation, life-threatening or major bleeding, and mortality were comparable between men and women, while the latter had a higher rate of major vascular complications (6.2% vs. 12.0% – P=0.02) and minor bleeding (8.9% vs. 15.6% – P=0.01).
Conclusions. Female gender appears to be a risk factor for major vascular complications and minor bleeding after TAVR. However, this does not impact the length of hospital stay and in-hospital mortality rate. The fundamental anatomical differences between women and men, such as their smaller body surface area and narrower vessel diameters, could potentially account for the higher incidence of vascular access complications observed in these groups. Nevertheless, prespecified and larger studies are necessary to validate these observations.

A353: ELECTRO-MECHANICAL CHANGES OF ATRIAL FUNCTION IN PATIENTS UNDERGOING PERCUTANEOUS PATENT FORAMEN OVALE (PFO) CLOSURE

Claudia Rubino (a), Giovanni Taverna (a), Stefania Lo Giudice (a), Saro Pistorio (a), Giuseppe Certo (a), Nastasia Mancini (a), Pasquale Crea (a), Giampiero Vizzari (a), Maurizio Cusmà Piccione (a), Francesco Costa (a), Scipione Carerj (a), Gianluca Di Bella (a), Giuseppe Andò (a), Antonio Micari (a), Concetta Zito (a)
(a) DEPARTMENT OF CLINICAL AND EXPERIMENTAL MEDICINE-CARDIOLOGY UNIT-UNIVERISTY OF MESSINA, MESSINA, ITALY

Introduction. Early atrial fibrillation (AF) is a rare finding after percutaneous patent foramen ovale (PFO) closure with metal occluders. Rigid closure devices could have a role in atrial stretch and probably modifying atrial function inducing AF onset. The MPV (P-wave morphology-voltage-duration) ECG risk score is a reliable tool, validated in other studies, to predict AF in general population. Our study proposes to assess electro-mechanical atrial function by investigating the correlation between change of atrial strain and MPV ECG risk score after PFO closure.
Methods. From a group of 113 patients who underwent percutaneous PFO closure, we selected 19 patients (aged 18-65 years) studied with analysis atrial strain pre and post procedure. To assess the impact of percutaneous PFO closure with rigid closure devices we focused on Δ value between atrial strain values after and before procedure. Analysis of P wave duration, axis and MPV score was assessed by the ECG obtained the day before the procedure. The MPV ECG risk score included three P-wave variables: morphology in the lower leads (II-III-aVF), voltage in lead I, and P-wave duration. Accordingly, AF probability is low with a score=0-2, intermediate with a score=3-4 and high with a score=5-6 high. Left atrial function was evaluated by using volumetric and speckle-tracking analysis assessing the following parameters: total emptying fraction (EF), strain values of the reservoir (Res), conduit (CD) and contraction phase (CT). These parameters were evaluated before and one month after the procedure.
Results. Patients risk factors were hypertension (n=8), dyslipidemia (n=8), diabetes (n=0), smokers (n=4). Mean age was 46,58 ± 12,15 yrs, CHA2DS2-VASc score was 2,32 ± 1,25, Rope score was 5,74 ± 1,93 and MPV ECG risk score was 1,42 ± 0,69. No patients were lost at follow-up. At 1 month follow up no patients developed AF. The variation of atrial strain values after and before procedure showed a trend toward significance of Δ-total EF (-3,53% ± 9,3; p=0,195), Δ-CT (-1,38% ± 12,6; p=0,699), Δ-CD (-7% ± 21,5; p=0,278) and the Δ-RES (0,07% ± 17,3; p=0,987). Correlation analysis showed a significant correlation between P-wave duration and Δ-RES (r=0,577; p=0,039), P-wave duration and Δ-EF (r=0,574; p=0,040), ECG MPV risk score and Δ-CD (r=0,575; p=0,050), ECG MPV risk score and Δ-CT (r=0,656; p=0,015). Moreover, positive correlation was found between PFO dimension and Δ-CT (r=-0,764; p=0,045) and ECG MPV risk score and age (r=-0,481; p=0.037).
Conclusions. Our study demonstrated a tight correlation between electrical assessment of atrial contraction, assessed before the procedure and variations in mechanical atrial function after PFO closure The detrimental effect on atrial function due to implanting a rigid device could promote the development of AF. Atrial strain together with the ECG MPV risk score, could better predict the onset of early AF in these patients.

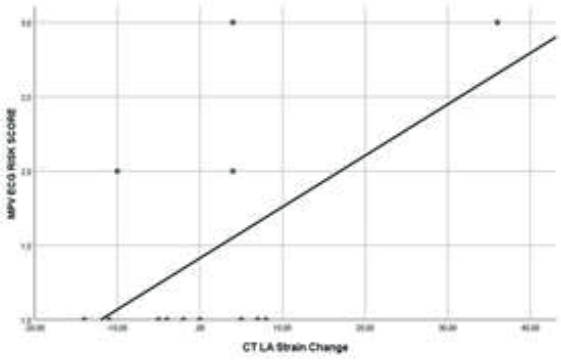

A354: A TYPICAL CASE OF MICROVASCULAR ANGINA WITH UNTYPICAL ECG FINDINGS

Simona Todisco (a), Federico Di Perna (a), Luigi Cappannoli (b), Antonino Buffon (b), Burzotta Francesco (b), Filippo Crea (b)
(a) UNIVERSITÀ CATTOLICA DEL SACRO CUORE-POLICLINICO AGOSTINO GEMELLI; (b) FONDAZIONE POLICLINCO UNIVERSITARIO AGOSTINO GEMELLI IRCCS-ROMA

Coronary microvascular dysfunction (CMD) relates to a broad range of clinical settings in which cardiac microcirculation is morphologically and/or functionally affected, leading to myocardial ischemia and causing anginal symptoms (microvascular angina). Based on the pathogenetic mechanism, there are two possible endotypes of CMD: 1) coronary microvascular spasm and 2) reduced coronary flow reserve (CFR). The gold standard for CMD diagnosis is represented by the coronary angiography with functional tests: 1) the acetylcholine provocative test for the diagnosis of microvascular spasm (endothelium-dependent dysfunction); 2) the determination of CFR and of the index of microvascular resistance (IMR) thorough a flow guidewire after endothelium-independent vasodilation (usually obtained with intracoronary adenosine injection). We report an emblematic case of CMD due to microvascular spasm in a

young woman with episodes of typical angina at rest, especially during the night, associated with tachycardia episodes. The patient was admitted to the cardiology unit and underwent coronary angiography, which revealed mild coronary atherosclerosis without any significant stenosis. Due to the very suggestive clinical presentation, provocative test by intracoronary acetylcholine infusion at increasing doses (20-50-100 micrograms) was also performed: from the beginning of the second dose (50 micrograms) the patient started suffering from her typical angor (symptomatology similar to that reported at home), and diffuse ST-T alterations (ST depression and T waves inversion in precordial leads) occurred. At the beginning of the third dose (100 micrograms) a lateral ST-segment elevation (mostly in aVL) was surprisingly observed. The ST-T modifications (including the elevation) were interestingly associated with only diffuse moderate vasoconstriction of the left anterior descending artery, not fulfilling the Covadis criteria for epicardial vasospasm, thus suggesting the presence of a vasospasm of the coronary microcirculation. Symptoms and ECG changes both regressed after intracoronary nitrates administration. Because of the diagnosis of microvascular angina with microvascular vasospasm, medical therapy with calcium antagonists was administered (withdrawing beta-blockers). Of note during hospitalization an additional episode of heart palpitation occurred, with evidence of inappropriate sinus tachycardia on 12-lead ECG. Upon administration of verapamil, there was the regression of both pain and tachycardia. This case highlights the importance of functional tests in patients with typical anginal symptoms and no evidence of coronary artery stenoses and, moreover, that ECG ST-elevation can be rarely observed also in the presence of microvascular vasospasm.

A355: AGE AND VASODILATOR RESPONSE TO DIFFERENT HYPEREMIC AGENTS: ADENOSINE VERSUS CONTRAST MEDIUM

Domenico Galante (b), Stefano Migliaro (i), Federico Di Giusto (a), Gianluca Anastasia (a), Edoardo Petrolati (a), Andrea Viceré (a), Giuseppe Zimbardo (c), Pio Cialdella (c), Enrico Romagnoli (a), Cristina Aurigemma (a), Francesco Burzotta (a), Carlo Trani (a), Roberto Martin-reyes (h), Sergio B. Baptista (g), Daniel Faria (j), Nicolas Amabile (f), Luis Raposo (e), Filippo Crea (a)
(a) UNIVERSITÀ CATTOLICA DEL SACRO CUORE - POLICLINICO GEMELLI IRCSS - ROMA; (b) OSPEDALE FATEBENEFRATELLI ISOLA TIBERINA - GEMELLI ISOLA; (c) POLICLINICO CASILINO - ROMA; (d) OSPEDALE GENERALE REGIONALE F. MIULLI ACQUAVIVA DELLE FONTI; (e) CENTRO HOSPITALAR DE LISBOA OCIDENTAL; (f) INSTITUT MUTUALISTE MONTSOURIS; (g) HOSPITAL CUF SINTRA; (h) HOSPITAL QUIRONSALUD SUR; (i) AURELIA HOSPITAL - ROMA; (j) HOSPITAL CLINICO SAN CARLOS - MADRID

Background. The influence of age on the vasodilatory response to different hyperaemic agents as well its influence on FFR and cFFR has not been previously explored.
Aims. To investigate the impact of age on these indices.
Methods. We extrapolated data from the PROPHET-FFR and MEMENTO studies. Only lesions with a relevant vasodilatory response to adenosine and contrast medium were considered of interest. A total of 2080 patients, accounting for 2294 pressure recordings were available for analysis. The cohort was stratified into three age terciles. Age-dependent correlations with FFR, cFFR, Pd/Pa and iFR were calculated. The vasodilatory response was calculated in 1619 lesions (with both FFR and cFFR) as the difference between resting and hyperaemic pressure ratios and correlated with ageing. The prevalence of FFR-cFFR discordance was assessed.
Results. Age correlated positively to FFR (r=0.062, p=0.006), but not with cFFR (r=0.024, p=0.298), Pd/Pa (r =-0.015, p=0.481) and iFR (r =-0.026, p=0.648). The hyperaemic response to adenosine (r=-0.102, p=<0.0001) and to contrast medium (r=-0.076, p=0.0023) showed a negative correlation with age. When adjusted for potential confounders, adenosine induced hyperaemia was negatively associated with age (p=0.04 vs p=0.08 for cFFR). Discordance decreased across age terciles (14.64% vs 12.72% vs 10.12%, p=0.032).
Conclusions. As compared to adenosine, contrast induced hyperaemia appeared to be less affected by age. cFFR may be considered a more stable and reproducible tool to assess epicardial stenosis in elderly patients.

A356: ANOMALOUS COMMON ORIGIN OF THE CORONARY ARTERIES FROM A SINGLE OSTIUM IN THE RIGHT SINUS OF VALSALVA IN A PATIENT WITH NON-ST ELEVATION MYOCARDIAL INFARCTION

Francesco Amata (a, b), Ottavia Cozzi (a, b), Giulio Stefanini (a, b), Giuseppe Ferrante (a, b), Damiano Regazzoli Lancini (b), Bernhard Reimers (b), Gianluigi Condorelli (a, b)
(a) DEPARTMENT OF BIOMEDICAL SCIENCES, HUMANITAS UNIVERSITY, MILAN, ITALY; (b) CARDIO CENTER, IRCCS HUMANITAS RESEARCH HOSPITAL, MILAN, ITALY

Ectopic origin of the left coronary artery from the right sinus of Valsalva is a rare coronary artery anomaly which is usually detected incidentally, although ischemia can occur due to its anomalous course or concomitant atherosclerotic disease. This uncommon anatomical condition may pose a particular challenge if coronary revascularization is needed, especially in the acute setting. We present a case of an 80-year-old man with an anomalous common origin of the right coronary artery (RCA), left circumflex (LCX) and left anterior descending (LAD) from a single ostium in the right sinus of Valsalva, with absence of a left main stem. The patient presented with non-ST elevation myocardial infarction, in the context of critical two-vessel disease, successfully treated with percutaneous revascularization. The procedure was challenging as an unusual take-off angle and vessel tortuosity made difficult to selectively cannulate the ostium using standard guiding catheters, requiring the use of an Amplatz left 1 catheter which facilitated coronary engagement and provided great passive support. Revascularization was also facilitated using hydrophilic guidewires with flexible shafts that provided excellent trackability and good torque performance in the patient's tortuous vessels. A hybrid revascularization strategy was performed, comprising angioplasty with Sirolimus-coated balloons on distal LAD and first diagonal branch (D1) and the implantation of a single Everolimus-eluting stent (EES) on the proximal LAD. Subsequently, the obtuse marginal branch (OM) was treated with a single EES, with a good result on angiography. In conclusion, percutaneous revascularization in coronary arteries with anomalous origin is more complex than with normal anatomy, requiring operator technical expertise to carry out the procedure successfully.

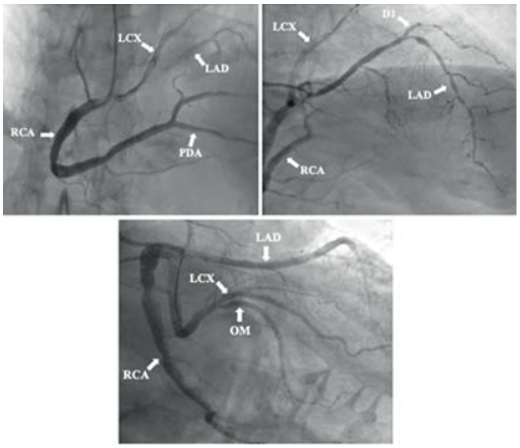

A357: RIGHT TRANSCAROTID TRANSCATHETER AORTIC VALVE IMPLANTATION (TAVI).

De Persio Giovanni (a), Luca Altamura (a), Tiziana Salatino (a), Anna Silvia Ghini (a), Roberto Celotto (a), Fabrizio Tomai (a)
(a) DEPT. CARDIOVASCULAR SCIENCES, EUROPEAN HOSPITAL, ROME, ITALY

Rationale. While the traditional iliofemoral access site remains the most common for TAVI, alternate access sites include the transapical, direct-aortic, and subclavian techniques. Transcarotid approach for TAVI may be considered when these access sites are not feasible.
Technical resolution. An 88-year-old male, with severe aortic stenosis and a previous pacemaker implantation, was admitted in our hospital for dyspnoea at rest. Transthoracic echocardiogram showed severe aortic stenosis (AVA: 0.7 cm^2) and reduced LVEF. Multislice CT angiography revealed severe aortic valve calcification, nearly occluded iliofemoral arteries and severe stenosis of the left common carotid and left subclavian arteries. Coronary angiography showed a diffuse three-vessel disease. At the light of these findings, the heart team proposed TAVI with a right transcarotid access. Under general anesthesia, the right common carotid artery was surgically exposed and a 6F sheath was introduced. A J-tipped soft guidewire was used to guide a JR4 catheter, which was then exchanged with a straight-tip guidewire to cross the aortic valve. After crossing, the straight guidewire was exchanged for a stiff guidewire, and a 26mm Edwards Sapien 3 Ultra valve was successfully implanted using the 21F Certitude delivery system under rapid pacing. Carotid arterial access was then surgically repaired.
Clinical implications. The patient was discharged 4 days after the procedure, without complications. At 6-month follow-up, the patient was asymptomatic and echocardiogram revealed normal bioprosthetic valve function and improved LVEF.
Perspectives. The minimally invasive transcarotid approach for TAVI is a valid option for patients in whom the transfemoral gold standard or other access sites are not feasible. Arguably, left carotid access (unfeasible in our patient) should be favored to the right because it provides superior coaxial alignment between the ascending aorta, optimal positioning for the transcatheter valve during the device deployment and simple operating room configuration.

A358: SAFETY FIRST, A CASE OF TAVI IN AN END-STAGE CKD PATIENT

Alice Centola (a), Federico De Marco (a)
(a) CENTRO CARDIOLOGICO MONZINO

Clinical presentation and initial work-up. We present a case of a 75 y.o. woman, admitted to the ER for worsening dyspnoea (NYHA IV) and

lower limb oedema. In her past medical history, she was hypertensive, she had an end-stage CKD (FANS abuse related), chronic anaemia, rheumatoid arthritis and a post-streptococcal glomerulonephritis in childhood. One year before coming to our attention, she was admitted to the ER f or acute heart failure and she was diagnosed of severe left ventricular systolic dysfunction and severe aortic stenosis (LVEF 32%, grad max/med 70/40 mmHg, AVA 0.5 cmq/0.28 cmq/mq). At admission to our ER she was severely dyspnoeic, normotensive, tachycardic, with lower limb oedema. Initial work-up consisted of blood tests, that found anemia (Hb 9.7 g/dL) and impairment of renal function with an acute kidney disease on a chronic kidney disease (BUN 198 mg/dL, creatinine 5.16 mg/dL), Chest X-Ray that showed diffused congestion, with pleural effusion. Transthoracic echocardiogram showed severe left ventricular dilatation, biventricular systolic disfunction, (LVEF 23%), severe aortic stenosis low-flow low-gradient type (v max 3.1 m/sec, ΔP max/med 39/27 mmHg, AVA 0,4 cm^2/0.26 cm^2/m^2, associated with mild aortic regurgitation, severe secondary mitral regurgitation and severe pulmonary hypertension. After discussion in Heart Team, indication to treatment with TAVI was established.

Pre-procedural planning and TAVI procedure. Because of the presence of end-stage CKD, pre-procedural planning consisted of CT Scan without contrast media, that showed aortic valve Calcium Score of 2680 AU, coronary arteries Calcium Score ofs 516 A; Doppler US of the femoral arteries that showed regular flow and good diameters bilaterally. The patient underwent TAVI procedure and intervention was guided by fluoroscopy and transesophageal echocardiogram. First of all Intraprocedural sizing of the aortic valve was performed thanks to transesophageal echocardiogram and, according to the found dimeters, a self-expandable valve was chosen. After delivering three different Pigtail catheters in each aortic cusp, 3-cusp-view and cusp-overlap view fluoroscopic projections were acquired. Because of high calcium burden pre-dilatation was performed. After pre-dilatation aortic valve was delivered and the realeased. After valve release, moderate paravalvular leak was evident, so post-dilatation was performed, achieving a good final result, with mild-to-moderate paravalvular leak. Only 5 cc of contrast media were injected, in order to check the site of puncture of the right femoral access.

Clinical Outcome and follow-up. Post-procedural transthoracic echocardiogram showed mild improvement of LVEF (34%), with a good result of TAVI intervention (transvalvular aortic gradients 17/9 mmHg, mild-moderate anterior and posterior PV; mild mitral regurgitation, no pulmonary hypertension. Non further worsening of renal function was evident and creatinine serum levels remained stable. Patient was discharged in a good clinical condition, with the indication to begin substitutive renal therapy.

Conclusions. No contrast media TAVI is a safe and effective treatment in patients with CKD and severe aortic stenosis.

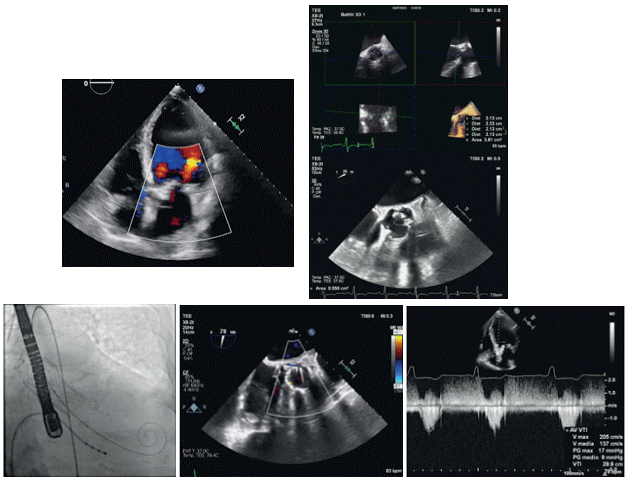

A359: REVASCULARIZATION WITHOUT DRUG ELUTING STENTS: A CASE REPORT ABOUT METALLIC-LESS REVASCULARIZATION TECHNIQUES

Sara Maisenti (a), Gabriele Facci (a), Francesca Rubino (a), Andrea Agbariah (a), Ilaria Armani (a), Simone Fezzi (a), Domenico Tavella (a), Valeria Ferrero (a), Flavio Luciano Ribichini (a)
(a) DIVISION OF CARDIOLOGY, DEPARTMENT OF MEDICINE, AZIENDA OSPEDALIERA UNIVERSITARIA INTEGRATA, VERONA, ITALY

Rational. 56 years old patient, admitted to our service for myocardial infarction without ST elevation. In medical history he had dyslipidaemia, hypertension and familiarity for cardiovascular disease, without previous cardiological problems. The patient went to the ER for chest pain, started after his work shift. When admitted to the ER, the patient was still symptomatic for chest pain, with resolution after 3 hours after somministration of analgesics, with normal pressure and heart rate. An ECG was performed, without relevant findings, at the blood exams significative movement of cardiac troponins. At the echocardiogram apical hypokinesia of left ventricle with preserved ejection fraction.

Technical resolution. Coronarography was performed, with evidence of severe diffuse atheromatic disease of the left anterior descending artery (LAD) at the proximal segment and sub-occlusive stenosis at the middle segment. Due to the diffuseness of the atherosclerotic disease on the LAD, which would have required a complete stenting of the artery, which using classical Drug Eluted Stents would have led to a complete "full metal jacket" of the artery, in such a young patient who does not have medical history suggesting a progression of the atheromatic disease, metallic-less techniques were chosen. The two lesions were pre-dilatated with a non-compliant (NC) balloon. The proximal lesion was treated with a bioresorbable scaffold (BVS) Magmaris 3x25 mm, post-dilatated with a NC balloon, without complications. The distal segment was treated with a Drug Eluting Balloon (DEB) Pantera Lux 2.5x20 mm, expanded for 90 seconds, with evidence of focal dissection, not flow limiting. At the clinical follow-up performed at one and three months, the patient was asymptomatic for angina, without any cardiovascular event.

Clinical implications. When facing coronaropathy in a young person, without many cardiovascular risk factors, it is a good option to treat the coronary with techniques that do not leave metallic material in the arteries, which exposes young patients to a higher rate of complications if compared to older patients. When it is preferred to use this kind of techniques, the options can be DEB or BVS. As seen in this case report, often the DEB can lead to complications.

Perspectives. Nowadays there is a rising interest in the use of DEB for focal de-novo lesions in young patients as well as in-stent restenosis (ISR). It's also well-known that every DEB complication needs the use of DES to fix it. However, little is proven and studied about the use of BVS on de-novo lesions and on coronary injuries as complications of "conventional" PCI, as well as those derived from DEB delivery.

A360: ACUTE AND LONG-TERM PERFORMANCE OF BIORESORBABLE SCAFFOLDS IN SPONTANEOUS CORONARY ARTERY DISSECTION (SCAD): THE EXPERIENCE OF THE COORDINATOR CENTER OF THE INTERNATIONAL MULTICENTER REGISTRY DISCO

Federico Giacobbe (a), Enrico Cerrato (b, c), Marco Pavani (b, c), Cristina Rolfo (b, c), Carloalberto Biolé (b), Matteo Bianco (b), Alfonso Franzé (b, c), Francesco Tomassini (b, c), Greca Zanda (b, c), Dario Celentani (c), Emanuele Tizzani (c), Alessandra Chinaglia (b), Ferdinando Varbella (c)
(a) AOU CITTÀ DELLA SALUTE E DELLA SCIENZA DI TORINO; (b) AOU SAN LUIGI GONZAGA ORBASSANO; (c) OSPEDALE DEGLI INFERMI RIVOLI

Background. Spontaneous Coronary Artery Dissection (SCAD) is a challenging clinical scenario and represents an increasingly studied cause of acute coronary syndrome (ACS). An interventional strategy in these cases remains controversial since it may require an extensive permanent metallic stenting of vessel to seal the dissection with a non negligible rate of complications. Moreover, SCAD patients are usually young women with non-calcified disease where Bioresorbable Scaffolds (BrS) may be an intriguing option.

Methods. DISCO IT/SPA is a International observational registry which retrospectively enrolled patients admitted with a diagnosis of SCAD across 26 Italian and Spanish centers. Baseline, procedural characteristics, in–hospital management and outcomes of 369 SCAD patients were collected, of these 12 patients were treated with PCI with BrS MAGMARIS at the coordinator center of Rivoli and Orbassano. Major cardiovascular events (MACEs) were defined as the composite of cardiovascular death, non-fatal Myocardial infarction (MIs) and any PCI performed.

Results. In our cohort of SCAD patients treated with BrS there was a slight prevalence of women (n=7, 58,3%) with an average age of 50,9±7,4 years. NSTE-ACS was the most common clinical presentation (83,3%), followed by STEMI (16,7%). Mean ejection fraction was 53,2±11,3%. In 7 patients the first treatment choice for SCAD was PCI with BrS deployment, in 5 patients BrS were deployed during hospitalization for unplanned PCIs (four of them) and after one month for a MI due to SCAD recurrence in the last patient. Multivessel disease was present only in one case and LAD-DG was the main vessel affected (n=10, 83,3%). SCAD type 2A was the most frequent (41,7%). Intravascular imaging was performed in 10 cases (83,3%) and procedural success was achieved in all cases. Angiographic follow-up was obtained in 9 patients (75%), through coronary angiogram (n=8) or CT scan (n=1), at a mean length of 5,2±5,6 months. In-hospital MACEs were 5 (23,8%) but none of them occurred after BrS deployment. The only MACE reported after BrS deployment was an unplanned PCI for SCAD progression.

Conclusions. In SCAD bioresorbable scaffolds represent an excellent option to preserve the natural physiology of the coronary vessels. Notably, in our cohort we reported a very high procedural success rate in PCIs assisted in large part by intracoronary imaging. Further studies with larger numerosity are needed to demonstrate the advantages of this type of stent in these patients.

A361: DECOMPENSATED HYPERTHYROIDISM IN ST-ELEVATION MYOCARDIAL INFARCTION: CLINICAL AND ANGIOGRAPHIC EVALUATION OF A RARE PRECIPITATING FACTOR

Dyovane Lopes (a), Paula Santiago Teixeira (a), Iran Gonçalves (a), Valdir Ambrósio Moises (a), Adriano Caixeta (a), Adriano H. P. Barbosa (a), Pedro Ivo De Marqui Moraes (a)
(a) ESCOLA PAULISTA DE MEDICINA - UNIVERSIDADE FEDERAL DE SÃO PAULO

Introduction. Hyperthyroidism is a hyperadrenergic state that predisposes to tachyarrhythmias, high-output heart failure and acute myocardial infarction (AMI) by mechanisms that include vasospasm and coronary thrombosis even in the absence of atherosclerotic substrate.
Objective: To describe the clinical and angiographic characteristics of patients with decompensated hyperthyroidism treated in a regional ST-elevation myocardial infarction (STEMI) network.
Methods. We analyzed 2723 consecutive STEMI patients (pts) from March 2010 to December 2019, attended in primary hospitals and referred to a tertiary center, 96.4% (2625 pts) of whom underwent fibrinolysis followed by cardiac catheterization (pharmaco-invasive strategy) and 3.6% (98 pts) submitted to primary percutaneous coronary intervention. Laboratory criteria for decompensated hyperthyroidism were defined as the association of thyroid-stimulating hormone (TSH) in suppressed serum levels (<0.05 mUI/mL) and free thyroxine (fT4) values above the upper reference limit of 1.7 ng/dL. Categorical variables were compared using chi-square test and numerical variables expressed as median and interquartile range and compared using Mann-Whitney test.
Results. Ten patients (0.37% of cases) had decompensated hyperthyroidism criteria at hospital admission, none of whom had prior knowledge of thyroid disease. Compared to the general STEMI cohort, those with hyperthyroidism had a lower median age (45.5 [42-59] x 57.5 [51-66] years; p<0.01), lower baseline LDL-cholesterol levels (96 [72-115] mg/dL x 126 [100-154] mg/dL; p<0.01), no case of diabetes mellitus (0.0% x 30.9%; p<0, 01) and higher baseline heart rate (90 [74-119] bpm x 77 [67-89] bpm; p<0.01). There was no difference between groups in terms of gender, hypertension, smoking, creatinine clearance and frequency of anterior wall involvement. From an angiographic point of view, all patients with decompensated hyperthyroidism had coronary obstruction exclusively in the "culprit artery", while in the STEMI cohort the single vessel coronary artery disease occurred in less than half of the cases (100% x 44, 9%; p<0.01). Although there were no deaths in the hyperthyroid group, there was no significant difference in hospital mortality (0.0% x 5.8%; p=1.0).
Conclusions. In STEMI patients treated in a regional network structured mainly by pharmaco-invasive strategy, decompensated hyperthyroidism was a rare phenomenon, predominantly in younger individuals, with less cardiovascular comorbidities and all with involvement of a single coronary artery disease. It is plausible to consider hyperthyroidism a rare precipitating factor of STEMI.

A362: CASUAL OR CAUSAL: A CASE REPORT OF OVERLAP SYNDROME

Giovanni Martino (a), Sabato Sorrentino (a), Salvatore De Rosa (a), Annalisa Mongiardo (a), Alessandro Caracciolo (a), Lorenzo Volpe (a), Alessandro Laschera (a), Ciro Indolfi (a)
(a) UNIVERSITÀ DEGLI STUDI MAGNA GRAECIA CATANZARO

Takotsubo syndrome (TTS) and acute coronary syndrome (ACS) are generally regarded as mutually exclusive diagnoses, however, recent reports have called this into question and suggest that the two conditions may coexist. Hereafter, we report a case of concurrent TTS and ST-elevation myocardial infarction (STEMI) recently admitted at our Institution. We present a case of a 75-year-old woman with a history of hypertension with 3-h left-sided chest pain and dyspnea after experiencing acute emotional stress. She was initially diagnosed with lateral ST-segment elevation myocardial infarction (STEMI) since the 12-lead electrocardiogram (ECG) showed 2 mm ST elevation in DI-aVL leads and ST depression in DIII-aVF. The trans-thoracic echocardiogram (TTE) revealed mid-distal segment hypokinesia of the anterolateral wall, apex akinesia with apical ballooning, and basal segment hyperkinesia, resulting in a 40% left ventricular ejection fraction (EF). Coronary angiography demonstrated a critical thrombotic stenosis involving the bifurcation of the circumflex (Cx) artery and an obtuse marginal (OM) branch (Medina 1,1,1), critical stenosis of right coronary artery (RCA), and no stenoses of left descending artery. Considering the comparable territory distribution and diameter of both the Cx artery and the OM branch, a mini crush stenting of the OM branch with a 2.5 x 15 mm drug-eluting stent (DES) and a 2.75 x 18 mm DES for the Cx artery was performed. Following the procedure, a total symptoms regression was noted, along with the complete resolution of the ST elevation in the lateral leads. However, on the following day, there was a gradual inversion of T waves and a significant elongation of the QT interval, from 430 msec at presentation to 630 msec. Furthermore, the echocardiogram revealed a persistent pattern of apical ballooning. These findings led to the interpretation of concurrent TTS and STEMI. Notably, the InterTAK Diagnostic score, which indicated a 76% likelihood of TTS, further supported this observation. On the fifth day of hospitalization staged PCI of residual critical stenosis of the right coronary artery was performed. During the hospitalization the patient not experienced major cardiac arrhythmias, the EKG revealed a progressive normalization of T waves inversion and shortening of QTc interval. At the discharge, the sixth day of hospitalization, the TTE showed a significative improvement of both regional wall motion abnormalities (RWMA) and left ventricular EF (45-50%). At 2 months of follow-up, the left ventricle RWMA was completely recovered with a left ventricle ejection fraction of 59% Simpson and an average Global longitudinal strain of -22.9%. Patients with concomitant TTS and obstructive coronary artery disease are frequently misdiagnosed as typical acute coronary syndrome (ACS), making differentiation challenging. In this case, the subsequent deep T-wave inversion across the precordial leads and the QTc interval elongation suggest a sequential occurrence of STEMI and TTS. Conversely, certain characteristics such as a short time to peak troponin (less than 6 hours) and a modest troponin elevation favor TTS as the primary cause, though the presence of TIMI flow III downstream of the lesion potentially explains limited troponin release. Although isolated TTS generally carries a favorable prognosis, the coexistence of these conditions may amplify the risk of short- and long-term outcomes. In the absence of a single "gold standard" diagnostic test, ventriculography and CMR may be useful complementary tools to correctly diagnose TTS during AMI, although it remains uncertain to determine if the coexistence of TTS and ACS is accidental or there is a causal link.

A363: IVA FANTASMA

Francesco Contorni (a), Nicoletta Franco (a), Filippo Ottani (a)
(a) UOC CARDIOLOGIA OSPEDALE INFERMI-RIMINI

Introduzione. L'arteropatia coronarica trova nella dissezione spontanea (S-CAD) un noto possibile meccanismo di limitazione al flusso, tipica di pazienti giovani, prevalentemente di sesso femminile. In un simile gruppo di pazienti, in assenza di pre-condizionamento ischemico del miocardio, la S-CAD si estrinseca spesso con quadri clinico-strumentali di sindrome coronarica acuta (SCA), la cui storia naturale ed il cui trattamento restano ad oggi pochi chiari.
Caso clinico. Un uomo di 57 anni, senza fattori di rischio cardiovascolari, giungeva in PS dopo visita cardiologica ambulatoriale in seguito ad episodio di dolore toracico tipico insorto 7 giorni prima, durante sforzo intenso. All'ecocardiogramma veniva riscontrata normale funzione sistolica sinistra in assenza di anomalie della cinesi segmentaria; all'ECG tuttavia si rilevavano T negative in sede antero-settale. Nel sospetto di recente SCA eseguiva primo dosaggio di troponina ad alta sensibilità, risultato positivo (Tnhs 158 pg/ml). Il giorno successivo, a distanza di 8 giorni dall'episodio indice, veniva eseguita coronarografia, con riscontro di occlusione ostiale dell'arteria discendente anteriore, in assenza di collateralizzazione di sorta; i restanti segmenti dell'albero coronarico risultavano invece del tutto indenni da malattia ateromasica. Si decideva di mantenere il paziente in osservazione e, a distanza di 5 giorni dal primo esame angiografico, veniva ripetuta coronarografia che confermava l'occlusione ostiale della discendente anteriore con iniziale collateralizzazione omo-coronarica del tratto peri-apicale, con segni di dissezione spiraliforme. Vista la buona funzione sistolica sinistra e l'assenza di aritmie registrate durante il monitoraggio, il paziente veniva dimesso con singola terapia antiaggregante e, a due mesi di distanza dall'evento, veniva sottoposto a TC coronarica che mostrava completa riabilitazione del vaso.
Conclusioni. La dissezione coronarica resta un'entità enigmatica, di difficile gestione clinica ed interventistica. Nei casi in cui mancano segni di sofferenza ischemica acuta in atto, la strategia conservativa rappresenta spesso l'opzione migliore, perfino in casi limite come quello incontrato nella nostra esperienza.

A364: EARLY ACUTE KIDNEY INJURY AFTER TRANSCATHETER AORTIC VALVE IMPLANTATION: PREDICTIVE VALUE OF CURRENTLY AVAILABLE RISK SCORES

Daniele De Feo (a), Fortunato Iacovelli (a), Francesco Spione (b), Alessandro Xhelo (a), Maurizio D'Alessandro (a), Francesco Loizzi (c), Alessandro Cafaro (d), Chiara Palmitessa (a), Alessandro Santo Bortone (a), Marco Matteo Ciccone (a)
(a) POLICLINICO UNIVERSITY HOSPITAL - BARI; (b) "MONTEVERGINE" CLINIC MERCOGLIANO; (c) "SS ANNUNZIATA" HOSPITAL - TARANTO; (d) "VITO FAZZI" HOSPITAL - LECCE

Background. Acute kidney injury (AKI) after transcatheter aortic valve implantation (TAVI) is a frequent complication associated with adverse outcomes and mortality. Several scores, such as Mehran; contrast medium volume, estimated glomerular filtration rate, emergency procedure, age, hypotension, myocardial infarction, left ventricular ejection fraction, anemia, and diabetes (CR4EATME3AD3); and age, serum creatinine, and left ventricular ejection fraction (ACEF) scores have already been tested in the prediction of TAVI-related AKI in small populations, but they have been proven to underperform compared with the coronary field. These scores were tested in only 559 patients and their area under the curve (AUC) at the receiver operating characteristic (ROC) analysis was respectively 0.55, 0.55, and 0.51, in predicting any stage of AKI. On the contrary, the William Beaumont Hospital (WBH) score has never been tested in any TAVI patient.
Methods. The main aim of our retrospective analysis was to investigate the predictive performance of these four coronary-specific AKI risk

scores in a larger cohort, to verify if they are reliable in predicting AKI after TAVI.
Results. Performing a ROC analysis we detected only slightly higher AUC values (Mehran, CR4EATME3AD3, and ACEF scores 0.70; 0.79; 0.71 respectively), confirming the limited diagnostic accuracy of these scores, which were developed in a different setting. The main findings of our study were: the incidence of AKI, based on the greater SCr value in the first 48 hours after TAVI, was 15.31%; short-term complications periprocedural mortality, were higher in AKI (patients 1.04%). According to a multivariate analysis we observed new independent predictors, i.e., contrast medium (CM) amount and osmolality, procedural and periprocedural - associated factors that lead to renal injury after TAVI.
Conclusions. Current available AKI risk scores have not demonstrated sufficient diagnostic accuracy to predict TAVI-related AKI because these scores do not include some procedural and periprocedural parameters, whose role in its multifactorial pathophysiology is not yet well understood. It is crucial to identify which patients are mostly exposed to this widespread but underestimated complication to improve patient's outcome. Further studies are surely needed so that a TAVI-dedicated AKI risk score may be created.

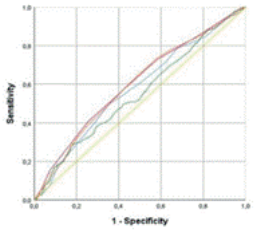

Figure 3. ROC curve analysis for current AKI risk scores predictive power in TAVI patients. ROC = receiver-operating characteristic; WBH = William Beaumont Hospital; ACEF = age, serum creatinine, and left ventricular ejection fraction; $CR_4EATME_3AD_3$ = contrast medium volume, estimated glomerular filtration rate, emergency procedure, age, hypotension, myocardial infarction, left ventricular ejection fraction, anemia, and diabetes.

Table 2
ROC analysis for the prediction of AKI by dedicated scores.

	Mehran score	WBH score	$CR_4EATME_3AD_3$ score	ACEF score
AUC (DeLong standard error)	0.576 ± 0.020	0.604 ± 0.020	0.597 ± 0.020	0.551 ± 0.021
95% CI	0.55-0.60	0.58-0.63	0.57-0.62	0.52-0.58
Asymptotic significance	**<0.001**	**<0.001**	**<0.001**	**0.012**
CL	−0.001	−0.001	−0.001	−0.001
Slope	1.001	0.988	0.981	0.922
Cut-off	13	4	6	1.86
Youden's index	0.143	0.153	0.155	0.105
Sensitivity (%)	50	41	63	28
Specificity (%)	65	74	53	82
Accuracy (%)	62	69	54	74
LR⁺/LR⁻	0.78-1.40	0.79-1.60	0.71-1.33	0.87-1.59

ROC = receiver-operating characteristic; AKI = acute kidney injury; WBH = William Beaumont Hospital; $CR_4EATME_3AD_3$ = contrast medium volume, estimated glomerular filtration rate, emergency procedure, age, hypotension, myocardial infarction, left ventricular ejection fraction, anemia, and diabetes; ACEF = age, serum creatinine, and left ventricular ejection fraction; AUC = area under the curve; CI = confidence interval; LR = likelihood ratio; CL = calibration in the large.

A365: NON TUTTE LE TROMBOSI CORONARICHE SONO ADATTE ALLO STENTING: UN CASO DI ANEURISMA CORONARICO NEL CONTESTO DI UNA SINDROME CORONARICA ACUTA

Antonio Capolongo (a, b), Felice Gragnano (a, b),
Elisabetta Moscarella (a, b), Ettore Blasi (a, b), Vincenzo De Sio (a, b),
Fabrizia Terracciano (a, b), Claudia Concilio (a, b), Vincenzo Diana (a, b),
Ivana Pariggiano (a, b), Enrica Golia (a, b), Arturo Cesaro (a, b),
Paolo Calabro (a, b)
(a) AORN SANT'ANNA E SAN SEBASTIANO; (b) UNIVERSITÀ DEGLI STUDI DELLA CAMPANIA L. VANVITELLI

Background. Gli aneurismi coronarici sono definiti come una dilatazione coronarica che supera di 1.5 volte il diametro dei segmenti coronarici adiacenti normali (non dilatati). La prevalenza degli aneurismi coronarici nella popolazione generale è di circa il 5%. I principali fattori di rischio associati sono l'aterosclerosi e la malattia di Kawasaki. La gestione dei pazienti con aneurismi coronarici rimane complessa e non standardizzata, in particolare nel contesto delle sindromi coronariche acute. Riportiamo il caso di un giovane paziente con infarto miocardico senza sopraslivellamento del tratto ST che alla coronarografia presentava multipli aneurismi dell'arteria discendente anteriore e dell'arteria circonflessa.
Caso clinico. Un uomo di 43 anni si presenta con dolore toracico acuto presso il Dipartimento di Emergenza della nostra AORN. L'ECG non rivelava alterazioni ischemiche specifiche, ma i livelli di troponina all'ingresso risultavano elevati. Pertanto, veniva effettuato un esame coronarografico, che evidenziava la presenza di multipli aneurismi coronarici dell'arteria discendente anteriore e dell'arteria circonflessa, con evidenza di trombosi coronarica acuta e di flusso lento nell'arteria discendente anteriore. In considerazione delle potenziali difficoltà di impianto dello stent e del rischio di malapposizione sulla parete della coronaria aneurismatica, si preferiva un approccio conservativo con terapia medica ottimale e doppia terapia antitrombotica (aspirina e warfarin).
Discussione. Le sindromi coronariche acute possono presentarsi nel contesto di un quadro angiografico complicato dalla presenza aneurismi coronarici. La gestione interventistica e medica di tali pazienti risulta difficile per l'assenza di evidenze in questo setting. Ulteriori studi clinici sono necessari per sviluppare algoritmi di trattamento standardizzati per migliorare la gestione e la prognosi di questi pazienti.

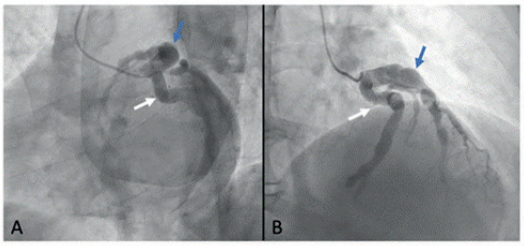

Figura. Angiografia coronarica con evidenza di alterazioni ectasiche dell'arteria discendente anteriore (freccia blu) e dell'arteria circonflessa (freccia bianca).

A366: GESTIONE DELL'INFARTO MIOCARDICO E DELL'ISCHEMIA MIOCARDICA SENZA OSTRUZIONE CORONARICA SIGNIFICATIVA: APPROFONDIMENTI DA UNA SERIE DI CASI CLINICI

Dario Grassini (a, b)
(a) UNIVERSITÀ DI PISA; (b) LABORATORIO DI EMODINAMICA, DIPARTIMENTO CARDIO-TORACO-VASCOLARE, AZIENDA OSPEDALIERO-UNIVERSITARIA PISANA, PISA

Acute coronary syndromes typically result from the formation of atherosclerotic lesions in a large epicardial vessel, which restrict blood flow either partially or completely. These lesions can be identified through angiography, an invasive imaging technique that enables visualization of the coronary arteries. However, a small percentage of patients, usually ranging from 5% to 10%, experience symptoms and/or signs of myocardial ischemia, either acute or chronic, without significant obstructive coronary lesions visible on angiography. This condition is particularly prevalent in young women and is characterized by two distinct forms: myocardial infarction with no obstructive coronary arteries (MINOCA) and myocardial ischemia with no obstructive coronary arteries (INOCA). MINOCA can be caused by a variety of heterogeneous mechanisms, including coronary vascular spasm, microvascular disease, spontaneous coronary dissection, and plaque rupture or erosion. Conversely, coronary vasospasm and microvascular dysfunction account for most patients with INOCA. We here present three cases of MINOCA/INOCA that were evaluated using optical coherence tomography, coronary flow reserve, index of microcirculatory resistance, and acetylcholine provocative test. These diagnostic tests allowed us to identify a specific condition and adopt a targeted treatment for each patient.

A367: TAVR IN SAVR IN IIIB TYPE AORTIC ROOT

Silvia Crescenzia Motta (a), Giuliano Costa (a), Orazio Strazzieri (a),
Elena Dipietro (a), Valentina Frittitta (a), Alessandro Comis (a),
Sofia Sammartino (a), Mariachiara Calì (a), Marco Barbanti (a),
Corrado Tamburino (a)
(a) POLICLINICO G.RODOLICO CATANIA

Rational. Transcatheter aortic valve implantation (TAVI) to manage bioprosthetic valve dysfunction has been successful in mitigating the risk of a redo cardiac surgery. However, TAVI-in-SAVR (surgical aortic valve replacement) is a complex intervention, potentially associated with feared complications such as coronary artery obstruction or Sinus of Valsalva sequestration. Coronary obstruction risk is highest in IIIB type aortic root according to VIVID classification.
Technical resolutions. BASILICA and chimney hybrid tecnique is a feasible strategy that required a careful CTA assessment to plan the best fluoroscopic working views to obtain an optimal laceration of the leaflet in a case of stentless bioprosthesis dysfunction.
Clinical implications. In case of IIIB type aortic root, double BASILICA should be considered but haemodynamic instability might occur after first laceration, hence bail-out strategy should be pre-emptively planned.
Perspectives. In consideration of the expansion of valve-in-valve TAVI procedure, it is essential to familiarize with BASILICA tecnique and CTA assessment using S-curved to perform effective procedure.

A368: RIGHT HEART CATHETERIZATION: ANTECUBITAL VEIN APPROACH TO REDUCE FLUOROSCOPY TIME, RADIATION DOSE AND GUIDEWIRES NEED

Luca Donisi (a, b), Giuseppe Locatelli (a, b), Luca Mircoli (a),
Federico Colombo (a), Lucia Barbieri (a), Gabriele Tumminello (a),
Stefano Carugo (a, b), Massimiliano Ruscica (c), Marco Vicenzi (a, b)
(a) DEPARTMENT OF CARDIO-THORACIC-VASCULAR DISEASES, FOUNDATION IRCCS CA' GRANDA OSPEDALE MAGGIORE POLICLINICO; (b) DEPARTMENT OF CLINICAL SCIENCES AND COMMUNITY HEALTH, UNIVERSITY OF MILAN; (c) DEPARTMENT OF PHARMACOLOGICAL AND BIOMOLECULAR SCIENCES "R. PAOLETTI", UNIVERSITY OF MILAN

Antecubital access for right heart catheterization (RHC) is a widespread technique even though there is a need to clarify if differences and significant advantages stand compared to proximal vein access (femoral vein). To pursue this issue, we retrospectively identified patients who underwent RHC in our clinic over a 7-year period (between Jan 2015 and Dec 2022).

We revised demographic, anthropometric, and procedural data including the fluoroscopy time, the radiation exposure, and the use of guidewires. The presence of any complications was also assessed. In patients with an antecubital access, the fluoroscopy time and the radiation exposure were lower compared to proximal vein access (6 vs 3 min, mean difference of 2 min, CI 95% 1-4 min, p<0.001 and 61 vs 30 cGy/m2, mean difference 64 cGy/m2, CI 95% 50-77, p<0.001). The number of patients requiring the use of at least one guidewire was lower in the group undergoing RHC (55% vs 43%, p=0.01). The feasibility was optimal as just 0.9% of procedure switched from antecubital to femoral access, with a negligible rate of complications. The choice of the antecubital site exhibits advantages, e.g., a shorter fluoroscopy time, a reduced radiation dose and a lower average number of guidewires used compared to proximal vein access.

A369: THE "WOGGLE" TECHNIQUE FOR VENOUS ACCESS SITE MANAGEMENT: AN OLD TECHNIQUE FOR A NEW NEED

Gabriele Tumminello (a), Lucia Barbieri (a), Carlo Avallone (a, b), Andrea Faggiano (a, b), Nello Bellissimo (b), Luca Mircoli (a), Federico Colombo (a), Marco Vicenzi (a, b), Massimiliano Ruscica (c), Stefano Carugo (a, b)
(a) DEPARTMENT OF CARDIO-THORACIC-VASCUAR DISEASES. FOUNDATION IRCCS CA GRANDA OSPEDALE MAGGIORE POLICLINICO, MILAN, ITALY; (b) DEPARTMENT OF CLINICAL SCIENCES AND COMMUNITY HEALTH, UNIVERSITY OF MILAN, ITALY; (c) DEPARTMENT OF PHARMACOLOGICAL AND BIOMOLECULAR SCIENCES "RODOLFO PAOLETTI", UNIVERSITÀ DEGLI STUDI DI MILANO, MILAN, ITALY

Background. Several closure devices are routinely used for percutaneous arterial access while a relative low number is available for the management of large bore venous accesses. The Woggle technique is a modification of the purse string suture which was introduced several years ago in patients undergoing haemodialysis.
Methods. A population of 45 patients who underwent transvenous femoral structural heart interventions was retrospectively evaluated to assess the feasibility and safety of the Woggle technique. The Woggle technique consists of a purge string suture with a collar to maintain the tension stable over time and a suture lock to tighten the suture.
Results. Sheaths magnitude ranged from 8 French (F) to 14 F. A rapid post procedural haemostasis was achieved in the whole population and in the 95% of cases definitive haemostasis was obtained after the first single release; mean time of release was 302±83min. Although no relevant bleedings were reported, a significant reduction in hemoglobin levels was found in the whole population. This decrement was statistically significant only in the group with sheaths higher than 12 F. A single mild local hematoma was recorded in the group in which smaller sheaths were used. Seventy-two % of patients were pre-treated with a dual antiplatelet therapy.
Conclusions. Woggle technique has shown to be a simple, effective, and safe approach for the management of large bore venous in percutaneous structural heart interventions.



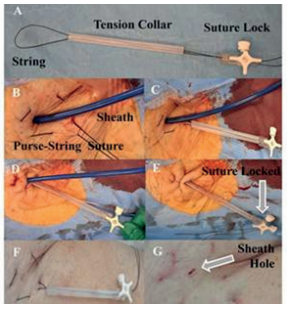

A370: DCB IN HIGHLY CALCIFIED LESIONS

Francesco Gioia (a, b), Latini Alessia Chiara (a, b), Mauro Gitto (a, b), Angelo Oliva (a, b), Laura Novelli (a, b), Damiano Regazzoli (a, b), Ottavia Cozzi (a, b), Antonio Mangieri (a), Francesco Tartaglia (a, b), Giulio Stefanini (a, b), Bernhard Reimers (a), Antonio Colombo (a), Alessandro Sticchi (a, b)
(a) HUMANITAS REASEARCH HOSPITAL; (b) HUMANITAS UNIVERSITY

Background. the use of drug coated balloons (DCBs) during angioplasty is steadily increasing in daily practice. The role of calcified lesions on DCB failure is still largely unknown due to lack of large cohort studies or limited follow-up time.
Aim. We aim to explore the potential role of significant calcifications on DCB failure at mid- and long-term follow-up.
Study design. We reported the single-centre data from a tertiary CathLab centre in Northern Italy with a dedicated experience in percutaneous coronary intervention (PCI) with DCB. Data were collected between May 2018 and September 2022. Only significant calcifications (defined as moderate or severe calcifications at angiographic evaluation) were collected.
Outcomes and measures. The primary endpoint was the occurrence of MACE, defined as the composite of death from any cause, cardiovascular (CV) death, target vessel (TV) myocardial infarction (TVMI), TV revascularization (TVR) and target lesion revascularization (TLR). Secondary outcomes included any component of the primary outcome, a composite of CV death and TVMI, as well as any revascularization during follow-up. Clinical features at baseline and procedural characteristics were assessed to identify significant prognostic predictors.
Results. A total of 576 patients who had undergone a PCI using DCB during the study period were included. Mean age (SD) was 70.0 ± 10.0 years, 17.4% were female and 25.2% had an ACS as clinical presentation, of which 33.1% had an ST-elevation ACS (STE/ACS). Patients with significant calcified lesions were more often male (87.6% vs 80.3% p-value 0.049) and diabetic (45.3% vs 36.0%, p-value 0.03). As expected, lesion preparation with non-compliant balloons (73.3% vs 60.8%, p-value 0.005) and any debulking technique (46.4% vs 5.8%, p-value <0.0001) and use of intravascular imaging (35.4% vs 16.7%, p-value <0.001) were more frequent with calcified as compared with non-calcified lesions. After a median follow-up of 229 (1-582) days, the primary endpoint occurred in 32 patients with significant calcification (19.9%) as compared with 51 patients in the control group (12.3%).

A371: CASE REPORT: UNA TUMEFAZIONE TARDIVA DI TASCA

Maria Francesca Massara (a), Paolo Tofoni (a), Giulia Stronati (a), Michela Casella (a), Federico Guerra (a), Antonio Dello Russo (a)
(a) UNIVERSITÀ POLITECNICA DELLE MARCHE

Case report. Uomo, 85 anni. Ricovero nel 2013 presso la Cardiologia Ancona per il riscontro di severa disfunzione ventricolare sinistra (FE 30%). In anamnesi esiti di lobectomia polmonare (2005).

- ECG: PR 220 msec, BBSn
- CGR: ndr.
- LAB: Hb 15 g/dl, PLT 229/mm3, Creatinina 1.1 mg/dl, Glicemia 84 mg/dl.
- Ecocardiogramma: severa dilatazione del VSX (VTDVS 105 ml/m2) e severa riduzione della FEVS per ipocinesia diffusa. Esame strain per eventuale impianto CRTD: non asincronia intraventricolare.

Si procedeva a impianto di ICD monocamerale in prevenzione primaria in sede sottoclaveare sx (profilassi antibiotica ciprofloxacin 1 g). Effettuato RX che mostrava corretto posizionamento dell'elettrocatetere, non PNX. Il paziente veniva dimesso con antibioticoterapia (Ciproxin 500 mg x7 die). Da allora ha proseguito il follow-up cardiologico con regolarità (visita cardiologica+controllo dell'ICD semestrale). Da segnalare introduzione nel 2020 di NAO per il riscontro di fibrillazione atriale (Rivaroxaban 20 mg). A dicembre 2021 l'ultimo controllo dell'ICD: non seventi aritmici, non alterazioni dei parametri elettrici, buone condizioni della tasca. Il 09.01.22 accesso al PS per la comparsa di tumefazione teso-elastica della tasca. Apiretico. Il medico del PS effettuava ecografia cutanea(versamento sottocutaneo non trabecolato) e procedeva ad aspirazione di 15 cc di liquido siero-ematico. Dimetteva il paziente con appuntamento presso gli Ambulatori PM. Non effettuata consulenza cardiologica né esami ematochimici. Il 19.01.22 il paziente si presentava ai nostri Ambulatori: voluminosa tumefazione teso-elastica dei tessuti molli sovrastanti la tasca, che risultava flottante. Non flogosi locale o sofferenza ischemica cutanea. Non soluzioni di continuità della cute. Non dolore. Riferiva inoltre di non aver assunto l'antibiotico prescritto. Negava febbre o traumi nelle settimane precedenti. Non essendo stati eseguiti gli esami ematochimici in PS non noto l'emocromo (Hb? WBC?), la funzione renale (sovradosaggio di Rivaroxaban?), gli indici di flogosi (PCR? PCT?), la funzione coagulativa (INR spontaneo?). Veniva programmato ricovero urgente per revisione chirurgica, decompressione della tasca, esecuzione di tampone colturale ed emocolture.
Conclusioni. Le ipotesi sono ematoma in corso di NAO, infezione di tasca o igroma cistico. In sede di revisione della tasca: evidenza di ematoma organizzato dei tessuti adiacenti alla tasca. Colturale di tasca ed emocolture negative.

A372: TAILORING DEVICE SELECTION FOR PATENT FORAMEN OVALE (PFO) CLOSURE: A CLINICAL CASE STUDY ON COMPLEX SEPTAL ANATOMY

Sarah Ragonese (a), Federica Leotta (a), Claudio Sanfilippo (a), Alessandra Licciardello (a), Carmelo Grasso (a), Davide Capodanno (a), Corrado Tamburino (a), Maria Elena Di Salvo (a)
(a) CENTRO ALTE SPECIALITÀ E TRAPIANTI (CAST) - POLICLINICO UNIVERSITARIO G.RODOLICO - SAN MARCO DI CATANIA

Rationale. This clinical case aims to illustrate the importance of proper device selection tailored on the anatomical characteristics of Patent Foramen Ovale (PFO).
Technical resolution. The use of intracardiac echocardiography can help in evaluating complex anatomy (in this case, accessory septum inserted in foramen ovale, cribriform interatrial septum, short rim) while avoiding general anesthesia, allowing better device selection.
Clinical implications. Proper anatomical evaluation may allow to choose a device with high radial force, thus allowing effective closure of the foramen ovale and, in the same time, great flexibility and adaptability respecting interatrial septum's anatomy. This aspect is essential to guarantee optimal procedural outcomes.
Perspectives. Future advances in device and delivery techniques is widening the landscape of available therapeutics for PFO, accounting for anatomical characteristics of the patient that allows for tailored selection of the device, further improving clinical and technical outcomes.

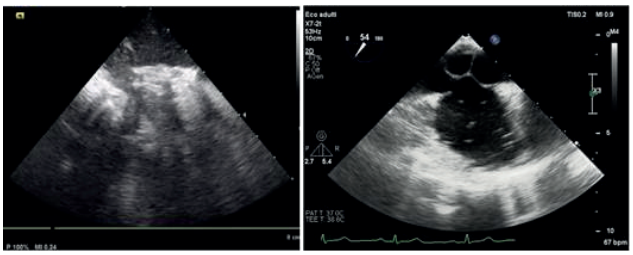

A373: ANGIOPLASTICA DI TRONCO COMUNE IN PAZIENTE CON NSTEMI E PATOLOGIA VALVOLARE

Davide D'Andrea (a), Gerardo Carpinella (a), Alessandro Bellis (a), Valentina Capone (a, b), Aniello Di Donato (a), Fulvio La Rocca (a), Dario Prozzo (a), Federica Serino (a), Vittorio Taglialatela (a), Fulvio Furbatto (a), Ciro Mauro (a)
(a) DEPARTMENT OF CARDIOLOGY, "A. CARDARELLI" HOSPITAL, NAPLES; (b) DEPARTMENT OF ADVANCED BIOMEDICAL SCIENCES, FEDERICO II UNIVERSITY HOSPITAL, NAPLES, ITALY

I progressi nell'ambito dell'interventistica cardiaca comportano sempre più frequenti accessi ospedalieri, sia tramite Pronto Soccorso che lista d'attesa, di pazienti portatori di diversi dispositivi di nuova generazione. Il caso che presentiamo riguarda un maschio di 78 anni, ricoverato presso la nostra U.O.C. con diagnosi di NSTEMI, affetto da diabete mellito tipo II, IRC III stadio, fibrillazione atriale permanente, HFrEF post-ischemico (FE 25%), pregressa sostituzione valvolare aortica per via percutanea (TAVI) e riparazione mitralica percutanea tramite sistema Pascal, portatore di CRT-D. Il quadro angiografico ha evidenziato: "stenosi critica del tronco comune paraostiale e del primo ramo MO di piccolo calibro e stenosi critica di IVP di coronaria destra in territorio fibrotico, con buon funzionamento a distanza di pregresse angioplastiche di arteria discendente anteriore e ramo circonflesso". Esclusa l'opzione cardiochirurgica in virtù dell'elevato rischio ad essa associato e della presenza di stent impiantati fino ai tratti distali dei vasi coronarici, si è optato dopo discussione in Heart Team per tentativo di angioplastica su tronco comune seguita da triplice terapia antitrombotica della durata di una settimana comprendente ASA, Clopidogrel e DOAC, per poi proseguire con il solo P2Y12 inibitore associato all'anticoagulante orale. La procedura ad elevato rischio presenta l'ulteriore difficoltà data dalla presenza di una valvola aortica biologica autoespandibile che, può rendere impervio l'accesso agli osti coronarici. Si è optato per un accesso femorale 6 Fr con cannulazione selettiva dell'ostio del TC mediante catetere guida Judkins 4.0, che ci ha consentito di accedere agevolmente alla sede di lesione ed ottenere una ottimale visualizzazione della stessa per il corretto posizionamento dello stent. Dopo predilatazione con pallone semicompliante 2.5 x 12 mm, si è proceduto ad impianto di stent medicato a rilascio di zotarolimus 3.5 x 8 mm, scelto in virtù dell'elevato rischio emorragico del paziente, postdilatato con pallone non compliante 3.75 mm con buon risultato finale. L'utilizzo di device di assistenza ventricolare, che normalmente deve essere preso in considerazione nei casi di angioplastica complessa in pazienti con severa riduzione della frazione di eiezione, non è stato possibile a causa concomitante presenza di valvola aortica artificiale e clip mitralica, le quali avrebbero potuto interferire con il corretto posizionamento e funzionamento di un eventuale VAD percutaneo. Casi come questo sono sempre più frequenti, quale risultato della più vasta platea di pazienti candidabili a TAVI ed in generale della più ampia disponibilità di devices intracardiaci per le più svariate patologie (valvolari, coronariche, aritmologiche etc.). A ciò si aggiunge naturalmente la nota relazione tra aumento dell'aspettativa di vita e la prevalenza di multiple patologie croniche, come nel caso del nostro paziente. È dunque fondamentale per il cardiologo interventista sapersi approcciare a tali nuove casistiche mediante l'aggiornamento e la formazione continui, che comprendano la perfetta conoscenza dei nuovi dispositivi immessi sul mercato, del loro utilizzo e dell'impatto che essi possono avere in eventuali procedure interventistiche successive. Inoltre, la procedura di angioplastica su tronco comune rappresenta una sfida complessa per ogni operatore ed è dunque importante che essa venga effettuata in centri con elevata expertise nel campo. A ciò va accompagnato un corretto inquadramento del paziente fragile e/o portatore di patologie multiple, al fine di poterne individualizzare ed ottimizzare il trattamento.

A374: UNO STEMI COMPLICATO: IN EQUILIBRIO TRA TROMBOSI ED EMORRAGIA

Rosanna Di Fonzo (a), Basilio Palumbo (b), Francesco Paolo Cancro (a), Sara Turino (a), Francesco Loria (a), Gennaro Galasso (a), Carmine Vecchione (a, c), Michele Roberto Di Muro (b), Lucia Soriente (b)
(a) DIPARTIMENTO DI MEDICINA E CHIRURGIA, UNIVERSITÀ DEGLI STUDI DI SALERNO; (b) U.O. CARDIOLOGIA INTENSIVA, A.O.U. "SAN GIOVANNI DI DIO E RUGGI D'ARAGONA", SALERNO; (c) UNITÀ DI FISIOPATOLOGIA VASCOLARE, IRCCS NEUROMED, POZZILLI (IS)

L'introduzione di terapie antitrombotiche più efficaci e potenti ha consentito la progressiva riduzione degli eventi ischemici associata tuttavia ad un aumento degli eventi emorragici. Quello che descriviamo è l'esempio di come le complicanze, iatrogene e non, possano sommarsi rendendo difficoltosa la routinaria gestione terapeutica durante e dopo la degenza ospedaliera. Parliamo di un paziente di sesso maschile, di 50 anni, tabagista e con anamnesi di dislipidemia in trattamento, che giungeva al nostro cath-lab con diagnosi di SCA-STEMI anteriore, dopo carico di ticagrelor 180 mg dal centro spoke dove si era recato per dolore toracico. Alla coronarografia, evidenza di malattia critica di arteria interventricolare anteriore media trattata mediante angioplastica primaria e per l'elevato carico trombotico mediante tromboaspirazione, impianto di DES e Tirofiban in bolo ed infusione continua di 18 ore. A 15 ore circa dall'evento, il paziente appariva confuso e afasico per cui veniva praticata TC encefalo con e senza mezzo di contrasto che documentava la presenza di un focolaio emorragico in sede atipica temporale sinistra, in assenza di malformazioni artero-venose non suscettibile di terapia chirurgica (BARC-3). In considerazione dell'elevato rischio emorragico, quindi, veniva praticata de-ecalation terapy a Cardioaspirina e Clopidogrel. A cinque giorni dall'evento, a complicare nuovamente il quadro clinico, è stato il riscontro, all'eco transtoracico di trombosi apicale. Per tale motivo, vista la stabilità della lesione emorragica alle TC e alla RMN di controllo, è stata introdotta in terapia Enoxaparina sodica 4000 UI in monosomministrazione, con risoluzione della formazione al controllo imaging ad un mese. Il paziente è stato quindi dimesso con indicazione a short-DAPT in considerazione dell'elevato PRECISE-DAPT score. L'arduo compito di gestire questo caso, ci ha portati a riflettere sull'importanza dell'inquadramento clinico del paziente pre e post PCI per ricercare l'adeguato trattamento antitrombotico bilanciando, in maniera dinamica durante la degenza, il rischio ischemico ed emorragico mediante i numerosi strumenti standardizzati a nostra disposizione.

CARDIO-ONCOLOGIA E CARDIO-TOSSICITÀ

A375: SGLT2I DAPAGLIFLOZIN DECREASES SYSTEMIC LEVELS OF NLRP3, IL-1 AND PCSK9 IN PRECLINICAL MODELS OF DOXORUBICIN CARDIOTOXICITY

Vincenzo Quagliariello (a), Maria Canale (d), Irma Bisceglia (a), Giuseppe Palma (b), Antonio Luciano (b), Francesca Bruzzese (b), Carlo Maurea (c), Andrea Paccone (e), Martina Iovine (e), Vienna Giordano (e), Nicola Maurea (e)
(a) DIVISION OF CARDIOLOGY, OSPEDALE SAN CAMILLO ROMA; (b) ANIMAL FACILITY, ISTITUTO NAZIONALE TUMORI-IRCCS-FONDAZIONE G.PASCALE OF NAPLES; (c) OSPEDALE DEL MARE OF NAPLES; (d) UOC CARDIOLOGIA, OSPEDALE DI VERSILIA, LIDO DI CAMAIORE; (e) DIVISION OF CARDIOLOGY, ISTITUTO NAZIONALE TUMORI-IRCCS-FONDAZIONE G PASCALE OF NAPLES

Background. Anthracyclines are an effective and widely used chemotherapy agent in the treatment of multiple solid organ tumors and hematologic malignancies. The use of anthracyclines as a standard cancer therapy is limited by the potential for the development of cardiac dysfunction, arrhythmias, and clinical heart failure. In recent five years, it was demonstrated that proprotein convertase subtilisin/kexin type 9 (PCSK9), a lipid metabolism-related protein, is a key orchestrator of immune infiltration in myocardial and cancer tissues and could regulate cardiac fibrosis and inflammation. PCSK9 is a protein with key roles in hepatic low density lipoprotein (LDL) homeostasis. PCSK9 systemic levels are associated to HOMA score and high insulin levels. Dapagliflozin exerts systemic ant-inflammatory properties and cardioprotective effects in diabetic and non-diabetic patients.
Purpose. We hypothesized that Dapagliflozin, administered during doxorubicin, could reduce PCSK9 systemic levels in preclinical models.
Methods. Female C57Bl/6 mice were untreated (Sham, n=6) or treated for 10 days with doxorubicin i.p at 2.17 mg/kg (DOXO, n=6), DAPA at 12 mg/kg (DAPA, n=6) or doxorubicin combined to DAPA (DOXO-DAPA, n=6). After treatments, plasma levels of PCSK9, IL-1β and CRP were

analyzed through selective anti-mouse ELISA methods. Myocardial and liver expression of NLRP3-inflammasome and IL-1β were analyzed through ELISA method in tissue lysates after treatments.
Results. DAPA associated to DOXO reduces significantly systemic levels of PCSK9 (-37,5% vs DOXO group, p<0,001). IL-1β and CRP levels were also reduced (-47,3 and – 28,5%, respectively; p<0.05 for both). Myocardial and liver IL-1β and NLRP3 inflammasome expression were also reduced in DAPA/DOXO group vs DOXO and control, indicating beneficial metabolic and anti-inflammatory effects of SGLT2i.
Conclusions. DAPA has been shown to reduce systemic levels of PCSK9 in preclinical models of short-term DOXO cardiotoxicity. To the best of our knowledge, this is the first evidence of SGLT-2/PCSK9 crass-talk in cardioncology therefore the overall picture of the study open a new window on the beneficial properties of DAPA against anthracyclines side effects.

A376: POLYDATIN AND PEA EXERTS VASCULOPROTECTIVE PROPERTIES AGAINST DOXORUBICIN-TRASTUZUMAB THERAPY AND CTLA-4/PD-1 BLOCKING AGENTS THROUGH MYD-88 AND NLRP3 PATHWAYS

Andrea Paccone (a), Vincenzo Quagliariello (a), Martina Iovine (a), Ilaria Giacobbe (a), Francesca Izzo (a), Matteo Barbato (a), Raffaele Arianna (a), Vienna Giordano (a), Alessia Merola (a), Francesco Ingenito (a), Fabrizio Maurea (b), Nicola Maurea (a)
(a) DIVISION OF CARDIOLOGY, ISTITUTO NAZIONALE TUMORI-IRCCS-FONDAZIONE G PASCALE; (b) OSPEDALE DEL MARE

Introduction. Palmitoylethanolamide (PEA) is an endogenous fatty acid mediator that is synthetized from membrane phospholipids by N–acyl phosphatidylethanolamine phospholipase D. It is a new analgesic drug with anti–inflammatory effects through the induction of PPAR–related pathways.
Purpose. We aimed to assess whether palmitoylethanolamide and polydatin complex co–incubated during doxorubicin and trastuzumab or immune checkpoint inhibitors (CTLA-4/PD-1 blocking agents), reduces vasculotoxicity in cellular models.
Methods. Human vascular endothelial cells and cardiomyocytes were exposed to subclinical concentration of doxorubicin (at 100 and 200 nM) combined to trastuzumab (at 100 and 200 nM) or CTLA-4 associated to PD-1 blocking agents at 100 nM and 200 nM, alone or in combination with a formulation composed by palmitoylethanolamide and polydatin (500 nM) for 48h. After the incubation period, we performed the following tests: determination of cell viability, through analysis of mitochondrial dehydrogenase activity, study of lipid peroxidation (quantifying cellular Malondialdehyde and 4–hydroxynonenal), intracellular Ca2+ homeostasis. Moreover, pro–inflammatory studied were also performed (activation of NLRP3 and MyD88; expression of peroxisome proliferator–activated receptor–α; mTORC1 Fox01/3a; transcriptional activation of p65/NF–κB and secretion of cytokines involved in cardiotoxicity (Interleukins 1β, 8, 6).
Results. Palmitoylethanolamide/polydatin co–incubated with doxorubicin-trastuzumab or CTLA-4/PD-1 blocking agents exerts vasculoprotective effects, enhancing cell viability compared to untreated cells (p<0,001 for all). Notably, PEA/polydatin reduced significantly the vasculotoxicity through peroxisome proliferator–activated receptor–α –related pathways, MyD-88 and NLRP3 inflammasome but without the involvement of calcium homeostasis. Several cytokines and chemokines were also reduced confirming its anti–inflammatory effect.
Conclusions. The present study demonstrates that palmitoylethanolamide/polydatin protects against vasculotoxicity induced by doxorubicin/trastuzumab therapy as well as by combined immune checkpoint inhibitors, by promoting an anti–inflammatory phenotype, representing a new therapeutic approach in cardioncology.

A377: CARDIO-TOX: A PILOT PROOF OF CONCEPT STUDY OF ACUTE CARDIOTOXICITY AND INFLAMMATION IN ADULT PATIENTS TREATED WITH CHIMERIC ANTIGEN RECEPTOR-T (CAR-T) CELLS.

Tamara Felici (a), Massimiliano Camilli (a), Giulia Coarelli (a), Luca Maggio (a), Antonio Di Renzo (a), Lorenzo Tinti (a), Federico Ballacci (a), Antonella Lombardo (a), Priscilla Lamendola (a), Rocco Antonio Montone (a), Gaetano Antonio Lanza (a), Filippo Crea (a), Giacomo Carella (a), Giorgio Minotti (b)
(a) DEPARTMENT OF CARDIOVASCULAR DISEASE, FONDAZIONE POLICLINICO UNIVERSITARIO A. GEMELLI IRCCS, UNIVERSITÀ CATTOLICA DEL SACRO CUORE, ROME, ITALY; (b) UNIVERSITÀ E FONDAZIONE POLICLINICO UNIVERSITARIO CAMPUS BIO-MEDICO, ROME, ITALY

Aims. Chimeric Antigen Receptor-T (CAR-T) cell infusion is a rapidly evolving antitumor therapy; however, cardiovascular (CV) complications, likely associated with cytokine release syndrome (CRS) and systemic inflammation, have been reported to occur. The CARdio-Tox study aimed at elucidating incidence and manifestations of cardiotoxicity of CAR-T cell therapy.
Methods and Results. Patients with blood malignancies candidate to CAR-T cells were prospectively evaluated by echocardiography at baseline, 7 days and 1 month after infusion. The study endpoints were i) incidence of acute cardiotoxicity, defined according to 2022 ESC Cardio-Oncology Guidelines (decrements of left ventricular ejection fraction (LVEF) or global longitudinal strain (GLS) and/or elevations of cardiac biomarkers (high sensitivity troponin I, natriuretic peptides) and ii), correlations of echocardiographic metrics with inflammatory biomarkers. Incidence of cardiotoxicity was high at 7 days (59,3%), particularly in subjects with CRS. Early LVEF and GLS decrements were inversely correlated with fibrinogen and interleukin-2 receptor levels (p always ≤0.01). Moreover, while left ventricular systolic and filling metrics markedly worsened at 7 days (p<0.05 for all parameters), they showed a partial but significant recovery at 30 days (p for 30 versus 7 days: 0,009 for LVEF, 0,025 for GLS and 0,041 for left atrial reservoir strain).
Conclusions. The combination of echocardiography and serum cardiac biomarkers reveals a high incidence of cardiotoxicity in patients treated with CAR-T cells and monitored at different time points. This calls for dedicated patient monitoring protocols.

A378: RISOLUZIONE TEMPESTIVA DI UNA SEVERA DISFUNZIONE VENTRICOLARE SINISTRA DA TOSSICITÀ TARDIVA DA PEMBROLIZUMAB

Silvia Festa (a, b), Ailia Giubertoni (a), Virginia Bolzani (a), Sara Bacchini (a), Luisa Airoldi (a), Alice Panizza (a), Lidia Rossi (a), Giuseppe Patti (a, b)
(a) A.O.U. MAGGIORE DELLA CARITÀ DI NOVARA; (b) UNIVERSITÀ DEGLI STUDI DEL PIEMONTE ORIENTALE "AMEDEO AVOGADRO"

Introduzione. La tossicità da inibitori dei check-point è una condizione conosciuta che solitamente si presenta nei primi mesi dopo l'inizio della terapia. Descriviamo il caso di una donna che ha manifestato una tossicità acuta severa dopo più di sei mesi dall'avvio di pembrolizumab.
Caso clinico. Una donna di 53 anni, senza alcun fattore di rischio cardiovascolare, accedeva al pronto soccorso lamentando dolore toracico trafittivo. Presentava inoltre un quadro di mastite acuta destra con febbre in esiti di mastectomia omolaterale per un carcinoma multifocale della mammella. La paziente era in terapia adiuvante con pembrolizumab da due mesi come terapia di mantenimento, in assenza di secondarismi di malattia o recidive locali. Il pembrolizumab era stato avviato otto mesi prima come terapia neoadiuvante prima dell'intervento di mastectomia (insieme a carboplatino e paclitaxel) e poi era stato mantenuto come farmaco adiuvante in monoterapia. All'arrivo in pronto soccorso la paziente era normotesa, febbrile e l'ECG mostrava tachicardia sinusale in assenza di alterazioni della ripolarizzazione. Agli esami ematici si evidenziava un lieve aumento della troponina I pari a 62 ng/L (v.n. <40 ng/L) e un aumento importante degli indici di flogosi (PCR 27 mg/dL). All'emogasanalisi è stata riscontrata un'insufficienza respiratoria, e lieve aumento dei lattati (lattati 3.5 mmoli/L) indicativi di iniziali segni di ipoperfusione periferica. All'ecocardiogramma si evidenziava un ventricolo sinistro con estesa acinesia dei segmenti medio-apicali con ipocinesia dei restanti segmenti condizionante importante scadimento della funzione contrattile globale e della portata cardiaca (FE 10%, LVOT VTI 10cm). Anche il ventricolo destro presentava contrattilità ridotta (TAPSE 11mm, S' 7cm/sec) e vi era un lieve versamento pericardico non emodinamicamente significativo; non si riscontravano valvulopatie di rilievo. Nel sospetto di miocardite immuno-mediata la paziente veniva trasferita in terapia intensiva cardiologica, dove veniva avviata ventilazione non invasiva con HFNC e terapia immunosoppressiva con steroidi endovenosi ad alte dosi, oltre alla terapia per lo scompenso cardiaco e a quella antibiotica per la mastite. Nei giorni successivi si è evidenziato un rapido miglioramento delle condizioni cliniche della paziente associato ad un progressivo recupero della funzionalità biventricolare. A completamento è stata eseguita una risonanza magnetica cardiaca a stabilizzazione del quadro clinico, che ha confermato il completo recupero della funzionalità biventricolare e l'assenza di pattern patologici. La paziente veniva quindi dimessa a domicilio e al controllo ad 1 mese dopo la dimissione l'ecocardiogramma confermava il completo recupero della funzionalità sistolica biventricolare.
Discussione. La miocardite autoimmune da inibitori del check point spesso ha un'insorgenza repentina ed il suo riconoscimento può non essere immediato ma entrare in diagnosi differenziale con altre patologie, come, nel caso presentato, la sindrome di Tako-Tsubo o la miocardiopatia da sepsi. Inoltre, a differenza di quanto riportato in letteratura, la tossicità da inibitori dei check-point solitamente avviene entro i primi due mesi di trattamento, mentre nella nostra paziente la tossicità si era manifestata dopo più di sei mesi dall'avvio. Nel nostro caso, il quadro clinico ha permesso di instaurare comunque una corretta diagnosi, confermata poi dalla rapida e completa risoluzione dopo l'avvio della terapia steroidea.

A379: IBRUTINIB RELATED CARDIOTOXICITY: ROLE OF ECHOCARDIOGRAPHIC EVALUATION

Vittoria Gammaldi (a), Martina Pucci (a), Luca Maria Capece (a), Adelaide Iervolino (a), Velia Iadevaia (a), Daniele Paoletta (a), Marina Iacono (a), Roberta Esposito (a)
(a) DEPARTMENT OF CLINICAL MEDICINE AND SURGERY, FEDERICO II UNIVERSITY, NAPLES

Background. Ibrutinib is a Bruton tyrosine kinase inhibitor, approved in the last few years for treatment as primary option for all subsets of chro-

nic lymphocytic leukemia (CLL). Its use is associated with increased incidence of atrial fibrillation (AF), and other cardiotoxicities.
Aims. Aim of the study is to determine whether there are echocardiographic parameters that could identify patients at major risk of developing ibrutinib-related atrial fibrillation (IRAF), and if there are any changes of those parameters at follow-up evaluation at six months.
Methods. We performed a retrospective review of 33 patients (mean age 70,59 ± 11,82; 31% females), admitted at our EchoLab in the last year, who underwent echocardiogram prior to Ibrutinib treatment. Then, we performed a prospective review of twenty-three patients out of the thirthy-three evaluated at baseline, admitted at our EchoLab six-months after starting therapy with Ibrutinib. Echo-Doppler assessment was realized according to the standards of the European Association of Cardiovascular Imaging (EACVI) standardization of the echo report. Left atrial (LA) strain was measured with EchoPAC, obtaining peak atrial longitudinal strain (PALS) and peak atrial contraction strain (PACS) on 4-chambers and 2-chambers views. Continuous normally distributed variables were compared by using the Student t-test. A probability value <0,05 was considered statistically significant. Analyses were performed with SPSS version 25 (IBM Corporation, Somers, New York).
Results. Last year we evaluated thirthy-three patients with echocardiogram prior Ibrutinib treatment. We found that seven of these developed atrial fibrillation (AF). Those patients had peculiar echocardiographic characteristics compared to the control group: they had lower ejection fraction (EF) (54,71 ± 1,79 vs 60,07 ± 4,30, p-value: 0,000), higher left atrium volume index (49,81 ± 15,06 vs 34,01 ± 9,29, p-value: 0,032), higher pulmonary arterial pressure values (PAPs) (43,00 ± 10,73 vs 32,11 ± 8,32, p-value: 0,037). It was noticed also that peak atrial longitudinal strain (PALS) and peak atrial contraction strain (PACS) were reduced in patients who developed IRAF (PALS 4Ch: 16,90 ± 7,45 vs 29,17 ± 11,14, p-value 0,015; PACS 4Ch: 9,10 ± 5,90 vs 14,37 ± 5,56, p-value: 0,120; PALS 2Ch: 20,15 ± 8,39 vs 29,58 ± 15,40, p-value: 0,83; PACS 2Ch: 11,54 ± 8,45 vs 16,45 ± 9,01, p-value: 0,28). Furthermore, it was noticed that PALS4 was statistically significant (p value: 0,015). Out of those thirthy-three patients, twenty-three came back to our EchoLab for follow-up after six months. We noticed that they did not have any worsening of the echocardiographic variables studied at basal evaluation. It was noticed also that peak atrial longitudinal strain (PALS) and peak atrial contraction strain (PACS) mantained a steady level between follow-up and basal measurement: (PALS 4Ch: 23,81 ± 8,59 vs 25,49 ± 10,83, p-value: 0,669; PACS 4Ch: 11,93 ± 5,21 vs 13,25 ± 4,47, p-value: 0,477; PALS 2Ch: 26,05 ± 11,12 vs 29,05 ± 17,27; p-value: 0,616; PACS 2Ch: 14,36 ± 6,14 vs 14,94 ± 9,18, p-value: 0,863).
Conclusions. In the first analysis we made a stratification of the patients who had major predisposition to develop ibrutinib-related atrial fibrillation (IRAF). Now, we have the first results on echocardiogram at six months follow-up. We noticed that none of the echocardiographic parameters studied before worsened or were statistically significant, especially PALS and PACS which have a pivotal role in the stratification of patients at risk for IRAF. This underlies what we already stated in the first study. We need to emphasize one more time the importance of baseline evaluation by echocardiogram including measurement of atrial strain of patients before starting treatment with Ibrutinib. The fact that PALS and PACS do not reduce at follow-up is fundamental, because it tells us that ibrutinib doesn't worsen atrial remodeling, so patients could continue therapy despite IRAF. Pharmacological intervention tailored on each patient could allow the preservation of cardiac function and improve patient outcomes in the long term.

A380: ROLE OF EARLY LEFT ATRIAL FUNCTIONAL DECLINE IN PREDICTING CARDIOTOXICITY IN HER2 POSITIVE BREAST CANCER PATIENTS TREATED WITH TRASTUZUMAB

Ilaria Minnucci (a), Corinna Bergamini (a), Laura Trento (a), Paolo Springhetti (a), Lorenzo Niro (a), Chiara Nannelli (a), Elvin Tafciu (a), Caterina Maffeis (a), Giovanni Benfari (a), Andrea Rossi (a), Flavio Luciano Ribichini (a)
(a) AZIENDA OSPEDALIERA UNIVERSITARIA INTEGRATA VERONA

Background. Trastuzumab is widely used in HER2 breast-cancer. However, it may cause left ventricular (LV) dysfunction. A decrease in LV global longitudinal strain (GLS) has been previously demonstrated to be a good predictor of subsequent cancer therapy related dysfunction (CTRCD). Left atrial morphological remodeling during Trastuzumab therapy has also been shown. Nevertheless, limited data are available regarding left atrial function in this clinical setting. The aim of this study is exploring the relationship between early changes in left atrial function and the development of Trastuzumab-induced cardiotoxicity.
Methods. Consecutive patients with diagnosis of HER2+ non-metastatic breast cancer treated with Trastuzumab were prospectively enrolled. A clinical, conventional, and advanced echocardiographic assessment was performed at baseline and every three months, until a one-year follow-up was reached.
Results. One-hundred-sixteen patients completed the 12 months follow-up, 10 (9%) cases of CTRCD were observed, all after the sixth month. GLS and LVEF significantly decreased in the CTRCD group at 6 months of follow up, with an earlier (3 months) significant worsening in left atrial morpho-functional parameters. Systolic blood pressure, early peak atrial longitudinal strain (PALS) and left atrial volume (LAVI) changes resulted independent predictors of CTRCD at multivariable logistic regression analysis. Moreover, the early variation of PALS presented a good AUC (0.86 ± 0.08, p=0.001) in identifying patients who developed future CTRCD at ROC analysis.
Conclusions. Early PALS decline in patients undergoing trastuzumab could possibly increase the accuracy in identifying future CTRCD in non-metastatic HER2 breast cancer patients, adding predictive value to conventional echocardiographic assessment.

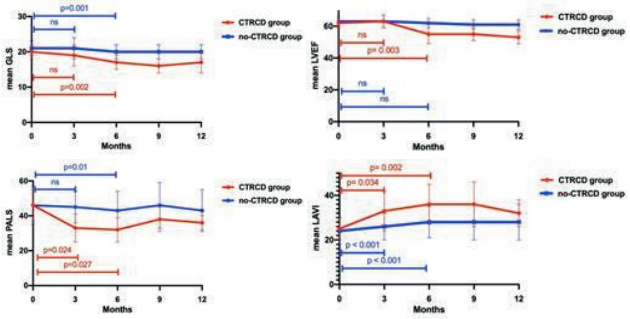

A381: DIFFERENZE LEGATE AL GENERE NELLA CARDIOTOSSICITÀ INDOTTA DA INIBITORI DELLE TIROSIN CHINASI IN PAZIENTI CON LEUCEMIA MIELOIDE CRONICA

Cristina Madaudo (a), Daniela Di Lisi (a), Fulvia Giannola (a), Antonino Gulotta (a), Luca Di Fazio (a), Aurelia Bono (a), Giuseppe Bosco (a), Angela Pilade (a), Saverio Coppola (a), Vincenzo Sucato (a), Egle Corrado (a), Alfredo Ruggeri Galassi (a), Giuseppina Novo (a)
(a) UOC DI CARDIOLOGIA - DIPARTIMENTO PROMISE, POLICLINICO UNIVERSITARIO "PAOLO GIACCONE" - UNIVERSITÀ DEGLI STUDI DI PALERMO

Background. Numerose patologie in ambito cardiologico mostrano delle differenze tra i due sessi nella prevalenza, nel decorso clinico, nell'approccio terapeutico e nella prognosi. Il campo della cardio-oncologia è vario e dinamico con nuove terapie oncologiche e cardiovascolari approvate ogni anno; tuttavia, la conoscenza degli effetti del genere in cardio-oncologia è limitata, in particolare dell'impatto del genere sulle cardiotossicità. Questo studio retrospettivo si pone come obiettivo quello di valutare l'influenza delle differenze di genere sull'incidenza di cardiotossicità con la finalità di promuovere un nuovo approccio alla gestione del paziente cardioncologico, che ponga una maggiore importanza alle differenze determinate dal sesso e dal genere.
Metodi. Lo studio ha arruolato 148 pazienti (età media di 58 ± 14.2 anni), di cui 66 donne e 82 uomini con la diagnosi di leucemia mieloide cronica (LMC) in trattamento con inibitori delle tirosin chinasi (TKIs). È stata eseguita la valutazione cardiologica ed è stato stimato il rischio cardiovascolare con lo strumento di valutazione del rischio proposto da HFA/ICOS. Sono stati registrati gli eventi avversi cardiovascolari durante il trattamento con TKis.
Risultati. Secondo la classificazione del rischio HFA/ICOS, rispettivamente, il 26% dei pazienti erano a rischio molto alto, il 28% a rischio alto, il 21% a rischio intermedio ed il 24% a rischio basso. Lo score HFA/ICOS è risultato essere un buon predittore degli eventi cardiovascolari, infatti, gli eventi avversi globalmente sono stati significativamente più frequenti nel gruppo a rischio molto alto ed alto. Non vi sono differenze statisticamente significative nell'incidenza di eventi globali tra uomini e donne, con una tendenza d'incidenza leggermente più alta nel gruppo donne (29% vs 39%, p 0.686). L'incidenza di trombosi arteriosa durante la terapia era significativamente più alta nel gruppo degli uomini rispetto al gruppo di pazienti donne (23,3% vs 9%, p 0.0231). L'incidenza di trombosi venosa durante la terapia era significativamente più alta nel gruppo delle donne rispetto al gruppo di pazienti uomini (6% vs 0%, p 0.0238). Non vi erano differenze statisticamente significative per l'incidenza di ipertensione arteriosa e polmonare durante il trattamento (p 0.320, p 0.051). Per quanto riguarda il gruppo donne, fattori cardiovascolari quali ipertensione arteriosa, dislipidemia mista e diabete mellito erano i maggiori predittori di eventi. Per quanto riguarda il gruppo uomini, l'ipertensione arteriosa, la dislipidemia mista e le precedenti terapie con altri TKis erano i maggiori predittori di eventi.
Conclusioni. Lo studio conferma che esistono differenze di genere nell'incidenza di eventi cardiotossici. Sebbene non siano state riscontrate differenze nell'incidenza di eventi globale tra i due gruppi, la trombosi arteriosa è stata più frequente nel gruppo degli uomini mentre gli eventi di tromboembolismo venoso si sono manifestati più frequentemente nel gruppo delle donne. Lo score HFA/ICOS ha dimostrato di predire bene l'insorgenza di eventi cardiotossici. I fattori cardiovascolari quali ipertensione arteriosa e la dislipidemia mista sono stati i maggiori predittori di eventi in entrambi i gruppi. Un approccio di genere nella pratica clinica può contribuire notevolmente alla promozione della salute tramite un miglioramento dell'appropriatezza delle cure in grado

di produrre vantaggi sia per i malati, sia per la sostenibilità del Servizio sanitario nazionale (SSN).

A382: IMMUNE CHECKPOINT INHIBITOR-ASSOCIATED MYASTHENIA GRAVIS, MYOSITIS AND MYOCARDITIS OVERLAP SYNDROME: A CASE REPORT

Linda Piras (a), Michela Zuccanti (a), Giuliano Tocci (a), Maria Beatrice Musumeci (a), Emanuele Barbato (a), Luca Leonardi (a), Matteo Garibaldi (a), Giacomo Tini Melato (a), Allegra Battistoni (a)
(a) AZIENDA OSPEDALIERA UNIVERSITARIA SANT'ANDREA, ROMA

Immune-checkpoint inhibitors (ICIs) have emerged as a groundbreaking approach in modern oncology, demonstrating remarkable efficacy in the treatment of various advanced neoplasms. Nevertheless, the benefits of ICIs are counterbalanced by the emergence of immune-related adverse events (irAEs) which can manifest in multiple organ systems and often necessitate prompt intervention. An overlap syndrome characterized by concurrent myositis, myasthenia gravis and myocarditis following ICI therapy has been recently reported as a rare but potentially lethal complication. We present a case report of a 48-year-old female patient, a smoker, with a history of Hashimoto's thyroiditis. She was recently diagnosed with advanced non-oncogene-addicted lung adenocarcinoma with bilateral pulmonary and skeletal metastases. In November 2022, the patient initiated first-line treatment with Pemetrexed–Carboplatin (CBDCA)-Nivolumab-Ipilimumab (CheckMate 9LA regimen: Nivolumab 360 mg IV every 3 weeks + Ipilimumab 1 mg/kg IV every 6 weeks + platinum-based chemotherapy IV every 3 weeks for two cycles). Following a single administration, in December 2022 she was admitted to the Oncology Ward due to the onset of severe diplopia, ptosis, asthenia and myalgia. Brain MRI ruled out acute cerebral events, while blood tests revealed elevated transaminase, creatine-kinase (CK) and lactate dehydrogenase (LDH) levels. The electrocardiogram showed a widespread ST-segment elevation and HsTnI levels were notably elevated at 7369 pg/ml, leading to a diagnosis of myocarditis. Consequently, she was promptly transferred to the Cardiology Intensive Care Unit. Neurological evaluation confirmed persistent ptosis, a positive ice-pack test, severe ophthalmoparesis with multi-directional diplopia, dysarthria and intermittent dysphagia. Muscle biopsy revealed inflammatory myopathy with marked necrotizing features and autoimmune panel analysis showed positive anti- small ubiquitin-like modifier (SUMO) activating enzyme (anti-SAE1) and anti-threonyl (anti-PL-7) antibodies. A definitive diagnosis of myocarditis/myositis/myasthenia gravis overlap syndrome secondary to ICI therapy was established, leading to immediate treatment initiation with corticosteroids, pyridostigmine and IntraVenous ImmunoGlobulin (IVIG 25 g/day for 4 days), according to current guidelines. After discharge, the patient underwent neurological, oncological and cardiac follow-up. Upon blood tests normalization, in April 2023 she resumed chemotherapy with carboplatin (CBDCA) and pemetrexed (PEM). Cardiac MRI (April 2023) scans revealed minimal pericardial effusion at the basal level of the left ventricle, an extensive area of signal alteration in the inferolateral and anterolateral segments in T2-weighted sequences and a thin subepicardial distribution of LGE in the lateral and anterolateral segments. This case highlights three critical lessons. Firstly, clinicians should be vigilant about the potential occurrence of this life-threatening triad during ICI therapy. The emergence of symptoms related to any of the three conditions (myocarditis, myositis or myasthenia gravis) should prompt a comprehensive evaluation for the presence of the other two. Secondly, the effective management of the patient necessitates the collaboration of a multidisciplinary team, providing the best possible care for the patient. Lastly, close follow-up of patients is essential due to the still unknown long-term prognosis.

A383: COMBINATORIAL IMMUNE CHECKPOINT BLOCKADE INCREASES MYOCARDIAL SECRETION OF H-FABP, NT-PRO-BNP, NLRP3, INTERLEUKIN 1 AND 6: BIOCHEMICAL IMPLICATIONS IN CARDIONCOLOGY

Vincenzo Quagliariello (a), Margherita Passariello (b), Irma Bisceglia (c), Andrea Paccone (a), Alessandro Inno (d), Fabrizio Maurea (a), Rapuano Lembo (e), Lorenzo Manna (e), Martina Iovine (a), Maria Canale (f), Marino Scherillo (g), Paolo Ascierto (h), Domenico Gabrielli (c), Nicola Maurea (a)
(a) DIVISION OF CARDIOLOGY, ISTITUTO NAZIONALE TUMORI-IRCCS-FONDAZIONE G PASCALE OF NAPLES; (b) UNIVERSITY OF NAPLES, FEDERICO II; (c) SAN CAMILLO FORLANINI, DIVISION OF CARDIOLOGY, ROME; (d) MEDICAL ONCOLOGY,-IRCCS OSPEDALE SACRO CUORE DON CALABRIA, NEGRAR; (e) CEINGE, NAPOLI; (f) UOC CARDIOLOGIA, OSPEDALE VERSILIA, LIDO DI CAMAIORE; (g) CARDIOLOGIA, OSPADALE SAN PIO BENEVENTO; (h) MELANOMA CENTER IMMUNOTHERAPY UNIT, ISTITUTO NAZIONALE TUMORI-IRCCS-FONDAZIONE G.PASCALE DI NAPOLI

Background. Immune checkpoint blockade alone or in combination with chemotherapy or radiotherapy or other immune checkpoint blocking agents have become an integral part of oncology in recent years. Monoclonal antibodies against CTLA-4 or PD-1 or PDL-1 are the most studied ICIs in randomized clinical trials, however, more recently, an anti-LAG3 (Lymphocyte activation gene-3) human monoclonal antibody, Relatlimab, has been approved by FDA for combinatorial treatment with Nivolumab for metastatic melanoma. Moreover, anti PD-L1blocking agent Atezolizumab is actually under study in association with Ipilimumab as innovative thearpy for metastatic lung cancer. Cases of cardiotoxicity such as myocarditis, vasculitis and endothelitis are rarely observed in these patients on monotherapy, however new combination therapies and the use of new targets in immunotherapy could expose patients to more adverse cardiovascular events.

Methods. Human cardiomyocytes co-cultured with human peripheral blood lymphocytes (hPBMCs) were exposed to monotherapy and combinatorial ICIs (PD-L1 and CTLA-4 or PD-1 and LAG-3 blocking agents, at 100 nM) for 48 h. After treatments, cardiac cell lysis and secretion of biomarkers of cardiotoxicity (H-FABP, NT-Pro-BNP), NLRP3-inflammasome and Interleukin 1 and 6 were determined through colorimetric and enzymatic assays.

Results. Both combinations of immune checkpoint inhibitors exert more potent cardiotoxic side effects compared to monotherapies against human cardiac cells co-cultured with human lymphocytes. LDH release from cardiac cells was 43% higher in PD-L1/CTLA-4 blocking agents, and 35.7% higher in PD-1/LAG-3 blocking agents compared to monotherapies. Biomarkers of cardiotoxicity, such as NT-Pro-BNP and H-FABP, were also strongly increased in combination therapy with respect to monotherapies. NLRP3 inflammasome, IL-6 and IL-1β levels were also increased by PDL-1/CTLA-4 and PD-1/LAG-3 combined blocking agents compared to untreated cells and monotherapies.

Conclusions. Data of the present study, although in vitro, indicate that combinatorial immune checkpoint blockade, induce a pro- inflammatory phenotype, thus indicating that these therapies should be closely monitored by the multidisciplinary team consisting of oncologists, cardiologists and immunologists.

A384: SOLUBLE GUANYLATE CYCLASE ACTIVATOR VERICIGUAT PREVENTS ANTHRACYCLINE-MEDIATED CARDIOTOXICITY AND SARCOPENIA THROUGH NO-SGC-CGMP-NLRPE PATHWAY: POTENTIAL ALLPLICATION IN CANCER PATIENTS

Vincenzo Quagliariello (a), Irma Bisceglia (c), Massimiliano Berretta (f), Martina Iovine (a), Maria Canale (d), Fabrizio Maurea (a), Andrea Paccone (a), Alessia Merola (a), Alessandro Inno (e), Marino Scherillo (b), Nicola Maurea (a)
(a) DIVISION OF CARDIOLOGY, ISTITUTO NAZIONALE TUMORI-IRCCS-FONDAZIONE G.PASCALE OF NAPLES; (b) DIVISION OF CARDIOLOGY, OSPADALE SAN PIO BENEVENTO; (c) DIVISION OF CARDIOLOGY, SAN CAMILLO HOSPITAL, ROMA; (d) UOC CARDIOLOGIA, OSPEDALE VERSILIA, LIDO DI CAMAIORE; (e) MEDICAL ONCOLOGY, OSPEDALE DON CALABRIA; (f) UNIVERSITY OF MESSINA

Introduction. Anthracycline-induced cardiomyopathies and sarcopenia are frequently seen in cancer patients, affecting their overall survival and quality of life; therefore, new cardioprotective strategies are needed in cardioncology. Vericiguat is a new oral guanylate cyclase activator that reduces heart failure hospitalizations or cardiovascular death through improvement of smooth muscle cell relaxation and reduction of myocardial fibrosis and inflammation.

Methods. In this study, we highlight on the potential cardioprotective properties of vericiguat against anthracycline-mediated cardiotoxicity and sarcopenia. Human cardiomyocytes were pre-exposed for 24h with doxorubicin (at 300 and 1000 nM) for 48 and 72h alone or combined to Vericiguat at 10^{-7}, 10^{-5} and 10^{-3} M. After the incubation period, we performed the following tests: determination of cell viability, through analysis of mitochondrial dehydrogenase activity, study of lipid peroxidation (quantifying cellular Malondialdehyde and 4-hydroxynonenal), intracellular Ca2+ homeostasis. Moreover, pro-inflammatory studied were also performed (activation of NLRP3 inflammasome; expression of peroxisome proliferator-activated receptor-α; Nitric Oxide, cGMP; transcriptional activation of p65/NF-κB and secretion of cytokines involved in cardiotoxicity (Interleukins 1β, 8, 6, CXCL-12).

Results. Vericiguat exerts significant cardioprotective strategies during incubation with doxorubicin. Cell viability was drastically improved thorugh the activation of cGMP/NO pathway. Notably, the same behavior was seen in muscle cells. Intracellular Ca^{++} content was significantly reduced in doxorubicin-vericiguat group than doxorubicin alone group ($p<0.001$). Furthermore, vericiguat reduces chemokines and cytokines involved in cardiomyopathies through NLRP-3 pathways in human cardiomyocytes and skeletal muscle cells.

Conclusions. The findings that emerged from this study could provide the rationale for further preclinical and clinical investigations aimed at reduce anthracycline cardiotoxicity and sarcopenia in cancer patients.

A385: COMBINED FPR1 INHIBITION AND TLR3 ACTIVATION PROTECT THE HEART FROM DOX-INDUCED CARDIOMYOPATHY

Leonardo Schirone (a), Daniele Vecchio (b), Valentina Valenti (c), Vincenzo Petrozza (b), Sebastiano Sciarretta (a, b), Giacomo Frati (a, b)
(a) IRCCS NEUROMED; (b) DIP. DI SCIENZE E BIOTECNOLOGIE MEDICO-CHIRURGICHE, "LA SAPIENZA" UNIVERSITÀ DI ROMA; (c) OSPEDALE SANTA MARIA GORETTI, LATINA

Introduction. Doxorubicin (DOX) is a powerful tool for fighting cancer, but its administration often bears serious side effects, including cardiotoxicity and immunosuppression. This led to a progressive reduction of

DOX administration to patients, forcing the choice toward therapeutic options that are often less effective but safer. Characterization of the molecular mechanisms underlying doxorubicin-induced cardiomyopathy has been a primary goal in past decades to develop new cardioprotective strategies in order to benefit from the unmatched antineoplastic activity of DOX. Formyl peptide receptor-1 (FPR1) is an inflammation-related protein essential for DOX antineoplastic activity by stimulating the immunologic response against tumoral cells. Notably, an FPR1 gene mutation (rs867228) associated with a downregulation of its signaling has a prevalence of 30% in the general population and is associated with significant cancer chemoresistance. It was recently demonstrated in mice that this refractory phenotype was rescued by the administration of a Toll-like receptor 3 (TLR3) agonist polyinosinic:polycytidylic acid (pIC). Also, TLR3 signaling is required for a proper cardiovascular adaptation to stress.
Hypothesis. FPR1 inhibition coupled with pIC administration protects the heart from DOXCM
Methods. C57BL/6 WT mice and mice with cardiomyocyte-specific FPR1 inhibition received 3 weekly injections of DOX, reaching a final cumulative dose of 15 mg/kg. Also, PIC or the FPR1-inhibitor Cyclosporin H (CsH) were administrated 3 times per week. Echocardiographic, histological and biochemical analyses were performed 6 weeks after the first administration of DOX.
Results. Wild-type (WT) mice treated with DOX had reduced fractional shortening (43,1±1,56% vs. 29,1±2,12%, n=7) while both FPR1-KO (29,1±2,12% vs. 43,8±1,2%, n=7-13) and CsH-treated (29,1±2,12% vs. 39,9±4,57%, n=4-7) mice that received DOX showed improved cardiac function. Administering pIC to DOX-treated mice did not impair the protective effect of FPR1-KO (39,3±3,34% vs. 41,8±1,26%, n=4-8). Mice treated with DOX developed fibrosis (0,5±0,09% vs. 1,7±1,06%, n=4-5), but this effect was reduced in FPR1-ko mice that received DOX (1,7±1,06% vs. 0,3±0,09%, n=5-6). DOX notoriously affects mitochondrial function, so we assessed that heart lysates derived from wild-type mice treated with DOX had reduced oxidative phosphorylation complex IV function (0,3±0,03 vs. 0,2±0,01, n=4), while FPR1-KO did not (0,2±0,01 vs. 0,3±0,01, n=4). We also verified that FPR1-KO mice had improved 6 weeks survival compared to the wild-type (70% vs 96%).
Conclusions. A combined FPR1 inhibition and TLR3 activation may represent a new potential approach to inhibit DOX-induced cardiomyopathy.

A386: EARLY CARDIOTOXICITY DETECTION BY ADVANCED ECHOCARDIOGRAPHY IN PATIENTS WITH MELANOMA AND BRAF GENE MUTATION TREATED WITH TARGET THERAPY

Asya Cautela (a), Giancarlo Trimarchi (a), Olga La Cognata (a), Mario Germano (a), Francesca Campanella (a), Mariacarmela Santarpia (b), Nicola Silvestris (b), Olimpia Trio (a), Roberta Manganaro (a), Maurizio Cusmà Piccione (a), Gianluca Di Bella (a), Scipione Carerj (a), Concetta Zito (a)
(a) DEPARTMENT OF CLINICAL AND EXPERIMENTAL MEDICINE, CARDIOLOGY UNIT, UNIVERSITY OF MESSINA, MESSINA, ITALY; (b) DEPARTMENT OF HUMAN PATHOLOGY "G. BARRESI", MEDICAL ONCOLOGY UNIT, UNIVERSITY OF MESSINA, MESSINA, ITALY

Background. Combination therapy with BRAF and MEK inhibitors (BRAF/MEKi) has significantly improved the outcome of patients with BRAF-mutated melanoma. A reduction in left ventricular ejection fraction (LVEF) is a known side effect during treatment with BRAF/MEKi.
Aim. This study aimed to identify the occurrence of cardiovascular adverse events (CVAEs), such as death, occurrence of clinical and subclinical cardiotoxicity, arrhythmias, QT prolongation, during treatment. It also aimed to investigate whether the latest myocardial function analysis software – Global Longitudinal Strain (GLS), Myocardial Work (MW) and Peak left Atrial Longitudinal Strain (PALS) – can detect early target therapy damage, to establish the added value that such assessment could provide in daily clinical practice.
Methods. 14 patients with advanced melanoma (stage III-IV) who underwent a Cardio-Oncologic follow-up during BRAF/MEKi treatment were included. Standard and advanced echocardiography and electrocardiography were performed at baseline and 3, 6 and 12 months after initiation of therapy with BRAF/MEKi. Subclinical cardiotoxicity was defined as a new decline of ≥10 percentage point (pp) to an LVEF value of 40-49%, or a new decline of <10 pp to an LVEF value<50% in the presence of new relative decline in GLS>15% from baseline value.
Results. 2 patients died (14%), without completing follow-up, for reasons related to cancer disease progression. 1 patient (7%) reported the development of exertional dyspnea at 12-month follow-up. 1 patient (7%) met the criteria for subclinical cardiotoxicity related to BRAF/MEKi. On average, there was no significant change in systolic and diastolic blood pressure during antineoplastic treatment. There was a mean QTc prolongation that did not reach statistical significance (407±175 ms at T0 vs 419±164 ms at T6, p=0.24; 407±175 ms at T0 vs 421±191 ms at T12, p=0.25) and no arrhythmias were reported. There was no statistically significant reduction in either LVEF (57.4±8.7% at T0 vs 56±4.6% at T6, p=0.06; 57.4±8.7% at T0 vs 56.5±6.3% at T12, p=0.60) or GLS (-19±5.2 at T0 vs -19.2±2.2 at T6 p=0.90; -19±5.2 at T0 vs -18.4±6.0 at T12, p=0.81), at 6 months and 12 months after the start of target therapy compared to baseline, but there was a statistically significant difference in Global Left Ventricular Myocardial Work Efficiency (GWE) which decreased from 94.8%, baseline value, to 93.25% (p=0.04) at 6 months and again to 93.1% (p=0.04) at 12 months of follow-up, respectively. Finally, there was a progressive reduction in left atrial reservoir function assessed by PALS, that was statistically significant when comparing the value at 6 and 12 months (38±9.7% vs 32.1±13.7%; p=0.02).
Conclusions. BRAF/MEKi drugs can cause an impairment in LV and LA function that can be precociously detected by Myocardial Work and PALS with an important impact on heart failure and atrial fibrillation prevention.

A387: CARDIAC UPTAKE OF 18-FLUORODEOXYGLUCOSE IN PATIENTS WITH LUNG CANCER

Suela Vani (a), Matteo Bauckneht (a), Stefano Benenati (a), Carlo Genova (a), Gianmario Sambuceti (a), Italo Porto (a), Pietro Ameri (a)
(a) UNIVERSITÀ DEGLI STUDI DI GENOVA

Introduction. Cancer has been associated with pathological changes in cardiac structure and function, up to causing a specific cancer-related cardiomyopathy. Most experimental studies pinpointed inflammation as the mechanism by which cancer affects the heart, but other factors may play a role. In particular, it has been hypothesized that cancer alters cardiac metabolism.
Objectives. Our aim was to investigate the cardiac uptake of 18-fluorodeoxyglucose (18F-FDG) in newly diagnosed IV stage lung cancer patients compared to a cancer-free control group, using 18F-FDG positron emission tomography (18F-FDG PET).
Methods. We retrospectively reviewed the 18F-FDG PET scans performed in 71 patients with lung cancer for staging, and in 89 patients with spondylodiscitis without endocarditis and not receiving corticosteroid, for exclusion of extra-vertebral infection foci. A blinded nuclear medicine specialist manually traced the volume of interest at the level of the left ventricle with the help of hybrid PET/computed tomography (CT) images and calculated the mean standardized uptake value (mSUV), the metabolically active volume of the segmented myocardium (metabolic cardiac volume, MCV), and the product of these two measurements (total cardiac glycolysis, TCG). Computed tomography (CT) images were used to identify the myocardium in case of low cardiac 18F-FDG uptake. Comparisons between groups were drawn by chi-square or unpaired t-test, while the association of lung cancer with 18F-FDG uptake was evaluated by linear regression.
Results. Patients with lung cancer or spondylodiscitis had similar age (67 ± 9 years and 68 ± 13 years, respectively, P=0.55) and sex distribution (males 67.6% and 70.8%, respectively, P=0.67). However, mean fasting plasma glucose level prior to 18F-FDG PET was lower in the spondylodiscitis than lung cancer group (91.2 ± 19 mg/dL vs 98.7 ± 20.9 mg/dL, P=0.02). There was no correlation between mSUV and fasting plasma glucose. mSUV (3.0 ± 2.3 vs 3.8 ± 2.9, P=0.04), MCV (76.4 ± 42.3 cm3 vs 124.9 ± 61.4 cm3, P<0.001), and TCG (248.7 ± 274.3 vs 544.2 ± 698.5, P<0.001) were lower in patients with lung cancer than in those with spondylodiscitis. Having lung cancer (vs having spondylodiscitis) was associated with a significant reduction of mSUV (beta -0.912, P=0.03), MCV (beta -47.8, P<0.001) and TCG (beta -305.6, P<0.001) also after adjusting for age, sex, and fasting plasma glucose before administration of 18F-FDG.
Conclusions. These results suggest that cardiac energy metabolism is influenced by the presence of cancer and call for additional studies to better understand whether deranged cardiac metabolism is a feature of cancer-related cardiomyopathy.

A388: GASTROCNEMIUS DVT IN A PATIENT WITH LUNG CANCER, COMPLICATED BY INFERIOR CAVA AND SUBCLAVIAN DVT. HIGH THROMBOTIC BURDEN OR RELUCTANCE TO TIMELY HIGH INTENSITY ANTICOAGULATION?

Agnese Maria Fioretti (a), Tiziana Leopizzi (b), Daniele La Forgia (a), Donato Oreste (a), Pietro Scicchitano (c), Riccardo Inchingolo (d), Pamela Pizzutilo (a), Raffaele De Luca (a), Alfredo Zito (a), Stefano Oliva (a)
(a) ISTITUTO TUMORI IRCCS "GIOVANNI PAOLO II" BARI; (b) OSPEDALE "SANTISSIMA ANNUNZIATA" TARANTO; (c) OSPEDALE "FABIO PERINEI" ALTAMURA (BARI); (d) OSPEDALE GENERALE REGIONALE "F. MIULLI" ACQUAVIVA DELLE FONTI (BARI)

Introduction. Cancer-associated thrombosis (CAT) is the second leading cause of death in malignancy, leading to anticancer drugs delay or interruptions.
Case report. A 67 y-o man, with hypertension and dyslipidemia, was in treatment with pemetrexed, pembrolizumab and platinum (PPP) for a lung adenocarcinoma IV stage (brain metastases). D-dimer: 8748 ng/ml. Troponin: 94 pg/ml. He was incidentally diagnosed with bilateral gastrocnemius deep vein thrombosis (GDVT) (Figure 1) without involvement of proximal veins during a duplex ultrasound (DU), performed for monitoring a peripheral arterial disease (PAD) treated with clopidogrel 75 mg/die. We decided not to start anticoagulants and to continue wi-

th antiplatelet therapy only, since it was a peripheral isolated incidental DVT. After 1 week, a CT-scan detected a partial incidental inferior cava DVT (ICDVT) (Figure 2); therefore, we replaced clopidogrel with subtherapeutic dose of enoxaparin (0.5 mg/kgx2/die) due to concomitant anemia (Hg: 9.8 gr/dl) and thrombocytopenia (115000/µl) and for suspected hemorrhagic brain metastases. (Patient's weight: 65 Kg). However, after 1 week he complained with pain at the right arm, appearing swollen, warm, tender and red. A DU showed a right symptomatic subclavian DVT (SDVT) (Figure 3). We increased enoxaparin to full-dose (1 mg/kgx2/die), replaced at the discharge from hospital with edoxaban 60 mg/die. D-dimer: 9042 ng/ml. After 1 month, he completed the PPP regimen and continued to receive pembrolizumab only. Importantly, the gastrocnemius, inferior cava and subclavian DVT were still present and we indicated to proceed with the anticoagulant treatment.

Conclusions. The ideal treatment for GDVT is still unclear. In this case, an active lung cancer patient with PAD in treatment with clopidogrel was incidentally diagnosed with GDVT without receiving anticoagulants, but soon after he developed an ICDVT. We replaced clopidogrel with enoxaparin, at the beginning with a subtherapeutic dose due to high bleeding risk, and afterwards with a therapeutic dose due to the comparison of a SDVT. At hospital discharge, enoxaparin was replaced with edoxaban without any DVT regression. The PPP regimen was successfully completed and the patient continued with pembrolizumab only. For the persistent multifocal DVT, the concomitant PAD, the ongoing immunotherapy and the aggressive active cancer still at play, we decided long-term anticoagulant treatment with edoxaban full-dose.

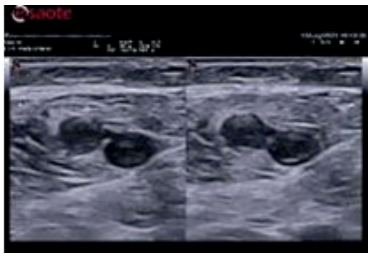

Figure 1.

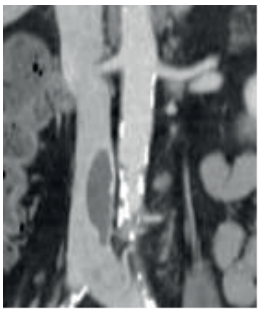

Figure 2.

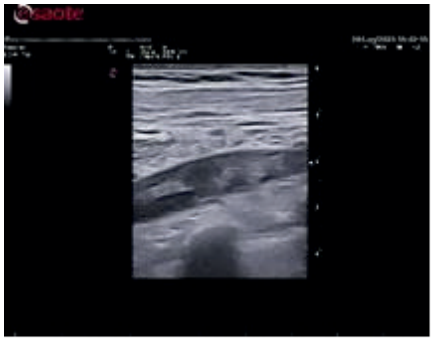

Figure 3.

A389: L'IMPORTANZA DEL FOLLOW-UP A LUNGO TERMINE NEL PAZIENTE ONCOLOGICO

Francesco Mautone (a), Maurizio Pesolo (a), Debora Ruggeri (a), Grazia Casavecchia (b), Matteo Gravina (a, b), Natale Daniele Brunetti (a, b)

(a) UNIVERSITÀ DI FOGGIA; (b) OSPEDALI RIUNTI DI FOGGIA

Introduzione. La cardio-oncologia è una nuova branca della cardiologia in crescente sviluppo, grazie anche alla recente pubblicazione delle Linee Guida ESC del 2022. Questa specialità nasce dall'esigenza di una precisa valutazione cardiologica in tutti quei pazienti sottoposti a farmaci chemioterapici che possono causare cardio-tossicità.

Caso clinico. Presentiamo il caso di una paziente di 48 anni, con ipercolesterolemia familiare, senza altri fattori di rischio cardiovascolare e precedenti cardiovascolari degni di nota. Affetta da Linfoma non Hodgkin follicolare di grado II/III da novembre 2020 e sottoposto a trattamento chemioterapico secondo schema R–CHOP (Rituximab associato a Ciclofosfamide, Doxorubicina, Vincristina e Prednisone) per 6 cicli e proseguito fino a marzo 2022 solo con Rituximab. Durante questi mesi la paziente è stata sottoposta a follow-up cardiologico periodico con esecuzione di ECG ed Ecocardiogramma risultati costantemente nella norma con una frazione di eiezione globale conservata. Alla valutazione cardiologica di controllo di settembre 2023, la paziente ha riferito l'insorgenza di dolore toracico precordiale, costrittivo, della durata di alcuni minuti, associato a cardiopalmo e di dispnea per sforzi lieve-moderati. L'ECG di controllo era nella norma, mentre l'Ecocardiogramma ha mostrato una Funzione Sistolica Globale lievemente ridotta (FEVS 50% valutata con metodica 3D) ed un GLS di –15.2%. Per approfondimento diagnostico è stata pertanto consigliata una Coro–TC che ha documentato la presenza di placca ateromasica, in parte calcifica, sul tratto prossimale dell'arteria coronarica destra e che si estendeva per circa 4 mm determinando una riduzione di area del 79% e del diametro del 85%. La paziente è stata quindi sottoposta ad esame coronarografico e angioplastica con impianto di Stent medicato su CDx.

Conclusioni. Questo caso dimostra come sia importante un adeguato follow–up cardiologico nel paziente oncologico e come le metodiche di imaging opportunamente utilizzate possono esserci di aiuto non solo nella prevenzione ma anche nella diagnosi e nel trattamento delle possibili cardiotossicità indotte dai chemioterapici.

A390: CARDIOTOXICITY IS NOT ONLY LEFT VENTRICULAR SYSTOLIC DYSFUNCTION: A CASE OF LONG-TERM MULTIORGAN AND CARDIAC COMPLICATIONS AFTER CHEMORADIOTHERAPY REQUIRING A MULTIDISCIPLINARY AND MULTISTEP APPROACH

Andrea Lalario (a, e), Antonio De Luca (a, b, c, e), Laura Massa (a, e), Marco Merlo (a, e), Gianfranco Sinagra (a, d, e)

(a) M.D.; (b) PH.D.; (c) FEACVI; (d) FESC; (e) CARDIOTHORACOVASCULAR DEPARTMENT, DIVISION OF CARDIOLOGY, AZIENDA SANITARIA UNIVERSITARIA GIULIANO ISONTINA AND UNIVERSITY OF TRIESTE, TRIESTE, ITALY

We present the case of a 54-year-old man with a remote history of Hodgkin's lymphoma. The patient was treated with polichemotherapy (Vincristine, Adriamycin, Bleomycin, Vinblastine, and Decarbazine), splenectomy, and thoracic and inguinal radiotherapy at the age of 18. These treatments led to post-actinic hypothyroidism and moderate restrictive pulmonary impairment. Twenty-four years later the patient experienced exertional angina. The left ventricular (LV) systolic function was normal and the coronary angiography showed a multivessel disease, treated with a double coronary artery grafting (left internal mammary artery to left anterior descending artery and right internal mammary artery to first obtuse marginal artery). In the following years, the patient developed a multivalvular heart disease (i.e. symptomatic severe aortic valve stenosis and severe mitral regurgitation) with multiple hospital admissions for heart failure requiring transcatheter aortic valve replacement (TAVR) and subsequent Tendyne transcatheter mitral valve replacement. Furthermore, patient experienced bradyarrhythmic syncope due to conduction disorders requiring pacemaker implantation. Even years after treatment, chemotherapy and radiotherapy can result in multiorgan and cardiac complications, not confined to LV systolic dysfunction. A multidisciplinary approach is essential for the proper management of each single patient.

A391: IL RUOLO DELL'HFA-ICOS SCORE NEL PREDIRE LA DISFUNZIONE CARDIACA CORRELATA ALLA CHEMIOTERAPIA NEL TUMORE DELLA MAMMELLA

Cristina Madaudo (a), Daniela Di Lisi (a), Denise Cristiana Faro (b), Antonella Ortello (a), Ludovico Rossetto (a), Oreste Fabio Triolo (a), Valentina Losi (b), Vincenzo Sucato (a), Egle Corrado (a), Alfredo Ruggero Galassi (a), Ines Paola Monte (b, c), Giuseppina Novo (a)

(a) UNITÀ DI CARDIOLOGIA - DIPARTIMENTO PROMISE, POLICLINICO UNIVERSITARIO "PAOLO GIACCONE"- UNIVERSITÀ DEGLI STUDI DI PALERMO; (b) DIPARTIMENTO CHIRMED, UNIVERSITÀ DEGLI STUDI DI CATANIA; (c) UNITÀ DI CARDIOLOGIA- POLICLINICO UNIVERSITARIO "G. RODOLICO - SAN MARCO" CATANIA

Background. Chemotherapy-related cardiac dysfunction (CTRCD) is the main complication of treatment with anthracyclines and trastuzumab, used to treat breast cancer. Echocardiography is fundamental in the evaluation of the left ventricular ejection fraction (LVEF) and global longitudinal strain (GLS) to define CTRCD in accordance with the 2022 ESC Guidelines on Cardio-Oncology. These guidelines recommend cardiovascular baseline risk stratification using the HFA/ICOS score to plan the most appropriate surveillance program and implement cardioprotective strategies. The aim of our study was to assess the usefulness of this score in patients with breast cancer undergoing chemotherapy in predicting the development of CTRCD.

Methods. A prospective multicenter study was carried out, enrolling 109 patients with breast cancer treated with anthracyclines or anthracyclines + trastuzumab. A cardiological evaluation, including ECG and echocardiogram at baseline (T0), three months (T1), and six months (T2) after starting treatment, was performed. In addition, baseline cardiovascular risk was assessed in all patients using HFA/ICOS score. During follow-up, we assessed the development of CTRCD, analyzing the occurrence of clinical HF symptoms and changes in LVEF and GLS.
Results. 21 patients (20,5%) developed asymptomatic mild CTRCD at T1 and 13 patients (14%) at T2. 1 patient developed moderate asymptomatic left ventricular dysfunction (LVD) at T1 and 1 patient at T2; no patient developed severe CTRCD at T1; however, one patient developed severe CTRCD at T2. At 3 months, 7 patients were mildly symptomatic for heart failure, and one instead required hospitalization due to more severe symptoms. At 6 months, 10 people were mildly symptomatic of heart failure with the need to increase therapy, but no patient was hospitalized. At 1-year follow-up, 5 people were symptomatic of heart failure with the need to improve treatment; of these 1 had a cardiovascular event (arrhythmia) and two uncontrolled blood pressure values. Evaluating the pre-chemotherapy cardiovascular risk according to HFA-ICOS, the population was divided into low, medium, high and very high. Sixty-one patients were in the low-risk group, 37 in the medium, 9 in the high, and two at very high risk. In addition, we found a significantly higher proportion of CTRCD in the very high-risk group (100%) and the high (89%) than in the medium (38%) and low-risk group (32%) with a p-value of 0,0056.
Conclusions. Our study confirms the usefulness of the HFA/ICOS score in the prediction of CTRCD in breast cancer women; it highlights the need for a careful evaluation of the LVEF and GLS during chemotherapy to identify early CTRCD and to start cardioprotective strategies.

A392: TOSSICITÀ VASCOLARE DA ICI: PROGRESSIONE DI ATEROSCLEROSI E ISCHEMIA MIDOLLARE

Daniela Di Lisi (a), Cristina Madaudo (a), Angelica Peritore (b), Grazia Gambino (a), Antonella Ortello (a), Paolo Sinagra (a), Federica Manfre (a), Salvatore Bonura (b), Vincenzo Sucato (a), Antonino Nicosia (b), Egle Corrado (a), Alfredo Ruggero Galassi (a), Giuseppina Novo (a)
(a) U.O.C CARDIOLOGIA, AZIENDA OSPEDALIERA UNIVERSITARIA POLICLINICO P. GIACCONE, PALERMO; (b) U.O.C CARDIOLOGIA, OSPEDALE GIOVANNI PAOLO II, RAGUSA

Gli immune checkpoint inhibitors (ICI) possono provocare diversi effetti tossici cardiovascolari: miocardite, pericardite, infarto miocardico, aritmie, vasculite, disturbi della conduzione A-V, dislipidemia, stroke ischemico. Evidenze recenti suggeriscono che gli ICI possono indurre una accelerazione del processo aterosclerotico e promuovere l'infiammazione delle placche aterosclerotiche. Casi di tossicità neurologica da ICI sono stati documentati quali la miastenia grave, la sindrome di Guillan Barrè e l'encefalite. Descriviamo un caso clinico di tossicità vascolare da ICI manifestatosi con progressione del processo aterosclerotico carotideo e ischemia midollare. Un paziente di 65 anni con multipli fattori di rischio cardiovascolare (ipertensione arteriosa, dislipidemia, diabete mellito di tipo II, ex fumatore), cardiopatia ischemica cronica (pregressa angioplastica coronarica con posizionamento di DES su arteria circonflessa), arteriopatia obliterante periferica sottoposta a rivascolarizzazione percutanea, aterosclerosi carotidea con stenosi carotidea sinistra del 65% è stato valutato presso il nostro ambulatorio di cardio-oncologia a seguito del riscontro di un carcinoma polmonare metastatico. Un trattamento con pembrolizumab è stato iniziato. Il paziente è stato sottoposto ad una valutazione cardiologica basale comprensiva di ecocardiogramma Color-Doppler (FE basale 45%), ECG, dosaggio troponina e NT-pro BNP (nei limiti di norma). Dopo circa 1 anno di terapia con pembrolizumab, il paziente ha presentato progressione della patologia carotidea aterosclerotica (stenosi del 90%) per cui è stato sottoposto ad angioplastica carotidea ed è stata iniziata una doppia terapia antiaggregante piastrinica (ASA + clopidogrel in sostituzione della sola terapia con ASA). È stato ottimizzato il profilo lipidico con incremento della dose di atorvastatina al massimo dosaggio tollerato e aggiunta di ezetimibe (LDL 33 mg/dl dopo terapia). La terapia ipoglicemizzante è stata ottimizzata con riduzione dei valori di emoglobina glicata. Considerata la buona risposta oncologica al trattamento con ICI e l'assenza di valide alternative terapeutiche, dopo discussione cardio-oncologica è stata ripresa la terapia con pembrolizumab circa 2 settimane dopo la rivascolarizzazione carotidea (ritardando il trattamento oncologico di una sola settimana). Quattro mesi dopo la ripresa della terapia con pembrolizumab (16 mesi dopo l'inizio della terapia con ICI), insorgenza improvvisa di astenia, miastenia, perdita del controllo sfinteriale, impossibilità a deambulare. Il paziente veniva ricoverato in urgenza presso la U.O di Neurologia nel sospetto di ictus ischemico. Veniva eseguita una TC encefalo che escludeva la presenza di ischemia cerebrale. Veniva posta diagnosi di ischemia midollare dopo esecuzione di RM della colonna vertebrale. Veniva iniziata terapia con metilprednisolone e proseguita la doppia terapia antiaggregante piastrinica con successivo recupero funzionale nelle settimane successive. Il nostro caso sottolinea la tossicità vascolare degli ICI con progressione di patologia aterosclerotica e vasculite a livello midollare, in un paziente con elevato rischio di cardiotossicità. Soprattutto in tali pazienti con multipli fattori di rischio cardiovascolare e pregressa ischemia miocardica, è importante l'ottimizzazione del profilo di rischio cardiovascolare e una adeguata terapia cardioprotettiva.

A393: STRAIN ATRIO-VENTRICOLARE GLOBALE IN CARDIO-ONCOLOGIA

Daniela Di Lisi (a), Luigi Rubino (a), Cristina Madaudo (a), Oreste Fabio Triolo (a), Ludovico Rossetto (a), Paolo Sinagra (a), Celeste Vullo (a), Francesco Comparato (a), Domenico Scelfo (a), Giuseppe Puccia (a), Vincenzo Sucato (a), Egle Corrado (a), Alfredo Ruggero Galassi (a), Giuseppina Novo (a)
(a) U.O.C DI CARDIOLOGIA, AZIENDA OSPEDALIERA UNIVERSITARIA POLICLINICO "P. GIACCONE", DIPARTIMENTO PROMISE, UNIVERSITÀ DEGLI STUDI DI PALERMO

Introduzione e obiettivi. La diagnosi di cardiotossicità correlata al trattamento antineoplastico (CTRCD) si basa sulla riduzione dei valori di frazione d'eiezione del ventricolo sinistro (LVEF), global longitudinal strain del ventricolo sinistro (GLS) e incremento dei markers di miocardionecrosi. Considerata la stretta correlazione esistente tra funzione atriale e funzione ventricolare sinistra, obiettivo del nostro studio è stato quello di valutare gli effetti tossici dei farmaci antineoplastici sulla funzione atriale e ventricolare sinistra, attraverso la valutazione di un nuovo indice ecocardiografico: il GAVS (strain atrio-ventricolare globale).
Materiali e metodi. uno studio prospettico è stato condotto arruolando 131 pazienti con carcinoma mammario (51,4 ± 10,4 anni) trattate con antracicline seguite da trastuzumab e/o taxani. Una valutazione cardiologica comprensiva di elettrocardiogramma ed ecocardiogramma è stata condotta prima di iniziare la terapia antineoplastica (T0), a 3 (T1)-6 (T2) e 12 mesi (T3) dall'inizio del trattamento. La valutazione ecocardiografica ha incluso la valutazione del GLS, strain atriale (PALS- peak atrial longitudinal strain) e stiffness atriale (rapporto tra PALS e E/e' medio), rapporto LVEF/GLS e valutazione del GAVS (somma in valore assoluto del GLS e del PALS in 4 e 2 camere). L'incidenza di CTRCD è stata valutata secondo la definizione delle linee guida ESC di Cardio-oncologia del 2022. La popolazione in studio è stata suddivisa in 2 gruppi: pazienti con sviluppo di CTRCD al follow-up (gruppo A: 44 pazienti) e pazienti senza sviluppo di CTRCD (gruppo B: 87 pazienti).
Risultati. la CTRCD si è sviluppata in totale in 44 pazienti. Di questi 3 pazienti (10%) hanno sviluppato CTRCD moderata al T2 con riduzione della LVEF al di sotto del 50%. 41 pazienti (31%) hanno sviluppato CTRCD lieve (21 pazienti al T1, 15 al T2 e 5 al T3). La LVFE si è ridotta significativamente solo al T2 (p-value 0,04), e il rapporto E/e' medio è incrementato significativamente al T3. Invece abbiamo riscontrato una riduzione significativa dei valori di GLS del ventricolo sinistro già al T1, così come degli altri indici di deformazione miocardica (PALS, LASI, GAVS) e del rapporto LVEF/GLS (p-value <0,05). I pazienti che sviluppavano CTRCD presentavano al basale valori significativamente più elevati di LASI, E/e' medio e GLS; non sono state riscontrate differenze significative degli altri parametri clinici ed ecocardiografici. Nel gruppo B, al follow-up si modificavano significativamente solo il PALS, LASI e GAVS. Nel gruppo A, si modificavano significativamente anche il GLS e il rapporto FE/GLS, la FE al T3. LASI e GLS sono risultati essere associati significativamente allo sviluppo di CTRCD. Un valore di LASI>0,18 ha mostrato la maggiore sensibilità e specificità nel predire lo sviluppo di CTRCD (p- value 0,085). Anche un valore di GAVS <57,5 si è associato con lo sviluppo di CTRCD ma in modo non significativo (p value 0,76).
Conclusioni. PALS, LASI e GAVS sono parametri addizionali, utili da monitorare in aggiunta al GLS, in corso di trattamento antineoplastico, al fine di individuare precocemente i primi segni di disfunzione cardiaca, prima della riduzione della LVEF. Dati a lungo termine sono necessari.

A394: RARO CASO DI RECIDIVA CARDIACA DI LINFOMA DIFFUSO A GRANDI CELLULE B: RISPOSTA ECOCARDIOGRAFICA ALLA CHEMIOTERAPIA

Federica Onorato (a, b), Andrea Giovanni Parato (b), Giuseppe Michienzi (b), Maria Cantonetti (a), Francesco Barillà (a, b), Riccardo Morgagni (a)
(a) FONDAZIONE PTV POLICLINICO TOR VERGATA; (b) UNIVERSITÀ DEGLI STUDI DI ROMA TOR VERGATA

Introduzione. Il linfoma diffuso a grandi cellule B (DLBCL) è il sottotipo più comune di linfoma non-Hodgkin negli adulti. Il trattamento standard è costituito dalla combinazione di Rituximab e chemioterapia a base di antracicline, che raggiunge la remissione completa (CR) in circa il 67% dei pazienti. Circa un terzo dei pazienti presenta una malattia refrattaria o una recidiva dopo terapia standard, prevalentemente entro 5 anni dal raggiungimento della CR.
Caso clinico. Paziente di 62 anni, fumatrice, senza pregresse patologie cardiovascolari, giungeva presso il Pronto Soccorso del nostro Ospedale per dispnea ed astenia. All'ECG d'ingresso tachicardia sinusale in assenza di alterazioni della ripolarizzazione ventricolare; PA 120/70 mmHg, Emoglobina 15,6 g/dl; all'EGA arterioso pO2 71 mmHg e pCO2 27 mmHg. In anamnesi GBC-DLBCL al terzo stadio andato incontro a remissione completa (CR) con terapia R-CHOP tre anni prima. Alla TC torace con mezzo di contrasto riscontro di una voluminosa massa intra-cardiaca con coinvolgimento anche del sacco pericardico (Figura 1). All'Ecocardiogramma

transtoracico evidenza di una massa voluminosa (area 31 cm2) occupante quasi tutto l'atrio destro (5,9 x 4,4 cm), che si estendeva attraverso la tricuspide anche al ventricolo destro, spostando il setto interventricolare, con conservata funzione sistolica del ventricolo sinistro (Figura 2). La biopsia endomiocardica eseguita tramite cateterismo cardiaco destro confermava la diagnosi di recidiva cardiaca di GBC-DLBCL. In virtù della buona funzione sistolica del ventricolo sinistro e dell'età del paziente, si decideva di procedere con un debulking chemioterapico mediante Gemcitabina, seguito da R-CHOP e MTX. La TC Total Body a 2 mesi post-trattamento mostrava una buona risposta alla terapia; al controllo ecocardiografico transtoracico non evidenza di tessuto cardiaco patologico (Figura 3).
Conclusioni. Il DLBCL cardiaco è un tumore raro, con pochi casi riportati in letteratura. Attualmente non esiste una terapia standard, in particolare per coloro che non sono idonei alla chemioterapia ad alte dosi e/o al trapianto di cellule staminali autologhe. L'approccio multidisciplinare cardiologico ed ematologico si è rivelato fondamentale nella gestione terapeutica della nostra paziente.

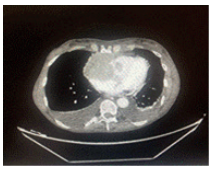
Figura 1

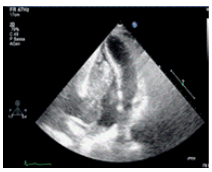
Figura 2

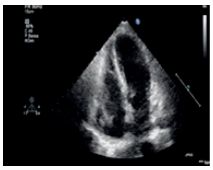
Figura 3

A395: UROTHELIAL CARCINOMA PROGRESSION: UNVEILING CARDIAC INVOLVEMENT AS DECEPTIVE PRELUDE - A CASE REPORT AND LITERATURE REVIEW

Gianluca Ricchetti (b), Massimo Slavich (a, b), Eustachio Agricola (b), Antonio Grimaldi (b), Michele Morosato (b)
(a) DEPARTMENT OF CARDIOLOGY, IRCCS SAN RAFFAELE SCIENTIFIC INSTITUTE; (b) CARDIOVASCULAR IMAGING UNIT, CARDIO-THORACIC-VASCULAR DEPARTMENT, IRCCS SAN RAFFAELE SCIENTIFIC INSTITUTE

Background. Cardiac metastasis in urothelial carcinoma is rare, but early detection is crucial for improved outcomes. We report a case of rapid cardiac metastatic involvement as the initial sign of disease recurrence.
Case presentation. We describe the case of a 59-year-old male with a known history of urothelial neoplasia who presented to our Emergency Department with worsening dyspnea. Six months earlier, he had undergone a nephroureterectomy for locally advanced urothelial carcinoma and completed four cycles of Taxol + Carboplatin chemotherapy with apparent clinical and radiological response. In April 2023, he underwent a follow-up echocardiography, which showed no abnormalities. One month later, he returned to the Emergency Department with subjective dyspnea. Upon admission, vital signs, biochemistry exams, and chest x-ray were normal. Echocardiography revealed a new, highly mobile, hyperechoic left ventricular mass with associated hypokinesia of the mid-segment of the lateral wall (initially overlooked and unreported). The mass was initially suspected to be a left ventricular fibroelastoma, despite the patient's history and its atypical presentation. The patient was discharged after 24 hours of monitoring but was urgently referred to our echocardiography service for a more detailed evaluation of the cardiac mass due to his previous neoplastic history. One month later, a planned echocardiographic evaluation revealed further expansion of the left ventricular mass, now appearing multilobulated with inhomogeneous echogenicity and a large highly mobile component. This was associated with akinesia of the apex and left ventricular lateral wall, along with moderate pericardial effusion. Urgent total-body CT was performed, which showed multiple cardiac masses infiltrating myocardium and pericardium, involving also RV. Moreover, were evidenced pulmonary and brain masses, interpreted as rapid metastatic progression of previous neoplasia.
Clinical discussion. Cardiac involvement in urothelial carcinoma is uncommon but carries significant prognostic implications and typically involve the pericardia and right ventricle. Early detection is challenging due to nonspecific symptoms, and most cases are identified postmortem. This report stands as the first documented instance of cardiac metastatic involvement serving as the initial indication of urothelial malignancy recurrence. It underscores the rapid and insidious progression of urothelial carcinoma, as depicted through a series of echocardiographic images. In this case, rapid progression and patient frailty ruled out biopsy. Cardiac MRI and CT are valuable tools for diagnosis, with CT offering high spatial resolution and vascularization assessment.
Conclusions. The case highlights the importance of considering cardiac metastasis in oncological patients presenting with rapidly worsening dyspnea. Utilizing multimodal imaging, including echocardiography, cardiac MRI, cardiac CT, and FDG-PET, is instrumental in distinguishing between thrombi and cardiac tumors. Nonetheless, definitive diagnosis is only achievable through biopsy, which is frequently not feasible in frail patients. Discriminating intracardiac thrombus from neoplastic involvement in patients with active malignancies bears significant implications for management and prognosis. In this case, echocardiography had certain limitations, including the inability to characterize tissue, assess revascularization, and evaluate extracardiac extension, which impeded its role in differential diagnosis. Total-body CT proved pivotal in diagnosing RV and LV masses as cardiac tumors, likely urothelial metastases, signaling a dismal prognosis. Currently, the management of urothelial malignancies with cardiac metastasis remains unclear, with most patients succumbing within weeks of diagnosis. Some limited attempts at chemotherapy and resection have shown modest improvements in patients' conditions.

A396: CARDIOTOSSICITÀ DA TRIOSSIDO DI ARSENICO

Luisa Simeoli (a), Christian Basile (a), Teresa Guarnaccia (a), Simona Soriano (a), Maria Francesca Di Santo (a), Maria Prastaro (a), Giovanni Esposito (a), Pasquale Perrone Filardi (a)
(a) UNIVERSITÀ DEGLI STUDI DI NAPOLI "FEDERICO II"

Introduzione. La Cancer Therapy-Related Cardiovascular Toxicity (CTR-CVT) indica un ampio spettro di tossicità a carico del sistema cardiovascolare (CV), riconducibile agli effetti collaterali di farmaci antineoplastici o relativi alla loro intrinseca attività antitumorale. La gestione della CTR-CVT ha un enorme impatto sul tipo di terapie antitumorali che i pazienti possono ricevere, nonché sugli esiti di morbilità e mortalità a lungo termine. Non essendo disponibili protocolli validati per il management di tutte le classi di farmaci antiblastici, le strategie terapeutiche si basano spesso sulla scelta individuale del clinico.
Descrizione del caso clinico. Un uomo di 65 anni, iperteso, ex-tabagista e affetto da insufficienza renale cronica II stadio, riceveva prescrizione per chemioterapia secondo schema ATRO-ATO (acido all trans retinoico + triossido di arsenico) a pieno dosaggio in seguito a diagnosi di Leucemia Promielocitica acuta. Al controllo basale, prima di iniziare la chemioterapia, si evinceva un quadro clinico, elettrocardiografico ed ecocardiografico nei limiti della norma. Il triossido di Arsenico rientra tra i farmaci ad elevato rischio di prolungamento del QTc con relativo rischio di sviluppare torsioni di punta e tachiaritmie ventricolari sostenute, per tale motivo veniva raccomandato di praticare un ECG settimanale durante le prime otto settimane di terapia insieme al dosaggio degli elettroliti (K e Mg). Dopo un mese di trattamento chemioterapico, il paziente sviluppava un episodio anasarcatico acuto con aumento ponderale di 10 kg associato a sintomatologia dispnoica per sforzi lievi. All'esame ecocardiografico si riscontrava lieve riduzione della frazione di eiezione rispetto al controllo basale (FE 50%) e calo del GLS>15% rispetto alla valutazione precedente. Si procedeva a richiedere il dosaggio dei biomarcatori (BNP e TnI), risultati positivi per aumentati valori del peptide natriuretico di tipo B (BNP 778 pg/ml). Al contempo l'esame ECG evidenziava QTc>500ms. Il quadro clinico e strumentale era suggestivo di duplice danno da chemioterapici, ossia di QTc lungo correlato all'utilizzo del triossido di Arsenico, evenienza che si verifica in percentuale variabile tra il 26% ed il 93% dei casi, ma anche di Cancer Therapy-related Cardiac Disfunction (CTR-CD) di grado moderato. Si è quindi agito con terapia diuretica infusiva in regime di DH fino alla risoluzione della congestione stessa e introduzione di terapia cardio-protettiva con ACEi e beta-bloccante, quest'ultimo indicato sia come terapia per la CTR-CVT che per il QTc lungo. In accordo con una valutazione multi-disciplinare si concordava di proseguire la chemioterapia con prudente monitoraggio del QTc e degli elettroliti sierici, nonché dosaggio dei markers di danno miocardico ad ogni ciclo di terapia. Al controllo a due mesi si verificava recupero degli indici di funzionalità sistolica del ventricolo sinistro e riscontro di QTc <500ms.
Conclusioni. La cardioncologia si pone come obiettivo la scelta del trattamento del cancro più compatibile con il profilo di rischio del singolo paziente dal punto di vista CV e più efficace dal punto di vista oncologico. Nonostante le recenti linee guida dedicate a questa nuova disciplina, restano numerosi interrogativi per i quali nuove evidenze e trials randomizzati sono necessari.

A397: MITIGATING CARDIOTOXICITY IN ONCOLOGIC TREATMENT: A CASE REPORT OF MANAGEMENT STRATEGIES

Francesco Torlone (a), Matteo Della Torre (a), Leoluca Nicolì (a), Roberto Franco Enrico Pedretti (a)
(a) CARDIOVASCULAR DEPARTMENT, IRCCS MULTIMEDICA, SESTO SAN GIOVANNI, MI

Introduction. Cardiovascular Toxicity Related to Cancer Treatment has emerged as a critical concern, representing a challenge that demands vigilance, prevention, and judicious surveillance.
Case report. A 59-year-old woman with a family history of non-ischemic dilatative cardiomyopathy and a history of papillary renal cell carcinoma (type 2) with sarcomatoid component and active lymphatic spread, on treatment with Sunitinib, an oral tyrosine kinase inhibitor, was admitted to the hospital due to acute decompensated heart failure. Echocardiography revealed severe left ventricular (LV) dilatation with an ejection fraction (LVEF) of 25%, mild tricuspid annular plane systolic excursion (TAPSE) impairment, and severe secondary mitral regurgitation (S-MR) despite a recent normal echocardiographic findings (LVEF 60%). Coronary CT angiography ruled out significant epicardial coronary artery ste-

nosis. Cardiac magnetic resonance confirmed a dilated LV with diffuse hypokinesia and an LVEF of 27%, while the right ventricle (RV) exhibited normal size with moderate hypokinesia. Importantly, no myocardial edema or tissue signal alterations were observed, although late acquired sequences exhibited non-specific intramyocardial contrast accumulation. The successful acute phase management included discontinuation of sunitinib and treatment of fluid overload and congestion with intravenous diuretics. Long-term therapy comprised a tailored regimen of sacubitril/valsartan, carvedilol, spironolactone, dapagliflozin, and inclusion in a cardiac rehabilitation program. At three-month follow-up the patient was completely asymptomatic (NYHA I) and the echocardiogram demonstrated a complete recovery (normal chambers dimensions and LVEF).
Conclusions. This case underscores the critical importance of rigorous risk stratification and robust secondary prevention strategies in patients requiring potentially cardiotoxic treatments. A meticulous evaluation of cardiovascular history is essential. Utilizing established risk scores like those outlined by the Heart Failure Association (HFA) and the International Cardio-Oncology Society (ICOS) provides valuable prognostic information. This case emphasizes the significance of vigilant surveillance and tailored management strategies in mitigating cardiotoxicity associated with oncologic treatments.

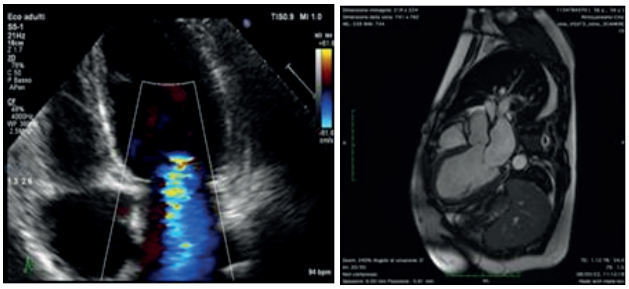

A398: LUCK NEVER MADE A MAN (NOR A WOMAN) WISE
Michele Alfieri (a, b), Alice Frangione (b), Edlira Rrapaj (b), Paolo Tofoni (a, b), Leonardo Brugiatelli (a, b), Federico Paolini (a, b), Francesca Coraducci (a, b), Gianmarco Bastianoni (a, b), Sara Belleggia (a, b), Antonio Dello Russo (a, b), Federico Guerra (a, b)
(a) UNIVERSITÀ POLITECNICA DELLE MARCHE; (b) CLINICA DI CARDIOLOGIA ED ARITMOLOGIA, AZIENDA OSPEDALIERO-UNIVERSITARIA DELLE MARCHE
Background. Anomalous aortic origin of a coronary artery represents a rare condition in the European population; clinical presentations may be completely silent but, in malignant variants, it can cause anginal symptoms or even sudden cardiac death (SCD). Anomalous right coronary artery (ARCA) origin from the left sinus of Valsalva is one of such conditions with a risk of major cardiovascular events in its variant decurring between the aorta and the pulmonic artery. Despite their widespread application, to date no data is available regarding safety of chest radiotherapy or cardiotoxic chemotherapy on such patients.
Case presentation. A 68-year-old Caucasian female affected by arterial hypertension was followed by our cardio-oncology facility for a breast carcinoma known since 2001, already treated with excision and hormonal therapy, relapsed in 2019. In 2020 she underwent quadrantectomy surgery followed by radiotherapy, paclitaxel and trastuzumab. During follow-up she was completely asymptomatic, but, after one year from the last round of chemotherapy, she began to experience repeated episodes of thoracic pain leading her to our emergency department. Considering her medical history and the possibility of a coronary involvement, a coronary-CT scan was then performed showing ARCA origin from the left sinus of Valsalva with a malignant inter-arterial course. Since it is known that such anomaly carries an intrinsic risk of developing significant ischemia and SCD, our patient was referred to the paediatric cardiac surgery unit. To make things worse, during pre-procedural planning another tumoral loco-regional recurrence was found. Considering the lack of major cardiovascular events and the need for a new breast operation and chemotherapic assessment, we decided to defer cardiac surgery. The patient then underwent a new course of chemotherapy with carboplatin, taxane and HER-2 inhibitor followed by hormonal therapy currently on board.
Discussion. The increasing incidence of cancer in latest years has led to the growing application of anti- neoplastic therapies and, of course, to the rise of their collateral effects. Among these, chest radiation therapy is a known cause of pulmonary hypertension, pericarditis, valvular and coronary deterioration leading to accelerated CAD even after years. On top of that, taxanes, platinum containing chemotherapy and HER-2 inhibitors may have an additional effect by inducing microvascular disfunction and heart failure. No study has hitherto verified those effects in patients with coronary anomalies and the safety of such combination is still unknown. Our case is not only unique for the rarity of the association between coronary congenital anomalies and cardiotoxic therapy, but also for the late detection of the coronary defect, whose malignant characteristics could have given an earlier manifestation.

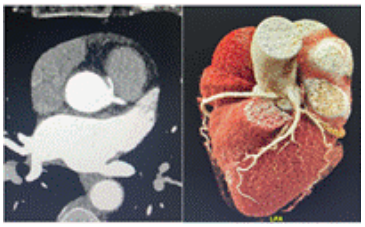

A399: THROMBOTIC STORM IN CARDIO-ONCOLOGY
Marco De Pietri (a), Andrea Erriquez (a), Gabriele Guardigli (a), Elisabetta Tonet (a)
(a) CARDIOLOGY UNIT, AZIENDA OSPEDALIERO-UNIVERSITARIA DI FERRARA
Background. Lo stato di ipercoagulabilità rappresenta una condizione causata da trigger clinici o iatrogeni documentata anche nell'ambito della cardio-oncologia.
Caso clinico. Presentiamo il caso di un paziente maschio di 64 anni, con fattori di rischio cardiovascolare, affetto da Linfoma di Burkitt stadio IV-B, trattato in prima battuta con schema R-DA-EPOCH (etoposide, prednisone, vincristina, ciclofosfamide, doxorubicina e rituximab). Durante i controlli di ristadiazione si riscontrava incidentalmente tromboembolia polmonare e trombosi venosa giugulare. In aggiunta, per il contestuale riscontro di malattia residua, veniva introdotto schema terapeutico secondo schema HyperCVAD (rituximab, metotrexate, citarabina). Dopo 72 ore dall'introduzione di tale regime terapeutico il paziente lamentava dolore toracico, in assenza di modificazioni ECG-grafiche, con presenza di difetto di cinetica in sede apicale e curva enzimatica suggestiva per sindrome coronarica acuta. Alla coronarografia riscontro di stenosi critica di asse IVA-D1 e RI, trattato con PCI e stenting, a cui seguiva introduzione di triplice terapia antitrombotica con acido acetilsalicilico, clopidogrel ed EBPM per 30 giorni. Tuttavia, a distanza di 20 giorni ed in concomitanza della somministrazione di II ciclo di terapia, si verificava nuovo episodio di dolore toracico con sostanziale incremento degli indici di miocardiocitonescrosi e riscontro alla coronarografia di ri-stenosi intrastent di D1 (culprit) e stenosi critica su IVA prossimale e media trattate con PCI e stenting. Il paziente veniva poi dimesso in triplice terapia antitrombotica, sostituendo EBPM con edoxaban.
Discussione. Dati di letteratura riportano che, seppur in rari casi, la terapia con rituximab possa determinare complicazioni trombotiche sia venose che arteriose. La stretta relazione temporale tra la somministrazione del farmaco e l'insorgenza di trombosi diffusa, unitamente alle evidenze attuali, ci consente di attribuire questo stato di ipercoagulabilità all'infusione del farmaco. La modifica del trattamento oncologico sulla base dei dati ora disponibili andrebbe pertanto ottemperata sulla base di rischio di progressione di malattia, caratteristiche del paziente ed efficacia del farmaco stesso. Inoltre, in un contesto di alto rischio trombotico (neoplasia attiva e fattori di rischio CV), la scelta dell'estensione della triplice terapia antitrombotica a 30 giorni e della sostituzione di EBPM con edoxaban appaiono quelle guidate da maggiori evidenze.

A400: EFFECTS OF IMMUNE CHECKPOINT INHIBITORS ON HEART, AN ADVANCED ECHOCARDIOGRAPHIC MONOCENTRIC STUDY: THE IM.IN. HEART STUDY
Giulia Elena Mandoli (a), Maria Concetta Pastore (a), Laura Spaccaterra (a), Andrea Marchese (a), Alessio Pecere (a), Anna Maria Di Giacomo (b), Luna Cavigli (a), Flavio D'Ascenzi (a), Serafina Valente (a), Michele Maio (b), Marta Focardi (a), Matteo Cameli (a)
(a) DEPARTMENT OF MEDICAL BIOTECHNOLOGIES, DIVISION OF CARDIOLOGY, UNIVERSITY OF SIENA, SIENA, ITALY; (b) CENTER FOR IMMUNO-ONCOLOGY, MEDICAL ONCOLOGY AND IMMUNOTHERAPY, DEPARTMENT OF ONCOLOGY, UNIVERSITY HOSPITAL & UNIVERSITY OF SIENA, SIENA, ITALY
Background. In the last decades, several therapies were developed in the field of oncology leading to a significant increase in the life expectancy of cancer patients. Recently, a pivotal role has been played by oncological immunotherapy, especially in patients with advanced stage tumors, particularly the class of Immune Checkpoint Inhibitors (ICI). Although these drugs have revolutionized the treatment of some types of tumors, they can cause both cardiac and extracardiac side effects through not completely known mechanisms. Unlike more classical therapies (such as anthracyclines), for which the possibility of an early diagnosis has been widely described by Speckle Tracking Echocardiography (STE), the potential cardiotoxic effects of ICI are still poorly defined. The aim of this study was to evaluate whether ICI treatment can induce a modification of standard and advanced standard echocardiographic parameters, e.g. Global Longitudinal Strain (GLS) and Peak Atrial Longitudinal Strain (PALS) by STE, highlighting a cardiac involvement in a subclinical phase.
Methods. A total of 41 patients with malignant tumors before ICI treatment were prospectively recruited. Patients underwent a complete clinical, biochemical, electrocardiographic, basic and advanced echocardiographic assessment at baseline and at 3, 6, and 12 months after starting treatment. Specifically, the evaluated echocardiographic parameters in-

cluded left ventricular size and function, left atrial volume, right ventricular size and function, and estimated pulmonary pressures. GLS was analyzed by a layer-specific analysis (endocardial (ENDO), epicardial (EPI), and midwall (MESO) GLS). Adverse events were recorded at each evaluation for each patient, including cardiac (myocarditis, pericarditis), all-cause mortality, and extra-cardiac events. Patients with pre-existing heart disease (cardiomyopathies, valvular heart disease, pericarditis), prior cardiac surgery, or cardiac pacemakers were excluded. Univariate logistic regression analysis was performed also to determine any correlation between changes in GLS and PALS over time and the occurrence of extra-cardiac adverse effects.
Results. The population had a mean age of 66±14 years, with females accounting for the 31%. The average baseline ejection fraction was 58±4%. Patients were mainly affected by cutaneous melanoma (44%), pleural mesothelioma (22%), and lung adenocarcinoma (12%). The main ICI treatments were Nivolumab, Pembrolizumab, or a combination of both. Comparing the GLS values at baseline vs follow-up, no significant difference in strain values was detected: -20,10 ± 4,18% vs. -18,34 ± 4,32%, p=0,640; ENDO -22,66 ± 4,95% vs. -20,30 ± 8,10%, p=0,685; MESO -20,01 ± 4,26% vs. -18,45 ± 4,30%, p=0,629; EPI -16,41 ± 8,4% vs. -16,30 ± 4,01%, p=0,182; PALS -29,40 ± 9,72% vs. 27,84 ± 9,23%, p=0,130. The following adverse events were recorded: one fatal myocarditis; extra-cardiac events: 8 cases of bone marrow toxicity with anemia, thrombocytopenia, leukopenia (20%), 4 cases of diarrhea (10%), and 3 cases of cutaneous reactions (7%). There were also 8 deaths (20%). At univariate analysis, the variation of the strain parameter values between baseline and follow-up was not a predictor of cardiac or extra-cardiac adverse events.
Conclusions. Although this is a preliminary result obtained in a pilot population, this study demonstrates that immunotherapy does not significantly impact on cardiac function. Even in patients with extracardiac adverse events or non-cardiovascular mortality, cardiac function, even evaluated with STE, does not appear to change during ICI administration.

A401: UN CASO DI SEVERA CARDIOTOSSICITÀ DA IMMUNO-CHECKPOINT INHIBITORS

Daniela Di Lisi (a), Francesca Castro (a), Domenico Scelfo (a), Luca Ganci (a), Emmanuele Antonio Camarda (a), Sonia Guercio (a), Vincenzo Sucato (a), Egle Corrado (a), Alfredo Ruggero Galassi (a), Giuseppina Novo (a)
(a) DIPARTIMENTO DI PROMOZIONE DELLA SALUTE, MATERNO-INFANTILE, DI MEDICINA INTERNA E SPECIALISTICA DI ECCELLENZA, UNIVERSITÀ DI PALERMO

Introduzione. La miocardite correlata alla terapia con inibitori degli immuno-checkpoint (ICI) rappresenta la complicanza più temibile, gravata da un alto tasso di mortalità. Frequentemente la miocardite può associarsi a sintomi neurologici e a forme di Miastenia Gravis e miosite.
Caso clinico. Una donna di 76 anni affetta da melanoma ulcerato al I dito del piede sinistro e metastatico è stata ricoverata presso la nostra U.O di Cardiologia, a seguito dell'insorgenza di severa astenia, dispnea, edemi declivi e edema periorbitario con ptosi palpebrale bilaterale venti giorni dopo la somministrazione del primo ciclo di Pembrolizumab-Nivolumab. All'ECG: fibrillazione atriale, emiblocco sinistro posteriore e blocco di branca destra. Agli esami ematochimici: aumento significativo degli indici di citolisi epatica, LDH, CPK, Troponina THs, mioglobina ed NT-proBNP. All'Ecocardiogramma Color-Doppler: ventricolo sinistro di dimensioni endocavitarie ai limiti superiori di norma, ipocinesia della parete inferiore basale e media; funzione sistolica ventricolare sinistra lievemente ridotta (FE biplana 44%); riduzione degli indici di deformazione miocardica del ventricolo sinistro (GLS -17,2%). Al monitoraggio ECG-grafico episodi di tachicardia ventricolare non sostenuta. La paziente lamentava inoltre diffuse algie muscolari per cui veniva eseguito dosaggio degli anticorpi anti-AchR e anti-Musk risultati negativi. Nel sospetto clinico-strumentale di miocardite da ICI e miosite periferica, la paziente veniva trattata con Metilprednisolone ad alte dosi (1000 mg/die) con scarso beneficio. Durante la degenza si assisteva a progressivo deterioramento delle condizioni cliniche (ipotensione, oligo-anuria, insufficienza respiratoria) con conseguente necessità di supporto inotropo, nonché di ventilazione non invasiva. Il quadro di instabilità emodinamica non consentiva il ricorso a test diagnostici di conferma, quali la RMC, e rendeva necessario il trasferimento in Rianimazione, dove veniva eseguita terapia immunosoppressiva di II linea in associazione a plasmaferesi. A causa, però, della severa compromissione del profilo clinico-emodinamico, la paziente andava incontro ad exitus.
Discussione. In letteratura sono stati descritti casi similari di sovrapposizione della miocardite da ICI con miosite/Miastenia Gravis, frequentemente associati a sieronegatività anticorpale. Il trattamento della tossicità neurologica non sempre è facile. Il nostro caso sottolinea l'importanza di una valutazione globale (cardiologica e neurologica) e di una diagnosi e trattamento tempestivi. Il monitoraggio ECG-grafico e dei livelli di troponina sono fondamentali durante la terapia con ICI per poter diagnosticare precocemente l'eventuale insorgenza di effetti tossici cardiovascolari. L'ecocardiogramma e la risonanza magnetica rappresentano il gold standard nella diagnosi non invasiva di miocardite. Pur tuttavia, nei pazienti con instabilità emodinamica e alto sospetto clinico di miocardite da immunoterapia, un trattamento tempestivo con immunosoppressori è fortemente consigliato. In caso di miocardite da ICI refrattaria al trattamento di I linea con corticosteroidi, il ricorso ad altre opzioni terapeutiche (quali immunosoppressori di II linea o plasmaferesi) deve essere attentamente valutato da parte di un team multidisciplinare.
Conclusione. La terapia con ICI sta sicuramente rivoluzionando la storia naturale di molti tumori, tuttavia, a causa della coesistenza di effetti benefici e cardiotossici, la diagnosi e il trattamento di queste forme di miocardite rappresentano una sfida per il cardiologo clinico, soprattutto nei casi di overlap miocardite/miosite periferica e/o altri sintomi neurologici.

A402: THE IMPACT OF CARDIOVASCULAR RISK FACTORS ON VENOUS AND ARTERIAL THROMBOTIC RISK ASSESSMENT IN PATIENTS WITH POLYCYTHEMIA VERA:A SINGLE CENTER RETROSPECTIVE STUDY

Giancarlo Buccheri (a), Daniela Di Lisi (a), Riccardo Tomasello (b), Giuseppe Vella (c), Grazia Gambino (a), Giuseppe Damerino (a), Giusy Sausa (a), Marco Santoro (b), Vincenzo Sucato (a), Egle Corrado (a), Alfredo Ruggero Galassi (a), Giuseppina Novo (a)
(a) UNIVERSITÀ DEGLI STUDI DI PALERMO - MALATTIE DELL'APPARATO CARDIOVASCOLARE; (b) UNIVERSITÀDEGLI STUDI DI PALERMO - EMATOLOGIA; (c) UNIVERSITÀ DEGÒI STUDI DI PALERMO - IGIENE E MEDICINA PREVENTIVA

Introduzione. La Policitemia Vera (PV) è una neoplasia mieloproliferativa cronica caratterizzata da una elevata incidenza di eventi trombotici arteriosi e venosi (TE). Attualmente, il rischio tromboembolico nei pazienti con PV viene stimato in: basso rischio (età <60 anni e assenza di precedenti trombosi) ed alto rischio (età>60 anni e/o precedenti trombosi). Studi suggeriscono che i fattori di rischio cardiovascolare (CVRF) incidono sulla storia naturale e prognosi di tale patologia.
Obiettivi. Dimostrare una correlazione diretta tra la presenza di CVRF e l'incidenza di TE nei pazienti con PV; identificare una nuova classe di rischio "intermedio" che possa consentire una più precisa stratificazione del rischio tromboembolico di questa popolazione.
Materiali e metodi. È stato condotto uno studio osservazionale, retrospettivo, monocentrico, condotto presso la AOUP "Paolo Giaccone" di Palermo, su una coorte di 195 pazienti con diagnosi di PV, 123 (63%) maschi e 72 (37%) femmine di età mediana alla diagnosi 61 anni (Q1;Q3 51-70 anni). Al momento della raccolta dei dati, 85 pazienti (44%) erano classificati come high risk, mentre 110 (56%) come low risk. Utilizzando un modello di Cox, è stata eseguita un'analisi multivariata esaminando l'associazione tra eventi vascolari pregressi (PVE), Età>60 anni e un indicatore composito di CVRF comprendente: obesità, fumo, cardiopatia ischemica, stenosi carotidea, arteropatia obliterante periferica. Infine, è stato calcolato un punteggio di rischio individuale per ogni paziente utilizzando i coefficienti ottenuti dal modello di regressione di Cox, stratificando i pazienti in tre gruppi di rischio in base alla presenza o meno di uno o più tra gli items sopracitati (basso: no item, intermedio: almeno 1 item, alto; almeno 2 o più items).
Risultati. Durante il periodo di osservazione, 27 pazienti hanno manifestato un evento cardiovascolare. La stratificazione del rischio ha rivelato che, nel gruppo a basso rischio il tasso di eventi cardiovascolari è stato del 2% (1 su 50 pazienti); nel gruppo intermedio il tasso è stato del 11,1% (9 su 81 pazienti); mentre nel gruppo ad alto rischio il tasso è stato del 26,6% (17 su 64 pazienti). Un test di Fisher ha confermato una significativa associazione tra la stratificazione del rischio e l'incidenza di TE (p-value=0.0005353). Il modello di Cox ha ulteriormente evidenziato che la presenza di PVE era associata a un rischio 2,8 volte maggiore di TE (HR=2.807), mentre la presenza di almeno uno tra i CVRF dell'item composito mostrava un rischio triplicato (HR=3.362), infine l'età>60 anni era associata a un rischio aumentato di 2,3 volte (HR=2.295).
Conclusioni. I risultati del nostro studio suggeriscono che la stratificazione del rischio in 3 classi, che includa un indicatore dei CVRF, è una metodologia efficace per identificare i pazienti con PV a maggior rischio di TE, anche quando questi verrebbero classificati come low risk PV. Questi risultati, limitatamente alla ridotta coorte di pazienti inclusi nello studio, ed alla natura retrospettiva della nostra analisi, sottolineano l'importanza di un'accurata valutazione del rischio cardiovascolare in questa popolazione. Successivi studi su coorti più estese, multicentrici e prospettici sono necessari per confermare i nostri risultati.

A403: LONG TERM PROGNOSTIC IMPACT OF SPAP ON THE RISK OF DEVELOPING ANTHRACYCLINE-RELATED CARDIOTOXICITY.

Marco Bernardi (a), Erica Rocco (b), Gianmarco Sarto (a), Beatrice Simeone (b), Maria Pia Pennino (c), Francesco Versaci (d), Sebastiano Sciarretta (b)
(a) SCUOLA DI SPECIALIZZAZIONE IN MALATTIE DELL'APPARATO CARDIOVASCOLARE, SAPIENZA UNIVERSITÀ DI ROMA; (b) UOC DI UTIC/CARDIOLOGIA UNIVERSITARIA, ISTITUTO ICOT DI LATINA, SAPIENZA UNIVERSITÀ DI ROMA, "POLO PONTINO"; (c) FACOLTA DI FARMACIA E MEDICINA, SAPIENZA UNIVERSITÀ DI ROMA, POLO PONTINO; (d) UOC DI CARDIOLOGIA, OSPEDALE SANTA MARIA GORETTI, LATINA

Introduction. Anthracycline-related cardiotoxicity is a clinically relevant issue. In cardio-oncology, it is pivotal to stratify the risk of cardiotoxicity to choose appropriate strategies of cardioprotection and follow-up tailored to patient features. Although numerous risk stratification scores are yet available, they have proven suboptimal in certain clinical settin-

gs. The identification of new predictors of cardiotoxicity is therefore one of the most active areas of research in cardio-oncology.
Aim. The aim of the present study was to identify new potential predictors of cardiotoxicity in order to achieve a more accurate prognosis stratification of oncological patients treated with anthracyclines.
Methods. Our retrospective analysis included 170 patients with hematological disorders who were treated with anthracyclines. Patients were evaluated before and after chemotherapy, during a median follow-up of approximately 1 year (369 days), examining several potential predictors including: biometric, laboratory, and ecocardiographic parameters; cardiovascular risk factors; type of hematological disease; and type of chemotherapy. The development of cardiotoxicity was evaluated through surrogate endpoints, including changes in ejection fraction and end-diastolic diameter, new-onset diastolic dysfunction, and composite endpoints.
Results. Our population was mainly male (60%), with a mean age of 57.6 years and a low prevalence of cardiovascular risk factors. After chemotherapy, both ejection fraction and end-diastolic diameter were reduced. Among all analyzed predictors, a higher sPAP (systolic pulmonary artery pressure) value was shown to positively correlate with a composite outcome (OR 1.059, p=0.042), given by ejection fraction reduction, end-diastolic diameter increase, or new-onset diastolic dysfunction. This correlation remained marginally significant after adjusting for gender and age in a multivariate analysis (OR 1.058, p=0.054). Moreover, ROC analysis showed a small discriminative ability of sPAP (AUC 0.6, CI 0.51-0.66), with the best cutoff value for correct discrimination of =/>32 mmHg. Subsequently, we aimed at assessing the degree of correlation between the three single constituents of the composite outcome and sPAP values. A trend toward a potential correlation between PAPs and ejection fraction reduction post-chemotherapy was identified, despite the absence of a statistically significant correlation. The study also emphasized that there was a strong correlation between ischemic heart disease, advanced age, and male sex and higher sPAP values at baseline. Conversely, higher tricuspid annular plane systolic excursion (TAPSE) values were found to be related to lower sPAP values.
Conclusions. These results put the basis for an accurate echocardiographic assessment of sPAP and right ventricle in oncological patients undergoing anthracycline treatment in order to better stratify their cardiovascular risk. Future larger studies are needed to further validate these findings.

A404: GUIDELINE-DIRECTED MEDICAL THERAPHY IN PATIENTS WITH HEART FAILURE AND INCIDENT CANCER

Silvia Tanda (b, c), Giacomo Tini (a), Matteo Toma (c),
Allegra Battistoni (a), Beatrice Musumeci (a), Emanuele Barbato (a),
Italo Porto (b, c), Marco Canepa (b, c), Pietro Ameri (b, c)
(a) CARDIOLOGY, DEPARTMENT OF CLINAL AND MOLECULAR MEDICINE, SAPIENZA UNIVERSITY OF ROME, AZIENDA OSPEDALIERA UNIVERSITARIA SANT'ANDREA, ROME, ITALY; (b) DEPARTMENT OF INTERNAL MEDICINE, UNIVERSITY OF GENOVA, GENOVA, ITALY; (c) CARDIOVASCULAR DISEASE UNIT, IRCCS OSPEDALE POLICLINICO SAN MARTINO, GENOVA

Introduction. It has been postulated that cancer hampers the delivery of guideline-directed medical therapy (GDMT) for heart failure (HF). However, few data are available in this regard, especially in the case of a new diagnosis (incident) of cancer.
Methods. We retrospectively reviewed the medical records of the patients evaluated at our HF Outpatient Clinic between 2010 and 2019 and selected those with a left ventricular ejection fraction <50% and at least 2 visits ≥3 months apart with complete information about GDMT. We assessed the prescription of GDMT – beta blockers (BB), renin-angiotensin system inhibitors (RASi) and mineralocorticoid antagonists (MRA) – at the time of the last HF evaluation and compared it between patients with and without incident cancer. For those with incident cancer, we also analysed the modifications of GDMT over the year after cancer diagnosis.
Results. Of 464 HF patients meeting the inclusion criteria, 39 (8%) had incident cancer. Subjects with and without incident cancer had similar characteristics, apart from a lower prevalence of chronic kidney disease (13% vs 29%, p=0.02) and a longer follow-up (8 [6; 17] vs 4 [2; 7] years, p<0.001) in the former than in the latter. There were no statistical differences in GDMT between patients with and without incident cancer at the last evaluation, although BB (78% vs 95%, p=0.08) and RASi (72% vs 82%, p=0.10) were numerically less used in those with incident cancer and there was a trend for a more frequent prescription of doses ≥50% of the target one in cancer than in non-cancer patients (59% vs 43%, p=0.06 for BB; and 64% vs 49%, p=0.09 for RASi). In the year following cancer diagnosis, 2 of 33 patients who had been diagnosed with cancer while on BB had a down-titration to a dosage <50%; 2 of 27 on RASi at cancer diagnosis stopped therapy, and another 3 had a down-titration to a dosage <50%; and 4 of 19 on MRA stopped therapy (Figure). Four patients were initiated on loop diuretic and no ICD was implanted following cancer diagnosis. Incident cancer was associated with non-cardiovascular death (OR 2.9, 95%CI [1.1-7.5], p=0.02), but not with cardiovascular death (OR 0.8, 95%CI [0.4-1.9], p=0.67).
Discussion. These single-centre study suggests that, on average, cancer does not hinder delivery of GDMT for HF, although down-titration or discontinuation of HF medications may occur in individual cases.

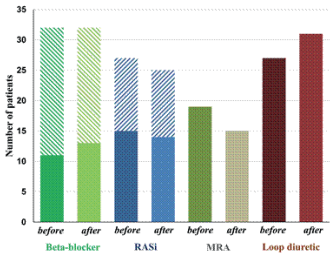

A405: MARKED ST-SEGMENT ELEVATION CAUSED BY PRIMARY CARDIAC LYMPHOMA

Saverio Tremamunno (a), Nello Cambise (a), Lorenzo Tinti (a),
Antonio Di Renzo (a), Angelo Giuseppe Marino (a),
Antonio De Vita (a), Francesca Augusta Gabrielli (a),
Priscilla Lamendola (a), Antonella Lombardo (a),
Gaetano Antonio Lanza (a)
(a) DEPARTMENT OF CARDIOVASCULAR AND PNEUMOLOGICAL SCIENCES - CATHOLIC UNIVERSITY OF THE SACRED HEART - FONDAZIONE POLICLINICO UNIVERISTARIO "A. GEMELLI" IRCCS

An 88-year-old male was referred to our cardiac outpatient clinic due to recent occurrence of pre-syncopal episodes, with a single syncopal episode. The ECG showed normal sinus rhythm with frequent premature ventricular and supraventricular complexes and abnormal and persisting convex ST segment elevation with negative T waves in anterior leads (V_1-V_3) (Fig. Panel A). The patient did not refer any chest pain and serial high-sensitivity cardiac troponin I serum levels were consistently within the normal range. Twenty-four-hour ECG Holter monitoring (HM) revealed several paroxysms of atrial flutter (AFL), with some pauses>3.0 sec at the interruption of tachy-arrhythmias before sinus rhythm restoration. Trans-thoracic colour-Doppler echocardiogram, cardiac computed tomography (cCT) and cardiac magnetic resonance imaging (cMRI) showed a cardiac mass infiltrating the free wall and outflow tract of the right ventricle, with protrusion into the right cavity (without significant flow obstruction) and spreading into the anterior pericardial space with mild effusion (Fig. Panel B; asterisks and arrows). Endomyocardial biopsy provided the diagnosis of NOS high grade B-cell non-Hodgkin primary cardiac lymphoma (Vimentin+, CD20+, BCL2+, BCL6+, MYC+, CD3-, CD5-, CD10-, CD23-, CD30-, KI67 90%). Chemotherapy with rituximab, cyclophosphamide, vincristine and prednisolone was started, which resulted in an early and considerable reduction of the cardiac mass, as assessed by both transthoracic echocardiogram and cCT, one month after treatment (Fig. Panel C; asterisks). Notably, ECG showed ST segment normalization, with a residual T wave inversion in anterior leads (Fig. Panel D). The patient did not refer any other episode of presyncope/syncope. A twenty-four-hour ECG HM did not show any recurrence of atrial flutter nor other tachy-arrhythmias, suggesting a role of the infiltrating cardiac tumour in the mechanisms responsible for the arrhythmia.

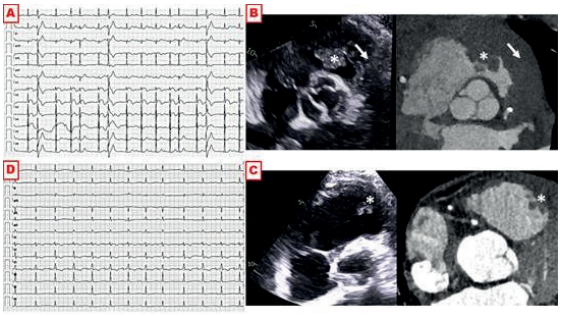

A406: AORTIC VALVE FIBROELASTOMA PRESENTING WITH MYOCARDIAL INFARCTION WITH NON OBSTRUCTIVE CORONARY ARTERIES (MINOCA)

Rocco Tritto (a), Martino Pepe (a), Maria Ludovica Naccarati (a),
Gianluigi Novielli (a), Simona Quarta (a), Daniele De Feo (a), Venanzio Francesco Napoli (a), Andrea Marzullo (b), Marco Matteo Ciccone (a)
(a) CARDIOVASCULAR DISEASES SECTION, DEPARTMENT OF INTERDISCIPLINARY MEDICINE (DIM), UNIVERSITY OF BARI "ALDO MORO"; (b) MOLECULAR PATHOLOGY SECTION, DEPARTMENT OF PRECISION AND REGENERATIVE MEDICINE AND IONIAN AREA (DIMEPRE-J), UNIVERSITY OF BARI "ALDO MORO"

A 35-year-old woman with known mitral valve prolapse and history of migraine presented to the Emergency Department because of several episodes of chest pain in the previous three days arising at rest and followed by spontaneous relief within few minutes. No electrocardiographic abnormalities were found but an oscillating trend of high sensitivity cardiac troponin I (hs-cTnI) was reported. After an urgent co-

ronary angiography which showed non obstructive coronary artery disease, the patient was referred to intensive care unit (ICU) with a working diagnosis of myocardial infarction with non-obstructive coronary arteries (MINOCA). Hence, an integrated imaging assessment was performed: trans-thoracic echocardiogram (TTE) and trans-esophageal echocardiogram (TEE) excluded segmental wall motion abnormalities and pericardial effusion but revealed a round-shaped hyperechoic floating mass attached to the aortic valve. Cardiac nuclear magnetic resonance (CMR) allowed to rule out an acute myocarditis and demonstrated on the T1-weightened imaging an isointense mass on the right cusp of the aortic valve. During the assessment of LGE in phase-sensitive inversion recovery (PSIR) the mass appeared hyperintense. The hypothesis of repetitive episodes of myocardial ischemia due to the transient obstruction of the coronary ostium determined by the pedunculated mass was formulated. After successful surgical excision, the histopathological examination of the specimen revealed mesenchymal tissue with the characteristics of cardiac papillary fibroelastoma (CPF).

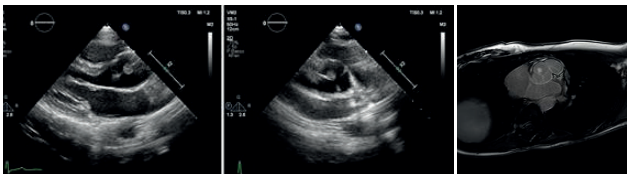

A407: SCOMPENSO CARDIACO ACUTO IN PAZIENTE CON CARCINOMA UROTELIALE TRATTATO CON CABOZANTINIB E DURVALUMAB

Francesco Mautone (a), Maurizio Pesolo (a), Debora Ruggeri (a), Grazia Casavecchia (b), Natale Daniele Brunetti (a, b)
(a) UNIVERSITÀ DI FOGGIA; (b) OSPEDALI RIUNITI FOGGIA

Introduzione. Per cardiotossicità si intende un danno al muscolo cardiaco correlato al trattamento chemioterapico. Questo può causare aritmie e scompenso cardiaco, talora fatali.

Case report. Paziente di 49 anni, diabetico, senza ulteriori fattori di rischio cardiovascolare. Affetto da Carcinoma uroteliale, in trattamento chemioterapico da marzo 2021 con Durvalumab e Cabozantinib (12 cicli) ed arruolato nello studio ARCADIA (utilizzo di Cabozantinib più Durvalumab in pazienti con carcinoma della vescica avanzato e trattato con chemioterapia, di istologia uroteliale e non uroteliale). Ad aprile 2023, viene sospeso il Durvalumab per aumento degli enzimi pancreatici (lipasi 150 UI/L; amilasi 300 UI/L) e per la verosimile genesi autoimmune della pancreatite. In data 07/05/2023 per l'insorgenza di epigastralgia, il paziente si reca in P.S., dove viene eseguito ECG con riscontro di tachicardia sinusale e sopraslivellamento del tratto ST in sede inferiore. Agli esami ematochimici: HS–TnI 27883,8 ng/dl.
Si decide di eseguire esame coronarografico in urgenza che mostra coronarie indenni da lesioni angiograficamente significative. Viene trasferito nell'Unità di Terapia Intensiva Coronarica, dove esegue ecocardiogramma con riscontro di severa disfunzione sistolica ventricolare sinistra (FE 25%). Agli esami ematochimici: globuli bianchi 19000/uL; PCR 28 mg/L; VES 117 mm/h. Il quadro evolve, in breve tempo, con un'insufficienza renale acuta (crea 10,5 mg/dl; e-GFR 9,3) e successivo Exitus.

Conclusioni. Questo caso dimostra come la cardiotossicità indotta dai chemioterapici può avere conseguenze temibili, quali lo scompenso cardiaco acuto, correlato ad un altissimo tasso di mortalità.

CARDIOPATIA ISCHEMICA

A408: FEASIBILITY, SAFETY AND PROGNOSTIC IMPLICATIONS OF ACETYLCHOLINE PROVOCATIVE TEST IN PATIENTS WITH MYOCARDIAL BRIDGE

Giuseppe Ciliberti (a), Renzo Laborante (a), Attilio Restivo (a), Fabio Casamassima (a), Gaetano Rizzo (a), Francesco Burzotta (a), Carlo Trani (a), Filippo Crea (a), Domenico D'Amario (b)
(a) UNIVERSITÀ CATTOLICA DEL SACRO CUORE, DIPARTIMENTO DI SCIENZE CARDIOVASCOLARI, ROMA, ITALIA; (b) UNIVERSITÀ DEL PIEMONTE ORIENTALE, DIPARTIMENTO DI MEDICINA TRANSLAZIONALE, AZIENDA OSPEDALIERO-UNIVERSITARIA MAGGIORE DELLA CARITÀ

Introduction. Among several pathophysiological mechanisms underlying myocardial bridge (MB)-related ischemia, coronary artery spasm (CAS) may play a pivotal role in promoting anginal symptoms and adverse cardiac events. Invasive acetylcholine (Ach) provocative test may unmask CAS and implement personalized therapies. However, evidence supporting the safety and relevance of this test is still lacking in MB patients. Therefore, the aim of our study is to assess the feasibility, safety, and prognostic role of invasive Ach test in MB patients.

Methods. This study is a pre-specified subgroup analysis of the "RIALTO", an ambispective and observational registry (ClinicalTrials.gov Identifier: NCT05111418) of patients with angiographic evidence of MB. Among the 444 patients enrolled in the registry, 73 underwent the intracoronary Ach test and were considered in this study. Ach test was considered positive for epicardial CAS in the presence of focal or diffuse epicardial coronary diameter reduction ≥90%, associated with the occurrence of anginal symptoms and ischemic ECG shifts. Microvascular CAS was diagnosed when anginal symptoms and typical ischemic ST-segment changes developed in the absence of epicardial coronary constriction. The incidence of major and minor complications was considered as a safety endpoint. Primary and secondary endpoints were, respectively, the incidence of major adverse cardiac events [MACE, defined as the composite of cardiac death, myocardial infarction and cardiac hospitalization] and the rate of significant angina [defined as Seattle Angina Questionnaire (SAQ) Angina Summary Score ≤70] in patients with and without CAS, up to 24 months follow-up (FUP).

Results. CAS was diagnosed in 65.8% of MB patients. The most common type and site of spasm was a focal constriction of the mid left anterior descending (LAD) coronary artery, which was also the most common location of MB. No fatal or major complications were reported, while 12.3% of patients experienced minor complications (transient episodes of brady- and tachyarrhythmia). The rate of MACE was significantly higher in patients with a positive Ach test (Ach+ patients) without calcium channel blockers (CCBs) prescription at discharge, compared with patients with a negative Ach test (Ach- patients) and compared with Ach+ patients receiving CCBs [45% vs. 20% and 9%, respectively, p<0.01]. The rate of patients with significant angina (SAQ ≤70) was significantly higher in the Ach+ group compared with the Ach- group (47.7% vs. 25%, log-rank=0.04).

Conclusions. CAS may be frequently detected in patients with MB. Invasive Ach provocative test may unmask CAS, one of the pivotal pathophysiological mechanisms underlying MB-related ischemia (impaired endothelium-dependent vasodilatation). This assessment proved to be safe and feasible, and it was able to identify a subgroup of patients with a higher anginal burden, for whom a targeted therapy with CCBs may reduce the incidence of adverse cardiac events.

A409: FAMILIAL RISK OF PRINZMETAL VARIANT ANGINA: A NATIONWIDE FAMILY STUDY IN SWEDEN

Fabrizio Ricci (a, b), Behzad Banihashemi (a), Mirnabi Pirouzifard (a), Jan Sundquist (a), Kristina Sundquist (a), Richard Sutton (c), Artur Fedorowski (a, d), Bengt Zoller (a)
(a) LUND UNIVERSITY, MALMÖ, SWEDEN; (b) UNIVERSITY OF CHIETI-PESCARA, ITALY; (c) IMPERIAL COLLEGE, LONDON, UK; (d) KAROLINSKA INSTITUTE, STOCKHOLM, SWEDEN

Background. Vasospastic angina (VSA) is a complex coronary vasomotor disorder associated with increased risk of myocardial infarction and sudden death. Despite considerable advances in understanding VSA pathophysiology, the interplay between genetic and environmental factors remains elusive.

Objectives. To determine familial VSA risk among first-degree relatives of affected individuals.

Methods. A population-based multigenerational cohort study was conducted, including full-sibling pairs born to Swedish parents between 1932 and 2018. Register-based diagnoses among relatives were ascertained through linkage to the Swedish Multigeneration Register and National Patient Register. Incidence rate ratios (IRRs) and adjusted hazard ratios (HRs) were calculated for relatives of individuals with VSA compared with relatives of individuals without VSA.

Results. The total study population included 5,764,770 individuals. Overall, 3,461 (0.06%) unique individuals (median age at disease onset 59 years, IQR:63-76) were diagnosed with VSA. Of these, 2,236 (64.61%) were females. The incidence rate of VSA for individuals with an affected sibling was 0.31 (95%CI:0.24-0.42) per 1000 person-years compared with 0.04 (95%CI:0.04-0.04) per 1000 person-years for those without an affected sibling, yielding an IRR of 7.58 (95%CI:5.71-10.07). The risk of VSA for siblings with an affected sibling was significantly increased in the fully adjusted model (HR: 2.56;95%CI:1.73-3.79). No increased risk of VSA was observed in spouses of affected individuals (HR 0.63;95%CI:0.19-2.09).

Conclusions. In this nationwide family study, we identified high familial risk for VSA independent of shared environmental risk factors. Our findings indicate that VSA tends to cluster in families, emphasizing the need to explore genetic and non-genetic factors that may contribute.

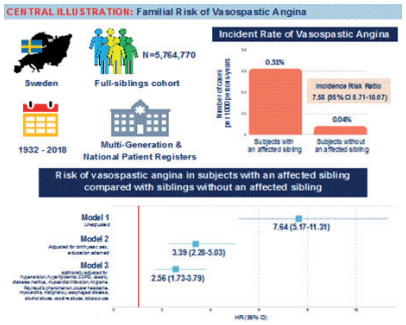

A410: PROGNOSTIC ROLE OF IN-HOSPITAL BLEEDING IN ACUTE CORONARY SYNDROME PATIENTS: INSIGHTS FROM PRAISE REGISTRY

Marco Bernardi (d), Luigi Spadafora (d), Matteo Betti (b), Giuseppe Biondi-Zoccai (a), Fabrizio D'Ascenzo (c)
(a) DEPARTMENT OF MEDICAL-SURGICAL SCIENCES AND BIOTECHNOLOGIES, SAPIENZA UNIVERSITY OF ROME, LATINA, ITALY; (b) DEPARTMENT OF CLINICAL SCIENCES AND COMMUNITY HEALTH, CARDIOVASCULAR SECTION, UNIVERSITY OF MILAN, MILAN, ITALY; (c) DEPARTMENT OF MEDICAL SCIENCES, UNIVERSITY OF TURIN, TURIN, ITALY; (d) SCUOLA DI SPECIALIZZAZIONE IN MALATTIE DELL'APPARATO CARDIOVASCOLARE, SAPIENZA UNIVERSITÀ DI ROMA

Introduction. Prediction of long-term outcomes of acute coronary syndrome (ACS) patients remains challenging, and the prognostic role of in-hospital bleeding (IHB) is still unclear.
Methods. We conducted a retrospective analysis on 23,270 patients enrolled in the international PRAISE registry and discharged after an ACS between 2003 and 2019. We aimed to detail differences among patients with and without IHB, with a focus on patient and procedural features, discharge medications, and 1-year outcomes. The primary endpoint was the composite of death, myocardial infarction, or major bleeding at the 1-year mark.
Results. Out of the total cohort, 1,060 patients experienced IHB, while 18,765 did not. Patients with IHB tended to be older, more frequently female (p<0.001), and exhibited a higher prevalence of cardiovascular risk factors, including hypertension and a history of prior cardiovascular events (p<0.001). Conversely, patients without IHB had a lower burden of comorbidities and underwent more frequent percutaneous coronary revascularization procedures, with a significantly higher proportion of radial access (p<0.001). One-year follow-up data showed that patients with IHB had significantly higher rates of mortality, reinfarction, major bleeding, non-fatal major bleeding, and composite adverse outcomes compared to those without IHB (all p<0.001, all OR>1). Bivariate and multivariate logistic regression analyses confirmed a strong association between IHB and adverse clinical outcomes, even after adjusting for various covariates (all p<0.001).
Conclusions. In-hospital bleeding during ACS hospitalization emerges as a robust predictor of long-term adverse outcomes. Developing new prognostic and predictive scoring systems using ACS hospitalization data is crucial for achieving more accurate and precise insights into long-term prognosis challenges.

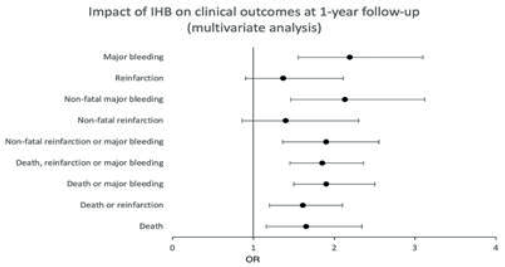

Figure 1. Multivariate analysis appraising the impact of IHB on clinical outcomes at 1-year follow-up after discharge.
IHB, in-hospital bleeding.

A411: IMAGING GUIDANCE TO PERCUTANEOUS REVASCULARIZATION IN CORONARY CHRONIC TOTAL OCCLUSION: A SYSTEMATIC REVIEW AND META-ANALYSIS

Giandomenico Bisaccia (c, d), John P. Greenwood (a, b), Fabrizio Ricci (d), Sabina Gallina (d), Chiara Bucciarelli-Ducci (c, e)
(a) LEEDS INSTITUTE OF CARDIOVASCULAR AND METABOLIC MEDICINE, UNIVERSITY OF LEEDS, LEEDS, UNITED KINGDOM; (b) DEPARTMENT OF CARDIOLOGY, LEEDS TEACHING HOSPITAL NHS TRUST, LEEDS, UNITED KINGDOM; (c) ROYAL BROMPTON AND HAREFIELD HOSPITALS, GUYS' & ST THOMAS NHS TRUST, LONDON, UNITED KINGDOM; (d) DIPARTIMENTO DI NEUROSCIENZE, IMAGING E SCIENZE CLINICHE, UNIVERSITÀ «G. D'ANNUNZIO» DI CHIETI-PESCARA, CHIETI, ITALIA; (e) SCHOOL OF BIOMEDICAL ENGINEERING AND IMAGING SCIENCES, FACULTY OF LIFE SCIENCES AND MEDICINE, KING'S COLLEGE UNIVERSITY, LONDON, UNITED KINGDOM

Background andAims. Whether recanalization of coronary chronic total occlusions (CTO) leads to net clinical benefit to patients is uncertain. We set out to investigate the use of imaging modalities to guide percutaneous recanalization of coronary chronic total occlusions (PCI-CTO).
Methods. We conducted a planned systematic review and meta-analysis of studies involving patients undergoing PCI-CTO. We collected information regarding study-level use of preprocedural stress testing, and noted cardiovascular outcomes and clinical endpoints at follow-up in this patient population. The review primary endpoint was major adverse cardiac events (MACE, cardiovascular death, nonfatal myocardial infarction (MI) and target vessel revascularization (TVR)) with a secondary composite endpoint of all-cause death and nonfatal MI. Secondary endpoints were individual MACE components along with changes in angina burden, LV ejection fraction, LV end-systolic volume, ischemic burden, and infarct extent after PCI. We pooled incidence rates, odds ratios (OR) or standardized mean differences (SMD), where appropriate, along with 95% confidence intervals (95%CI) through inverse variance meta-analysis. This study is registered with PROSPERO (CRD42023417014).
Results. Of 1264 publications retrieved, 31 studies (26 observational and 5 randomized) were finally included for a total of 7260 patients. Guidance to PCI-CTO varied greatly among included studies, with only a minority implementing routine preprocedural inducible ischemia and myocardial viability assessment. At a median of 3.1 years (range 1-5 years), MACE occurred at a rate of 7.8 events per 100 patient-years. Compared with patients with no clear imaging indication to PCI-CTO (2 studies, 219 of 2960 patients), those with either inducible ischemia or preserved viability in the CTO territory had reduced odds of death and MI (OR, 0.3, 95%CI0.2-0.5). PCI-CTO was associated with sensible increases in SAQ score, proportion of patients free from angina, LV systolic function, and myocardial perfusion, with no change in fibrosis burden. At meta-regression analysis, a greater systolic function benefit was found for studies enrolling patients with lower average baseline LVEF (R^2=63%, p<0.0001).
Conclusions. Most of the evidence on imaging-guided PCI-CTO derives from observational studies not restricting the procedure to patients with preserved viability and/or inducible ischemia in the CTO territory. Future randomized clinical trials are to be prioritized to elucidate whether ischemia and viability-guided PCI-CTO leads to improved patient outcomes compared with optimized medical therapy.

A412: EFFETTO DEI MIRNA SUL RIMODELLAMENTO VENTRICOLARE E SULLA FIBROSI MIOCARDICA IN PAZIENTI CON INFARTO MIOCARDICO ACUTO

Federica Marzano (a), Christian Basile (a), Angela Colella (a), Alfonsina Chirico (a), Vincenza Abbate (a), Gaetano Asile (a), Simona Soriano (a), Simone Agizza (a), Fabrizio Perrone Filardi (a), Paola Gargiulo (a), Pasquale Perrone Filardi (a), Stefania Paolillo (a)
(a) UNIVERSITÀ DEGLI STUDI DI NAPOLI FEDERICO II

Background. L'infarto miocardico acuto è la più frequente causa di scompenso cardiaco. Una quota significativa dei pazienti infartuati va incontro ad un progressivo rimodellamento ventricolare, che determina dilatazione e disfunzione contrattile, influendo negativamente sulla prognosi a distanza, specialmente nel caso di infarto miocardico con sopraslivellamento del segmento ST (STEMI). I microRNA (miRNA) sono piccoli RNA non codificanti che regolano l'espressione genica. Recenti evidenze suggeriscono che alcuni miRNA possano svolgere un importante ruolo diagnostico, prognostico e terapeutico nelle patologie cardiovascolari, e in particolare nel rimodellamento ventricolare negativo, mediante la modulazione della fibrosi miocardica. Lo strain miocardico (global longitudinal strain, GLS) è risultato un forte predittore di fibrosi miocardica. Scopo di questo studio è pertanto definire se il rimodellamento ventricolare e lo sviluppo di fibrosi, valutato tramite strain, correlino con l'espressione e i livelli di miRNA in pazienti con STEMI sottoposti con successo ad angioplastica coronarica.
Metodi. Sono stati arruolati nel presente studio 109 pazienti (casi) con STEMI e significativa disfunzione ventricolare sinistra alla dimissione (FE <45%) e 31 pazienti (controlli) con STEMI senza disfunzione ventricolare sinistra significativa (FE>45%) trattati con successo con angioplastica primaria. Sono state registrate basalmente le caratteristiche cliniche e demografiche, i dati coronarografici, laboratoristici, ed elettrocardiografici. I pazienti sono stati sottoposti ad ecocardiogramma transtoracico per lo studio della disfunzione sistolica e prelievo di sangue venoso per il dosaggio dei miRNA circolanti.
Risultati. Sono stati analizzati 109 casi (età media 65.0 anni, 71.6% maschi) con FE media di 41% e 31 controlli (età media 57.8 anni, 80.6% maschi) con FE media di 54%. Al basale, i casi presentavano indici di miocardionecrosi significativamente più alti, all'arrivo e al picco della curva, rispetto ai controlli. All'ecocardiogramma transtoracico basale, i casi presentavano più frequentemente disfunzione diastolica, rimodellamento ventricolare e sovraccarico polmonare rispetto ai controlli. 8 miRNAs sono stati identificati come differenzialmente espressi tra casi e controlli (miR-18b-5p; miR-375-5p; miR-208a-3p; miR-483-5p; miR-18a-5p; miR-331-3p; miR-192-5p; miR-1260a) (p-value <0.05). In particolare, miR-192-5p correlava inversamente con il GLS (β=-1.9, p<0.001), mentre miR-1260a correlava in maniera diretta con il GLS (β=0.52, p=0.004)
Conclusioni. I dati ottenuti supportano l'ipotesi che la concentrazione di specifici miRNA possa essere un fattore aggiuntivo nella valutazione della fibrosi miocardica dopo sindrome coronarica acuta.

A413: PROGNOSTIC VALUE OF COMBINED FRACTIONAL FLOW RESERVE AND PRESSURE-BOUNDED CORONARY FLOW RESERVE

Domenico Galante (a, b), Antonio Maria Leone (b), Stefano Migliaro (e), Federico Di Giusto (a), Gianluca Anastasia (a), Edoardo Petrolati (a), Andrea Viceré (c), Pio Cialdella (c), Eloisa Basile (d), Domenico D'Amario (f), Rocco Vergallo (g), Rocco Antonio Montone (a), Antonino Buffon (a), Enrico Romagnoli (a), Cristina Aurigemma (a), Francesco Burzotta (a), Carlo Trani (a), Filippo Crea (a, b)

(a) UNIVERSITÀ CATTOLICA DEL SACRO CUORE - POLICLINICO A.GEMELLI IRCSS -ROMA; (b) FATEBENEFRATELLI ISOLA TIBERINA - GEMELLI ISOLA; (c) POLICLINICO CASILINO - ROMA; (d) OSPEDALE GENERALE REGIONALE F. MIULLI ACQUAVIVA DELLE FONTI; (e) AURELIA HOSPITAL - ROMA; (f) AZIENDA OSPEDALIERO UNIVERSITARIA MAGGIORE DELLA CARITÀ NOVARA; (g) OSPEDALE POLICLINICO SAN MARTINO IRCSS, GENOVA

Background. Coronary flow reserve (CFR) has an emerging role to predict outcome in patients with and without flow-limiting stenoses. However, the role of its surrogate pressure bounded-CFR (Pb-CFR) is controversial. We investigated the usefulness of combined use of fractional flow reserve (FFR) and Pb-CFR to predict outcomes.

Methods. This is a sub-study of the PROPHET-FFR trial, including patients with chronic coronary syndrome and functionally tested coronary lesions. Patients were divided into four groups based on positive or negative FFR (cut-off 0.80) and preserved (lower boundary ≥2) or reduced (upper boundary <2) Pb-CFR: Group1 FFR≤0.80/Pb-CFR <2; Group 2 FFR≤0.80/Pb-CFR≥2; Group 3 FFR>0.80/Pb-CFR<2; Group 4 FFR>0.80/Pb-CFR≥2. Lesions with positive FFR were treated with PCI. Primary endpoint was the rate of major adverse cardiac events (MACEs), defined as a composite of death from any cause, myocardial infarction, target vessel revascularization, unplanned cardiac hospitalization at 36-months.

Results. A total of 609 patients and 816 lesions were available for the analysis. At Kaplan-Meier analysis MACEs rate was significantly different between groups (36.7% Group 1, 27.4% Group 2, 19.2% Group 3, 22.6% Group 4, p=0.019) and more prevalent in groups with FFR≤0.80 irrespective of Pb-CFR. In case of discrepancy, no difference in MACE were observed between groups stratified by Pb-CFR. FFR ≤0.80 was associated with an increased MACE rate (30.2% vs 21.5%, p<0.01) while Pb-CFR<2 was not (24.5% vs 24.2% Pb-CFR≥2 p=0.67).

Conclusions. FFR confirms its ability to predict outcomes in patients with intermediate coronary stenoses. Pb-CFR does not add any relevant prognostic information.

A414: INTRA-HOSPITAL VARIATION IN PLASMA TRIEMTHYLAMINE N-OXIDE LEVELS PREDICT MAJOR ADVERSE CARDIAC EVENTS; IMPACT OF THE FEMALE GENDER

Aneta Aleksova (a), Mariano Stornaiuolo (e), Alessandra Lucia Fluca (a), Milijana Janjusevic (a), Agnese Derin (a), Laura Munaretto (a), Enzo Merro (a), Laura Padoan (b, c), Alessandro Pierri (d), Stefano D'Errico (a), Ettore Novellino (e), Gianfranco Sinagra (a)
(a) AZIENDA SANITARIA UNIVERSITARIA DI TRIESTE AND UNIVERSITY OF TRIESTE, DEPARMENT OF MEDICAL SURGICAL AND HEALTH SCIENCES, CARDIOVASCULAR DEPARTMENT, TRIESTE, ITALY; (b) UNIVERSITY OF PERUGIA, CARDIOLOGY AND CARDIOVASCULAR PATHOPHYSIOLOGY, PERUGIA, ITALY; (c) AZIENDA SANITARIA UNIVERSITARIA GIULIANO ISONTINA, CARDIOLOGY DEPARTMENT GORIZIA-MONFALCONE, GORIZIA, ITALY; (d) CARDIOLOGY DEPARTMENT AND INTENSIVE CORONARY CARE UNIT, PERRINO HOSPITAL, BRINDISI, ITALY; (e) UNIVERSITY OF NAPOLI FEDERICO II, DEPARTMENT OF PHARMACY, NAPOLI, ITALY

Background. Trimethylamine N-oxide (TMAO), has been found to accelerate atherosclerotic processes by disrupting lipid metabolism. It is well-established that the intake of certain foods such as meat, dairy products and eggs affect the increased concentration of this gut microbiota metabolite, yet the exact mechanisms of TMAO hospital fluctuation and its impact on outcome after an AMI is still unclear.

Aims. To assess the prognostic value of in-hospital dynamics of TMAO, blood samples were collected on admission and on discharge from 149 patients with acute myocardial infarction (AMI). The end-point was composed of a major adverse cardiac event (MACE) defined as all-cause mortality, reinfarction and development of heart failure.

Methods. Plasma TMAO was determined by Mass Spectrometry DI-FT-ICR-MS.

Results. Median TMAO concentration was significantly higher on admission than on discharge, (respectively, 7.81 [3.47 – 19.98] vs 3.45 [2.3 – 4.78] μM, p<0.001). After estimating 3.45 μM as the cut-off for TMAO using continuous hazard ratio analysis, we separated our cohort into two groups. The first group (low-low/high/low-LL/HL) included 75 (50.3%) patients whose TMAO levels remained below 3.45 μM throughout the hospital stay (LL) or were initially above the cut-off at admission and decreased during hospitalisation (HL). Vice versa, the second group (high-high/low-high-HH/LH) included 74 (49.7%) patients whose TMAO levels remained high (HH) or increased above the cut-off concentration during hospitalisation (LH). During a median follow-up of 30 months, 32 (21.5%) and 19 (12.8%) patients reached the endpoint. At Kaplan-Meier analysis, patients from the group HH/LH had a worse outcome (p=0.05). Interestingly, upon dividing the cohort by gender and considering only the male population, the Kaplan-Meier analysis revealed that the patients from HH/LH group were more prone to experience the end-point (p=0.003). In the female population, only a trend was observed (p=0.074). In multivariable Cox analysis, older age, TMAO increase during the hospital stay and decrease of LV systolic function were independent predictors of worse outcome.

Conclusions. After AMI, permanently high or increasing levels of TMAO during hospitalisation are associated with a higher risk of MACE during long-term follow-up.

A415: IMPACT OF ACUTE CORONARY SYNDROME PRESENTATION ON CLINICAL OUTCOMES AT 1-YEAR FOLLOW-UP: EVIDENCE FROM THE 23,700-PATIENT PRAISE INTERNATIONAL REGISTRY

Matteo Betti (a, b), Luigi Spadafora (c), Marco Bernardi (c), Fabrizio D´ascenzo (d), Ovidio De Filippo (d), Gaetano Maria De Ferrari (d), Giuseppe Biondi-zoccai (e, f)
(a) DEPARTMENT OF CLINICAL SCIENCES AND COMMUNITY HEALTH, CARDIOVASCULAR SECTION, UNIVERSITY OF MILAN, 20122 MILAN, ITALY; (b) CENTRO CARDIOLOGICO MONZINO, IRCCS, 20138 MILAN, ITALY; (c) DEPARTMENT OF CLINICAL, INTERNAL MEDICINE, ANESTHESIOLOGY AND CARDIOVASCULAR SCIENCES, SAPIENZA UNIVERSITY OF ROME, 00185 ROME, ITALY; (d) DIVISION OF CARDIOLOGY, CARDIOVASCULAR AND THORACIC DEPARTMENT, CITTÀ DELLA SALUTE E DELLA SCIENZA, TURIN, ITALY; (e) DEPARTMENT OF MEDICAL-SURGICAL SCIENCES AND BIOTECHNOLOGIES, SAPIENZA UNIVERSITY OF ROME, 00185 ROME, ITALY; (f) MEDITERRANEA CARDIOCENTRO, NAPLES, ITALY

Background. Acute coronary syndromes (ACS) continue to be the primary cause of death among cardiovascular diseases, which are responsible for one-third of all deaths. Even though ST-elevation myocardial infarction (STEMI) and non-ST-elevation myocardial infarction (NSTEMI) share the same risk factors, STEMI appears to have the poorest prognosis after discharge. Still, little evidence demonstrates differences in short- and long-term clinical outcomes following discharge.

Methods. A total of 23,700 ACS patients diagnosed with either STEMI or NSTEMI were included in this analysis. The data were obtained from the PRAISE international registry which covered the period from 2003 to 2019. Our study primarily examined features regarding patients and procedures, medications prescribed at discharge, and outcomes at 1-year follow-up. Main outcomes included mortality, recurrent myocardial infarction, significant bleeding events, non-fatal recurrent myocardial infarction, and non-fatal significant bleeding events within one year after hospital discharge. Additionally, composite outcomes were assessed, including mortality or recurrent myocardial infarction, mortality or significant bleeding events, mortality, recurrent myocardial infarction or significant bleeding events, and non-fatal recurrent myocardial infarction or significant bleeding events.

Results. A cohort of 12,365 patients (57%) diagnosed with STEMI and 9,424 patients (43%) diagnosed with NSTEMI was included in the study. Numerous baseline differences were observed. For instance, patients with NSTEMI had a higher rate of cardiovascular risk factors, of prior revascularization, and a higher prevalence of multivessel disease, despite having a slightly higher mean left ventricular ejection fraction (all p<0.05). Rates of complete revascularization were comparable between the two groups. Upon discharge, patients with STEMI were more frequently administered the strong P2Y12 inhibitor Prasugrel, in addition to receiving more frequently guideline-directed medical therapy (P<0.001). At the 1-year mark, both groups exhibited comparable clinical outcomes, except for non-fatal reinfarction, which we found more prevalent among NSTEMI patients (P<0.05). However, it is worth noting that this difference did not hold statistical significance at the multivariate analysis (p=0.1).

Conclusions. Outcomes between STEMI and NSTEMI groups were similar after one year, with the only difference that the latter faced more non-fatal reinfarctions, probably due to a less intense medical treatment and follow-up. Hence, attention should be paid not to underestimate NSTEMI patients, despite the prevailing idea that they may have a better prognosis than STEMI patients.

A416: CMR AS THE FIRST LINE TEST COMPARED TO EXERCISE ECG AND SPECT IN PATIENTS WITH STABLE CHEST PAIN: INSIGHTS FROM CE-MARC

Giandomenico Bisaccia (a, b), Peter P. Swoboda (c), Chiara Bucciarelli-Ducci (b, e), John P. Greenwood (c, d)
(a) DIPARTIMENTO DI NEUROSCIENZE, IMAGING E SCIENZE CLINICHE, UNIVERSITÀ «G. D'ANNUNZIO» DI CHIETI-PESCARA, CHIETI, ITALIA; (b) ROYAL BROMPTON AND HAREFIELD HOSPITALS, GUYS' & ST THOMAS NHS TRUST, LONDON, UNITED KINGDOM; (c) LEEDS INSTITUTE OF CARDIOVASCULAR AND METABOLIC MEDICINE, UNIVERSITY OF LEEDS, LEEDS, UNITED KINGDOM; (d) DEPARTMENT OF CARDIOLOGY, LEEDS TEACHING HOSPITAL NHS TRUST, LEEDS, UNITED KINGDOM; (e) SCHOOL OF BIOMEDICAL ENGINEERING AND IMAGING SCIENCES, FACULTY OF LIFE SCIENCES AND MEDICINE, KING'S COLLEGE UNIVERSITY, LONDON, UNITED KINGDOM

Background and Aim. Exercise ECG is widely performed in the assessment of patients with suspected cardiac chest pain. Our aim was to assess the comparative diagnostic and prognostic yield of exercise ECG, single photon emission computed tomography (SPECT) and cardiovascular magnetic resonance (CMR), alone and sequentially, in a large prospective patient population.

Methods. Current Controlled Trials ISRCTN77246133. This is a post-hoc sub-study of CE-MARC, a randomized trial of patients with stable chest pain undergoing exercise ECG, CMR, SPECT and invasive coronary angiography. All patients recruited to CE-MARC who were also assessed by exercise ECG were included, and followed up to a median (IQR) of 6.3(0.1,6.8) years. Main outcomes were sensitivity, specificity, positive (PPV) and negative (NPV) predictive values, and area under the curve (AUC) for diagnostic accuracy, and hazard ratios (HR) of MACE for prognostic significance.

Results. Of 752 patients in the CE-MARC trial, 580 had exercise ECG and invasive coronary angiography, of which 503 also had SPECT and CMR. At follow-up, a total of 91 (15.7%) patients experienced MACE. Using invasive angiography as the reference test, the sensitivity, specificity, PPV and NPV (95%CI) of exercise ECG were 68.3(61.9,74.0), 72.5(67.6,76.9), 61.0(54.8,66.8), 78.4(73.7,82.5). Exercise ECG was significantly less sensitive than CMR and less specific than both CMR and SPECT. A positive exercise ECG result was not predictive of MACE at follow-up (HR 1.14[0.75, 1.72], p=0.53). Sequential SPECT following an exercise ECG compared to SPECT alone resulted in improved sensitivity (86.3% vs. 65.5%; p=0.027) and NPV (79.0% vs. 87.9%; p=0.011) at a cost of reduced specificity (83.7% vs. 64.1%; p<0.0001) and PPV (72.1% vs. 60.7%; p=0.009), and was not prognostically significant (HR 2.31[0.88,6.08], p=0.091). CMR alone had both a greater diagnostic and prognostic yield than exercise ECG, SPECT and a combination of the two. Following an inconclusive exercise ECG, a sequential CMR did not outperform CMR alone as the first-line test.
Conclusions. In patients with suspected cardiac chest pain, exercise ECG was less sensitive than CMR and less specific than both CMR and SPECT. CMR alone as the first-line test was more sensitive and prognostically accurate than exercise ECG, SPECT, or a sequential combination of both tests.

A417: USE OF CANGRELOR IN PATIENTS WITH ST-SEGMENT ELEVATION MYOCARDIAL INFARCTION UNDERGOING PERCUTANEOUS CORONARY INTERVENTION: A RETROSPECTIVE SINGLE-CENTER STUDY FROM CARDARELLI HOSPITAL, NAPLES

Valentina Capone (a, b), Davide D'Andrea (a), Fulvio Cacciapuoti (a), Rossana Castaldo (c), Monica Franzese (c), Eduardo Bossone (d), Ciro Mauro (a)
(a) DEPARTMENT OF CARDIOLOGY, "A. CARDARELLI" HOSPITAL, NAPLES; (b) DEPARTMENT OF ADVANCED BIOMEDICAL SCIENCES, FEDERICO II UNIVERSITY HOSPITAL, NAPLES, ITALY; (c) IRCCS SDN, NAPLES, ITALY; (d) DEPARTMENT OF PUBLIC HEALTH, "FEDERICO II" UNIVERSITY OF NAPLES, VIA PANSINI, 5, 80131 NAPLES, ITALY

Introduction. Cangrelor is an endovenous adenosine diphosphate (ADP) receptor antagonist (P2Y12 receptor inhibitor, P2Y12i) designed for use in patients undergoing percutaneous coronary intervention (PCI). Unlike the oral adenosine diphosphate receptor antagonists currently available, cangrelor has reversible antiplatelet effects resulting in a rapid onset/offset effect. A meta-analysis showed that the benefit of cangrelor with respect to major ischaemic endpoints was counterbalanced by an increase in minor bleeding complications.
Methods. Here we report a retrospective single-center study conducted on 100 consecutive P2Y12 receptor inhibitor-naïve patients admitted to our Cath-lab from January 2020 to January 2023 with diagnosis of ST-segment elevation myocardial infarction (STEMI) who underwent urgent PCI and received a bolus and infusion of cangrelor (30 µg per kilogram followed by an infusion of 4 µg per kilogram per minute and continued for at least 2 hours); at the conclusion of the infusion of cangrelor, patients received a loading dose (LD) of oral P2Y12i (i.e., ticagrelor, clopidogrel, prasugrel). The decision to use cangrelor was made by the cardiologist on a case-by-case basis, in P2Y12 receptor inhibitor-naïve ACS patients undergoing PCI, according to current guidelines. The cangrelor group was compared to a control group of 100 sex and age-matched STEMI patients who received a LD of oral P2Y12i (i.e., ticagrelor, clopidogrel, prasugrel). The bleeding risk was evaluated by both drop in haemoglobin values and bleedings according to BARC criteria. Major adverse cardiovascular events (MACEs) at 48 hours including death, myocardial infarction, ischemia-driven revascularization, and stent thrombosis were searched. 2D-echocardiography ejection fraction (EF) values at the time of adimission at the emergency department (ED) and before discharge, measured through Simpson biplane method in most cases, were reported. The data were tested for normality through the Shapiro–Wilk test. The Wilcoxon rank-sum test or t-test was used, as required, for comparisons of continuous variables between groups. Categorical variables were expressed as percentages and were compared using the chi- square test or the Fisher's exact test. Holm's correction was used for multiple hypothesis correction, if necessary.
Results. Cangrelor and control groups did not differ significantly in cardiovascular risk factors, timing of chest pain onset, culprit vessel, catheter access site, and rise in cardiac troponins (p>0.05). Also, left ventricular EF evaluated by 2D-echocardiography at the admission at the ED did not differ between the two groups (43.7±7.6% vs 45.7±8.1%, p-value 0.0957). Haemoglobin before the procedure did not differ between cangrelor and control group (14.3±1.6 g/dl vs 14.6±1.9 g/dl respectively, p-value 0.305). Haemoglobin values after PCI (i.e., 6-8 hours after the procedure) did not differ significantly amongst the two groups (13.9±1.5 g/dl vs ± 14.1±1.9g/dl respectively, p-value 0.528); neither haemoglobin before discharge/staged PCI/other procedure differ between the two groups (13.4±1.6 g/dl vs 13.8±1.9 g/dl, p-value 0.306). All bleedings in both groups were classified as BARC Type 1–2. In addition, EF before discharge and increase in EF did not differ significantly between cases and controls. Only one case of 48h-death was detected in each group (cardiovascular arrest).
Conclusions. According to our single-center experience, the use of cangrelor in STEMI patients does not increase the bleeding risk. Moreover, similar cardiovascular adverse events and recovery in cardiac function by 2D-echocardiography has been observed in the two groups.

A418: LOCKDOWN FOR COVID-19, AIR POLLUTION AND ACUTE CORONARY SYNDROMES: A COMMON THREAD OR NOT? TERNI'S EXPERIENCE

Marco Dell'Uomo (a), Martina Sordi (a), Irene Dominioni (a), Marcello Dominici (a), Giacomo Pucci (a), Alessio Arrivi (a)
(a) AZIENDA OSPEDALIERA SANTA MARIA DI TERNI, UNIVERSITÀ DEGLI STUDI DI PERUGIA

Background. During the lockdown for COVID-19, a massive decrease in hospital admissions for acute coronary syndrome (ACS) and a drop in air pollution were both detected in Italy. Our aim was to investigate the possible association between these two events at the Province of Terni, one of the most polluted urban and industrial area in Central Italy.
Methods. We analyzed data of daily 24-h urban air concentrations of particulate matter (PM)10 and PM2.5 from fixed station monitoring network located in the main city centers of the Terni province, and accesses for ACS at the catheterization laboratory of the Cardiological Hub Center of the Terni University Hospital during lockdown. A comparison was made with data corresponding to the same lockdown time period of years 2019, 2018, and 2017.
Results. Invasive procedures for ACS decreased in 2020 (n=49) as compared with previous years (n=93 in 2019, n=109 in 2018, and n=89 in 2017, p<0.001). Conversely, reductions in average PM10 (20.7 µg/m^3) and PM2.5 (14.7 µg/m^3) in 2020 were consistent with a long-term decreasing trend, being comparable to those recorded in 2019 and 2018 (all p>0.05) and slightly lower than 2017 (p<0.05). The Granger-causality test demonstrated the lack of association between time-varying changes in air pollution and the number of procedures for ACS.
Conclusions. Our results did not support the hypothesis that reduction in invasive procedures for ACS during lockdown was linked to an air cleaning effect. Reasons other than reduced air pollution should be sought to explain the observed decrease in ACS procedures.

A419: TREATMENT OF REFRACTORY ANGINA WITH THE CORONARY SINUS REDUCER

Eleonora Gnan (a, b, c), Giacomo Maria Cioffi (c), Matthias Bossard (c), Mehdi Madanchi (c), Irena Majcen (c), Stefano Carugo (a, b), Florim Cuculi (c), Adrian Attinger (c)
(a) DEPARTMENT OF CLINICAL SCIENCES AND COMMUNITY HEALTH, UNIVERSITY OF MILAN, ITALY; (b) DEPARTMENT OF CARDIO-THORACIC-VASCULAR DISEASES, FOUNDATION IRCCS CA GRANDA OSPEDALE MAGGIORE POLICLINICO, MILAN, ITALY; (c) HERZZENTRUM, LUZERNER KANTONSSPITAL, SWITZERLAND

Aims. The Coronary Sinus Reducer (CSR) is a relatively recent addition to the therapeutic armory available for refractory angina (RA), a condition that deeply affects the quality of life of a nonnegligible percentage of patients with coronary artery disease (CAD). One randomized trial and several observational studies have showed CSR efficacy in obstructive CAD, but very scarce data exists on patients with RA despite complete revascularization, and no data is available on non-obstructive, purely microvascular dysfunction. We present our experience with CSR at a Swiss tertiary center.
Methods and Results. We enrolled 56 consecutive patients from the prospective COMPLEX registry, that presented with RA despite optimal antianginal therapy, without further option for revascularization, and that received a CSR between June 2018 and November 2022. Endpoints were anginal symptoms, evaluated with the Canadian Cardiovascular Society (CCS) score, procedural success rate and complications, and MACE as a composite of all-cause mortality, cardiovascular death, acute coronary syndromes (ACS) and heart failure hospitalizations. A total of 38 (68%) patients were males, mean age was 70±10. 22 (39%) patients had diabetes. Mean CCS class at baseline was 2.7±0.6, and mean number of antianginal drugs was 2.2±1.2. Three-vessel disease was present in 39 (70%) patients, and 22 (39%) had at least one chronic total occlusion (CTO) lesion. 48 (86%) patients underwent at least one percutaneous or surgical coronary revascularization procedure. 8 (14%) patients presented with non-obstructive CAD, while 12 (21%) had obstructive CAD but were completely revascularized at baseline. Noteworthy, we offered CSR as a compassionate treatment also to patients that met exclusion criteria of most previously published studies: ACS in the last 3 months (15, 27%), recent revascularization (12, 21%), previously implanted cardiac resynchronization therapy (CRT) device (2, 3.6%), predominantly right coronary artery (RCA) disease (5, 9%). Procedural success was achieved in 98% of cases, with only 1 patient requiring a second, ultimately successful, procedure. No major periprocedural complication resulting in bailout surgery, periprocedural death or myocardial infarction occurred. Clinical follow-up was available for 54 (96%) of patients. After a median of 258 days (IQR 104-405) from CSR implantation, mean CCS class was 1.6±1.1, while the median number of antianginal drugs was 2±1. Overall, 70.2% of patients improved by ≥1 CCS class and 36.2% by ≥2 CCS classes. An improvement by ≥1 CCS class was also observed in 77.8% of

patients with non-obstructive or completely revascularized disease. Mortality and MACE were 7% and 15% respectively.
Conclusions. In our cohort of patients, CSR implantation was safe and resulted in an improvement of anginal symptoms, in line with previous studies. The effect was maintained also among patients with non-obstructive or completely revascularized disease. To our knowledge, this is the first time that CSR efficacy is described also in patients with non-obstructive disease.

A420: FAST TRACK PCSK9I IN ACS

Mihaela Ifrim (a), Francesco Candido (a), Massimo Russo (a), Saverio Muscoli (a)
(a) UNIVERSITÀ DEGLI STUDI DI TOR VERGATA

Introduction. Patients with ACS are at increased risk for recurrent ischemic manifestations, especially in the first months after the acute event, and fall into the category of individuals at very high CV risk. In these patients, lowering LDL-C reduces CV morbidity and mortality, with clinical benefits proportional to LDL-C reduction. In ACS, early initiation of treatment with high-intensity statins reduces recurrence of events; however, these drugs, even in combination with ezetimibe, often fail to achieve target LDL-C levels or are not tolerated by patients, necessitating initiation of therapy with PCSK9i. Current guidelines for dyslipidemia provide for a step-by-step approach, but this involves a long latency between initiation of therapy and achievement of target LDL-C levels, leading to a potential increase in CV events. However, a more intensive approach, supported by recent evidence, involves starting PCSK9i therapy during hospitalization for ACS or in the immediately following period, in addition to the maximum tolerated dose therapy of stat/ezt.
Methods. We retrospectively analyzed 132 patients aged>18 years and <80 years (mean age 63 years) who underwent PCI for ACS in the past year (2022). Among these patients, we compared those who had AIFA-identified characteristics for prescribing PCSK9i in the "fast track" regimen with the control group in which standard therapy with a high-dose statin (atorvastatin 80 mg) was administered. Of the 68 patients in the PCSK9i group, 23 patients received evolocumab 140 mg, 36 patients received alirocumab 150 mg, and the remaining 9 patients received alirocumab 75 mg; of these, 9 patients received PCSK9i as monotherapy for stat/ezt intolerance. Lipid profile was assessed at the time of admission and 8 weeks later. Percent change, mean percent change, and standard deviation were calculated for all lipid profile values. A Student's t test was also performed to evaluate each lipid profile variable.
Results. At 8 weeks after initiation of therapy, patients treated with PCSK9i had a mean reduction in LDL-C of 70.6% (SD±18.95; p=0.0001), while those treated with atorvastatin 80 mg had a mean reduction of 40.49% (SD±17.8112; p=0.0001). In addition, a significant decrease in TOT -C was observed in patients treated with PCSK9i (48.12% (SD±16.8) versus 20.06% (SD±18.51); p=0.0002). The levels of HDL-C (change 2.08% (SD±21.26) vs. 6.02% (SD±29.51), p=0.57) and TG (reduction 16.73% (SD± 30.28) vs. 0.84% (SD±37.99; p=0.70) did not show significant differences between the two groups.
Conclusions. Patients who started early maximal lipid-lowering therapy with the addition of PCSK9i to the stat/ezt association showed TOT-C and LDL-C reductions greater than 50%, which is in line with the targets required by the ESC guidelines. Therefore, a fast-track approach seems to be more effective in high-risk patients and to achieve therapeutic goals faster than the stat/ezt combination, prospectively reducing mortality CV.

A421: INCREMENTAL VALUE OF MYOCARDIAL WORK ANALYSIS FOR DETECTION OF CORONARY ARTERY DISEASEDURING DIPYRIDAMOLE STRESS ECHOCARDIOGRAPHY

Francesca Lofrumento (a), Maurizio Cusmà-Piccione (a), Giampiero Vizzari (a), Roberto Licordari (a), Francesca Parisi (a), Roberta Manganaro (a), Olimpia Trio (a), Cesare De Gregorio (a), Quirino Ciampi (b), Scipione Carerj (a), Gianluca Di Bella (a), Antonio Micari (a), Concetta Zito (a)
(a) DEPARTMENT OF CLINICAL AND EXPERIMENTAL MEDICINE, UNIVERSITY OF MESSINA, AOU POLICLINIC G. MARTINO, CARDIOLOGY UNIT; (b) CARDIOLOGY DIVISION, FATEBENEFRATELLI HOSPITAL, BENEDETTO, ITALY

Introduction. Dipyridamole stress-echocardiography (DipSE) relies on operator's expertise and might have suboptimal diagnostic accuracy in identifying patients with single-vessel coronary artery disease (CAD). 2D strain, and, recently, myocardial work (MW) analysis, provide a more accurate evaluation of myocardial function, being able to detect subtle regional abnormalities.
Aims. Aim of our study was to investigate the additive role of MW analysis for detecting myocardial ischemia during Dip-SE in patients screened for CAD.
Methods. We retrospectively enrolled 50 patients who underwent Dip-SE followed by computed tomographic (CT) coronary angiography, in case of non-diagnostic test, or by invasive coronary angiography (ICA), when the test was diagnostic or after a positive coronary CT. According to CT/ICA results patients were divided in group 1 (with obstructive CAD) and group 2 (without obstructive CAD). Thereafter, matching Dip-SE and CT/ICA results, the two groups were split in subgroups: 1A (true positives), 1B (false negatives), 2A (false positives) and 2B (true negatives). Global longitudinal strain (GLS), global work index, global constructive work, global wasted work and global work efficiency (GWE) were calculated off-line.
Results. (Fig. 1) In group 1, GLS improved at low and worsened at peak dose while in group 2 it improved from low to peak dose. At peak dose, GWE decreased in group 1 (p 0.025) and increased in group 2 (p 0.001). In false positives, at peak dose GLS decreased (p 0015) likewise in true positives while GWE increased (p 0.023) differently from true positives, proving to be more accurate than GLS for discerning patients without obstructive CAD. Moreover, GWE had the best AUC (0.845) for identifying obstructive CAD with a net reclassification improvement of 0.049 (p 0.005).
Conclusions. GWE shows an additive role for ruling-out obstructive CAD, improving the diagnostic performance of a standard Dip-SE.

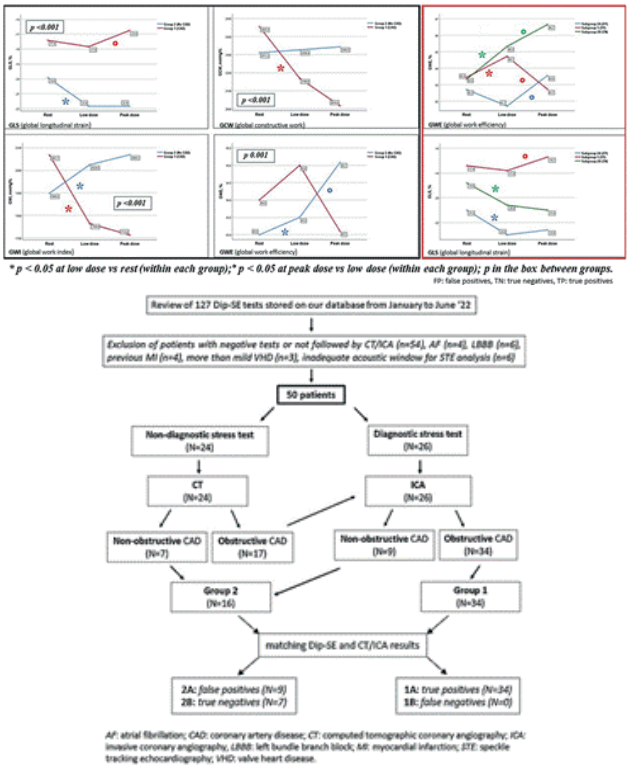

Figura 1.

A422: UN CASO DI SINDROME CORONARICA ACUTA PRECIPITATO DA INSUFFICIENZA VALVOLARE AORTICA ACUTA

Giulia Maiolo (a), Lorenzo Cangiano (a), Piergiuseppe Agostoni (a), Giancarlo Marenzi (b)
(a) UNIVERSITÀ DEGLI STUDI DI MILANO; (b) CENTRO CARDIOLOGICO MONZINO

Una donna di 78 anni giungeva presso il Pronto Soccorso del nostro Istituto per dolore toracico trafittivo irradiato al braccio sinistro. La paziente era nota per sostituzione di aorta ascendente e impianto di bioprotesi (Stentless Elan 23) in posizione aortica per stenosi severa 15 anni prima, e per conseguente impianto di pace-maker bicamerale per blocco atrio-ventricolare avanzato nel post-operatorio. Alla visita la paziente appariva ancora sintomatica per dolore toracico, inizialmente in buone condizioni di compenso di circolo. All'auscultazione cardiaca vi era un soffio sisto-diastolico sul focolaio aortico di intensità II/VI Levine e la pressione arteriosa era 130/45 mmHg. L'ECG evidenziava ritmo da pacemaker in VAT con evidenza di sottoslivellamento del tratto ST consensuale al QRS in V4-V6 e sopraslivellamento consensuale al QRS in aVR. È stato eseguito quindi un ecocardiogramma in regime di urgenza che mostrava moderata riduzione della funzione sistolica ventricolare sinistra con aree di ipocinesia apicale; a livello della bioprotesi aortica si riscontrava invece una dubbia immagine mobile iperecogena con segnale Doppler di rigurgito significativo. Durante l'osservazione iniziale si assisteva inoltre a un rapido peggioramento del quadro di compenso cardiocircolatorio con insufficienza respiratoria. Pertanto, in ragione del quadro clinico, elettrocardiografico ed ecocardiografico che indirizzavano verso un quadro di sindrome coronarica acuta in concomitanza di un severo vizio valvolare, si discuteva il caso con i colleghi cardiochirurghi e si decideva di dare priorità allo studio del circolo coronarico, anche in ragione del proibitivo rischio chirurgico in emergenza. Alla coronarografia si evidenziava stenosi serrata alla triforcazione tronco comune-arteria

interventricolare anteriore -arteria circonflessa che veniva trattata con angioplastica e apposizione di stent (su circonflessa e alla biforcazione tronco comune-arteria interventricolare anteriore). La procedura veniva complicata da fibrillazione ventricolare trattata in maniera efficace con DC-Shock. Durante la successiva degenza in terapia intensiva cardiologica, tuttavia, nonostante la buona riuscita della procedura di angioplastica, si assisteva a un progressivo peggioramento del quadro emodinamico con necessità di supporto amminico: l'ecocardiogramma mostrava un recupero della funzione sistolica ventricolare sinistra, con persistenza di insufficienza valvolare aortica severa in un quadro di sospetta frattura di cuspide non coronarica, confermata poi all'esame transesofageo. Veniva dunque eseguito un impianto percutaneo di valvola aortica in urgenza con posizionamento di bioprotesi Edwards Sapiens 23. La paziente veniva infine dimessa in buon compenso cardiocircolatorio e l'ecocardiogramma dimostrava un buon funzionamento della bioprotesi aortica neo-impiantata. La paziente si presentava, quindi, con un quadro di sindrome coronarica acuta, ma grazie all'obiettività (soffio cardiaco, elevata pressione differenziale) e al successivo ecocardiogramma è stato possibile identificare in tempi brevi la concomitante presenza di un vizio valvolare severo, verosimilmente acuto. Questo caso è un esempio di come un quadro cronico di severa stenosi coronarica possa degenerare in una sindrome coronarica acuta, a seguito dell'insorgenza di un vizio valvolare acuto e di come la valutazione clinica e l'ecocardiogramma in urgenza siano strumenti fondamentali nell'identificazione del giusto percorso diagnostico e terapeutico.

A423: SEVERE-1 STUDY PROTOCOL: SECONDARY PREVENTION AND EXTREME CARDIOVASCULAR RISK EVALUATION, FOCUS ON PREVALENCE AND ASSOCIATED RISK FACTORS

A. Maloberti (a, b), R.c.m. Intravaia (b), C. Mancusi (c), A Cesaro (d), E. Golia (d), I. Fucile (c), S. Coletta (d), B De Chiara (b), D Bernasconi (a, b), M Algeri (b), M. Ardissino (b), E. Inglese (b), F. Scaglione (b), P. Calabrò (d), N. De Luca (c), C Giannattasio (a, b)

(a) SCHOOL OF MEDICINE AND SURGERY, MILANO-BICOCCA UNIVERSITY, MILAN ITALY; (b) CARDIOLOGY 4, NIGUARDA HOSPITAL, MILAN ITALY; (c) FEDERICO II UNIVERSITY HOSPITAL, NAPLES ITALY; (d) S. ANNA E S. SEBASTIANO HOSPITAL, CASERTA ITALY

Background. Despite significant improvement in secondary CV prevention strategies, some Acute and Chronic Coronary Sindrome (ACS and CCS) patients will suffer recurrent CV events (also called "extreme CV risk"). Recently new biochemical markers, such as Uric Acid (UA), Lipoprotein A (LpA) and several markers of inflammation, have been described to be associated with CV events recurrence.

Aims. We proposed a study (SEVERE-1) for the accurate characterization of extreme CV risk patients enrolled in Cardiac Rehabilitation (CR) programs. Our aims are to describe the prevalence of extreme CV risk and its association with newly described CV risk factors.

Methods. We will evaluate 730 ACS patients enrolled in a CR program. Extreme CV risk will be defined as the presence of a previous (within 2 years) CV events in the patients clinical hystory. UA, LpA and inflammatory markers (interleukin-6 and -18, tumor necrosys factor alpha, C-reactive protein, calprotectin and osteoprotegerin) will be assessed in ACS/CCS patients with extreme CV risk and compared with ACS/CCS patients without extreme CV risk and two control groups: 1180 hypertensives and 765 healthy subjects. Then we will assess the association between newly described CV risk factors and extreme CV risk with multivariable model and, for biomarkers selected as relevant, we will create two score system for the identification of extreme CV risk patients. The first one will use only clinical variables while the second one will introduce biochemical markers on top. The AUC values will be used to compare the diagnostic accuracy. Finally, by exome sequencing we ill both evaluate polygenic risk score ability to predict recurrent events and we will do mendellian randomization analysis on CV biomarkers.

Conclusions. Our study proposal was granted by the PNRR M6/C2 call. With this study we will give definitive data on extreme CV risk prevalence (probably higher than what actually believed) rising attention on this condition and leading cardiologist to better diagnose this condition and to carry out a more intensive treatment optimization that will leads to a reduction of future ACS recurrence.

A424: EFFECT OF SUBLINGUAL NITROGLYCERIN ON THE RESULTS OF EXERCISE STRESS TEST IN PATIENTS WITH NON-OBSTRUCTED CORONARY ARTERIES AND DIFFERENT RESULTS OF INTRACORONARY ACETYLCHOLINE TEST

Angelo Giuseppe Marino (a), Giuseppe Gentile (a), Fabio De Benedetto (a), Ludovica Lenci (a), Saverio Tremamunno (a), Nello Cambise (a), Lorenzo Tinti (a), Antonio Di Renzo (a), Antonietta Belmusto (a), Antonio De Vita (a), Filippo Crea (a), Gaetano Antonio Lanza (a)

(a) DEPARTMENT OF CARDIOVASCULAR AND PNEUMOLOGICAL SCIENCES - CATHOLIC UNIVERSITY OF THE SACRED HEART - FONDAZIONE POLICLINICO AGOSTINO GEMELLI

Background. Up to 50-60% of patients with exercise-induced angina and 10-15% of patients with a clinical presentation of non-ST-segment elevation acute coronary syndrome (NSTE-ACS) show non obstructive coronary artery disease (NO-CAD) at angiography. ECG exercise stress test (EST) induces ischemic ST-segment changes in a proportion of these patients, while intracoronary acetylcholine (Ach) test may induce epicardial coronary artery spasm (CAS) or coronary microvascular spasm (CMVS). However, whether these abnormal responses to Ach identify the mechanism responsible for the clinical syndrome in the individual patient, or merely represent a non-specific increased coronary reactivity, is not clear. It is well-known that CAS, but not CMVS, can effectively be prevented by short-acting nitrate administration. In this study we assessed whether, among patients with angina and NO-CAD showing a positive EST, the preventive administration of short acting nitrates has any different effects on EST findings according to the different results of Ach testing.

Methods. We enrolled 81 consecutive patients with exercise-induced angina or a clinical picture of NSTE-ACS who showed NO-CAD (no coronary vessel with>50% stenosis and/or fractional flow reserve <0.80) at angiography and underwent intracoronary acetylcholine (Ach) test. Patients were divided into 3 groups according to the result of Ach test: 1) patients with CAS (i.e., narrowing of the epicardial coronary diameter ≥90%, associated with typical symptoms and/or ischemic ECG changes); 2) patients with CMVS (i.e., induction of typical symptoms and ischemic ECG changes in the absence of CAS at angiography); 3) patients with a negative test. All patients underwent a basal EST (B-EST) after withdrawal of anti-ischemic drug therapy. In patients with a positive test (i.e., induction of ST-segment depression and/or typical angina), the test was repeated after 48-72 hours following administration of 5 mg of sublingual isosorbide dinitrate (N-EST).

Results. Of 81 patients, 40 (49%) had epicardial spasm at Ach test (CAS-group), 14 (17%) had CMVS (CMVS-group) and 27 (34%) had a negative Ach test (NEG-group). There were no significant differences between groups in age, sex, cardiovascular risk factors and clinical presentation (stable/unstable angina or MINOCA). There were also no significant differences between groups in EST results at B-EST. B-EST was positive (horizontal or downsloping ST-segment depression>1 mm) in 19 patients (23.5%) only: 8 (20%) in the CAS-group, 6 (43%) in the CMVS-group and 5 (18%) in the NEG-group (p=0.076). N-EST performed in these 19 patients showed similar results in the 3 groups. Furthermore, results did not differ significantly compared to B-EST in any group. N-EST was still positive in 7 (87.5%), 4 (66.7%) and 4 (80%) patients in the CAS-group, CMVS group and NEG-group, respectively (p=0.78).

Conclusions. Among patients with chest pain and NO-CAD, the results of EST did not differ significantly between those with CAS, CMVS or a negative result at Ach test. The preventive administration of short-acting nitrates also showed similar poor effects on the EST results in the 3 groups. Our data suggest that, in these patients, the mechanism responsible for exercise-induced ST-segment depression is not correlated to the the results of Ach testing and is unlikely to consist of epicardial CAS, due to the poor response to nitrates.

A425: CLINICAL SYMPTOMATIC OUTCOME IN PATIENTS WITH NON-OBSTRUCTED CORONARY ARTERIES AND DIFFERENT RESULTS OF INTRACORONARY ACETYLCHOLINE TEST

Ludovica Lenci (a), Giuseppe Gentile (a), Angelo Giuseppe Marino (a), Fabio De Benedetto (a), Saverio Tremamunno (a), Nello Cambise (a), Lorenzo Tinti (a), Antonio Di Renzo (a), Antonietta Belmusto (a), Antonio De Vita (a), Filippo Crea (a), Gaetano Antonio Lanza (a)

(a) DEPARTMENT OF CARDIOVASCULAR AND PNEUMOLOGICAL SCIENCES - CATHOLIC UNIVERSITY OF THE SACRED HEART - FONDAZIONE POLICLINICO AGOSTINO GEMELLI

Background. Up to 50-60% of patients with exercise-induced angina and 10-15% of patients admitted to hospital with a clinical diagnosis of non-ST-segment elevation acute coronary syndrome (NSTE-ACS) show non obstructive coronary artery disease (NO-CAD) at angiography. Intracoronary acetylcholine (Ach) test may induce epicardial coronary artery spasm (CAS) or coronary microvascular spasm (CMVS) in these patients, which may lead to a different therapeutic management. Whether the results of Ach test impact significantly on clinical symptomatic outcome in these patients has poorly been investigated.

Methods. We enrolled 81 consecutive patients who underwent coronary angiography at our Center because of stable angina or a clinical picture of NSTE-ACS but were found to have NO-CAD (no coronary vessel with>50% stenosis and/or fractional flow reserve <0.80) at angiography and underwent intracoronary acetylcholine (Ach) test. Patients were divided into 3 groups according to the result of Ach test: 1) patients with epicardial spasm (i.e., narrowing of the epicardial coronary diameter ≥90%, associated with typical symptoms and/or ischemic ECG changes); 2) patients with CMVS (i.e., induction of typical symptoms and ischemic ECG changes in the absence of CAS at angiography); 3) patients with a negative test. The clinical conditions of patients were assessed at a median follow-up of 275 days (IQ range 158-542) by the Seattle Angina Questionnaire (SAQ), which investigates, through 19 questions, 5 aspects of the anginal clinical status: physical limitation (SAQ1), angina stability (SAQ2), angina frequency (SAQ3), treatment satisfaction (SAQ4) and perception of the disease (SAQ5).

Results. Of 81 patients, 40 (49%) had epicardial spasm at Ach test (CAS-group), 14 (17%) had CMVS (CMVS-group) and 27 (34%) had a negative Ach test (NEG-group). There were no significant differences between groups in age, sex, cardiovascular risk factors and clinical presentation (stable/unstable angina or MINOCA). Also, the three groups did not show significant differences in any of the SAQ categories, as shown in the Table. Furthermore, SAQ scores did not significantly differ among patients of the 3 groups who were treated either by beta-blockers (SAQ average score 84+13, 75+15 and 82+13, respectively; p=0.42) or calcium-channel blockers (69+29, 75+20, and 86+10, respectively; p=0.31).
Conclusions. Among patients with chest pain and NO-CAD, the results of SAQ did not differ significantly between those with CAS, CMVS or a negative result in response to Ach test. Beta-blockers and calcium-channel blockers therapy seemed unable to obtain significant different symptomatic effects in the 3 groups of patients.

	CAS-group (n=40)	CMVS-group (n=14)	NEG-group (n=27)	p
Physical limitation	89±21	85±25	89±20	0.83
Angina stability	70±31	77±28	83±28	0.27
Angina frequency	87±18	88±16	90±17	0.77
Treatment satisfaction	81±22	79±19	77±23	0.76
Disease perception	54±21	60±17	63±22	0.20
Average SAQ score	80±19	76±18	78±16	0.69

A426: TAKOTSUBO: ANTITESI TERAPEUTICA TRA OSTRUZIONE DINAMICA DELL'LVOT E DISFUNZIONE VENTRICOLARE SINISTRA

Mattia Marteddu (a), Marco Medda (a), Gabriele Khalil (a), Mattia Casati (a), Stefano Cossu (a), Mattia Biddau (a), Maria Francesca Marchetti (a), Roberta Montisci (a)
(a) AZIENDA OSPEDALIERO-UNIVERSITARIA DI CAGLIARI - POLICLINICO UNIVERSITARIO "DUILIO CASULA"

La sindrome di Takotsubo (ST) è una condizione clinica caratterizzata da una transitoria disfunzione sistolica ventricolare sinistra o biventricolare con lieve rialzo degli indici di danno miocardico, in assenza di ostruzione coronarica significativa all'angiografia. In fase acuta è possibile avere quadri clinici complessi e presenza di numerose complicanze sia meccaniche sia aritmiche. Nei casi di shock cardiogeno è importante individuare l'esatto meccanismo responsabile, differenziando un quadro di grave disfunzione sistolica dalla presenza di ostruzione del tratto di efflusso del ventricolo sinistro (LVOTO). In quest'ultimo caso, infatti, sono da sconsigliare le amine per evitare un ulteriore peggioramento dell'ostruzione, ma si dovrà utilizzare il riempimento volemico e betabloccanti per ridurre l'ipercinesia dei segmenti basali che contribuisce ad aumentare l'ostruzione dinamica sistolica. In caso di persistenza del quadro di shock cardiogeno potrà essere utilizzato il sistema Impella. Presentiamo il caso di una donna di 72 anni affetta da ipertensione arteriosa e prolasso mitralico. Ricoverata presso centro Spoke nel sospetto di sindrome coronarica acuta e trasferita presso l'Emodinamica del nostro centro per eseguire studio coronarografico, risultato negativo. Ritrasferita presso l'UTIC del centro Spoke veniva fatta diagnosi di ST, all'ecocardiogramma colorDoppler FE 25%, acinesia dei segmenti medio-apicali, ipercinesia dei segmenti basali e insufficienza mitralica moderata. Dopo qualche ora, evoluzione del quadro clinico in shock cardiogeno con persistenti bassi valori pressori, contrazione della diuresi ed elevazione dei lattati, per cui veniva instaurata terapia con Noradrenalina con peggioramento del quadro clinico e successivamente riferita al nostro centro per un eventuale supporto al circolo. All'arrivo presso la nostra UTIC quadro di shock cardiogeno, FE 25% con grave LVOTO (gradiente 80 mmHg) per SAM ed insufficienza mitralica severa, normale funzione del ventricolo destro. Veniva immediatamente sospesa la terapia con noradrenalina e sottoposta a riempimento volemico associato a stimolazione diuretica con furosemide in infusione continua con beneficio. In fase acuta episodi recidivanti di fibrillazione atriale con FVM 150/min sottoposti a CV farmacologica con amiodarone e.v. con ripristino del ritmo sinusale. Nei giorni successivi la degenza è stata caratterizzata da un difficile equilibrio tra l'ipotensione secondaria al LVOTO, rispondente a fluid challenge e metoprololo endovena, e segni di scompenso congestizio determinati dalla bassa FE con necessità di adattare la posologia della terapia diuretica e degli introiti idrici. È stata inoltre impostata un'adeguata terapia anti-scompenso. In sesta giornata è stata eseguita RM cuore che ha confermato un quadro di ST con iniziale recupero della funzione contrattile cardiaca e riduzione del LVOTO, in assenza di aree di delayed ehnancement. Durante la degenza si è assistito a un progressivo miglioramento della funzione del ventricolo sinistro, alla dimissione FE 50% e non più evidenza di SAM. La paziente è stata dimessa con terapia ottimizzata per lo scompenso cardiaco e amiodarone. In conclusione, la gestione acuta della ST può essere impegnativa poiché il trattamento principe di alcune complicanze può determinare il peggioramento delle condizioni del paziente (risultano terapie antitetiche quelle per l'LVOTO e la disfunzione ventricolare sinistra), per cui è necessario un continuo monitoraggio ecocardiografico che garantisca di volta in volta l'adeguamento terapeutico a seconda della complicanza che maggiormente determina la gravità del quadro clinico.

A427: UNA WELLENS DA POLMONITE?

Maria Francesca Massara (a, b), Filippo Pirani (a), Giada Refi (b), Andrea Giovagnoli (b), Letizia Zappelli (b), Giorgio Di Noto (b), Federico Guerra (a), Antonio Dello Russo (a)
(a) UNIVERSITÀ POLITECNICA DELLE MARCHE; (b) OSPEDALE CARLO URBANI - JESI (AN) - AST 2 MARCHE

Background. La sindrome di Wellens, denominata anche "left anterior descending coronary syndrome", si caratterizza per la comparsa di modifiche dell'onda T registrate all'ECG durante il periodo libero da sintomatologia anginosa nei pazienti con storia di dolore toracico. I criteri diagnostici sono: alterazioni dell'onda T nelle derivazioni precordiali, assenza di movimento significativo degli enzimi di danno cardiaco, mancanza di sopraslivellamento del tratto ST, assenza di perdita dell'onda R, assenza di onde Q patologiche. Rappresenta una manifestazione ECG di stenosi critica dell'arteria interventricolare anteriore prossimale in pazienti con angina instabile, e si associa a un elevato rischio di sviluppare infarto anteriore esteso con prognosi severa. Si riconoscono due pattern: il tipo 1 che si distingue per la presenza di onde T profonde negative in V2-V3, e il tipo 2 che si caratterizza invece per onde T difasiche nelle precordiali. Inizialmente classificate come due tipi separati, ad oggi sono considerate l'una l'evoluzione dell'altra.
Case report. Uomo, originario del Bangladesh, 65 anni. In anamnesi cardiopatia ischemica cronica con coronaropatia trivasale in esiti di pregressa rivascolarizzazione chirurgica (CABG 2007: AMIS su IVA + Y graft di AMID su MO1-MO2-IVP) e recente ricovero per SCA-NSTEMI (giugno 2022) con quadro coronarografico invariato rispetto al precedente. Comorbidità: arteriopatia obliterante periferica, diabete mellito tipo II con danno d'organo, BPCO con recenti riacutizzazioni. Ultima scintigrafia miocardica nel 2021, effettuata per angina da sforzo, risultava positiva per ischemia miocardica inducibile in regione postero-laterale. Accedeva a luglio 2023 al Pronto Soccorso per febbre, tosse produttiva e dolore toracico gravativo. Agli accertamenti strumentali di primo livello si rilevavano alterazioni del tratto ST nelle derivazioni inferiori e in V1-V2 con T negative/isodifasiche, non presenti nei precedenti tracciati ECG in visione, associato a lieve rialzo della troponina con curva ischemica (101 → 303 à 277 à 155 pg/dl, v.n. <50 pg/dl) per cui veniva formulata diagnosi di SCA-NSTEMI. Ecocardiogramma: rimodellamento concentrico del ventricolo sinistro, normale funzione sistolica globale con ipocinesia della parete inferiore medio-basale (nota). Collateralmente, alla TC torace riscontro di addensamenti polmonari del lobo medio dx e del lobo superiore sx per cui veniva intrapresa terapia antibiotica ev e terapia inalatoria broncoattiva. EGA in AA: pH 7.45, pO2 83, Lat 0.8, HCO3- 24, P/F 360. Effettuava studio coronarografico che mostrava tuttavia quadro invariato rispetto al precedente (AMIS e AMID pervie; buon run-off nei rami nativi, non stenosi distalmente all'anastomosi). Durante il ricovero si assisteva alla remissione clinica dei sintomi, degli indici di flogosi e dei marker di danno miocardico. Veniva dimesso a seguito di ottimizzazione della terapia antischemica con DAPT e diagnosi di SCA-NSTEMI. Persistevano tuttavia alla dimissione le alterazioni elettrocardiografiche (T negativa in DI-aVL-V1-V2). Richiesta in post ricovero RM cardiaca.
Conclusioni. Le ipotesi diagnostiche sono in primo luogo un possibile IMA tipo II da discrepanza in corso di polmonite (sebbene durante il ricovero non siano mai state documentate ipossia/ipovolemia/ipotensione tali da determinare IM), MINOCA o malattia del microcircolo (durante lo studio coronarografico non sono stati eseguiti test funzionali come iFR/FFR, ACh, IMR) o possibile esito miocarditico (in attesa della RM).

Figura 1. Pattern ECG della sindrome di Wellens tipo 1 e 2.

A428: SPONTANEOUS LEFT MAIN CORONARY ARTERY DISSECTION: CLINICAL FEATURES, MANAGEMENT AND OUTCOMES

Michele Morosato (a, d), Carlo Gaspardone (b, d),Davide Romagnolo (a, d), Francesco Johannes Federico (a, d), Francesco Moroni (e), Matteo Pagnesi (f), Luca Baldetti (c), Alessandro Beneduce (a)
(a) CARDIOTHORACIC DEPARTMENT, IRCCS SAN RAFFAELE SCIENTIFIC INSTITUTE, MILAN, ITALY; (b) CARDIOLOGY UNIT, IRCCS SAN RAFFAELE SCIENTIFIC INSTITUTE, MILAN, ITALY; (c) CARDIAC INTENSIVE CARE UNIT, IRCCS SAN RAFFAELE SCIENTIFIC INSTITUTE, MILAN, ITALY; (d) VITA-SALUTE SAN RAFFAELE UNIVERSITY, MILAN, ITALY; (e) PAULEY HEART CENTER, VIRGINIA COMMONWEALTH UNIVERSITY, RICHMOND, VIRGINIA, USA; (f) INSTITUTE OF CARDIOLOGY, ASST SPEDALI CIVILI, BRESCIA, ITALY

Background. Spontaneous coronary artery dissection (SCAD) is a significant cause of myocardial infarction (MI), particularly in young women, and is linked to an increased risk of long-term major adverse cardiovascular events (MACE). Dissection involving the left main coronary artery (LM) is rare and lacks specific data. The aim of this study is to investigate clinical features, management, and outcomes of patients suffering from LM SCAD.

Methods. We conducted a systematic review and patient-level pooled analysis of literature published between 1990 and 2022 using "left main" and "dissection" as search keywords.
Results. The analysis included 125 patients diagnosed with LM SCAD. The mean patient age was 40±10 years, with women accounting for 80% of the cases. Cardiovascular risk factors were minimally prevalent. Remarkably, 36% of cases occurred during pregnancy. Most patients (75%) manifested acute coronary syndrome: 63% ST-segment-elevation MI, 28% with non-ST-segment-elevation MI, and 9% with unstable angina. Cardiogenic shock (CS) at presentation was documented in 21% of patients, while serious ventricular arrhythmias in 8% of cases. In 76% of patients, dissections spread to other vessels, most frequently affecting the left anterior descending artery (LAD) (in 68% of cases), and less commonly extending to both the LAD and left circumflex artery (in 40% of cases). In-hospital death occurred in 7% of the cohort. Invasive management was chosen for most of the patients, with percutaneous coronary intervention (PCI) and coronary artery bypass grafting (CABG) carried out in 29 (24%) and 45 (37%) patients, respectively. Revascularization was associated with lower rates of the primary composite endpoint of all-cause death, myocardial infarction, need for urgent myocardial revascularization, heart failure hospitalization and need for heart transplant or left ventricular assist device implantation (HR 0.32, 95%CI 0.17-0.61, p<0.001). In hemodynamically stable patients (88, 72%), the benefit of the invasive strategy was confirmed (HR 0.26, 95% CI 0.11-0.62, p=0.002) and a trend towards less incidence of the primary endpoint was also present in unstable patients (34, 28%) (HR 0.38, 95% CI 0.14-1.06, p=0.066). Further comparison of revascularization strategies among the 74 patients treated invasively revealed that patients undergoing CABG had a lower incidence of the primary endpoint compared to those treated with PCI (HR 0.29, 95% CI 0.10-0.87, p=0.027). This difference is primary driven by stable patients (CABG vs. PCI, HR 0.16, 95% CI 0.03-0.81, p=0.026) because conversely, when considering unstable patients, no difference was identified (CABG vs. PCI, HR 0.76, 95% CI 0.17-3.43, p=0.723).
Conclusions. Our analysis of the most extensive collection of LM SCAD patients showed considerable in-hospital mortality and post-discharge MACE. Revascularization significantly improved clinical outcomes regardless patient's hemodynamic condition.

A429: REAL-WORLD IMPACT ON MORTALITY OF DRUG ADHERENCE TO STATIN, BETA-BLOCKER AND ACEI/ARB THERAPY IN POST-STEMI PATIENTS WITH PRESERVED EF: RESULTS FROM THE FAST-STEMI REGISTRY

Marco Nebiolo (a), Giuseppe Giannino (a), Federico Giacobbe (a), Umberto Di Vita (a), Arianna Morena (a), Emanuele Ravetti (a), Mattia Troncone (a), Ludovica Carmagnola (a), Ovidio De Filippo (a), Fabrizio D´ascenzo (a), Francesco Bruno (a), Filippo Angelini (a), Umberto Annone (b), Gaetano Maria De Ferrari (a)
(a) DEPARTMENT OF MEDICAL SCIENCES, UNIVERSITY OF TURIN, TURIN, ITALY; DIVISION OF CARDIOLOGY, CARDIOVASCULAR AND THORACIC DEPARTMENT "CITTA DELLA SALUTE E DELLA SCIENZA DI TORINO" HOSPITAL, TURIN, ITALY; (b) CIVIC HOSPITAL OF CIRIE, CIRIE, ITALY

Background. The impact of drug therapy on cardiovascular outcomes after ST-elevation acute myocardial infarction (STEMI) in patients with preserved ejection fraction (EF) remains unknown.
Purpose. To identify the impact of drug adherence to statins, ACEi/ARB and beta-blockers on cardiovascular and all-cause mortality at one year after the index event and on total follow-up length in patients affected by STEMI with preserved EF.
Methods. We evaluated real-world adherence to the most common cardiovascular drugs by comparing the number of tablets purchased in Piedmont drugstores analyzing their registries, to the expected demand of tablets in the follow-up period. A total amount of 6043 patients from 2012 to 2017 was enrolled in the FAST-STEMI registry and followed up for 4,7±1,6 years. We excluded 299 patients with intraprocedural and intra-hospital deaths and 2595 patients with reduced or mildly reduced EF. The best compliance cut-off was found by ROC curve analysis with Youden index; Kaplan Meier and Cox proportional hazard models were performed to evaluate cumulative event rates of CV mortality and all-cause mortality at follow-up.
Results. Of the total 3194 patients were 2396 men (76.1%) with an average age of 63,3±12,1 years old. 318 (10,1%) were diabetic, 115 (3,7%) presented with CKD while 110 (3,5%) had previous CAD. The average adherence after 1 year to beta-blockers was 96,4% (IQR 82,2-100); to statins was 90,4% (IQR 40,3-100) and to ACEi/ARB 87,0% (IQR 61,4-100). At one year, optimal adherence to statin and ACEi/ARB therapy (defined over Youden's analysis cut offs) resulted both associated to lower cardiovascular mortality (0% vs 2,9%, p<0.001, and 0,1% vs 1,0%, p=0.001, respectively), as well as all-cause mortality (0,4% vs 9,9%, p<0.001, and 1,0% vs 2,5%, p=0.006 respectively) whereas no difference was seen based on beta-blockers adherence. On an average follow-up length of 4,92±1,35 years ACEi/ARB optimal adherence showed a reduction of both cardiovascular and all-cause death (1,4% vs 2,8%, p=0.036; 7,1% vs 12,4%, p<0.001), statins did not impact on CV mortality but reduced all-cause death (9,3% vs 11,4%, p=0.026) whereas beta-blockers adherence seemed not to correlate with both CV and all-cause mortality (2,5% vs 1,4%, p=0.03; 9,3% vs 7,3%, p=0.04), as shown in Fig 1. At multivariate Cox regression analysis ACEi/ARB adherence resulted independent predictor of reduced both CV (HR 0.49 95%CI 0.24-0.98, p=0.045) and all-cause mortality (HR 0.65 95%CI 0.46-0.93, p=0.01), statin adherence resulted independent predictor of reduced all-cause death (HR 0.68; 95% CI 0.47-0.90; p 0.04), beta-blockers did not show correlation with mortality.
Conclusions. In a real-world setting of patients after STEMI with preserved EF, lower ACEi/ARB and statin adherence resulted positively correlated with an increase in all death causes and cardiovascular mortality, whilst the adherence to the beta-blocker therapy seemed to not correlate with survival.



A430: PREDICTORS FOR AND THE ROLE OF ABNORMAL MAPPING VALUES AT CARDIAC MAGNETIC RESONANCE IN MYOCARDIAL INFARCTION WITH NON-OBSTRUCTIVE CORONARY ARTERIES

Andrea Impellizzeri (a), Lisa Canton (a), Khrystyna Ryabenko (a), Damiano Fedele (a), Marcello Casuso Alvarez (a), Ornella Di Iuorio (a), Virginia Marinelli (a), Claudio Asta (a), Luca Bergamaschi (a), Pasquale Paolisso (c), Anna Giulia Pavon (b), Luigi Lovato (d), Nazzareno Galiè (a), Carmine Pizzi (a)
(a) UNIT OF CARDIOLOGY, DEPARTMENT OF EXPERIMENTAL, DIAGNOSTIC AND SPECIALTY OF MEDICINE, UNIVERSITY OF BOLOGNA, BOLOGNA, ITALY; (b) CARDIOCENTRO TICINO INSTITUTE, LUGANO, SWITZERLAND; (c) UNIVERSITY OF NAPLES FEDERICO II, DEPARTMENT OF ADVANCED BIOMEDICAL SCIENCES, NAPLES, ITALY; (d) ALMA MATER STUDIORUM, UNIVERSITY OF BOLOGNA, RADIOLOGY UNIT - CARDIOTHORACIC VASCULAR DEPARTMENT, BOLOGNA, ITALY

Background. Cardiovascular magnetic resonance (CMR) plays a crucial role in the diagnostic approach of Myocardial infarction with non-obstructive coronary arteries (MINOCA), as a result of its ability to perform myocardial tissue characterization using mapping sequences.
Purpose. To analyze clinical and prognostic differences in MINOCA patients with and without abnormal mapping values when early CMR is performed.
Methods. We assessed all MINOCA cases from January 2017 to October 2021 in our Center. MINOCA was defined according to current European guidelines criteria. Acute myocarditis, Tako-tsubo syndromes and cardiomyopathies were excluded. CMR protocol included cine images, T1 and T2 mapping and late gadolinium enhancement (LGE). Abnormal mapping was considered as the presence of prolonged native T1 and T2 mapping with a specific pattern suggestive of ischemic myocardial injury. The receiver operating characteristics curve (ROC) for the detection of abnormal mapping was derivate. Multivariate logistic regression analysis was used to determine predictors of abnormal mapping. The primary outcome of major adverse cardiovascular events (MACE) in patients with and without abnormal mapping was evaluated.
Results. The final cohort included 198 MINOCA, 161 (81.3%) of which constituted the abnormal mapping group (M+) while the remaining 37 consisted of MINOCA without either abnormal mapping values or presence of late gadolinium enhancement (normal CMR findings, m-). The mean time delay between acute clinical presentation and CMR was 4.8 ± 1.5 days. Among the M+ group, patients were older and presented familiarity for cardiovascular disease and hypercholesterolemia more frequently compared to the m- group. At admission, the M+ group more frequently presented ST segment alterations, wall motion abnormalities (WMA) and greater left ventricular (LV) volumes, compared to the m- ones. Furthermore, the M+ group exhibited greater peak high sensitivity-Troponin I (hs-TnI) values. The ROC curve for the detection of abnormal mapping showed that peak Tn values had an excellent area under the curve (AUC) of 0.935 (95%CI 0.902-0.968), p<0.001. At multivariable analyses, adjusted for confounding factors, the strongest predictor of abnormal mapping was the peak hs-TnI values (OR 1.02, 95% CI 1.01-1.03, p<0.001). Finally, MINOCA M+ had more MACE compared to m- ones (16.8% vs 2.7%, p<0.001) at a mean follow up time of 33.7 ± 12.0 months.
Conclusions. Among selected MINOCA, abnormal mapping values when early CMR is performed identify a subgroup of patients with worse clinical presentation and outcome. Some baseline characteristics (such as ST alterations, WMA and LV volumes) may support the detection of abnormal mapping. Overall, peak hs-TnI values have an excellent diagnostic performance to predict abnormal mapping values and could be useful in identifying high-risk MINOCA and the consequent need for a CMR evaluation.

A431: CORONARY MICROVASCULAR DYSFUNCTION AND EARLY CARDIOVASCULAR COMPLICATIONS AFTER STEMI

Leonardo Portolan (a), Roberto Scarsini (a), Rafail Kotronias (b, c, d), Francesco Della Mora (a), Stefano Andreaggi (a), Stefano Benenati (b, c, d), Federico Marin (b, c, d), Sara Sgreva (a), Alberto Comuzzi (a), Caterina Butturini (a), Gabriele Pesarini (a), Domenico Tavella (a), Oxford Acute Myocardial Infarction Study Oxami Study (b, c, d), Keith Channon (b, c, d), Hector Garcia Garcia (e), Flavio Ribichini (a), Adrian Banning (b, c, d), Giovanni Luigi De Maria (b, c, d)
(a) DIVISION OF CARDIOLOGY, DEPARTMENT OF MEDICINE, UNIVERSITY OF VERONA, VERONA, ITALY; (b) OXFORD HEART CENTRE, OXFORD UNIVERSITY HOSPITALS NHS TRUST, OXFORD, UK; (c) DIVISION OF CARDIOVASCULAR MEDICINE, RADCLIFFE DEPARTMENT OF MEDICINE, UNIVERSITY OF OXFORD, OXFORD, UK; (d) NATIONAL INSTITUTE FOR HEALTH RESEARCH (NIHR), OXFORD BIOMEDICAL RESEARCH CENTRE, OXFORD, UK; (e) INTERVENTIONAL CARDIOLOGY, MEDSTAR WASHINGTON HOSPITAL CENTRE, WASHINGTON, USA

Background and Objectives. Previous data suggest that patients with no coronary microvascular dysfunction (CMD) after primary percutaneous coronary intervention (pPCI) suffer a very low rate of early cardiovascular complications (ECC) and can be considered for early discharge. Recently, the angiography-derived index of microcirculatory resistance (NH-IMR$_{angio}$) was demonstrated to be a reliable tool to assess CMD after pPCI in STEMI patients. We aim to assess whether NH-IMR$_{angio}$ could be a user-friendly tool to identify patients at low risk of ECC, potentially candidates for expedited care pathway and early hospital discharge.
Methods. 568 STEMI patients from a retrospective analysis of two independent, international, prospective, observational cohorts. After pPCI NH-IMR$_{angio}$ was measured starting from standard coronary angiographic views with 3D-modeling and computational analysis of the coronary flow. In the first cohort (298 patients, 52.5%) the pressure/thermodilution wire-based index of microcirculatory resistance was also assessed at the end of pPCI. The primary endpoint (early cardiovascular complications, ECC) was a composite of cardiovascular death, cardiogenic shock, acute heart failure, life-threatening arrhythmias, left ventricular thrombus, post-STEMI mechanical complications, and rehospitalization for acute heart failure or acute myocardial infarction at 30 days follow-up.
Results. Overall, 54 (9.3%) patients met the primary endpoint. NH-IMR$_{angio}$ showed good accuracy in predicting ECC (AUC=0.766 [0.706-0.827], p<0.0001) and a significant correlation with pressure/thermodilution-based IMR (r=0.607, p<0.0001). Importantly, patients with NH-IMR$_{angio}$-defined CMD (NH-IMR$_{angio}$≥40 units) suffered more frequently the primary endpoint (18.1% vs 1.4%, p<0.0001). NH-IMR$_{angio}$ was associated with incremental prognostic value compared to conventional clinical, angiographic and echocardiographic features (adjusted-odds-ratio 14.861 95% CI 5.177-42.661, p<0.0001). The absence of post-pPCI NH-IMR$_{angio}$-defined CMD (NH-IMR$_{angio}$<40 units) showed an excellent negative predictive value (98.6%) in ruling out ECC. Discharging patients with NH-IMR$_{angio}$<40 units 48 hours after admission would reduce the total in-hospital stay by 943 days (median 2 [1-4] days per patient).
Conclusions. NH-IMR$_{angio}$ is a valuable risk stratification tool in patients with STEMI. NH-IMRangio-guided strategies for early discharge may contribute to safely shorten hospital stay, optimizing resource utilization.

A432: PLAQUE BURDEN AND MORPHOLOGY: MULTIPARAMETRIC DATA INTEGRATION TO ADDRESS THE PREDICTION OF FUTURE CARDIAC EVENTS. A CLIMA SUBSTUDY

Simone Budassi (a, b), Flavio Giuseppe Bicciré (a, b, c), Valeria Marco (b), Ylenia La Porta (b, d), Emanuele Sammartini (b), Giulia Paoletti (b), Caterina Debelak (b, c), Giuseppe Varricchione (b, e), Mario Albertucci (a, b), Franco Fabbiocchi (f), Riccardo Di Pietro (a, b), Francesco Burzotta (g), Yukio Ozaki (h), Paolo Angelo Canova (i), Fernando Alfonso (j), Eloisa Arbustini (k), Francesco Prati (a, b, l)
(a) CARDIOLOGY DEPARTMENT SAN GIOVANNI ADDOLORATA HOSPITAL-ROME ITALY; (b) CENTRO LOTTA ALL'INFARTO (CLIC) FOUNDATION - ROME ITALY; (c) SAPIENZA UNIVERSITY OF ROME - ROME ITALY; (d) DEPARTMENT OF CARDIOVASCULAR SCIENCES, CAMPUS BIO MEDICO UNIVERSITY - ROME ITALY; (e) DEPARTMENT OF MEDICAL AND SURGICAL SCIENCES, UNIVERSITY OF FOGGIA - FOGGIA ITALY; (f) CENTRO CARDIOLOGICO MONZINO, IRCCS - MILAN ITALY; (g) DEPARTMENT OF CARDIOVASCULAR AND THORACIC SCIENCES, UNIVERSITÀ CATTOLICA DEL SACRO CUORE, FONDAZIONE POLICLINICO UNIVERSITARIO AGOSTINO GEMELLI - ROME ITALY; (h) DEPARTMENT OF CARDIOLOGY, FUJITA HEALTH UNIVERSITY HOSPITAL - TOYOAKE JAPAN; (i) PAPA GIOVANNI PAOLO XXIII HOSPITAL - BERGAMO ITALY; (j) DEPARTMENT OF CARDIOLOGY HOSPITAL UNIVERSITARIO LA PRINCESA - MADRID. SPAIN; (k) CENTER FOR INHERRITEDCARDIOVASCULAR DISEASE, IRCCSFONDAZIONE POLICLINICO SAN MATTEO - PAVIA ITALY; (l) SAINT CAMILLUS INTERNATIONAL MEDICAL UNIVERSITY - ROME ITALY

Background andAims. Aim of the present study was to investigate two different approaches to study the patient risk of developing future cardiac events: the burden of coronary atherosclerosis, as assessed by the Gensini score, and plaque morphology, as assessed by intracoronary optical coherence tomography (OCT).
Methods. We assessed the Gensini score and OCT features of plaque vulnerability in 847 patients from the CLIMA registry. Patients were divided into four Gensini quartiles: first quartile (<5.5 points), second quartile (5.5-10.5 points), third quartile (10.5-16.5 points), and fourth quartile (>16.5 points). The main study endpoint was a composite of cardiac death, myocardial infarction and/or target vessel revascularization.
Results. At 1-year follow-up, 65 patients (7,6%) experienced the main composite endpoint. The composite endpoint of cardiac death, MI or target vessel revascularization was significantly affected by the Gensini score (univariate HR 1.42, 95%CI 1.11-1.81, p=0.005; multivariate HR 1.35, 95%CI 1.03-1.77, p=0.027). We noticed a very low incidence of the main composite endpoint in the first Gensini quartile (1.3%) and a much higher incidence in the remaining groups (8.3% for the second Gensini quartile, 8.9% for the third and 8.3% for the fourth). When stratified for morphological plaque evaluation at OCT, patients in the last three quartiles with a FCT <75 µm (HR 2.93; p=0.001) or the simultaneous presence of the four CLIMA criteria of vulnerability (HR 5.94, p<0.001) experienced more frequently adverse events.
Conclusions. The burden of coronary artery disease, as assessed by the Gensini score, can predict clinical events. However, the presence of OCT criteria of plaque vulnerability further stratifies patients at risk of cardiac events, even in presence of an extensive angiographic coronary involvement.

A433: DISSEZIONI CORONARICHE SPONTANEE: TERAPIA MEDICA VS TERAPIA INTERVENTISTICA. RISULTATI A LUNGO TERMINE ED IMPLICAZIONI CLINICHE

Maria Teresa Savo (a), Saverio Continisio (c), Riccardo Bariani (a), Filippo Zilio (b), Francesca Mantovani (d), Giulia Mattesi (a), Carlo Maria Dellino (f), Elena Cozza (a), Filippo Amato (a), Barbara Bauce (a), Francesco Tona (a), Raffaella Motta (a), Antonello D´andrea (e), Eleonora Bonvicini (b), Roberto Bonmassari (b), Sabino Illiceto (a), Valeria Pergola (a)
(a) UNIVERSITÀ DEGLI STUDI DI PADOVA; (b) UNITÀ OPERATIVA DI CARDIOLOGIA, OSPEDALE SANTA CHIARA,AZIENDA PROVINCIALE PER I SERVIZI SANITARI, TRENTO; (c) ISTITUTO CLINICO SAN ROCCO-SAN DONATO GROUP BRESCIA; (d) ARCISPEDALE SANTA MARIA NUOVA REGGIO EMILIA; (e) PRESIDIO OSPEDALIERO UMBERTO I-NOCERA INFERIORE U.O.C. CARDIOLOGIA; (f) IRCCS ISTITUTO CLINICO HUMANITAS RESEARCH HOSPITAL, ROZZANO MILANO

Background. La dissezione coronarica spontanea (SCAD) rappresenta una causa di sindrome coronarica acuta, infarto del miocardio e morte cardiaca improvvisa. L'incidenza globale della SCAD è di circa il 4% di tutte le sindromi coronariche acute, sebbene raggiunga il 35% tra le donne giovani. Il trattamento della SCAD può comprendere l'approccio conservativo con terapia medica, il trattamento invasivo con angioplastica percutanea (PCI) o chirurgico mediante bypass aorto-coronarico (CABG).
Materiali e metodi. Tutti i pazienti con SCAD e con dati disponibili al follow-up ricoverati in 5 centri italiani sono stati inclusi nel presente studio osservazionale retrospettivo e divisi in 3 gruppi secondo il trattamento ricevuto: 1) terapia medica conservativa, 2) PCI, 3) CABG. Gli endpoints primari considerati al follow-up erano i seguenti: morte per tutte le cause, infarto del miocardio, SCAD ex novo, ricovero non programmato per PCI, e sanguinamenti maggiori. Inoltre gli stessi endpoints sono stati valutati in una sub-analisi del gruppo terapia medica riguardo singola o duplice terapia antiaggregante (SAPT, DAPT).
Risultati. Dei 205 pazienti inclusi nello studio, la maggioranza (167 pari a 81,5%) ha ricevuto un trattamento conservativo con terapia medica, mentre 38 pazienti (18,5%) sono stati sottoposti a trattamento interventistico/chirurgico. I gruppi PCI e CABG comprendevano in maniera statisticamente significativa pazienti con un numero maggiore di vasi coinvolti (p<0.001), lunghezza maggiore della dissezione (p<0.001) e maggior coinvolgimento di segmenti prossimali (p<0.001). Ad un follow-up medio di 7,5 anni non veniva osservata alcuna differenza per quanto riguarda i seguenti endpoint: infarto del miocardio (p=0.403), morte per tutte le cause (p=0.613), SCAD ex novo (p=0.625), e sanguinamenti maggiori (p=0.789). Contrariamente, i pazienti del gruppo PCI hanno mostrato una più alta incidenza di ricoveri non programmati per PCI ex novo (10.5% vs 1.3%, p=0.022). Tra i pazienti trattati conservativamente, 110 (65,9%) sono stati trattati con SAPT e 48 (28,7%) con DAPT. I pazienti trattati con DAPT presentavano un maggior tasso di infarto del miocardio al follow-up (p=0.012), mentre non si osservata nessuna differenza tra i sottogruppi per gli altri endpoints.
Conclusioni. Il trattamento maggiormente diffuso per i pazienti affetti da SCAD è rappresentato dalla terapia medica conservativa, mentre l'approccio interventistico/chirurgico viene riservato a pazienti con maggior numero di vasi coinvolti e segmenti prossimali. Non vi è alcuna differenza tra i vari gruppi di trattamento per eventi avversi maggiori, ad eccezione di una più elevata incidenza di PCI ex novo al follow-up nel gruppo interventistico.

A434: EFFICACY AND SAFETY OF BRIDGING ANTIPLATELET THERAPIES IN PATIENTS UNDERGOING CARDIAC AND NON-CARDIAC SURGERY: META-ANALYSIS

Riccardo Scalamera (a), Stefano Benenati (a, c), Roberta Della Bona (b), Pietro Ameri (a, b), Marco Canepa (a, b), Rocco Vergallo (a, b), Italo Porto (a, b)

(a) DIPARTIMENTO DI MEDICINA INTERNA (DIMI), UNIVERSITÀ DEGLI STUDI DI GENOVA, GENOVA, ITALIA; (b) UNITÀ OPERATIVA DI CARDIOLOGIA, DIPARTIMENTO CARDIO-TORACO-VASCOLARE (DICATOV), OSPEDALE POLICLINICO SAN MARTINO IRCCS - IRCCS CARDIOVASCULAR NETWORK, GENOVA, ITALIA; (c) OXFORD HEART CENTRE, JOHN RADCLIFFE HOSPITAL, OXFORD UNIVERSITY HOSPITALS - NHS FOUNDATION TRUST - OXFORD - UNITED KINGDOM

Aim. To compare the rates of adverse events across different bridging antiplatelet therapies administered in the context of surgical procedures.
Methods. We performed a meta-analysis of studies reporting adverse events after cardiac (CS) or non-cardiac surgery (NCS). Co-primary endpoints were the incidence rates (IR) of study-defined major adverse cardiovascular events (MACE) and fatal or life-threatening bleeding. Overall trend for subgroup difference was assessed, carrying out pairwise comparisons when the former was significant. Meta-regressions were run to assess the impact of the type of surgery.
Results. 21 (n=757) articles were selected, including 1 randomized controlled trial (RCT), 15 observational studies and 5 case series. The overall IR of MACE was 3.16% (95% CI 1.65%-4.67%) and significant difference across subgroups was found (p<0.01). Both cangrelor (IR 6.93%, 95% CI 3.67%-10.19%) and eptifibatide (IR 5.25%, 95% CI 1.78%-8.71%) resulted in higher rates compared to tirofiban (IR 1.12%, 95% CI 0%-3.08%, p=0.01 vs. cangrelor and p=0.04 vs. eptifibatide). The incidence of life threatening or major bleeding was 5.8% (95% CI 2.67%-8.93%), without significant differences across subgroups (p=0.21). Meta-regression showed heightened incidence of fatal or life-threatening bleeding across progressively higher percentages of patients undergoing CS (p=0.007), which in turn were more represented in studies using cangrelor.
Conclusions. When administered as a bridging therapy in the context of surgical procedures, tirofiban is associated with lower MACE compared to cangrelor and eptifibatide. Selection bias resulting in higher frequency of CS procedures in cangrelor studies should be accounted for when assessing the impact of different bridging therapies on life threatening or major bleeding.

A435: SAFETY AND EFFICACY OF LOW-DOSE TICAGRELOR AFTER 33 MONTHS FOLLOW-UP

Gianmaria Scherillo (a, m), Arturo Cesaro (a, m), Vincenzo Acerbo (a, m), Gianantonio De Michele (a, m), Giovanni Signore (a, m), Giuseppe Raucci (a, m), Marco Tontodonato (a, m), Andrea Vergara (a, m), Domenico Panico (a, m), Francesco Paolo Rotolo (a, m), Francesco Scialla (a, m), Gennaro Porcelli (a, m), Grazia Brienza (k), Carmine De Matteis (b), Vincenzo De Rosa (c), Luigi Di Lorenzo (d), Giovanni Di Tommaso (e), Andrea Farro (j), Monica Sicuranza (j), Luciano Fattore (f), Franco Guarnaccia (g), Pietro Iodice (h), Massimo Di Giorgio (k), Giosuè Santoro (k), Salvatore Severino (i), Angelo Silverio (l), Gennaro Galasso (l), Paolo Calabrò (a, m)
(a) AORN SANT'ANNA E SAN SEBASTIANO; (b) P.O. MADDALONI (ASL CE); (c) P.O. DOTT.SSA ANASTASIA GUERRIERO MARCIANISE (ASL CE); (d) P.O. SAN ROCCO SESSA AURUNCA (ASL CE); (e) P.O. PIEDIMONTE MATESEE (ASL CE); (f) P.O. SAN GIUSEPPE MOSCATI AVERSA (ASL CE); (g) CENTRO POLIDIAGNOSTICO "ANGIOCARD" SANT'ANTIMO (ASL NAPOLI 2 NORD); (h) P.O. MELORIO SANTA MARIA CAPUA VETERE (ASL CE); (i) CASA DI CURA "SAN MICHELE" MADDALONI (ASL CE); (j) PINETA GRANDE HOSPITAL (ASL CE); (k) ASL CE; (l) UNIVERSITÀ DEGLI STUDI DI SALERNO; (m) UNIVERSITÀ DEGLI STUDI DELLA CAMPANIA "LUIGI VANVITELLI"

The optimal Dual Antiplatlet Therapy (DAPT) duration in patients with high ischemic risk remains controversial. The PEGASUS-TIMI 54 trial showed that in patients with Miocardial Infarction (MI) and additional ischemic risk factors the use of low-dose Ticagrelor (60mg bis in die) reduced the risk of cardiovascular death, MI, and stroke compared with placebo. However, follow-up for PEGASUS-TIMI 54 was 33 months long, therefore benefits and risks associated with continuation of this treatment beyond this time point is at present unclear. We aimed at reporting real life data on the use of prolonged DAPT with Ticagrelor 60mg beyond 3 years, analyzing long-term efficacy and safety outcomes. We enrolled consecutive patients eligible for Ticagrelor 60 mg in six high-volume centers, and collected 18 months outcomes. The primary efficacy end point was 18-months net major adverse clinical events (NACE) defined as a composite of all-cause mortality, myocardial infarction, stroke, CV-related hospitalization, and major bleeding. One-hundred thirty two patients completed follow-up. At 18 months follow-up, 4 patients (3%) experienced a new MI, and 8 patients a new revascularization (6%). 4 patients had stroke, 2 of which ischemic (1,5%) and 2 of which hemorragic (1,5%). The percentage of patients with BARC 2-3-5 bleeding events was consistent with PEGASUS-TIMI 54 and than other clinical trials were BARC classification was used. In conclusion, in a real-world study involving patients with a history of myocardial infarction, our data show the safety and efficacy of Ticagrelor 60mg bis in die after the 3-year limit of the PEGASUS-TIMI 54 trial.

A436: IN-HOSPITAL AND LONG-TERM CLINICAL OUTCOMES OF AN ALL-COMERS POPULATION UNDERGOING ROBOTIC PERCUTANEOUS CORONARY INTERVENTION (R-PCI): SINGLE CENTER REGISTRY

Michele Mattia Viscusi (a, b), Dario Bertolone (a, b), Konstantinos Bermpeis (a), Thabo Mahendiran (a), Giulia Botti (a), Marta Belmonte (a, b), Emanuele Gallinoro (a), Pasquale Paolisso (a, b), Jozef Bartunek (a), Jeroen Sonck (a), Carlos Collet (a), Adriaan Wilghenof (a), Bernard De Bruyne (a), Emanuele Barbato (a, c), Marc Vanderheyden (a), Eric Wyffels (a)
(a) CARDIOVASCULAR RESEARCH CENTER, OLV HOSPITAL, AALST, BELGIUM; (b) DEPARTMENT OF ADVANCED BIOMEDICAL SCIENCES, UNIVERSITY OF NAPLES, FEDERICO II, NAPLES, ITALY; (c) DEPARTMENT OF CLINICAL AND MOLECULAR MEDICINE, SAPIENZA UNIVERSITY, ROME, ITALY

Robotic Percutaneous Coronary Intervention (R-PCI) is an approach where the operator manipulates guidewires and catheter devices remotely from a radiation-shielded cockpit. R-PCI provides several advantages over conventional manually-performed PCI, in terms of reduction in radiation exposure and occupational hazard. Several studies performed in the last 15 years confirmed the safety and efficacy of robotic assisted coronary interventions for simple coronary lesions. However, despite a growing body of contributions has been collected also in multiple complex clinical setting, the currently available evidence are still inconclusive in terms of in-hospital and, particularly, long-term clinical outcomes. Therefore, we aimed to report the main results of our single-center (Cardiovascular Research Center, OLV Hospital, Aalst, Belgium) registry including 111 patients who underwent R-PCI between 2021 and 2023. Clinical outcomes have been finally compared according to the complexity of the procedure using the median value of SYNTAX Score (SS≥14 vs <14). The reported mean age in the overall population has been 68.7±10.6, with a higher prevalence of males (68.5%). The vast majority were patients affected by stable coronary artery disease (92%), some of them with previous history of either PCI (28.8%) or bypass surgery (10.8%). The target vessel has been the left anterior descending (LAD) artery in almost half of the patients, with a mean SYNTAX Score of 14.8±8.4 and predominantly B1 lesions (44.8%). Nearly half of interventions were bifurcation-PCI, moreover multivessel PCI and CTO-PCI have also been performed (14.4% and 3.6%, respectively). Technical success has been achieved in 91% of the procedures, with 1.8% of robotics malfunctions and a very low rate of manual conversion (4.5%). In the overall population, long-term clinical outcomes (mean follow-up ~309 days) are showed in Figure 1. When assessing procedural and in-hospital events in the two groups (SS≥14 vs <14), we observed significantly longer procedural times and Dose-Area Product (DAP) in patients undergoing more complex procedures (94.5±32.1 vs 78.7±25.5, p=0.011 and 109.1±103.2 vs 75.1±66.2, p=0.010, respectively) with no further relevant difference between the two groups (Figure 2 and 3). In conclusion, our experience confirms the safety and effectiveness of R-PCI reporting very low rates of in-hospital and long-term complications regardless the complexity of the procedure. However, in less complex procedures, R-PCI is associated with significantly lower procedural time and radiation exposure.

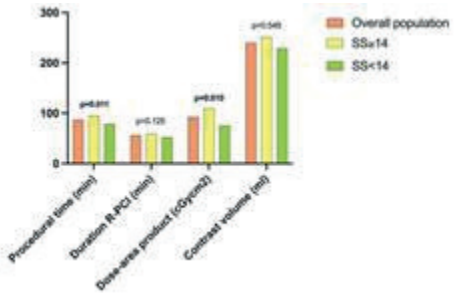

Figure 1

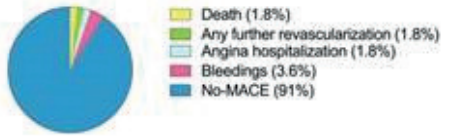

Figure 2

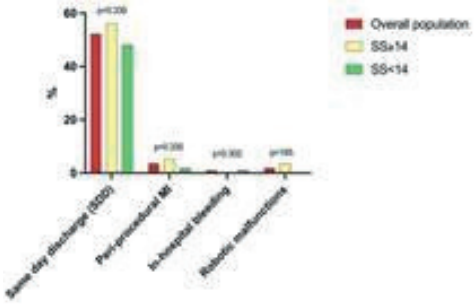

Figure 3

A437: COMPARISON OF MYOCARDIAL INFARCTION WITH NON-OBSTRUCTIVE CORONARY ARTERIES (MINOCA) VERSUS TYPE 2 MI WITH NSTEMI PRESENTATION; AN ITALIAN OBSERVATIONAL STUDY

Laura Padoan (c, d), Laura Munaretto (a), Enzo Merro (a), Alessandra Lucia Fluca (a), Milijana Janjusevic (a), Agnese Derin (a), Vincenzo Chiarandia (a), Alessandro Pierri (b), Stefano D´errico (a), Cristina Hiche (a), Andrea Di Lenarda (e), Gianfranco Sinagra (a), Aneta Aleksova (a)

(a) AZIENDA SANITARIA UNIVERSITARIA DI TRIESTE AND UNIVERSITY OF TRIESTE, DEPARTMENT OF MEDICAL SURGICAL AND HEALTH SCIENCES, CARDIOVASCULAR DEPARTMENT, TRIESTE, ITALY; (b) CARDIOLOGY DEPARTMENT AND INTENSIVE CORONARY CARE UNIT, PERRINO HOSPITAL, BRINDISI, ITALY; (c) AZIENDA SANITARIA UNIVERSITARIA GIULIANO ISONTINA, CARDIOLOGY DEPARTMENT GORIZIA-MONFALCONE, GORIZIA, ITALY; (d) UNIVERSITY OF PERUGIA, CARDIOLOGY AND CARDIOVASCULAR PATHOPHYSIOLOGY, PERUGIA, ITALY; (e) AZIENDA PER L'ASSISTENZA SANITARIA N.1, OSPEDALE MAGGIORE, CENTRO CARDIOVASCOLARE, TRIESTE, ITALY

Background. Overlapping clinical-instrumental features despite different etiology of myocardial infarction with non-obstructive coronary arteries (MINOCA) and type 2 myocardial infarction (MI) with non-obstructive coronary disease, presenting as non-ST elevation myocardial infarction (NSTEMI) pose a diagnostic challenge to clinicians, further influencing appropriate therapy and risk stratification.

Aim. To determine the prevalence of MINOCA and type 2 MI with non-obstructive coronary disease within a large population of patients, to identify subtle differences and clinical-instrumental features between two entities, the factors involved in the disease development and worsening conditions during long-term period.

Methods. After reviewing the angiographic and clinical data of 18223 patients with MI who underwent coronary angiography between 2005 and 2022, 538 patients were included in the study (301 (56%) of whom had MINOCA and 237 (44%) had type 2 MI). The primary outcome was a composite of all-cause mortality, non-fatal AMI, hospitalization for heart failure (HF) and non-fatal transitory ischemic attack (TIA) or stroke.

Results. The mean age of the whole cohort was 68 (11.5) years. In each sub-cohort, two-thirds of patients were female. Compared with type 2 MI patients, MINOCA patients were younger (66.3 ± 11.7 vs. 70.6 ± 11 years, p<0.01), more likely to be smokers (p<0.01) and to have atypical cardiovascular risk factors such as adverse pregnancy events (p=0.01). Patients with type 2 MI were more likely to have typical risk factors including diabetes (p<0.01), hypertension (p=0.002), carotid atherosclerotic disease (p<0.01) and sedentary lifestyle (p=0.002). At logistic regression analysis typical chest pain (p<0.01), lower heart rate (p=0.01), sinus rhythm (p<0.01), younger age (p=0.02), hypo/akinesia with non-coronary echocardiographic distribution (p<0.01), postmenopausal status (p=0.01), and the absence of following: palpitations (p<0.01), ST-segment changes (p<0.01), diastolic dysfunction (p<0.01), were found to be independent predictors of MINOCA. The final model of the predictors of MINOCA, at multivariate logistic regression analysis, had a very high AUC of 0.865, p<0.01 at ROC analysis. These variables were used for the generation of nomogram for MINOCA prediction. During a median follow-up of 61.1 months, 135 patients (25,1%) met the primary combined end-point (11% MINOCA, 14,1% type 2 MI). At Kaplan-Meier analysis, MINOCA patients had better outcomes than patients with type 2 MI (p<0.01). At Cox multivariable regression analysis, older age, male gender, worse systolic function and the following comorbidities: chronic obstructive pulmonary disease, chronic renal failure, hyperuricemia, and hematologic disease, were independent predictors of a worse outcome.

Conclusions. The MINOCA cohort was associated with unconventional cardiovascular risk factors. Although a significant number of patients with MINOCA reached the primary end-point, this cohort had a more favorable prognosis in comparison to type 2 MI during the long-term follow-up.

A438: NO GENDER DIFFERENCES OF IMPACT OF VITAMIN D DEFICIENCY ON THE SEVERITY OF CAD

Aneta Aleksova (d, e), Alessandra Lucia Fluca (d, e), Milijana Janjusevic (d, e), Beatrice Pani (d), Laura Munaretto (e), Lorenzo Zandonà (a), Andrea Chicco (a), Agnese Derin (e), Cristina Hiche (e), Alessandro Pierri (f), Laura Padoan (e, g), Antonio Paolo Beltrami (b), Enzo Merro (e), Stefano D´errico (d), Elisabetta Stenner (c), Gianfranco Sinagra (d, e)

(a) SC LABORATORIO UNICO, OSPEDALE MAGGIORE, ASUGI, TRIESTE, ITALY; (b) UNIVERSITÀ DEGLI STUDI DI UDINE, UDINE, ITALY; (c) USL TOSCANA NORDOVEST, CHEMICAL-CLINICAL ANALYSIS LABORATORY, DEPARTMENT OF DIAGNOSTICS, PISA, ITALY; (d) UNIVERSITÀ DEGLI STUDI DI TRIESTE, TRIESTE, ITALY; (e) AZIENDA SANITARIA UNIVERSITARIA GIULIANO ISONTINA, CARDIOTHORACOVASCULAR DEPARTMENT, TRIESTE, ITALY; (f) CARDIOLOGY DEPARTMENT AND INTENSIVE CORONARY CARE UTIC, PERRINO HOSPITAL, BRINDISI, ITALY; (g) UNIVERSITY OF PERUGIA AND CARDIOVASCULAR PATHOPHYSIOLOGY, PERUGIA, ITALY

Background. Vitamin D deficiency is common in patients with acute myocardial infarction (AMI). Low vitamin D levels are associated with a pro-inflammatory state, endothelial dysfunction and vascular stiffness that increase the risk of adverse outcomes in patients with AMI with an effect comparable to diabetes mellitus.

Aims and Methods. Blood samples were collected on admission from 1444 patients who had undergone coronary angiography for acute coronary syndrome from 2014 to 2022. The aim was to assess the association of low vitamin D levels with the incidence and severity of coronary artery disease (CAD) and the impact of gender differences on the outcome in patients with severe hypovitaminosis D. CAD was defined as the presence of at least one coronary vessel stenosis greater than 50%. Severe CAD was defined as three-vessel and/or left main coronary artery disease. Hypovitaminosis D was defined as a vitamin D level of 20 ng/ml or less, while vitamin D concentrations ≤10 ng/ml were identified as severe hypovitaminosis D. The outcome was all-cause mortality.

Results. In our cohort, the mean age was 66.07 (11.44) and 404 (28%) patients were female. A comparison between genders showed that females were older (69.94 (11.39) vs. 64.57 (11.11), respectively, p<0.01). Female patients had lower levels of vitamin D compared to male patients (15.7 [8.63 – 25.48] vs 17.95 [11.1 – 24.4] ng/ml, p<0.01). However, hypovitaminosis D was highly prevalent in both genders (females 62.1% Vs. males 58.1%, p=0.16). At logistic multivariable regression analysis, male gender (OR: 3.36, p<0.01), older age (OR: 1.14, p<0.01), diabetes mellitus (OR: 1.8, p=0.01) and high cholesterol levels (OR: 1.04, p=0.02) were independent predictors of CAD but not vitamin D levels. While, severe CAD was predicted by severe hypovitaminosis D (OR: 1.49, p=0.02), male gender (OR: 2.21, p<0.01), diabetes mellitus (OR: 1.33, p=0.04), older age (OR: 1.16, p<0.01), low levels of haemoglobin (OR: 1.49, p=0.04), uric acid>7 mg/dl (OR: 1.43, p=0.01), high levels of C-reactive protein (CRP) (OR: 1.03, p=0.03) and statin treatment (OR: 1.53, p<0.01). Using the variables in the final model, we computed a nomogram for predicting severe CAD. During a median follow-up of 66 [39 - 99] months, 332 (23%) patients died. The Kaplan-Meier analysis estimates that the female gender was more susceptible to adverse events than males, considering patients with CAD (p<0.01) and severe CAD (p<0.01). Women had a higher risk of death than man both in patients with and without severe hypovitaminosis D (p<0.01 and p=0.05, respectively). At multivariable Cox regression analysis, in patients with severe CAD, severe hypovitaminosis D was an independent predictor of adverse outcome (HR: 1.79, p<0.01) along with older age (HR: 1.09, p<0.01), diabetes mellitus (HR: 1.51, p=0.04), GFR<60 ml/min/1.73 m^2 (HR: 2.51, p<0.01) but not gender. In female patients, older age (HR: 1.08, p<0.01), diabetes mellitus (HR: 2.23, p<0.01), GFR<60 ml/min/1.73 m^2 (HR: 2.91, p<0.01) and worse left ventricular systolic function (HR: 1.22, p<0.01) were independent predictors of death but not vitamin D levels.

Conclusions. Low levels of vitamin D contribute to the severity of CAD. In patients with severe CAD, low vitamin D levels contributes to an adverse outcome with no differences between genders.

A439: SINDROME CORONARICA ACUTA CAUSATA DA PUNTURA DI VESPA (SINDROME DI KOUNIS)

Pasquale Gagliardi (a), Giuseppe Lanzillo (a), Barbara Marinoni (a), Barbara Petracci (a), Enrico Baldi (a)

(a) DIVISIONE DI CARDIOLOGIA, FONDAZIONE IRCCS POLICLINICO SAN MATTEO, PAVIA, ITALY

La Sindrome di Kounis (KS) è definita come l'insorgenza di una sindrome coronarica acuta (SCA) associata a una reazione anafilattica. Un uomo di 64 anni, sportivo, con anamnesi cardiologica muta giungeva presso il Pronto Soccorso del nostro Ospedale per dispnea e dolore toracico insorti durante attività fisica e preceduti da episodio sincopale. Il paziente riferiva di aver avvertito, durante lo svolgimento dell'attività fisica (ciclismo) una sensazione di puntura di insetto, senza possibilità di identificarla precisamente. I parametri all'arrivo erano: PA 85/45 mmHg, FC 70 bpm, all'ECG segni di ripolarizzazione precoce (Fig. 1), agli ematochimici rialzo della hsTNI (328 ng/L), D-Dimero nella norma. L'ecocardiogramma transtoracico non mostrava anomalie della cinesi. In considerazione del sospetto di KS, si impostava terapia solo con ASA e statina, evitando i farmaci comunemente usati per trattare le reazioni allergiche che avrebbero potuto peggiorare il quadro emodinamico e vasomotorio riducendo ulteriormente la perfusione coronarica. Durante il ricovero in Cardiologia, in considerazione del quadro clinico e dei fattori di rischio cardiovascolare (dislipidemia e pregresso tabagismo), si effettuava coronarografia, che mostrava coronarie indenni da lesioni ostruttive angiograficamente significative, ma che evidenziava, durante la prima iniezione di mezzo di contrasto, vasospasmo dell'ostio della coronaria di destra, dominante (Fig. 2 - sx), risoltosi spontaneamente (Fig. 2 - dx). Il picco di hsTNI post-procedurale (3953 ng/L) e la presenza dell'antigene i77 della Vespa Europea al dosaggio sierologico degli allergeni supportava la fisiopatologia della sindrome coronarica acuta concomitante alla reazione allergica ed avvalorava l'ipotesi diagnostica di KS tipo I (senza coronaropatia sottostante). Si dimetteva il paziente in terapia con calcio-antagonisti, per contrastare il vasospasmo coronarico che caratterizza la KS, e si programmava follow-up a breve termine con esami ematochimici, test ergometrico e visita cardiologica che risultavano nella norma. La KS, sebbene rara, è un'entità clinica da non sottovalutare, soprattutto nei soggetti allergici con evidenza di SCA senza occlusioni coronariche. I dati disponibili in letteratura sono scarsi e non è chiaro

quale sia la prognosi a medio-lungo termine. Appare quindi ragionevole seguire i pazienti ambulatorialmente soprattutto nei primi mesi post-evento e programmare dei test strumentali di controllo.

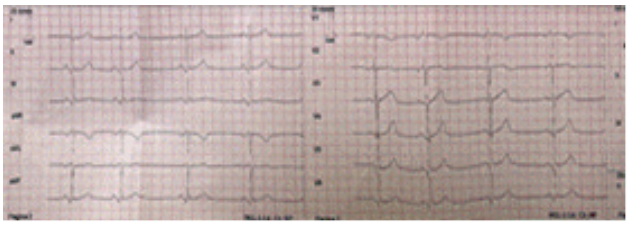

Figura 1.

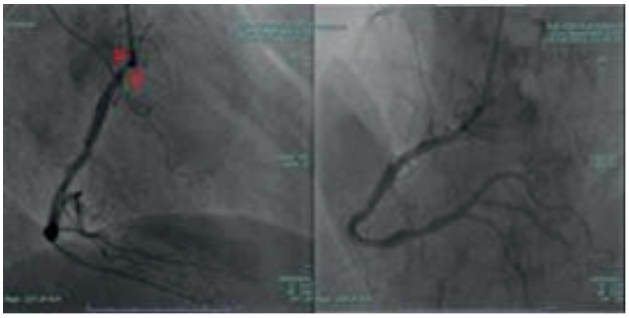

Figura 2.

A440: NUOVO EVENTO CARDIOVASCOLARE A DISTANZA DI UN ANNO IN PAZIENTE CON BUON CONTROLLO DEI FATTORI DI RISCHIO CARDIOVASCOLARE

Domenico Mario Giamundo (a), Alessio Di Landro (a), Giulia Manni (a), Linda Cota (a), Domenico Sergi (a), Lucy Barone (a), Massimo Marchei (a), Francesco Barillà (a)
(a) POLICLINICO TOR VERGATA

Introduzione. La prevenzione secondaria dopo SCA (sindrome coronarica acuta) è di fondamentale importanza per ridurre l'incidenza di MACE e migliorare la prognosi nel follow-up. Il controllo dei fattori di rischio evitabili, le modifiche dello stile di vita, ma soprattutto il controllo accurato della colesterolemia (con un target di LDL-C<55 mg/dL) e la doppia terapia antiaggregante (ASA in associazione con un inibitore del recettore P2Y12), sono delle raccomandazioni mandatorie (classe IA) per ridurre il rischio di stent trombosi, reinfarto e progressione di malattia aterosclerotica (nel vaso culprit e non).
Caso clinico. Paziente di 68 anni, con storia anamnestica di dislipidemia e pregresso STEMI anteriore (2021), complicato da arresto cardiocircolatorio, trattato con angioplastica primaria ed impianto di 2 stent sul tratto medio dell'arteria discendente anteriore (IVA), in prossimità dell'origine del primo ramo diagonale. A maggio 2023 accede all'ambulatorio del nostro nosocomio per un controllo casuale e riferisce che da circa un mese accusa un dolore, incostante, gravativo, all'emitorace sinistro, non in rapporto con l'esercizio, a regressione spontanea. L'ECG mette in evidenza un sottoslivellamento orizzontale, più marcato in V4-V5 e negativizzazione dell'onda T in aVL, compatibili con ischemia subendocardica in sede antero-laterale. Il paziente viene inviato al DEA, dove gli esami ematochimici documentavano incremento degli indici di miocardiocitonecrosi (troponina I hs di 3492 ng/L), veniva posta diagnosi di NSTEMI e il paziente veniva inviato in emodinamica per studio coronarografico. L'esame documentava una buona pervietà degli stent sul tratto medio dell'IVA e una subocclusione del primo ramo marginale ottuso, che viene trattato con PTCA mediante pallone medicato. L'ecocardiogramma eseguito durante la degenza, ha documentato una ipocinesia del setto e dell'apice del ventricolo sinistro, con funzione sistolica globale conservata (FE 50%), disfunzione diastolica di I grado (E/A 0.8), lieve insufficienza mitralica e tricuspidale. Il profilo lipidico durante la degenza era il seguente: trigliceridi 70 mg/dL, colesterolo totale 92 mg/dL, LDL 40 mg/dL, HDL 37 mg/dL, Lp(a) 24.9 mg/dL (V.N. <30 mg/dL). Lo screening trombofilico era il seguente: omocisteina 12.20 µmol/L (V.N. 5.4-16.2 µmol/L), fattore V Leiden 52% (V.N. 80-120%), test di resistenza alla proteina C attivata-V Leiden 287 sec (V.N.>120 sec), antitrombina III 73% (V.N. 80-120%), proteina C funzionale 76% (V.N. 65-145%), proteina S funzionale 94% (V.N. 74-146%), fibrinogenemia 400 mg/dL. Lo studio genotipico è negativo per polimorfismi del fattore V Leiden e del fattore II. Il paziente è stato dimesso continuando la doppia terapia antiaggregante a dosaggio pieno (Cardioaspirina 100 mg/die e Ticagrelor 90 mg/bid) ed ottimizzando la terapia per il trattamento della dislipidemia con un inibitore del PCSK9 associato a Rosuvastatina ed Ezetimibe, con l'obiettivo di mantenere un target di LDL-C ≤20 mg/dL.
Conclusioni. Il caso clinico da noi riportato è a conferma che alcuni pazienti, nonostante un accurato controllo dei fattori di rischio, del target di LDL-C e un trattamento farmacologico ottimizzato, hanno un rischio residuo di eventi CV elevato. In questi pazienti è verosimile che i target di LDL-C devono essere ancora più stringenti, probabilmente, come già dimostrano alcuni dati della letteratura, al di sotto di quelli attualmente raccomandati dalle linee guida.

A441: COMPLICANZE EMORRAGICHE DOPO INFARTO MIOCARDICO ACUTO: RISULTATI DEL CAMPUS-VASCULAR DISEASE REGISTRY

Agostino Spanò (a), Ylenia La Porta (a), Ilaria Cavallari (a), Asia Festa (a), Rosetta Melfi (a), Gianpaolo Ussia (a), Francesco Grigioni (a)
(a) DIPARTIMENTO DI SCIENZE CARDIOVASCOLARI, UNIVERSITÀ CAMPUS BIOMEDICO DI ROMA, ROMA

Background. La terapia antitrombotica riduce l'incidenza di eventi ischemici ricorrenti nell'infarto miocardico acuto (IMA) al costo di un aumento dei sanguinamenti che si associa ad un rischio di mortalità comparabile o superiore a quello di un nuovo IMA.
Obiettivi principali. Valutare l'incidenza e la gravità dei sanguinamenti intra-ospedalieri, a 6 e a 12 mesi nei pazienti con IMA di tipo 1, identificare le variabili associate al rischio di sanguinamenti intra-ospedalieri e confrontare diversi score di rischio emorragico.
Metodi. Sono stati inclusi pazienti con diagnosi di IMA di tipo 1 ricoverati presso l'UTIC della Fondazione Policlinico UNIVERSITARIO Campus Bio-Medico di Roma tra Ottobre 2020 e Novembre 2022. Il rischio emorragico è stato valutato tramite alcuni score (PRECISE-DAPT, criteri ARC-HBR, PEGASUS-HBR e SWEDEHEART). I sanguinamenti sono stati definiti secondo la classificazione BARC. Sono stati inoltre raccolti dati sulla sede dei sanguinamenti, sulla loro gravità e sulla gestione della terapia antitrombotica.
Risultati. Sono stati inclusi 190 pazienti, di cui 32.6% di sesso femminile. Al baseline, il 42.6% dei pazienti era ad elevato rischio di sanguinamento secondo lo score PRECISE-DAPT e il 44.2% secondo i criteri ARC. L'incidenza di sanguinamenti intra-ospedalieri è stata del 32.1%, di cui il 9.0% maggiori. A 6 mesi e 12 mesi l'incidenza di sanguinamenti è stata rispettivamente del 15.4% e del 24.0%. I pazienti che avevano sperimentato un sanguinamento intra-ospedalieri avevano un significativo aumento del rischio di mortalità nel follow-up indipendentemente dalla loro gravità. Le variabili associate ad un aumentato rischio di sanguinamenti intra-ospedalieri BARC 3b erano un ridotto filtrato glomerulare (p=0.013), un valore elevato di proteina C reattiva (p=0.026), l'uso del prasugrel o del ticagrelor (p=0.022) e un punteggio PRECISE-DAPT ≥25 (p=0.015).
Conclusioni. Circa 1 su 2 soggetti con IMA presenta, oltre ad un elevato rischio ischemico, un elevato rischio di sanguinamento. La maggioranza dei sanguinamenti si è verificata in ospedale e nei primi mesi di terapia rimanendo sostanzialmente stabile tra i 6 e i 12 mesi di follow-up. Lo score PRECISE-DAPT, oltre ad individuare i pazienti ad elevato rischio di sanguinamento a lungo termine, sembrerebbe essere un valido strumento per predire il rischio di sanguinamenti intra-ospedalieri permettendo di mettere in atto sin da subito strategie di prevenzione.

A442: A CLINICAL CASE OF MULTIPLE MIOCARDIAL INFARCTIONS IN A PATIENT WITH HYPEROMOCYSTEINEMIA AND MTHFR MUTATION

Attilio Lauretti (a), Andrea D'Amato (b), Leda Bernardi (b), Cristina Volponi (b), Maurizio Menichelli (b)
(a) UNIVERSITÀ DEGLI STUDI DI ROMA LA SAPIENZA- OSPEDALE S. ANDREA; (b) PRESIDIO OSPEDALIERO FROSINONE-ALATRI, OSPEDALE FABRIZIO SPAZIANI DI FROSINONE

Introduction. We describe a case of an acute myocardial infarction with elevation of ST-tract (STEMI) in the anterior leads treated by revascularization through invasive coronary angiography and Drug Eluting Stents implantation (DES) in a male patient of 54 years old with four previous acute myocardial infarction. During the hospitalization a genetic mutation of the methylene tetrahydrofolate reductase(MTFHR), previously unknown, was discovered.
Case report. A man of 54 years old, was transported by ambulance to the hospital for typical chest pain in the Precordium. In his medical history were present smoke, arterial hypertension, type two diabetes mellitus, dyslipidaemia, hyperuricemia and multiple events of myocardial acute infarction, with a previous inferior STEMI occurred in 2018, a second anterior STEMI in the same year, an other anterior STEMI few months afterwards with spontaneous thrombosis of the stent previously implanted on left anterior descendent artery; one previous NSTEMI occurred in 2021; 12-lead ECG showed sinus rhythm at 75 bpm, with ST-elevation of 1 mm in V1 and a slight ST-elevation in V2 with inversion of all T waves from V2 to V6 and in lead I, II and avF. Coronary angiography showed thrombotic material at the proximal tract of the stent previously implanted on the left anterior descending artery. The lesion was treated by PTCA + 1 DES. After the PCI the patient was transferred to the ICU. Echocardiographic exams showed parietal hypertrophy with akinesia of apex, anterior wall and inferior-posterior wall, EF of 25% and an apical mural thrombus.
Discussion. In consideration of all the previous acute myocardial infarctions and so of the high ischemic burden of the patient, a thrombophilic screening which included dosage of homocysteine, was per-

formed. The tests showed elevated levels of homocysteine (23 umol/L). A genetic test was performed showing a mutation in homozygosity for SNP C677T of MTHFR. An haematology consultation was carried out, and the consultant recommended to start a therapy with 5 mg of folic acid per day, to prosecute for three months. It is well known as such mutation decreases MTHFR enzyme activity leading to a rise of homocysteine levels in the blood. The most common MTHFR mutation is the MTHFR C677T mutation. To have any harmful effect, mutations must be present in both copies of MTHFR genes. Although these mutations have an effect on the regulation of homocysteine, adequate folate levels essentially cancel this defect. Multiple studies and some meta-analysis showed a strong relationship between hyperhomocysteinemia and the risk of coronary, cerebral, and peripheral atherosclerosis, even though the subsample sizes are limited. The therapy for hyperhomocysteinemia consists of adequate intake of folate, vitamins B6 and B12. It is not still clear if the reduction of blood levels of homocysteine has an impact on the prognosis of the patients in terms of reduction of risk of cardiovascular events; randomized control trials did not demonstrate an effective reduction of cardiovascular risk in patients with Hyperomocysteinemia without homocystinuria, treated with lowering Homocysteine-levels therapies. The VISP-trial, which was a multi-center, double-blind, randomized, controlled clinical trial, with 3680 partecipants enrolled, did not evidence any effect on vascular outcomes during the 2 years of follow-up. With our case-report we want to underline the importance of hyperhomocysteinemia as a strong risk factor for cardiovascular events, in a contest where clear evidences about the effectiveness of the lowering-homocysteinemia therapies on the reduction of cardiovascular risk, are still lacking.

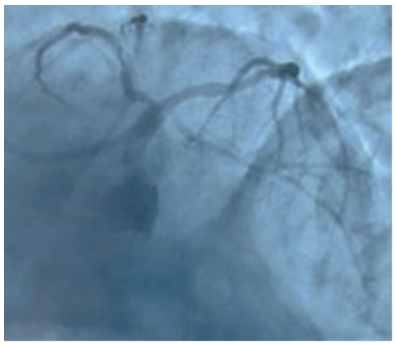

A443: I MILLE VOLTI DEL MICROEMBOLISMO

Laura Lombardi (a), Francesco Bendandi (a), Alessandro Mazzapicchi (a), Francesco Chietera (a), Leonardo Ciurlanti (a), Francesco Palermo (a), Marco Foroni (a), Gabriele Ghetti (a)
(a) IRCCS POLICLINICO SANT'ORSOLA MALPIGHI, ALMA MATER STUDIORUM UNIVERSITÀ DI BOLOGNA

Donna, 89 anni, affetta da cardiopatia ischemica cronica sottoposta a pregresse rivascolarizzazioni percutanee a carico del ramo interventricolare anteriore e del ramo circonflesso e portatrice di bioprotesi valvolare aortica tipo Sapien 3 Ultra 26 mm, in regolare follow-up cardiologico con riferito benessere soggettivo e documentazione strumentale di buon funzionamento della protesi valvolare. Si segnala in anamnesi sindrome linfoproliferativa cronica. Per insorgenza improvvisa di dispnea a riposo e persistenza della sintomatologia, veniva allertato il 118, con riscontro di desaturazione alla valutazione ossimetrica (SpO2 85%) e all'ECG di sopralivellamento del tratto ST-T in AVR e sottolivellamento in sede anteriore; pertanto, veniva condotta in sala emodinamica per coronarografia in emergenza. All'arrivo arresto cardiocircolatorio, per cui iniziate manovre rianimatorie con ripresa della circolazione spontanea con blocco atrioventricolare completo e ritmo di scappamento ventricolare, per cui posizionato pacemaker temporaneo. Eseguita coronarografia con riscontro di occlusione ostiale del tronco comune, trattata con angioplastica percutanea e impianto di stent medicato. All'ecocardiogramma transtoracico successivo evidenza di voluminosa vegetazione endocardica su valvola mitrale determinante insufficienza di grado severo da fissurazione del lembo anteriore e ispessimento paraprotesico su bioprotesi aortica per estensione endocarditica. Durante la degenza veniva, inoltre, evidenziato deficit stenico dell'emisoma destro e afasia, pertanto eseguita TC encefalo che documentava ictus ischemici multifocali su verosimile base embolica. Avviata quindi terapia antibiotica mirata per E. faecalis isolato nelle emocolture. Per rischio chirurgico proibitivo, è stato escluso un eventuale intervento cardiochirurgico. Nonostante la terapia antibiotica mirata, si è assistito ad un peggioramento delle condizioni cliniche generali fino al sopraggiungere della morte a seguito di arresto cardiocircolatorio in corso di PEA e successiva asistolia.
Conclusioni. L'embolia settica è una complicanza frequente e potenzialmente fatale dell'endocardite, caratterizzata da un tasso di incidenza tra il 20 e il 50%. Sebbene il circolo cerebrale e splenico sia usualmente colpito, in rari casi il coinvolgimento del circolo coronarico e conseguentemente l'infarto miocardico acuto con sopraslivellamento del tratto ST (STEMI) può risultare la prima manifestazione dell'endocardite, spesso di difficile diagnosi in fase acuta e gravata ulteriormente da elevata mortalità. La diagnosi, sebbene possa essere sospettata in base alla storia clinica e eventuali caratteristiche angiografiche, risulta esser sempre confermata, a seguito dell'approccio invasivo in fase acuta, dalla diagnostica ecografica.

A444: DAYLIGHT SAVING TIME SHIFTS AND ACUTE MYOCARDIAL INFARCTION: DIFFERENT TEMPORAL AND SEX-SPECIFIC PATTERNS IN ANDALUSIA, SPAIN

Francisco Josè Rodriguez-cortes (a), Jorge Jimenez-hornero (b), Juan Francisco Alcala-diaz (c), Francisco Jose Jimenez-hornero (a), Juan Luis Romero-cabrera (c), Rosaria Cappadona (d), Pablo Jesus Lopez-soto (a), Roberto Manfredini (d)
(a) DEPARTMENT OF NURSING, UNIVERSIDAD DE CORDOBA, SPAIN; (b) DEPARTMENT OF ELECTRICAL ENGINEERING AND AUTOMATIC CONTROL, UNIVERSIDAD DE CORDOBA, SPAIN; (c) DEPARTMENT OF INTERNAL MEDICINE, LIPIDS AND ATHEROSCLEROSIS UNIT, UNIVERSIDAD DE CORDOBA, SPAIN; (d) DEPARTMENT OF MEDICAL SCIENCES, CENTER FOR STUDIES ON GENDER MEDICINE, UNIVERSITY OF FERRARA, ITALY

Background. Transitions into and out of Daylight Saving Time (DST) may disrupt circadian rhythms, lead to sleep disturbance and deprivation, and a series of studies reported an association between DST and acute myocardial infarction (AMI), especially following the spring shift (Janszky et al, 2008; Jiddou et al, 2013). Andalusia is located in the southern part of Spain, a country with a DST change similar to the other European countries. However, Spain is in the Greenwich Mean Time+2 (GMT+2) time zone during summer, although this corresponds to GMT+1 during DST. The aim of this work was to investigate whether transitions both to and from DST led to an increase in the incidence of hospital admissions for major adverse cardiovascular events (MACE).
Methods. This observational study analyzed data from patients admitted to Andalusian public hospitals (years 2009-2019). A total of 157 221 patients were diagnosed with MACE (mean age was 61.7±9.9 years): 71 992 with AMI (59.7% STEMI).
Results. The patients admitted for AMI were predominantly men (77.9%). Observed/expected (O/E) ratios found no differences in the spring shift, but in the autumn shift there were more hospital admissions for AMI (p=0.045) and NSTEMI (p=0.003) for men. As for MACE, the O/E analysis did not show significant differences among DST shifts, but only a slight increase in autumn (1.03; p=NS). The O/E ratio showed an increased risk of AMI (1.06; p=0.044), NSTEMI (1.12; p=0.013), and ACS (1.05; p=0.042) during the autumn DST. As for the day-of-week analysis, different patterns were found for disaggregated subgroups by sex. Men had tended more admissions for AMI on Friday (p=0.05) and Monday (p=0.06) after the autumn shift, and the number of percutaneous interventions (PCI) was also higher on Friday (1.37; p=0.02). On the other hand, women showed significantly lower hospital admission on Friday after the autumn shift (0.68; p=0.01), whereas PCI showed a trend towards a higher incidence on Wednesday (p=0.06). As for NSTEMI, men exhibited a higher number of admissions on Saturday (1.48; p=0.02); followed by Monday and Wednesday (p=0.08).
Conclusions. The main finding of the study is a significant increase of hospital admissions for AMI (especially STEMI) and ACS around the autumn DST transition, with different day-by-week patterns for men and women. This does not agree the majority of previous studies, reporting an increase in hospital admissions for AMI following the spring shift (Manfredini et al, 2019). However, this study is conducted in Andalusia, Southern Spain, a region characterized by warm Mediterranean climate, many sunshine hours per year, and significant discrepancy between solar time and official time, especially in the most western areas. Peculiar geographic area and latitude may explain such differences and, at least to the best of our knowledge, no studies conducted at this same latitude are available. The tendency towards an evening chronotype, with higher nighttime caloric intake, associated with a more sedentary lifestyle could act as potential risk factors (Dashti et al, 2021), and the differences by sex in temporal patterns deserve further investigations as well.

A445: SINDROME DI TAKOTSUBO: QUANDO LA PATOLOGIA CARDIACA DIVENTA DI INTERESSE MULTIDISCIPLINARE

Marco Medda (a), Mattia Marteddu (a), Gabriele Khalil (a), Baldassare Maria Alonzo (a), Mattia Biddau (a), Christian Cadeddu Dessalvi (a)
(a) AZIENDA OSPEDALIERO-UNIVERSITARIA DI CAGLIARI - POLICLINICO DUILIO CASULA

Background. La Sindrome di Takotsubo (TTS), nota anche come Sindrome transitoria da ballooning apicale del ventricolo sinistro, è una patologia caratterizzata da un'acuta disfunzione miocardica reversibile in assenza di coronaropatia ostruttiva. Si manifesta frequentemente in donne nel periodo post-menopausale ed è spesso correlata a stress psico-fisici. È risaputo il ruolo predominante dell'aumento delle catecolamine circolanti nella patogenesi della TTS. Sono state segnalate cause

iatrogene e determinate patologie, come le sindromi endocrinologiche, che possono portare a tale disfunzione. I glucocorticoidi, in particolare, svolgono un ruolo importante nella contrattilità del miocardio, favorendo il trasporto del calcio attraverso il reticolo sarcoplasmatico dei miocardiociti, modulando la risposta vascolare ai beta-agonisti e di conseguenza l'inotropismo cardiaco.
Case report. Donna di 54 anni, affetta da sindrome polighiandolare autoimmune tipo 2, in periodo menopausale e senza altri fattori di rischio cardiovascolare. Nella serata precedente al ricovero avrebbe lamentato malessere generale associato a diffuse e aspecifiche algie toraciche. Per tale motivo sarebbe stato contattato il 118, all'arrivo due episodi di arresto cardiocircolatorio sottoposti a rianimazione cardiopolmonare (RCP) e DC-shock con ripristino del ritmo sinusale (RS), intervallati da tachicardia a QRS largo senza polso. È stato successivamente eseguito elettrocardiogramma con evidenza di diffuso sopraslivellamento del tratto ST per cui è stato eseguita coronarografia urgente con riscontro di coronarie angiograficamente normali. La paziente, dopo l'arrivo in UTIC, ha presentato recidiva di tachicardia ventricolare senza polso con perdita di coscienza per cui è stata sottoposta a ulteriore RCP e DC-shock con ripristino del RS. All'ecocardiografia acinesia medio-apicale diffusa con ipercinesia dei segmenti basali, severa riduzione della funzione ventricolare sistolica (Frazione d'eiezione 32%) e marcata disfunzione diastolica. Agli esami ematochimici evidenza di grave disioniemia (Na 125 mEq/L, K 7.7 mEq/L). È stato inoltre eseguito dosaggio dell'ormone Adrenocorticotropo e del cortisolo che, relazionati agli altri esami ematochimici e alla clinica hanno posto diagnosi di crisi Addisoniana. Durante la degenza è stata incrementata la dose sostitutiva di cortisolo con progressivo miglioramento clinico e normalizzazione della natriemia e kaliemia, rispettivamente 132 mEq/L e 4.8 mEq/L. Alla valutazione ecocardiografica a un mese dall'evento normale funzione sistolica globale, in assenza di alterazioni della cinetica parietale.
Conclusioni. È necessario rendere tutti gli specialisti consapevoli dell'eziologia di questo processo patologico che, seppur raro, deve essere riconosciuto immediatamente e non esitare in temibili complicanze. Nel nostro caso la causa principale può essere riconosciuta nella patologia endocrinologica che ha determinato da una parte un'alterazione della modulazione del calcio nei miociti influenzando la risposta inotropa cardiaca e dall'altra un'alterazione degli ioni potassio correlabile con l'insorgenza dell'aritmia. Il corretto follow-up della patologia di base, in questo caso, avrebbe potuto evitare l'insorgenza della TTS e del quadro aritmico. È necessario sottolineare anche come, a seconda della causa di TTS, sia diverso l'approccio terapeutico da utilizzare e che l'inquadramento repentino sia fondamentale nella risoluzione del quadro e nella completa restitutio ad integrum.

A446: RADIAL ARTERY ACCESS IN PATIENTS WITH ACUTE CORONARY SYNDROME: BEYOND RISK SCORES

Simone Persampieri (a), Martino Baluci (a), Leonardo De Martino (a), Doranna De Pace (a), Irene Ferrari (a), Chiara Anchisi (a), Erica Gondoni (a), Alessandro Lupi (a)
(a) CARDIOLOGIA ASL VCO

Background. Transradial artery access (TRA) is associated with lower bleedings than transfemoral artery access (TFA), especially in patients with acute coronary syndromes (ACS). Conflicting results has been obtained on mortality. We aim to investigate the hemorrhagic and mortality prognostic role of TRA in a mixed population of ACS patients, beyond commonly used risk scores.
Methods. This study is a retrospective analysis of prospectively collected clinical data concerning a population of patients admitted to the Coronary Care Unit (CCU) of ASL VCO (Domodossola and Verbania, Italy) with a diagnosis of ACS. Independent association of TRA with events has been studied by bivariate logistic regression with CRUSADE and HAS-BLED score for bleedings and with GRACE and CHA2DS2-Vasc score for mortality. Bleeding Academic Research Consortium (BARC) grade 2-3 bleedings were considered.
Results. 1001 patients admitted to our institution for ACS composed our population (age 69 [57-78]; 71% male. In 51% of patients the diagnosis was of NSTE-ACS and in 49% of STEMI. Regarding risk factors, 27% had an history of diabetes, 64% had arterial hypertension and 48% had dyslipidaemia. Smoking history was declared by 58% of patients, while previous myocardial infarction was present in 20% of them. Most patients were treated with dual oral antiplatelet therapy, while 25% received glycoprotein IIb/IIIa antagonists. In-hospital mortality (IHM) was 2.2%, post-discharge mortality (PDM) 3.4%. In-hospital bleeding (IHB) rate was 5.1% and post-discharge bleeding (PDB) rate was 3.8%. TRA was associated with IHM independently to CHA2DS2-Vasc (OR 0.39 [0.16-0-93], p=0.03), but not to GRACE score (OR 1 [0.35-2.86], p=1.00). IHB was associated with TRA independently to CRUSADE (0.46 [0.26-0.81], p=0.008) and to HAS-BLED score (OR 0.42 [0.24-0.75], p=0.003). TRA showed an association with PDM independently to GRACE (OR 0.44 [0.20-0.95], p=0.04) and CHA2DS2-Vasc score (OR 0.41 [0.19-0.87], p=0.02). Regarding PDB, only HAS-BLED score was significantly associated at univariate analysis (OR 1.6 [1.14-2.23], p=0.007).
Conclusions. In ACS patients, compared to widely used mortality and bleeding scores, TRA showed independent association with IHM, PDM and IHB reduction. However, the advantages related to bleeding risk reduction are no longer evident during follow-up.

A447: ABILITY OF GRACE, TIMI, HEART AND ACEF SCORES IN PREDICTING LONG-TERM OUTCOMES IN THE SUBSET OF MINOCA

Claudio Asta (a), Damiano Fedele (a), Lisa Canton (a), Francesca Bodega (a), Nicole Suma (a), Francesco Pio Tattilo (a), Andrea Impellizzeri (a), Sara Amicone (a), Ornella Di Iuorio (a), Khrystyna Ryabenko (a), Matteo Armillotta (a), Angelo Sansonetti (a), Andrea Stefanizzi (a), Daniele Cavallo (a), Marcello Casuso (a), Davide Bertolini (a), Andrea Rinaldi (a), Francesco Angeli (a), Luca Bergamaschi (a), Alberto Foà (a), Pasquale Paolisso (a), Carmine Pizzi (a)
(a) POLICLINICO SANT'ORSOLA

Background. Long-term outcomes in patients affected by myocardial infarction with non-obstructive coronary arteries (MINOCA) are not necessarily benign. Several clinical risk-scoring tools have been developed and validated in large cohorts of patients with acute myocardial infarction (AMI) to predict prognosis. Nevertheless, their performance in the specific subset of MINOCA has been poorly evaluated.
Aims. To test and compare the performance of GRACE, TIMI, HEART, and ACEF scores in predicting long-term outcomes in MINOCA patients.
Methods. We selected patients admitted for AMI and subsequently diagnosed with MINOCA. We further excluded patients with myocarditis, Takotsubo syndrome, cardiomyopathies, and other non-ischaemic causes of acute myocardial injury. GRACE, TIMI, HEART, and ACEF scores at admission were retrospectively computed. The ability of each score to predict a composite endpoint of all-cause death or acute myocardial infarction after 1 year of follow-up was evaluated and compared through the area under the curve (AUC) of the receiver operating characteristic curves. Youden index was applied to select the best cut-offs to identify high-risk patients.
Results. 250 patients affected with true MINOCA were included. Mean GRACE, TIMI, HEART, and ACEF scores were 128, 2, 7, and 1.11, respectively. After 1 year of follow-up, 11 patients (4.4%) died and 8 (3.2%) presented a recurrence of AMI. In the prediction of the composite endpoint GRACE, TIMI, HEART, and ACEF scores were sub-optimal, showing AUCs of 0.78, 0.71, 0.66, and 0.68, respectively. No significant differences were registered among the four scores. However, the GRACE score resulted optimal in predicting all-cause death at 1-year follow-up with an AUC=0.93, which was significantly higher when compared to the AUC of TIMI (p<.001) and HEART score (p<.003), with no difference with the AUC of the ACEF score (p.061). Finally, in our cohort, the best cut-off of GRACE score was 171, higher when compared with the cut-off of 140 applied in obstructive AMI. The application of this cut-off allowed the identification of patients who experienced the composite endpoint at 1-year follow-up with a sensitivity=68%, a specificity=89%, a positive predictive value=34%, and a negative predictive value=97%.
Conclusions. Existing prognostic scoring systems can be applied to identify MINOCA patients with a higher risk of death or recurrent AMI at long-term follow-up. In particular, the GRACE score seems to be the best choice, being significantly superior to TIMI and HEART scores in predicting 1-year mortality. Nevertheless, the performance of these scores in MINOCA was sub-optimal. New risk assessment models, specifically developed for MINOCA patients and possibly including more sophisticated imaging techniques, are needed.



A448: SEX- AND AGE-RELATED DIFFERENCES IN OUTCOMES OF PATIENTS WITH ACUTE MYOCARDIAL INFARCTION: MINOCA VS. MIOCA

Khrystyna Ryabenko (a, b), Damiano Fedele (a, b), Lisa Canton (a, b), Ornella Di Iuorio (a, b), Daniele Cavallo (a, b), Virginia Marinelli (a, b), Claudio Asta (a, b), Francesco Pio Tattilo (a, b), Nicole Suma (a, b), Sara Amicone (a, b), Andrea Impellizzeri (a, b), Matteo Armillotta (a, b), Andrea Stefanizzi (a, b), Angelo Sansonetti (a, b), Carmine Pizzi (a, b)
(a) IRCCS - AZIENDA OSPEDALIERO-UNIVERSITARIA SANT'ORSOLA-MALPIGHI; (b) DIMEC

Purpose. To evaluate the impact of age and sex on clinical presentation and outcomes of patients with acute myocardial infarction (AMI), com-

paring those with non-obstructive and obstructive coronary arteries (MINOCA vs MIOCA).
Methods. We enrolled 2455 patients with AMI undergoing coronary angiography from January 2017 to September 2021. Patients were divided according to the type of AMI and sex: male (n=1593) and female (n=607) in MIOCA; male (n=87) and female (n=168) in MINOCA. Each cohort was further stratified based on age (≤/>70 years). The primary endpoint, namely major adverse events (MAE), was a composite of all-cause death, recurrent AMI, and hospitalization for heart failure (HF) at follow-up.
Results. The median follow-up was 28 [15-41] months. In the MINOCA cohort, female patients were significantly older compared to males, had more frequently dyslipidemia, presented a higher GRACE score (p<0.001 for all), and those ≤70 years had higher prevalence of SCAD (p=0.030). In the MIOCA group, female patients were older, with a higher prevalence of arterial hypertension and chronic kidney disease (p<0.001 for all). Male patients were more often smokers, with higher BMI, and presented more frequently with STEMI and typical angina at admission, while females had a higher Killip class and GRACE score (p<0.010 for all). The rate of MAE was higher in females than in males in both groups (MINOCA [26.8% vs 13.8%; p=0.018]; MIOCA [33.4% vs. 26.9%; p=0.002]). However, when corrected for age, sex did not result as independently predictive of bad outcomes. When stratified by age, among MINOCA patients, females ≤70-year-old had a higher incidence of MAE [18 (23.7%) vs 4 (5.9%); p=0.003] regard to male peers, mainly driven by higher prevalence of re-hospitalization for HF (p=0.045) and recurrence of AMI (p=0.006). Only in this sub-group of MINOCA patients, female sex was an independent predictor of MAE (HR=3.09; 95%CI: 1.02-9.59; p=0.040). Furthermore, females ≤70-year-old affected with MINOCA had worse outcomes even when compared to their MIOCA peers. Finally, secondary prevention medical therapy was less prescribed in females with MINOCA compared to MIOCA.
Conclusions. MINOCA females ≤70-year-old had a significantly higher incidence of MAE, compared to males and MIOCA female peers. This might be due to the different pathophysiology of the ischemic event, with subsequently unfitting secondary prevention medical therapy prescription.

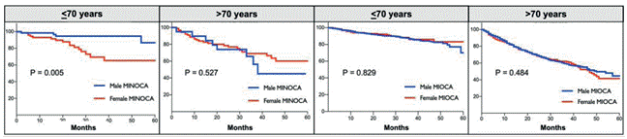

A449: PERIPROCEDURAL MYOCARDIAL INFARCTION AND INJURY IN NSTEMI PATIENTS

Matteo Armillotta (a), Luca Bergamaschi (a), Angelo Sansonetti (a), Andrea Stefanizzi (a), Francesco Angeli (a), Sara Amicone (a), Francesca Bodega (a), Nicole Suma (a), Lisa Canton (a), Andrea Impellizzeri (a), Davide Bertolini (a), Francesco Pio Tattilo (a), Daniele Cavallo (a), Damiano Fedele (a), Khrystyna Ryabenko (a), Ornella Di Iuorio (a), Marcello Casuso (a), Virginia Marinelli (a), Claudio Asta (a), Andrea Rinaldi (a), Pasquale Paolisso (a), Gianni Casella (b), Alberto Foà (a), Carmine Pizzi (a)
(a) UNIVERSITY HOSPITAL POLICLINIC S. ORSOLA-MALPIGHI, CARDIOLOGY, DEPARTMENT OF MEDICAL AND SURGICAL SCIENCES, BOLOGNA, ITALY; (b) MAGGIORE HOSPITAL, CARDIOLOGY DEPARTMENT, BOLOGNA, ITALY

Background. Non-ST-elevation myocardial infarction (NSTEMI) is a common cardiac condition that contributes to a substantial portion of hospital admissions and cardiovascular morbidity and mortality worldwide. Percutaneous coronary intervention (PCI) has demonstrated a significant positive impact on outcomes in patients with NSTEMI. However, periprocedural myocardial infarction (PMI) and myocardial injury remain relatively common in PCI procedures, even though the negative prognostic role of periprocedural events is only well established in patients undergoing PCI for chronic coronary syndrome with normal baseline cardiac troponin (cTn) levels. Indeed, the incidence and prognostic role of additional post-PCI cTn elevations in patients with acute coronary syndrome who have elevated cTn levels at baseline (pre-PCI) is still unknown.
Purpose. To investigate the incidence and prognostic impact of PMI and myocardial injury in NSTEMI patients undergoing PCI.
Methods. We prospectively evaluated all patients admitted to our coronary care unit from 2017 to 2022 affected by NSTEMI who underwent PCI. We only enrolled patients with stable (≤20% variation) or falling pre-procedure baseline cTn values. According to the Fourth Universal Definition of Myocardial Infarction (4th UDMI), we divided the entire population into three distinct subgroups: 1) type 4a MI; 2) procedural myocardial injury; and 3) no procedural ischemic complications. All the subsequent analyses were performed accordingly. The primary endpoint was all-cause mortality at 1-year. The secondary endpoint was a composite of major adverse cardiovascular events (MACE) at 1-year, including all-cause mortality, non-fatal reinfarction, urgent revascularization, non-fatal ischemic stroke and hospitalization for heart failure (HF). Patients who could not be followed up for at least 1-year were excluded from the analysis.
Results. The final cohort included 1412 patients: 1) type 4a MI was identified in 240 patients (17.0%); 2) procedural myocardial injury was recognized in 288 patients (20.4%); 3) and the remaining 884 patients (62.6%) did not experience any procedural ischemic complications. For both the endpoints, Kaplan-Meier curves clearly showed a more unfavorable trend for patients with PMI (p<0.001). However, there were no statistically significant differences between the other two groups (p=0.08 for all-cause mortality and p=0.121 for MACE). Multivariable Cox regression mode showed a robust association between PMI and 1-year mortality [HR: 3.47 (95% CI: 2.17-5.55); p<0.001]. In contrast, procedural myocardial injury defined by the 4th UDMI (post-PCI cTn elevation>20% compared to baseline) was not associated with 1-year mortality [HR: 1.63 (95% CI: 0.92-2.88); p=0.097].
Conclusions. Among NSTEMI patients undergoing PCI and with stable pre-procedure cTn levels, PMI is significantly correlated with 1-year mortality and MACE. On the other hand, the 4th UDMI definition of procedural myocardial injury did not show any significant impact on the 1-year prognosis in our population.

A450: PREDICTORS OF PERIPROCEDURAL MYOCARDIAL INFARCTION FOLLOWING PERCUTANEOUS CORONARY INTERVENCTION IN NSTEMI

Marcello Casuso Alvarez (a), Matteo Armillotta (a), Luca Bergamaschi (a), Angelo Sansonetti (a), Andrea Stefanizzi (a), Francesco Angeli (a), Sara Amicone (a), Francesca Bodega (a), Nicole Suma (a), Lisa Canton (a), Andrea Impellizzeri (a), Davide Bertolini (a), Francesco Pio Tattilo (a), Daniele Cavallo (a), Damiano Fedele (a), Khrystyna Ryabenko (a), Ornella Di Iuorio (a), Virginia Marinelli (a), Claudio Asta (a), Andrea Rinaldi (a), Pasquale Paolisso (a), Gianni Casella (b), Alberto Foà (a), Carmine Pizzi (a)
(a) UNIVERSITY HOSPITAL POLICLINIC S.ORSOLA-MALPIGHI, CARDIOLOGY, DEPARTMENT OF MEDICAL AND SURGICAL SCIENCES, BOLOGNA, ITALY; (b) MAGGIORE HOSPITAL, CARDIOLOGY DEPARTMENT, BOLOGNA, ITALY

Background. Percutaneous coronary intervention (PCI) has demonstrated benefit in patients with Non-ST-elevation myocardial infarction (NSTEMI), even though periprocedural myocardial infarction (PMI) remains relatively common in PCI procedures. However, while risk factors of periprocedural events are well established in patients undergoing PCI for chronic coronary syndrome with normal baseline cardiac troponin (cTn) levels, evidence on predictors of additional post-PCI myocardial infarction in patients with NSTEMI is missing.
Purpose. To investigate the predictors of PMI in patients affected by NSTEMI undergoing PCI.
Methods. We prospectively evaluated all NSTEMI patients admitted to our coronary care unit from 2017 to 2022 who underwent PCI. NSTEMI patients were managed according to the current European guidelines criteria. The diagnosis of PMI (type 4a myocardial infarction) was based on the Fourth Universal Definition of Myocardial Infarction. We only enrolled patients with stable (≤20% variation) or falling pre-procedure baseline cTn values. A multivariable logistic regression analysis was performed to investigate the factors independently associated with the occurrence of PMI after PCI. For the analysis, we selected the main known predictors of PMI after elective PCI, specifically age, serum creatinine, multivessel disease, coronary bifurcation PCI, left main or proximal left anterior descending PCI, multivessel PCI and stent length ≥60 mm. In addiction, we evaluated the potential predictive role of a GRACE score>140.
Results. The final court of the study included 1412 patients. PMI was recognized in 240 patients (17.0%). Although patients who developed PMI showed a worse risk profile, as documented by a higher mean age, a higher complexity of atherosclerotic disease, and thus a significant technical difficulty of PCI compared to other patients, at the multivariable logistic regression only age [OR: 1.02 (95% CI: 1.01-1.04); p=0.006], coronary bifurcation PCI [OR: 3.71 (95% CI: 2.70-5.10); p<0.001], and stent length ≥60 mm [OR: 1.87 (95% CI: 1.30-2.68); p=0.001] were independent predictors of PMI. Interestingly, left main or proximal PCI [OR: 0.92 (95% CI: 0.66-1.26); p=0.596] and multivessel PCI [OR: 1.17 (95% CI: 0.80-1.70); p=0.415] were not independently associated with an increased risk of type 4a myocardial infarction.
Conclusions. Among NSTEMI patients undergoing PCI, age and two PCI complexity features, namely coronary bifurcation PCI and stent length ≥60 mm, represent independent predictive factors of PMI. This finding may have important clinical implications for clinical practice, providing valuable insights for the identification of higher-risk NSTEMI patients undergoing PCI, which could lead to a more accurate management.

A451: STEMI O NON STEMI? QUESTO È IL DILEMMA

Davide Rossi (a), Claudio Scollo (a), Mario Di Marino (a), Fabrizio Ricci (a), Sabina Gallina (a), Giulia Renda (a)
(a) UNIVERSITÀ DEGLI STUDI G. D'ANNUNZIO CHIETI-PESCARA

Uomo di 65 anni con storia di ipertensione arteriosa, tabagismo attivo, arteriopatia obliterante cronica degli arti inferiori. Trasportato in PS dal 118 per dolore toracico oppressivo, con irradiazione interscapolare. All'EO: non segni di scompenso cardiaco. NIBP 150/95 mmHg, FC 91

bpm, satO2 95% in aria ambiente, apiretico. All'ECG: Ritmo sinusale con 91 bpm; minimo sopraslivellamento isolato del tratto ST in DIII, sottoslivellamento marcato del tratto ST da V4 a V6 con onda T difasica e minimo sopraslivellamento ST maggiore in V1 rispetto a V2. Tale aspetto elettrocardiografico viene definito "pattern di Aslanger" e nonostante non soddisfi i criteri per STEMI, rappresenta un'interruzione del flusso coronarico con danno miocardico a valle, essendo un infarto miocardico occlusivo o "Occlusive Myocardial Infarction" (OMI). Agli esami di laboratorio: curva significativa delle troponine ad alta sensibilità (picco 6000 pg/ml); l'ecocardiogramma mostrava una cinetica globale del Vsn ai limiti inferiori (FE 52%) in relazione ad acinesia dell'apice settale ed inferiore. È stato eseguito prontamente l'esame coronarografico con riscontro di malattia coronarica trivasale: CTO di CDx non dominante, stenosi subocclusiva della biforcazione IVA media e D1, stenosi critica di IVP del Cx. Il caso è stato discusso collegialmente optando per PCI-DES su biforcazione IVA-D1 e IVP. Questo caso può essere definito come STEMI – e OMI + e necessità di rivascolarizzazione precoce, potendo migliorare così prognosi e morbilità, salvando dalla necrosi ampie zone di miocardio. Il pattern di Aslanger è caratterizzato da: sopraslivellamento del tratto ST in DIII; sottoslivellamento del tratto ST in una qualsiasi delle derivazioni da V4 a V6 con onda T difasica e componente terminale positiva; tratto ST in V1 di ampiezza maggiore rispetto a V2; può esserci anche sopraslivellamento del tratto ST in aVR. Il pattern si deve alla comparsa di due vettori legati all'ischemia: uno diretto verso la parete inferiore e quindi verso le derivazioni inferiori (in particolare verso DIII) e un altro legato ad ischemia subendocardica diffusa, secondaria ad una estesa coronaropatia e quindi diretto verso aVR. Il vettore risultante è diretto verso i 180 gradi e questo spiega come mai compaiono tali alterazioni tipiche.

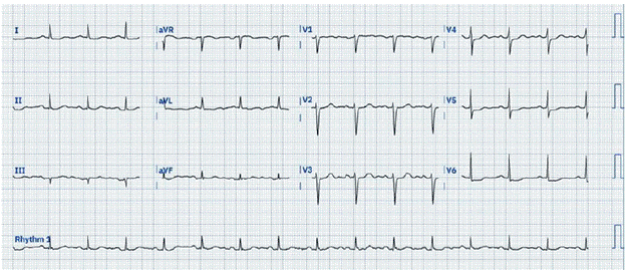

A452: BEYOND CORONARY ARTERY CALCIUM SCORE: EPICARDIAL FAT VOLUME IN CARDIOVASCULAR RISK STRATIFICATION

Antonella Sabatini (a, b, c), Olena Mahneva (c), Mahfouz El Shahawy (c)
(a) AOUI VERONA UNIV. HOSPITAL - CARDIOLOGY; (b) BOZEN/BOLZANO REGIONAL HOSPITAL - CARDIOLOGY; (c) CARDIOVASCULAR CENTER OF SARASOTA, SARASOTA, FLORIDA, USA

Background. Elevated Coronary Artery Calcium Score (CACS) and Epicardial Fat Volume (EFV) have been reported as risk factors for cardiovascular disease (CVD) and are used in CVD risk assessment.

Purpose. To investigate whether asymptomatic subjects with significantly elevated CACS but normal EFV have significant obstructive coronary artery disease (CAD).

Methods. We screened 2932 subjects, 18 years +, for CVD risk assessment using the Early Cardiovascular Disease Risk Scoring System (ESCVDRS), also known as Rasmussen Risk Score (RRS), previously reported. The ESCVDRS includes 7 vascular and 3 cardiac tests. Out of the 2932 subjects, 334 underwent cardiac CT for EFV and CACS determination using Siemens Somatom Definition Dual source CT scanner 64x2. Out of these, 25 subjects (11M/14F) with significantly elevated CACS and normal EFV were further assessed regarding their exercise level, structural and functional abnormalities, presence of significant obstructive CAD and/or ischemic changes as determined by stress test, CT angiogram and cardiac cath.

Results. As shown in the tables below:

Elevated CACS in the presence of normal EFV was not associated with significant obstructive CAD nor with significant structural and functional abnormalities.

In the female group, it was previously shown that post-menopausal subjects were associated with excessive EFV tend to be symptomatic for chest pain due to potentially underlying microvasculature damage. In our study, the female group with slightly elevated LDL compared to male group and normal EFV are not associated with significantly elevated biomarkers.

Normal EFV was not associated with significantly elevated biomarkers in the male group.

High exercise level was associated with normal EFV and no evidence of significantly elevated risk factors of CVD.

Conclusions. Exercise is your best pill for modulating EFV and other CVD enhancing risk factors. High levels of exercise are associated with normal EFV leading to reduced cytokine expression, minimizing endothelial dysfunction and endovascular calcification. Elevated CAC may be localized perivascularly rather than intravascularly, diminishing intracoronary obstruction. Accordingly, high levels of exercise, med. therapy (i.e. Semaglutide) is recommended. Early detect to protect!

Table 1: Demographics and average cardiovascular disease (CVD) risk scores.

	Male (n = 11)	Female (n = 14)	P-Value
Epicardial Fat Volume (EFV)	77	72	0.71
Coronary Artery Calcium Score (CACS)	1403	532	0.20
Age	77	72	0.78
Evidence of Obstructive CAD	None	None	-
Cardiovascular Health Assessment Score (ESCVDRS)	6.09	8.25	0.34

Table 2: Biomarkers

	Male (n = 11)	Females (n = 14)	P-Value
Micro-albuminuria (mg/mmol)	0.21	0.16	0.73
Pro-BNP (pg/mL)	96.64	40.25	0.35
CRP (mg/dL)	0.2	0.3	0.34

Table 3: Modifiable Risk Factors

	Male (n = 11)	Females (n = 14)	P-Value
Fasting Blood Glucose (mg/dL)	95	88	0.20
Sitting Blood Pressure (mmHg)	120/75	123/77	0.49
Abnormal Rising Blood Pressure post-protocol Exercise (mmHg)	29	24	-
Total Cholesterol (mg/dL)	150	199	0.05
HDL (mg/dL)	56	65	0.41
Non-HDL (mg/dL)	94	134	0.09
LDL (mg/dL)	75	118	0.04
Triglycerides (mg/dL)	97	82	0.32
BMI	27.16	22.66	0.03
Waist Circumference (cm)	34.48	36.13	0.32
Exercise level	Very Active	Very Active	-

A453: LONG-TERM FOLLOW-UP ON SPONTANEOUS CORONARY ARTERY DISSECTION: PREDICTORS OF CARDIOVASCULAR RE-HOSPITALIZATION AND MORTALITY

Francesco Flore (a), Chiara Simonini (a), Veronica Carmina (a), Chiara Napolitano (a), Gaetano Pinnacchio (b), Gianluigi Bencardino (b), Francesco Perna (b), Rocco Antonio Montone (b), Maria Lucia Narducci (b), Gemma Pelargonio (a, b), Gaetano Antonio Lanza (a, b), Filippo Crea (a, b)
(a) DIPARTIMENTO DI SCIENZE CARDIOVASCOLARI, UNIVERSITÀ CATTOLICA DEL SACRO CUORE, ROMA; (b) DIPARTIMENTO DI SCIENZE CARDIOVASCOLARI, FONDAZIONE POLICLINICO UNIVERSITARIO AGOSTINO GEMELLI IRCCS, ROMA

Background. Spontaneous coronary artery dissection (SCAD) is an emerging cause of acute coronary syndrome (ACS), disproportionately affecting women. In recent years research focused on clinical outcomes and the most appropriate therapeutic approach to improve them. A relevant role seems to be played by SCAD recurrence. However, there is still debate on these matters and prospective randomized trials are lacking. Our study aims to investigate the number of cardiovascular events in SCAD patients and whether there are potential predictors of these events.

Methods. Our single-center prospective observational study enrolled 76 patients affected by SCAD. Follow-up of patients was conducted by monitoring the electronic database of our Institution and by telephone contact with patients. Hospitalization and death due to cardiovascular (CV) causes were the composite endpoint of our study.

Results. Seventy-six consecutive patients with a diagnosis of SCAD were characterized by clinical presentation, underlying risk factors and triggers for SCAD. In thirthy-five patients (46.1%) a second coronary angiography was performed during the index hospitalization to determine whether the dissection spontaneously healed. In the end, roughly half of our patients were treated with medical therapy only. During follow-up, the primary endpoint of our study occurred in thirthy-six patients (47.3%) and its only independent predictor was coronary revascularization (HR 1.92, 95% CI 1.13 – 3.21, p=0.015).

Conclusions. SCAD, usually considered a rare and relatively benign cause of ACS, is actually a clinically insidious condition and it is linked to high rates of re-hospitalization and death from CV events.

A454: INFARTO MIOCARDICO ACUTO IN PAZIENTE CON ANEURISMA GIGANTE DELLA CORONARIA DESTRA: PRESENTAZIONE CLINICA E MANAGEMENT

Elisa Venturoli (a), Veronica Moriconi (b), Francesco Contorni (b), Andrea Gardi (b), Camilla Matese (a), Federica Frascaro (a), Marco Zuin (a), Paolo Cimaglia (a), Filippo Ottani (b)
(a) U.O. CARDIOLOGIA, AZIENDA OSPEDALIERO-UNIVERSITARIA DI FERRARA, CONA (FE); (b) U.O. CARDIOLOGIA, OSPEDALE INFERMI, RIMINI

Introduzione. Gli aneurismi delle arterie coronariche, definiti come una dilatazione di un segmento coronarico di oltre una volta e mezzo il diametro del segmento adiacente, rappresentano un'entità clinica relativamente rara, con una prevalenza nella popolazione generale compresa tra lo 0.9 ed il 4.9%. Gli aneurismi giganti, caratterizzati da un aumento di quattro volte del diametro di riferimento, hanno una prevalenza ancora minore, stimata attorno allo 0.02%. Data la rarità di tale condizione e l'assenza di specifiche linee guida, il loro management rimane complesso.

Caso clinico. Un uomo di 73 anni, con storia di ipertensione arteriosa sistemica, dislipidemia, fibrillazione atriale permanente e steno-insufficienza valvolare aortica moderata, si presentava in Pronto Soccorso per dolore retrosternale oppressivo perdurante da circa un'ora. Il primo ECG mostrava un sopraslivellamento del tratto ST nelle derivazioni inferiori

con specularità in DI e aVL, con seguente regressione del dolore e del sopraslivellamento dell'ST ai tracciati successivi; all'ecocardiogramma non si evidenziavano anomalie di cinetica segmentaria e la funzione ventricolare sinistra risultava conservata; concomitava un significativo movimento dei marker di miocardiocitonecrosi, per cui il paziente veniva ricoverato con diagnosi di infarto miocardico acuto con sopraslivellamento transitorio del tratto ST in sede inferiore. Lo studio coronarografico documentava un aneurisma gigante al tratto prossimale della coronaria destra, del diametro massimo di 40 mm, con flusso turbolento a livello della dilatazione ed opacizzazione del tratto a valle marcatamente rallentata (TIMI 1), con plausibile stenosi critica a valle dell'aneurisma (Figura A). I restanti rami coronarici erano esenti da lesioni angiograficamente significative. Dopo discussione in Heart Team, il paziente veniva quindi sottoposto ad intervento cardiochirurgico di bypass aortocoronarico con vena safena per coronaria destra al tratto medio ed esclusione dell'aneurisma coronarico destro mediante legatura pre- e post-aneurisma (Figura B). Come controllo post-operatorio è stata eseguita una angioTC coronarica, che ha mostrato buon esito del bypass ed efficace esclusione dell'aneurisma coronarico (Figura C). A un mese dall'evento acuto il paziente era in buone condizioni cliniche, asintomatico.

Discussione. Il caso presentato evidenzia come l'intervento cardiochirurgico con legatura dell'aneurisma e bypass aortocoronarico rappresenti una possibile strategia terapeutica nei pazienti con aneurismi coronarici giganti nell'ambito di una sindrome coronarica acuta.

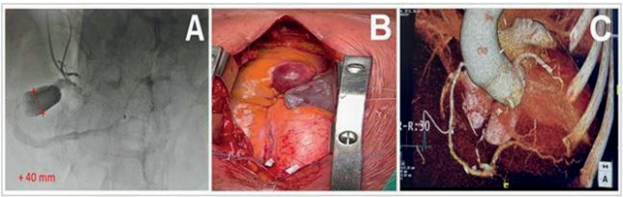

A455: CHARACTERISTICS AND OUTCOME OF PATIENTS WITH VARIOUS TYPE OF ACUTE CORONARY SYNDROME

Alessandra Lucia Fluca (a, f), Laura Munaretto (a, f), Beatrice Pani (f), Vincenzo Chiaradia (f), Agnese Derin (a), Laura Padoan (c, d), Enzo Merro (a, f), Cristina Hiche (a), Alessandro Pierri (b), Stefano D´errico (f), Milijana Janjusevic (a), Andrea Di Lenarda (e), Gianfranco Sinagra (a, f), Aneta Aleksova (a, f)
(a) AZIENDA SANITARIA UNIVERSITARIA GIULIANO ISONTINA, CARDIOTHORACOVASCULAR DEPARTMENT, TRIESTE, ITALY; (b) CARDIOLOGY DEPARTMENT AND INTENSIVE CORONARY CARE UTIC, PERRINO HOSPITAL, BRINDISI, ITALY; (c) UNIVERSITY OF PERUGIA AND CARDIOVASCULAR PATHOPHYSIOLOGY, PERUGIA, ITALY; (d) AZIENDA SANITARIA UNIVERSITARIA GIULIANO ISONTINA, CARDIOLOGY DEPARTMENT GORIZIA-MONFALCONE, GORIZIA, ITALY; (e) AZIENDA PER L'ASSISTENZA SANITARIA N.1, OSPEDALE MAGGIORE, CENTRO CARDIOVASCOLARE, TRIESTE, ITALY; (f) UNIVERSITÀ DEGLI STUDI DI TRIESTE, TRIESTE, ITALY

Background. Myocardial Infarction with Nonobstructive Coronary Arteries (MINOCA), type 1 myocardial infarction (MI), type 2 MI and Takotsubo syndrome (TTS), are distinct entities according to the underlying pathophysiological mechanisms.

Aims. We aimed to compare the clinical characteristics of these four groups and explore the prognostic impact of those features on major cardiovascular events.

Methods. In this single-centre retrospective observational study, data on 18223 patients who underwent invasive coronary angiography between 2005 and 2022 were extracted from a clinical database. Overall, 1162 patients were included, of whom 301 had MINOCA, 237 had type 2 MI, 138 had TTS and 486 had type 1 MI. The primary endpoint was defined as a composite of non-fatal AMI, non-fatal transient ischemic attack (TIA) or stroke, hospitalization for heart failure (HF) and death. The secondary endpoints were defined as (1) hospitalization for HF, (2) a composite event of atrial fibrillation (AF), TIA and/or stroke, and (3) all-cause mortality.

Results. The mean age of the enrolled population was 68.2 ± 11.01 years and 47% were male. The TTS population was more likely hypotensive and exhibited a lower incidence of obesity and diabetes mellitus (DM). Atypical risk factors such as post-menopause were more frequent in patients with TTS and MINOCA. The TTS group had a worse echocardiographic presentation on admission, but the systolic function normalized on discharge. Patients with type 2 MI were more likely to have hypertension and had a similar incidence of DM and diastolic dysfunction as type 1 MI. However, patients with type 2 MI received less frequent DAPT, nitrates, beta-blockers and statins upon discharge compared to type 1 MI. The MINOCA group received a similar therapy as type 1 MI, while TTS were less treated. During a median follow-up of 62 [30 – 102] months, in total 358 patients reached the primary endpoint. Considering the secondary endpoints, 84 patients were hospitalized for HF, 76 patients had AF/TIA/stroke and 253 patients died. In the Kaplan-Meier analysis, patients with type 1 MI were more likely to experience the primary endpoint, similar to type 2 MI, while the TTS and MINOCA groups had a better and comparable pattern (p<0.01). A similar trend was observed for the secondary endpoint for death (p<0.01), while patients with type 2 had the highest probability of developing AF/TIA/stroke (p<0.01). Regarding hospitalization for HF, groups with non-obstructive coronary arteries had a better outcome than patients with type 1 MI (p<0.01). After adjustment for male gender (HR: 1.48, p=0.02), older age (HR: 1.19, p<0.01), DM (HR: 1.53, p=0.01), anemia (HR: 1.87, p<0.01), reduced systolic function (HR: 1.13, p<0.01) and high C-reactive protein (HR: 1.04, p=0.02), left bundle branch block (HR: 1.84, p=0.01) and statins on discharge (HR: 0.7, p=0.05) the type 1 MI was a predictor of worse outcome compared to type 2 MI (HR: 5.8, p<0.01), MINOCA (HR: 3.1, p<0.01) and TTS (HR: 2.64, p<0.01).

Conclusions. Patients with type 1 MI have a worse prognosis compared to those with type 2 MI, MINOCA and TTS. Despite TTS patients had the worst clinical presentation on admission and, compared to the other groups being less treated upon discharge, had the best outcome. Type 2 MI was very close to type 1 MI in terms of clinical characteristics and events, but not for therapy on discharge.

A456: PERIOPERATIVE TAKOTSUBO SYNDROME: A SYSTEMATIC REVIEW

Vincenzo Castiglione (a, b), Francesco Gentile (a, b, c), Francesco Negro (c), Carlo Vitale (c), Mattia Alberti (c), Giovanni Mondello (c), Angelica Lossi (c), Eliana Carapellucci (c), Carlo Palombo (c), Raffaele De Caterina (c), Doralisa Morrone (c)
(a) HEALTH SCIENCE INTERDISCIPLINARY CENTER, SCUOLA SUPERIORE SANT'ANNA, PISA, ITALY; (b) FONDAZIONE TOSCANA GABRIELE MONASTERIO, PISA, ITALY; (c) CARDIOLOGY DIVISION, PISA UNIVERSITY HOSPITAL, PISA, ITALY

Background. Takotsubo syndrome (TTS) is characterized by transient ventricular dysfunction in the absence of obstructive coronary artery disease that may be triggered by intense physical or emotional stress. Surgery and invasive procedures are important causes of psychological and/or physical stress, and have been associated with cases of perioperative TTS (pTTS).

Purpose. We describe demographic and clinical characteristics, correlates and outcomes of patients with pTTS in a systematic review of reported cases.

Methods. We performed a systematic literature search in PubMed from January 1975 to May 2022. We selected 971 articles of which 252 were case reports and 8 were case series, describing 292 cases of pTTS. After excluding patients not meeting both the 2008 Mayo Clinic and 2018 European Society of Cardiology diagnostic criteria for TTS, we selected a final cohort of 186 pTTS patients.

Results. Patients' mean age was 58 ± 18 years and 148 (87%) were women. Only 22 (12%) patients had a history of intense emotional or physical stress before the invasive procedure. Most patients underwent general anaesthesia (n=97, 52%), and pTTS development was documented intraoperatively in 70 (38%) cases. Cardiothoracic surgery and cardiovascular interventions (n=51, 27%) were the most common invasive procedures associated with pTTS, followed by abdominal surgery (n=45, 24%), and caesarean delivery (n=16, 9%). Most patients (n=143, 77%) developed the "classical" TTS subtype, whereas 18 (10%) had the basal/inverted subtype and 22 (12%) the midventricular or focal subtype. Left ventricular (LV) median ejection fraction at first assessment was 32% (25-40), and mechanical circulatory support was required in 34 (18%) cases. Six (3%) deaths occurred during hospitalization. Among patients with available follow-up, 156 (84%) completely recovered LV systolic function within a median time of 14 (7-30) days.

Conclusions. pTTS is a clinically relevant complication of surgery and invasive procedures, most commonly occurring during or immediately after a cardiovascular, thoracic, or abdominal intervention. Similar to non-perioperative TTS, pTTS usually affects women, but with no apparent association with prior physical or emotional stressors, suggesting that surgery and invasive procedures could themselves be triggers of TTS in certain individuals. pTTS presentation is burdened with severe LV systolic dysfunction, with a significant proportion of patients requiring mechanical assistance, but those who survive the acute phase usually fully recover cardiac function.

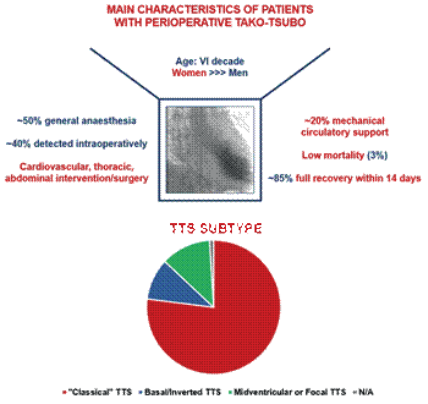

A457: HAIR CORTISOL AND INFLAMMATORY INDEXES IN ACUTE CORONARY SYNDROME: PRELIMINARY DATA OF THE STRESS-ACS ACTION STUDY

Andrea Denegri (a), Francesca Rossi (b), Giulia Magnani (a), Filippo Luca Gurgoglione (a), Domenico Tuttolomondo (a), Manjola Noni (a), Federico Barocelli (a), Elia Indrigo (b), Chiara Maccari (b), Paolo Ossola (b), Carlo Marchesi (b), Massimo Corradi (b), Roberta Andreoli (b), Diego Ardissino (b), Giampaolo Niccoli (b)

(a) AZIENDA OSPEDALIERO-UNIVERSITARIA DI PARMA; (b) UNIVERSITÀ DEGLI STUDI DI PARMA

Background. Secondary prevention in acute coronary syndromes (ACS) was mainly focused on traditional cardiovascular (CV) risk factors control; however emerging evidence highlighted chronic psychosocial stress (PSS) as a new potential CV risk factor. The aim of the present study was to investigate the potential association of PSS, expressed by hair cortisol (HC) levels and inflammation in a real-world cohort of ACS-patients.
Methods. Among patients enrolled in the STRESS-ACS-ACTION study, those presenting with ST- or non-ST-elevation myocardial infarction (STEMI or NSTEMI) were considered for the present analysis. Hair samples to assess HC were processed and analyzed by a centralized laboratory. A regression analysis was performed to describe the relationships between significant variables at univariate analysis.
Results. Out of 60 patients, 39 (65%) were diagnosed with STEMI; these subjects did not differ for baseline characteristics compared to NSTEMI patients except for cardiac biomarkers and LVEF ($p<0.05$). Neutrophils (N), lymphocytes (L), neutrophil to lymphocyte ratio (NLR) and systemic immune inflammatory index (SII), were all significantly higher in STEMI patients ($p<0.05$) while total white blood cell count (WBC 11.0±3.6 vs 9.8±3.3 x10^3/mmc, p=0.191) and CRP (37.1±41.2 vs 20.2±29.6 mg/l, p=0.180) were only numerical increased as well as HC (8.8±17.6 vs 5.3±5.6, p=0.390). STEMI patients with HC>7 pg/mg (mean), still presented higher levels of WBC (14.2±3.2 vs 10.7±3.5 x10^3/mmc, p=0.042). A positive correlation was found between CRP and WBC (R=0.458, p=0.002) and between HC and WBC (R=0.270, p=0.111).
Conclusions. STEMI patients present higher levels of N, L, NLR, SII and numerical increase of HC and WBC at admission. Inflammation plays a key role in endothelial dysfunction that is implicated into the development of cardiovascular events. These preliminary data suggest a possible role of secondary prevention therapies targeting chronic PSS and inflammation to further reduce the residual CV risk of ACS patients.

A458: SIGNIFICANT REDUCTION IN VENTRICULAR ARRHYTHMIC BURDEN AFTER CTO REVASCULARIZATION: A CASE REPORT

Chiara Giordano (a, b), Alberto Pollina (a), Gabriele Tumminello (a), Andrea Faggiano (a, b), Stefano Carugo (a, b)

(a) DEPARTMENT OF CARDIO-THORACIC-VASCULAR DISEASES, FOUNDATION IRCCS CA GRANDA OSPEDALE MAGGIORE POLICLINICO, 20122 MILAN, ITALY; (b) DEPARTMENT OF CLINICAL SCIENCES AND COMMUNITY HEALTH, UNIVERSITY OF MILAN, 20122 MILAN, ITALY

Background. Research involving individuals with implantable cardioverter-defibrillators (ICDs) has revealed that the presence of a chronic total occlusion (CTO) is a significant independent predictor of malignant arrhythmias requiring ICD therapy. This is probably because the myocardial territory supplied by a CTO is a pro-arrhythmogenic milieu characterized by scar tissue, large scar border zone, hibernating myocardium, residual ischemia despite collaterals, areas of slow conduction, and heterogeneity in repolarization. Re-establishing coronary blood flow through revascularization procedures may potentially lead to electrical stabilization, as indicated by a reduction in QT(c) dispersion, a decrease in the T wave peak-to-end interval, a reduction of late potentials, and a decrease in the scar border zone area.
Case description. We present the case of a 76-year-old patient admitted to the emergency room due to cardiac arrest for sustained ventricular tachycardia. Following successfully resuscitation with external defibrillation and restoration of sinus rhythm (without ST elevation alterations), the patient was urgently transported to the catheterization lab, where, in absence of culprit lesions, it was identified a chronic occlusion of the circumflex artery with collateral recirculation, both homocoronary and heterocoronary. Echocardiography revealed normal ejection fraction. A collective decision to assess the viability of the circumflex artery territory before a potential coronary revascularization to reduce arrhythmic events was made. Before discharge, the patient underwent implantation of a single-chamber ICD for secondary prevention of sudden cardiac death. Subsequently, ambulatory follow-up revealed multiple sustained ventricular tachycardia episodes despite maximal beta-blocking and antiarrhythmic therapy, responsive to antitachycardia pacing. The case was reviewed, and collectively, it was decided not to perform the assessment of myocardial viability and proceed directly with the revascularization of the circumflex artery CTO, in attempt to reduce the burden of arrhythmic events. During subsequent 6 months follow-up, the device interrogations no longer detected ventricular arrhythmias.
Clinical considerations. Future investigations should delve into whether revascularization of chronic total occlusions (CTOs) effectively leads to a reduced occurrence of malignant ventricular arrhythmias.

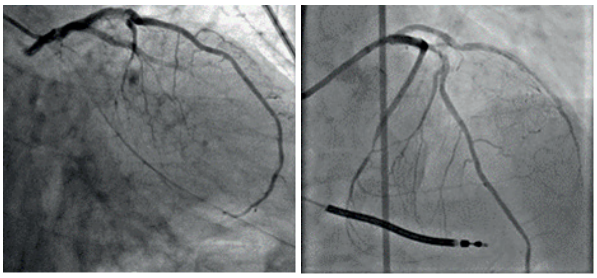

A459: BURDEN OF ATRIAL FIBRILLATION IN ST-ELEVATION MYOCARDIAL INFARCTION - IL TRIAL BASTA

Nicola Ferrara (a), Pasquale Crea (a), Francesco Costa (a), Maria Clara Tropea (a), Maria Claudia Lo Nigro (a), Serena Miccichè (a), Giuseppe Pelaggi (a), Gianluca Di Bella (a), Antonio Micari (a), Scipione Carerj (a)

(a) DIPARTIMENTO DI MEDICINA CLINICA E SPERIMENTALE, CARDIOLOGIA CON UTIC, UNIVERSITÀ ' DEGLI STUDI DI MESSINA

La Fibrillazione Atriale (FA) rappresenta la più comune aritmia cardiaca nei pazienti ospedalizzati con diagnosi di Infarto Miocardico Acuto (IMA) con sopraslivellamento del tratto ST (STEMI), risultando esserne una complicanza importante durante il decorso clinico. In un ampio studio svedese di Batra G et al., che ha coinvolto 106780 pazienti con diagnosi di IMA, la prevalenza di Fibrillazione Atriale era del 15.5% e più comunemente si trattava di diagnosi di nuova insorgenza (7,6%), con frequente ripristino del ritmo sinusale prima della dimissione. Sebbene l'associazione tra questa aritmia e l'IMA risulti essere complessa e bidirezionale, è chiaro come tali pazienti presentino durante follow-up i peggiori outcomes: tutti i sottotipi di fibrillazione atriale riscontrati in caso di IMA hanno infatti un rischio significativamente più alto di mortalità per tutte le cause rispetto ai pazienti in ritmo sinusale, soprattutto in caso di FA di nuova insorgenza con FA alla dimissione. Da un punto di vista terapeutico, le maggiori implicazioni dovute alla presenza di FA nei pazienti con STEMI, sottoposti a PCI, dipendono dalla gestione della terapia antitrombotica, che deve necessariamente tener conto da un lato del rischio trombotico e dall'altro di quello emorragico. La gestione periprocedurale in caso di IMA e PCI è dettagliata nelle linee guida della Società Europea di Cardiologia (ESC). Nei pazienti con FA dopo un recente IMA e l'impianto di stents coronarici, le evidenze suggeriscono di adottare, almeno per un breve periodo (da una settimana ad un mese) una triplice terapia, che includa un OAC (preferibilmente un NAO), un inibitore di P2Y12 (soprattutto il Clopidogrel) e l'acido acetilsalicilico a basse dosi. Tuttavia, ciò aumenta il rischio emorragico e pertanto il passaggio ad una duplice terapia con OAC ed inibitore di P2Y12 è consigliabile il prima possibile. In tali casi, il ruolo della terapia anticoagulante appare pertanto poco chiaro, lasciando spesso dubbi al clinico, il quale ha l'ostico compito di raggiungere una decisione terapeutica ponderando il rischio ischemico e quello emorragico. In letteratura sono presenti pochi studi, per lo più osservazionali, mirati a valutare l'efficacia e la necessità della terapia anticoagulante nei pazienti con FA di nuova insorgenza e diagnosi di STEMI. Considerata la possibilità che la fibrillazione atriale parossistica in corso di STEMI possa essere innescata dall'episodio ischemico acuto e che il rischio di recidiva possa essere legato a multipli fattori tra cui l'efficacia e la tempistica della rivascolarizzazione, la sede dell'infarto e le comorbidità, appare importante analizzare l'evoluzione dell'aritmia nel tempo in questa categoria di pazienti. Il trial BASTA è uno studio osservazionale prospettico che include i pazienti affetti da IMA con persistente sopraslivellamento del tratto ST (STEMI) e Fibrillazione Atriale di nuovo riscontro (FA New-Onset) presente al momento della diagnosi o presentatasi nelle ore successive all'evento, entro comunque la dimissione. I pazienti arruolati saranno sottoposti a controllo elettrocardiografico seriato durante il ricovero e a visita cardiologica di controllo ed elettrocardiogramma ad un mese e a sei mesi come da routine. In caso di portatori di CIED (cardiac implanted electronic devices), sarà eseguito il controllo dello stesso alla dimissione e durante visita di controllo. L'obiettivo del nostro studio è quello di valutare il tempo libero da FA (obiettivo primario), il burden di FA, i trend prescrittivi della terapia antitrombotica e gli outcome clinici a medio termine (obiettivi secondari) nei pazienti con STEMI ed FA di prima diagnosi. Allo studio è stata inoltre inclusa un'analisi retrospettiva della stessa popolazione di pazienti trattati presso la nostra Istituzione.

A460: FAST TRACK PCSK9-I DOPO SCA: "THE LOWER AND THE EARLIER THE BETTER" IN UN PAZIENTE CON SHOCK CARDIOGENO E RESIDUA MALATTIA ATEROSCLEROTICA DI GRADO INTERMEDIO DEL TRONCO COMUNE

Imma Forzano (a), Domenico Florimonte (a), Giuseppe Gargiulo (a)

(a) UNIVERSITÀ DEGLI STUDI DI NAPOLI FEDERICO II

I progressi sulla terapia ipolipemizzante (LLT) hanno consentito di raggiungere grandi successi in termini di prevenzione primaria e secondaria

degli eventi cardiovascolari (CV), ma il rischio residuo di eventi maggiori (MACE) permane elevato anche nei soggetti trattati secondo gli "standards of care". Nei pazienti naive da LLT, anche se a rischio CV molto elevato o estremo, le linee guida ESC suggeriscono un approccio "stepwise" con l'iniziale introduzione di una statina ad elevata potenza ed eventuale aggiunta sequenziale di ezetimibe e PCSK9-I qualora non si raggiunga il target di LDL-c entro 4-6 settimane. L'approccio "fast-track" prevede l'uso della terapia massimale con statina, ezetimibe e PCSK9-I già a partire dal ricovero e riduce LDL-c di circa l'85%, portando nel più breve tempo possibile la maggioranza dei pazienti a target. Presentiamo un caso di real life con applicazione della strategia fast track. Un uomo di 62 anni, naive da LLT, giunge presso il nostro cathlab con diagnosi di STEMI anteriore complicato da shock cardiogeno ed insufficienza respiratoria, in supporto rianimatorio ed intubazione orotracheale. I fattori di rischio CV noti sono l'obesità e l'ipertensione arteriosa. Alla coronarografia: stenosi calcifica subocclusiva del tratto medio del ramo discendente anteriore (RDA) della coronaria sinistra, stenosi intermedia del tronco comune (TC) e dell'ostio di RDA. Il ramo circonflesso della coronaria sinistra e la coronaria destra sono ateromasici ma esenti da stenosi angiograficamente significative. Si posiziona dispositivo di assistenza meccanica al circolo (Impella CP) mediante accesso arterioso femorale ottenendo buon supporto di circolo (3.5 l/min) e miglioramento del quadro emodinamico. Si procede a PCI protetta del tratto medio del RDA tramite multiple predilatazioni con catetere a palloncino, impianto di stent medicato e postdilatazione con catetere a palloncino. Si ottiene un ottimo risultato angiografico finale con flusso anterogrado TIMI 3. Alla valutazione finale effettuata con IVUS, non si evidenziano lesioni significative al tratto distale del TC (Minimal Lumen Area MLA 14 mm^2) e all'ostio di RDA (MLA 9 mm^2). Al termine della procedura si lascia in situ l'introduttore radiale per il monitoraggio invasivo della PA ed il dispositivo di assistenza meccanica al circolo. Agli esami di laboratorio: Tn-I di 24502 pg/ml, colesterolo totale di 233 mg/dl, LDL-c di 165 mg/dl. Alla luce del rischio CV molto alto del paziente e dell'evidenza laboratoristica di dislipidemia misconosciuta, si procede con la fast track: atorvastatina 40 mg, ezetimibe 10 mg ed alirocumab 150 mg con prima somministrazione intraospedaliera. Nei giorni seguenti il paziente riceve supporto con inotropi endovenosi, fino al raggiungimento della stabilità emodinamica con rimozione di Impella ed estubazione orotracheale. Alla piena stabilizzazione, il paziente viene dimesso in buone condizioni cliniche con terapia ottimizzata. Alla dimissione già si osserva il raggiungimento del target dei livelli di LDL-c (<55 mg/dL): 44 mg/dl. Al controllo ambulatoriale a 30 giorni il paziente esibisce esami esterni con LDL-c di 28 mg/dl. Recentemente è stato dimostrato che un approccio atto a ridurre i livelli di LDL-c con l'introduzione precoce di PCSK9-I già durante il ricovero apporta una significativa riduzione dei MACE e della morte CV in pazienti ad elevato rischio. Resta da stabilire quale sia il cut-off ideale di LDL-c per prediligere la strategia fast-track. Alla luce di tali evidenze e del recente aggiornamento AIFA sui criteri di rimborsabilità dei PCSK9-I, l'approccio fast-track è ragionevole ed appropriato per ridurre drasticamente e precocemente i livelli di LDL-c e pertanto il rischio CV residuo nei pazienti sopravvissuti a SCA.

A461: IMPACT OF FRAILTY ON IN-HOSPITAL MORTALITY IN OLDER PATIENTS UNDERGOING PERCUTANEUS CORONARY INTERVENTION: A PROSPECTIVE OBSERVATIONAL STUDY

Michele Granatiero (a), Marco Mele (b), Ilaria Ragnatela (a), Francesco Mautone (a), Erika Tabella (a), Luciano Rossi (a), Matteo Romano (a), Natale Daniele Brunetti (a)
(a) DEPARTMENT OF MEDICAL AND SURGICAL SCIENCES, UNIVERSITY OF FOGGIA, FOGGIA, ITALY; (b) CARDIOTHORACIC DEPARTMENT, POLICLINICO RIUNITI UNIVERSITY HOSPITAL, FOGGIA, ITALY

Background. In the last decades population ageing has led to an increasing number of older, frail, comorbid patients admitted for acute myocardial infarction (AMI) and NSTEMI[1]. In older patients an invasive strategy should be carefully weighted taking into account frailty, comorbidity, potential risks and benefits, but frailty scales are not well validated in addressing invasive management of older patients with NSTEMI[2]. This prospective observational study sought to evaluate the impact of frailty on in-hospital outcome in older patients with NSTEMI undergoing percutaneous coronary intervention (PCI).
Methods. We consecutively enrolled 116 NSTEMI-patients aged>75 years; 32 frail patients underwent PCI, 16 frail patients did not undergo PCI, and 58 non-frail patients underwent PCI, 10 non-frail patients did. Patients with type-2 MI and STEMI were excluded. Frailty was defined as a Rockwood Frailty Scale score ≥5[3].
Results. In-hospital mortality was 2.9% in fail patients, 1.5% in non-frail, borderline higher in frail patients undergoing PCI (OR 5.18, 95%CI 0.94 to 28.46, p=0.058), non-significantly higher in frail patients not treated with PCI (OR 3.62, 95%CI 0.15 to 83.53, p=0.42). PCI did not impact in-hospital mortality both in older NSTEMI frail patients (OR 1.29, 95%CI 0.22 to 7.55, p=0.77) and in non frail patients (OR 0.92, 95%CI 0.42- 20.77, p=0.963).
Conclusions. In a small observational study, frailty (Rockwood score ≥5) was associated with a poor prognosis in older NSTEMI patients, even in patients undergoing PCI; PCI did not significantly improve prognosis in frail older NSTEMI patients.

References

Rosegren A. et al; Age, clinical presentation, and outcome of acute coronary syndromes in the Euroheart acute coronary syndrome survey. Eur Heart J 2006; 27:789795;
Byrne R. A. et al; 2023 ESC Guidelines for the management of acute coronary syndromes: Developed by the task force on the management of acute coronary syndromes of the European Society of Cardiology (ESC). Eur Heart J 2023;
Rockwood K et al; A global clinical measure of fitness and frailty in elderly people; CMAJ 2005; 173:489-95.

A462: ACUTE CORONARY SYNDROME DURING PREGNANCY, A PLAY IN THREE ACTS. A CHALLENGING CASE OF MYOCARDIAL BRIDGE AND VASOSPASTIC ANGINA

Marco Palmieri (c), Carla Zannelli (c), Henri Xhakupi (c), Roberta Della Bona (b)
(a) IRCSS OSPEDALE POLICLINICO SAN MARTINO; (b) U.O. CARDIOLOGIA, DIPARTIMENTO CARDIO-TORACO-VASCOLARE (DICATOV), IRCCS OSPEDALE POLICLINICO SAN MARTINO; (c) SCUOLA DI SPECIALIZZAZIONE IN MALATTIE DELL'APPARATO CARDIO-VASCOLARE, UNIVERSITÀ DEGLI STUDI DI GENOVA

The risk of acute coronary sindrome (ACS) during pregnancy is 3-4 fold higher than in non-pregnant women of the same age, and is increasing due to higher maternal age and consequent risk factors exposure. Identifying the causes of ACS is challenging due to the risk of fetal harm in diagnostic process. We report the case of a 39-year-old woman at the 22nd week of pregnancy who was admitted to our emergency room for chest pain radiating to the interscapular region, jugular and left arm and associated with diaphoresis, lasting about 4 hours. In her past medical history previous mild smoking history and a previous uncomplicated pregnancy was reported. The first EKG showed a stretched ST and inverted T waves infero-lateral leads. The echocardiogram revealed preserved left systolic function with hypokinesia of the mid-distal anterior interventricular septum (IVS). High-sensitivity cardiac I troponin was increased with a peak of 17473 ng/L (normal values <40 ng/L). Clinical examination and gynecological ultrasonography showed no fetal abnormalities. A chest computed tomography (CT) was performed excluding aortic dissection. The patient was admitted to the cardiological intensive care unit and despite the clinical, laboratory, and echocardiographic findings suggestive for ACS, due to her clinical stability (at admission the patient was asymptomatic) the coronary angiography was deferred, and an initially conservative treatment with acetylsalicylic acid (ASA), low-molecular-weight heparin and metoprolol was adopted. After multidisciplinary discussion, given the epidemiological suspicion of coronary artery dissection that could be aggravated by coronary catheter angiography, the patient underwent coronary CT angiography with low dose of radiation (estimated total dose to the fetus from the 2 CTs=0.58 mGy) that excluded atherosclerosis or coronary dissection, but showed a long complete intramyocardial course about 3 mm deep of the distal para-apical anterior descending artery (LAD), with significant narrowing at the end of the systole (~55%). To better investigate the pathophysiological mechanism of myocardial ischemia, a cardiac magnetic resonance without contrast medium was carried out confirming the hypokinesia of the mid-anterior IVS. Interestingly, T2 mapping imaging revealed transmural edema involving the mid-anterior and mid-inferior segments of the IVS; as a result, the myocardial injury appeared located upstream of the intramyocardial bridge. On suspicion of vasospastic angina, we chose amlodipine among dihydropyridine calcium channel blockers because, according to several studies, its intake in early pregnancy does not seem to be associated with an increase in fetal malformations; in addiction, amlodipine has the longest onset of action reducing the chances of vasodilator symptoms which can reduce placental perfusion. The patient was discharged home with a diagnosis of Myocardial Infarction with Nonobstructive Coronary Arteries (MINOCA), asymptomatic and in hemodynamic stability. In order to prevent further events of myocardial injury as consequence of the reported main findings, a home therapy based on low dosage of amlodipine, metoprolol and ASA was adopted. The subsequent course of the pregnancy was uneventful with full-term delivery, without obstetric and perinatal complications. In addition, a new cardiac MRI with gadolinium is planned to corroborate the diagnosis and evaluate the presence of any scars. In conclusion, ischemic heart disease in pregnant women is a challenge that requires a balance between potential risks and benefits for the health of both the mother and the child.

A463: A RARE CASE OF TAKOTSUBO SYNDROME TRIGGERED BY NSTEMI

Pasquale Policastro (a, b), Pier Giorgio Tiberi (a, b), Melwyn Luis Muthukkattil (a, b), Allegra Battistoni (a, b), Damiano Magrì (a, b), Giuliano Tocci (a, b), Emanuele Barbato (a, b), Angela Gurgo (a, b)
(a) SAPIENZA UNIVERSITÀ DI ROMA; (b) AZIENDA OSPEDALIERA UNIVERSITARIA SANT'ANDREA

Takotsubo syndrome (TTS) is a cardiomyopathy characterized by acute myocardial damage, associated with transient reversible regional

wall motion abnormalities (RWMAs) and electrocardiographic alterations, that cannot be solely explained by coronary lesions at the invasive coronary angiography (ICA). We herein report a rare presentation of a TTS triggered by non-ST segment elevated myocardial infarction (NSTEMI) in an 83-year old male patient, admitted twice in the course of 5 days to our CCU and Cardiology ward. The patient was a former smoker affected by hypertension and presented to our Emergency Department (ED), referring several episodes of chest pain at rest within the previous 24 hours. The electrocardiogram (ECG) showed typical ischemic alterations in association with increased troponin levels, despite no echocardiographic (TTE) abnormalities. An ICA was thus performed, highlighting a significant first septal branch stenosis, deemed as not eligible for revascularization. The patient was therefore discharged after three days of observation, with a diagnosis of NSTEMI and with an optimal medical therapy for improved symptom control. The morning after being discharged, the patient had a new episode of chest pain, for which he came back to our ED. The ECG showed mild ST-segment elevation in V2 and negative T waves in V4-V5 associated with increased troponin levels while the echocardiogram highlighted an apical and distal interventricular septal akinesia. An ICA was not performed again due to the recent angiographic evidence. During hospitalization, the ECG demonstrated a characteristic TTS progression while serial TTE exhibited resolution of the RWMAs. To the best of our knowledge, this is the first case report in literature describing a TTS triggered by NSTEMI in the span of a week. In the absence of typical emotional triggers, this unique case of TTS may represent a consequence of other physical stressors, such as hospitalization, and a possible pathophysiological response to cardiac events.

A464: SPONTANEOUS CORONARY ARTERY DISSECTION AND TRIPTANS: POSSIBLE MASKED KILLERS: A CASE REPORT

Dajana Polito (a), Andrea Segreti (a), Mariagrazia Piscione (a), Arianna Martucciello (a), Lorenzo Frau (a), Gian Paolo Ussia (a), Francesco Grigioni (a)
(a) FONDAZIONE POLICLINICO UNIVARSITARIO CAMPUS BIOMEDICO

In the present article, we describe the case of a 51-year-old female coming to the Emergency Department following an episode of acute chest pain. The cardiovascular risk factors were an actual smoking habit (10 cigarettes per day) and a family history of cardiovascular disease (her father died when he was fifty-five). The electrocardiogram (EKG) demonstrated ST segment elevation in the precordial leads. Therefore, the patient underwent cardiac angiography, which showed spontaneous dissection of the medium-distal section of the anterior descending artery. She reported no comorbidities except for headaches treated with Sumatriptan. A correlation between spontaneous coronary artery dissection (SCAD) and triptans has already been reported in the literature. If myocardial infarction is more common in patients with cardiovascular risk factors, SCAD seems more frequent in young and smoker females. This clinical case helps us to discuss the pathophysiological mechanisms of SCAD. The dissection of the anterior descending artery is due to circumferential shear stress caused by these drugs, combined with smoking habits and estrogen deprivation. These latter influence the immune system and the circulating progenitor cells, which are reduced and less active to replace senescent endothelial cells. That is why an intimal flap was formed so that the blood would enter the media and the dissection would be perpetuated. The suspension of the drug is necessary to prevent the vasoconstriction of the vessel from exacerbating the wall stress caused by smoke and sexual hormones deficiency.

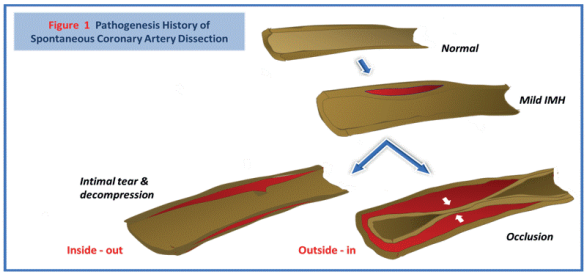

Figure 1 Pathogenesis History of Spontaneous Coronary Artery Dissection

"Inside-out': intramural haematoma (IMH) is caused by rupture of the endothelial-intimal layer, which allows blood from the vascular lumen to enter the vessel wall. "Outside-in', a bleeding episode in the coronary artery wall (at the level of the vasa vasorum) is the main cause of an IMH without intimal rupture

A465: UN PONTE TRA I MECCANISMI DI ISCHEMIA MIOCARDICA

Ciro Pollio Benvenuto (a), Simona Todisco (a), Domenico Galante (a), Andrea Vicerè (a), Vincenzo Viccaro (a), Chiara Giuliana (a), Antonio Maria Leone (a)
(a) UNIVERSITÀ CATTOLICA DEL SACRO CUORE

L'angina pectoris, descritta per la prima volta da William Heberden ben 250 anni fa, è il prodotto dell'ischemia miocardica. Quest'ultima veniva fatta risalire esclusivamente alla malattia aterosclerotica ostruttiva del distretto coronarico epicardico, finché negli ultimi anni si è affermato il concetto di ischemia miocardica senza coronaropatia ostruttiva (Ischemia with Non Obstructive Coronary Arteries, INOCA) come prodotto di alterazioni funzionali, quali il vasospasmo, tanto del compartimento epicardico quanto del microcircolo coronarico, o strutturali, a carico però dei vasi di piccolo calibro (pre-arteriole ed arteriole). Un altro possibile meccanismo di INOCA è il bridge miocardico: quest'ultimo, precedentemente ritenuto un'alterazione congenita per lo più benigna, può produrre invece ischemia attraverso molteplici meccanismi, tra loro strettamente correlati. Viene quindi presentato il caso di una donna affetta da angina pectoris che è stata sottoposta a coronarografia con test funzionali, dimostrando un quadro di malattia aterosclerotica non emodinamicamente significativa, associata a disfunzione microvascolare e spasmo epicardico nel contesto di un lungo segmento intramiocardico dell'Arteria Discendente Anteriore.

A466: OMI: REPLACING THE STEMI MISNOMER?

Davide Maria Scordo (a), Chiara Martini (a), Davide Rossi (a), Giulia Renda (a), Sabina Gallina (a), Fabrizio Ricci (a)
(a) UNIVERSITÀ "G. D'ANNUNZIO" CHIETI - PESCARA

An 84-year-old woman with hypertension, hyperlipidaemia and ischemic heart syndrome (previous PCI-DES on LAD-D1 six months earlier) presented to the emergency department complaining of substernal, crushing chest pain radiating to the left arm and dyspnoea. ECG (fig. A) showed atrial fibrillation (AF) with rapid ventricular response (RVR), a new onset of left anterior fascicular block (LAFB), ST depression (STD) in II, III, aVF and V5-V6; negative T waves in aVL and subtle ST elevation (STE) in lead aVL and aVR. Laboratory testing revealed Troponin-I level of 356 pg/mL to 6080 pg/mL and Hb 9.5 g/dL. Echo showed a LV with EF 40% and new apical akinesia, moderate mitral regurgitation, severe tricuspidal regurgitation. She was assigned a diagnosis of acute coronary syndrome (ACS) without ST elevation (NSTEMI). Invasive coronary angiography, performed 23 hours after first medical contact, was notable for intrastent restenosis of LAD-D1 (Fig. B) of 90% (culprit lesion with TIMI flow 2). So, angiography demonstrated the presence of an Occlusive Myocardial Infarction (OMI) and angioplasty with stent placement was performed successfully. Triple anticoagulant therapy was started. The patient was discharged on DAT (high bleeding risk), diuretic therapy, ACE-I, betablocker, statin. One-month follow-up was uneventful. Echo showed a LV with EF of 50%, persistent akinesia of the antero-apical septum. This case is not a STEMI. Despite working diagnosis of ACS-NSTE, it is a case of OMI, specifically STEMI(-) OMI. In fact, observational studies have shown that about 25% of NSTE are OMI. In our patient's ECG, the abnormalities of repolarization are not secondary only to AF with RVR. Two vectors can be identified (Fig. C): one of transmural ischemia reflects OMI, resulting in a STE in lead aVL, and one directed towards aVR that represents diffuse subendocardial ischemia caused by RVR and anemia, which results in STE, this attenuates STE in lead aVL. The composite vector defines subtle STE in leads aVR and aVL and reciprocal STD in inferior leads. The new LAFB could be attributable to the same ischemic territory of the culprit vessel. The resulting T waves vector is directed to inferior leads, realizing a discrepancy in their orientation respect to QRS axis. This ECG alterations are caused by ischemia. We can consider this a novel "Northern OMI" pattern. In patients with suspected ACS, with/without other relevant conditions (i.e. AF, anemia, hypotension), OMI must be considered, even in the absence of obvious STEMI pattern. Observational studies have shown that STEMI(-)OMI patients have similar clinical outcomes and prognosis to patients presenting with STEMI(+) criteria, so it would be necessary to recognize OMI patterns to perform emergency revascularization and improve the prognosis.

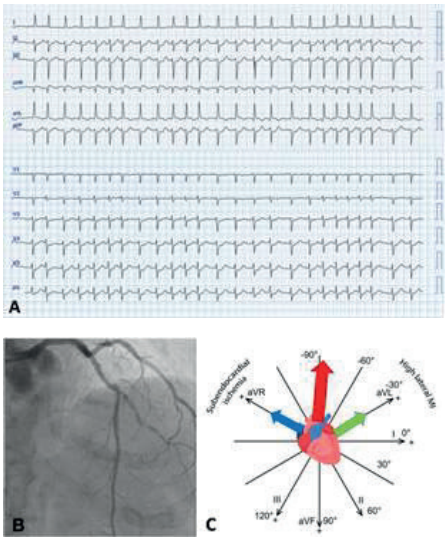

A467: A HUGE LEFT VENTRICLE THROMBUS AND ITS CONSEQUENCES: IS THIS PREVENTABLE?

Roberta Ruggieri (a), Adriana Mallardi (a), Viviana De Luca (a), Debora Rizzo (a), Bux Francesca (a), Rosanna Valecce (a), Pasquale Caldarola (b), Vincenzo Massimo Bonfantino (a)
(a) UOC CARDIOLOGIA, PO DI VENERE, VIA OSPEDALE DI VENERE, 1, 70131 BARI (BA), ITALY; (b) UOC CARDIOLOGIA, PO SAN PAOLO, VIA CAPO SCARDICCHIO, 70123, BARI (BA), ITALY

A 64 years–old man was admitted to our emergency unit after being involved in a car crash, in which pedestrians were run over by his car. When he arrived to police department, he showed neurological symptoms and his nephews took him to the Hospital. He underwent a cranial CT with evidence of two areas of ischemic stroke in frontal lobe. After a neurological examination, he had a cardiac consultation, knowing his history of chronic coronary syndrome. Sinus rhythm with QS-aspect plus ST-segment elevation in all precordial and inferior leads were recorded by 12-lead EKG. A transthoracic echocardiogram showed a very large septal and apical aneurism with a wide apical mural thrombus and a very big amount of spontaneous echo-contrast in LV cavity. The aneurism was huge and difficult to be fully detected by echocardiography. In order to exclude a pseudoaneurysm, the patient underwent a cardiac MRI showing a 8 cm-long left ventricular aneurism with a laminated thrombus inside. The patient's past history shed light on management of MI complications. In the previous year, he had an ACS episode, and he underwent a coronary angiography which showed a chronic totally occlusion of LAD. It had not been treated since there was just a large apical and anterior aneurism of scar tissue. He was discharge with dual antiplatelet therapy for ACS without anticoagulation. However, this patient had almost all identified risk factors for developing LV thrombosis and some others for hemorrhagic consequenses. In literature, authors invite clinicians to consider the perceived risk of thrombus formation versus the bleeding risk of combining antiplatelet and anticoagulation therapy. In conclusion, an ACS with a chronic coronary occlusion in a patient with risk factors for LV thrombosis probably deserves a combination of antiplatelet and anticoagulation therapy, in a patient-selected strategy. Weighting ischemic and hemorrhagic risks must be the everyday effort of cardiologists, even if sometimes it turns out to be extremely difficult.

A468: CARDIOVASCULAR RISK FACTORS AND CORONARY ARTERY LESIONS IN HIGH RISK IMMIGRANT POPULATION: REAL LIFE EXPERIENCE FROM AN ITALIAN CENTRE

Claudia Tamburro (a), Russo Massimo (a), Pietro Oro (a), Federica Porzio (a), Mihaela Ifrim (a), Roberto Rosenfeld (a), Lucy Barone (a), Aikaterini Andreadi (a), Saverio Muscoli (a), Davide Lauro (a), Francesco Barilla´ (a)
(a) U.O.C. CARDIOLOGIA POLICLINICO "TOR VERGATA"

Background. Prevalence of coronary artery disease (CAD) varies significantly with ethnicity. Patients from Eastern Europe (EEP), Middle East and North Africa (MENAP), and South Asia (SAP) are among the high-risk populations.
Methods. The aim of this retrospective study is to identify cardiovascular risk factors and specific coronary findings in high-risk immigrant groups. From 2016 to 2021, we compared the medical records and coronary angiographies of 220 patients from the above high-risk ethnic groups referred for Acute Coronary Syndrome (ACS) with 90 Italian patients (IP). This retrospective study was designed to provide information on cardiovascular risk factors and specific coronary findings in high-risk immigrant groups. We compared medical records of 220 patients with ACS from the above high-risk ethnic groups with those of 90 IPs between 2016 and 2021. In addition, we evaluated coronary angiographies with a focus on culprit lesion, primarily multi-vessel and left heart disease.
Results. At the first event, the mean ages for IP were 65.4 ± 10.2 years, SAP were 49.8 ± 8.5 years (Relative Reduction (ReR) 30.7%), EEP were 51.9 ± 10.2 years (ReR 26%), and MENAP were 56.7 ± 11.4 years (ReR 15.3%); $p<0.0001$. The prevalence of hypertension was considerably higher in the IP group. Diabetes was less prevalent in EEP and MENAP. When compared to other groups, SAP demonstrated a significantly greater prevalence of left main artery disease ($p=0.026$) and left anterior descending artery disease ($p=0.033$) than EEP and MENAP. In SAP, we found that the 40–50 age group had a greater prevalence of three-vessel coronary artery disease.
Conclusions. Our data suggest the existence of a potential coronary phenotype in several ethnic groups, particularly SAP, and underestimate the frequency of CV risk factors in other high-risk groups, supporting the role of a genetic influence in these communities.

A469: IMPELLA CP IMPLANTATION TROUGHOUT AN EVOLUT PRO PLUS SELF-EXPANDABLE BIOPROSTHESIS FOR A COMPLEX HIGH-RISK PCI: A CASE REPORT

Marco Addari (b), Livio Giuliani (a), Paolo Ciarelli (b), Federica De Donno (b), Maria Vittoria Caprio (b), Serena Rossi (a), Sabina Gallina (b)
(a) EMODINAMICA E CARDIOLOGIA INTERVENTISTICA, OSPEDALE SS. ANNUNZIATA, CHIETI; (b) DEPARTMENT OF NEUROSCIENCE, IMAGING AND CLINICAL SCIENCES, G. D'ANNUNZIO UNIVERSITY OF CHIETI-PESCARA

An 89 years-old woman with past history of a Medtronic Evolut PRO 26 self-expandable transcatheter aortic valve replacement (TAVR) for symptomatic severe aortic stenosis, with contextual implantation of a drug eluting stent (DES) on the left main using the Chimney technique due to a high risk of left coronary artery occlusion, presented at the emergency department of our center complaining angina and worsening dyspnea. In the Emergency Department an EKG showed antero-lateral ST deviation and T-wave inversion with concomitant troponin level elevation. A trans-thoracic echocardiogram was also performed, showing concentric hypertrophy of the left ventricle with a preserved ejection fraction and segmental hypokinesia of the lateral and anterior walls; a preserved functioning of the aortic prosthesis with a trivial paravalvular leak was observed. The chest x-ray showed no signs of pulmonary congestion, but a mild right pleural effusion. Hence, the patient was admitted in coronary intensive care unit with a working diagnosis of acute coronary syndrome and a new coronary angiography was scheduled for the next day. The angiography showed a severe, unstable coronary lesion on the proximal segment of LAD and chronic total occlusion of left circumflex artery. Revascularization of unstable coronary lesion on the proximal segment of LAD (last patent vessel), in an elderly patient with a previous history of TAVR with implant of self-expanding Evolut Pro+ 26mm valve and left main stenting with chimney technique was considered immediately challenging. A dedicated Heart Team was performed to plan the best procedural strategy. Firstly, our strategy was to execute revascularization without any mechanical circulatory support in order to avoid possible complications related to the potential interaction between pVAD's outlet and prosthesis' struts. At the admission to the Cath-lab, the patient was hemodynamically stable; good values of blood pressure, heart rate and oxygen saturation were observed. A left radial arterial access was firstly obtained. Left Main was engaged with an extra back-up guiding catheter, and a workhorse guidewire was advanced through the distal LAD. During the first semi-compliant balloon pre-dilatation, the patient became hypotensive and experienced progressive severe bradycardia with subsequent cardiac arrest. RCP maneuvers was performed, with contextual intravenous epinephrine and atropine administration; temporary trans-venous pacemaker was suddenly inserted via right femoral vein. After several minutes of CPR ROSC was achieved, with evidence of PMK-induced rhythm. Standing the impending hemodynamic instability, IMPELLA implantation became abruptly binding. An emergent right femoral arterial access was obtained and through it IMPELLA CP was positioned using TTE and fluoroscopy guidance. TTE confirmed the IMPELLA CP outlet to be above CoreValve Evolut leaflets. IMPELLA CP provided about 4 L/min of forward flow, ensuring good hemodynamic balance to continue the procedure safely. Effective PCI with implantation of a 3.5*22mm DES and consequent post-dilatation with non compliant balloon were performed with an optimal final result. At the end of the procedure, standing the condition of hemodynamic balance, weaning procedures from IMPELLA support was performed with progressive reduction of flow rate by two levels until reaching P2 support. After a short-term monitoring during P2 IMPELLA support, pVAD was safely removed and haemostasis of arterial accesses was obtained. The patient was therefore admitted in coronary intensive care unit for continouos clinical and hemodynamic monitoring. At the end of the procedure the patient was re-admitted in cardiac intensive care; a satisfactory hemodynamic balance was continuously maintained. In the following days the patient underwent pacemaker implantation for sick sinus syndrome. She was therefore discharged, starting a period of cardiologic rehabilitation in a dedicated ward. This case demonstrated the safety and feasibility of IMPELLA CP implantation through a self- expandable transcatheter aortic valve during an high risk PCI procedure. It highlighted also possible technical concerns about both eventual interactions between IMPELLA's outlet and valve's frames, and unplanned coronary re-access for PCI in the setting of an acute coronary syndrome in a patient with history of previous TAVR procedure.

A470: THE COMPLEX WORLD OF NON-OBSTRUCTIVE CORONARY ARTERIES DISEASES: A CLINICAL-INSTRUMENTAL AND PROGNOSTIC COMPARISON

Laura Munaretto (a), Enzo Merro (a), Alessandra Lucia Fluca (a), Milijana Janjusevic (a), Laura Padoan (c, d), Cristina Hiche (a), Stefano D´errico (a), Alessandro Pierri (b), Andrea Di Lenarda (e), Gianfranco Sinagra (a), Aneta Aleksova (a)
(a) AZIENDA SANITARIA UNIVERSITARIA DI TRIESTE AND UNIVERSITY DI TRIESTE, DEPARTMENT OF MEDICAL SURGICAL AND HEALTH SCIENCES, CARDIOVASCULAR DEPARTMENT, TRIESTE, ITALY; (b) CARDIOLOGY DEPARTMENT AND INTENSIVE CORONARY CARE UTIC, PERRINO HOSPITAL, BRINDISI, ITALY; (c) UNIVERSITY OF PERUGIA, CARDIOLOGY AND CARDIOVASCULAR PATHOPHYSIOLOGY, PERUGIA, ITALY; (d) AZIENDA SANITARIA UNIVERSITARIA GIULIANO ISONTINA, CARDIOLOGY DEPARTMENT GORIZIA-MONFALCONE, GORIZIA, ITALY; (e) AZIENDA PER L'ASSISTENZA SANITARIA N.1, OSPEDALE MAGGIORE, CENTRO CARDIOVASCOLARE, TRIESTE, ITALY

Background. ACS with non-critical coronary arteries represents a major diagnostic, therapeutic and prognostic challenge for clinicians.
Aims. We sought to compare the clinical-anamnestic characteristics and evaluate the prognosis of three populations with initial presentation of

non-critical coronary arteries with different etiopathology namely Myocardial Infarction with Nonobstructive Coronary Arteries (MINOCA), type 2 myocardial infarction (MI) and Takotsubo syndrome (TTS), conditions that are difficult to differentiate.
Methods. In this single-centre retrospective observational study, data on 18223 patients who underwent invasive coronary angiography between 2005 and 2022 were obtained using the electronic health records software. After reviewing the angiographic and clinical data, the final cohort included 676 patients with non-ST elevation myocardial infarction (NSTEMI), of whom 301 had MINOCA, 237 had type 2 MI and 138 had TTS. The endpoint was defined as a composite of non-fatal AMI, non-fatal TIA or stroke, hospitalization for HF and death.
Results. Comparing the three groups, TTS population was older, followed by the type 2 MI and MINOCA population (72 ± 10 vs 70.55 ± 10.94 vs 66.33 ± 11.67 years, p<0.01). The TTS group tended to be more hypotensive (p<0.01), more tachycardiac (p<0.01) and with fewer cardiovascular risk factors such as diabetes (15.2% vs 17.3% vs 29.1%, TTS vs MINOCA vs type 2 MI p<0.01) and hypertension (65.9% vs 72.1% vs 83.5%, TTS vs MINOCA vs type 2 MI, p<0.01). TTS cohort had worse left ventricular systolic function on admission (46.88 ± 11.05 vs 54.55 ± 11.84 vs 57.67 ± 9.72, TTS vs MINOCA vs type 2 MI, p<0.01) and on discharge (51.78 ± 11.24 vs 57.36 ± 10.45 vs 58.56 ± 9.69, TTS vs MINOCA vs type 2 MI, p<0.01). During a median follow-up of 60 [34 – 101] months, 157 patients reached the endpoint. In the Kaplan-Meier analysis, patients with type 2 MI were more likely to experience the composite endpoint, while the TTS group was less likely (p<0.01). In the overall cohort, ACEi/ARB therapy on admission was an independent predictor of the composite endpoint (HR: 1.58; p=0.01), while dual antiplatelet therapy (DAPT) (HR: 0.59; p=0.01) and statin (HR: 0.71; p=0.03) at discharge were protective. After dividing the population according to diagnosis, ACEi/ARB therapy remained a negative predictor only in the type 2 MI cohort (HR: 2.03; p=0.01) as well as beta-blocker therapy at admission in TTS (HR: 2.97; p=0.03), while statin therapy remained protective in the MINOCA (HR: 0.51; p=0.01) and DAPT therapy in the TTS group (HR: 0.21; p=0.04) at discharge. Although a substantial number of patients with all three diagnoses achieved the endpoint, the multivariable Cox regression analysis indicated that type 2 MI, in addition to older age, male gender, worse LVEF, and anemia, as independent factors for worse outcome.
Conclusions. Among patients with non-critical coronary arteries, those diagnosed with type 2 MI were associated with worse outcome more than patients with MINOCA and TTS. Furthermore, the use of DAPT in patients with TTS and statins in the MINOCA group showed a protective role. Instead, the use of ACEI/ARB at admission could be a marker of greater early impairment of the type 2 MI population and beta-blockers in the acute decompensated HF phase of TTS could predict a poorer outcome.

A471: NUOVE FRONTIERE IN RISONANZA: LA PERFUSIONE QUANTITATIVA

Paolo Assabbi (a), Alberto Cossu (a), Federico Sanguettoli (a), Gianluca Calogero Campo (a), Elisabetta Tonet (a)
(a) AZIENDA OSPEDALIERA UNIVERSITARIA DI FERRARA

L'utilizzo della Risonanza magnetica da stress nella cardiopatia ischemica cronica ha assunto negli ultimi anni sempre più importanza grazie alla possibilità di valutare in modo non invasivo anche i pazienti con pregressa angioplastica coronarica. Paziente di 72 anni Donna, riferita c/o il nostro Centro per Sospetta Cardiopatia ischemica.

- Fattori di rischio cardiovascolare: ipertensione arteriosa, familiarità per CAD, dislipidemia, diabete mellito tipo II, pregressa abitudine tabagica.
- Anamnesi patologica remota: non precedenti di rilievo.
- Anamnesi cardiovascolare: Ateromasia non critica dei TSA.
- Anamnesi recente: Durante visita cardiologica riferisce angina da sforzo per sforzi moderati associati ad astenia per cui veniva prescritta RM stress.

L'indagine mostrava ventricolo sinistro non dilatato, non difetti di cinetica globale o segmentaria, FE calcolata pari al 60%; cinetica da stress invariata rispetto al basale. Nelle sequenze post-infusione di regadenoson, dopo somministrazione di EV di gadolinium, hanno mostrato in fase precoce, valori di Myocardial blood flow (MBF) uniformemente bassi nonostante stimolo vasodilatatore (valori <1.8 in pressochè tutti i segmenti), nonché valori di myocardial perfusion reserve index (MPRi) patologici (<1.5). Tale quadro risultava suggestivo per malattia ostruttiva epicardica trivasale o con coivolgimento del tronco comune. Alla coronarografia riscontro di severa coronaropatia interessante il tronco comune. Trattata con efficace angioplastica e stenting di asse TC-CX. La perfusione quantitativa rappresenta la più accurata valutazione RM della perfusione miocardica. In particolare, essa permette di quantificare il MBF per grammo miocardico. Tale metodica ha trovato applicazione negli ultimi anni sia per quel che riguarda la valutazione della malattia epicardica sia della malattia del microcircolo. Inoltre indici quali MPRi e MBF risultano essere fattore indipendente di aumentati MACE e morte cardiovascolare.
Bibliografia

- Patel AR, Antkowiak PF, Nandalur KR et al. Assessment of advanced coronary artery disease: advantages of quantitative cardiac magnetic resonance perfusion analysis. J Am Coll Cardiol 2010;56:561–9.
- Hsu LY, Jacobs M, Benovoy M et al. Diagnostic Performance of Fully Automated Pixel-Wise Quantitative Myocardial Perfusion Imaging by Cardiovascular Magnetic Resonance. JACC Cardiovasc Imaging 2018;11:697–707.
- Kotecha T, Chacko L, Chehab O et al. Assessment of Multivessel Coronary Artery Disease Using Cardiovascular Magnetic Resonance Pixelwise Quantitative Perfusion Mapping. JACC Cardiovasc Imaging 2020;13:2546–2557.
- Sammut EC, Villa ADM, Di Giovine G et al. Prognostic Value of Quantitative Stress Perfusion Cardiac Magnetic Resonance. JACC Cardiovasc Imaging 2018;11:686–694.

A472: PRESENTAZIONE ATIPICA DI UNO PSEUDOANEURISMA VENTRICOLARE: VECCHIE COMPLICANZE VISTE CON NUOVI OCCHI?

Leonardo Brugiatelli (a), Federico Guerra (a), Michele Alfieri (a), Giulia Stronati (a), Gianmarco Bastianoni (a), Federico Paolini (a), Antonio Dello Russo (a)
(a) UNIVERSITÀ POLITECNICA DELLE MARCHE

Presentiamo il caso di una paziente di 79 anni, donna, con storia di cardiopatia ischemica, fibrillazione atriale parossistica e pregresso ictus ischemico frontotemporoparietale destro. Per un episodio di angina instabile era stata sottoposta, nel 2020, a coronarografia che aveva rivelato la presenza di una stenosi distale dell'arteria interventricolare anteriore (di esile calibro, non rivascolarizzabile), per cui era stata intrapresa terapia medica anti-anginosa (beta bloccante, calcio-antagonista, ranolazina) con buona risposta clinica e successiva ripresa funzionale. Ad aprile 2023 accedeva presso il pronto soccorso del nostro Ospedale per dispnea ingravescente presente da 3-4 settimane. Alla valutazione ecografica risultava una normale funzione sistolica del ventricolo sinistro, in presenza di uno pseudoaneurisma (4.5x7.8 mm) dell'apice del ventricolo il quale, in previsione di intervento cardiochirurgico, veniva confermato alla TC cardiaca (vedi immagine allegata). La paziente è stata quindi sottoposta ad intervento cardiochirurgico di riparazione dello pseudoaneurisma (resezione e sutura diretta) in circolazione extra-corporea. Nel post-operatorio si segnala un lieve peggioramento della disfagia (già presente a domicilio), ma per il resto risulta privo di complicanze maggiori e caratterizzato da un buon recupero funzionale. Dal punto di vista cardiologico, a due mesi dalla dimissione, si segnala solamente la presenza di una lieve riduzione della funzione sistolica (FEVS 45%) per discinesia del setto ed acinesia dell'apice (sede di pregresso intervento), con scarso correlato clinico (lieve dispnea, buone condizioni generali).

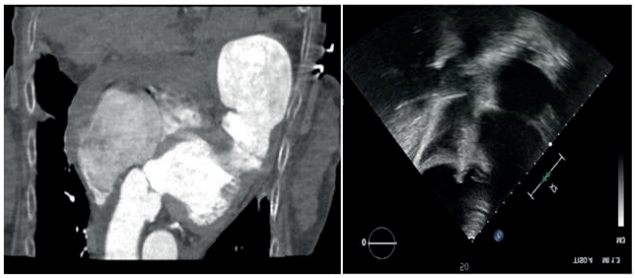

A473: TYPE II KOUNIS SYNDROME AND TYPE II TAKOTSUBO SYNDROME: A DOUBLE JEOPARDY

Valentina Capone (b, c), Eduardo Bossone (d), Fulvio Cacciapuoti (c), Salvatore Chianese (b, c), Vittorio Taglialatela (c), Davide D´andrea (c), Federico Cacciapuoti (a), Ciro Mauro (c)
(a) DEPARTMENT OF CARDIOLOGY VANVITELLI UNIVERSITY, NAPLES, ITALY; (b) DEPARTMENT OF ADVANCED BIOMEDICAL SCIENCES, FEDERICO II UNIVERSITY, NAPLES, ITALY; (c) CARDIOLOGY DIVISION, ANTONIO CARDARELLI HOSPITAL, NAPLES, ITALY; (d) DEPARTMENT OF PUBLIC HEALTH, FEDERICO II UNIVERSITY, NAPLES, ITALY

Introduction. Kounis syndrome is an acute coronary syndrome associated with an anaphylactic reaction. It can be triggered by various environmental agents and drugs, including contrast medium, but is often underdiagnosed due to the overlapping symptoms between myocardial ischemia and allergic reactions. The underlying mechanism involves endothelial dysfunction caused by mast cell activation and the release of inflammatory cytokines, which play a significant role in inducing coronary vasospasm. Acute multivessel coronary spasm is also amongst the vascular pathophysiological hypotheses of Takotsubo syndrome (TTS), which is a stress-induced cardiomyopathy, that include amongst its triggering events physical stress, including medical conditions and procedures. Therefore, these syndromes could co-exist in the same patient or even the anaphylactic reaction leading to Kounis syndrome, or its own treatment, could favor a TTS.
Case report. We present the case of a 63-year-old woman hospitalized for pancreatitis. After the administration of contrast medium for a computed tomography scan, she developed an allergic reaction progressively worsening up to anaphylactic shock. She was suddenly treated with endovenous adrenaline reaching hemodynamic stability. However, due

to the persistence of dyspnea and chest discomfort, a 12-lead ECG was performed and showed a new onset left bundle branch block. On physical examination she was diaphoretic and dyspneic. Vital signs were collected. Bedside 2D echocardiography showed a severe reduction in systolic function, with symmetrical regional abnormalities involving the mid-ventricular segments of the anterior, inferior, and lateral walls; offline global longitudinal strain was -9.3% with mainly apex involvement. Dual antiplatelet therapy was then promptly started, and a primary percutaneous coronary intervention was performed, showing a chronic occlusion of the right coronary artery without any significant stenosis on the left anterior descendant and circumflex coronary arteries. Left heart ventriculography showed apical and mid-wall hypokinesis. Since the patient presented with both ischemic and soon earlier anaphylactic symptoms, several laboratory tests were performed: small rise in serum troponin and elevated serum cardiac natriuretic peptides along with rise in serum tryptase, histamine, eosinophils, immunoglobulin E, cardiac enzymes were found. In absence of a culprit lesion on left anterior descendant coronary, considering results from blood and instrumental exams, a TTS was therefore hypothesized. However, considering the elevated levels of immunoglobulins E and histamine, the diagnosis of an acute allergic coronary syndrome (Kounis syndrome) was also highly suspected. After allergic reaction has been controlled, the patient was also treated with intravenous Furosemide and Levosimendan to support hemodynamics, resulting in an improvement of clinical symptoms. The patient was discharged after 12 days with diagnosis of TTS, although it was no possible to exclude a Kounis syndrome.
Conclusions. Diagnosis and treatment Kounis syndrome is a clinical challenge due to the overlapping of allergic and myocardial ischemia pathophysiologic mechanisms. Sometimes, TTS, secondary to medical conditions (allergic reaction) or procedures (catecholamine administration), could also be underdiagnosed. Timely patient - tailored therapeutic interventions should be implemented to prevent and treat life threatening complications.

A474: A RARE CASE OF ACUTE MEDIASTINITIS WITH CARDIAC INVOLVEMENT MIMICKING ACUTE CORONARY SYNDROME WITH ST ELEVATION (ACS-STE)

Maria Cristina Carella (a), Daniele De Feo (a), Paolo Basile (a), Eugenio Carulli (b), Nicola Bozza (b), Marco Gentile (a), Tiziana Cappelluti (a), Cinzia Forleo (a), Marco Matteo Ciccone (a), Andrea Igoren Guaricci (a)
(a) U.O.C. CARDIOLOGIA UNIVERSITARIA - A.O.U.C. POLICLINICO DI BARI; (b) U.O.C. CARDIOLOGIA E UTIC - P.O. MADONNA DELLE GRAZIE - MATERA

Introduction. Acute infectious mediastinitis represents a rare inflammation of the mediastinum associated with high mortality in absence of a prompt diagnosis and treatment. Cardiac involvement may occur due to the contiguity of these structures. However, ECG changes simulating an acute coronary syndrome with ST segment elevation (ACS-STE) were never reported during this life-threatening disease.
Case presentation. We report the case of a 73-year-old patient found confused, dyspneic, with sphincter release and fever by family members. On arrival of the ambulance the ECG, immediately performed, showed a ST-segment elevation in the inferior and lateral leads, with a diagnosis of ACS-STE, requiring the activation of the local STEMI network. The urgent coronary angiography, performed in our hospital, revealed the absence of critical coronary stenosis. Molecular swab for Sars-Cov2 was negative. Echocardiography displayed a normal systolic function without regional wall motion abnormalities of the left ventricle and a mild pericardial effusion. A mild increase of troponins and a marked elevation of C-reactive protein was pointed out. A chest computed tomography (CT) was performed to rule out pulmonary embolism, given the presence of hypocapnic hypoxaemia on haemogasanalysis. A severe radiologic picture of the lung compatible with acute respiratory distress syndrome (ARDS) was observed, with the presence of inhomogeneous areas in the mediastinum, leading to the suspicion of mediastinitis. Subsequently, a CT scan of the neck and an ENT consultation confirmed the diagnosis, although the source of infection was not identified. The patient was admitted to our Intensive Care Unit due to a sudden deterioration of the respiratory function, requiring orotracheal intubation and invasive mechanical ventilation. Empirical antibiotic therapy was started while awaiting the results of bronchoaspiration and blood cultures. In the following days an unexpected improvement of the clinical conditions of the patient was observed.
Discussion. To the best of our knowledge, this is the first case of acute infectious mediastinitis presenting with ACS-STE. A myopericarditis may explain the ECG changes, caused by the dissemination of the inflammatory process from the mediastinum to the heart. As previously reported in literature, the presence of pneumomediastinum and hematomas at this level as well as infiltrating tumors such as thymoma, lymphoma and lung tumors can induce ACS-STE, due to the extrinsic compression of coronary arteries. Post-sternotomy mediastinitis, related to a deep infection of the sternal wound, is one of the most worrying complications in case of cardiac surgery. It is associated with a low overall incidence but significant mortality rate. However, ECG changes that may mimic myocardial infarction have not been reported in literature. Also, mediastinitis arising from the oropharynx or oral cavity are associated with a very poor prognosis, despite all surgical and therapeutic precautions. To date, however, there are no cases described with ECG alterations suggesting myocardial infarction.
Conclusions. Acute infectious mediastinitis is a rare and life-threatening disease which may be complicated by cardiac involvement. ECG changes, related to the spread of the inflammation in the pericardium and myocardium, may mimic a SCA-STE, leading to the activation of the STEMI network, with a delay in the correct diagnosis and the proper therapeutic management.

A475: HAIR CORTISOL AND ECHOCARDIOGRAPHIC PARAMETERS IN CORONARY ARTERY DISEASE:PRELIMINARY DATA OF THE STESS-ACS-ACTION STUDY.

Giulia Magnani (a), Sara Bartoletti (b), Andrea Denegri (a), Filippo Luca Gurgoglione (a), Domenico Tuttolomondo (a), Manjola Noni (a), Federico Barocelli (a), Elia Indrigo (b), Chiara Maccari (b), Paolo Ossola (b), Carlo Marchesi (b), Massimo Corradi (b), Roberta Andreoli (b), Diego Ardissino (b), Giampaolo Niccoli (b)
(a) AZIENDA OSPEDALIERO-UNIVERSITARIA DI PARMA; (b) UNIVERSITÀ DI PARMA

Background. Despite the reduction in the mortality rate in recent years, due to improvement in secondary preventive strategies, patients with acute coronary syndrome (ACS) still present a significant risk of recurrent ischemic events and heart failure (HF). Recent evidences indicate chronic mental stress as an emerging new CV risk factor. Hair cortisol (HC) is emerging as a new biomarker of exposure to chronic stress. We investigated therefore if HC concentrations are related to a worse CV phenotype and adverse cardiac remodeling.
Methods. Patients hospitalized for ACS or outpatients with CV risk factors (CVrF) were recruited for the present study at the Cardiology Unit of Parma University Hospital. Blood, urine and hair samples were collected from each patient, together with anamnestic data, laboratory data and echocardiographic parameters related to cardiac geometry. A regression analysis was performed to assess the relationships between significant variables at univariate analysis. Parameters of LV geometry, such as relative wall thickness (RWT) and left ventricular mass index (LVMi) were measured by echocardiography at the Echocardiography Lab of the Cardiology Unit and analyzed by cut-off of HC.
Results. In the overall population the mean concentration of HC was 7.4 ± 13.8 pg/mg. Among patients presenting with ACS, and particularly with ST-elevation myocardial infarction (STEMI), the mean HC concentrations were higher compered to patients with CVrF (STEMI: 8.8 pg/mg; NSTEMI: 5.3 pg/mg; CVrF: 5.9 pg/mg). In the overall population, patients with higher HC levels were younger and presented a higher prevalence of CVrF (familiarity for CAD (60.0% vs. 40.7%),hypertension (70.0% vs. 63.0%), diabetes (40.0% vs. 16.7%), dyslipidemia (60.0% vs.47.4%), smoking habit (70.0% vs. 48.1%), as well as higher levels of inflammation markers, such as C-reactive protein (CRP) (45.7 mg/L vs. 28.4 33.2 mg/L). The mean levels of HC were 2-times higher in patients with RWT ≥0.42 (10.7 pg/mg) compared to patients with RWT <0.42 (4.3 2.9 pg/mg). Similarly mean levels of HC were higher in patients with LVEF <50% compared to patients with LVEF ≥50% (5.7 pg/mg vs. 9.4 pg/mg). In patients with LVMi ≤115 g/m2 the mean levels of HC were lower compared to patients with LVMi>115 g/m 2 (5.3 pg/mg vs. 9.3 pg/mg).
Conclusions. HC levels, expression of chronic mental stress, are higher in patients with STEMI compared to patients with NSTEMI and CVrF only. Higher levels of HC characterize a worse CV phenotype and are associated with a concentric cardiac remodeling. HC may therefore be a useful biomarker to identify those patients that may benefit for implementation of preventive measures, including management strategies to target mental stress.

A476: FATTORI PREDITTIVI DI WORSE OUTCOME IN PAZIENTI AFFETTI DA INFARTO MIOCARDICO IN ASSENZA DI OSTRUZIONE CORONARICA (MINOCA)

Laura Garatti (a), Giuseppe Esposito (a, b)
(a) OSPEDALE NIGUARDA CA' GRANDA; (b) DEPT. OF ADVANCED BIOMEDICAL SCIENCES, UNIVERSITY FEDERICO II, NAPLES, ITALY

Con il termine MINOCA (myocardial infarction with non obstructive coronary arteries o infarto miocardico senza ostruzione coronarica significativa) si intende un danno miocardico acuto compatibile con la definizione universale di infarto miocardico in assenza di lesioni coronariche significative all'esame angiografico. La prevalenza è variabile e va dall'1% al 14% dei pazienti affetti da sindrome coronarica acuta (SCA). La prognosi è dipendente dalla causa sottostante e a differenza di quanto si pensasse in passato, non è benigna, ma è caratterizzata da tassi di mortalità e morbilità di poco inferiori all'infarto miocardico con stenosi angiograficamente significative. Identificare i fattori predittivi di peggior outcome è pertanto importante. Sono stati arruolati dal 2014 al 2022, in uno studio retrospettivo, pazienti con diagnosi di MINOCA (n=54), ricoverati presso l'UNITÀ di Cure Intensive Cardiologiche (UCIC) dell'Ospedale Niguarda Ca' Granda di Milano. È stato eseguito un follow up ad 1 e 3 anni dopo la dimissione. L'endopoint composito primario era

definito da morte per tutte le cause, morte per cause cardiovascolari, reSCA e stroke. L'età media della popolazione era di 57,5 anni ed il 53,7% dei pazienti era di sesso femminile. Il verificarsi dell'endpoint composito primario è stato del 46,2%. L'analisi statistica ha evidenziato variabili a posteriori che si sono mostrate prognostiche in termini di worse outcome. In particolare, la PCR (p=0,048) dal punto di vista laboratoristico, mentre, ad un anno di follow up, l'ipertensione arteriosa (p=0,016) e la fibrillazione atriale (p=0,020) nel contesto di una frazione di eiezione (FE) conservata. Dunque, questi ultimi fattori, potrebbero essere predittivi di fenotipi affetti da MINOCA con evoluzione verso uno scompenso cardiaco a frazione di eiezione preservata (HFpEF)?

A477: INTRACORONARY LITHOTRIPSY IN PRIMARY PCI

Fulvio La Rocca (a), Ciro Mauro (a), Davide D´andrea (a),
Gerardo Carpinella (a), Fulvio Furbatto (a), Vittorio Taglialatela (a)
(a) AORN A. CARDARELLI

Razionale. Con l'allungamento dell'aspettativa di vita ed il progredire delle terapia di prevenzione e trattamento dei fattori di rischio cardiovascolare e dello scompenso cardiaco è in aumento la popolazione di ultraottantenni che vanno incontro a sindromi coronariche acute che necessitano del tempestivo trattamento percutaneo. In questa popolazione la patologia coronarica può assumere maggiore complessità.
Risoluzione tecnica. Il caso in questione si riferisce ad una donna, 93 anni, che accede presso la ns Emodinamica per STEMI anteriore. L'angiografia mostra una subocclusione trombotica di IVA, nel contesto di una severa patologia calcifica, indilatabile con palloni semicomplianti e non complianti di calibri crescenti. Solo il trattamento con litotrissia intracoronarica con catetere a palloncino Shockwave permette una corretta preparazione della lesione e il successivo ed efficace impianto di DES.
Implicazioni cliniche. Il decorso del ricovero è progredito in assenza di complicanze fino alla dimissione dopo 6 giorni dall'angioplastica primaria. Al follow up ad un mese si registra un miglioramento della funzione sistolica globale, FE 50%, con acinesia del segmento apicale anteriore e settale.
Prospettive. Il trattamento dell'infarto miocardico acuto non prevede nella stragrande maggioranza dei casi l'utilizzo di devices di debulking di lesioni calcifiche. In casi selezionati, in cui la patologia acuta si determina su un quadro di severa patologia cronica, può essere necessario l'utilizzo di questi sistemi, al fine di migliorare l'efficacia a lungo termine dell'angioplastica.

A478: COULD ANTIPLATELET THERAPY MESS UP YOUR OPTIMAL ANGIOGRAPHYC RESULT?

Daniel Cesarini (a), Iacopo Muraca (a), Enrico Marchi (a),
Matteo Pennesi (a), Angela Migliorini (a), Renato Valenti (a)
(a) AZIENDA OSPEDALIERA UNIVERSITARIA CAREGGI

A 57-year-old male patient with multiple cardiovascular risk factors, including hypertension, dyslipidemia, and a family history of coronary artery disease (CAD), presented to the emergency department with chest pain lasting over 12 h. Despite previous episodes of chest pain and dyspnea, his electrocardiogram (ECG) showed normal sinus rhythm with QS complexes in the inferior leads. High-sensitive serum troponin T (hs-TnT) levels did not indicate a significant delta in the serial blood tests. Echocardiography revealed akinesia of the basal-mid segment of the inferior wall and mildly decreased systolic function. The patient was transferred to the cath-lab where coronary angiography revealed occlusion due to massive thrombosis in the right coronary artery and stenosis in the left anterior descending artery. Percutaneous coronary intervention (PCI) was performed, successfully restoring blood flow in the right coronary artery and resolving the patient's symptoms. Medication administered during the procedure included unfractionated heparin, a cangrelor bolus plus continuous infusion, a ticagrelor bolus, and aspirin. On the first day after the procedure, the patient experienced a brief loss of consciousness. With continuous ECG monitoring, there was evidence of a sinoatrial block of more than 15 seconds followed by two more pauses of about 4 seconds each. Repeated echocardiography and coronary angiography showed no new abnormalities or periprocedural complications. Based on the duration of the pauses and the clinical presentation, pacemaker implantation was indicated according to current ESC guidelines. However, considering the possibility of ticagrelor-induced sinoatrial block, the patient was switched to prasugrel and closely monitored without undergoing pacemaker implantation. Further investigations, including carotid sinus massage and an electrophysiological study, did not reveal any significant abnormalities (AH interval 95 ms, HV interval 40 ms and correct sinus node recovery time: 220 ms). A loop recorder was implanted, which recorded no further episodes of sino-atrial block. In the following weeks, the patient continued therapy with aspirin and prasugrel, and no other side effects or events occurred.

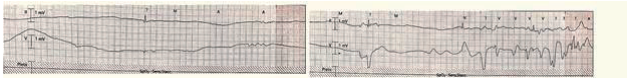

A479: LA RELAZIONE "COMPLICATA" TRA CUORE E CERVELLO, UN RARO CASO DI SINDROME TAKO TSUBO

Gianpaolo D´arco (a), Gisberta Chiorazzo (a), Antonio Aloia (a)
(a) UTIC OSPEDALE SAN LUCA VALLO DELLA LUCANIA (SA)

La cardiomiopatia Tako-tsubo (TTC) è una disfunzione miocardica transitoria che colpisce principalmente il ventricolo sinistro, mimando una sindrome coronarica acuta. Questa condizione può essere scatenata da eventi stressanti psicologici/fisici o da una serie di condizioni mediche tra cui le convulsioni e/o lo stato epilettico (SE). L'evoluzione è per lo più favorevole, ma a volte la TTC può evolvere in condizioni potenzialmente letali. Donna, 63 anni, giunge in PS per crisi epilettiche subentranti. In anamnesi sclerosi multipla ed epilessia già in trattamento farmacologico con Acido valproico/sodio valproato.Non patologie cardiovascolari. In urgenza trattata con benzodiazepine e sottoposta ad esami ematochimici ECG e TAC cranio. All'ECG si presenta tachicardia sinusale a frequenza ventricolare media di 129 bpm con onde T negative in in sede infero laterale e da V3 a V6. Agli esami ematochimici lieve rialzo della Troponina ad alta sensibilità (THs) (126 pg/dl) e normale funzionalità renale (egfr 89 ml/min). Alla TAC Encefalo: Moderata accentuazione della sostanza bianca in sede peri-ventricolare in assenza di ulteriori variazioni sensitometriche del tessuto cerebrale. Viene inviata in consulenza cardiilogica dove all'ecoscopia in urgenza si rileva: dilatazione del ventricolo sinistro con acinesia dei segmenti medio apicali e funzione sistolica severamente depressa. Per tale ragione la paziente viene ricoverata in Utic e sottoposta a studio coronarografico in urgenza che vede: coronarie indenni da lesioni angiograficamente evidenti e acinesia dell'apice cardiaco alla ventricolografia. Durante a degenza viene eseguito un elettroencefalogramma e una consulenza neurologica che conferma la diagnosi di male epilettico in fase subacuta. Per tale ragione viene reimpostata la terapia medica antiepilettica e cardiologica e alla dimissione impostato uno stretto follow up cardiologico e della terapia medica. La TTC predispone i pazienti a eventi cardioembolici, shock cardiogeno, insufficienza cardiaca, aritmia, rottura della parete ventricolare e morte improvvisa. La mortalità acuta di questa condizione è fino all'8%. La TTC dopo le crisi è stata sospettata come causa di morte improvvisa inspiegabile nell'epilessia (SUDEP) in alcuni studi osservazionali. Al momento dell'autopsia della SUDEP si riscontrano anomalie cardiache fino al 33% dei pazienti con risultati istopatologici simili alla malattia miocardica indotta da catecolamine.

A480: MINOCA: ALLA RICERCA DI UN COLPEVOLE. STORIA DI UN ARRESTO CARDIACO

Luca Renzi (a), Alessandro Novelli (a), Alessandro Di Francesco (a),
Saverio Muscoli (a), Marina Vellini (a), Luciano Emidio Di Battista (a),
Cinzia Razzini (a), Francesco Barillà (a)
(a) UNIVERSITÀ DEGLI STUDI DI ROMA TOR VERGATA

Background. L'arresto cardiaco viene definito come un'improvvisa cessazione dell'attività cardiaca tale per cui si assiste ad una compromissione elettrica e meccanica del muscolo, in assenza di segni di attività respiratoria. L'incidenza media annuale di arresto cardiaco extra-ospedaliero nei paesi europei, varia dai 47.8 ai 57.9 casi per 100.000 abitanti corrispondenti a 343.496 casi annuali.
Caso clinico. Paziente maschio di 58 anni, forte fumatore, dislipidemico, con storia di potus; presenta un arresto cardiocircolatorio extraospedaliero trattato con 10 DC shock su FV e con una RCP di circa 50 minuti. All'arrivo in PS si procedeva a IOT, l'ECG documentava ritmo sinusale con alterazioni diffuse del tratto ST-T e la Tpn Hs era di 18.485 ng/L. Veniva eseguita coronarografia documentante albero coronarico ateromasico in assenza di stenosi angiograficamente significative, successivamentesi presentava TVNS e sopraslivellamento del tratto ST-T in sede inferiore. Veniva successivamente estubato e trattato con cicli di NIV per episodi di EPA. All'ecocardiogramma c/D era presente una FE ai limiti inferiori con acinesia setto-apicale, pattern diastolico restrittivo e assenza di valvulopatie di rilievo. Dopo una settimana, per il persistere di sopraslivellamento transitorio del tratto ST documentati al tracciato elettrocardiografico si impostava, nel sospetto di vasospasmo coronarico, terapia con Diltiazem e Nitrati con beneficio clinico. Veniva eseguita la RM cardiaca che escludeva la presenza di aree di LGE ed evidenziava cardiomiopatia restrittiva con preservata funzione biventricolare. Veniva infine dimesso dopo impianto di ICD bicamerale in prevenzione secondaria.
Discussione. Il MINOCA è una condizione che comprende un ampio spettro di sindromi cliniche, rappresenta spesso una sfida dal punto di vista diagnostico-terapeutico. È dimostrato come il vasospasmo coronarico possa giocare un ruolo e, sebbene la sua patogenesi rimanga di natura multifattoriale, l'abuso di alcolici può essere annoverato tra i fattori precipitanti. Un ruolo preponderante sembra essere dato dalla riduzione della sintesi di NO e la conseguente inibizione del rilascio di calcio dal reticolo sarcoplasmatico. Altri possibili pathway includono la riduzione della prostaciclina (PGI2) e l'aumento dell'espressione di endoteli-

na. Nel nostro caso clinico l'ipotesi della disfunzione endoteliale si pone come un epifenomeno subentrante al rilievo strumentale, evidenziato mediante RM cardiaca, di una cardiomiopatia restrittiva. È ipotizzabile che l'arresto cardiaco in questo paziente riconosca diversi meccanismi causali, da una parte il substrato strutturale e dall'altra l'evento ischemico. Il miglioramento del quadro clinico-strumentale conseguente ad introduzione di nitroderivato e Calcio antagonista suggerisce l'eziologia vasospastica. L'impianto di ICD in prevenzione secondaria assume un ruolo fondamentale in questo paziente anche alla luce della documentata cardiopatia strutturale.

A481: INTRAMYOCARDIAL DISSECTING HEMATOMA SECONDARY TO SUBACUTE ANTERIOR MYOCARDIAL INFARCTION: A CASE REPORT

Mariagrazia Piscione (a), Dajana Polito (a), Lorenzo Frau (a), Gian Paolo Ussia (a), Francesco Grigioni (a)
(a) FONDAZIONE POLICLINICO UNIVERSITARIO CAMPUS BIOMEDICO

A patient of 78 years old was admitted to the Emergency Department of our Hospital for chest pain and progressive dyspnea. He reported that, a month before, he had gone to his Cardiologist for persistent angina and the electrocardiogram had documented: "-ST elevation as anterior myocardial infarction". He had decided not to go to the hospital. Because of the anginal symptoms and the demonstration of a vitality area at the myocardial scintigraphy, he underwent coronary angiography which demonstrated: trivessels coronary artery disease with chronic occlusion of the anterior descending artery which was treated with the implantation of two drug eluting stents on circumflex artery and a single drug eluting stent on the anterior descending artery. The pre-discharge echocardiogram showed: aneurysmal dilatation of the apex with the presence of a voluminous thrombotic formation (wall hematoma?). To better identify this evidence, cardio-RMN was performed which described a partially thrombosed intramural hematoma (IH). In consideration of the clinical features and the high operative risk, there was no cardiac surgery indication. The day after, the patient presented a speech production disorder, dysarthria and oral rhyme deviation so that a brain computed tomography (CT) and supra-aortic trunks color Doppler were required. The angio-CT of the brain demonstrated absence of tomodensitometric lesions of recent onset affecting the brain tissues. At the level of the left carotid bifurcation, there was evidence of an eccentric fibrolipidic plaque which caused sub-occlusive stenosis of the origin of the internal carotid artery (ICA) (80%). The neurological videat classified the ischemic event as high-risk transient ischemic attack in a patient with sub-occlusive stenosis of the left ICA but because of the high operative risk, surgery ICA was not suggested. To conclude, intramyocardial dissecting hematoma is a life-threatening complication of a myocardial infarction. It is due to hemorrhagic dissection of spiral myocardial fibers causing blood dripping within the myocardium. Mechanisms of formation of it consist of the increase of pressure in capillaries and the rupture of vessels into the media. The Occluded Artery Trial shows that late PCI to open the occluded infarction-related artery does not improve composite endpoints of death, rehospitalization for heart failure, or myocardial infarction. Nevertheless, there are possible mechanisms by which reopening an infarction- related artery may confer benefit: first of all, time to initiate the formation of the scar depends on an early inflammatory response so that blood influx in the ischemic area may improve myocardial healing and prevent myocardial remodeling. Secondly, an open, blood filled artery may help to maintain the structural integrity of the necrotic myocardium and limit the expansion of the infarction. Moreover, late riperfusion elicits intra myocardial hemorrhage, oedema and contraction band necrosis, within which sarcolemmal tubes persist and prevent collapse of the necrotic tissue, collagen turnover is more pronounced in patient with an occluded infarction-related area and thus prevention of interstitial collagen turnover may be another beneficial effect. The discharge therapy consisted of medical treatment with double antiaggregant therapy instead of anticoagulation to defend the thrombus stability.

A482: EFFECT OF DRUG ADDICTION ON CARDIOVASCULAR SYSTEM: A DANGER HOST FOR HEART

Mariateresa Pontoriero (a), Daniele Paoletta (a), Martina Pucci (a), Marina Iacono (a), Adelaide Iervolino (a), Luca Maria Capece (a), Roberta Esposito (a)
(a) DEPARTMENT OF CLINICAL MEDICINE AND SURGERY, FEDERICO II UNIVERSITY HOSPITAL, NAPLES

Introduction. In recent years the use of narcotic substances, one of which is cocaine, especially between the ages of 18-45, has led to an increase in the incidence of cardiovascular diseases. Cocaine is a troponic alkaloid compound, whose cardiac-related complications include acute conditions such as arrhythmia and acute myocardial infarction (MI) and chronic conditions such as cardiomyopathy and coronary artery disease (CAD). Cocaine-induced cardiotoxicity can cause sudden death. Cocaine is a powerful sympathomimetic agent as it stimulates the sympathetic nervous system and inhibits the reuptake of norepinephrine, dopamine and serotonin, interacting with each transporter; It also blocks sodium and potassium channels, inducing abnormal and depressed cardiovascular profiles. Cocaine, therefore, can cause cardiovascular conditions, exacerbate pre-existing cardiovascular conditions and can negatively influence the patient's therapy, compliance and cardiovascular management strategy.
Clinical case. A 42-year-old patient came to our observation for chronic ischemic heart disease (two myocardial infarctions, one treated in 2020 with PTCA and stening on IVA, the other treated in 2021 with PTCA and stening on Cdx) of which in the second event, following the rupture of the papillary muscle and the onset of severe mitral insufficiency, the mitral valve was replaced with mechanical valve. After two years he had a third myocardial infarction, and consequentely a defibrillator implant. In medical history the patient had arterial hypertension, type II diabetes mellitus, mixed dyslipidemia. Due to the occlusion of the left femoral artery, a stent was placed. Reviewing the patient's medical history, he reported abuse of narcotic substances, particularly cocaine. Furthermore, the patient had aortic valve degeneration causing a moderate degree of aortic stenosis. The transthoracic echocardiogram showed, in fact, segmental dyskinesias, reduced systolic function of the left ventricle (EF 30%), diastolic dysfunction of at least II degree with increased filling pressures associated with mild left atrial dilatation (40 ml/m^2). The aortic valve showed steno-insufficiency with prevalent moderate degree stenosis of low flow-low gradient type (AVAI 0.6 cm2/m2, AVA plan 1.3 cm2) and mild degree insufficiency. The therapy carried out involved the use of double antiaggregation, angiotensin receptor inhibitor and neprilysin inhibitor (with an increasing dosage till the maximum, with a stable EF 35%), hypoglycemic agents including a glyphozine, in addition, therapy with beta blocker, loop diuretic and anticoagulant (TAO).
Conclusions. It is known that cocaine abuse causes various complications involving different organs, but is mainly associated with adverse cardiovascular effects. Cocaine, being a powerful cardiovascular stimulant, has been associated with electrocardiographic anomalies, arrhythmias, valve damage, acute myocardial infarction, hypertension. Studies in the literature have documented the increased cardiovascular risk in subjects who abuse cocaine and show the importance of better education on drug use problems and the effects they have on the cardiovascular system. The deleterious effects that cocaine has on the cardiac system should raise awareness among those who use it and the timeliness and early management of symptoms should limit adverse events.

A483: LA SINDROME DI TAKOTSUBO: TUTTO CIÒ CHE NON SAPPIAMO SULLA "NOTA" SINDROME DEL CUORE INFRANTO.

Maria Letizia Berloni (a), Silvia Zagnoni (a), Francesca Sciarra (a), Gianni Casella (a)
(a) OSPEDALE MAGGIORE CARLO ALBERTO PIZZARDI

La sindrome di Takotsubo si associa ad un tasso di ricorrenza pari all'1.5%-4% dei casi l'anno e sono scarsi i dati circa eventuali fattori predisponenti o protettivi. Dai dati disponibili emerge un più basso tasso di ricorrenza nei pazienti dimessi con terapia a base di ACEi o sartani mentre i beta bloccanti non sembrerebbero avere influenza sul tasso di recidiva della sindrome. Presentiamo il caso di una donna, 81 anni, con storia di pregressa sindrome di Takotsubo sviluppata durante ricovero per frattura di femore e dimessa in terapia con ACEi e Bisoprololo a bassa dose, ancora in corso al momento del nuovo ricovero, e con un parziale recupero della funzione sistolica globale del ventricolo sinistro alle visite di controllo. La paziente accedeva nuovamente in PS dopo circa due anni dal precedente episodio per dolori addominali diffusi e cefalea persistente da alcuni giorni; all'arrivo emergeva un quadro di edema polmonare acuto con severo impegno interstiziale alla TC, valori pressori140/80 mmHg e severa lattacidemia (Lac 7.9 mmol/L). All'ECG evidenza di tachicardia sinusale, BBSn incompleto, alterazioni secondarie della ripolarizzazione ventricolare; agli esami di laboratorio si evidenziava un movimento troponinico significativo 123 ng/L ->1094 ng/L (0h – 3h). Veniva eseguito un ecocardiogramma transtoracico che evidenziava un'acinesia setto-apice e dell'apice in toto, con severa riduzione della frazione di eiezione del ventricolo sinistro (FE 30%), senza evidente ostruzione dinamica all'LVOT, in assenza di significativa valvulopatia mitralica, PAPs nei limiti. In UTIC, valutata l'assenza di segni di ostruzione dinamica, veniva impostata terapia con nitrati endovena per favorire l'unloading del ventricolo sinistro e venivano impostati supporto ventilatorio (NIV) e terapia diuretica. Nel sospetto di sindrome di Takotsubo veniva eseguito uno studio coronarografico che confermava la presenza di stenosi moderata dell'IVA (invariata rispetto alla precedente coronarografia), e alla ventricolografia si evidenziava un'ipocinesia diffusa con ipercinesia dei segmenti basali (aspetto apical ballooning) in contesto di severissima riduzione della funzione sistolica globale; il quadro emerso confermava il sospetto di recidiva di Takotsubo. Nei giorni successivi di degenza si assisteva ad un progressivo miglioramento del quadro emodinamico e ad un'evoluzione ECG con comparsa di onde T negative giganti in sede laterale con allungamento del QTc. Per il quadro di epigastralgia veniva eseguita un'ecografia addome e una TC addome che evidenziavano un quadro di ileo paralitico con concomitante sofferenza ischemica intestinale, attribuiti al quadro di bassa portata. La paziente e i familiari riferivano all'ingresso la persistenza di una invalidante cefalea i giorni precedenti il ricovero, che è stata ritenuta essere il trigger stressogeno alla base della recidiva di Takotsubo.

Conclusioni. I meccanismi fisiopatologici alla base della sindrome di Takotsubo sono ancora oggi ignoti, così come sconosciuti sono i fattori predisponenti o protettivi alla base delle recidive; i dati a disposizione non sono sufficienti a risolvere i nostri interrogativi. Nel caso presentato due trigger diversi hanno contribuito a scatenare i due eventi, e una terapia a base di ACEi e Betabloccanti non ha avuto effetto nel prevenire la ricorrenza dell'evento. Alcuni registri hanno provato a dare delle risposte a questi quesiti, rendendo ancora più chiara la necessità di ulteriori studi randomizzati multicentrici per conoscere meglio la "nota" sindrome del cuore infranto.

A484: NON È MAI TROPPO TARDI: ARRESTO CARDIACO IN CORONARIA UNICA IN ETÀ ADULTA.

Manuel Bosco (a), Martina Solli (b), Anna Degiovanni (b), Giuseppe Patti (a)
(a) UNIVERSITÀ PIEMONTE ORIENTALE; (b) AOU MAGGIORE DELLA CARITÀ

Introduzione. Le coronarie con origine anomala dal seno di Valsalva non consueto sono un riscontro sempre più frequente grazie alle metodiche di imaging cardiaco. Nonostante alcune tipologie di anomalie coronariche siano benigne, studi autoptici evidenziano un'associazione tra rischio di morte cardiaca improvvisa e decorso coronarico interarterioso. Nonostante gli sforzi per identificare i pazienti a rischio, restano ancora dibattuti la classificazione, la prevalenza, la stratificazione del rischio e la gestione terapeutica.

Descrizione del caso. Donna, 64 anni, sovrappeso e con familiarità per cardiopatia ischemica, senza precedenti cardiologici. Ad Agosto 2023 viene ricoverata in seguito ad arresto cardiocircolatorio da fibrillazione ventricolare trattata con defibrillazione, intubazione orotracheale, Adrenalina ed Amiodarone. Dopo ripresa del ritmo, si evidenziava un quadro di infarto miocardico acuto con sopraslivellamento del tratto ST in sede infero-posteriore e severa disfunzione ventricolare sinistra con acinesia infero-posteriore e setto-apicale. La paziente veniva quindi sottoposta a coronarografia urgente che mostrava origine unica della coronaria destra e coronaria sinistra dal seno di Valsalva destro; si riscontrava inoltre stenosi critica del tronco comune pre-divisionale e occlusione di ramo posterolaterale, verosimilmente da spasmo, vista la ricanalizzazione dopo somministrazione di Nitrato intracoronarico. Il ramo posterolaterale mostrava ateormasia moderata, in assenza di stenosi critiche e con un flusso TIMI 3, motivo per cui si terminava la procedura. Nei giorni successivi la paziente, emodinamicamente ed elettricamente stabile, dopo parziale recupero della funzione ventricolare sinistra, veniva sottoposta ad angioTC coronarica che mostrava decorso del tronco comune posteriormente al bulbo aortico, con calibro ridotto in prossimità di quest'ultimo e normale opacizzazione di tutte le diramazioni coronariche. Dopo discussione collegiale, in considerazione delle difficoltà tecniche dell'approccio percutaneo, si optava per trattamento chirurgico. Alla luce del decorso della coronaria sinistra evidenziato all'angioTC, si sottoponeva la paziente ad intervento di duplice bypass arterioso con discendente anteriore e ramo posterolaterale.

Discussione. Il caso presentato mostra che, come già noto in letteratura, i casi di anomalia coronarica con origine aortica debbano essere approcciati in modo olistico, tenendo in considerazione età del paziente, quadro di presentazione e decorso coronarico. Ad oggi, la gestione di questi pazienti rimane complessa. Per quanto concerne la cardiologia interventistica, l'imaging intracoronarico e i test funzionali potrebbero rivestire un ruolo determinante per la scelta terapeutica in questa tipologia di pazienti.

A485: INCLISIRAN AFTER PCSK9 MONOCLONAL ANTIBODY THERAPY: AN UNEXPECTED SWITCH

Laura Torlai Triglia (a), Marco Covani (b), Gabriella Dallaglio (b), Lorena Malpeli (c), Tonino Fabbricatore (c), Filippo Luca Gurgoglione (b), Angela Guidorossi (c), Michele Bianconcini (c), Giampaolo Niccoli (b)
(a) UNIVERSITÀ DEGLI STUDI DI MODENA E REGGIO EMILIA; (b) UNIVERSITÀ DEGLI STUDI DI PARMA; (c) CARDIOLOGIA AZIENDA OSPEDALIERO UNIVERSITARIA DI PARMA

Background. Proprotein convertase subtilisin kexin 9 (PCSK9) inhibitors are a potent new class of lipid-lowering drugs that allow for a consistent reduction of low density lipoprotein cholesterol (LDL-c) levels. While two PCSK9 monoclonal antibody (MoAb) are broadly used in clinical practice, Inclisiran, is a promising first-in-class small interfering ribonucleic acid (siRNA) targeting the hepatic synthesis of PCSK9. Real world data on its lipid-lowering effect as well as solid evidence on cardiovascular outcomes are still unclear. In particular, only few data are available on the switching from PCSK9 MoAb to the siRNA.

Methods. We report data on three patients who switched from PCSK9 MoAb (median treatment of 12 months) to Inclisiran therapy, due to patients' preference or ineffectiveness of the previous lipid-lowering treatment. LDL-cholesterol levels were assessed at baseline and after 3 months from the first injection of Inclisiran.

Results. Patients (65, 67 and 70 years old) were enrolled between February 2023 and April 2023. One was female. Two patients were receiving lipid lowering therapy for primary prevention, a third for secondary prevention. Two patients were receiving only PCSK9 MoAb before switching to Inclisiran, one was receiving ezetimibe that was stopped after the change. For the first patient, LDL-c levels were 48 mg/dl at baseline and 72 mg/dl after 3 months of Inclisiran therapy, resulting in a 50% increase; for the second, LDL-c was 64mg/dl at baseline and 102 mg/dl at 3 months (+59%); and for the last patient, 227mg/dl at baseline and 220mg/dl after 3 months (-3%) (Figure).

Conclusions. Inclisiran is a novel PCSK9 inhibitor, especially relevant for its specific mechanism of action and favorable twice yearly administration. High inter-individual variability and unusual response to the drug have been reported, particularly after switching from PCSK9 MoAb. Our patients on PCSK9 MoAb experienced no effect or even an increase in LDL-c after switching to Inclisiran monotherapy. More data are needed to confirm the lipid-lowering potential of Inclisiran without background hypolipidaemic therapy.

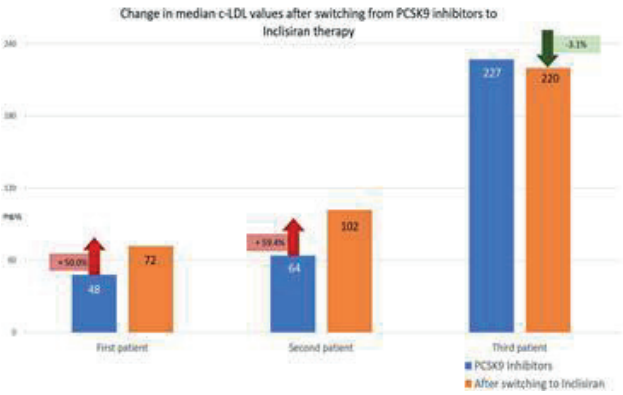

A486: GLP-1 ANALOGUES AND RESIDUAL CARDIOVASCULAR RISK REDUCTION: A FOCUS ON EPICARDIAL ADIPOSE TISSUE

Fulvio Cacciapuoti (a), Ciro Mauro (a), Davide D'Andrea (a), Valentina Capone (a), Federico Cacciapuoti (b)
(a) DEPARTMENT OF CARDIOLOGY "A. CARDARELLI" HOSPITAL - NAPLES, ITALY; (b) CHAIR OF INTERNAL MEDICINE "L. VANVITELLI" UNIVERSITY - NAPLES, ITALY

The management of residual cardiovascular risk remains a crucial aspect in patients with chronic coronary syndrome undergoing revascularization. Despite advances in managing major risk factors, the recurrence of coronary events and atherosclerotic disease progression indicate suboptimal control of cardiovascular risk. Recent research has focused on epicardial adipose tissue (EAT) as a contributor to persistent high cardiovascular risk, particularly coronary risk. Traditionally viewed as a passive energy reserve, EAT is now recognized as an active endocrine organ secreting various molecules that can influence nearby cardiac structures and promote atherosclerosis. Obesity, especially visceral obesity, is a major cardiovascular risk factor linked to conditions like dyslipidemia, type 2 diabetes, hypertension, heart failure, and ischemic heart disease. Advanced imaging techniques enable precise assessment of visceral fat deposits, including EAT, which has emerged as an independent indicator of cardiovascular risk. Studies show that EAT, particularly in the pericoronary region (PCAT), is associated with early and frequent development of coronary atherosclerosis, independent of body mass index. EAT undergoes changes over time, shifting from thermogenic brown adipocytes in early life to pro-inflammatory macrophages later on. Presence of PCAT not only leads to lipid infiltration and volumetric enlargement of atherosclerotic lesions but also fosters a pro-inflammatory state due to increased cytokine and adipokine synthesis. This state, coupled with hyperglycemia, leads to endothelial damage and plaque destabilization. Research on animals has shown that surgical removal of EAT slows atherogenesis progression and reduces inflammatory response. Consequently, researchers are exploring EAT as a new therapeutic target to reduce residual cardiovascular risk in ischemic heart disease patients. Molecules like statins, sodium-glucose cotransporter-2 inhibitors (SGLT2i), and glucagon-like peptide-1 receptor agonists (GLP-1-RA) have demonstrated efficacy in reducing EAT volume. Liraglutide, a synthetic GLP-1 analogue, has been found to effectively and safely reduce visceral adipose tissue, including EAT, thus mitigating cardiometabolic risks in both diabetic and non-diabetic patients. The mechanisms by which Liraglutide affects EAT are not yet fully understood, but it may involve GLP-1 receptors in visceral adipose tissue. Moreover, Liraglutide's favorable effects on the inflammatory component of coronary plaque have been observed, likely due to modulation of pro-inflammatory signaling in macrophages. Ongoing studies, such as the SELECT study evaluating Semaglutide's cardiovascular effects, offer promising avenues to further understand the impact of GLP-1-RA on cardiovascular risk in patients with overweight or obesity and a history of cardiovascular disease.

A487: UNA SCARICA ELETTRICA "CORONARICA"

Luca Canovi (a), Gianluca Calogero Campo (a), Gabriele Guardigli (a)
(a) UNIVERSITÀ DEGLI STUDI DI FERRARA

Paziente di 79 anni affetto da cardiopatia ischemica cronica post-infartuale esordita nel 1993 con IMA anteriore trattato con fibrinolisi. Nel 2008 episodio di Arresto Cardio-Circolatorio (ACC) da Fibrillazione Ventricolare (FV) rianimato per cui eseguiva coronarografia con riscontro di severa coronaropatia trivasale trattata con triplice Bypass Aorto-Coronarico (BPAC) e contestuale aneurismectomia. Eseguito inoltre impianto di ICD in prevenzione secondaria. Nel 2017 per ripresa di angina ed evidenza di ischemia inducibile alla miocardioscintigrafia veniva ripeturo lo studio coronarografico con riscontro di quadro invariato e pervietà dei BPAC. All'ecocardiogramma riscontro di severa riduzione della Frazione di Eiezione (FE) per cui veniva eseguito upgrade a dispositivo di resincronizzazione cardiaca (CRT-D). All'ultimo ETT eseguito (Giugno 2023) evidenza di ventricolo sinistro dilatato con FE stimata 40%. In data 13 Settembre 2023 episodio sincopale con lieve trauma cranico per cui venivano allertati i soccorsi. In Pronto Soccorso all'interrogazione del dispositivo evidenza di tachiaritmia in finestra Fibrillazione Ventricolare (FV) trattata efficacemente dal dispositivo con erogazione di DC-shock. Seguiva ricovero in Terapia Intensiva Cardiologica con ottimizzazione della terapia medica e anti-aritmica. Il giorno successivo al monitoraggio telemetrico nuovo episodio di Tachicardia Ventricolare Polimorfa con efficace trattamento da parte del dispositivo con erogazione di DC-shock. Veniva quindi eseguito studio coronarografico con riscontro di severa malattia dell'asse Tronco Comune (TC) – Arteria Interventricolare Anteriore (IVA) a monte dell'innesto del graft e di ramo Postero-Laterale (PL) di Coronaria Destra (CDx). Veniva quindi eseguita efficace rivascolarizzazione percutanea con angioplastica e stenting medicato di TC-IVA e di PL, in assenza di complicanze. La restante degenza si svolgeva regolarmente in assenza di recidive aritmiche.

A488: CUORE VS CERVELLO

Gloria Anna Varotto (a), Baldassarre Maria Alonzo (a),
Roberta Montisci (a)
(a) AZIENDA OSPEDALIERA UNIVERSITARIA DI CAGLIARI - POLICLINICO DUILIO CASULA

Background. La terapia cardine dell'infarto miocardico con ST persistentemente sopralivellato (STEMI) è rappresentata dalla riperfusione miocardica da effettuarsi il più precocemente possibile, preferibilmente mediante angioplastica primaria ed impianto di stent medicato; ciò rende necessario l'impiego di farmaci anticoagulanti ed antiaggreganti come Eparina non frazionata, Acido acetilsalicilico ed inibitore di P2Y12. Tra quest'ultimi il Cangrelor rappresenta l'unico da poter somministrare per via endovenosa. Questi farmaci espongono ad un rischio emorragico, soprattutto i pazienti con trauma cranico per il reale rischio di emorragia intracranica che può essere fatale.
Case report. Uomo, 53 anni, forte fumatore, familiarità per patologie cardiovascolari: presenta arresto cardiocircolatorio sul luogo di lavoro con successiva caduta a terra e trauma cranico. Per tale motivo venivano allertati i soccorsi che all'arrivo sul posto iniziavano le manovre di rianimazione cardiopolmonare (RCP). Per riscontro di asistolia seguita da fibrillazione ventricolare (FV), venivano erogati 11 DC shock e somministrati Adrenalina e Amiodarone come da protocollo ALS, con ripristino del circolo. Al primo elettrocardiogramma (ECG) teletrasmesso al nostro presidio ospedaliero evidenza di ritmo sinusale con diffuso sottolivellamento del tratto ST; in pronto soccorso veniva ripetuto ECG con evidenza di STEMI in sede laterale e consensuali alterazioni della cinetica e frazione d'eiezione del 45% all'eco fast. Il paziente è stato sottoposto a intubazione oro-tracheale e coronarografia urgente: veniva riscontrata subocclusione all'ostio e nella porzione prossimale del secondo ramo diagonale dell'arteria discendente anteriore e ramo interventricolare posteriore con due stenosi non significative nel tratto medio e veniva eseguito trattamento con angioplastica primaria ed impianto di stent medicato sul ramo diagonale. Durante la procedura sono stati somministrati Acido acetilsalicilico, Eparina non frazionata e Cangrelor per via endovenosa. Veniva quindi eseguita TC capo per il noto trauma cranico che evidenziava la presenza di emorragia subaracnoidea dell'emisfero destro ed ematoma subdurale a livello fronto-temporo-parietale, con consensuale frattura del tavolato occipito-parietale ad estensione fino alle mastoidi. All'arrivo in UNITÀ di terapia intensiva cardiologica nuovo episodio di instabilità emodinamica con successiva insorgenza di FV alternata ad asistolia: praticata RCP con massaggio cardiaco esterno e DC shock inefficaci per cui, dopo circa 30 minuti, veniva dichiarato il decesso.
Conclusioni. Il caso clinico rende evidente ciò che da sempre è ben noto: se da un lato la terapia antiaggregante ed anticoagulante risulta essere fondamentale nella prevenzione dell'occlusione acuta di stent, dall'altro amplifica il rischio emorragico. La domanda che ci si pone è se, in caso di STEMI con trauma cranico ben documentato, si possa posticipare l'esecuzione della coronarografia alla TC cranio e, in caso di positività per lesioni emorragiche acute o fratture del tavolato osseo con rischio di sanguinamento, si possa considerare come primo obiettivo quello della prevenzione del sanguinamento intracranico e modificare la strategia riperfusiva riducendo al minimo l'utilizzo di anticoagulanti e antiaggreganti o posponendo la riapertura della coronaria.

CARDIOPATIE CONGENITE E MALATTIE DEL CIRCOLO POLMONARE

A489: EFFICACY OF SPECIFIC THERAPY IN PATIENTS WITH PULMONARY ARTERIAL HYPERTENSION ASSOCIATED WITH PORTAL HYPERTENSION, HIV OR BOTH

Francesco Cennerazzo (a), Daniele Guarino (a), Fabio Dardi (a),
Alberto Ballerini (a), Ilenia Magnani (a), Riccardo Bertozzi (a),
Federico Donato (a), Giulia Martini (a), Monica Salvi (a),
Alessandra Manes (a), Nazzareno Galiè (a), Massimiliano Palazzini (a)
(a) IRCCS AZIENDA OSPEDALIERO-UNIVERSITARIA DI BOLOGNA

Background. Pulmonary arterial hypertension (PAH) is a rare complication of both portal hypertension (Po-PAH) and HIV infection (HIV-PAH) and can occur in patients with both HIV infection and liver disease (HIV/Po-PAH). The use of the PAH-specific drug classes (prostanoids, endothelin-1 receptor antagonists [ERA] and phosphodiesterase-5 inhibitors [PDE5-i]) in these patients is largely justified by retrospective and observational case reports since, to date, there are no randomized clinical trials except for the PORTICO trial which demonstrated the efficacy of treatment with macitentan in patients with Po-PAH. The aim of the study was to evaluate the efficacy of PAH-specific drugs, both monotherapy and dual oral upfront therapy (ERA + PDE5i started within 1 month apart), in patients with Po-PAH, HIV/Po-PAH and HIV-PAH.
Methods. Between 1998 and 2023 we enrolled patients with Po-PAH, HIV-PAH and HIV/Po-PAH referred to our centre and undergoing monotherapy with prostanoid, ERA and PDE5-I or dual upfront oral therapy. The efficacy of the drugs was assessed by comparing clinical parameters (NYHA functional class), exercise capacity (six-minute walking test) and hemodynamic parameters at baseline and after a treatment period of 3-6 months. The data are expressed as mean and standard deviation and were compared with Student's t-test for paired data.
Results. 128 patients were enrolled (83 Po-PAH, 23 HIV/Po-PAH and 22 HIV-PAH). 20 patients were treated with ERA monotherapy, 90 with PDE5-I, 13 with prostanoids and 5 patients were treated with dual oral upfront therapy. Pre-post therapy comparisons are shown in the table below.
Conclusions. Prostanoids, ERAs and PDE5-Is, both in monotherapy and as dual upfront oral therapy, are associated with a significant improvement in functional class, exercise capacity and hemodynamic parameters. The effect of such drugs is similar to what is observed in patients suffering from other forms of PAH.

	Po-PAH (*n* = 83)			HIV/Po-PAH (*n* = 23)			HIV-PAH (*n* = 22)		
	Pre	Post	P-Value	Pre	Post	P-Value	Pre	Post	P-Value
WHO-FC III/IV (%)	46	22	< 0.001	30	5	< 0.001	45	27	< 0.001
6MWD (m)	423 (± 109)	477 (± 94)	< 0.001	518 (± 100)	570 (± 80)	< 0.001	432 (± 146)	485 (± 135)	0.004
RAP (mmHg)	8 (± 5)	7 (± 3)	0.057	6 (± 3)	5 (± 2)	0.216	10 (± 5)	8 (± 5)	0.075
PAPm (mmHg)	49 (± 11)	42 (± 11)	< 0.001	46 (± 11)	38 (± 9)	< 0.001	48 (± 13)	44 (± 13)	0.091
CI (l/min/m2)	3.1 (± 0.8)	3.8 (± 1.0)	< 0.001	3.1 (± 0.7)	3.8 (± 0.8)	< 0.001	2.4 (± 0.8)	2.9 (± 0.7)	0.013
PVR (WU)	7 (± 5)	5 (± 3)	< 0.001	8 (± 3)	5 (± 2)	< 0.001	9 (± 5)	7 (± 4)	0.004
SvO2 (%)	67.8 (± 10.1)	73.1 (± 7.3)	< 0.001	65.1 (± 11.2)	70.2 (± 6.3)	0.004	55.4 (± 9.8)	63.5 (± 9.8)	< 0.001

6MWD: 6 minutes walking test distance; CI: cardiac index; PAPm: mean pulmonary arterial pressure; PVR: pulmonary vascular resistance; RAP: right atrial pressure; SvO2: mixed venous oxygen saturation; WHO-FC: world health organization functional class; WU: Wood Units.

A490: IMPACT OF PARENTERAL PROSTANOIDS IN PULMONARY ARTERIAL HYPERTENSION: THE RELEVANCE OF TIMING

Silvia Papa (a), Gianmarco Scoccia (a), Giorgia Serino (a), Francesca Ileana Adamo (a), Jean Pierre Jabbour (a), Annalisa Caputo (a),
Michela Boromei (a), Domenico Filomena (a), Domenico Laviola (a),
Enrico Maggio (a), Giovanna Manzi (a), Alexandra Mihai (a),
Tommaso Recchioni (a), Alexandra Sabusco (b), Livia Valeri (a),
Sara Vinciullo (a), Carmine Dario Vizza (a), Roberto Badagliacca (a)
(a) SAPIENZA UNIVERSITY OF ROME; (b) UNIVERSITY OF EASTERN PIEDMONT, NOVARA

Parenteral prostanoids are being recommended in pulmonary arterial hypertension (PAH) treatment, but the prognostic relevance of delayed treatment initiation is still debated. This study assessed the impact of the timing of prostacyclin treatment initiation on reducing PVR and achieving a low-risk profile in PAH patients. The study enrolled 151 patients started on parenteral prostanoid with different treatment strategies. All patients underwent right heart catheterization, clinical evaluation, risk assessments at baseline and after 1-year follow-up. Patients with upfront strategy including parenteral prostanoid plus one oral drug had -5.3±6.2WU (-50±19%) reduction in PVR, patients with upfront strategy including parenteral prostanoid plus double oral drug had -12.8±5.9WU(-68±17%) reduction in PVR, while patients with add-on strategy including parenteral prostanoid after oral drugs had -3.9±3.5WU(-23±19%) reduction in PVR. An upfront strategy including parenteral prostanoids was independently associated with an increased likelihood of achieving the greater reduction of PVR compared with an add-on strategy. Additionally, the greater the severity of PH at the time of diagnosis, in terms of PVR and RV reverse remodeling, the higher the probability of treatment failure. An upfront strategy including a parenteral prostanoid is associated with the highest

likelihood of achieving a low-risk profile and a greater reduction of PVR compared with parenteral prostanoid as an add-on to oral treatment.

A491: CHARACTERISTICS, OUTCOMES AND RISK STRATIFICATION IN OBESE VS. NON-OBESE PATIENTS WITH PULMONARY ARTERIAL HYPERTENSION

Giulio Savonitto (f), Davide Barbisan (f), Pietro Ameri (g), Carlo Maria Lombardi (b), Alberto Giannoni (c), Simonetta Monti (c), Mauro Driussi (d), Piero Gentile (e), Luke Howard (a), Matteo Toma (g), Matteo Pagnesi (b), Valentino Collini (d), Marianna Adamo (b), Luciana D'Angelo (e), Edoardo Airò (c), Marco Metra (b), Andrea Garascia (e), Francesco Lo Giudice (a), Gianfranco Sinagra (f), Davide Stolfo (f)

(a) HAMMERSMITH HOSPITAL, IMPERIAL COLLEGE NHS TRUST, LONDON, UK; (b) CARDIOLOGY UNIT, DEPARTMENT OF MEDICAL AND SURGICAL SPECIALTIES, RADIOLOGICA SCIENCES AND PUBLIC HEALTH UNIVERSITY, SPEDALI CIVILI OF BRESCIA, BRESCIA, ITALY; (c) CARDIOTHORACIC AND VASCULAR DEPARTMENT, UNIVERSITY HOSPITAL OF PISA, PISA, ITALY; (d) CARDIOLOGY, CARDIOTHORACIC DEPARTMENT, ASUFC, UDINE, ITALY; (e) DE GASPERIS CARDIO CENTER, NIGUARDA HOSPITAL, MILANO, ITALY; (f) DIVISION OF CARDIOLOGY, CARDIOVASCULAR DEPARTMENT, AZIENDA UNIVERSITARIA INTEGRATA DI TRIESTE (ASUITS), TRIESTE, ITALY; (g) CARDIOVASCULAR DISEASE UNIT, IRCCS OSPEDALE POLICLINICO SAN MARTINO, GENOVA, ITALY

Background. Prevalence of obesity in Western countries is increasing and growing attention has been dedicated to obese individuals with cardiovascular diseases. In Group 1 pulmonary arterial hypertension (PAH) the subgroup of obese patients remains understudied although obesity can worsen physical symptoms, favour misdiagnosis or delayed diagnosis of the disease and might influence the prognosis.

Purpose. To explore the characteristics of obese patients with PAH, to assess the association between obesity and prognosis and the predictive accuracy of available risk assessment tools for prognostic stratification in obese vs non-obese patients.

Methods. We retrospectively included naïve patients diagnosed with PAH according to the 2015 European guidelines criteria, who were enrolled between 2001 and 2022 at seven European tertiary care centres for PAH management and who had available Body Mass Index (BMI) information. Obesity was defined as a BMI>30 kg/m^2. Primary outcome was 10-year all-cause mortality. Unadjusted survivor functions were estimated using the Kaplan-Meier method. Uni and multivariable Cox regression models were fitted to assess the association between obesity and outcome and to verify the performance of ESC/ERS risk stratification tool, in obese vs non-obese patients.

Results. Among the 397 patients included (median age 61 years, IQR 48-74; 67% females), 96 (24%) were obese. Obese patients had worse cardiovascular comorbidity profile. At diagnosis they had higher WHO functional class, larger atrial remodelling and worse functional capacity. Baseline risk was similarly distributed (77% vs 74% at intermediate risk and 8% vs 12% at high risk in obese vs non-obese, p=0.594). Univariate Kaplan-Meier analysis showed that obesity was a negative predictor of 10-year mortality (HR 0.598, 95%CI 0.356-0.991, p=0.045), even adjusting for confounding comorbidities (HR 0.552, 95%CI 0.326-0.936, p=0.27). When assessed separately and after adjustment for multiple confounders, ESC/ERS risk score was associated with the outcome in non-obese (HR 2.023, 95%CI 1.328-3.008, p=0.001), but not in obese patients (HR 1.105, 95%CI 0.394-3.096, p=0.850).

Conclusions. Despite the higher burden of comorbidity and the worse functional class at presentation, obese patients with PAH had better long-term survival introducing a potential "obesity paradox" also in this disease. Current risk stratification tools might not perform adequately in patients with obesity claiming for focused research aiming to improve risk stratification across subgroups of patients with PAH.

A492: EARLY TREATMENT FAILURE IN INCIDENT PULMONARY ARTERIAL HYPERTENSION

Giulio Savonitto (a), Davide Barbisan (a), Pietro Ameri (f), Carlo Maria Lombardi (g), Alberto Giannoni (c), Simonetta Monti (c), Mauro Driussi (d), Piero Gentile (e), Luke Howard (b), Matteo Toma (f), Matteo Pagnesi (g), Valentino Collini (d), Marianna Adamo (g), Luciana D'Angelo (e), Edoardo Airò (c), Marco Metra (g), Andrea Garascia (e), Francesco Lo Giudice (b), Gianfranco Sinagra (a), Davide Stolfo (a)

(a) DIVISION OF CARDIOLOGY, CARDIOVASCULAR DEPARTMENT, AZIENDA SANITARIA UNIVERSITARIA INTEGRATA DI TRIESTE (ASUITS), TRIETE, ITALY; (b) HAMMERMITH HOSPITAL, IMPERIAL COLLEGE NHS TRUST, LONDON, UK; (c) CARDIOTHORACIC AND VASCULAR DEPARTMENT, UNIVERSITY HOSPITAL OF PISA, PISA, ITALY; (d) CARDIOLOGY, CARDIOTHORACIC DEPARTMENT, ASUFC, UDINE, ITALY; (e) DE GASPERIS CARDIO CENTER, NIGUARDA HOSPITAL, MILANO, ITALY; (f) CARDIOVASCULAR DISEASE UNIT, IRCCS OSPEDALE POLICLINICO SAN MARTINO, GENOVA, ITALY; (g) CARDIOLOGY UNIT, DEPARTMENT OF MEDICAL AND SURGICAL SPECIALTIES, RADIOLOGICA SCIENCES AND PUBLIC HEALTH UNIVERSITY, SPEDALI CIVILI OF BRESCIA, BRESCIA, ITALY

Background. Pulmonary arterial hypertension (PAH) is a rare and severe disease often leading to premature right heart failure and death. Available risk stratification tools are commonly adopted in clinical practice for the prediction of annual mortality after diagnosis and during follow-up. However, in some cases the severity of disease can expose the patients to early treatment failure (ETF). In this study we aimed to define factors associated with ETF in incident PAH.

Methods. We retrospectively analyzed treatment-naïve PAH patients diagnosed according to 2015 European guidelines criteria and enrolled between 2001 and 2022 in a multicenter European registry collecting data from seven European tertiary care centers for the management of PAH. ETF occurrence was defined as death or hospitalization due to worsening PAH <6 months after diagnosis. Factors associated with ETF at univariable logistic regression analysis were adjusted for the ESC/ERS risk stratification tool (expressed as continuous variable).

Results. In a total population of 411 patients (median age 60 years, IQR 47-73, 67% female), 45 (11%) experienced ETF. They were older (69 ± 14 vs. 58 ± 16 years, p<0.001), more likely had diabetes mellitus (DM) and presented with HF symptoms. Atrial fibrillation was more frequent and renal function more impaired. Patients with ETF also showed echocardiographic metrics of larger left and right atrial remodelling and worse right ventricular function. Estimated risk by ESC/ERS risk stratification tool was higher and they were discharged with more aggressive therapy. After adjustment for the ESC/ERS risk stratification score, age at diagnosis (OR 1.05, 95%CI 1.03-1.08, p<0,001), eGFR<60 ml (OR 2.2, 95%CI 1.2-4.4, p=0,021), AF (OR 2.9, 95%CI 1.2-6.9, p=0,020) and E/E' ratio (OR 1.2, 95%CI 1.1-1.3, p<0.001) were significantly associated with higher probability of ETF.

Conclusions. In a real-world cohort of treatment-naïve patients with PAH, about 10% experienced early events. In addition to current available tools for risk stratification, other factors could aid the clinicians to identify patients at high risk of ETF in order to implement more aggressive upfront therapeutic strategies.

A493: PREGNANCY IN WOMEN WITH A FONTAN CIRCULATION: SHORT AND LONG-TERM OUTCOMES

Susanna Breviario (b), Konstantinos Dimopoulos (a), Kaushiga Krishnathasan (a), Claudia Montanaro (a), Isma Rafiq (a)

(a) ROYAL BROMPTON HOSPITAL LONDON; (b) OSPEDALE MOLINETTE TORINO

Background. The Fontan circulation is the palliative surgery of choice in patients with a functionally single ventricle. Life expectancy in these patients has improved in recent decades thanks to the Fontan operation. As a result, more women are reaching child-bearing age and may wish to become pregnant. However, pregnancy in these patients carries risks of maternal and foetal complications. Our study evaluated the short and long-term outcome of pregnancy in contemporary women with Fontan circulation.

Methods. We reviewed all women with a Fontan circulation who underwent pregnancy at our tertiary care centre between 2005 and 2023. Short and long-term morbidity and mortality were reviewed. Women who had a miscarriage before 18 weeks were analysed separately. Moreover, we compared women who reached at least 18 weeks of gestation with women with the same physiology who did not become pregnant.

Results. There was a total of 26 pregnancies in 18 patients beyond 18 weeks of gestation, the majority resulting in a preterm delivery (73.1%). There were no maternal deaths but 3 stillbirths at 18, 20 and 24 weeks of gestation. Half of the neonates (13, 50.0%) were small for gestational age. Cardiac events occurred in 5 (19.2%) pregnancies, all consisting in supraventricular arrhythmias. Post-partum cervical haemorrhage complicated 6 (23%) pregnancies. At a median follow up of 6.1 [5.2-10.6] years, there were no deaths or significant worsening in the resting oxygen saturation (p=0.11) compared to pre-pregnancy. No patients developed liver disease or congestive heart failure. Atrial arrhythmias occurred in 3 (11.5%) cases. The systolic ventricular function decreased in only 2 (7.7%) cases, with no significant changes in BNP or cardiopulmonary exercise test parameters. Women who carried pregnancy on compared to Fontan patients who did not become pregnant, less frequently had liver disease (p=0.008) or cyanosis (p<0.001). Their resting oxygen saturation (p=0.003) and peak VO2 at cardiopulmonary exercise test (p=0.013) were higher.

Conclusions. A careful selection of patients with Fontan circulation during pre-pregnancy counselling can greatly assist in minimising complication during and after pregnancy. Pregnancy in this selected population is well tolerated, despite potential risks for the new-borns. A medium-long term follow-up is reassuring in term of mortality and morbidity.

A494: PROGNOSTIC VALUE OF LEFT ATRIAL STRAIN IN PEDIATRIC CARDIOMYOPATHIES:A MULTI-CENTRE STUDY

Rosalba De Sarro (a), Martina Avesani (b), Sara Moscatelli (c), Nunzia Borrelli (d), Giulia Pelaia (a), Alessia Mendicino (a), Isabella Leo (a), Salvatore De Rosa (a), Daniela Concolino (a), Daniele Torella (a), Giovanni Di Salvo (b), Jolanda Sabatino (a)

(a) DEPARTMENT OF EXPERIMENTAL AND CLINICAL MEDICINE, MAGNA GRAECIA UNIVERSITY CATANZARO, ITALY; (b) DIVISION OF PAEDIATRIC CARDIOLOGY,DEPARTMENT OF WOMEN AND CHILDREN'S HEALTH,UNIVERSITY

HOSPITAL PADUA,ITALY; (c) PAEDIATRIC CARDIOLOGY DEPARTMENT,ROYAL BROMPTON HOSPITAL HAREFIELD NHS FOUNDAION TRUST,LONDON, UK; (d) ADULT CONGENITAL HEART DISEASE UNIT,A.O.DEI COLLI,MONALDI HOSPITAL,NAPLES,ITALY

Background. The left atrium is an early indicator of left ventricular (LV) dysfunction. However, the prognostic significance of left atrial (LA) function, in children with dilated cardiomyopathy (DCM), hypertrophic cardiomyopathy (HCM), and restrictive cardiomyopathy (RCM) has not been well established.

Aims. This study aimed to assess the prognostic value of LA strain, measured using 2-D echocardiographic speckle-tracking analyses (2D-STE), in paediatric cardiomyopathies (CMP).

Methods. The study has a multicentre retrospective design and involved children with cardiomyopathies, who had undergone standard echocardiographic examinations and 2-D speckle-tracking analyses, including LV longitudinal peak systolic strain (LS), and LA peak systolic strain. The primary endpoint was a combination of sudden or cardiac death, hospitalization due to heart failure (HF), or life-threatening arrhythmias.

Results. A total of 155 children were included in the study, with an average age of 8.8 ± 6 years, comprising 50 with DCM, 50 with HCM, 10 with RCM, and 45 healthy controls (CTRL). Twenty-two patients (14%) experienced the primary endpoint during a median follow-up of 5 years. LA peak systolic strain and strain rate values displayed a consistent and significant decrease with the severity of diastolic dysfunction. Several factors including left ventricular ejection fraction (LVEF), left atrial volume index (LAVI), LV global longitudinal strain (GLS), and LA reservoir strain were associated with the outcome in univariate analysis (all P<0.05). These independent variables were chosen according to univariable analyses and clinical relevance. LA reservoir strain emerged as a more robust predictor of the outcome compared to the other echocardiographic variables. In the multivariable model, LA reservoir strain remained significantly associated with the outcome (HR: 3.05; P<0.05).

Conclusions. 2D-STE-derived LA reservoir strain serves as a robust and independent prognostic predictor in children with cardiomyopathies, surpassing the predictive capacity of LV GLS, LVEF, and LAVI. Therefore, considering LA strain in the management of children with CMP may enhance the risk stratification of the disease and facilitate the planning for early clinical intervention.

A495: MID-TERN ELECTROCARDIOGRAPHIC ATRIAL REMODELING AFTER PERCUTANEOUS ASD CLOSURE WITH GCO DEVICE IN PEDIATRIC POPULATION

Jennifer Fumanelli (a), Silvia Garibaldi (b, c), Biagio Castaldi (a), Alessandra Pizzuto (c), Domenico Sirico (a), Massimiliano Cantinotti (d)
(a) PEDIATRIC CARDIOLOGY UNIT, DEPARTMENT OF WOMEN'S AND CHILDREN'S HEALTH, PADUA; (b) FONDAZIONE TOSCANA GABRIELE MONASTERIO PER LA RICERCA MEDICA E SANITA PUBBLICA, ELECTROPHYSIOLOGY DIVISION; (c) FONDAZIONE TOSCANA MONASTIERO PER LA RICERCA MEDICA E SANITA PUBBLICA, PEDIATRIC CARDIOLOGY AND GUCH DIVISION; (d) FONDAZIONE MONASTIERO CNR-REGIONE TOSCANA, PEDIATRIC CARDIOLOGY AND CARDIAC SURGERY

Background. Ostium secundum Atrial Septal Defect (ASD) is a common congenital heart defect, found in about 1.0/1.000 live births and leads to right chamber volume overload, pulmonary hypertension, systemic embolism, atrial arrhythmias and premature death over a long-term follow-up. Atrial arrhythmias are well known long-term complications of ASD, possibly due to chronic right atrial volume overload and resulting stretch. In addition, also in other congenital and acquired heart diseases, P-wave and QTc dispersion are well-known predictors of arrhythmias and are often considered as prognostic factors of morbidity and mortality. The GORE® CARDIOFORM septal occluder is an atrial septal defect/patent foramen ovale closure device with theoretical advantages over other commercialized devices thanks to its softness and anatomical compliance. Our aim was to evaluate the short and medium-term electrocardiographic changes after percutaneous ASD closure with GCO in a pediatric population.

Methods. This was a prospective single-arm study performed at the Pediatric Cardiology and GUCH Unit of the Heart Hospital "G. Pasquinucci" of Massa and the Pediatric Cardiology Unit of the University of Padua. We enrolled 39 pediatric patients (age 5-18 years) with isolated ASD submitted to trans-catheter closure with GCO from January 2020 to June 2021. The following patients were excluded from the study: (i) patients with sinus venosus or primum type ASD, (ii) patients with inadequate rims, (iii) patients with significant cardiac/extra-cardiac comorbidities. EKG was performed before, at 24 hours and 6 months after ASD transcatheter closure. P wave dispersion, QTc ed QTc dispersion were calculated. We performed EKG Holter recording at 6-months after device implantation.

Results. Patients' age and BSA were 8.2±4.2 years and 1.0±0.3 m2 respectively. At the baseline mean P wave dispersion was 40±15 msec and decreased at 24h (p<0.002), without any further change at 6 months. PR conduction significantly improved at 24 h from device implantation (p=0.018) and did not significantly change at 6 months. Absolute QTc value did not significantly changed at 24, but significantly improved at 6 months from the procedure (p=0.03). QTc dispersion decreased at 24 hours (p<0.02) and at 6 months (p<0.002) from device implantation. After device deployment, 2 pts developed transient, self-limited junctional rhythm. One of them needed a short course of Flecainide for supra-ventricular tachycardia. No tachy/brady-arrhythmias were recorded at the 6-months follow-up ever.

Conclusions. Percutaneous ASD closure with the GCO device results in significant, sudden improvement of intra-atrial, atrio-ventricular and intraventricular electrical homogeneity. These favorable electrical changes persist unaltered over a mid-term follow-up, possibly due to a positive right heart volumetric remodeling not hindered by the mechanical impact of the occluding device and could explain the low rate of cardiac arrhythmias found at the mid-term ambulatory ECG evaluation in this series.

A496: PROGNOSTIC ASSESSMENT OF EARLY CARDIOVASCULAR DYSFUNCTION BY 3D-ECOCARDIOGRAPHY AND CORRELATIONS WITH CLINCAL AND HEMATOLOGICAL DATA IN SICKLE-CELL DISEASE

Francesca Coppi (a), Francesca Tampieri (a), Matteo Boschini (a), Giovanni Palazzi (a), Giulio Leo (a), Gabriele Melegari (a), Antonio Manenti (a), Giuseppe Boriani (a), Anna Vittoria Mattioli (a)
(a) UNIVERSITY OF MODENA AND REGGIO EMILIA, POLICLINICO DI MODENA, 41124, MODENA, ITALY

Background. Sickle-cell disease is a set of chronic hemolytic anemias which affects around 300.000 newborns worldwide each year. This autosomal-recessive disorder results in the generation of sickle-shaped red blood cells, which, by a combination of hemolysis and vaso-occlusion, create a state of endothelial inflammation and dysfunction having repercussions that involve almost all organs. The University Hospital of Modena and Reggio Emilia follows the widest group of patients with drepanocytosis in Emilia-Romagna, administering therapies, treating complications and monitoring their health status since they are intercepted.

Methods and Results. We collected a group of 46 children, with an age span between 3 and 21 years old, both males and females, with HbSS (homozygous) and HbSC (heterozygous) sickle-cell anemia, upon which we performed a 3D echocardiogram, with the aim of detecting early cardiac implications of the disease by focusing on the volumes of both left and right heart chambers, left ventricle global longitudinal strain (LV-GLS) and right ventricle free wall strain (RV-FWS). The echocardiographic findings were also combined with the clinical and hematological data as number of systemic and pulmonary crises, Hemoglobin, Leukocytes, Polymorphonuclear Leukocytes, Platelets, LDH, Bilirubin, GOT and GPT, HbS and HbF which were collected within the same time-span, to assess whether there was any statistical correlation among them. The great sophistication of 3D-Echocardiography indeed allowed us to detect volumetric and contractile alterations in a significant number of patients and interesting correlations emerged by combining those data with the clinical and hematological ones.

Conclusions. Three-dimensional echocardiography is a valuable method to monitor cardiac abnormalities in these patients from an early age and that, by positively correlating with the blood parameters accounting for the systemic involvement of the hemolytic anemia, cardiac dysfunction is strictly dependent on the general cardiovascular state of the disease.

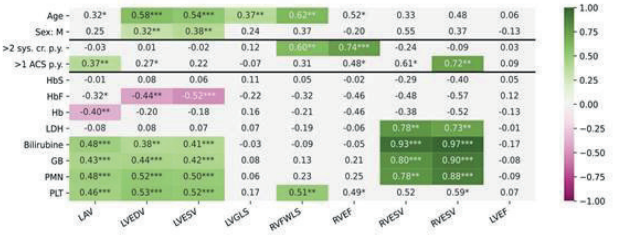

Figure 1. Correlation between hematological and 3D- and STI- echocardiographic data.

A497: PHENOTYPE AND OUTCOME CORRELATES OF HIGH DOSE LOOP DIURETICS IN TYPE 1 PULMONARY HYPERTENSION

Davide Barbisan (a), Giulio Savonitto (a), Francesco Lo Giudice (b), Carlo Maria Lombardi (c), Edoardo Airo (d), Mauro Driussi (e), Piero Gentile (f), Luke Howard (b), Alberto Giannoni (d), Valentino Collini (e), Matteo Toma (g), Andrea Garascia (f), Marco Metra (c), Gianfranco Sinagra (a), Pietro Ameri (g), Davide Stolfo (a)
(a) CARDIOTHORACOVASCULAR DEPARTMENT, UNIVERSITY HOSPITAL CATTINARA, ASUGI AND UNIVERSITY OF TRIESTE, ITALY; (b) HAMMERSMITH HOSPITAL, IMPERIAL COLLEGE NHS TRUST, LONDON, UK; (c) CARDIOLOGY UNIT, DEPARTMENT OF MEDICAL AND SURGICAL SPECIALTIES, RADIOLOGICA SCIENCES AND PUBLIC HEALTH UNIVERSITY, SPEDALI CIVILI OF BRESCIA, BRESCIA, ITALY; (d) CARDIOTHORACIC AND VASCULAR DEPARTMENT, UNIVERSITY HOSPITAL OF PISA, PISA, ITALY; (e) CARDIOLOGY, CARDIOTHORACIC DEPARTMENT, ASUFC, UDINE, ITALY; (f) DE GASPERIS CARDIO CENTER, NIGUARDA HOSPITAL, MILANO, ITALY; (g)

CARDIOVASCULAR DISEASE UNIT, IRCCS OSPEDALE POLICLINICO SAN MARTINO, GENOVA, ITALY; DEPARTMENT OF INTERNAL MEDICINE, UNIVERSITY OF GENOVA, GENOVA, ITALY

Use of higher dose of loop diuretics has been associated with worse survival in acute and chronic heart failure. The use of loop diuretics in type 1 pulmonary hypertension (PAH) is generally less frequent compared to heart failure and required doses may be lower. The clinical and prognostic characteristics of patients requiring high dose of loop diuretics in PAH remain unexplored. We studied the characteristics of patients requiring different doses of loop diuretic and their association with survival in PAH. Patients with a diagnosis of PAH, enrolled from 2001 and 2021 at seven European centers for the management of PAH were retrospectively included in the study. High dose diuretic use was defined according to the median dose of furosemide in the overall cohort and patients were then divided into two subgroups: no/low dose and high dose diuretic use. Primary outcome was 5-year survival. Predictors of high dose diuretic use were assessed by multivariable logistic regression analysis. Multivariable Cox regression analysis was performed to test the association between high dose diuretic use and 5-year survival. Among the 402 patients included (median age 61 years, IQR 49-74; 67% females), 231 (57%) were treated with loop diuretics. Median furosemide dose was 25 mg (IQR 0-40 mg) and accordingly patients were divided in no/low dose (n. 260, 65%) vs high dose (n. 142, 35%) diuretic ones. Patients in the high dose group were older, had more comorbidities, including impaired renal function (Figure 1) and characteristics of a more severe disease (41% vs 27% at intermediate-high risk and 42% vs 22% at high risk based on COMPERA 2.0 classification, p<0.001). Predictors of high dose loop diuretic use were obesity (OR 2.04, 95%CI 1.06-3.91, p=0.032), COMPERA 2.0 risk class (OR 1.66, 95%CI 1.19-2.31, p=0.003) and right atrial pressure risk class (OR 2.23, 95%CI 1.42-3.51, p=0.001). Rates of monotherapy, dual and triple combination therapy were similar in patients at no/low vs high dose. Crude 5-year survival was significantly lower in patients in the high dose group (log-rank p=0.002). However, after adjustment for age, sex and main risk factors (i.e. COMPERA 2.0 score, TAPSE/PASP, right atrial pressure and cardiac index), high loop diuretic dose was not significantly associated with higher 5-year mortality risk. Use of high dose of loop diuretics in PAH characterizes patients with higher burden of comorbidities, more severe disease and worse survival. However, in PAH, the need of high loop diuretic dose represents a marker of disease severity rather than an independent prognostic factor.

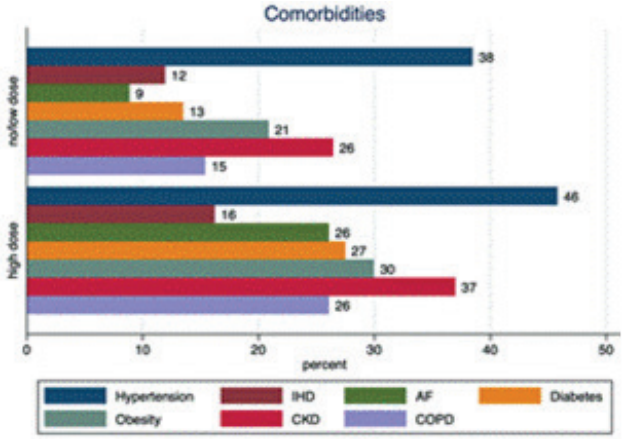

Figure 1. Distribution of comorbidities according to loop diuretic dose.

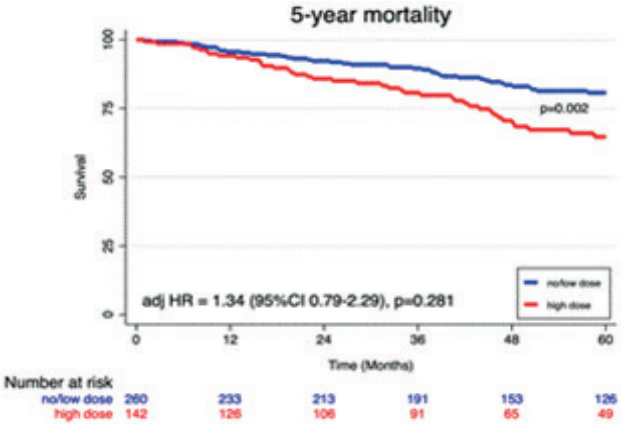

Figure 2. 5-year survival in the no/low vs high loop diuretic dose patients.

A498: DEFORMATION IMAGING BY STRAIN ECHOCARDIOGRAPHY AND CLINICAL OUTCOMES IN CHRONIC HEART FAILURE OVER SACUBITRIL-VALSARTAN AND CARDIAC RESYNCHRONIZATION THERAPY IN ADULT CONGENITAL HEART DISEASE PATIENTS WITH SYSTEMIC RIGHT VENTRICULAR FAILURE

Paolo Tofoni (a), Gianmarco Bastianoni (a), Alessandro Bacchiocchi (b), Francesco Bianco (c), Valentina Bucciarelli (c), Alessandro Capestro (c), Paolo Compagnucci (a), Giuseppe Ciliberti (a), Federico Guerra (a), Marco Pozzi (a), Carlo Catassi (b), Antonio Dello Russo (a)
(a) CARDIOLOGY ARRHYTHMOLOGY CLINIC, UNIVERSITY HOSPITAL "UMBERTO I - LANCISI - SALESI", MARCHE POLYTECHNIC UNIVERSITY OF ANCONA; (b) DEPARTMENT OF PEDIATRICS UNIVERSITY HOSPITAL "UMBERTO I - LANCISI - SALESI" POLYTECHNIC UNIVERSITY OF ANCONA; (c) DEPARTMENT OF PEDIATRIC AND CONGENITAL CARDIOLOGY AND CARDIAC SURGERY, UNIVERSITY HOSPITAL "UMBERTO I - LANCISI - SALESI" OF ANCONA

Background. Sacubitril/valsartan administration and cardiac resynchronization therapy (CRT) radically changed the treatment of heart failure with reduced ejection fraction (HFrEF) in the last few years. There is limited evidence suggesting similar efficacy of both treatments in HFrEF patients with a right systemic ventricle due to congenital heart disease (CHD).

Purpose. The aim of this study was to identify both clinical and deformation imaging predictors by strain echocardiographic analysis after sacubitril/valsartan implementation and CRT implantation in CHD patient with symptomatic HFrEF due to a systemic right ventricular failure.

Methods. In 2019-23, we enrolled 15 consecutive CHD patients (median age 23±5 years, all males) presenting with signs and symptoms of heart failure, a New York Heart Association (NYHA) Class II-III, right ventricular (RV) ejection fraction (EF) <35% despite the maximal tolerated treatment with β-blocker and ACE-inhibitor/angiotensin II receptor-blockers, right bundle branch block (RBBB) with a QRS ≥150 ms or first degree atrioventricular block and QRS ≥130 ms. The participants were started on sacubitril/valsartan and then candidate to CRT. Patients underwent transthoracic echocardiography (TTE), 6-minute walking test (6-MWT) and cardiopulmonary exercise test (CPET) at the enrolment, at 6-month from the implementation of sacubitril-valsartan and 6-month after CRT implantation. Clinical data, laboratory tests, comprising Troponins, BNP/NT-proBNP, and electrocardiograms were also collected at each evaluation during the follow-up.

Results. Of 15 participants, 67% (n=10/15) were congenitally corrected transpositions of great arteries (ccTGA) and 5% (n=5/15) TGA after atrial switch. The latter, and n=3 ccTGA, underwent surgical CRT implantation; in two cases, only biventricular leads were implanted. Four patients also underwent a systemic atrioventricular valve mechanical replacement. After sacubitril/valsartan administration, NT-proBNP values decreased significantly (P<0.001), while a clinical improvement was detected by NYHA class improvement (P<0.001) and increased 6-MWT distance (422 [335, 482] versus 500 [445, 562] m; P<0.001). RV EF and CPET VO2-max demonstrated a temporal trend of increment over the treatments (P-trend <0.001 and 0.004, respectively); of note, RV EF slightly increased after sacubitril valsartan implementation (32.5±6.2 to 35.2±6.5%; P<0.032), but only after CRT significantly improved up to 42.5±7.2% (P<0.001). GLS showed similar results with a fully resynchronized strain pattern of the RV only after CRT implantation, while a significantly augmentation was demonstrated after both treatments (P-trend <0.035 and <0.001, respectively).

Conclusions. In CHD patient with symptomatic HFrEF due to a systemic right ventricular failure the combination of sacubitril/valsartan administration and CRT implantation was effective in terms of symptoms, NT-proBNP reduction an RV GLS augmentation. Only CRT was able to significantly improve RV EF and resulted with a fully resynchronized RV strain pattern.

A499: DIRECT FICK, INDIRECT FICK AND THERMODILUITION: ARE THEY REALLY INTERCHANGEABLE? AN OBSERVATIONAL, PROSPECTIVE STUDY

Maria Vittoria Caprio (a), Serena Rossi (c), Federica De Donno (a), Marco Addari (a), Paolo Ciarelli (a), Livio Giuliani (c), Sabina Gallina (a, b)
(a) DEPARTMENT OF NEUROSCIENCE, IMAGING AND CLINICAL SCIENCES, "G. D'ANNUNZIO" UNIVERSITY OF CHIETI-PESCARA, 66100 CHIETI, ITALY; (b) HEART DEPARTMENT, SS. ANNUNZIATA HOSPITAL, ASL 2 ABRUZZO, 66100 CHIETI, ITALY; (c) INTERVENTIONAL CARDIOLOGY DEPARTMENT, SS. ANNUNZIATA HOSPITAL, ASL 2 ABRUZZO, 66100 CHIETI, ITALY

Introduction. Direct Fick (DF) is the most accurate method for CO evaluation in Right Heart Catheterization (RHC), but it is not widely used as it requires direct oxygen uptake (VO2) measurement[1], additional equipment and time-consuming procedures. In contrast, the Indirect Fick (IF) method is simpler and faster, but less reliable[2]. Current European Society of Cardiology (ESC) Guidelines recommend Direct Fick or Thermodilution (TD) for CO measurement[3]. Of note, data on the direct comparison between these three methods is poor. The objective of our study is to compare CO evaluation by the DF method (DFCO), IF method (IFCO) and TD (TDCO). Secondly, we aimed to assess how potential divergences among these methods may affect Pulmonary Vascular Resistance (PVR) calculation and risk stratification.

Methods. This is an observational, prospective, investigator-initiated, no-profit study, approved by the Ethics Committee of the G. D'Annunzio University of Chieti-Pescara. All consecutive patients aged ≥18 years, referred for RHC for suspected PH, were included. Exclusion criteria were contraindications to RHC, cardiac shunts and failure to obtain informed consent.

1. DFCO was calculated by the following formula: VO2 in millilitres per minute/(arteriovenous oxygen content difference × 10).
2. For IFCO, VO2 was calculated by using Dehmer's formula (body surface area x 125)[4].
3. TDCO was calculated by the injection of 10 ml of cold saline (0-4 °C) solution into the right atrium through the proximal catheter port of the Swan-Ganz catheter and by measuring the temperature variation at the catheter distal tip thermistor placed into the pulmonary artery. At least 3 CO estimates with <15% variation were averaged.

Differences between the 3 methods of CO calculation have been evaluated through Bland-Altman analysis. Here differences in paired measurements are plotted against the mean of the same two measurements. We defined a priori the limits of maximum clinically acceptable differences between the methods on CO estimate at ±0.5 L/min, which correspond to 10% of the mean CO. Agreements among the three methods in PVR group allocation (>2 or ≤2 WU) and in the three-strata risk stratification3 were tested using Cohen's Kappa statistic.

Results. Between January and September 2022, 43 patients were enrolled. They were predominantly female (n=31, 72%) with a mean age of 66.0 ± 13.4 years. At Bland- Altman plots, 24 (56%) out of 43 cases, differed by more than 10% (±25ml/min) by direct VO2 measurement. Mean CO values did not significantly differ (DFCO 4.2 ± 1.6 L/min; IFCO 4.6 ± 1.3 L/min; TDCO 4.6 ± 1.4 L/min; P=NS for all pairwise comparisons) and showed significant Pearson's correlation (DFCO vs IFCO R=0.85, p<0,01; DFCO vs TDCO R=0.76, p<0,01; IFCO vs TDCO R=0.68, p<0,01). However, in Bland-Altman plots, individual differences were consistently wide across the spectrum of estimated values. In 53% of cases (n=23/43) IFCO differed by more than 10% from DFCO (Figure panel A); in 67% of cases (n=29/43) TDCO differed by more than 10% from DFCO (Figure panel B) and in 56% of cases (n=24/43) IFCO differed for more of 10% from TDCO (Figure panel C). Despite discrepancies among different CO measurement methods, we found good agreement between DF and TD in PVR classification (Cohen's kappa=0.76), and moderate agreement using the IF method (Cohen's kappa IF vs DF=0.56; Cohen's kappa IF vs TD=0.49). Among the entire cohort, RHC revealed Pulmonary Arterial Hypertension in 36 patients (84%). In this subgroup, we evaluated if the difference in CO measurement influenced ESC three-strata model risk stratification and therapeutic management. We found that in almost half of patients risk class changed according to the CO measurement method used.

Conclusions. In our series, discrepancies in CO estimation did not consistently affect PVR classification, although the small sample size and the low number of patients with values close to the pathological cut-off for PVR (2 WU) might have mitigated the results. However, these discrepancies significantly affected risk stratification, whose assessment is crucial for a goal-oriented therapeutic approach in PAH patients. In conclusion, the available methods for CO estimation are not interchangeable and potential discrepancies may significantly impact risk stratification, with relevant repercussions on decision-making. Larger studies are needed to confirm our results and better investigate the magnitude of CO measurement discordances among different methods on PH patients undergoing RHC.

A500: RIMODELLAMENTO ELETTROMECCANICO DOPO CHIUSURA PERCUTANEA DI DIFETTO INTERATRIALE CON UN NUOVO DEVICE

Biagio Castaldi (a), Angela Di Candia (a), Jennifer Fumanelli (a), Domenico Sirico (a), Silvia Garibaldi (b), Massimiliano Cantinotti (b), Silvia Scalera (b), Alessandra Pizzuto (b), Pietro Marchese (b), Giuseppe Santoro (b), Giovanni Di Salvo (a)

(a) UNIVERSITÀ DEGLI STUDI DI PADOVA - UOC DI CARDIOLOGIA PEDIATRICA; (b) FONDAZIONE TOSCANA GABRIELE MONASTERIO, MASSA - UOC DI CARDIOLOGIA PEDIATRICA

Introduzione. La chiusura transcatetere è il trattamento di prima linea per il difetto del setto atriale (DIA) ostium secundum. Il GORE® Cardioform ASD Occluder (GCA) è potenzialmente innovativo rispetto ad altri dispositivi autocentranti. Lo scopo di questo studio era di confrontare i cambiamenti meccanici nelle proprietà atriali e ventricolari prima e dopo l'impianto di GCA.

Metodi. Tutti i pazienti consecutivi di età <18 anni che hanno eseguito la chiusura isolata del DIA con un singolo dispositivo GCA sono stati arruolati da due centri. L'ecocardiografia e l'ECG sono stati eseguiti il giorno prima, 24 ore e 6 mesi dopo la chiusura del DIA.

Risultati. Tra gennaio 2020 e febbraio 2021, sono stati arruolati 70 pazienti pediatrici con ASD. L'età media era di 7,9±3,9 anni, il diametro medio del difetto era di 17,1±4,5 mm. L'analisi della deformazione longitudinale globale non ha mostrato alcun cambiamento nella funzione longitudinale del ventricolo sinistro (T0 -23,2±2,8%; 24h -23,0±2,8%; 6 mesi -23,5±2,7%). Una riduzione precoce e transitoria della deformazione longitudinale è stata rilevata nei segmenti del setto basale (T0 -19,8±3,3%; 24h -18,7±3,6%; 6 mesi -19,2±3,4%), nell'atrio sinistro (T0 41,4±15,3%; 29,2±1,4% e 39,0±12,9%, rispettivamente) e il ventricolo destro (-27,6±5,4%, -23,6±5,0% e -27,3±4,6, rispettivamente) 24 ore dopo la chiusura, secondaria a cambiamenti emodinamici dovuti al reindirizzamento del flusso dopo la chiusura del DIA. Sei mesi dopo la procedura, solo l'atrio sinistro ha mostrato una lieve riduzione della deformazione longitudinale globale, dovuta alla presenza del dispositivo all'interno del setto. La dispersione media dell'onda P al basale è diminuita da 40±15 msec a 30±13 msec a 6 mesi (p<0,001). La dispersione del QTc è diminuita significativamente (da 40,9±13,0 a 28,0±18,2, p<0,001) a 6 mesi dalla procedura. La durata dell'onda P preoperatoria e la dispersione dell'onda P erano correlate con t0 lo strain atriale destro (R=-0,43, p=0,01 e R=0,42, p=0,01, rispettivamente) e sinistro (R=-0,36, p=0,03; R=-0,34, p=0,04). A 6 mesi non è stata trovata alcuna correlazione con la dispersione delle onde P e lo strain dell'atrio. La dimensione del difetto era correlata alla durata dell'onda P al T0 (R=0,37, p=0,02) e alla dispersione dell'onda P (R=0,29, p=0,04). Non è stata, invece, trovata alcuna correlazione tra la durata e la dispersione delle onde P e QT e le dimensioni del dispositivo a 6 mesi. La durata dell'onda QT e la dispersione dell'onda QT non hanno mostrato alcuna correlazione con lo strain del VD o del VS, prima e dopo la chiusura dei DIA.

Conclusioni. Il dispositivo GCA si è dimostrato sicuro, altamente versatile ed efficace per la chiusura percutanea dei DIA. Questo studio dimostra che la GCA non ha avuto alcun impatto sulla funzione longitudinale ventricolare destra e sinistra globale e regionale 6 mesi dopo l'impianto. La meccanica atriale è stata preservata, ad eccezione dei segmenti coperti dal dispositivo, con una tendenza al recupero complessivo della funzione atriale al follow-up a 6 mesi. Sulla base dei dati disponibili in letteratura, questo è stato il primo dispositivo che non ha dimostrato alcun impatto sulla meccanica ventricolare sinistra e destra, indipendentemente dalla dimensione del dispositivo utilizzato.

A501: PERFORMANCE AND FAILURE OF SURGICALLY IMPLANTED RIGHT VENTRICLE TO PULMONARY ARTERY CONDUIT IN CONGENITAL HEART DISEASE

Emanuela Concetta D'Angelo (a), Gabriele Egidy Assenza (a), Anna Balducci (a), Ylenia Bartolacelli (a), Ambra Bulgarelli (a), Lucio Careddu (b), Cristina Ciuca (a), Elisabetta Mariucci (a), Luca Ragni (a), Andrea Donti (a), Gaetano Domenico Gargiulo (b), Emanuela Angeli (b)

(a) PEDIATRIC CARDIOLOGY AND ADULT CONGENITAL HEART DISEASE PROGRAM, DEPARTMENT OF CARDIO-THORACIC AND VASCULAR MEDICINE, IRCCS, AZIENDA OSPEDALIERO-UNIVERSITARIA DI BOLOGNA, ITALY; (b) PEDIATRIC AND ADULT CONGENITAL HEART DISEASE CARDIOTHORACIC SURGERY, DEPARTMENT OF CARDIO-THORACIC AND VASCULAR MEDICINE, IRCCS, AZIENDA OSPEDALIERO-UNIVERSITARUA DI BOLOGNA, ITALY

Background. Surgical implantation of right ventricle to pulmonary artery (RV-PA) conduit is an important component of congenital heart disease (CHD) surgery but with limited durability and need for re-intervention. Current single center, retrospective, cohort study is reporting longterm performance of surgically implanted RV-PA conduit in a consecutive series of children and adults with CHD.

Methods. Patients with CHD referred for RV-PA conduit surgical implantation (October 1997 and January 2022) have been included. Primary outcome was conduit failure defined as peak gradient above 64mmHg/severe regurgitation/need for conduit-related interventions. Longitudinal echocardiographic studies were available for mixed-effect linear regression analysis.

Results. Two-hundred and fifty-two patients were initially included. One hundred and forty-nine patients were available and elegible for follow-up data collection. After a median follow-up time of 49 months the primary study endpoint occurred in 44 (29%) patients. Multivariable Cox regression model identified adult age (>18 years) at implantation and pulmonary homograft as protective factors (HR 0.11, 95% CI 0.02-0.47, p-value 0.003 and HR 0.34, 95% CI 0.16-0.74, p-value 0.006, respectively). Fever within 7 days of surgical conduit implantation was a strong, independent risk factor for early (within 24 months) failure (HR 4.29, 95% CI 1.41-13.01, p-value 0.01). Longterm use of oral anticoagulant was independently associated with slower progression of peak echocardiographic gradient across conduits (p-value 0.027).

Conclusions. In patients with CHD, surgically implanted RV-PA conduit failure is faster in children and after non-homograft conduit implantation. Early fever after surgery is a strong risk factor for early failure. Longterm anticoagulation seems to exert a protective effect.

A502: THE EXERCISE-STRESS ECHOCARDIOGRAPHY IN REPAIRED AORTIC COARTATION: DYNAMIC EVALUATION OF MYOCARDIAL SYSTOLIC FUNCTION

Jennifer Fumanelli (a), Jolanda Sabatino (a), Martina Avesani (a), Irene Cattapan (a), Alice Pozza (a), Giovanni Di Salvo (a)

(a) PEDIATRIC CARDIOLOGY UNIT, DEPARTMENT OF WOMEN'S AND CHILDREN'S HEALTH, PADUA

Background. The echocardiography-derived myocardial work (MW) is an increasingly used tool in advanced echocardiography to better un-

derstand the performance of the left ventricle in term of stroke work, oxygen consumption and myocardial metabolism. Arterial hypertension, hypertrophic cardiomyopathy and dilated cardiomyopathy have been the main subjects of study in adult population, but the understanding of the left ventricle mechanisms in the congenital heart disease is quiet lacking.

Aim and Methods. Our aim was to evaluate the left ventricle deformation through MW parameters analysis in repaired aortic coarctation patients (both at rest and) during physical stress echocardiography. We enrolled 25 patients affected by repaired aortic coarctation from June 2020 to April 2023. We firstly performed a baseline echocardiography; then, an exercise echocardiography was performed applying a semi-supine bicycle Bruce's ergometer protocol. Multiple stress parameters were assessed during the exercise and at the peak level, such as the arterial pressure, symptoms, EKG modifications and the myocardial systolic function. The post-processing analysis of standard function parameter, LV speckle-tracking and MW indices at the baseline and during stress was done by EchoPAC™ Software.

Results. Patients' age was 23 ± 13 years old with a prevalence of male gender (19 male, 6 female). 23 patients have additional heart defects such as bicuspid aortic valve (n=16) and/or subvalvular aortic membrane (n=2) and/or VSD (n=5) and/or other cardiac abnormalities. 19 patients underwent cardiac surgery and 6 submitted to percutaneous procedure (3 dilation with stent and 3 aortoistmoplasty respectively). Half sample had higher systolic blood pressure (mean 139/74 mmHg), independently on the anti-hypertensive therapy. The baseline longitudinal LV systolic function was reducted despite the normal global function (GLS -16.9%±3, EF 64.2%±5). The baseline MW analysis showed a subclinical systolic dysfunction: global work index (GWI) and global constructive work (GCW) were similar to healthy population. The global wasted work (GWW) was increased and the global work efficiency (GWE) mild reducted. At the peak level of stress the GWI remained stable (1714 mmHg% vs 1710 mmHg% at rest), while the GCW and GWW increased (GCW: 2901 mmHg% vs 2172 mmHg% at rest, GWW: 145 mmHg% vs 128 mmHg% at rest). The GWE slightly improved (94.4% vs 93.5% at rest). The gender, the additional heart defects were independent variables of GCW and GWW improvement during exercise, while the presence of cardiac hypertrophy is directly correlated to a reduction of GWI during stress. The increasing of gradient across descending aorta is correlated to an improvement of all MW parameters.

Conclusions. The baseline LV performance MW analysis showed a subclinical systolic dysfunction, which improved during stress echo in term of total work and productive work, despite the increasing of non-productive work. These results could reflect a reserve of myocardial function under stress, which however decreases in the presence of cardiac hypertrophy. The hypertrophy assessment could therefore play a key role in predicting initial signs of myocardial systolic dysfunction detectable only under exercise.

A503: DISFUNZIONE DIASTOLICA NEL VENTRICOLO DESTRO SISTEMICO: STUDIO DI RISONANZA MAGNETICA SULLA FUNZIONE ATRIALE NEI PAZIENTI CON TRASPOSIZIONE CONGENITAMENTE CORRETTA DEI GRANDI VASI

Francesco Giangiacomi (a, h), Giandomenico Disabato (b), Giulia Pasqualin (c), Domenica Paola Basile (c, d), Lara Tondi (e), Antonia Camporeale (b), Marco Vicenzi (h, i), Andrea Attanasio (f), Gianluigi Guida (f), Alessandro Giamberti (g), Massimo Chessa (d), Stefano Carugo (a, h), Massimo Lombardi (b)

(a) UNIVERSITÀ DEGLI STUDI DI MILANO, DIPARTIMENTO DI SCIENZE CLINICHE E DI COMUNITÀ, MILANO, ITALIA; (b) IRCCS POLICLINICO SAN DONATO, SERVIZIO DI IMAGING CARDIACO MULTIMODALE, SAN DONATO MILANESE, ITALIA; (c) IRCCS POLICLINICO SAN DONATO, UNITÀ DI CARDIOLOGIA PEDIATRICA E CONGENITI ADULTI, SAN DONATO MILANESE, ITALIA; (d) IRCCS POLICLINICO SAN DONATO, UNITÀ DI CARDIOLOGIA DEI CONGENITI ADULTI, SAN DONATO MILANESE ITALIA; (e) UNIVERSITÀ DEGLI STUDI DI MILANO, DIPARTIMENTO DI RADIOLOGIA, FONDAZIONE IRCCS CA GRANDA OSPEALE MAGGIORE POLICLINICO, MILANO, ITALIA; (f) CENTRO PER LO STUDIO E LA CURA DELLE AMILOIDOSI SISTEMICHE, PAVIA, ITALIA; (g) IRCCS POLICLINICO SAN DONATO, UNITÀ DI CARDIOCHIRURGIA PEDIATRICA E CARDIOCHIRURGIA DEI CONGENITI ADULTI, MILANO, ITALIA; (h) FONDAZIONE IRCCS CA GRANDA OSPEDALE MAGGIORE POLICLINICO, DIPARTIMENTO CARDIO-TORACO-VASCOLARE, MILANO, ITALIA; (i) DYSPNEA LAB, UNIVERSITÀ DEGLI STUDI DI MILANO, DIPARTIMENTO DI SCIENZE CLINICHE E DI COMUNITÀ, MILANO, ITALIA

Introduzione. La trasposizione congenitamente corretta dei grandi vasi (congenital corrected transposition of great arteries, ccTGA) comporta il fatto che il ventricolo destro viene a trovarsi in posizione sistemica (systemic right ventricle, sRV). I pazienti con ccTGA sono spesso asintomatici nelle prime decadi di vita, tuttavia, nel tempo, il sRV, confrontandosi con le elevate pressioni della circolazione sistemica, tende a manifestare segni di disfunzione. Pertanto, questi pazienti sviluppano spesso i sintomi di insufficienza cardiaca (heart failure, HF) nell'età adulta. Ci sono poche evidenze in letteratura per quanto riguarda la disfunzione diastolica nei pazienti con sRV. Abbiamo ipotizzato che la disfunzione diastolica sia una componente importante della fisiopatologia del sRV e quindi che un'accurata valutazione di questa possa portare ad un migliore inquadramento e stratificazione prognostica di questi pazienti. Il presente studio ha l'obiettivo di esplorare la funzione diastolica dei pazienti con ccTGA tramite un'analisi dei parametri morfo-funzonali dell'atrio sinistro tramite risonanza magnetica cardiaca (cardiac magnetic resonance, CMR).

Metodi. Abbiamo analizzato retrospettivamente le immagini di risonanza magnetica di 33 pazienti con ccTGA che si sono riferiti al nostro centro tra l'aprile 2014 ed il dicembre 2022. I pazienti con ccTGA sono stati confrontati con un gruppo di soggetti sani (gruppo di controllo) e con un gruppo di pazienti con cardiomiopatia ipertrofica (Hypertrophic Cardiomyopathy, HCM) con HFpEF diagnosticata secondo le linee guida europee sullo scompenso cardiaco, matchati per età a sesso. Sono stati confrontati i seguenti parametri morfo-funzionali relativi al LA: volume del LA, frazione d'eiezione (EF) e strain reservoir (εs), conduit (εe) e booster (εa). Tutti i pazienti erano in ritmo sinusale al momento della risonanza.

Risultati. L'età media dei pazienti era di 41,8 anni per il gruppo di pazienti con ccTGA e di 39 anni per i gruppi HCM e controllo. In tutti e tre i gruppi le donne rappresentavano il 39% dei soggetti. Rispetto ai pazienti del gruppo di controllo, i pazienti con ccTGA avevano una significativa compromissione della funzione del LA (LA EF: 41,6 ± 15,1 vs 63,9 ± 7,8, p<0,001, εs: 19,0 ± 8,3 vs 38,0 ± 10,3, p<0,001, εe: 11,7 ± 5,9 vs 21,1 ± 8,3 p<0,001, εa: 7,6 ± 4,1 vs 16,8 ± 6,1, p<0,001). Al contrario, non è stata osservata nessuna differenza tra il gruppo di pazienti con ccTGA e con HCM riguardo la funzione del LA (EF: 41,6 ± 15,1 vs 42,0 ± 10,1, εs: 19,0 ± 8,3 vs 22,6 ± 8,8, εe: 11,7 ± 5,9 vs 12,6 ± 7,0, εa: 7,6 ± 4,1 vs 10 ± 3,7). Per quanto riguarda i parametri morfologici, i pazienti con ccTGA presentavano dei volumi del LA maggiori rispetto sia al gruppo di controllo che ai pazienti con HCM.

Conclusioni. I pazienti con ccTGA presentano un'alterata funzione atriale sinistra ed un aumento significativo del volume, compatibili con la presenza di disfunzione diastolica. Saranno necessari ulteriori studi per valutare l'impatto clinico di questo dato morfo-funzionale.

A504: COMPARATIVE EFFECTIVENESS OF ORAL THERAPIES TARGETING THE PROSTACYCLIN PATHWAY IN PULMONARY ARTERIAL HYPERTENSION: A SYSTEMATIC REVIEW AND NETWORK META-ANALYSIS

Giovanna Manzi (a), Marco Valerio Mariani (a), Domenico Filomena (a), Silvia Papa (a), Tommaso Recchioni (a), Carmine Dario Vizza (a), Roberto Badagliacca (a)

(a) POLICLINICO UMBERTO I - ROMA

Background. Oral prostanoids are recommended in patients with pulmonary arterial hypertension (PAH) and a unsatisfactory response to first-line therapy.

Objective. To compare effectiveness of oral therapies targeting the prostacyclin pathway in PAH patients.

Methods. An online search of Medline, Cochrane Registry, Scopus and EMBASE libraries (from inception to May, 1 2020) was performed. Eight randomized controlled studies were included in the meta-analysis involving 3023 patients, of whom 828 receiving oral treprostinil, 607 patients receiving selexipag, 125 patients receiving beraprost, and 1463 patients received placebo.

Results. As compared to placebo, oral treprostinil (WMD 9.05, 95% CI 3.0280-15.0839, p=0.0032) and beraprost (WMD 21.98, 95% CI 5.0536-38.9063, p=0.0109) arms significantly increased 6 minute walking distance (6MWD) at follow-up from baseline, whereas selexipag use was associated with a non-significant increase in 6MWD (WMD 15.41, 95% CI -0.6074; 31.4232, p=0.0593). Compared to placebo, the risk of clinical worsening was significantly lowered by selexipag (RR 0.47, 95% CI 0.35 – 0.65, p<0.001) and oral treprostinil (RR 0.65, 95% CI 0.46–0.90, p 0.012), whereas a non-significant reduction of the outcome was related to beraprost use (RR 0.70, 95% CI 0.36–1.38, p 0.31). No significant difference in 6MWD change and clinical worsening reduction were found among oral treprostinil and selexipag. Beraprost use less frequently caused adverse events as compared to selexipag and oral treprostinil.

Conclusions. No differences in 6MWD change, clinical worsening reduction and adverse events rates were found among oral treprostinil and selexipag, resulting in similar efficacy and safety profile.

A505: CARATTERISTICHE ECOCARDIOGRAFICHE ED IMPATTO PROGNOSTICO DELL'ADATTAMENTO DEL VENTRICOLO DESTRO E DELL'ACCOPPIAMENTO VENTRICOLO-ARTERIA POLMONARE NEI PAZIENTI CON SARCOIDOSI

Simona Pavoncelli (a, b), Francesco Morrone (a, b), Matilde Lambardi (a, b), Elvira Delcuratolo (a, b), Maria Cristina Tavera (c), Elena Bargagli (d), Alberto Palazzuoli (a)

(a) UNITÀ DI MALATTIE CARDIOVASCOLARI, DIPARTIMENTO CARDIO-TORACO-VASCOLARE AOUS, UNIVERSITÀ DEGLI STUDI, SIENA; (b) SCUOLA DI SPECIALIZZAZIONE IN MALATTIE DELL'APPARATO CARDIOVASCOLARE, DIPARTIMENTO DI BIOTECNOLOGIE MEDICHE, UNIVERSITÀ DEGLI STUDI, SIENA; (c) CARDIOLOGIA CLINICO-CHIRURGICA, AOU SENESE, OSPEDALE SANTA MARIA ALLE SCOTTE, SIENA; (d) CLINICA DI MALATTIE APPARATO RESPIRATORIO, DIPARTIMENTO SCIENZE MEDICHE, CHIRURGICHE E NEUROSCIENZE, UNIVERSITÀ DEGLI STUDI DI SIENA

Background. La sarcoidosi è universalmente inserita tra le patologie polmonari restrittive e ha una prognosi variabile in base al progressivo coinvolgimento polmonare e alla relativa ripercussione a carico del circolo polmonare. Tuttavia, la progressione di malattia cambia in relazione al coinvolgimento temporale e all'estensione delle alterazioni polmonari e agli effetti sul ventricolo destro e sul circolo polmonare. In considerazione della potenziale ripercussione cardiaca, lo studio funzionale del cuore è diventato rilevante per la valutazione e lo screening in questi pazienti. Nonostante ciò, l'impatto della funzione del ventricolo destro (RV) e l'accoppiamento ventricolo-arteria polmonare in questo ambito è stato poco studiato.
Scopo dello studio. Valutare la prevalenza di ipertensione polmonare e disfunzione del ventricolo destro in pazienti con sarcoidosi; analizzare l'impatto prognostico dei parametri ecocardiografici tradizionali ed emergenti in un periodo di follow up medio di 2 anni.
Metodi. I pazienti sono stati sottoposti ad una valutazione clinico-spirometrica e pulsossimetrica. La valutazione ecocardiografica è stata eseguita secondo le linee guida dell'American Society of Ecocardiography. I diametri del ventricolo destro sono stati misurati nella proiezione 4-camere al basale. Le PAPs sono state valutate sulla valvola tricuspide mediante analisi del CW doppler. Il parametro TAPSE è stato ottenuto usando la metodica M-mode posizionando il cursore in corrispondenza della porzione laterale dell'anello tricuspidalico. L'onda S' è stata misurata utilizzando il metodo TDI in sede basale-laterale dell'anello tricuspidalico. L'accoppiamento ventricolo-arteria polmonare è stato analizzato usando il TAPSE/PAPs ratio e il S'/PAPs ratio. L'analisi dello strain del RV è stata ottenuta in proiezione 4 camere con il metodo speckle tracking specifico sulla parete libera del ventricolo destro.
Risultati. Abbiamo incluso 191 pazienti con diagnosi di sarcoidosi polmonare. L'aumento della PAPs>35 mmHg è stato trovato in 62 pazienti. Un incremento del diametro del RV>40 mm è stato riscontrato in 45 pazienti. Una riduzione della funzione longitudinale stimata mediante TAPSE ed onda S' è stata riscontrata in 63 pazienti. Infine, 55 pazienti hanno mostrato un RV STRAIN <21. La riduzione del rapporto TAPSE/PAPs e la diminuzione del rapporto onda S'/PAPs sono stati identificati rispettivamente in 32 e 58 pazienti. Non è stata dimostrata una correlazione significativa tra il diametro del RV e la PAPs (r=0.34), mentre lo strain ventricolare era correlato con l'onda S e con il TAPSE (r=0.72 e r=0.65 rispettivamente). Infine, è stata dimostrata una correlazione tra la DLCO <70% ed un incremento della PAPs e decremento della funzione ventricolare destra (r=0.78 e r 0.63 rispettivamente). Le analisi effettuate durante il follow up hanno mostrato che PAPs aumentata, TAPSE ridotta e decremento dello strain longitudinale erano correlate con una prognosi avversa (HR 2.3, HR 1.5 e HR 1.88 rispettivamente). Infine, un ridotto accoppiamento ventricolo-arteria polmonare nei pazienti con PH (ipertensione polmonare) evidenziato sia mediante rapporto TAPSE/PAPs sia S'/PAPs era indicativo di un incrementato rischio (HR 1.8 e HR 2.1 rispettivamente).
Conclusioni. Una rilevante percentuale di pazienti con sarcoidosi mostra un incremento delle pressioni polmonari associato ad una disfunzione ventricolare destra. L'ipertensione polmonare e una ridotta funzione RV sono correlate ad un outcome peggiore. Un alterato rapporto di accoppiamento ventricolo- arteria polmonare è indicativo di prognosi infausta in pazienti con evidenza di ipertensione polmonare dovuta a sarcoidosi.

A506: COMPARATIVE ASSESSMENT OF MYOCARDIAL WORK INDEX IN UNIVENTRICULAR AND BIVENTRICULAR HEART FAILURE PATIENTS

Giulia Pelaia (b), Rosalba De Sarro (b), Alessia Mendicino (b), Martina Avesani (a), Domenico Sirico (a), Elena Reffo (a), Isabella Leo (c), Daniela Concolino (e), Daniele Torella (c), Salvatore De Rosa (d), Roberta Biffanti (a), Giovanni Di Salvo (a)
(a) DEPARTMENT OF WOMAN'S AND CHILDREN'S HEALTH, UNIVERSITY OF PADUA; PAEDIATRIC RESEARCH INSTITUTE (IRP), FOUNDATION CITTÀ DELLA SPERANZA, PADUA, ITALY; (b) PAEDIATRIC CARDIOLOGY AND CONGENITAL HEART DISEASE UNIT, DEPARTMENT OF EXPERIMENTAL AND CLINICAL MEDICINE, MAGNA GRAECIA UNIVERSITY, CATANZARO, ITALY; (c) DEPARTMENT OF EXPERIMENTAL AND CLINICAL MEDICINE, MAGNA GRAECIA UNIVERSITY, CATANZARO, ITALY; (d) DEPARTMENT OF MEDICAL AND SURGICAL SCIENCES, MAGNA GRAECIA UNIVERSITY, CATANZARO, ITALY; (e) PAEDIATRIC UNIT, DEPARTMENT OF SCIENCE OF HEALTH, MAGNA GRAECIA UNIVERSITY, CATANZARO, ITALY

Background. The Fontan operation has significantly improved survival in single ventricle patients; however, cardiac function and exercise capacity may decline over time compared to patients with biventricular circulation. Quantitative assessments of the impact of Fontan circulation on myocardial work have been lacking. Recently, a non-invasive method for calculating myocardial work (MW), using speckle tracking analysis and estimation of left ventricular (LV) pressure from brachial artery cuff pressure, has been introduced and used to elucidate and quantify mechanisms of heart failure in biventricular circulations.
Purpose. This study aims to: 1) evaluate the diagnostic performance of non-invasive myocardial work indices in predicting subclinical myocardial impairment in univentricular hearts with Fontan circulation; 2) evaluate and quantify the different features of cardiac work in univentricular hearts and in biventricular hearts with reduced or preserved ejection fraction.
Methods. The study population comprised a total of 140 patients: 47 Fontan patients, 47 healthy age- and sex-matched controls (CTRL), 23 patients with dilated cardiomyopathy (DCM) and HFrEF, and 23 patients with HFpEF. Ventricular systolic function and global longitudinal strain (GLS) were assessed, and cardiopulmonary exercise tests were conducted. Global myocardial work index (MWI), along with measures of Global Constructive Work (MCW), Wasted Work (MWW), and Work Efficiency (MWE), were calculated based on the LV pressure-strain loops.
Results. Fontan patients exhibited significantly reduced MWI, MCW, and MWE compared to healthy CTRL (p<0.001, p=0.001, p=0.001, respectively). Additionally, GLS and ejection fraction (EF) were significantly lower in Fontan patients (p<0.001, p<0.002). Even Fontan patients with normal EF had lower MWI values compared to CTRL (p<0.05). Those with functional systemic right ventricles also showed reduced MWE compared to patients with functional systemic left ventricles (p=0.030). Patients with HFrEF exhibited significantly reduced MWI, MCW, and MWE, and significantly increased MWW compared to Fontan patients CTRL (p<0.001, p=0.001, p=0.001, p=0.001 respectively). Fontan patients exhibited significantly reduced MWI, and MCW compared to HFpEF patients (p<0.001, p 0.001, p<0.001, respectively) with comparable EF, MWE, and MWW. At univariate analysis, peak VO2 was significantly associated with age, atrioventricular regurgitation, and MWI in Fontan patients. Multivariate regression revealed that lower peak VO2 was linked to older age (p=0.003) and lower MWI (p=0.026).
Conclusions. Fontan physiology is associated with unfavorable ventricular work. In univentricular hearts with preserved ejection fraction, MWI demonstrates significantly better performance compared to biventricular hearts with HFrEF, albeit still inferior to those with heart failure and preserved EF. Finally, MWI may serve as a more sensitive indicator of myocardial work impairment than EF and has the potential to predict exercise capacity in Fontan patients.

A507: MULTIPARAMETRIC EVALUATION OF SYSTEMIC RIGHT VENTRICLE IN PATIENTS WITH BIVENTRICULAR CIRCULATION: COMPARISON BETWEEN ADVANCED IMAGING AND CARDIOPULMONARY EXERCISE TEST DATA

Alice Pozza (a), Elena Reffo (a), Martina Avesani (a), Annachiara Cavaliere (b), Biagio Castaldi (a), Giovanni Di Salvo (a)
(a) PEDIATRIC CARDIOLOGY UNIT, DEPARTMENT OF WOMEN'S AND CHILDREN'S HEALTH, UNIVERSITY OF PADUA; (b) NEURORADIOLOGY UNIT, PEDIATRIC RADIOLOGY, UNIVERSITY OF PADUA

Background. Improvements in imaging techniques allowed implementation in understanding right ventricle (RV) physiology. RV might support systemic circulation, resulting in a condition called systemic RV (sRV). Biventricular versions of sRV include congenitally corrected transposition of the great arteries (ccTGA) and dextro-transposition of the great arteries (D-TGA) after Mustard or Senning procedure. sRV may cause a high burden of morbidity and premature mortality from heart failure. A close follow-up is therefore mandatory. Echocardiographic assessment of sRV is challenging due to peculiar shape of RV and lack of a standardized protocol to evaluate RV function. Cardiac magnetic resonance imaging (CMR) is a promising tool in the functional assessment of sRV. Cardiopulmonary exercise test (CPET) provides information about functional capability and exercise limitations of patients affected by sRV.
Aim. To evaluate function and exercise capability in a cohort of sRV patients with biventricular physiology by investigating the correlation between standard/speckle tracking echocardiography (STE), standard/feature-tracking CMR (FT-CMR) and CPET data, overcoming the lack of normal reference values.
Methods. Longitudinal study in a cohort of 14 patients with sRV and biventricular circulation. All patients underwent CPET with estimation of basal oxygen saturation, heart rate and oxygen consumption (VO2 max); advanced three-dimensional (3D) echocardiography with estimation of ejection fraction (EF) and STE; CMR and FT-CMR to quantify sRV deformation. Qualitative variables are reported as median values, standard deviation or percentage.
Results. Median age: 28.4±10.7 years; 57% female; median BSA 1.59±0.49 m^2. 57% ccTGA patients; 43% D-TGA patients: 28.5% after Mustard procedure and 14.5% after Senning procedure. Ongoing medical treatment: beta-blocker (28%), ACE-inhibitor (35%), sartan (21%), diuretic (14%), sacubitril-valsartan (7%), glifozine (7%); antiaggregant therapy (21%), anticoagulant therapy (7%). All patients presented sinus rhythm. Standard echocardiography: EF sRV 46.9±5.8%; GLS sRV -15.0±3.1%. FT-CMR analysis: EF sRV 48.6±4.3%; GLS sRV -21±4.06%. 50% of patients were grouped in NYHA functional class I, 50% in NYHA functional class II. CPET showed VO2 max 25.68 ± 6 ml/kg/min. CMR and echocardiographic data showed a good correlation between end diastolic volumes and GLS values. Strain analysis performed with echo and CMR documented correlation (r 0.76, p<0.005), furthermore correlation between end diastolic volume data was depicted (r 0.75, p<0.05), thus showing a reproducibility between the two imaging modalities. However, correlation between systolic volumes, EF and exercise capability was weak. This limitation refers primarily to tricuspid regurgitation, which is the main predictor of outcome for patients affected with sRV.
Conclusions. Assessment of sRV in biventricular physiology is challen-

ging. 3D echocardiographic evaluation might be hampered because of poor acoustic window and software limitations, as it is semi-automated and tends to poorly assess sRV because of left-convex interventricular septum shape. Functional assessment through GLS is easy to perform and allows a better correlation between echo and CMR imaging data. Tricuspid regurgitation remains crucial in predicting outcome of patients affected by sRV.

A508: PROGNOSTIC ROLE OF SIGNIFICANT TRICUSPID REGURGITATION IN PATIENTS WITH PULMONARY ARTERIAL HYPERTENSION AND PRESERVED RIGHT VENTRICULAR FUNCTION

Martina Moschella (b), Giulio Savonitto (a), Andrea Baccelli (b), Martina Maldera (e), Franceco Lo Giudice (d), Stefano Ghio (b)
(a) CARDIOTHORACOVASCULAR DEPARTMENT, UNIVERSITY HOSPITAL CATTINARA, ASUGI AND UNIVERSITY OF TRIESTE, TRIESTE, ITALY; (b) POLICLINICO FOUNDATION SAN MATTEO IRCCS, PAVIA, ITALY; (c) RESPIRATORY UNIT, ASST SANTI PAOLO E CARLO, SAN PAOLO HOSPITAL, DEPARTMENT OF HEALTH SCIENCES, UNIVERSITY OF MILAN, MILAN, ITALY; (d) HAMMERSMITH HOSPITAL CARDIOLOGY, LONDON, UNITED KINGDOM OF GREAT BRITAIN AND NORTHERN IRELAND; (e) UNIVERSITY OF FOGGIA, SCHOOL OF MEDICINE, FOGGIA, ITALY

Background. Tricuspid regurgitation (TR) is a common finding in patients affected by pulmonary arterial hypertension (PAH), resulting from right ventricular remodeling and impaired leaflet coaptation. Severe TR has been shown to be a marker for poor clinical, functional, and hemodynamic parameters in newly diagnosed patients with pulmonary hypertension.

Purpose. Our study aims to investigate the additive prognostic role of significant TR when associated with an echocardiographic parameter of right ventricular function, in a cohort of PAH patients.

Methods. We retrospectively included newly diagnosed patients with World Health Organization group 1 PAH, enrolled between 2012 and 2021. The primary endpoint was all-cause mortality. Firstly, we stratified patients based on their baseline Tricuspid Annular Plane Systolic Excursion (TAPSE) values, using a cut-off of 17 mmHg. We then further stratified each TAPSE group based on the presence of Significant TR, defined as at least Moderate TR at echocardiogram. The prognostic impact of TAPSE ≤17 mm and significant TR on the overall population was assessed using univariate Cox regressions. Subsequently, significant TR impact on survival was assessed stratifying patients based on TAPSE values.

Results. Of the 147 patients included (71% females), 90 (61%) exhibited a TAPSE ≤17 mm, while 57 (39%) a TAPSE>17 mm. Notably, those with lower TAPSE displayed a more severe disease profile, with lower Fractional Area Change (FAC), lower PeakVO2 levels at Cardiopulmonary Exercise Testing (CPET), higher Mean Pulmonary Artery Pressures (52 ± 11 mmHg vs. 45 ± 12 mmHg, p=<0.001), higher Pulmonary Vascular Resistances (PVR) (14 ± 6 WU vs. 9 ± 6 WU, p=<0.001), and lower Stroke Volume Index (24 ± 9 ml/m2 vs. 29 ± 10 ml/m2, p=0.006). Moreover, patients with lower TAPSE values had higher COMPERA risk scores and received more aggressive vasoactive therapy upon discharge. When considering only patients with preserved TAPSE stratified on the presence of significant TR, the two subpopulations were similar in terms of demographics, comorbidity profiles, functional class, 6-minute walk test performance, COMPERA scores, and therapy at discharge. The presence of significant TR was associated with higher values of PVR (11 ± 8 WU vs 8 ± 5 WU, p=0,035). A baseline TAPSE ≤17 mm was not associated with increased overall mortality (HR 0.93, 95%CI 0.56-1.54, p=0.782). However, while significant TR was linked to increased overall mortality (HR 2.23, 95%CI 1.20-4.14, p=0.012), it was strongly associated with higher mortality risk only in patients with preserved TAPSE (HR 9.10, 95%CI 2.62-31.29 p<0.001), but not in cases with TAPSE ≤17 mm (HR 0.94, 95%CI 0.43-2.03, p=0.871).

Conclusions. Our study shows that in therapy-naïve patients with PAH, moderate to severe tricuspid regurgitation is associated with an increased risk of all-cause mortality. However, when considering right ventricular function, low TAPSE values are not associated with an increased risk of all-cause mortality. Notably, significant tricuspid regurgitation (TR) retains its prognostic impact only in patients who maintain preserved right ventricular function (TAPSE>17 mm), while significant TR loses its negative prognostic strength when associated with right ventricular dysfunction. Further studies are needed to delve into the reasons behind this and confirm our findings.

A509: AETIOLOGY MEDIATED PROGNOSTIC IMPLICATIONS OF RENAL DYSFUNCTION IN PULMONARY ARTERIAL HYPERTENSION

Giulio Savonitto (a), Davide Barbisan (a), Pietro Ameri (c), Carlo Maria Lombardi (d), Alberto Giannoni (e), Simonetta Monti (e), Mauro Driussi (f), Piero Gentile (g), Luke Howard (b), Matteo Toma (c), Matteo Pagnesi (d), Valentino Collini (f), Marianna Adamo (d), Luciana D'Angelo (g), Edoardo Airò (e), Marco Metra (d), Andrea Garascia (g), Francesco Lo Giudice (b), Gianfranco Sinagra (a), Davide Stolfo (a)
(a) DIVISION OF CARDIOLOGY, CARDIOVASCULAR DEPARTMENT, AZIENDA SANITARIA UNIVERSITARIA INTEGRATA DI TRIESTE (ASUITS), TRIESTE, ITALY; (b) HAMMERSMITH HOSPITAL, IMPERIAL COLLEGE NHS TRUST, LONDON, UK; (c) CARDIOVASCULAR DISEASE UNIT, IRCCS OSPEDALE POLICLINICO SAN MARTINO, GENOVA, ITALY; DEPARTMENT OF INTERNAL MEDICINE, UNIVERSITY OF GENOVA, GENOVA, ITALY; (d) CARDIOLOGY UNIT, DEPARTMENT OF MEDICAL AND SURGICAL SPECIALTIES, RADIOLOGICA SCIENCES AND PUBLIC HEALTH UNIVERSITY, SPEDALI CIVILI OF BRESCIA, BRESCIA, ITALY; (e) CARDIOTHORACIC AND VASCULAR DEPARTMENT, UNIVERSITY HOSPITAL OF PISA, PISA, ITALY; (f) CARDIOLOGY, CARDIOTHORACIC DEPARTMENT, ASUFC, UDINE, ITALY; (g) DE GASPERIS CARDIO CENTER, NIGUARDA HOSPITAL, MILANO, ITALY

Background. Renal dysfunction is frequent in pulmonary arterial hypertension (PAH) and has important prognostic implication. The aetiology of renal dysfunction in PAH can be heterogeneous and includes cardiorenal syndrome (CRS) and right heart failure-induced neurohormonal activation, but also primary chronic kidney disease which is increasing due to the changing epidemiology of PAH. Different aetiologies might have different impact on prognosis and different evolution over time.

Purpose. In this multicenter, retrospective study we analyzed the different prognostic implications of renal failure in PAH based on its aetiology (i.e. mediated by congestion vs primary renal disease).

Methods. We retrospectively studied incident PAH patients from seven tertiary care centers for the management of the disease, diagnosed from April 2001 to November 2022. Renal dysfunction was defined as estimated glomerular filtration rate (eGFR) <60 ml/min/1.73 m^2 and stratified according to the median value of right atrial pressure (RAP) measured invasively in the overall population. Primary outcome was 5-year all-cause mortality. Unadjusted survivor functions were estimated using the Kaplan-Meier method. The association between renal failure and outcome in the overall population and stratified by RAP was assessed at univariable analysis and after adjustment for the ESC/ERS risk stratification tool.

Results. In total, 358 patients were included (mean age 59 ± 16 years, 67% female) and 105 (29%) had renal dysfunction (i.e. eGFR <60 ml/min/1.73 m^2). Patients with renal dysfunction were older, had more comorbidities, more impaired functional capacity and higher natriuretic peptides. Main echocardiographic and invasive hemodynamic metrics were similar. Patients with renal dysfunction were at higher risk according to the ESC/ERS risk stratification tool. Unadjusted (hazard ratio – HR- 1.7, 95%CI 1.1-2.8, p=0,19) and ESC/ERS risk stratification tool adjusted survival (HR 1.8, 95%CI 1.1-2.8, p=0.018) was worse in patients with renal dysfunction. However, when the overall population was stratified according to median RAP (203 patients with RAP≤8 mmHg vs 155 with RAP>8 mmHg), renal dysfunction was significantly associated with lower survival only in patients with RAP≤8 mmHg (HR 2.2, 95%CI 1.2-4.1, P=0,013), irrespective of ESC/ERS risk stratification tool (HR 2.4, 95%CI 1.3-4.5, P=0,006).

Conclusions. Impaired renal function is frequently encountered in contemporary patients with incident PAH and may have different aetiology. The genesis of renal dysfunction can influence the relation between renal failure and prognosis, as only renal dysfunction in absence of venous congestion demonstrated an association with poorer survival. Our findings highlight the need of more precise approach to the definition of the aetiology of renal dysfunction in PAH in order to better characterize its implications on the outcome of the patients.

A510: MANAGEMENT OF PULMONARY VALVE DYSFUNCION IN CLINICAL PRACTICE: AN ITALIAN SURVEY

Biagio Castaldi (a), Gianfranco Butera (c), Mario Carminati (b), Massimo Chessa (b), Lorenzo Galletti (c), Alessandro Giamberti (b), Luca Giugno (b), Aurelio Secinaro (c), Vladimiro Vida (b), Giovanni Di Salvo (a)
(a) UNIVERSITY OF PADUA; (b) SAN DONATO HOSPITAL; (c) BAMBINO GESÙ HOSPITAL

Aim. Transcatheter Pulmonary Valve Implantation (TPVI), when feasible, is the first-line approach to pulmonary valve replacement. Our aim was to obtain a picture of current TPVI practice in Italy.

Methods. After conducting a literature review on TPVI, online surveys were devised by an Advisory Board of 10 experts from the three Italian reference centers for congenital heart diseases and sent electronically to physicians working either in implanting center or in referral non-implanting cardiologic centers.

Results. Approximately 450 physicians across Italy were invited to contribute. 82 physicians answered. EchoColorDoppler, electrocardiogram and cardiac magnetic resonance were considered the first line approach to monitor these patients, before and after TPVI. For non-implanting centers, reasons for non-referral of patients for PVR were: paucisymptomatic disease (67%) and patients' poor adherence to disease management programs (41%), but also the lack of connections with specialized centers (33%). For implanters, the main reasons for refraining from TPVI were: high risk for coronary compression (67% first rank), the need for concomitant cardiac surgical procedures (39% first rank) and the unsuitable anatomy of the conduit (39% first rank). The availability of new larger valves of a self-expandable nature was indicated as a key technological development for expanding the cohort of patients currently eligible for TPVI.

Conclusions. Despite a non-invasive imaging protocol for the follow up and selection of patients candidate to TPVI is well implemented in Italy, there is still a lack in connections between non-implanting and implanting centers.

A511: SCREENING FOR PULMONARY ARTERIAL HYPERTENSION IN PATIENTS WITH SYSTEMIC SCLEROSIS. IS IT POSSIBLE TO IMPROVE SPECIFICITY?

Francesca Coppi (a), Francesca Tampieri (a), Matteo Boschini (a), Vernizia Morgante (a), Giulio Leo (a), Marco De Pinto (a), Salvatore Arrotti (a), Fabio Alfredo Sgura (a), Rosario Rossi (a), Amelia Spinella (a), Dilia Giuggioli (a), Giuseppe Boriani (a), Anna Vittoria Mattioli (a)

(a) UNIVERSITY OF MODENA AND REGGIO EMILIA, POLICLINICO DI MODENA, 41124, MODENA, ITALY

Background. Systemic sclerosis (SSc) is a common cause of type I pulmonary arterial hypertension (PAH). Transthoracic echocardiography (TTE) is the first line diagnostic tool for diagnose of cardiovascular involvement and can be supported from second line assessment as right heart catheterization (RHC). The aim of the study was to verify if the range suggested by guidelines of TAPSE/sPAP in patients with SSc is predictive of PAH and to correlate the TAPSE/sPAP ratios and the hemodynamic parameters (sPAP, PVR) for the RHC and with clinical parameter presence of telangiectasias and functional parameter (DLCO).

Methods and Results. From January 2023 to June 2023, 50 consecutive patients with systemic sclerosis (SSc), 94% female, were monitored in this prospective observational study. A total of 4 patients showed no PAH and 46 with PAH-SSc. The RHC showed high correlations with TAPSE/sPAP of 0.6 (p=0.00002) also for the terms used for its calculation sPAP (R=0.55, p=0.001) but not with TAPSE (R=0.01, p=NS). In subjects without PAH, the higher value TAPSE/sPAP ratio was indicative of an optimal afterload with good pulmonary arterial ventricle coupling. Secondly was evaluated the parameter in patients with PAH-SSc. The data derived from the 46 SSc patients with pre-capillary PAH had a TAPSE/sPAP ratio of 0.6. There was a trend of correlation among TAPSE/sPAP, PCWP, and PVR, but not with TAPSE; without a statistical significance, possibly due to the lack of data disposable for PCWP and PVR. This trend could be attributed to TAPSE/sPAP having a greater correlation with the afterload. Therefore, the ratio may be more useful than the load itself to determine the association to cardiac output, and arterial ventricle coupling. Was also found a slight inverse correlation between TAPSE/sPAP ratio and telangiectasias (R=-0.25, p<0.1) and a very strong one between TAPSE alone DLCO.

Conclusions. All the screening model have high sensitivity, important for reducing or eliminating missed diagnoses, but low specificity. We believe that the modification of TAPSE/sPAP cut off and the use of other functional and clinical parameter could perform better in specificity and reduction of referrals amount for RHC.

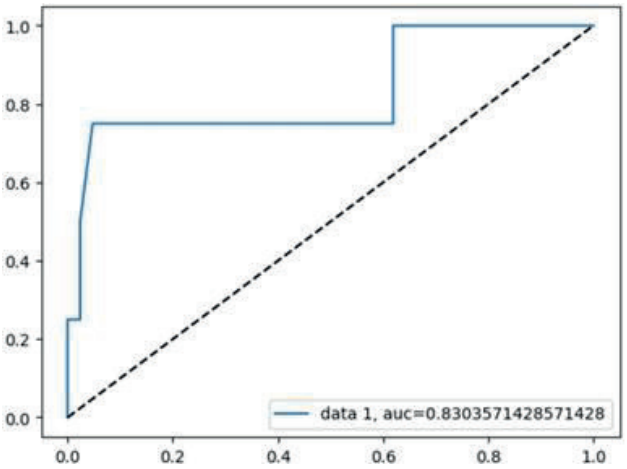

Figure 1. ROC curve for RHC starting for TAPSE/sPAP ratio.

A512: A VERY RARE CAUSE OF PRE-CAPILLARY PULMONARY HYPERTENSION: THE PAMI SYNDROME

Giulio Savonitto (a), Manuela Iseppi (a, b), Alessia Pin (c), Gianfranco Sinagra (a), Alberto Tommasini (c), Davide Stolfo (a)

(a) DIVISION OF CARDIOLOGY, CARDIOVASCULAR DEPARTMENT, AZIENDA SANITARIA UNIVERSITARIA INTEGRATA DI TRIESTE (ASUITS), TRIESTE, ITALY; (b) INTEGRATED UNIVERSITY HOSPITAL OF VERONA CAMPUS BORGO TRENTO; (c) BURLO GAROFALO PEDIATRIC INSTITUTE

We report the first known case of PAMI syndrome associated with pulmonary arterial hypertension (PAH) with a positive response to cyclophosphamide and pulmonary vasodilators. The clinical history begins at the age of 7 months with the onset of severe pancytopenia of unknown etiology and fever. The patient then developed migrating arthritis, recurrent fever, hepatosplenomegaly, and growth deficit. At the age of 17, worsening dyspnea prompted cardiac investigations, which revealed severe pre-capillary pulmonary hypertension. After a multidisciplinary evaluation, a dual therapy with vasoactive agents in combination with cyclophosphamide and prednisone was initiated, leading to rapid clinical improvement. After approximately 10 years of clinical stability, the Sildenafil discontinuation resulted in a clinical deterioration, necessitating its reintroduction, which provided benefit. Genetic revaluation in adulthood identified the underlying condition known as PAMI syndrome. Given that PAMI syndrome is characterized by an intense systemic inflammatory response, with many similarities with PAH related to Systemic lupus erythematosus (SLE), the parameters and the degree of functional autonomy responded appropriately to immunosuppressive therapy in the early stages and remained stable with vasoactive therapy. PAMI syndrome is a rare autoinflammatory disease which can be associated with pre-capillary pulmonary hypertension. The exact cause and optimal treatment approach are not fully understood yet. A combination of immunosuppressive agents and pulmonary vasodilators may be beneficial. Further studies are needed to confirm this association and to provide better treatment options.

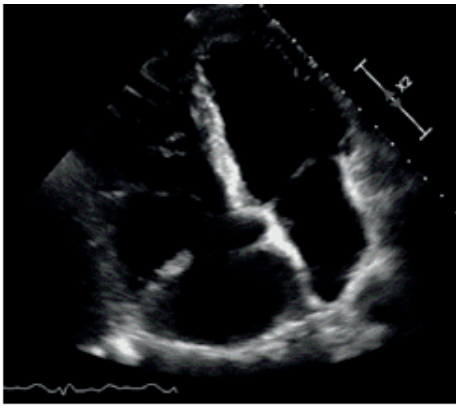

Figure 1. Echocardiogram in 2010. Fractional area change (FAC): 23%. Tricuspid annular plane excursion (TAPSE): 13 mm. Systolic pulmonary artery pressure: 90 mmHg. Right ventricular end-diastolic aera (RVEDA): 28 cmq.

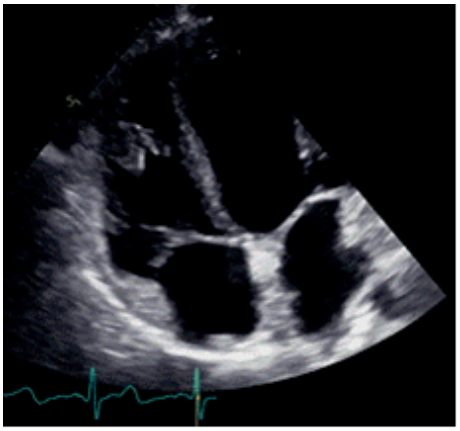

Figure 2. Echocardiogram in 2023. FAC: 47%. TAPSE: 24 mm. sPAP: 41 mmHg. RVEDA: 18 cmq.

A513: ENDOTHELIAL FUNCTION IN PAH: A COMPARISON BETWEEN HEALTHY INDIVIDUALS, SSC, AND SSC-PAH PATIENTS

Lucia Tricarico (a, c), Ester Bevere (c), Deborah Villani (c), Francesca Croella (c), Debora Ruggeri (c), Celeste Migliozzi (c), Damiano D'Alessandro (c), Nicola Di Nunno (c), Luciano Umberto Rossi (c), Mattia Granato (c), Rossella De Luca (c), Raffaele Capasso (c), Laura Giannetti (c), Stefano Annoscia (c), Corrado Sorrentini (c), Michele Correale (a), Massimo Iacoviello (a, c), Addolorata Corrado (b, c), Francesco Paolo Cantatore (b, c), Natale Daniele Brunetti (a, c)

(a) DEPARTMENT OF CARDIOLOGY, POLICLINICO RIUNITI FOGGIA; (b) DEPARTMENT OF RHEUMATOLOGY, POLICLINICO RIUNITI FOGGIA; (c) DEPARTMENT OF MEDICAL AND SURGICAL SCIENCES, UNIVERSITY OF FOGGIA

Background. Endothelial dysfunction plays a pivotal role in the development of various cardiovascular and vascular conditions, including those associated with systemic sclerosis (SSc) and pulmonary hypertension (PH). In the context of SSc, endothelial dysfunction within the pulmonary arteries contributes to elevated resistance and pressure within the pulmonary circulation.

Aim. To assess potential differences in peripheral endothelial function between healthy individuals and patients with SSc. Additionally, the

study aims to investigate potential differences in peripheral endothelial function between SSc patients with TR velocity <280 msec and those with TR velocity>280 msec.
Methods. Patients with SSc were followed up between February 2022 and June 2023. At the same time healthy individuals with similar characteristics were enrolled. Echocardiography and flow-mediated dilatation (FMD) of the radial artery to evaluate endothelial function were performed in an ambulatory setting.
Results. Sixty-seven patients with SSc (mean age 60.58 ± 10.06, female sex 94%) and forty-eight healthy individuals (mean age 57.98 ± 11.05, female sex 92%) were recruited for the study. Among the SSc patients, 11 exhibited a TR velocity>280 msec and a TAPSE <16 mm. We conducted a comparison of endothelial function between patients with SSc and healthy individuals, yielding statistically significant findings (basal radial artery diameter 0,16 cm ± 0,04 vs 0,21 cm ± 0,03, p value 0,049 and post dilatation radial artery diameter 0,21 cm ± 0,05 vs 0,27 ± 0,03, p value 0,004). Within the scleroderma population, we categorized participants into two groups: those with TR velocity <280 msec and those with TR velocity>280 msec. The comparison between these two subgroups revealed statistically significant differences in endothelial function (basal radial artery diameter 0,16 cm ± 0,04 vs 0,20 cm ± 0,06, p value 0,034 and post dilatation radial artery diameter 0,20 cm ± 0,05 vs 0,23 ± 0,07, p value 0,049).
Conclusions. Our study unveiled impaired peripheral endothelial function in patients with SSc, which correlated with an increase in tricuspid regurgitation velocity. This finding suggests that FMD could potentially serve as a novel tool for assessing and identifying early increments in resistance and pressure within the lung.

A514: THE RELATIONSHIP AMONG PERIPHERAL ENDOTHELIAL FUNCTION AND HEMODYNAMIC PARAMETERS IN PATIENT AFFECTED BY PULMONARY HYPERTENSION

Lucia Tricarico (a, b), Debora Ruggeri (b), Celeste Migliozzi (b), Ester Bevere (b), Francesco Chirivì (b), Luciano Umberto Rossi (b), Mattia Granato (b), Deborah Villani (b), Michele Correale (a, b), Massimo Iacoviello (a, b), Natale Daniele Brunetti (a, b)
(a) DEPARTMENT OF CARDIOLOGY, POLICLINICO RIUNITI FOGGIA; (b) DEPARTMENT OF MEDICAL AND SURGICAL SCIENCES, UNIVERSITY OF FOGGIA

Background. In pulmonary hypertension (PH), endothelial dysfunction and inflammation are key factors contributing to pulmonary vasculopathy. These processes are initiated by shear stress and hypoxia, leading to increased proliferation of endothelial and smooth muscle cells, vasoconstriction, and a heightened risk of thrombosis within the pulmonary circulation. While most research has centered on the pulmonary vasculature, there is limited understanding of the extent of peripheral endothelial damage in various vascular beds among PH patients.
Aim of the study. To evaluate the possible relationship between the peripheral endothelial function and the hemodynamic parameters of right heart catheterization, in order to provide a non-invasive method for the indirect evaluation of pulmonary pressure and vascular resistance, to predict if the PH is a precapillary or postcapillary, to select more accurately the patients who should undergo right heart catheterization.
Methods. Patients with suspected PH, based on symptoms, medical history and clinics were followed up between January 2021 and June 2023. All patients underwent physical examination, ECG, echocardiography, endothelial function and right heart catheterization at baseline.
Results. Ninety-five patients with suspected pulmonary hypertension (PH) were recruited for the study (mean age 62.69 ± 12.82 years, male sex 58%). Among them, sixty-two had pulmonary hypertension: twenty-eight had a pre-capillary form (mean age 63.75 ± 13.48 years, male sex 50%), and thirty-four had a post-capillary form (mean age 67.47 ± 12.45 years, male sex 53%). Thirty-three patients did not have pulmonary hypertension (mean age 56.88 ± 10.49 years, male sex 70%). The percentage of flow-mediated dilatation (FMD%) shows an inverse correlation (r: -0,26, p: 0,025) with precapillary PH and with the value of pulmonary arterial systolic pressures (PAsP) (r: -0,28, p: 0.016), instead it shows a linear correlation with the value of pulmonary capillary wedge pressure (PCWP) (r: 0,17, p:0.018).
Conclusions. Peripheral endothelial function may be related to hemodynamic parameters of patient affected by pulmonary hypertension. To validate these findings, additional multicenter studies are required.

A515: PERIPHERAL ENDOTHELIAL FUNCTION AND NEW CARDIOPULMONARY EXERCISE TEST PARAMETERS IN PATIENTS AFFECTED BY PULMONARY HYPERTENSION

Lucia Tricarico (a, b), Celeste Migliozzi (b), Debora Ruggeri (b), Francesco Chirivì (b), Ester Bevere (b), Deborah Villani (b), Raffaele Capasso (b), Luciano Umberto Rossi (b), Mattia Granato (b), Michele Correale (a), Massimo Iacoviello (a, b), Natale Daniele Brunetti (a, b)
(a) DEPARTMENT OF CARDIOLOGY, POLICLINICO RIUNITI FOGGIA; (b) DEPARTMENT OF MEDICAL AND SURGICAL SCIENCES, UNIVERSITY OF FOGGIA

Background. Endothelial dysfunction is a key factor in the development and progression of pulmonary hypertension. It leads to abnormal constriction and remodeling of pulmonary arteries, resulting in increased pulmonary vascular resistance. During cardiopulmonary exercise testing (CPET) in patients with pulmonary hypertension, reduced exercise capacity, impaired oxygen uptake, and increased dead space ventilation often become apparent. These CPET findings reflect the adverse impact of pulmonary hypertension on exercise tolerance.
Aim. To investigate the potential correlation between peripheral endothelial function and new cardiopulmonary exercise test parameters (circulatory power and ventilatory power) in patients with suspected pulmonary hypertension (PH).
Methods. Patients with suspected PH, based on symptoms, medical history and clinics were followed up between January 2021 and June 2023. All patients underwent physical examination, ECG, echocardiography, endothelial function assessment by FMD, CPET and right heart catheterization at baseline.
Results. Ninety-five patients with suspected pulmonary hypertension (PH) were recruited for the study (mean age 62.69 ± 12.82 years, male sex 58%). Among them, sixty-two had pulmonary hypertension: twenty-eight had a pre-capillary form (mean age 63.75 ± 13.48, male sex 50%), and thirty-four had a post-capillary form (mean age 67.47 ± 12.45, male sex 53%). Thirty-three patients did not have pulmonary hypertension (mean age 56.88 ± 10.49, male sex 70%). The percentage of flow-mediated dilatation (FMD%) shows an inverse correlation with circulatory power (r: -0,39, p: 0.02) and ventilatory power (r: -0,42, p: 0.013).
Conclusions. Peripheral endothelial function could be linked to the functional capacity of patients with pulmonary hypertension. To validate these findings, additional multicenter studies are required.

A516: USE OF PAH-SYMPACT QUESTIONNAIRE IN REAL-LIFE

Veronica Vecchiato (a), Matteo Toma (a), Bertamino Matilde (a), Silvia Tanda (a), Martina Solimano (a), Martina Licausi (a), Giulia Guglielmi (a), Italo Porto (a, b), Pietro Ameri (a, b)
(a) DEPT. OF INTERNAL MEDICINE UNIVERSITY OF GENOVA, ITALY; (b) CARDIOLOGY UNIT, CARDIOTHORACIC AND VASCULAR DEPARTMENT (DICATOV), IRCCS, OSPEDALE POLICLINICO SAN MARTINO

Background. The Pulmonary Arterial Hypertension-Symptoms and Impact (PAH-SYMPACT) questionnaire is being used in clinical trials to quantify symptoms and impact of PAH. However, data about its performance in real-life are scant.
Methods. Consecutive patients with PAH evaluated at a single center between March and September 2022 were invited to complete the 1-day version of the PAH-SYMPACT questionnaire. Each item of the questionnaire is score from 0 to 4, with 0 being the smallest and 4 the greatest cardiovascular or cardiopulmonary symptom severity or physical or cognitive/emotional impact. The characteristics of subjects with PAH-SYMPACT total score below or above the median of the study sample were compared by means of the Fisher exact test or Mann-Whitney test. Next, an univariable linear regression analysis was performed with PAH-SYMPACT above the median value as dependent variable, followed by forward selection, to identify the correlates of worse PAH-SYMPACT score.
Results. 27 patients were included. The median PAH-IMPACT total score was 14 (8-24). Subjects with higher scores were more often female (92% vs 36%), had higher NYHA class (2.4±0.7 vs 1.6±0.5), peak tricuspid regurgitation velocity (4.1±0.6 vs 3.4±0.7 m/s) and pulmonary vascular resistance (8.6±4.2 vs 5.6±2.6 WU), and lower cardiac output (4.7±1.3 vs 5.5±1.2 L/min). Of these variables, female sex and NYHA were significantly associated with having above-median PAH-SYMPACT score (Figure), and the association persisted after forward selection [female sex: odds ratio (OR) 11.5, 95% confidence interval (CI) 5.34-17.6; NYHA: OR 9.13, 95%CI 0.40-17.9].
Conclusions. The 1-day PAH-SYMPACT questionnaire well discriminated patients with a higher PAH burden in this real-world cohort. Our results indicate an influence of sex on the score that needs to be further investigated.

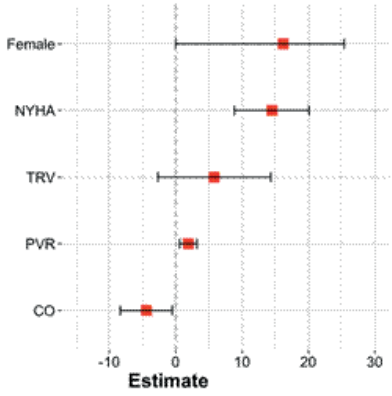

A517: AN UNEXPECTED COMPLICATION OF ICD IMPLANTATION AND ITS MANAGEMENT IN A PATIENT WITH SYSTEMIC RIGHT VENTRICLE: A CASE REPORT

Massimiliana Abbate (a, b), Giancarlo Scognamiglio (b), Flavia Fusco (b), Assunta Merola (b), Michela Palma (b), Nicola Grimaldi (b), Rosaria Barracano (b), Nunzia Borrelli (b), Papaccioli Giovanni (a, b), Davide Sorice (a, b), Giovanni Domenico Ciriello (b), Diego Colonna (b), Anna Correra (b), Emanuele Romeo (b), Berardo Sarubbi (b)
(a) UNIVERSITÀ DEGLI STUDI DELLA CAMPANIA LUIGI VANVITELLI; (b) ACHD UNIT - OSPEDALE MONALDI

A 36-years-old man with diagnosis of transposition of the great arteries (TGA), and previous surgical correction with Mustard operation was under regular follow-up at our ACHD tertiary centre. He had undergone a permanent transvenous PMK implant due to sinus node dysfunction at the age of 17. During follow-up a progressive decline of sRV sistolic function was observed along with repetitive episodes of non-sustained ventricular tachycardia at serial ECG Holter. Therefore, a PMK upgrading to cardiac resynchronisation therapy and implantable defibrillator (CRT-D) was performed with the insertion of an active fixation lead in the subpulmanory left ventricle apex. Three years later, in absence of any symptoms, routine echocardiography showed an abnormal position of the ventricular electrocatheter raising the suspicion of LV wall perforation. Accordingly, a cardiac CT was performed, confirming migration of the PMK tip into the mediastinal fat, in the absence of any effusion (Figure 1). After multidisciplinary review, we performed an electrophysiological study with induction of ventricular tachycardia, which was readily recognized and promptly interrupted by the defibrillator. Considering the complex anatomy and the normal function of the device, there was a consensus towards a conservative management with strict clinical and echocardiographic follow up. Few months later, the routine device control revealed high impedance levels, suggestive of fractured ICD lead. Therefore, the patient was scheduled for surgical removal of the device with repair of the ventricular tear with proleen suture, and implantation of epicardial electrodes with new generator placement in right pararectal abdominal pocket (Figure 2-3). After successful surgery, the patient was discharged home with a wereable defibrillator. Five months later a subcutaneous implantable cardioverter-defibrillator (S-ICD) was placed. At subsequent follow up the patient was stable and asymptomatic, with normal device electrical parameters and no further complications. In patients with TGA and atrial switch repair, the extremely complex anatomy may negatively impact on leads position and functioning. In this case, the ICD lead was correctly placed through the stiff intratrial baffle and actively fixed in the subpulmonary left ventricle, which, however, presents a smoother endocardium than a normal right ventricle. This peculiar characteristics may have caused the progressive migration of the lead until perforation of the left ventricle.

Figure 1

Figure 2

Figure 3

A518: UNA PROTESI VALVOLARE MECCANICA IN GRAVIDANZA, OLTRE LE LINEE GUIDA.

Pietro Pigò (a), Gabriele Egidy Assenza (b), Emanuela Angeli (b), Ylenia Bartolacelli (b), Ambra Bulgarelli (b), Cristina Ciuca (b), Emanuela Concetta D'Angelo (b), Gaetano Domenico Gargiulo (b), Gianluigi Pilu (c), Andrea Donti (b)
(a) SCUOLA DI SPECIALIZZAZIONE IN MALATTIE DELL'APPARATO CARDIOVASCOLARE, UNIVERSITÀ DI BOLOGNA; (b) DIPARTIMENTO CARDIO-TORACO-VASCOLARE, IRCCS AZIENDA OSPEDALIERO-UNIVERSITARIA DI BOLOGNA; (c) DIPARTIMENTO OSPEDALE DELLA DONNA E DEL BAMBINO, IRCCS AZIENDA OSPEDALIERO-UNIVERSITARIA DI BOLOGNA

Donna di 30 anni, con diagnosi alla nascita di tunnel ventricolo sinistro-aorta e displasia della valvola aortica, sottoposta a tre interventi cardiochirurgici culminati nella sostituzione valvolare aortica con protesi meccanica bidisco, all'età di 21 anni, senza difetti residui. Successiva stabilità clinica (NYHA II), con gradiente medio trans-protesico di 30 mmHg. In terapia domiciliare con solo warfarin. Prima gravidanza, non pianificata, all'età di 28 anni, normodecorsa in terapia anticoagulante con enoxaparina sottocute, pur con aumento del gradiente trans-protesico medio fino a 53 mmHg (mismatch paziente-protesi di grado severo senza segni di severa disfunzione protesica), risoltosi dopo il completamento dell'allattamento. All'età di 30 anni riscontro di seconda gravidanza non pianificata, alla nona settimana. In seguito a discussione collegiale (Heart Pregnancy Team), è stata consigliata l'interruzione di gravidanza per rischio eccessivo (classe mWHO III, e rischio proibitivo di un eventuale quarto intervento cardiochirurgico). Per il rifiuto della paziente, si è deciso di proseguire con stretto follow-up. La terapia con warfarin è stata sostituita da eparina sottocute, partendo dal dosaggio di 6000 UI BID per il peso corporeo (58 kg), e successivo monitoraggio settimanale dell'attività anti-Xa, con range terapeutico 0.8-1.2 UI/mL (picco, 4 ore dopo la somministrazione) e ≥0.6 UI/mL (valle, pre-dose), e aggiustamento della dose fino al massimo raggiunto di 10000+8000 UI/die. Questa scelta, differente rispetto alle linee guida europee sulla gestione delle malattie cardiovascolari in gravidanza (ESC 2018), che raccomanderebbero la prosecuzione di warfarin quando la dose giornaliera è <5 mg, è stata dettata da due ragioni: il rischio, basso ma non accettato dalla paziente, di embriopatia da warfarin; e la possibilità di garantire uno stretto monitoraggio dei livelli di picco e valle dell'attività anti-Xa. Durante la gravidanza, interessata anche da infezione da SARS-CoV-2 sintomatica per tosse, si è assistito al lieve peggioramento della dispnea da sforzo e al progressivo incremento del gradiente transprotesico medio fino a 50 mmHg (misura ecodopplergrafica). È stato pianificato il parto alla 34° settimana, mediante taglio cesareo in anestesia generale, previa riduzione della dose di enoxaparina fino a 4000 UI in monosomministrazione e profilassi dell'endocardite infettiva, svoltosi senza complicanze e con successiva ripresa della terapia anticoagulante orale. La scelta di un parto cesareo in anestesia generale ha permesso di evitare il passaggio a eparina non frazionata, raccomandato dalle linee guida, in virtù della programmabilità dell'intervento e dell'assenza di puntura epidurale o spinale. La gravidanza costituisce una sfida nella gestione delle protesi valvolari meccaniche. Da un lato per il diverso assetto coagulativo, con maggiore probabilità di trombosi protesica e necessità di reintervento in emergenza. Dall'altro, per le aumentate richieste emodinamiche, in parte persistenti anche nel puerperio (anemia, allattamento), con possibile sviluppo di mismatch paziente-protesi. Tale gestione è possibile grazie al lavoro d'équipe di tutte le personalità mediche, assistenziali e sociali coinvolte e allo stretto monitoraggio della terapia anticoagulante parenterale.

A519: THROMBUS IN TRANSIT: A CHALLENGING THERAPEUTIC CHOICE

Gianmarco Bastianoni (a), Federico Paolini (a), Leonardo Brugiatelli (a), Michele Alfieri (a), Giulia Stronati (a), Michela Cottini (b), Simone Maffei (b), Federico Guerra (a), Giovanni Tarsi (b), Antonio Dello Russo (a)
(a) AZIENDA OSPEDALIERO-UNIVERSITARIA DELLE MARCHE; (b) AST PESARO URBINO

Introduction. Pulmonary embolism is an acute and potentially life-threatening condition characterized by the obstruction of one or more branches of the pulmonary artery by emboli. In a patient with pulmonary embolism, it is important to stratify the risk into low, intermediate-low, intermediate-high, and high-risk categories. High-risk pulmonary embolism is a specific condition characterized by hemodynamic instability defined as one of the following clinical presentations: cardiac arrest, obstructive shock, or persistent hypotension (>15 minutes). Only in this high-risk patient category fibrinolytic therapy is justified according to ESC guidelines.

Case description. An 85-year-old man presented to the emergency department with an episode of dyspnea that occurred at rest during the night, without any other associated symptoms. His medical history was unremarkable for cardiovascular events. Cardio-pulmonary examination showed no significant abnormalities or signs of heart failure. The initial electrocardiogram (ECG) revealed sinus tachycardia with previously unknown right bundle branch block (BBDx) and an S1Q3T3 pattern. Laboratory tests showed a slight elevation in troponin and BNP levels, along with a markedly elevated D-dimer. Suspecting pulmonary embolism (PE), a

pulmonary angiography CT was performed, confirming the diagnosis of bilateral sub-segmental PE. Bedside echocardiography showed normal biventricular size and preserved systolic function with moderate tricuspid regurgitation and an estimated pulmonary arterial pressure (PAPs) of approximately 50 mmHg. Given the hemodynamic stability of the patient, anticoagulant therapy with intravenous heparin was initiated, and the patient was admitted to the intensive care unit. Within 24 hours of admission, the patient experienced sudden loss of consciousness accompanied by hypotension and bradycardia, and volume resuscitation was initiated. The patient quickly regained consciousness, although mild confusion persisted. A follow-up echocardiogram revealed dilated and hypokinetic right heart chambers with a large floating thrombotic mass in the right ventricle. Despite not meeting the criteria for hemodynamic instability according to ESC guidelines, and in the absence of absolute or relative contraindications, fibrinolytic therapy with alteplase was initiated. A follow-up echocardiogram 2 hours after the start of therapy showed complete dissolution of the thrombotic mass with no worsening of the pulmonary condition. After 7 days of hospitalization without further complications, the patient was discharged home with appropriate treatment.
Conclusions. High-risk pulmonary embolism is characterized by hemodynamic instability. However, according to the latest ESC guidelines, this condition is defined by specific clinical criteria. The patient with "transit thrombus" without hemodynamic instability as defined by ESC criteria falls into a therapeutic gray area where the cardiologist must decide whether to pursue fibrinolytic therapy or not. The presented clinical case exemplifies the difficulty in making this decision and may support the use of fibrinolysis in this sub-category of patients, provided that there are no absolute or relative contraindications.

A520: ENDOCARDITE INFETTIVA DA BARTONELLA HENSELAE IN VENTRICOLO DESTRO A DOPPIA CAMERA

Lorenzo Bianchi (a), Vered Gil Ad (b), Giovanni Masoero (b), Italo Porto (a, b)
(a) DIPARTIMENTO DI MEDICINA INTERNA, UNIVERSITÀ DI GENOVA, GENOVA, ITALIA; (b) UNITÀ DI MALATTIE DELL'APPARATO CARDIOVASCOLARE, IRCCS OSPEDALE POLICLINICO SAN MARTINO, GENOVA, ITALIA

Introduzione. Le cardiopatie congenite sono associate a un aumentato rischio di endocardite infettiva, in particolare le cardiopatie cianogene, le cardiopatie con persistente shunt intracardiaco e le cardiopatie con vizi valvolari emodinamicamente significativi. Il ventricolo destro a doppia camera (Double Chambered Right Ventricle, DCRV) è una rara cardiopatia congenita in cui il ventricolo destro è suddiviso da una fascia muscolare o da ipertrofia trabecolare infundibolare, in due camere, una prossimale ad alta pressione e una distale a bassa pressione, e possono coesistere altri difetti cardiaci e malformazioni valvolari. Riportiamo un caso di un uomo di 46 anni con prima diagnosi di DCRV complicata da endocardite infettiva da Bartonella Henselae con interessamento tri-valvolare e della parete del ventricolo destro.
Descrizione del caso. Si tratta di un uomo di 46 anni, ex fumatore e consumatore moderato di alcolici. Alla nascita diagnosi di stenosi polmonare congenita non severa, seguita nei primi anni di vita ma successivamente autosospensione dei controlli. Accedeva in PS per dispnea ingravescente, edemi e lesioni petecchiali agli arti inferiori. Alla TC torace/addome riscontro di embolia polmonare segmentaria destra e subsegmentaria bilaterale, linfoadenomegalie ilari bilaterali, addensamenti polmonari nodulari e pseudonodulari con cavitazioni, cardiomegalia ed epatosplenomegalia. All'ecocardiografia trans-toracica sospetta DCRV con severa ostruzione medio-ventricolare destra associata a severa dilatazione della camera prossimale e segni di sovraccarico (D-shape del ventricolo sinistro), rigurgito tricuspidalico massivo, rigurgito polmonare severo, plurime macrovegetazioni fluttuanti sulle valvole tricuspide, aortica, polmonare, sul fascio muscolare ostruttivo e lungo la parete del ventricolo destro (VD). Il caso è stato poi approfondito con ulteriori metodiche di imaging: ecocardiografia trans-esofagea, RM e TC Cardiaca, che hanno confermato la diagnosi di DCRV, evidenziando uno spesso fascio muscolare anomalo tra il setto interventricolare e le ipertrabecolature endocardiche della parete libera del VD, determinante una severa stenosi sotto-infundibolare. Sono state inoltre diagnosticate una displasia della valvola polmonare con dilatazione del tronco polmonare, un difetto del setto interventricolare perimembranoso con shunt sx-dx e un'endocardite con interessamento plurivalvolare e della parete libera del VD. Dagli accertamenti colturali ed immunologici è stato indentificato l'agente eziologico dell'endocardite, la Bartonella Henselae, batterio gram-negativo spesso trasmesso dal graffio dei gatti. Questa infezione, in presenza di fattori predisponenti, può complicarsi con endocardite e nei casi più gravi portare vasculiti e malattia granulomatosa epato-splenica. Il paziente è stato ulteriormente sottoposto a biopsia cutanea evidenziante vasculite cutanea leucocitoclasica e a RM encefalo e PET total-body che escludevano ulteriori embolizzazioni settiche. È stata avviata una terapia antibiotica mirata con Doxiciclina e Gentamicina che ha portato al miglioramento clinico e alla regressione delle vegetazioni. Il paziente è stato successivamente sottoposto ad intervento cardiochirurgico di disostruzione della stenosi infundibolare del VD, chiusura del difetto interventricolare, sostituzione valvolare polmonare e plastica tricuspidalica in assenza di complicanze.

A521: PLATYPNEA - ORTHODEOXIA SYNDROME RELATED TO PATENT FORAMEN OVALE UNMASKED BY SARS-COV2 INFECTION

Ludovica Massa (a, b), Valentina Cagnetta Domass (a, b), Francesca Bursi (a, b), Stefano Buratti (b), Marco Guazzi (a, b)
(a) UNIVERSITÀ DI MILANO; (b) OSPEDALE SAN PAOLO - MILANO

Platypnea-Orthodeoxia Syndrome (POS) is a rare and probably underdiagnosed syndrome that can be related to the presence of patent foramen ovale (PFO). Few cases of POS after COVID-19 have been reported in literature. We report a 77-year-old woman case presenting to the emergency department (ER) for a drop attack without loss of consciousness and dyspnea. She had an history of hypertension and was an ex-smoker. Remote medical history was remarkable for two previous hospitalizations for multifocal pneumonia and ischemic stroke, without sequelae. Upon arrival in the ER she was polypnoic with SpO2 85%, arterial blood gas (ABG) showed pO2 47mmHg, pCO2 39mmHg, after ventilation with reservoir mask 10 L/min SpO2 reached 100%. The patient tested positive for Sars-Cov2. Her chest computed tomography (CCT) scan excluded pulmonary embolism, but it showed bilateral basal band opacities same as in the anterior segment of the right lobe, consistent for atelectasis. Mild bronchiectasis and multiple costal fractures. Scintigraphy showed an increased perfusion in the atelectasis zone. She was treated with Remdesevir short course, intravenous corticosteroids and continuous positive airway pressure (CPAP) cycles. After two weeks she was still in need of CPAP despite negative swab for Sars-Cov2 and stable CCT scan. ABG was then performed in both ortho- and clinostatism. It documented a PaO2 decrease of 20 mmHg in orthostatism, therefore POS was suspected. Transthoracic echocardiogram (TTE) was performed, limited by poor acoustic window. It showed normal biventricular size and function with no significant valve disease. No signs of pulmonary hypertension. Contrast study with agitated saline solution demonstrated the presence of a significant right to left shunt at rest and during Valsalva maneuver. To better understand the site and morphology of the shunt, transesophageal echocardiography (TEE) was performed. It showed an atrial septal aneurysm with a large PFO during the whole cardiac cycle, which determined a severe right to left shunt. A prominent Eustachian valve was also noted, a known potential anatomic factor favoring POS. Transcatheter closure of PFO was successfully performed using an Amplatzer Occluder device in size 25/25mm through transfemoral access and combined angiography and TEE guidance. We hypothesized that in this patient the occurrence of Sars-Cov2 pneumonia caused a severe ventilation/perfusion (V/Q) mismatch due to a double mechanism. In addition to V/Q mismatch due to fibrotic evolution of portions of the lung parenchyma, there was an overlapping effect due to PFO causing a severe right to left shunt, which determined an acute manifestation of POS. The latter was the main determinant of the mismatch, indeed after the PFO closure we obtained a significant clinical benefit although not a complete remission and the patient could be discharged with low-flow oxygen support with nasal cannulas. We assume we were able to correct the main component of V/Q mismatch by closing the PFO, but another component still persisted due to the presence of fibrosis in the lungs. In the diagnostic work-up of acute dyspnea, it is important to look for POS, since it can be treatable with a minimally invasive approach.

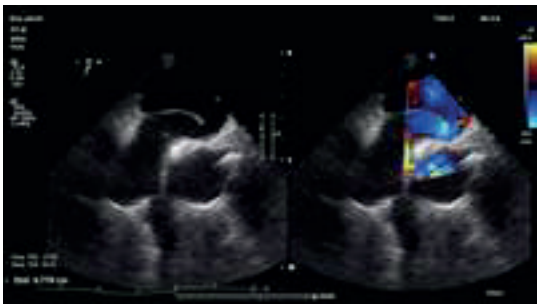

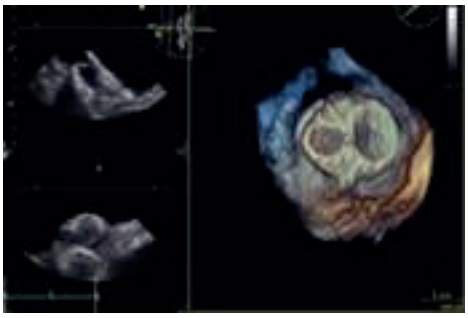

A522: FROM ARRHYTHMIC SYNCOPE TO CARDIAC SURGERY: A CASE REPORT

Nicola Cesani (a), Alessando Villaschi (a), Lucia Torracca (a), Gianluigi Condorelli (a), Monica Bocciolone (a)
(a) HUMANITAS UNIVERSITY

Introduction. Congenital anomalies of the coronary arteries affect less than 5% of the population. Altough usually detected as incidental findings with little to no significant consequence, approximately 20% of these anomalies carry the potential risk of causing coronary ischemia, which can lead to myocardial infarction, arrhytmia, and sudden cardiac death.

Case presentation. A 31-year-old woman, with no cardiac history or risk factors, was urgently admitted to our emergency department for syncope, preceded by heart palpitations and chest pain at rest. Her mother had undergone coronary artery bypass grafting (CABG) at the age of 34 due to a spontaneous left main (LM) coronary artery dissection. An initial transthoracic echocardiogram detected systolic curling of the posterior mitral annulus, although it appeared to have minimal clinical significance (mitral annular disjunction of 4-5mm with absence of Pickelhaube's sign). Electrocardiographic changes in the high lateral leads, despite negative serum troponin, hinted at possible ischemic involvement. A transesophageal echocardiography identified an abnormal origin of the LM coronary artery from the medial portion of the right coronary sinus, with inter-arterial cours leading to vascular compression, as evidenced on coronary CT scan. At coronary angiography, inducible myocardial ischemia under pharmacological stress with dobutamine was detected (instantaneosu wave-free ratio (iFR) on LAD: 0.88), despite a healthy epicardial coronary circulation. This procedure was complicated by the spontaneous focal dissection of the proximal right coronary artery and the late occlusion of the left radial artery, the site of arterial access, which were treated conservatively. In light of her suggestive family history, a next-generation sequencing (NGS) genetic study for major vasculopathies was conducted but turned out negative. After Heart Team evaluation, cardiac surgery was planned, involving the intraconal unroofing of the left coronary artery and a single coronary artery bypass (saphenous vein graft – posterior interventricular artery). No procedure related complication was noted and the patient was discharged after 14 days of cardiopulmonary rehabilitation.

Discussion and Conclusions. Anomalous aortic origin of a coronary artery (AAOCA), particularly interarterial and intramural types, are known to be the second leading cause of SCD in young athletes. Adopting a standardized patient evaluation approach and involving multidisciplinary consultation is the path to promote a more comprehensive and informed approach to patient care. Echocardiography is the initial diagnostic imaging method recommended, while advanced techniques like CTA or CMR provide detailed anatomical insight. Coronary angiography and subsequent functional assessment with pharmacologic agents are essential components of the diagnostic process, risk stratification and management decision. Current guidelines recommend surgical intervention for those patients with signs and/or symptoms of ischemia (class I). However, treating AAOLCA with an intramural course presents surgical challenges due to the unacceptably high incidence of graft failure caused by competitive flow. The transconal approach to unroof the trans-septal LM coronary artery, pioneered by Najm and colleagues, entails circumferentially transecting and extending the right ventricular infundibulum using autologous pericardium, and has shown excellent surgical outcomes in the short-term follow-up. This innovative surgical techinque offers a promising advancement in treating AAOLCA with favorable results.

A523: DIVERTICOLO CONGENITO DEL VENTRICOLO SINISTRO: UTILIZZO DELL'IMAGING MULTIMODALE PER LA DIAGNOSI E LA STRATIFICAZIONE DEL RISCHIO

Marcello Cosenza (a, b), Michele Morosato (a, b), Gabriele Paci (a, b), Riccardo Colombi (a, b), Eustachio Agricola (a, b), Federico Biondi (a)
(a) UNITÀ DI IMAGING CARDIOVASCOLARE, IRCCS OSPEDALE SAN RAFFAELE, MILANO, IT; (b) UNIVERSITÀ VITA-SALUTE SAN RAFFAELE, MILANO, IT

Introduzione. I diverticoli o aneurismi congeniti del ventricolo sinistro costituiscono un'entità rara la cui diagnosi è per lo più incidentale. Possibili complicanze comprendono la rottura, le aritmie ventricolari, il tromboembolismo, lo sviluppo di scompenso cardiaco congestizio e la morte cardiaca improvvisa. In assenza di un gold-standard, la diagnosi avviene per esclusione e l'imaging multimodale è chiave per distinguere questa entità dai più comuni aneurismi/pseudo-aneurismi ad eziologia ischemica, infiammatoria, autoimmune o quali manifestazione di cardiomiopatie. In mancanza di linee guida specifiche, la necessità di trattamento è strettamente individualizzata e orientata dalla modalità di presentazione.

Caso clinico. Ragazzo di 21 anni con riscontro elettrocardiografico di onde Q patologiche isolate nelle derivazioni aVL, V5 e V6 durante valutazione per rilascio di idoneità sportiva. Negava familiarità per morte cardiaca improvvisa o cardiomiopatie. Asintomatico per angor e dispnea a riposo o sotto sforzo. Non storia di sincope o palpitazioni a riposo o da sforzo. All'ecocardiogramma trans-toracico lieve disfunzione sistolica e dilatazione del ventricolo sinistro (FEVS 47%, VTDi 80 ml/mq), in presenza di ampio aneurisma coinvolgente la parete antero-laterale. Ventricolo destro nei limiti per dimensioni e funzione (figura, A-B). Ecocardiogramma sotto sforzo, massimale per FC raggiunta, negativo per aritmie da sforzo e nel recupero. Alla cine-RMN cuore con mezzo di contrasto evidenza di multipli diverticoli/aneurismi della parete anteriore del ventricolo sinistro, a parete assottigliata e con ridotta contrattilità, estesi dal passaggio basale-medio al passaggio medio-apicale (6.5 x 4 x 2.5 cm) (figura, C). Lieve riduzione della funzione sistolica globale. Normale massa miocardica. Normali valori di T1 e T2 ed assenza di edema o di late gadolinium enhancement (LGE). Si procedeva a ventricolografia e coronarografia che documentavano coronarie epicardiche indenni da lesioni stenosanti ed assenza di ponti miocardici (figura, D). Holter ECG delle 24 ore negativo per aritmie. A completamento diagnostico è stata eseguita biopsia endomiocardica (BEM) del ventricolo destro che ha evidenziato cardiomiociti di normale morfologia, senza evidenza istologica di cellule infiammatorie, fibrosi sostituiva o necrosi. Test genetico per ricerca di mutazioni geniche note associate a cardiomiopatie attualmente ancora in corso. Vista l'anamnesi familiare negativa per storia di cardiomiopatia o di morte cardiaca improvvisa, l'assenza di sintomi di pertinenza cardiologica nonostante vita attiva (atleta non agonista), la RMN e la BEM entrambe negative per alterazioni di tipo infiammatorio/sostitutivo a carico del miocardio, l'assenza di aritmie al monitoraggio elettrocardiografico a riposo e alle prove da sforzo è stato deciso di avviare il paziente a stretto follow-up clinico-strumentale ambulatoriale con idoneità ad eseguire attività sportiva non agonistica.

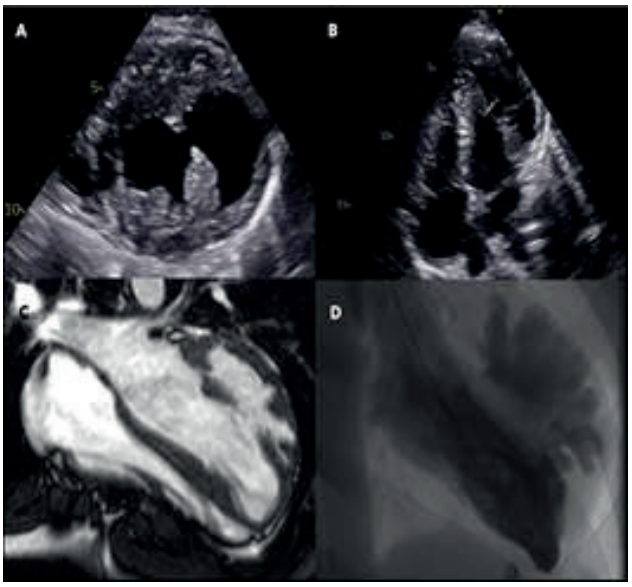

A524: STRANGER THINGS: SINDROME DI MARFAN O IMPOSTORE?

Vera Fico (a), Elena Pisani (a), Veronica Speranza Vitiello (a), Maria Tiziana Mele (a), Mattia Zampieri (b), Martina Berteotti (a), Iacopo Olivotto (b)
(a) CAREGGI; (b) MAYER

Caso clinico. Un paziente maschio di 65 anni è stato indirizzato presso il nostro centro per sospetta Sindrome di Marfan, in seguito al riscontro di dilatazione del bulbo aortico e all'indagine genetica con mutazione variabile di incerto significato (VUS) sul gene della fibrillina (FBN1) e pregressi episodi di lussazione articolare. Alla valutazione presso il nostro centro si presentava asintomatico, il fenotipo non appariva suggestivo per un habitus marfanoide, all'obiettività cardiologica si riscontrava soffio sistolico 2/6L che il paziente riferiva noto sin dalla giovane età. Non familiarità per sindromi aortiche. A completamento è stata eseguita ecocardiografia transtoracica, con riscontro di radice aortica di normali dimensioni ma tuttavia presentava aneurisma del seno coronarico destro, insufficienza aortica e presenza di DIV restrittivo peri-membranoso con shunt sinistro-destro con Vmax>4 m/s. Il reperto dell'aneurisma è stato confermato dall'AngioTC aorta toracica, restanti segmenti aortici risultati nel limite. Il caso è stato discusso collegialmente ed è stata posta indicazione alla riparazione chirurgica di entrambi i difetti.

Discussione. Gli aneurismi del seno di Valsalva sono molto rari, con un tasso di incidenza che varia dallo 0,1% al 3,5% di tutte le malattie cardiache congenite. L'associazione tra aneurisma del seno coronarico e DIV è stata riscontrata nel 20-30% dei casi. L'aneurisma dei seni di Valsalva è spesso il risultato dell'assenza del normale tessuto elastico muscolare che induce un assottigliamento della parete dei seni aortici. La presenza del DIV determina la mancanza di un supporto anatomico al seno coronarico, pertanto predisponendo ad un prolasso della cuspide verso il DIV inducendo insufficienza aortica. L'ipotesi più accreditata dell'associazione tra DIV e aneurisma del seno di Valsalva viene

ricondotta alla mancata fusione della porzione distale del setto bulbare durante la vita fetale. L'aneurisma si ritrova più comunemente a livello del seno coronarico destro, meno comunemente nel seno non coronarico, con un'incidenza rispettiva pari al 77% e 23%, e raramente a livello del seno sinistro. La presenza dell'aneurisma solitamente è asintomatica anche per lunghi periodi, occasionalmente può indurre sintomatologia conseguente alla compressione dell'arteria coronarica o alla rottura improvvisa dell'aneurisma che può essere spesso la prima manifestazione.
Conclusioni. Conseguentemente al riscontro del DIV associato ad aneurisma del seno coronarico è decaduta l'ipotesi iniziale di sindrome di Marfan ed è stata avvalorata l'ipotesi di un'alterazione nell'embriogenesi. La precoce riparazione dei seni coronarici è raccomandata per prevenire endocardite o un ulteriore aumento delle dimensioni dell'aneurisma con eccellenti risultati a lungo termine. È riportato un tasso di sopravvivenza del 95% a vent'anni. Se trattati conservativamente, i pazienti tipicamente muoiono di scompenso cardiaco ed endocardite entro un anno dall'insorgenza dei sintomi. In conclusione, i pazienti con aneurisma dei seni coronarici devono essere sottoposti ad un'attenta valutazione preoperatoria per l'eventuale identificazione della presenza di ulteriori difetti cardiaci coesistenti che possono apparire misconosciuti all'ecocardiografia transtoracica per cui è raccomandata l'esecuzione del ecocardiografia transesofagea o se tollerata la RMN cardiaca.

A525: REVERSE REMODELING OF RIGHT VENTRICLE IN A NOVEL DIAGNOSIS OF PULMONARY HYPERTENSION AND HIV, 3 YEARS FOLLOW-UP

Andrea Imporzani (a), Francesca Ceriani (a), Elena Ghirimoldi (a), Chiara Lauri (a), Michele Tirloni (a), Mariangela Lattanzio (a), Roberto De Ponti (a)
(a) UNIVERSITÀ DEGLI STUDI DELL'INSUBRIA

Introduction. Pulmonary arterial hypertension (PAH) is a severe and uncommon complication of HIV infection, with a prevalence of 0.5% among HIV-infected patients. This clinical and histopathologic phenotype is categorized among group I classification of PAH and it closely resembles idiopathic PAH.
Case description. We report the case of a Caucasian 42 years-old woman, who is smoker and has no cardiovascular history. In August 2020, she was admitted to the emergency department of the local hospital due to peripheral edema and worsening dyspnea in the last 6 months. The electrocardiogram (ECG) revealed sinus tachycardia (100 bpm), right ventricular strain, and right axial deviation. Transthoracic echocardiography showed markedly dilated right sections, with dilatation of pulmonary artery and d-shaped left ventricle. It also revealed moderate tricuspid regurgitation, with severe pulmonary hypertension and ubiquitous pericardial effusion. She had hypocapnia and elevated D-dimer and NT-proBNP levels. In the suspicion of pulmonary embolism, a CT scan was performed, which revealed no filling defects, but it collaterally detected lumbo-aortic lymphadenopathy. Therefore, serological tests were performed, and they revealed HIV positivity not previously diagnosed with a high viral load, markers of previous HBV infection, and no autoimmune markers. Right heart catheterization (RHC) was performed, and severe PAH was confirmed (mPAP 52 mmHg, PWAP 12 mmHg, PVR 10 WU, CI 2.5 l/min/sqm). HIV-associated PAH was eventually diagnosed, and highly active antiretroviral therapy (HAART) and specific PAH therapy were initiated, according to AMBITION protocol after evaluation of potential drug-drug interactions. During the follow-up, the specific dual therapy was titrated, serial echocardiograms and blood sampling analysis were performed, which showed progressive reverse remodeling of the right cardiac chambers (RHRR), normalization of NTproBNP (from 2532 to <125 ng/l stably), full recovery of functional capacity (6MWT 402 to 550 mt) and WHO class improvement (from IV to I). We also documented normalization of previous ECG alterations. RHC was repeated at 6 months, and it showed a clear improvement in hemodynamics (mPAP 31 mmHg, PWAP 11 mmHg, PVR 3.1 WU, CI 4.6 l/min/sqm), which confirmed clinical and echocardiographic data. The specific PAH therapy was well tolerated, and the patient remained asymptomatic. Furthermore, she achieved and maintained so far the "low risk" class, according ESC Guidelines 2022.
Discussion. PAH-HIV pathogenesis is still unclear; some of the virus proteins (GP-120, NEF, TAT) seem to play a key role by causing endothelial damage, altering the cell apoptosis/proliferation balance, and inducing the release of proinflammatory cytokines. To improve the otherwise severe prognosis of these patients, it is essential to act both through specific arterial vasodilator therapy and blocker of viral replication to turn off the proinflammatory stimulus and remodeling of the pulmonary circulation. This dual therapeutic approach aims at reducing pulmonary vascular resistance, to decrease afterload, and allow RHRR, a key element in determining the prognosis of these patients.
Conclusions. This clinical case is an example of how the synergistic action of the dual treatment approach can lead to RHRR, the most significant positive prognostic factor in PAH patients.

A526: UNMASKED ISCHEMIC ANOMALOUS ORIGIN OF CORONARY ARTERY BY INTRACORONARY FUNCTIONAL EVALUATION IN YOUNG ATHLETE

Enrico Incaminato (a, b), Davide Avenoso (a, b), Federica De Vecchi (b), Domenico D'Amario (a, b), Giuseppe Patti (a, b)
(a) UNIVERSITÀ DEGLI STUDI DEL PIEMONTE ORIENTALE 'AMEDEO AVOGADRO'; (b) AOU MAGGIORE DELLA CARITÀ DI NOVARA

Background. Anomalous Origin of Coronary Artery (AOCA) is a potential leading cause of Sudden Cardiac Death (SCD) in young adults, especially during physical exertion. Given the frequently asymptomatic nature of AOCA, early diagnosis poses often a clinical challenge. The clinical presentation is very heterogeneous but must be correctly framed for an early diagnosis and for correct prognostic stratification. Even after the diagnosis, it is important to univocally characterize the cause of the symptoms triggered by the myocardial ischemia induced by the anomalous course of the coronary artery in its epicardial tract during physical stress.
Case summary. We present the case of a 15-year-old male, competitive athlete (football), who experienced, during and after playing a soccer match, persistent chest pain and exertional dyspnoea. He was transferred to the Emergency Department. Laboratory tests revealed a modest elevation in Troponin levels (TnI), while echocardiography was unremarkable except for a trivial pericardial effusion (<2 mm). The patient was discharged with a diagnosis of myopericarditis and the indication to undergo a Cardiac MRI (CMR) and Holter 24h ECG. CMR was not able to unveil any feature compatible with recent or previous myocarditis, but interestingly, during Myocardial first-pass perfusion imaging sequences elicit perfusion deficit compatible with an obstructive disease of the RCA. Holter ECG monitoring showed phases of Isorhythmic atrioventricular (AV) dissociation and II grade type I AV block. Coronary Computed Tomography Angiography (CCTA) was then performed, showing right aortic AOCA characterized by a high-risk intramural and inter-arterial course (slit-like ostium). To fully elucidate the compression mechanism of the intramural segment, it is crucial to study the morphological changes and behavior of the anomalous coronary lumen during the whole cardiac cycle. The decision was made to evaluate the hemodynamic significance of coronary lesions with an invasive combined morphologic and hemodynamic assessment. Intravascular Ultrasound (IVUS) and Fractional Flow Reserve (FFR) with Coronary Flow Reserve (CFR) were calculated, at rest conditions and after adenosine and dobutamine administration to simulate physiological stress. IVUS evidenced a stenosis area equal to 72% in the intramural proximal tract at rest, which was considered already significant. This finding was associated with an FFR value of 0.76 at an HR of 91 bpm that was further reduced to 0.74 at 130 bpm. Importantly, non-hyperemic indexes such as Pd/Pa decreased from 0.95 to 0.83 during the dobutamine challenge. The reduced Coronary Flow Reserve (CFR) was consistent with the epicardial origin of the obstruction in the presence of normal Index of Microcirculatory Resistance (IMR) values at rest and during pharmacological stress. The patient underwent a preoperative MRI which showed, at peak stress with dobutamine and atropine, perfusion abnormalities in the basal-inferior and infero-septal regions. Based on this comprehensive assessment, the indication was made to perform the surgical correction. After surgery, the patient was asymptomatic. Prolonged ECG monitoring failed to reveal any major arrhythmias and the cardiopulmonary test revealed normal functional reserve during repeated maximal exercise.
Discussion. Our clinical case aims to point out the importance of a comprehensive assessment in patients with AOCA for diagnostic and prognostic purposes.

A527: FUNCTIONAL CARDIORESPIRATORY ADAPTATION IN THE CLINICAL MODEL OF SYMPTOMATIC SYSTEMIC SCLEROSIS WITH NORMAL RESTING HEMODYNAMICS

Giulio Pio Federico Mallardi (a, e), Manè Chobanyan (a), Giulia Guffanti (a), Giulia Acquati (a), Irene Rota (b, d), Crizia Colombo (a, e), Chiara Bellocchi (a, c), Lorenzo Beretta (a, c), Stefano Carugo (a, e), Marco Vicenzi (a, e)
(a) DEPARTMENT OF CLINICAL SCIENCES AND COMMUNITY HEALTH, UNIVERSITY OF MILAN, 20122 MILAN, ITALY; (b) OSPEDALE DI LEGNANO NUOVA SEDE, CARDIOLOGY UNIT; (c) SCLERODERMA UNIT, REFERRAL CENTER FOR SYSTEMIC AUTOIMMUNE DISEASES, FONDAZIONE IRCSS CA' GRANDA OSPEDALE MAGGIORE POLICLINICO DI MILANO, UNIVERSITY OF MILAN, MILAN, ITALY; (d) OSPEDALE CIVILE DI LEGNANO, ASST OVEST MILANESE, MILANO, ITALY; (e) DEPARTMENT OF CARDIO-THORACIC-VASCULAR AREA, CARDIOLOGY UNIT

Patients with Systemic Sclerosis (SSc) are well-known to be at risk of developing pulmonary hypertension (PH). In some SSc patients with unexplained dyspnea, intermediate probability of PH on echocardiography, and hyperventilation during Cardiopulmonary Exercise Testing (CPET), right heart catheterization (RHC) may appear normal at rest and unable to explain symptoms. So this study aims to explore and describe the hemodynamic changes and the cardiorespiratory adaptation during exercise in SSc patient. We recruited 16 patients with SSc and unexplained dyspnea. They underwent ambulatory assessment through clinical examination, plasma NT-proBNP level measurement, echocardiography evaluation and maximal CPET. Then, a RHC at rest and an invasive CPET were performed in all patients, from which step-by-step hemodynamic

parameters were derived. Patients were grouped according to the pulmonary circulation adaptation: resistive group (R), with unchanged or increased pulmonary vascular resistance (PVR) from rest to peak of exercise; non resistive group (nR), with normal decreasing of PVR ($Delta_{peak-rest}$>20% of rest value). Pulmonary compliance (Ca), distensibility coefficient (α), hemoglobin concentration (Hb), oxygen consumption (VO2, ml/min) and ventilatory equivalent carbon dioxide (VE/VCO2) were also considered. RESULT: among the sixteen patients all were female with a median age of 66 years. At baseline catheterization, the entire population did not show pathological hemodynamic findings. Median pulmonary artery pressure value at rest was 18 mmHg and median pulmonary artery wedge pressure 10 mmHg. Median pulmonary vascular resistance (PVR) resulted 1.5 UW. Dynamic changes during exercise showed a significant lower median alfa coefficient value in R than nR group (0.010% [0.0059-0.011] vs 0.012% [0.0121-0.021]. As reported in Table 1, the changes of main parameters from rest to peak of exercise was significantly different for Delta PVR (by definition), Delta CO (p=0.001), and Delta Hb (p=0.041). Delta Ca was equal in intergroup analysis.

Discussion. To date, this is the first study showing the pulmonary vascular adaptation in SSc patients having unexplained dyspnea and normal cardiopulmonary hemodynamic at rest. Among R and nR subjects, we found that being equal the Ca (which reflects the behavior of large-caliber pulmonary vessels), R group showed significantly lower α (which reflects more precisely the behavior of small-caliber vessels). We supposed that the reduction of the distensibility of the small vessels may increase the right ventricular afterload that, in its turn, limits the contractility reserve. Therefore, the reduction of Delta CO seems compensated by an early "splenic squeeze" resulting in a 50% higher Delta Hb.

Conclusions. Based on these results, we show that in SSc patients dyspnea can origin from a deregulation of pulmonary vascular tone during effort. This phenomenon can be attributed to a structured increased stiffness of the pulmonary circulation due to SSc or even to an induced vasoreactivity because of endothelial dysfunction. Moreover, we can not exclude also the role of augmented blood viscosity due to increased Hb. This study open new pathophysiological hypotheses that deserves further investigation.

Variazioni emodinamiche all'esercizio	Popolazione totale n=16	Popolazione R n=9	Popolazione nR n=7	p-value
Δ PVR (WU)	-0,19 [-0,61-0,38]	0,34 [0,14-1,2]	-0,92 [-1,44-0,40]	0,001
Δ CO (L/min)	4,4 [2-6,4]	2 [0,7-2,75]	6,4 [4,2-6,9]	0,001
Δ Ca (ml/mmHg)	-1,43 [-3,79-(-1,1)]	-0,5 [-2,14-(-1,1)]	-1,2 [-1,5-(-0,4)]	0,000
Δ Hb (g/dL)	1,2 [0,8-1,65]	1,9 [1,3-2,2]	1 [0,7-1,1]	0,041

A528: CHANGES IN THE CATH LAB IN THE TREATMENT OF ADULT PATIENTS WITH CONGENITAL HEART DISEASE: A 12-YEAR EXPERIENCE IN A SINGLE REFERRAL CENTER WITH THE ESTABLISHMENT OF A DEDICATED WORKING GROUP

Marco Alfonso Perrone (a, b), Roberto Formigari (a), Mario Panebianco (a), Elettra Pomiato (a), Francesca Fanisio (a), Paolo Guccione (a), Rosalinda Palmieri (a), Massimiliano Raponi (a), Maria Giulia Gagliardi (a)

(a) DEPARTMENT OF CARDIOLOGY AND CARDIAC SURGERY, BAMBINO GESÙ CHILDREN'S HOSPITAL IRCCS, ROME ITALY; (b) DIVISION OF CARDIOLOGY AND CARDIOLAB, DEPARTMENT OF CLINICAL SCIENCES AND TRANSLATIONAL MEDICINE, UNIVERSITY OF ROME TOR VERGATA, ROME, ITALY

Background. Adults with congenital heart disease (ACHD) are a growing population needing ongoing care. The aim of this study was to investigate if a dedicated ACHD team impacted the timing and indication of invasive cardiology procedures in these patients at our hospital.

Methods. Our retrospective single-center study enrolled adult patients with moderate or complex congenital heart disease and with at least one cardiac catheterization between January 2010 and December 2021. According to the period, procedures were labeled as group A (2010 to 2015) or group B (2016 to 2021) and further divided into diagnostic (DCC) and interventional cardiac catheterizations (ICC).

Results. 594 patients were eligible for the study. Both DCC (p<0.05) and ICC increased between groups A and B (p<0.05). In group B: Fontan patients accounted for the majority of DCC (p<0.001), while DCC decreased in arterial switch repair (p<0.001). In Fontan patients, conduit stenting was prevalent (p<0.001), while fenestration closures dropped (p<0.01). In patients with tetralogy of Fallot and native outflow tract, percutaneous pulmonary valve implantations (PPVI) increased, with a concurrent reduction in pulmonary valve replacements (p<0.001 vs. surgical series). In right ventricular conduits, ICC increased (p<0.01), mainly due to PPVI. Among Mustard/Senning patients, baffle stenting increased from Group A to Group B (p<0.001). In patients with pulmonary atresia and biventricular repair, ICC often increased for pulmonary artery stenting.

Conclusions. A dedicated working group could improve ACHD patients' indications for interventional procedures, leading to tailored treatment, better risk stratification and optimizing time until heart transplantation.

A529: PROPOSTA DI UN MODELLO ORGANIZZATIVO DI GESTIONE CONDIVISA DEI PAZIENTI CON EMBOLIA POLMONARE: DALLA GESTIONE IN PRONTO SOCCORSO ALL'APPROPRIATEZZA DEL RICOVERO

Claudio Girasoli (a), Amedeo Picciolo (a), Giuseppe Colonna (a)

(a) U.O. DI CARDIOLOGIA - UTIC CON EMODINAMICA

Introduzione. L'Embolia Polmonare (EP) costituisce la terza causa di morte cardiovascolare, dopo Sindrome Coronarica Acuta e Stroke, con una incidenza di 160/100.000 casi abitanti/anno. La presentazione clinica è spesso aspecifica, il che rende ragione della difficoltà diagnostica e del frequente riscontro autoptico di EP (59% non diagnosticata in vita).

Materiali e metodi. Dal 2022 abbiamo istituito un percorso di gestione intraospedaliero per assicurare il corretto inquadramento diagnostico a tutti i Pazienti che accedono al Pronto Soccorso (PS) e stratificarne la classe di rischio al fine di identificare il setting di ricovero più adeguato. L'iter diagnostico nasce dall'integrazione tra sospetto clinico, esami diagnostici di primo livello (ECG, EGA, Rx torace, esami ematochimici) e probabilità clinica pre-test (Wells, Ginevra modificato). Nei Pazienti con Wells da 0 a 4 e D-dimero negativo la diagnosi di EP può essere esclusa; negli altri casi si esegue una angio-TC polmonare. Lo Score sPESI con il dosaggio della troponina e l'ecocardiogramma si utilizzano nei Pazienti con diagnosi di EP ad alto rischio per la stratificazione prognostica e per individuare la destinazione del ricovero.

Risultati. Il confronto dei dati epidemiologici riguardanti l'EP tra il 2021 e il 2022 ci ha permesso di verificare come, grazie al percorso di gestione condivisa intraospedaliero, si sia ottenuta una diversa distribuzione dei ricoveri nelle UNITÀ Operative coinvolte: i ricoveri in Cardiologia si sono ridotti dal 17% al 7% (in UTIC dal 3% allo 0%) al contrario i ricoveri in Medicina Interna sono passati dal 3% del 2021 al 10% nel 2022; stabili i ricoveri nell'UNITÀ Operativa di Pneumologia (dall'8% del 2021 al 9% del 2022). I ricoveri in altri reparti del Presidio Ospedaliero di Pazienti affetti da altre importanti co-morbidità prevalenti sono passati dal 3% al 7%.

Conclusioni. In un'epoca caratterizzata da una grave crisi economica anche in campo sanitario, grazie ai risultati finora ottenuti, riteniamo di aver dimostrato come il percorso intraospedaliero dell'EP assicura il corretto inquadramento diagnostico ed il tempestivo trattamento a tutti i Pazienti che accedono al PS, ne consente la stratificazione secondo la classe di rischio e identifica il setting di ricovero più adeguato, realizzando un modello organizzativo che possa dare concreti risultati in termini di mortalità/morbidità e sostenibilità economica.

A530: SINDROME IPEREOSINOFILA: UN CASO INSOLITO DI IPERTENSIONE POLMONARE

Marco Saderi (a), Francesca Virgilio (a), Antonietta Forteleoni (a), Pierluigi Merella (a), Gavino Casu (a)

(a) UOC CARDIOLOGIA CLINICA E INTERVENTISTICA, AZIENDA OSPEDALIERO UNIVERSITARIA DI SASSARI, VIA ENRICO DE NICOLA, 07100 SASSARI, ITALIA

Background. La sindrome ipereosinofila (SIE) è una condizione rara descritta in base all'eosinofilia ematica, al danno d'organo/tessuto e all'esclusione di cause secondarie di danno d'organo ed eosinofilia. Mentre l'endocardite di Loeffler rappresenta una manifestazione cardiaca della SIE, l'ipertensione polmonare (IP) vi è raramente associata, specialmente le forme pre-capillari.

Caso clinico. Una donna di 39 anni si è presentata al Pronto Soccorso lamentando dispnea a riposo (classe NYHA IV). L'anamnesi mostrava sinusite cronica e asma allergica. Gli esami di laboratorio hanno evidenziato leucocitosi eosinofila, aumento dei livelli di IgE e di pro-BNP. L'ecocardiogramma ha mostrato una disfunzione ventricolare globale e lesioni isoecoiche a livello delle valvole mitrale e tricuspide, quest'ultima determinante una stenosi severa con marcata dilatazione dell'atrio destro. La RM cardiaca ha rivelato un ispessimento isodenso dei lembi della valvola atrio-ventricolare, associato ad aree anulari di late gadolinium enhancement compatibili con fibrosi/necrosi subendocardica. Tutti gli esami hanno escluso forme di ipereosinofilia secondaria e primitiva. È stata pertanto posta la diagnosi di endocardite di Loeffler e sono state introdotte sia una terapia anticoagulante in profilassi tromboembolica sia una terapia immunosoppressiva con corticosteroidi e imatinib mesilato, seguite da una rapida diminuzione del livello di eosinofili e dal miglioramento dei sintomi. Nel follow-up, la paziente ha continuato a lamentare dispnea per sforzi moderato-intensi (classe NYHA II). L'ecocardiogramma ha rivelato segni indiretti di IP, poi identificata nella forma precapillare al cateterismo cardiaco destro (PAPm 22 mmHg, PCWP 14 mmHg, PVR 2,2 WU). La tromboembolia polmonare cronica è stata esclusa mediante angio-TC polmonare e scintigrafia ventilo-perfusoria. Dato il lieve grado di IP, la dispnea è stata ritenuta conseguente alla stenosi tricuspidale residua; pertanto, una gestione conservativa con visite di controllo programmate è stata considerata la migliore opzione terapeutica.

Discussione. Il ruolo degli eosinofili nel circolo polmonare è attualmente poco chiaro e varia a seconda della conta di eosinofili, della classe di IP e della storia clinica del paziente (allergie, BPCO). La risposta infiammatoria mediata dall'infiltrazione e dall'aggregazione degli eosinofili potrebbe spiegare il rimodellamento arterioso polmonare nei pazienti allergici che presentano SIE. L'IP correlata a imatinib mesilato è un effetto collaterale estremamente raro ed è stata considerata improbabile.

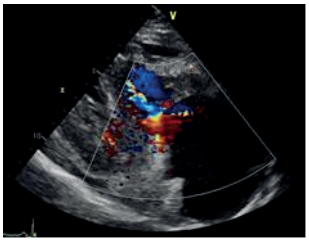

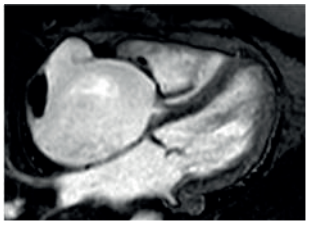

A531: SELEXIPAG FOR PULMONARY ARTERIAL HYPERTENSION ASSOCIATED WITH CONGENITAL HEART DISEASE (ESINMENGER SYNDROME)

Paolo Alfonso Ciarelli (b), Serena Rossi (a), Marco Addari (b), Maria Vittoria Caprio (b), Federica De Donno (b), Livio Giuliani (a), Sabina Gallina (b)
(a) 1) EMODINAMICA DIAGNOSTICA E INTERVENTISTICA OSPEDALE "SS. ANNUNZIATA", CHIETI; (b) 2) DEPARTMENT OF NEUROSCIENCE, IMAGING AND CLINICAL SCIENCES "G. D'ANNUNZIO" UNIVERSITY, CHIETI-PESCARA, ITALY

Background. Eisenmenger syndrome (ES) represents the most severe hemodynamic phenotype of pulmonary arterial hypertension (PAH) in association with congenital heart disease (CHD). In this setting defects closure is controindicated and medical treatment strategy has the same pathophysiologic rationale of pulmonary arterial hypertension (PAH). According to the 2022 ESC/ERS guidelines Bosentan is recommended in symptomatic patients with Eisenmenger syndrome to improve exercise capacity (Class I) and sequential combination therapy including ERAs, PDE5is, riociguat, prostacyclin analogues and prostacyclin receptor agonists, should be considered if patients do not meet treatment goals (Class IIa). Selexipag, an orally available and selective prostacyclin receptor agonist, has become available for treatment of PAH, but experience in patients with ES is limited.

Case description. A 38-year-old woman with Eisenmenger syndrome due to unrepaired perimembranous ventricular septal defect, patent ductus arteriosus and persistent left superior vena cava. She was evaluated by our group for worsening dyspnoea (WHO-FC III) and cyanosis despite monotherapy with Bosentan 125 mg bd:

- Clinical Examination: digital clubbing and labial cyanosis.
- Six minutes walking test: functional capacity of 190 metres.
- Transthoracic echocardiography: hypertrophic and enlarged right ventricle with mild longitudinal dysfunction.
- Cardiac magnetic resonance (RM): presence of perimembranous ventricular defect, patent ductus arteriosus, persistent left superior cava together with ventricle hypertrophy and a small focus of fibrosis in the basal junctional area.
- Pulmonary function test: moderate restrictive pattern and a mild reduction of the diffusing capacity of the lung for carbine monoxide (DCLO).
- Four-strata risk assesstment: intermediate-high risk (WHO-FC III; 6WMT 190 mt; BNP 550 PG/ml).
- RHC: RAP 16 mmHg, PAPs/d/m 189/90/126 mmHg, PAWP 15 mmHG, CO 3.4 L/min, CI 1,9 L/min/mq, PVR 36, Qp/Qs 0.8.

We started combination therapy including:

- PDE5 inhibitors: Silfenadil 20 mg tid.
- Endothelin receptor antagonist: Macitentan 10 mg od.
- Selective pgi2 receptors agonist: Selexipag (started ad dosage of 200 µg twice daily and titrated up to 1600 µg twice daily.

A twelve month follow up: No side effects were reported; RHC: RAP 5 mmHg, PAPs/d/m 123/54/82mmHg, PAWP 5 mmHg, CO 4.4 L/min/mq, CI 2.8 L/min/mq, PVR 9 WU, Qp/Qs 1.80; Echocardiography, brain natriuretic peptide, 6MWT and RHC allowed reclassification of the patient as low risk. Two years later: no side effects were reported; according echocardiography, brain natriuretic peptide and 6MWT the patients is still at low risk.

Conclusions. The use of selexipag in patients with Eisenmenger syndrome is controversial. The GRIPHON study, the multicentre, double-blinded, randomized, event-driven, controlled trial evaluating the safety and efficacy of selexipag in PAH patients, recruited only 110 patients with repaired congenital systemic to pulmonary shunts among the entire cohort, but none of them had Eisenmenger syndrome. A post-hoc analyses of GRIPHON suggests that selexipag may delay disease progression and is well-tolerated in patients with corrected CHD-PAH. So, evidences on the use of selexipag in ES patients are lacking. Our patient achieves a significant clinical improvement with an upfront triple oral combination therapy including selexipag. This case report may provide an insight into therapeutic options for patients with Esenmenger syndrome. Nevertheless, further investigation is needed to clarify the role of a triple oral combination therapy in this setting.

A532: OSTRUZIONE AB ESTRINSECO DI RAMO POLMONARE SOTTOPOSTO AD ANGIOPLASTICA IN PAZIENTE CON TUMORE POLMONARE AVANZATO

Carmen Del Giudice (a), Enrica Pezzullo (a), Mario Giordano (a), Giampiero Gaio (a), Maurizio Cappelli Bigazzi (a), Biagio Liccardo (a), Francesco Natale (a), Paolo Golino (a), Francesco Loffredo (a)
(a) AORN MONALDI- UNIVERSITÀ DEGLI STUDI DELLA CAMPANIA- LUIGI VANVITELLI

Riportiamo il caso di una donna di 39 anni con storia personale di adenocarcinoma polmonare avanzato (pT4N2) in nota mutazione del gene EGFR (del esone19), sottoposta a pneumonectomia sinistra e linfoadenectomia ilo mediastinica omolaterale. In benessere clinico fino ad agosto 2023, quando per comparsa di dispnea parossistica e ortopnea si recava presso il nostro ambulatorio di Cardiologia, con successiva evidenza all'ecocardiogramma di segni diretti ed indiretti di ipertensione polmonare. Nello specifico veniva evidenziata una severa dilatazione delle camere cardiache di destra e una pressione ventricolare destra di circa 90 mmHg stimata dal picco di rigurgito tricuspidale; Inoltre il ventricolo sinistro presentava un D shape, con un movimento sisto-diastolico posteriore del setto interventricolare come da sovraccarico delle sezioni destre. Una sezione asse corto sui vasi mostrava un ramo polmonare destro piccolo, tortuoso con una notevole accelerazione al color e un PG max 70 mmHg al Doppler pulsato. Questi dati ecocardiografici sono stati poi confermati dall'Angio-tc che mostrava una compressione ab estrinseco del ramo polmonare di destra. La paziente veniva quindi sottoposta a cateterismo cardiaco destro che confermava un gradiente massimo di 90 mmHg nel tronco polmonare e un PG max di 25 mmHg in ramo polmonare destro distale e successiva angiografia che confermavano la stenosi significativa. Si procedeva quindi ad angioplastica e stenting del ramo polmonare destro con riduzione immediata del gradiente. A un mese di follow up la paziente mostrava significativo miglioramento dei test funzionali. Infatti il suo Test dei sei minuti rivelava una distanza percorsa di 660 metri, una saturazione di 97% in aria ambiente e una frequenza cardiaca massima di 105 bpm. L'ecocardiogramma confermava stabilità dei gradienti transpolmonari con un PG massimo di 25 mmHg e una pressione ventricolare destra di 40 mmHg. Inoltre le sezioni destre mostravano un significativo rimodellamento, con completa risoluzione dei segni diretti e indiretti di ipertensione polmonare. Nei pazienti con storia di pneumectomia si può osservare lo sviluppo di ipertensione polmonare precapillare per meccanismi di rimodellamento del letto vascolare polmonare. Nel nostro caso la valutazione ecocardiografica ha evidenziato una causa differente, ossia, una compressione del ramo polmonare destro confermata poi alla TC. Questo reperto ci ha consentito di procedere ad angioplastica polmonare con significativo miglioramento funzionale oltre che rimodellamento cardiaco, confermato ai follow up successivi.

A533: INEFECTIVE MEDICAL THERAPY IN PULMONARY EMBOLISM DUE TO A RIGHT ATRIAL ORGANIZED THROMBUS

Elena Ghirimoldi (a), Alessia Pellitteri (a), Caterina Facciolo (a), Katia Celentano (a), Riccardo Sgaria (a), Valentina Guida (a), Mariangela Lattanzio (a), Paolo Borsani (a), Andrea Musazzi (a), Battistina Castiglioni (a), Roberto De Ponti (a)
(a) OSPEDALE DI CIRCOLO FONDAZIONE MACCHI

Introduction. Fibrinolysis and anticoagulation therapy are the gold standard in the treatment of pulmonary embolism (PE). In case of failure, a multidisciplinary management including surgery should be considered.

Case presentation. 44-years-old obese woman affected by diabetes mellitus and in estroprogestinic oral therapy presented in the Emergency Room with acute dyspnoea. She referred episodes of dyspnoea also in the previous months. Diagnostic investigations showed PE at intermediate-high risk with obstruction of the right pulmonary artery, dilatation of the right heart chambers, and the presence of a floating mass of 1.6x1.6 cm adherent to the lateral wall of the right atrium. Deep venous thrombosis was excluded by ultrasounds imaging. The patient was admitted to the Intensive Care Unit. After initial clinical response to fibrinolysis and anticoagulation therapy, in the third day of hospitalization she showed acute respiratory distress refractory to oxygen therapy with high-flow nasal cannula. A second CT scan showed extension of the obstruction to the left pulmonary artery, persistence of the right pulmonary artery obstruction, and an unchanged right atrial mass. The patient underwent ineffective percutaneous thrombus aspiration and during the procedure cardio-circulatory arrest with pulselessness electric activity refractory to emergent fibrinolysis occurred. Therefore, the patient was intubated, extracorporeal membrane oxygenation machine positioned, and hemodynamic stability achieved. Since the neoplastic nature of the atrial mass, which now presented a peduncle adherent to the atrial wall at transesophageal echocardiogram, could not be excluded and fibrinolysis and anticoagulation therapy were ineffective, the patient underwent urgent surgery with removal of the atrial mass and recanalization of the pulmonary artery. Histological examinations documented an atrial organized thrombus, with a peduncle, necrotic material and focal calcifications. Afterwards, anticoagulation therapy with vitamin K antagonist was introduced and the clinical conditions improved. Before hospital discharge, transthoracic echocardiogram showed normalization of the right ventricle with persistence of mild right ventricular disfunction and pulmonary hypertension, while obstruction of distal pulmonary artery branches only was present at CT scan.

Conclusions. An organized thrombus in the right heart chambers refractory to antithrombotic therapy is a rare cause of PE and it represents a challenge in the differential diagnosis with an atrial neoplasia. In this specific case, surgery provided both diagnosis and appropriate therapy.

A534: ACTUAL PLACE OF DOPPLER ECHOCARDIOGRAPHY IN SYSTEMIC SCLEROSIS

Francesca Coppi (a), Antonio Manenti (a), Matteo Boschini (a), Francesca Tampieri (a), Giulio Leo (a), Vernizia Morgante (a), Gabriele Melegari (a), Marco De Pinto (a), Rosario Rossi (a), Amelia Spinella (a), Dilia Giuggioli (a), Giuseppe Boriani (a), Anna Vittoria Mattioli (a)
(a) UNIVERSITY OF MODENA AND REGGIO EMILIA, POLICLINICO DI MODENA, 41124, MODENA, ITALY

Background. Not only pulmonary arterial hypertension (PAH), but also several other parameters can be detected by doppler trans-thoracic echocardiography (TTE) in systemic sclerosis (SSc), making invasive diagnostic procedures such as right heart catheterization (RHC) a diagnostic procedure of second choice.

Methods and Results. In our experience from 2020-2022, comprising 60 patients, aged between 50 and 75 years, with SSc and no other pre-existing or concomitant pulmonary and cardiac pathologies, TTE was positive in 55 patients (p-value <0.05), in terms of increased PA derived systolic pressure (PAPs) and diameter, elevated tricuspid valve regurgitant jet velocity (TR-Vmax) and annular plane systolic excursion (TAPSE). These parameters, which directly indicate PAH and right ventricle (RV) overload, were confirmed in 15 patients, who underwent RHC and in an equivalent group of 15 others, submitted to a pulmonary artery angiography during a chest computed tomography. In addition, today's sophisticated 3D echocardiography allows the acquisition of important related data on overall cardiac function. In particular, considering that the increase in pulmonary resistance causes increase of the walls of the right ventricle to hypertrophy before they dilate, its diastolic compliance decreases. This is followed by a dilatation of RV, first in its longitudinal diameter, which also involves the interventricular septum (IVS) especially in its non-rigid fibrous part. As a result, at the end of diastole, the IVS shifts to the left, decreasing the diastolic compliance of the left ventricle, which functions as a D-shaped cardiac structure; consequently, its systolic ejection fraction decreases, in the context of total cardiac restrictive physiology (Figure 1). Progression to RV failure can also be detected through dilatation of the inferior vena cava (IVC), with reduced inspiratory collapsibility, to reflux of blood flow, demonstrated by a positive oscillation during systole. In SSc, all these data make it possible to identify the warning signs of right ventricular insufficiency, considering that the main balancing mechanisms of PAH, the recruitment of additional capillaries and dilation of pre-existing ones, are impaired. Thus, the progression of RV insufficiency worsens TV regurgitation and RA dilatation. Even more worrying could be a dilatation of the LA secondary to severe diastolic insufficiency of the LV. About this, a stress TTE could demonstrate a limited contractile reserve of the LV, which evolves into a true heart failure (HF). More sophisticated echocardiographic technologies can be applied prospectively, such as speckle-tracking echocardiography, which allows a more precise assessment of the function of each part of a cardiac chamber, regardless of transient conditions such as volume overload or reversible pulmonary arterial hypertension. Sometimes indication to a coronarography may follow.

Conclusions. Cardiologists, pulmonologists and rheumatologists need to be informed of the current TTE clinical value in the diagnosis and prognosis of pulmonary hypertension secondary to systemic sclerosis, identifying patients at high risk of disease progression, who need targeted specialist care and more intensive follow-up.

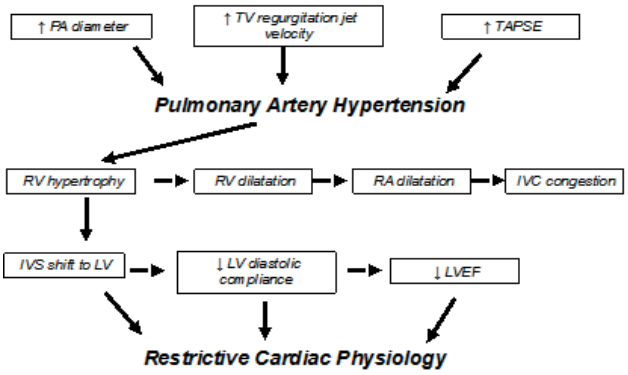

Figure 1. Flowchart: from pulmonary hypertension to restrictive cardiac.

A535: BMPR2 MUTATION: A RARE CASE OF COEXISTENCE OF PULMONARY ARTERIAL HYPERTENSION (PAH) AND ARRHYTHMOGENIC RIGHT VENTRICULAR CARDIOMYOPATHY (ARVC)?

Maria Claudia Lo Nigro (a), Alice Moncada (a), Federica Cocuzza (a), Francesca Campanella (a), Alessia Giglio (a), Pasquale Crea (a), Gianluca Di Bella (a), Scipione Carerj (a), Antonio Micari (a)
(a) DIPARTIMENTO DI MEDICINA E CLINICA SPERIMENTALE, UOC DI CARDIOLOGIA CON UTIC, UNIVERSITÀ DEGLI STUDI DI MESSINA, MESSINA, ITALIA

Pulmonary hypertension is a clinical condition that encloses a group of disorders characterized by abnormally high pressures in the pulmonary arteries. Pulmonary arterial hypertension (PAH) is a rare, complex and often misunderstood disease characterized by high resistance of the pulmonary arteries that leads to right heart failure. PAH can be sporadic (idiopathic PAH or primary pulmonary hypertension), familial (caused by germline mutations in BMPR2, a member of the TGF beta type II receptor family) or associated with other conditions, including connective diseases, congenital heart disease, HIV infection, portal hypertension etc. The lack of specific symptoms (especially dyspnea) probably causes diagnostic underestimation of this condition. Our clinical case deals with a 59-years old woman who is diagnosed with pulmonary hypertension (a primary form of the disease, having later ascertained familiarity). In the course of the patient's diagnostic workup, a cardiac MRI was performed and it showed signs of right ventricle atypicality, almost mimicking arrhythmogenic right ventricular cardiomyopathy (ARVC). It has been recently identified how germline mutations in the BMPR2 gene, implicated in PAH itself, may be associated with other heart diseases such as ARVC. Thus, at that point in our diagnostic pathway we were struck by a big query. Was it a rare case of coexistence of Pulmonary Arterial Hypertension (PAH) and Arrhythmogenic Right Ventricular Cardiomyopathy (ARVC)?

A536: PARTIAL ANOMALOUS PULMONARY VENOUS CONNECTIONS: MANAGEMENT OF A SERENDIPITY

Enrico Maggio (a), Jean Pierre Jabbour (a), Gianmarco Scoccia (a), Roberto Badagliacca (a)
(a) DEPARTMENT OF CLINICAL INTERNAL, ANESTHESIOLOGICAL AND CARDIOVASCULAR SCIENCES, SAPIENZA UNIVERSITY OF ROME, VIALE DEL POLICLINICO 155, 00161 ROME

Background. Total and partial anomalous pulmonary venous connections (TAPVC and PAPVC) represent rare anomalies characterized by an anomalous connection of some (PAPVC) or all (TAPVC) pulmonary veins draining directly, or through one or more systemic veins, into the right atrium instead of the left atrium.

Clinical case. 75-year-old patient admitted to our center for suspected pulmonary hypertension on TTE performed at another center. This suspicion was subsequently confirmed by our expert center. The physical examination revealed a III/VI murmur on the tricuspid focus, an incomplete RBBB on the ECG, repeating TTE confirmed suggestive findings such as dilation of the right cardiac chambers and moderate-severe TR with TTG 41 mmHg, sPAP 61mmHg, with normal function of the right ventricle (TAPSE 30mm, s' 13cm/s); therefore, the diagnostic workup of PH was planned. A right heart catheterization (RHC) was executed and it ruled out a diagnosis of PH, but the oximetric runs highlighted a suspicion of left-right shunt (Fig. 1). Therefore, we planned a TEE, that showed no ASD and no VSD (however were not visible the inflow tract of the left superior pulmonary vein and the right superior pulmonary vein into the left atrium), and a CT angiography of the chest that documented an anomalous drainage of the left superior pulmonary vein into the left brachiocephalic vein, and of the right superior pulmonary vein into the superior vena cava. To evaluate the hemodynamic impact of this shunt the Qp/Qs calculation resulted>2. However, the functional capacity measured by a cardiopulmonary test showed an excellent exercise capacity. In consideration of the patient's age and the excellent functional capacity shown on the cardiopulmonary test, the Heart Team of our hospital decided not to proceed with the surgical correction of the defect, also considering the high technical complexity and perioperative risks.

Conclusions. it's important to remember that even in the presence of echocardiographic signs of PH, it may not be present, and that the value of sPAP found on the echocardiogram does not always agree with the one recorded by RHC (due to possible under-/overestimation both on ultrasound, by virtue of the alignment with the flow and the characteristics of the regurgitation and the anatomy, or on RHC by virtue of possible calibration errors). A careful interpretation of the oximetric runs found during RHC can reveal a congenital heart disease that cannot be identified by the TTE assessment. Finally, it's important to keep in mind that congenital defects are not always diagnosed at a young age (especially if asymptomatic) and, therefore, their presence in geriatric patients cannot be excluded in advance.

mPAP	13 mmHg	SVC	94%
PCWP	5 mmHg	IVC	82%
PVR	0,79 WU	Upper RA	87%
Qp	10,19 L/min	Lower RA	87%
Qs	4,22 L/min	RV	87%
Qp/ Qs	2,41 L/min	PA	87%
CI	2,22 L/min/m2	AAo	99%
SVi	31,68 mL/m2	DAo	99%

A537: THE USE OF DOACS IN PATIENT WITH PROTHROMBIN THROMBOPHILIA

Alessandro Martis (a), Michele Migliari (a), Simone Angius (a), Luca Fazzini (a), Cinzia Soro (a), Christian Cadeddu Dessalvi (a)
(a) UNIVERSITÀ DEGLI STUDI DI CAGLIARI

Introduction. Prothrombin thrombophilia is characterized by venous thromboembolism, seen most commonly in adults as deep-vein thrombosis in the legs or pulmonary embolism. The clinical expression of prothrombin thrombophilia is variable: many individuals heterozygous or homozygous for the mutation never develop thrombosis, some have recurrent thromboembolism before age 30 years.

Case report. A 71-y/o woman has come at our emergency department due to worsening dyspnea, persisting for about a month, even due to minimal efforts at the time of admission, with simultaneous calves' pain which regressed shortly before hospitalization. She was a known patient with hypertension, diabetes and obesity (BMI 47.45). On arrival, she was hemodynamically stable, his laboratory results were significant for a pro-BNP of 33,442 pg/ml and high sensitivity troponin T of 199 ng/L but without movement, neutrophilic leukocytosis, PCR 37.3 mg/dL. The blood gas analysis showed an increase in lactate (2.4 mmol/L). The electrocardiogram showed sinus rhythm with heart rate of 92 bpm, incomplete right bundle block, S1T3 pattern and a poor R wave progression from V3 to V6. A first echocardiogram was performed, a concentric remodeling of the left ventricle was found, with reduced cavity volumes and a marked systo-diastolic D-shaped appearance, due to right ventricle overload, with preserved contractile function (EF 62%) in the absence of alterations of segmental kinetics. A transmitral impaired relaxation pattern was present. Still, dilated right ventricle with severe global systolic function reduction, with a free wall hypoakinesia and an apical wall spearing (McConnel sign) and an impaired tricuspid annular plane excursion (12 mm). There was also a dilated pulmonary artery trunk and the main left branch dilated, a moderate tricuspid regurgitation and a severe pulmonary hypertension (PASP 65 mmHg), and a distended inferior vena cava with diminished inspiratory collapsibility. Due to these findings, a CT pulmonary angiography (CTPA) was performed, showing a non-occluding thrombus affecting the right and left branches of the pulmonary artery which extend into the segmental and subsegmental lobar branches. The patient was admitted to our ICU, cycles of oxygen therapy were performed and anticoagulant therapy was initially instituted with LMWH parenterally. During hospitalization, a genetic test was performed which showed heterozygous mutation of the prothrombin gene and subsequent evaluation by the hemostasis and thrombosis specialist who indicated a long-term anticoagulant therapy with Apixaban 5 mg bid. Meanwhile, a venous colorDoppler ultrasound of the lower limbs was performed, showing a superficial venous thrombosis affecting the left external saphenous vein, for which an elastocompressive stocking was placed. The patient was discharged in good clinical and haemodynamic conditions. At the six-monthly follow-up there was no major bleeding; on control CT there was evidence of thrombotic formation reduction. Echocardiogram showed a RV improvement, with a better systolic function and a normal TAPSE (16mm).

Discussion. The purpose of this abstract is to submit a case of efficacy and safety of DOACs, particularly Apixaban, in patients admitted in hospital with pulmonary embolism and subsequent diagnosis of prothrombin thrombophilia.

A538: SINDROME DI AARSKOG-SCOTT: SEMPRE NECESSARIO UN FOLLOW-UP CARDIOLOGICO?

Paolo Alberto Gasparini (b), Eleonora Rodighiero (a, c), Elisa Lodi (a, c), Maria Grazia Modena (a, c)
(a) CENTRO P.A.S.C.I.A. (PROGRAMMA ASSISTENZIALE SCOMPENSO CARDIACO, CARDIOPATIE DELL'INFANZIA E A RISCHIO); (b) AOU POLICLINICO DI MODENA-UNIVERSITÀ DI MODENA E REGGIO EMILIA; (c) AOU POLICLINICO DI MODENA-UNIVERSITÀ DI MODENA E REGGIO EMILIA - SCUOLA DI SPECIALIZZAZIONE IN MEDICINA DELLO SPORT E DELL'ESERCIZIO FISICO

Introduzione. La sindrome di Aarskog-Scott (AAS) è una sindrome rara caratterizzata principalmente da bassa statura, disturbi scheletrici e dismorfismi genito-urinari. Alcune cardiopatie congenite (CHD) correlate ad AAS sono state descritte nella popolazione giapponese oltre 25 anni fa in pazienti senza diagnosi genetica e sono state riportate come lievi, a risoluzione spontanea e che rappresentano le più frequenti CHD riscontrabili anche nella popolazione generale (e.g., DIV, DIA). La base genetica di AAS risiede in mutazioni del gene FGD1 localizzato sul cromosoma Xp11.22. La prevalenza stimata è di circa 1/25000, ma solo ~ 60 casi sono stati confermati geneticamente.

Presentazione del caso. Presentiamo il caso di due gemelli maschi – nati in seguito a fertilizzazione in vitro - di età inferiore ad un anno affetti da AAS con diagnosi genetica confermata da mutazione del gene FGD1 sull'esone 6, variante c.1327 C>T p. (Arg443 Cys). Considerato il quadro sindromico e l'identificazione alla nascita di un forame ovale pervio (PFO) sono stati inviati a visita cardiologica pediatrica per follow-up. Clinicamente non presentavano alcuna alterazione di rilievo, ecocardiograficamente è stata riscontrata la persistenza di un piccolo PFO con minimo shunt sx-dx non emodinamicamente rilevante in entrambi. Alla luce del quadro, in assenza di linee guida specifiche sul follow-up di PFO, basandoci su esperienza del centro e letteratura contemporanea, abbiamo impostato un follow-up ecocardiografico in età scolare.

Conclusioni. Le CHD associate alla sindrome sono state descritte in pazienti senza conferma genetica, il che potrebbe implicare che i pazienti studiati fossero affetti da altre sindromi fenotipicamente simili all'AAS, ma genotipicamente differenti, e.g., la Noonan che, al contrario dell'AAS, si presenta frequentemente associata a problematiche cardiologiche. Pertanto, non sembra che AAS sia strettamente legata all'insorgenza di CHD, per cui dopo averle escluse con una prima ecocardiografia non sembrerebbe necessario impostare un follow-up solo perché affetti dalla sindrome, utile invece seguirli in condizioni specifiche e.g, CHD, ma anche di PFO. Il riscontro di PFO genera controversie. Secondo alcuni autori si tratta di una condizione fisiologica assai frequente nella popolazione senza specifiche implicazioni sulla vita del soggetto, secondo altri invece potrebbe avere un ruolo fondamentale nella genesi di emicrania, ictus etc.; tuttavia la forza delle indicazioni è relativamente bassa e orientata alla prevenzione secondaria. Tra gli elementi generalmente più condivisi vi è la necessità di follow-up in caso di immersioni professionali e voli astronautici.

A539: RELEVANCE OF TREE-DIMENSIONAL PRINTING WHEN PLANNING PACEMKER IMPLANTATION IN COMPLEX CONGENITAL HEART DISEASE: A CASE REPORT

Davide Castagno (a), Irene Borzillo (a), Susanna Breviario (a), Fulvio Gabbarini (a)
(a) DIVISION OF CARDIOLOGY, CARDIOVASCULAR AND THORACIC DEPARTMENT, "CITTÀ DELLA SALUTE E DELLA SCIENZA" HOSPITAL, TURIN, ITALY

Three-dimensional printing is an emergent technique derived from computer tomography, cardiac magnetic resonance and three-dimensional echocardiography. In the context of congenital heart diseases, it could be useful for interventional cardiologist in planning complex procedures. We report the first case of 3D printing to assist single-chamber pacemaker implantation in a patient with dextrocardia and congenitally corrected transposition of great arteries associated with ventricular septal defect and pulmonary atresia surgically corrected.

A540: LA SEZIONE "TRE VASI" IN ECOCARDIOGRAFIA FETALE. UNA FONTE PREZIOSA PER IL CARDIOLOGO

Ignazio Massimo Scimone (a), Paolo Guccione (b), Lilia Oreto (c), Benedetta Scimone (a), Michele Iannopollo (a), Vincenzo Montemurro (d)
(a) SERVIZIO DI CARDIOLOGIA FETALE ASP - REGGIO CALABRIA (CASA DELLA SALUTE DI SCILLA); (b) OSPEDALE PEDIATRICO BAMBINO GESÙ - ROMA; (c) CARDIOLOGIA PEDIATRICA - UNIVERSITÀ DI MESSINA; (d) CARDIOLOGIA TERRITORIALE ASP - REGGIO CALABRIA

Introduzione. La classica sezione ecocardiografica bidimensionale dei "tre vasi" della base, molto nota in cardiologia fetale, evidenzia in corrispondenza del tetto del mediastino la sede anatomica, i rapporti reciproci ed il calibro dei grossi vasi della base rappresentando rispettivamente da destra verso sinistra e da dietro in avanti la vena cava superiore (posteriore destra), l'aorta e l'arteria polmonare in posizione anteriore sinistra. Essa, nella pratica dell'ecocardiografia fetale, risulta sempre preziosa ed immediata soprattutto in alcuni contesti quali: le cardiopatie con interessamento tronco-conale, la valutazione della lateralità dell'arco aortico, lo studio dei ritorni venosi sistemici, la predittività di coartazione/ipoplasia tubulare dell'arco aortico posteriore.

Materiali e metodi. Scopo del presente lavoro è quello di sostenere l'immediata potenzialità diagnostica della sezione "tre vasi" della base in ecocardiografia fetale, a partire dalla 16^ settimana di gravidanza, nei casi fetali di arco aortico destro, nella persistenza della vena cava superiore sinistra (VCSS), nell'agenesia della vena cava superiore destra (VCSD), nella diagnosi di coartazione/ipoplasia dell'arco aortico posteriore e nella trasposizione dei grossi vasi. L'arco aortico destro, nelle sue varianti, viene immediatamente caratterizzato per il suo decorso antero-posteriore alla destra della trachea. Nella persistenza della VCSS la dilatazione del seno coronarico si associa in questa sezione ad una rappresentazione a "4 vasi" che da destra verso sinistra mette in luce una VCSD (di calibro più piccolo rispetto al solito), l'aorta, l'arteria polmonare e quindi la VCSS (di calibro simile a quello della VCSD) accanto ed a sinistra rispetto all'arteria polmonare.

Nella rara agenesia della VCSD vediamo da destra verso sinistra l'aorta, l'arteria polmonare, e quindi la VCSS il cui calibro appare significativamente maggiore rispetto alla variante più frequente sopra citata ricevendo il ritorno venoso sopradiaframmatico nell'insieme con un seno coronarico che apparirà marcatamente dilatato e con un flusso che in questo caso attraversa il tronco venoso anonimo verso sinistra. Nella forma classica di trasposizione (D-TGA) l'anomala posizione anteriore destra dell'aorta stravolge la sezione dei tre vasi creandosi una anomala sovraimposizione dei grossi vasi nel loro decorso antero-posteriore. Ciò impedisce la rappresentazione del classico segno della V. Infine, è importante sottolineare come una netta riduzione di calibro in questa sezione "del cerchietto" dell'aorta ascendente può essere predittiva, specie se di riscontro precoce (secondo trimestre), di coartazione/ipoplasia dell'arco aortico posteriore.

Discussione e Conclusioni. La sezione dei "tre vasi" della base rappresenta in epoca fetale una eccellente ed intuitiva sezione ecocardiografica per lo studio della lateralità dell'arco aortico, dei ritorni venosi sistemici nelle diverse varianti, nella TGA e per l'analisi delle differenti espressività restrittive dell'arco aortico posteriore.

COVID-19

A541: IMPATTO DEL COVID-19 SULLA SINDROME CORONARICA ACUTA: DIFFERENZE TRA LE DIVERSE ONDATE EPIDEMICHE

Vincenzo Sucato (a), Giusy Sausa (a), Alessandro D'Agostino (a), Evola Salvatore (a), Giuseppe Coppola (a), Giuseppina Novo (a), Egle Corrado (a), Alfredo Ruggero Galassi (a)
(a) UOC DI CARDIOLOGIA, DIPARTIMENTO PROMISE, AOU POLICLINICO PAOLO GIACCONE, UNIVERSITÀ DEGLI STUDI DI PALERMO

Introduzione. Fin dall'inizio della pandemia COVID-19 è stata dedicata grande attenzione alle implicazioni cardiovascolari indotte dall'infezione da coronavirus. Non meno importanti sono tuttavia gli effetti indiretti del virus sulla salute cardiovascolare che hanno contribuito all'aumento della mortalità per tutte le cause registrato durante la pandemia. Il nostro è uno studio osservazionale retrospettivo che si propone di confrontare le eventuali differenze epidemiologiche, cliniche e gestionali intercorse tra le quattro ondate epidemiche in gruppi di pazienti ricoverati per sindrome coronarica acuta (SCA). Al fine di mettere in luce il peso esercitato dalla pandemia sulla gestione della SCA è stato analizzato l'impatto sugli ospedali e sul ricorso alle cure ospedaliere da parte dei pazienti, focalizzando l'attenzione su tasso di ricoveri e mortalità intra-ospedaliera per sindrome coronarica acuta e su come questi dati possano essere stati influenzati dai tempi di gestione extra e intra-ospedalieri (tempo di "door-to-balloon") e dal ritardo nella richiesta di soccorso da parte del paziente (tempo di "symptoms-to-balloon").
Materiali e Metodi. Abbiamo incluso nello studio 98 pazienti ricoverati per SCA presso la nostra UTIC tra Marzo 2020 ed Marzo 2022 e sottoposti a procedura di rivascolarizzazione mediante angioplastica coronarica transluminale percutanea (PCI). I pazienti esaminati sono stati divisi in quattro gruppi rappresentativi delle quattro ondate epidemiche che hanno interessato il nostro Paese. Le caratteristiche demografiche, cliniche e procedurali sono state analizzate consultando le cartelle cliniche, i relativi allegati e i registri operatori.
Risultati. Il tasso di ricoveri per SCA si è incrementato progressivamente fino a un aumento del 178% nella terza ondata rispetto alla prima (p=0,003), con un aumento del 900% se si considerano solo gli NSTEMI (rappresentanti il 54% delle diagnosi di SCA del terzo gruppo contro il 14,3% nel primo). Le caratteristiche cliniche dei pazienti sono risultate sovrapponibili eccetto il netto aumento di fumatori nella terza ondata (p=0,04), verosimile effetto indiretto del lockdown. Non ci sono state differenze significative nella procedura di angioplastica eccetto una riduzione dell'uso di inibitori della glicoproteina IIb/IIIA nella terza ondata (p=0,04); incidenza di complicanze e risultati angiografici sovrapponibili. La degenza media è risultata più bassa nella terza ondata con una media di 5 ± 2 giorni (p=0,007).
Conclusioni. Dallo studio è emerso che la gestione della SCA, patologia tempo dipendente per eccellenza, ha risentito maggiormente degli effetti indiretti della pandemia durante la prima ondata sia per l'impreparazione delle strutture ospedaliere sia per la paura del contagio che ha dissuaso la popolazione dal chiedere aiuto. Tuttavia, dopo un apparente ritorno alla normalità registrato nella terza ondata, la situazione è nuovamente peggiorata nella quarta con il maggior numero di contagi mai registrato nel nostro Paese, il collasso delle strutture sanitarie e il ritorno della paura del contagio. In questa ondata inoltre è stato maggiormente evidente l'effetto dell'interruzione dei programmi di screening e follow-up e dell'adozione di stili di vita scorretti favoriti dal lockdown.

A542: PHENOTYPES OF ACE2 DEFICIENCY AND BLOOD PRESSURE DURING HOSPITALIZATION FOR COVID-19

Federico Blasi (a, b), Michele Golino (a), Elena Ghirimoldi (a), Andrea Imporzani (a), Carlo Arnò (a), Alessia Carpani (a), Sergio Masnaghetti (c), Roberto De Ponti (a), Fabio Angeli (a, c)
(a) DEPARTMENT OF HEART AND VESSELS, OSPEDALE DI CIRCOLO, UNIVERSITÀ DELL'INSUBRIA, VARESE, ITALY; (b) CARDIOLOGY DEPARTMENT, RHO HOSPITAL, RHO (MI), ITALY; (c) DEPARTMENT OF MEDICINE AND CARDIOPULMONARY REHABILITATION, MAUGERI CARE AND RESEARCH INSTITUTE, IRCCS TRADATE, 21049 TRADATE, ITALY

Introduction. The link between SARS-CoV-2 infection and raise in blood pressure (BP) is well known. Proven risk factors for severe infection include advanced age, obesity, cardiovascular disease, hypertension, diabetes, and male gender. All these risk factors share a common characteristic: an overactivation of the ACE (angiotensin converting enzyme) system and an ACE2 receptor deficiency.
Methods. We conducted a prospective case-control study in hospitalized patients with confirmed diagnosis of SARS-CoV-2 infection by nasopharyngeal swab and imaging features consistent with COVID-19 pneumonia. The primary outcome was the rate of persistent raise in BP requiring a new or intensified anti-hypertensive treatment during hospitalization. BP values ≥140 mmHg systolic or 90 mmHg diastolic for at least two consecutive days defined the persistent rise in BP.
Results. The population included 58 patients, with a mean age of 64±1.9 years and of which 38% were female. Patients had a mean BMI of 27.2±0.63 and a high percentage of history of hypertension (55%). Diabetes was present in 17% of patients and 28% were active smokers. The prevalence of prior cardiac events, cerebrovascular events, and COPD were 16, 10, and 5%, respectively. At admission, on average, patients were normotensive (mean systolic BP 121±2.3; mean diastolic BP 76±1.4), but during hospitalization, 45% of patients showed a persistent increase in BP. Predictors of uncontrolled BP were age (p=0.006), history of previous hypertension (p=0.002), diabetes (p=0.043), and previous cardiovascular events (p=0.027), all characteristics associated with functional ACE2 deficiency. We then divided the population by the number of these phenotypes coexisting in the same patient and analyzed the occurrence of the primary outcome. In the presence of a single risk factor, 41% of patients developed a persistent rise in BP. The percentage became progressively significant as the phenotypes of ACE2 deficiency coexisting increased, respectively to 57% and 78% in the presence of 2 or 3 characteristics, and up to 100% of events recorded in the group with all 4 risk factors. The risk of developing uncontrolled hypertension, based on the number of ACE2 deficiency phenotypes present, showed a trend towards an increased risk in the presence of a single phenotype, with an OR of 9.1 (CI: 0.957-86.480; p=0.055), which could be considered clinically significant. With the overlap of more than one ACE2 receptor deficiency phenotype, the risk of developing persistent hypertension increased significantly, obtaining an OR of 17 in case of 2 factors simultaneously (OR=17; p=0.015) and even higher in the presence of 3 or more factors (OR=58.5; p=0.002).
Conclusions. These results highlight that the different phenotypes related to ACE2 receptor deficiency, when associated with each other, have a synergistic effect in the development of persistent arterial hypertension during COVID-19 pneumonia. Therefore, advanced age, the presence of arterial hypertension, diabetes or previous cardiovascular events must be considered as warning lights to identify patients at a higher risk of developing hypertension during hospitalization for SARS-CoV2 infection.

A543: LONG-TERM EFFECTS ON RIGHT VENTRICULAR FUNCTION AFTER COVID-19 RELATED PULMONARY EMBOLISM

Rachele Manzo (a), Federica Ilardi (a), Mario Crisci (b), Dalila Nappa (a), Cecilia Calabrese (b), Anna Scognamiglio (b), Fortunato Arenga (b), Domenica Francesca Mariniello (b), Valentino Allocca (b), Anna Annunziata (b), Antonello D´andrea (b), Raffaele Merenda (b), Vittorio Monda (b), Giuseppe Fiorentino (b), Giovanni Esposito (a)
(a) UNIVERSITY OF NAPLES FEDERICO II; (b) MONALDI HOSPITAL

Background. Coronavirus disease-2019 (COVID-19) frequently presents with cardiac involvement because of both the effects of direct infection and increased pulmonary resistance due to acute respiratory distress syndrome (ARDS) and pulmonary embolism (PE). Echocardiographic evidence of adverse right ventricle (RV) remodeling in the acute phase of COVID-19 pneumonia has been extensively described and associated with increased early mortality. However, to date, little is known about the persistence of myocardial injury in recovered COVID-19 patients, with or without a previous diagnosis of PE.
Purpose. The aim of this study was to investigate the presence of subclinical cardiac dysfunction in recovered COVID-19 patients, with or without a previous diagnosis of PE at one year of follow-up.
Methods. Patients hospitalized between March 2020 and March 2021 with a diagnosis of COVID-19-related pneumonia, either complicated with PE or not and recovered from COVID-19 and prospectively followed up in the outpatient clinic were screened. Exclusion criteria were previous history of coronary artery disease, arrhythmia, valvular heart disease, chronic obstructive pulmonary disease, bronchial asthma, and obstructive sleep apnea. Out of 68 patients with COVID-19-related pneumonia, 44 patients (mean age 58.4 ± 13.3, 70% males) were divided into two groups (PE+ and PE-, each comprising 22 patients) and underwent clinical and transthoracic echocardiographic examination, including right-ventricle global longitudinal strain (RV-GLS), and RV free wall longitudinal strain (RV-FWLS) analysis.
Results. At one-year follow-up, patients with PE+ had LV dimensions, global and longitudinal systolic function, and atrial volume comparable with those without history of PE. However, despite no significant differences were found in right-chamber dimensions and RV systolic function between the two study groups, PE+ patients showed a significant reduction in RV-GLS (-16.4 ± 2.9 vs. -21.6 ± 4.3%, p<0.001) and RV-FWLS values (-18.9 ± 4 vs. -24.6 ± 5.12%, p<0.001) compared to PE- patients. At ROC-curve analysis, RV-FWLS<21% was the best cut-off to predict PE diagnosis in patients after COVID-19-related pneumonia (sensitivity 74%, specificity 89%, area under the curve=0.819, p<0.001). At multivariate logistic regression model, after adjustment for right ventricular outflow tract acceleration time and hypertension, RV-FWLS <21% was found to be independently associated with PE (HR 34.96, 95% CI:3.24–377.09, p=0.003) and obesity (HR 10.34, 95% CI:1.05–101.68, p=0.045).

Conclusions. In recovered COVID-19 patients with a history of PE+, there is a persistence of subclinical RV dysfunction one year after the acute phase of the disease, detectable by a significant impairment in RV-GLS and RV-FWLS. A reduction in RV-FWLS of lower than 21% is independently associated with COVID-19-related PE.

A544: ROLE OF HOME MONITORING FOR THE DIAGNOSIS OF POST-COVID-19 AUTONOMIC DYSFUNCTION AND FOR ARRHYTMIC BURDEN QUANTIFICATION IN PATIENTS WITH IMPLANTABLE CARDIAC DEVICES

Davide Avenoso (a, b), Chiara Ghiglieno (a), Carmine Romano (a, b), Aia Lila (b), Gabriele Dell'Era (a), Giuseppe Patti (a, b)
(a) AZIENDA OSPEDALIERO UNIVERSITARIA MAGGIORE DELLA CARITÀ DI NOVARA; (b) UNIVERSITÀ DEGLI STUDI DEL PIEMONTE ORIENTALE AMEDEO AVOGADRO

Introduction. The SARS-CoV 2 diffusion created interest in post-acute sequelae from SARS-CoV2 (PASC) and cardiovascular autonomic dysfunction (CVAD). Since it is often challenging to reach a definite diagnosis, we sought to evaluate the potential role of cardiac implantable electronic devices (CIED) in identifying CVAD in patients with previous infection from SARS-CoV2 (COVID-19).
Methods. We retrospectively enrolled all patients with COVID-19 and a CIED. Through home monitring software we evaluated circadian heart rate trend, number of total AF/atrial tachycardia (AT) episodes, average heart rate (HR) during AF/AT, AF/AT 24h arrhythmic duration, ventricular arrhythmias and percentage of ventricular pacing.
Results. A total of 34 patients were evaluated, 17 (50%) females, mean age 63.12 ± 13,28 years. No difference was observed in the parameters evaluated between patients with symptoms suggestive of CVAD and an asymptomatic control group. During active COVID-19 and the 3 months following the infection, a higher rate of AF/AT episodes was recorded compared to before the disease: median 0 (0-0) vs 0 (0-1), p=0.018. A trend towards higher AF duration was also observed: 0.001 (0-1.2) vs 0.55 (0.03 – 3.84), p=0.09.
Conclusions. In patients with symptoms suggestive of CVAD and CIED, cardiac parameters analyzed with home monitoring didn't show any significant difference compared to an asymptomatic control group. During SARS-CoV2 and in the 3 months after the infection, however, a higher rate of AF/AT is observed, as well as a higher supraventricular arrhythmic duration, supporting a prolonged pro-inflammatory state even in patients with "mild" COVID-19.

A545: SHORT AND LONG TERM OUTCOMES OF HOSPITALIZED VACCINATED AND UNVACCINATED COVID-19 SURVIVORS: A MULTIDISCIPLINARY APPROACH

Antonella Ciuffreda (a), Gianluca Di Pietro (a), Lucia Ilaria Birtolo (a), Sara Monosilio (a), Sara Cimino (a), Silvia Prosperi (a), Paolo Severino (a), Angelo Petroianni (e), Paolo Palange (e), Claudio M. Mastroianni (d), Nicola Galea (b), Marco Francone (b), Maria Ciardi (d), Francesco Pugliese (c), Francesco Fedele (a), Roberto Badagliacca (a), Viviana Maestrini (a), Carmine Dario Vizza (a), Massimo Mancone (a)
(a) DEPARTMENT OF CLINICAL, INTERNAL, ANESTHESIOLOGICAL AND CARDIOVASCULAR SCIENCES, SAPIENZA, UNIVERSITY OF ROME, "POLICLINICO UMBERTO I", HOSPITAL, ROME, ITALY; (b) DEPARTMENT OF RADIOLOGICAL, ONCOLOGICAL AND PATHOLOGICAL SCIENCES, SAPIENZA UNIVERSITY OF ROME, "POLICLINICO UMBERTO I" HOSPITAL, ROME, ITALY; (c) DEPARTMENT OF ANAESTHESIA AND INTENSIVE CARE MEDICINE, SAPIENZA UNIVERSITY OF ROME, "POLICLINICO UMBERTO I" HOSPITAL, ROME, ITALY; (d) DEPARTMENT OF PUBLIC HEALTH AND INFECTIOUS DISEASES, SAPIENZA UNIVERSITY OF ROME,"POLICLINICO UMBERTO I", ROME, ITALY; (e) DEPARTMENT OF PUBLIC HEALTH AND INFECTIOUS DISEASES, DIVISION OF PULMONARY MEDICINE, SAPIENZA UNIVERSITY OF ROME, "POLICLINICO UMBERTO I" HOSPITAL, ROME, ITALY

Background. Coronavirus disease 2019 (COVID-19) has been recognized as a dangerous lung condition often characterized by heart involvement. Post-acute long-lasting symptoms observed after the recovery phase were called by the international medical community, "Long-COVID Syndrome". This condition usually occurs three months from the onset of Sars-CoV2 infection, lasts at least for two months and cannot be explained by instrumental tools. The advent of COVID-19 vaccination prevented infections and severe clinical manifestations of the disease but the role of vaccination in Long-Covid Syndrome is still controversial. This study evaluated the different prevalence of post-acute sequelae at short and long-term follow-up among hospitalized unvaccinated and vaccinated COVID-19 survivors through a multidisciplinary approach.
Methods. After 2 months from discharge, unvaccinated and vaccinated COVID-19 survivors underwent a follow-up visit at a dedicated "post-COVID-19 Outpatient Clinic". A cardiovascular evaluation including electrocardiogram, troponin and echocardiography was performed. Further tests were requested when clinically indicated. Medical history, symptoms, arterial-blood gas, blood tests, chest computed tomography, and treatment of both in-hospital and follow-up evaluation were recorded. A one-year telephone follow-up was performed.
Results. N=458 consecutive unvaccinated and vaccinated COVID-19 survivors underwent the follow-up visit. Despite vaccinated patients were older, had more cardiovascular risk factors and comorbidities, they were less frequently admitted to the intensive care unit during Sars-Cov2 infection (9.6% vs 1.7%, p=<0.001) and they had fewer severe respiratory complications that required intubation (6,9% vs 1.3%, p=0.002) or non-invasive ventilation compared to the non-vaccinated ones. Among the overall cohort, 31 (6,7%) COVID-19 survivors showed delayed onset of cardiovascular condition at two-months follow-up visit. In particular, non-vaccinated patients experienced more frequently myocarditis (4.8% vs 0.9%, p=0.013) and pulmonary embolism (1.8% vs 0%, p=0.042) compared to the vaccinated ones. Chest CT performed at follow-up showed persistent radiological abnormalities in 157 (34,2%) patients with more persistence of ground glass (44.5% vs 2.6%, p=<0.001) or consolidations (15.3% vs 0.9%, p=<0.001) in the non-vaccinated group. At one-year follow-up 61% (n=278) of survivors reported symptoms, with fatigue (18.8%) and dyspnoea (15.3%) being the most frequent. Non-vaccinated patients reported more symptoms such as dyspnea (20.5% vs 10%, p=0.002) and psychological symptoms (10% vs 3.5%, p=0.005) compared to the vaccinated ones.
Conclusions. COVID-19 vaccines prevent non only severe lung and cardiac manifestations of the disease during in-hospital course but also at short term follow-up leading to a lower persistence of symptoms at 1 year follow-up.

A546: LONG TERM OUTCOME AMONG PATIENTS SURVIVED TO THE ACUTE PHASE OF COVID-19. THE ROLE PLAYED BY ARRHYTHMIAS AND HYPERINFLAMMATION

Domenico Cozzolino (a), Riccardo Nevola (a), Andrea Padula (a), Concetta Aprea (a), Christian Catalini (a), Maria Elena Corona (a), Celestino Sardu (a), Raffaele Marfella (a)
(a) UOC MEDICINA INTERNA, UNIVERSITÀ DELLA CAMPANIA L. VANVITELLI

Objectives. Not completely exhaustive are the data on outcomes among COVID-19 patients beyond the acute phase of the disease. The aims of the present study were to investigate all-cause mortality among COVID-19 patients from our COVID dedicated center one year after hospital discharge and the factors/conditions associated with death.
Methods. All the patients discharged from our center were periodically evaluated by clinical assessment and by digital healthcare registry consultation. All the findings acquired on discharge day represented the baseline data and served for statistical analysis.
Results. Of a total of 208 patients admitted, 187 patients were discharged. Among these subjects, 17 patients died within 12 months (non-survivors) from hospital discharge. Compared to survivors, non-survivor patients were significantly (p<0.05) older, exhibited a significantly greater number of comorbidities and a significantly larger prevalence in active malignancy, heart failure, and arrhythmias, and showed significantly higher circulating levels of B-type natriuretic peptide, troponin, C-reactive protein, and d-dimer, significantly longer heart rate-corrected QT interval, and significantly lower values of glomerular filtration rate. By the univariate analysis, the factors/conditions associated with the risk of death in our cohort of COVID-19 patients were advanced age, active cancer, heart failure, arrhythmias, lower values of glomerular filtration rate, and higher circulating levels of BNP, troponin, CRP, and d-dimer. At multivariate analysis, cancer, arrhythmias, and high C-reactive protein levels were found to be factors independently associated with death.
Conclusions. At 1-year follow-up, about 9% of patients discharged from our COVID center had a fatal outcome. Ageing, myocardial injury, impaired renal function, and, especially, cancer, hyperinflammation and arrhythmias strongly predicted a worst long-term outcome among COVID-19 patients.

A547: RUOLO PROGNOSTICO DELL'EMBOLIA POLMONARE NEL PAZIENTE COVID-19

Monica Salvi (a), Massimiliano Palazzini (a), Susanna Contucci (b), Eleonora Vita (b), Cinzia Nitti (b)
(a) UNITÀ DI CARDIOLOGIA- IRCCS AZIENDA OSPEDALIERO-UNIVERSITARIA DI BOLOGNA; (b) DIPARTIMENTO D'EMERGENZA - AZIENDA OSPEDALIERO-UNIVERSITARIA DELLE MARCHE

Motivazione allo studio. La malattia da COVID-19 è associata ad un aumentato rischio di tromboembolismo venoso, tanto maggiore quanto più è intensivo il setting assistenziale, diversi studi lasciano ipotizzare un ruolo prognostico sfavorevole. I dati della letteratura al riguardo non sono univoci. Con questo lavoro condotto al Dipartimento di Emergenza, in pazienti con COVID-19 nei quali l'embolia polmonare (EP) era stata confermata o esclusa con CTPA al momento dell'ingresso, vogliamo apportare il nostro contributo. La modalità di arruolamento rende a nostro parere più veritiero il ruolo dell'EP legata al COVID-19, escludendo tutte le altre eziologie di embolia polmonare.
Casistica e metodi. In uno studio retrospettivo abbiamo arruolato 676 pazienti di età>18 anni, valutati al Dipartimento di Emergenza (DE) per sintomi correlabili a infezione da Sars-Cov2 e diagnosi confermata con test molecolare rapido, sottoposti a CTPA nel periodo 01/03/2020 -15/04/2021
Risultati. I maschi erano il 63%, età media 66 anni. Tutti i pazienti sono stati ricoverati e hanno avuto follow-up a 30 giorni. È stato valutato l'end-point mortalità. È stato valutato l'interessamento polmonare da COVID-19 con i seguenti Risultati.<25% 169 pazienti (25%); tra 25-50% 279

(41,27%); tra 51-75% 142 (21,01%);>75% 86 (12,72%). Valutando la mortalità a 30 giorni l'interessamento <o>al 50% è risultato discriminante. La diagnosi di EP è stata posta in 96 pazienti pari al 14,20% (IC95%: 11,65-17,06). In 22,92% centrale, in 52,08% segmentaria, in 25,00% sub-segmentaria. A 30 giorni 78 pazienti erano deceduti pari a 11,54% (IC95%: 8,96-13,86). La mortalità a 30 giorni dei pazienti senza EP e con interessamento polmonare <50% è stata del 5,84% (IC95%: 3,73-8,63), pazienti senza EP e con interessamento polmonare ≥50% è stata del 16,95% (IC95%: 11,73-23,30). Nel gruppo EP la mortalità a 30 giorni è stata globalmente del 24,73% (IC95%: 16,36-34,76), se l'interessamento polmonare da COVID-19 era inferiore al 50%, è stata del 14,58 (IC95%. 6,07-27,74), se interessamento superiore al 50% è stata del 35,56% (IC95%: 21,86-51,22). Possiamo pertanto individuare tre gruppi a differente rischio di mortalità: interessamento polmonare COVID-19 <50% senza EP, rischio basso con mortalità a 30 giorni 5,75% (IC95%: 3,68-8,50); interessamento polmonare <50% ed EP o interessamento polmonare ≥50% senza EP, rischio intermedio con mortalità a 30 giorni del 17,11% (IC95%: 12,45-22,63); interessamento polmonare ≥50% con EP, rischio alto con mortalità a 30 giorni del 33,33% (IC95%: 20,39-48,41).

Conclusioni. I nostri dati hanno la peculiarità di essere stati raccolti al Dipartimento di Emergenza in pazienti affetti da COVID-19 precedentemente non trattati nei quali l'embolia polmonare quando diagnosticata era già presente alla prima valutazione. I nostri dati in questi pazienti evidenziano: prevalenza di EP al DE del 14,20%, particolarmente elevata se si considera il setting di rilevazione; confermano il ruolo prognostico negativo indipendente dell'embolia polmonare nel paziente affetto da COVID-19 che richiede ospedalizzazione, almeno raddoppiando il rischio di morte a breve termine, indipendentemente dall'estensione della polmonite COVID-19 e indipendentemente dal burden trombotico. I nostri dati suggeriscono pertanto particolare attenzione nella gestione di questi pazienti con approccio multidisciplinare e stretto monitoraggio.

A548: CARDIOVASCULAR DISEASE IN COVID-19 HEALTHCARE WORKERS: PROGNOSTIC IMPLICATION INSIDE HEART-COVID STUDY

Agostino Spano´ (b), Lorenzo Guarino (b), Myriam Carpenito (b), Simona Mega (b), Francesco Piccirillo (b), Giulia Marra (b), Alessia Delli Veneri (b), Francesco Antonio Veneziano (b), Gian Paolo Ussia (b), Francesco Grigioni (b)

(a) CAMPUS BIOMEDICO DI ROMA; (b) FONDAZIONE POLICLINICO UNIVERSITARIO CAMPUS BIOMEDICO

Background. The cardiac sequelae of coronavirus disease 2019 (COVID-19), a worldwide global pandemic, are still uncertain, particularly in non-hospitalized, low cardiac risk outpatient population. The aim of our study was to investigate COVID-19 long sequelae among a cohort of non-hospitalized healthcare workers (HCWs) from the "Policlinico Universitario Campus Bio-Medico".

Methods. This prospective single-center cohort study enrolled 78 HCWs. The study cohort was composed by 39 HCWs who had recovered from COVID-19 evaluated at a median of 8 months (I.C. 200,9-275 days) post-infection. The symptoms reported during COVID-19 infection were classic symptoms of a viral infection: fever (66,7%), cough (59%), asthenia (71,8%), rhinitis (7,7%), exertional dyspnea (25,6%), chest pain or pressure (38,46%), headache (66,7%), conjunctivitis (5,1%), gastrointestinal disorders (2%), loss of taste and smell (69,2%), and muscle pain (71.8%). Moreover a cohort of 39 HCWs who did not experienced infection in the previous twelve months was recruited as control and matched for age, sex, and risk factors. At the time of recruitment, all patients in the study cohort underwent a comprehensive clinical evaluation, standard 12-lead ECG, 24 hour ECG Holter, 6MWT and advanced echocardiographic examination.

Results. We found that although systolic ventricular function assessed by ejection fraction was similar between the two groups (60,9± 4,5% vs 59,8± 2,8% p=0.22), global longitudinal strain of the left ventricle (GLS) even if in normal range, was slightly and significantly reduced in COVID compared to the control group (-19,2± 3 vs -21,6± 2, p=0,0001). In addition, we stratified the study cohort into tertiles according to the number of symptoms referred in the acute phase of disease (Group A: 0-4 symptoms, [n=14], group B: 5-6 symptoms, [n=13]; group C: ≥7 symptoms, [n=12]). We found that, those post-COVID subjects who presented more symptoms during infection, exhibit a significant reduced value of GLS compared to less symptomatic ones (group C: -17,8 ± 2,6%, vs group A: -20,3± 3%, p=0,021). A secondary analysis was performed on a study cohort stratified by the number of days of symptom persistence (Group D: 7-11 days, [n=13]; Group E: 12-15 days, [n=13]; Group F: ≥16 days, [n=13]). Interestingly, we found that GLS was reduced more in the group of subjects in which symptoms lasted longer than in the group in which symptoms lasted only a short time (group F: -17,9 ± 3,2%, vs group D: -20,2± 2,9%, p=0,036).

Conclusions. Beyond the acute phase, the presence of such persistent myocardial dysfunction suggests cardiac involvement as a possible lasting consequence of COVID-19. Notably, this reduction seems to be related to the number and persistence of symptoms, suggesting a greater inflammatory burden that could lead to subclinical myocardial involvement, even in young people without comorbidities or a history of cardiovascular disease. The study findings indicate that the long-term cardiovascular follow-up of these patients may be more important than thought.

A549: EVOLUZIONE BENIGNA A LUNGO TERMINE DELLA MIOPERICQRDITE DA VACCINO A MRNA PER COVID-19

Federico Ballatore (a), Jacopo Costantino (a), Antonio Lattanzio (a), Giulia Marchionni (a), Maria Alfarano (a), Cristina Chimenti (a), Carmine Dario Vizza (a)

(a) DIPARTIMENTO DI SCIENZE CLINICHE INTERNISTICHE, ANESTESIOLOGICHE E CARDIOVASCOLARI

Background. Myopericarditis following coronavirus disease – 2019 (COVID-19) vaccine is a described entity, but its long-term evolution is still unclear.

Methods. Patients with a diagnosis of myopericarditis after mRNA COVID-19 vaccine represented our population. Clinical evaluation, laboratory tests, non-invasive cardiac tests, and echocardiographic and cardiac MRI (CMR) were performed at baseline, at six months and at 2-years follow-up.

Resources. Between January and August 2021, we identified 7 consecutive patients with myopericarditis following mRNA vaccination. The median age was 29 years (IQR: 25.5-53.5 years) and all patients were males. The median time from vaccine administration to symptoms onset was 5 days (IQR: 4-7 days); 5 patients received BNT162b2, two mRNA-1273 and only one patient developed symptoms after first dose of vaccine. The most commons symptoms at presentation were chest pain (100%) and fatigue (71.4%). Left Ventricular Ejection Fraction (LVEF) was preserved in 6 of them while it was mildly reduced in 1 (median LVEF: 61.3% [IQR:60-62.9%]. Late Gadolinium Enhancement (LGE) was detected at CMR in the 42.9% of cases. Treatment was conservative for patients except 1; a pericardiocentesis was necessary due to the massive pericardial effusion. At six months follow-up, all patients were asymptomatic with normal troponin level, electrocardiogram and echocardiogram confirming the complete healing of the inflammatory process and cardiac MRI showed a reduction of the areas of LGE. After 2 years CMR was repeated and showed resolution of the inflammation and dissolution of the LGE signal. Two patients received a COVID-19 vaccine booster dose without evidence of myopericardial involvement.

Conclusions. Myopericarditis associated with mRNA COVID-19 vaccination is more frequent in young males and is usually characterized by a benign evolution, even at long-term follow-up.

A550: CORONARY INFLAMMATION ON CHEST COMPUTED TOMOGRAPHY AND COVID-19 MORTALITY.

Domenico Tuttolomondo (a, b), Carmine Pizzi (c, d), Nicola Gaibazzi (b), Giampaolo Niccoli (a, b)

(a) UNIVERSITÀ DEGLI STUDI DI PARMA, PARMA, ITALY; (b) AZIENDA OSPEDALIERO UNIVERSITARIA DI PARMA, PARMA, ITALY; (c) UNITÀ DI CARDIOLOGIA, IRCCS AZIENDA OSPEDALIERO UNIVERSITARIA DI BOLOGNA, BOLOGNA, ITALY; (d) UNIVERSITÀ DEGLI STUDI DI BOLOGNA, BOLOGNA, ITALY

Background. The main factors associated with coronavirus disease-19 (COVID-19) mortality are age, comorbidities, pattern of inflammatory response and SARS-CoV-2 lineage involved in infection. However, the clinical course of the disease is extremely heterogeneous, and reliable biomarkers predicting adverse prognosis are lacking. Our aim was to elucidate the prognostic role of a novel marker of coronary artery disease inflammation, peri-coronary adipose tissue attenuation (PCAT), available from high-resolution chest computed tomography (HRCT), in COVID-19 patients with severe disease requiring hospitalization.

Methods. Two distinct groups of patients, admitted to Parma University Hospital in Italy with COVID-19 in March 2020 and March 2021 (first and third wave peaks of COVID-19 pandemic in Italy, with prevalence of wild-type and B.1.1.7 SARS-CoV-2 lineage, respectively) were retrospectively enrolled. The primary endpoint was in-hospital mortality. Demographic, clinical, laboratory, HRCT data and coronary artery HRCT features (coronary calcium score and PCAT attenuation) were collected to establish which variables were associated with mortality.

Results. Among the 769 patients enrolled, 555 (72%) were discharged alive and 214 (28%) died. In multivariable logistic regression analysis, age (p<0.001), number of chronic illnesses (p<0.001), smoking habit (p=0.006), P/F ratio (p=0.001), platelet count (p=0.002), blood creatinine (p<0.001), non-invasive mechanical ventilation (p<0.001), HRCT visual score (p<0.001) and PCAT (p<0.001), but not the calcium score, were independently associated with in-hospital mortality.

Conclusions. Coronary inflammation, measured with PCAT on chest HRCT, was independently associated with higher mortality in patients with severe COVID-19, while the pre-existent coronary atherosclerotic burden was not associated with adverse outcomes after adjustment for covariates.

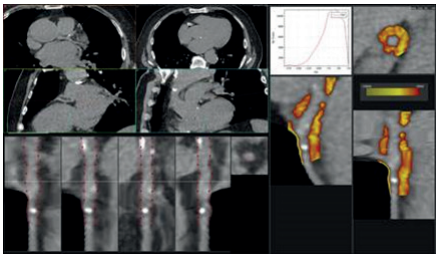

DIABETE E MALATTIE DEL METABOLISMO

A551: INCLISIRAN, NEW FRONTIER IN HYPOLIPIDEMIC THERAPY: REAL-WORLD DATA

Giulia Guidotti (a), Viola Liberati (a), Martina Berteotti (a), Elena Lotti (a), Francesco Alfano (a), Andrea Sorrentino (a), Rossella Marcucci (a)
(a) DIPARTIMENTO DI MEDICINA SPERIMENTALE E CLINICA, UNIVERSITÀ DEGLI STUDI DI FIRENZE, MALATTIE ATEROTROMBOTICHE

Background. In October 2023 AIFA approved a new molecule targeting PCSK9, Inclisiran, a siRNA which selectively target hepatocytes where it promotes cleavage of intracellular PCSK9 mRNA, with an advantage versus Evolocumab and Alirocumab, PCSK9-inhibitors (PCSK)-i), relative to the lower number of administrations. While this drug has shown efficacy and safety in randomized controlled trial, its applicability in real-world clinical settings remains to be elucidated. Therefore, this analysis aims to assess the early effects of this drug in a tertiary centre lipid and cardiovascular risk clinic.
Population and Methods. We performed a retrospective analysis of the first 50 patients who received a single dose of Inclisiran at our clinic between 1 January 2023 and 1 July 2023. Data were collected using electronic healthcare records. The lipid profile was assessed before starting the treatment and at 3 months follow-up. Data on adverse events were also recorded.
Results. Our population consisted of 50 patients: 16 (32%) female, mean age of 59,24±13 years, 12 (54,5%) with heterozygous familial hypercholesterolemia, 16 (32%) at high risk and 34 (68%) at very hight risk. 36 (72%) patients, re-evaluated at 3 months follow-up, show a mean baseline LDL-C reduction from 130,6±62 mg/dL to 81,1±48 mg/dL by 24,7±49%. Notably in patients not previously treated with others PCSK9-i (n=26), eg. Evolocumab and alirocumab, the median LDL-C relative reduction was 43.8 ± 25%, with a wide range of responses ranging from 8,3% to 87,4%, while in patients who switched from others PCSK9-i to Inclisiran (n=10) we observed a relative increase of 19.6±67%. 11 (30,6%) patients achieved a 50% or greater reduction in LDL-C from baseline; 14 (37,8%) patients reached ESC guidelines LDL-C target: 2 at high-risk patients (LDL-C target <70 mg/dL) and 12 at very high risk patients (LDL-C target <55 mg/dl). Predictably, we could observe a significantly higher probability of reaching LDL-C target at 3 months in patients on triple therapy (p<0.001), showing the role of background lipid lowering therapies (LLTs). Adverse events were recorded in two patients (5,6%): one patient complained headache and dyspepsia, while the other patient reported palpitations and asthenia, resulting in the discontinuation of the therapy.
Conclusions. In naïve patients Inclisiran shown an efficacy such as that reported in trials, with good security profile. As might be expected, given the 10% lower efficacy of Inclisiran compared to the other PCSK9-i, patients who switched from Evolocumab or Alirocumab to Inclisiran showed an increase of baseline LDL-C levels, which however remained close to the recommended target. We are aware that Inclisiran has been shown to reach its peak of efficacy after the second administration at 3 months. Thus, further studies on larger samples providing data after the second administration will be needed. At last, despite the effectiveness of these new therapeutic options, background LTTs therapy keep his relevance in order to achieve the LDL-C target.

A552: CARDIAC COMORBIDITIES IN MCARDLE DISEASE: SYSTEMATIC REVIEW FROM A CASE REPORT

Lorenzo Bianchi (c), Domeniko Hoxhaj (a), Gabriele Vadi (a), Pietro Ameri (b, c), Italo Porto (b, c)
(a) DEPARTMENT OF CLINICAL AND EXPERIMENTAL MEDICINE, UNIVERSITY OF PISA, PISA, ITALY; (b) CARDIOVASCULAR DISEASE UNIT, IRCCS OSPEDALE POLICLINICO SAN MARTINO, GENOA, ITALY; (c) DEPARTMENT OF INTERNAL MEDICINE, UNIVERSITY OF GENOA, GENOA, ITALY

Introduction. McArdle syndrome is a rare form of glycogenosis (type 5), due to deficiency of the musculoskeletal enzyme myophosphylase that manifests itself as exercise intolerance, cramps and myalgias, occasionally rhabdomyolysis, myoglobinuria, and kidney failure. Cardiac involvement is a rare occurrence, according to the few data reported in the literature.
Case presentation. A 72 years old man, hypertensive and dyslipidemic, suffering from mitral valvulopathy by prolapse of the posterior leaflet, at 61 years was subjected to cardiac surgery of mitral and tricuspidal annuloplasty. Preoperative coronary angiography showed stenosis of the circumflex artery and the right coronary, which were not revascularized in that context. The patient was also suffering from McArdle syndrome, diagnosed at the age of 63, which caused a progressive limitation of physical activity and muscle cramps, associated with the phenomenon of "second wind" with a negative history of myoglobinuria and kidney failure. At the age of 72 he performed electively coronary angioplasty with placement of two stents on both the circumflex artery and the right coronary. Due to myopathy, an inhibitor PCSK9 was prescribed, which was effective in controlling LDL values and was muscle safe in a one-month follow-up.
Objectives. To evaluate cardiac comorbitidies in patients with McArdle syndrome, as this is an association not well known in literature.
Methods. A systematic review of the literature was conducted by MEDLINE/Pubmed, with no time limit until July 2023. Case reports, case series, and retrospective studies that clearly described cardiac comorbidities in McArdle syndrome patients were selected as eligibility criteria. Articles of patients with type 5 glycogenosis without cardiac comorbidities or with McArdle syndrome and heart disease without an accurate description of cardiac comorbidity were excluded.
Results and Conclusions. 7 case reports and 1 retrospective study were included in this review. For case reports, the average age was 54.3 years (range 29-69) and 85.7% were male. As for heart disease, four patients (57.1%) suffered from coronary heart disease (CAD), one from aortic bicuspidy (14.3%), one from dilated cardiomyopathy (14.3%) and two from hypertrophic cardiomyopathy (28.6%), one of which had also CAD. The prevalence of CAD in the retrospective study was 33% (5 of 14 patients with glycogenosis V). Contrary to what was previously thought, emerged the hypothesis that glycogenosis type 5 may predispose to an accelerated atherosclerotic process, given the high prevalence of coronary heart disease in this population, despite the limited number of cases. In addition, associations between glycogenosis V and hypertrophic and dilated cardiomyopathy, aortic bicuspidy and mitral prolapse were reported; the latter had apparently never been described. A cardiological screening might be recommended in McArdle disease to detect and manage cardiac comorbidities, and to improve the outcome of these patients.

A553: INCLISIRAN: SICUREZZA ED EFFICACIA ANCHE IN REAL LIFE?

Francesco Briani (a, b), Mauro Bagli (a, b), Gabriele Bertani (a, b), Margherita Fabroni (a, b), Andrea Bottardi (a, b), Antonio Mugnolo (a), Gabriele Venturi (a), Alberto Zamboni (a), Francesco Bacchion (a), Giorgio Morando (a)
(a) OSPEDALE MATER SALUTIS LEGNAGO; (b) AOUI VERONA

Introduzione. Inclisiran è un nuovo farmaco ipolipemizzante appartenente alla classe degli small interfering RNA (siRNA), molecola in grado di interagire con l'RNA messaggero (mRNA) di PCSK9 ed impedirne la traduzione. È indicato in pazienti adulti affetti da ipercolesterolemia primaria o da dislipidemia mista che non abbiano raggiunto il target terapeutico, nonostante terapia ipolipemizzante con statina ed ezetimibe al massimo dosaggio tollerato o per intolleranza alla terapia statinica.
Risultati. Presentiamo i dati parziali del follow-up di 19 pazienti in trattamento con Inclisiran presso la Cardiologia dell'Ospedale Mater Salutis di Legnago, da settembre 2022 ad oggi. L'età media dei pazienti è 65 anni, di cui un quarto affetti da diabete mellito, il 90% da ipertensione arteriosa ed il 63% con pregressi eventi cardiovascolari. La maggior parte dei pazienti presentano un rischio cardiovascolare estremamente alto e molto alto (84%) secondo le linee guida ESC 2019. Circa l'85% dei pazienti erano in trattamento con statina ed ezetimibe. Il valore medio di colesterolo LDL pre-trattamento con Inclisiran era 118 mg/dl. Dai dati raccolti abbiamo osservato un miglioramento dei valori di LDL già nella prima settimana dopo la prima somministrazione del farmaco, raggiungendo a 1 mese una riduzione del 56% (dato in linea con gli studi registrativi). Tale riduzione si confermava stabile nel controllo a 3 e 6 mesi ed ha permesso il raggiungimento del target LDL in due terzi della popolazione. Il trattamento è risultato ben tollerato, in assenza di effetti collaterali. Al momento nessuno dei pazienti trattati ha presentato eventi cardiovascolari durante il follow-up.
Conclusioni. Sulla base di queste osservazioni preliminari real life, la terapia con Inclisiran risulta uno strumento sicuro ed efficace nel raggiungimento del target LDL in pazienti ad elevato rischio cardiovascolare.

Colesterolo LDL	mg/dl	Riduzione
Basale	118	
1 settimana	90	24%
1 mese	52	56%
3 mesi	53	55%
6 mesi	50	58%

A554: IMPROVEMENT OF GLOBAL LONGITUDINAL STRAIN AND MYOCARDIAL WORK IN TYPE 2 DIABETES PATIENTS ON SODIUM GLUCOSE CONTRASPORTER INHBITORS THERAPY

Carmen Del Giudice (a), Marco Malvezzi Caracciolo D'Aquino (a), Alfredo Caturano (a), Gabriella Scognamiglio (a), Enrica Pezzullo (a), Dario Fabiani (a), Andreina Carbone (c), Roberta Bottino (c), Valentina Caso (a), Gerardo Nigro (a), Biagio Liccardo (a), Antonello D´andrea (b), Paolo Golino (a), Vincenzo Russo (a)
(a) AORN MONALDI- UNIVERSITÀ DELLA CAMPANIA, LUIGI VANVITELLI, NAPOLI; (b) PO UMBERTO I, DIPARTIMENTO DI CARDIOLOGIA, NOCERA INFERIORE (SA); (c) UNIVERSITÀ DELLA CAMPANIA-LUIGI VANVITELLI, NAPOLI

Introduction. Sodium-glucose cotransporter 2 inhibitors (SGLT2-i) are a novel class of oral hypoglycaemic agents currently used among patients with type 2 diabetes mellitus (T2DM). The effects of SGLT2-i inhibitors on cardiac structure and function are not fully understood. The aim of the present study is to evaluate the echocardiographic changing among patients with well-controlled TDM2 treated with SGLT2-i inhibitors in real-world setting.
Methods. 35 well-controlled T2DM patients (65± 9 years, 43.7% male) with preserved left ventricular ejection fraction and 35 age and sex-matched controls were included. T2DM patients underwent clinical and laboratory evaluation; 12-lead surface electrocardiogram (ECG); 2-dimensional color Doppler echocardiography at enrolment, before SGLT2-i administration, and at six months follow-up after an uninterrupted 10 mg once daily of Empagliflozin (n: 21) or Dapagliflozin (n: 14). Standard echocardiographic measurements, LV global longitudinal strain (LV-GLS), global wasted work (GWW) and global work efficiency (GWE) were calculated.
Results. T2DM patients showed higher E\E' ratio (8.3±2.5 vs 6.3±0.9; p=0.0001) and lower LV-GLS (15.8±8.1 vs. 22.1±1.4%; p=0.0001) and global myocardial work efficiency (91±4 vs 94±3%; P: 0.0007) compared to age and sex-matched controls. At six-months follow-up, T2DM patients showed a significant increase in LVEF (58.9± 3.2 vs 62± 3.2; p=0.0001), LV-GLS (16.2±2.8 vs 18.7±2.4%; p=0.003) and GWE (90.3±3.5 vs 93.3±3.2%; P=0.0004) values; conversely, GWW values (161.2± 33.6 vs 112.72± 37.3 mmHg%; P=0.0001) significantly decreased.
Conclusions. SGLT2-I therapy showed a significant anti-remodelling effectiveness, improving the LV-GLS and MWE, among well-controlled diabetic patients with preserved left ventricular ejection fraction.

A555: DEVELOPMENT OF KEY INDICATORS FOR MONITORING THE PRESCRIPTIVE APPROPRIATENESS OF PATIENTS WITH DYSLIPIDEMIA IN A PROVINCIAL HEALTH AUTHORITY IN ITALY

Calogero Russo (a), Francesco La Tona (a), Alessandro Ghigi (b), Elisa Giacomini (b), Mario Giuffrida (a), Paola Greca (a), Carmela Nappi (b), Nicola Ferrante (c), Luca Degli Esposti (b)
(a) AZIENDA SANITARIA PROVINCIALE (ASP) DI ENNA, ENNA, ITALIA; (b) CLICON S.R.L. SOCIETÀ BENEFIT, BOLOGNA, ITALIA; (c) NOVARTIS FARMA S.P.A., MILANO, ITALIA

Objectives. This real-world analysis aimed to design and to calculate a panel of key indicators for the assessment of lipid goal achievement, appropriateness of therapy prescription and treatment utilisation and management of care for patients treated with lipid-lowering drugs in settings of clinical practice in Italy.
Methods. Patients with at least one LDL-C determination during year 2022 were identified by using the administrative and laboratory databases of a provincial health authority with a catchment area of 170,009 health-assisted residents alive in 2022. The achievement of lipid goals was assessed by comparing the last detected LDL-C value with the lipid goals indicated by European guidelines (LDL-C goals <70 mg/dL for high CV risk and <55 mg/dL for very high CV risk, <116 others). For the definition of cardiovascular risk level, an adaptation of the European guidelines was applied. The presence of lipid-lowering treatments (statins, ezetimibe or PCSK9 inhibitors) was detected in the 6 months preceding the last LDL-C test. The following indicators were developed: outcome indicators (% treated patients who did not reach the lipid goals); refill indicators (% treated patients that refill therapy without interruption); appropriateness (% treated patients prescribed with lipid-lowering drugs recommended by the Note 13 of the Italian Medicine Agency – AIFA); specialist visit indicators (% treated patients with specialistic visit in the 3-month before the last LDL-C detection.
Results. Overall, 8,057 patients with LDL-C determination were included in the present analysis: 5,159 were not receiving lipid-lowering drugs prior the LDL-C test, however, among them 1,973 patients at high CV risk and 518 patients at very high CV risk had LDL-C levels higher than the target ones. The key indicators were calculated among the 2,898 patients treated with lipid-lowering drugs (of which 1,619 and 1,036 were at high and very high CV risk, respectively). The outcome indicators showed a failure in reaching lipid goals in 72% of all patients (N=2,095), in 74% of patients at high cardiovascular risk (N=1,203 not reaching the recommended LDL-C of 70 mg/dL) and in 77% of patients at very high risk (N=796 not reaching the recommended LDL-C of 55 mg/dL). Refill indicators showed a proportion of 82% (N=2,390), who were still on lipid-lowering treatment at the end of 2022, and similar proportions were observed in patients at high or very high CV risk. The appropriateness indicators revealed 36% (N=586) of patients at high risk and 54% (N=562) at very high risk were prescribed therapies recommended by the AIFA Note 13. Finally, 93% (N=2,681) of patients did not have a specialist visit during a 3-month period before the LDL-C detection.
Conclusions. In spite of some limitations of this real-world analysis, as relatively short observational period, a number of priorities were identified to improve the better management of dyslipidemia, as patients who failed reaching the lipid goals even though they are under treatment and refill their prescription or not yet treated, and the optimization of the therapeutic approach, especially for those at high and very high CV risk. The periodic monitoring of the presented indicators will allow to evaluate the actions that will be undertaken in order to improve the management of patients with dyslipidemia.

A556: ASSOCIAZIONE TRA NEUROPATIA AUTONOMICA CARDIACA E 1H-PLPG IN SOGGETTI A DIFFERENTE TOLLERANZA GLICEMICA

Raffaele Jiritano (a), Giuseppe Monea (a), Luca Salerno (a), Ennio Abramo (a), Ylenia Varano (a), Maria Resilde Natale (a), Alberto Cosenza (a), Francesco Andreozzi (a)
(a) UNIVERSITÀ DEGLI STUDI MAGNA GRAECIA-DIPARTIMENTO DI MEDICINA E CHIRURGIA-U.O.C. MEDICINA INTERNA

Numerose sono le evidenze cliniche su come soggetti euglicemici (NGT) e con parametri di tolleranza glucidica nella norma ma un valore di glicemia>155 mg/dL a 1 h da un carico orale standard di glucosio (1h PLPG) (1h-high) siano a rischio incrementato di DMT2 e danno microvascolare subclinico, predittori di eventi cardiovascolari avversi futuri. La Neuropatia Cardiaca Autonomica è una seria complicanza del Diabete che predispone il paziente a ipotensione ortostatica, intolleranza allo sforzo, aritmie severe e SCA; essa rappresenta tuttavia una condizione sottostimata. I segni iniziali della CAN sono legati ad uno sbilanciamento del rapporto tra sistema nervoso parasimpatico e ortosimpatico a favore del secondo e sono associati a variazioni dei parametri di Heart Rate Variability e della PA. Allo stato attuale i rapporti associativi tra 1hPLPG>155 mg/dl negli euglicemici e lo sviluppo di CAN non sono stati approfonditi.
Metodi. Il nostro studio è stato condotto su una coorte di 39 soggetti divisi per classe di tolleranza glicemica. 10 individui erano NGT, 10 soggetti afferivano al gruppo NGT-1H, 9 mostravano ridotta tolleranza al glucosio (Impaired Glucose Tolerance, IGT), mentre a 10 soggetti è stata posta una nuova diagnosi di T2DM. Tutti i soggetti dello studio, infatti, sono stati sottoposti a test di tolleranza orale al glucosio (OGTT) con un carico di 75 g. Sono stati effettuati prelievi ematici a 0, 30, 60, 90 e 120 minuti per misurare i livelli plasmatici di glucosio e insulina.La presenza di CAN è stata valutata attraverso una applicazione del pannello di Ewing e del relativo score (0-5), comparabile allo score di Bellavere, composto da una batteria di 5 test: valutazione di ipotensione ortostatica, incremento diastolico pressorio durante stretta submassimale su dinamometro, rapporto RR tra il 30° e il 15 ° battito dopo assunzione dell'ortostatismo, rapporto tra RR max/min. in Valsalva, rapporto RR massimo espiratorio/minimo inspiratorio. Uno score di 1.5 è considerato come cut-off per diagnosi di CAN. I pazienti sono stati sottoposti inoltre a monitoraggio ECG di 24 h con un registratore Holter tricanale con valutazione dell'HRV.
Risultati. La prevalenza di CAN fosse significativamente maggiore nei NGT-1H rispetto ai NGT e simile a quella riscontrata nei gruppi IGT e T2DM (p<0.001). Conseguentemente a questa osservazione, tutte le misure di HRV erano ridotte in maniera similare nei soggetti NGT-1H, IGT e TD2M rispetto al gruppo NGT. Inoltre, un'analisi di correlazione parziale corretta per età, sesso e body mass index (BMI) ha evidenziato come i valori di 1H-PG fossero negativamente correlati con ogni misura di HRV. Per valutare il contributo indipendente dei valori di 1H-PG al rischio di CAN, è stata eseguita un'analisi di regressione logistica multipla includendo età, sesso e BMI come covariate; 1H-PG è risultata significativamente associata con un lieve aumento del rischio di CAN (OR=1,091; p=0.010). L'associazione ha mostrato una lieve attenuazione quando nel modello è stata inclusa anche il fasting glucose (OR=1,080; p=0.024), mentre si è dimostrata maggiore quando si è inclusa la glicemia a due ore dall'OGTT (OR=1,100; p=0.02) o il valore di HOMA-IR come indice di insulino-resistenza (OR=1,100; p=0.04).
Conclusioni. I nostri risultati mostrano evidenza di come elevati valori di 1h-PLPG siano un predittore di sviluppo di CAN, con prevalenza nei 1h-high comparabile al soggetto diabetico e prediabetico, giustificando l'ipotesi che questa categoria di pazienti debba essere studiata più attentamente per la stratificazione del rischio aritmico. Studi prospettici sono necessari per valutare l'impatto sulla mortalità per cause cardiovascolari.

A557: EVOLOCUMAB AND ALIROCUMAB: A REAL WORLD PHOTOGRAPHY

Viola Liberati (a), Giulia Guidotti (a), Martina Berteotti (a), Elena Lotti (a), Francesco Alfano (a), Andrea Sorrentino (a), Rossella Marcucci (a)
(a) DIPARTIMENTO DI MEDICINA SPERIMENTALE E CLINICA, UNIVERSITÀ DEGLI STUDI DI FIRENZE, SOD MALATTIE ATEROTROMBOTICHE, AOU CAREGGI

Background. There is a growing gap between the ideal guidelines LDL-C targets and the LDL-C levels achieved in clinical practice. Indeed, real

world data show that about 80% of (very) high risk patients disregarded guideline recommendations. Therefore, our aim was to provide data of PCSK9i use in clinical practice investigating the adherence to guideline recommendations, with a focus on the role of background oral lower lipid therapy in the probability of target attainment.
Methods. Between April 2018 and December 2023, patients evaluated at our center and who started PCSK9-i therapy were included in a prospective registry. The lipid profile was assessed before starting PCSK9i therapy and during follow-ups that were performed every six months, with a median follow-up of 24 (6-48) months. Results are presented for the total population and stratified by patient subgroups: high risk patients with asymptomatic heterozygous familial hypercholesterolemia (LDL-C target <70 mg/dl) and very high risk patients with known atherosclerotic cardiovascular disease (LDL-C target <55 mg/dl)
Results. Our cohort consisted of 271 patients: 100 (36,9%) women, mean age of 65,1±11,1 years, 60 (22,1%) at high risk and 211 (77.9%) at very high risk. At the first 6 month follow up, mean baseline LDL-C values decreased from 144,8±52,7 mg/dL to 59,3±37,4 mg/dL (from 183,8±46,9 to 75,1±37,8 in high risk patients and from 130,9±41,5 to 55,2±36,4 in very high risk patients), with a mean relative reduction of 57.4±26.1%, similar in the two subgroups. At 6 months 57.7% patients reach their LDL-C target according to the latest ESC guidelines: 51.1% patients at high risk (target <70 mg/dl), and 59.4% at very high risk (target <55 mg/dl). The percentage of patients on target did not change significantly in subsequent follow-ups. Background oral hypolipidemic therapy was a predictor of optimal LDL-C control: the presence of at least one lipid lowering drug was associated with significantly lower LDL-C levels (87,1±36,1 mg/dl vs 59,5±8,7, p<0,001) and consequently with a significantly higher probability of reaching the target (59,6% vs 20,6%, p<0,001). Three patients underwent percutaneous coronary revascularization for an acute coronary syndrome (2 and 6 months after starting the treatment). During follow-up, 5 patients switched to Inclisiran therapy, 2 due to adverse events (flu-like syndrome) and 3 for reduced therapeutic adherence.
Conclusions. In conclusion, our analysis confirms that PCSK9i are safe and effective drugs, allowing most patients of our cohort to reach LDL-C target through a 55-60% reduction. Among the predictors of therapeutic failure, the absence of concomitant oral lower lipid therapy played a key role, confirming the value of combination therapy in the management of patients at (very) high cardiovascular risk and the importance of its persistence over time.

A558: THE IMPACT OF EPICARDIAL FAT THICKNESS ON LEFT ATRIAL STRAIN AND DIASTOLIC FUNCTION IN NORMAL WEIGHT AND OVERWEIGHT PATIENTS

Giancarlo Trimarchi (a), Saro Pistorio (a), Giovanni Taverna (a), Lucio Teresi (a), Maurizio Cusmà Piccione (a), Roberta Manganaro (a), Cesare De Gregorio (a), Antonio Micari (b), Gianluca Di Bella (a), Concetta Zito (a), Scipione Carerj (a)
(a) DEPARTMENT OF CLINICL AND EXPERIMENTAL MEDICINE, CARDIOLOGY UNIT, UNIVERSITY OF MESSINA, MESSINA, ITALY; (b) DEPARTMENT OF BIOMEDICAL AND DENTAL SCIENCES AND MORPHOLOGICAL AND FUNCTIONAL IMAGING, UNIVERSITY OF MESSINA, MESSINA, ITALY

Background. The proximity of epicardial adipose tissue to the heart and its high metabolic activity make it a key player in cardiovascular diseases. Epicardial fat thickness (EFT) assessment has become a crucial factor in determining cardiometabolic risk. EFT is commonly calculated as the distance on the free wall of the right ventricle at end-systole between the outer wall of the myocardium and the visceral layer of the pericardium from the parasternal long axis view. The metabolic syndrome, insulin resistance, coronary artery disease, subclinical atherosclerosis, and heart failure are all substantially correlated with EFT. In this context, the evaluation of diastolic function and left atrial (LA) strain analysis may provide a better insight on predisposing conditions that can led to the development of heart failure with preserved ejection fraction (HFpEF) in patients with increased EFT.
Aim. To evaluate the impact of epicardial fat thickness on diastolic function and LA function, assessed by strain analysis, in normal weight and overweight patients.
Methods. 80 patients were retrospectively enrolled, distinguishing between 31 pts with EFT>5 mm and 49 pts with EFT <5 mm. All patients underwent a complete transthoracic echocardiogram in order to measure EFT, to assess diastolic function and calculate LA strain parameters: LA reservoir function (LAres), LA conduit function (LAcd) and LA contraction function (LAct).
Results. There were no differences between patients with EFT>5 mm and those with EFT<5 mm in terms of sex (23 vs 25 male pts; p=0,06), age (46,6±11,1 vs 45±12 yrs; p=0,06), and systolic blood pressure (133,3±19 vs 126,1±14 mmHg; p=0,06); while the first group showed significantly higher values of mean arterial pressure (98±15 vs 91±11 mmHg; p=0,02), diastolic blood pressure (82±13 vs 74±10 mmHg; p=0,004), prevalence of dyslipidemia (51 vs 17%; p=0,002), smoking habit (55 vs 17%; p=0,03) and diabetes (16 vs 2%; p=0,03). There was no significant difference regarding mitral annulus systolic myocardial velocity (S') at Tissue Doppler Imaging (10±1,6 vs 10±1,7 cm/sec; p=0,7) and ejection fraction (60±5 vs 59±6%; p=0,2); while LV mass index (78±15 vs 68±22 g/m2; p=0,04) is significantly higher in patients with EFT>5 mm. Regarding diastolic function parameters, there was no difference in terms of E/A ratio (1,09±0,3 vs 1,10±0,4; p=0,3), E/e' ratio (6,3±1,2 vs 6,2±2,1; p=0,8), tricuspidal annular plane systolic excursion (TAPSE) (23±2,8 vs 22±2,4 mm; p=0,1), tricuspidal S' (14,4±1,4 vs 13±2,4 cm/sec; p=0,1), LAVi (24±7 vs 21±7 ml/m2; p=0,1) and diastolic dysfunction degree (11 pts vs 12 pts grade I; p=0,1), while systolic pulmonary artery pressure (SPAP) (±0,3 vs 1,10±0,4 mmHg; p=0,006) is higher in patients with increased EFT. LA strain analysis showed that LAres (35±7 vs 40± 8%; p=0,01) and LAcd (-19±6,1 vs -23±8%; p=0,02) are significantly reduced in patients with EFT>5 mm, while there is no difference between the two groups in terms of LA ct (-16±5 vs -17± 5%; p=0,5). Regarding correlations, EFT inversely correlates to LAres and it directly correlates to LAcd (r=0,34; p=0,01) and SPAP (r=0,47; p=0,002).
Conclusions. LA strain analysis offers a deeper understanding of the underlying conditions that contribute to the development of heart failure with preserved ejection fraction (HFpEF) in patients with heightened EFT.

A559: EVALUATION OF ARTERIAL STIFFNESS THROUGH PULSE WAVE VELOCITY MEASUREMENT IN PATIENTS WITH INCREASED EPICARDIAL FAT THICKNESS

Giancarlo Trimarchi (a), Paolo Bellocchi (a), Lucio Teresi (a), Olimpia Trio (a), Roberta Manganaro (a), Maurizio Cusmà Piccione (a), Cesare De Gregorio (a), Antonio Micari (b), Gianluca Di Bella (a), Concetta Zito (a), Scipione Carerj (a)
(a) DEPARTMENT OF CLINICAL AND EXPERIMENTAL MEDICINE, CARDIOLOGY UNIT, UNIVERSITY OF MESSINA, MESSINA, ITALY; (b) DEPARTMENT OF BIOMEDICAL AND DENTAL SCIENCES AND MORPHOLOGICAL AND FUNCTIONAL IMAGING, UNIVERSITY OF MESSINA, MESSINA, ITALY

Background. Epicardial fat thickness (EFT) assessment has a key role in determining cardiometabolic risk. It is commonly calculated as the distance on the free wall of the right ventricle at end-systole between the outer wall of the myocardium and the visceral layer of the pericardium from the parasternal long axis view. It is already known than An EFT>7 mm strongly correlates with higher left ventricular (LV) mass index, diastolic dysfunction degree, and with increased carotid stiffness and intima-media thickness. In this context, carotid–femoral pulse wave velocity (PWV) is considered the gold standard for arterial stiffness assessment in clinical practice and may help in better characterizing individual individual risk profile, if combined with EFT evaluation.
Aim. To evaluate the impact of epicardial fat thickness on arterial stiffness of entire carotid-femoral arterial axis, assessed by PWV analysis, in patients with preserved ejection fraction.
Methods. 80 patients were retrospectively enrolled, distinguishing between 20 pts with EFT>7 mm and 60 pts with EFT <7 mm. All patients underwent a standard transthoracic echocardiogram to measure EFT and at the same time carotid-femoral pulse wave velocity (PWV) measurement through an applanation tonometry system.
Results. There were no differences between patients with EFT>7 mm and those with EFT<7 mm in terms of sex (55 vs 65% male pts; p=0,2), age (46,6±10 vs 39±13 yrs; p=0,06), systolic blood pressure (132±19 vs 127±16 mmHg; p=0,2) mean arterial pressure (99±14 vs 92±13 mmHg; p=0,07) prevalence of diabetes (15 vs 5%; p=0,1) and smoking habit (21 vs 13%; p=0,1); while patients with EFT>7 mm showed significantly higher values of diastolic blood pressure (82±10 vs 75±12 mmHg; p=0,03) and higher prevalence of dyslipidemia (52 vs 23%; p=0,02) than those with EFT <7 mm. Moreover, there was no significant difference regarding LV ejection fraction (60±5 vs 59±6%; p=0,2), while LV mass index (77±15 vs 70±21 g/m^2; p=0,04) is significantly higher in patients with EFT>7 mm. Regarding evaluation of arterial stiffness, patients with EFT>7 mm have significantly higher values of PWV (9,5±2,4 vs 8,4±1,9 m/sec; p=0,04), furthermore EFT directly correlates with PWV (r=0,30; p=0,02) and LVMi (r=0,36; p=0,03).
Conclusions. EFT can impact on arterial stiffness and its evaluation in combination with carotid-femoral PWV may better stratify individual overall cardiovascular risk profile. Compared to previous literature data which were limited to the assessment of arterial stiffness of the carotid district only, our results establish a direct correlation between EFT and PWV, calculated using applanation tonometry, along the entire carotid-femoral arterial axis.

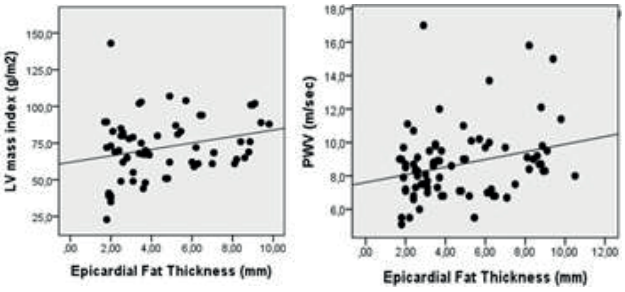

A560: C2CD4B ELICITS ENOS UNCOUPLING VIA A PI3K/AKT/PKC-ALPHA SIGNALING PATHWAY AND ITS INHIBITION PREVENTS HYPERGLYCEMIA-INDUCED ENDOTHELIAL DYSFUNCTION

Paola Di Pietro (a), Valeria Prete (a), Angela Carmelita Abate (a), Antonio Damato (b), Eleonora Venturini (b), Carmine Izzo (a), Maria Rosaria Rusciano (a), Valeria Visco (a), Michele Ciccarelli (a), Albino Carrizzo (a, b), Carmine Vecchione (a, b)
(a) DIPARTIMENTO MEDICINA, CHIRURGIA ED ODONTOIATRIA, UNIVERSITÀ DEGLI STUDI DI SALERNO, BARONISSI; (b) UNITÀ DI FISIOPATOLOGIA VASCOLARE, I.R.C.C.S. INM NEUROMED, POZZILLI

High glucose-induced endothelial dysfunction is an important pathological feature of diabetic vasculopathy. Whilst genome-wide studies have identified association between type 2 diabetes mellitus and increase expression of C2 calcium dependent domain containing 4B (c2cd4b), no study has yet explored the possible direct effect of c2cd4b on vascular function. To this aim, pressure myograph was used to perform vascular reactivity studies. Nitric oxide and oxidative stress were assessed by difluorofluorescein diacetate and dihydroethidium, respectively. High glucose upregulated C2CD4b mRNA expression in mice mesenteric arteries in a time-dependent manner. Interestingly, inhibition of C2CD4b expression by genetically knockdown efficiently prevented hyperglycemia-induced endothelial dysfunction. Through in vitro studies, we found that recombinant c2cd4b evoked endothelial dysfunction of mice mesenteric arteries, an effect associated with increased reactive oxygen species (ROS) production and decreased nitric oxide (NO) bioavailability. In isolated human umbilical vein endothelial cells (HUVECs), c2cd4b increased phosphorylation of endothelial nitric oxide synthase (eNOS) at the inhibitory site Thr494 and reduced endothelial eNOS dimerization. Interestingly, pharmacological inhibition of phospho-inositide 3-kinase (PI3K)/Akt pathway with wortmannin effectively attenuated oxidative stress, NO reduction, impairment of endothelial function, and eNOS uncoupling induced by c2cd4b. Furthermore, recombinant c2cd4b upregulated protein expression of phosphorylated PKCa, an effect that was counteracted by wortmannin pretreatment. Interestingly, PKCa inhibitor, Go6976, prevented c2cd4b-induced eNOS dysfunction in HUVECs, thus suggesting its contribution in c2cd4b signaling cascade, acting downstream of PI3K to mediate uncoupling of eNOS. These data demonstrate for the first time that c2cd4b exerts a direct effect on vascular endothelium via a PI3K/Akt/PKC alpha-signaling pathway, and provide a new perspective on c2cd4b as a promising therapeutic target for the prevention of diabetes-associated vascular complications.

A561: EARLY DIAGNOSIS OF SUBCLINICAL ATHEROSCLEROSIS IN ASYMPTOMATIC TYPE 2 DIABETIC NORMOTENSIVE POSTMENOPAUSAL WOMEN

Maria Maiello (b), Francesca Amati (a), Marco Matteo Ciccone (a), Pasquale Palmiero (b, c)
(a) CARDIOVASCULAR DISEASE SECTION, DETO, UNIVERSITY OF BARI; (b) CARDIOLOGY EQUIPE, DSS 1, ASL BRINDISI; (c) SCHOOL OF MEDICINE, BRINDISI SITE, UNIVERSITY OF BARI

Background. Arterial stiffness is a marker of cardiovascular disease useful to identify, at an early stage, subjects with higher cardiovascular risk.
Aims. The goal of our study was to assess the prevalence of arterial stiffness, assessed by global Pulse Wave Velocity (gPWV), among diabetic normotensive postmenopausal women (DPMW) and its correlation with glycosylated hemoglobin (HbA1c) levels.
Patients and Methods. We enrolled 641 consecutive DPMW affected by type 2 diabetes, diagnosed over five years. 300 normotensive normoglycemic postmenopausal women were included as the control group (CG). We assessed arterial stiffness by gPWV, performed by pulsed Doppler (3.5 MHz probe) using 2-dimensional guidance and ECG trigger. Philips Epiq 7 was used which is an echo-Doppler system equipped with a multifrequency transducer. The gPWV was assessed as normal for a velocity equal to or lower than 7.1 m/s.
Results. 29 (4.5%) women had an increased gPWV among 641 DPMW, and 4 (1.3%) among 300 women of CG, p<0.01. There was no difference in mean age between the two groups: 57±12 and 56±4 respectively, p=0.2. DPMW with HbA1c>7.5% were 228 (35.6%), 205 (32%) had an increased gPWV, and 23 (3.6%) had a normal gPWV. Women with HbA1c <7.5% were 413 (64,4%), and 6 had an increased gPWV (0.9%), p<0.0000. DPMW with abnormal ECG were 207 (32.3%), 11 of them had an increased gPWV (5.3%), p=0.5 versus women with an increased gPWV and normal ECG, 18 (4.1%).
Conclusions. We found a high prevalence of increased gPWV in asymptomatic normotensive DPMW; there is a statistically significant correlation between increased gPWV and HbA1c high levels, but there is not between increased gPWV and abnormal ECG rate, however, actually ECG is the unique cardiologic test recommended by current Guidelines in all diabetic patients. We conclude that early detection of the high level of HbA1c and increased PWV may identify asymptomatic DPMW with a higher risk to develop cardiovascular disease; while a simple ECG, when normal, is not enough to assess the cardiovascular risk in our population.

A562: PREVALENZA SUBOTTIMALE DEL RAGGIUNGIMENTO DEI TARGET TERAPEUTICI IN PAZIENTI IPERCOLESTEROLEMICI A RISCHIO MOLTO ALTO: IMPATTO DELLA DIAGNOSI ALLA PRESENTAZIONE E DEL SESSO ED UTILITÀ DELLA MISURAZIONE DEI VALORI DI LIPOPROTEINA (A)

Giuseppe Merola (a), Vincenzo Lombardo (a), Giuseppe Tartaglione (a), Vincenzo D'Ambrosio (a), Artemisia Ruggiero (a), Nicole Carabetta (a), Ciro Indolfi (a), Daniele Torella (a), Salvatore De Rosa (a)
(a) UNIVERSITÀ MAGNA GRAECIA DI CATANZARO

Introduzione. Le terapie ipolipemizzanti sono fondamentali per la prevenzione cardiovascolare ma diversi registri hanno evidenziato che una quota importante dei pazienti non raggiunge i target di LDL prefissati. Il dosaggio dei livelli di Lp(a), una lipoproteina a bassa densità, dai noti effetti pro-aterogeni, può consentire una più accurata stratificazione del rischio cardiovascolare. Questo registro retrospettivo monocentrico ha l'obiettivo di caratterizzare il profilo di rischio clinico e i livelli di lipidi plasmatici in una popolazione di pazienti ad elevato rischio cardiovascolare giunti all'attenzione clinica presso un centro terziario. In particolare, si intende definire l'impatto della misurazione di Lp(a) sul profilo di rischio ed il raggiungimento dei valori target.
Metodi. Questo studio ha incluso pazienti ad elevato rischio cardiovascolare, per cui sono stati individuati i target di LDL-C e conseguente rimodulazione della terapia ipolipemizzante. Ad ogni paziente è stato effettuato il dosaggio del pannello lipidico completo e dei livelli di Lp(a) al ricovero, utilizzando il test Roche (risultato in nmol/L) oppure il test Siemens (in mg/dL).
Risultati.I risultati del registro aperto evidenziano un'età media di 68±10 anni, di cui un terzo di sesso femminile. La diagnosi alla presentazione clinica era di Sindrome Coronarica Acuta (SCA) nel 36% dei casi e di sindrome coronarica cronica (SCC) per i rimanenti. La coorte presentava un elevato rischio cardiovascolare. Infatti, il 35.2% dei soggetti aveva una storia di IMA pregresso, tabagismo attuale o pregresso si registrava nel 57.1%, ed un terzo dei pazienti aveva una diagnosi di diabete. Il 44.7% dei soggetti aveva valori di pressione arteriosa elevati, ed il 17% presentava fibrillazione atriale. Alla presentazione, il 29% dei soggetti inclusi presentava valori di LDL-C al di sotto del target raccomandato in base al profilo di rischio. I valori di Lp(a) non correlavano con i livelli di LDL-C(p=0.657), HDL (p=0.533), né coi trigliceridi (p=0.105). Il 38.1% dei pazienti inclusi presentava valori di Lp(a) superiori a 50 mg/dl, mentre il 15.2% presentava valori superiori a 200 mg/dl. Le pazienti di sesso femminile erano meno frequentemente a target (22.9%) rispetto agli uomini (32.9%). La distanza dal target era infatti di 22.8±37.2 mg/dl per gli uomini e di 34.4±39.6 mg/dl per le donne. In aggiunta, il 20% delle donne presentava valori di Lp(a) superiori a 200 mg/dl, contro il 12.9% negli uomini. Infine, nonostante l'elevato profilo di rischio cardiovascolare e l'elevata prevalenza di un pregresso IMA, i pazienti riferiti per sindrome coronarica acuta soddisfacevano meno frequentemente i livelli target di LDL all'arrivo (13.2%), rispetto ai pazienti con SCC (38.8%), presentando una significativa differenza nella distanza di valori target di colesterolo LDL (45.3±41.4 mg/dl vs 16.2±32.1 mg/dl e; p<0.001).
Conclusioni. Nonostante la disponibilità di una gamma di farmaci ipolipemizzanti di notevole efficacia e dimostrata sicurezza, una proporzione non trascurabile di pazienti ad elevato rischio cardiovascolare giungono ancora oggi per la comparsa di nuovi sintomi di ischemia o con nuovi eventi coronarici acuti, presentando valori di colesterolo LDL al di sopra dei target raccomandati, particolarmente nei soggetti di sesso femminile. Questi risultati suggeriscono la necessità di mettere in campo strategie di sensibilizzazione sociale al rischio cardiovascolare, che informino i soggetti a rischio della disponibilità di test diagnostici molto efficienti e di terapie molto efficaci In questo contesto, il ricorso alla misurazione dei livelli di LP(a) può rivelarsi utile ad una quantificazione più precisa e personalizzata del rischio cardiovascolare dei pazienti.

A563: EVALUATION OF ADHERENCE TO LONG-TERM PHARMACOLOGICAL LIPID-LOWERING THERAPY IN OUTPATIENTS PATIENTS

Mario Paolo Miceli (a), Chiara Palermo (a), Giulia Tignanelli (a), Martina Pulicanò (b), Brunella Napolitano (c), Valentina Napolitano (d), Andrea Domenico Ruffolo (e), Vitaliano Spagnuolo (f), Dante Siclari (g)
(a) NURSING STUDENT, UNIVERSITY OF CATANZARO; (b) MEDICAL STUDENT, UNIVERSITY OF CATANZARO; (c) GRADUATE SCHOOL OF MEDICAL ONCOLOGY UNIT, CAREGGI UNIVERSITAL HOSPITAL, FLORENCE; (d) GRADUATE SCHOOL OF RADIOLOGY UNIT, UNIVERSITY OF TURIN; (e) GRADUATE SCHOOL OF GERIATRY UNIT, UNIVERSITY OF CATANIA; (f) LIPID CENTER, AO OF COSENZA; (g) ASP OF CROTON

Background. Adherence to lipid-lowering therapy is crucial in reducing cardiovascular risk. Several methods can be used to assess therapeutic adherence. The Morisky scale is a validated one and widely used as a measure of adherence.
Patients and Methods. We aimed to assess the adherence to pharmacological therapy in the first 160 patients with dyslipidemia consecutively attending our outpatient clinic dedicated to cardiovascular prevention and already under pharmacological treatment for at least twenty-four months (average 33.4±12.2). The four-item Morisky scale was used (good adherence score <3). Out of the 160 patients who were given the questionnaire, eight did not complete it in full. Among the

remaining 152 patients, 64 were females and 88 were males. The mean age was 65.38±13.38 years, and the average number of drugs taken was 2.65±1.76.
Results. Among the 152 patients who completed the assessment, eight (5.6%) showed low adherence (score ≥3). The average number of drugs taken by these patients was 3.55±0.8.
Discussion. The Morisky scale is validated in assessing forgetfulness in drug intake, intentional changes in dosage and mode of administration, and the difficulty in following a specific therapeutic regimen. In our study, the intake of therapy in a consecutive group of 160 patients with dyslipidemia under treatment with lipid-lowering drugs for a long time showed excellent adherence to the pharmacological therapeutic regimen (94.75%). As expected, in patients with low adherence, a higher number of prescribed drugs were noted compared to the overall average of patients.
Conclusions. In an outpatient clinic, dedicated to cardiovascular prevention, in patients on long-term follow-up, excellent adherence to pharmacological lipid-lowering therapy was observed. As expected, the few patients with poor adherence had a higher total number of prescribed drugs compared to the sample average in the study.

A564: L'IMPORTANZA DELLA DIAGNOSI DI FH: UN CASO CLINICO PARADIGMATICO

Giulia Guidotti (a), Viola Liberati (a), Martina Berteotti (a), Elena Lotti (a), Betti Giusti (a), Elena Sticchi (a), Ada Kura (a), Francesco Alfano (a), Andrea Sorrentino (a), Rossella Marcucci (a)
(a) DIPARTIMENTO DI MEDICINA SPERIMENTALE E CLINICA, UNIVERSITÀ DEGLI STUDI DI FIRENZE, MALATTIE ATEROTROMBOTICHE, AOU CAREGGI

Descrizione clinica e trattamento. Il paziente M.A., di anni 60, giungeva a visita presso il nostro ambulatorio a Gennaio 2020, al fine di garantire l'ottimizzazione della terapia ipolipemizzante (LLT) ed un adeguato follow up. A Dicembre 2019 il paziente veniva ricoverato presso AOU Careggi con la diagnosi di infarto miocardico acuto NSTEMI, con successiva dimostrazione di coronaropatia trivasale critica sottoposta a PCI e stenting medicato su Cx e MO1. Il paziente riferiva pregressa esposizione tabagica, familiarità per malattia cardiovascolare in giovane età, ipertensione arteriosa ed ipercolesterolemia in terapia con rosuvastatina/ezetimibe 20/10 mg. Nonostante la buona aderenza alla LLT, al momento del ricovero il paziente presentava un valore di colesterolo LDL (LDL-C) di 138 mg/dl, ben lontano dal target previsto per classe di rischio (<55 mg/dl). Gli elevati livelli di colesterolo LDL, associati ad una anamnesi familiare positiva per malattia coronarica in età precoce (Dutch Lipid Clinic Network Score [DLCN] pari a 7, diagnosi probabile), ponevano il sospetto diagnostico di ipercolestrolemia familiare eterozigote (HeFH). Sospetto confermato dal successivo studio genetico, con dimostrazione di una mutazione in eterozigosi per il recettore delle LDL. Inoltre, considerato il mancato raggiungimento del target, nonostante la massima LTT tollerata, abbiamo ottimizzato la terapia ipolipemizzante del paziente, prescrivendo un anticorpo monoclonale inibitore della PCSK9, Evolocumab. Dallo screening familiare a cascata è emersa nel figlio del paziente, di 29 anni, una diagnosi certa di HeFH, con punteggio 8 al DLCN. È stata in primo luogo iniziata una terapia di associazione con rosuvastatina/ezetimibe 20/10 mg, che ha permesso una riduzione del 63% ma non il raggiungimento del target (<70 mg/dl); per cui abbiamo prescritto anche al figlio Evolocumab. L'aggiunta di evolocumab alla terapia ipolipemizzante di combinazione ha quindi permesso il raggiungimento del target di LDL-C sia nel padre (<55 mg/dl) che nel figlio (<70 mg/dl).
Discussione. Nel corso degli anni i livelli target di LDL-C si sono ridotti progressivamente, ciononostante, nella pratica clinica i pazienti rimangono spesso sotto-trattati, con raggiungimento subottimale del target. Nella HeFH, condizione comune ma ancora oggi fortemente sottotrattata, la gestione diventa ancora più complessa. In questa particolare categoria una monoterapia con statine permette solo ad una piccola percentuale di pazienti di raggiungere il target terapeutico. Questo trova conferma nel caso clinico descritto, in cui, solamente una terapia combinata con diversi farmaci ipolipemizzanti che agiscono con meccanismi diversi ma complementari, è riuscita a portare il paziente al target preposto. Una corretta gestione del nostro caso indice ha inoltre permesso di individuare e trattare precocemente il figlio del paziente. L'importanza di questo approccio è data dal fatto che nella FH la prevenzione primaria risulta più efficace della prevenzione secondaria (riduzione del 48% della mortalità per CHD vs il 25%).
Conclusione. La principale sfida che ci troviamo ad affrontare è la diffusione della consapevolezza, tra pazienti e tra il personale sanitario, dell'importanza di una diagnosi precoce e di un trattamento tempestivo e aggressivo delle ipercolesterolemie familiari, al fine di una gestione terapeutica adeguata del rischio cardiovascolare.

A565: ORDINARIA AMMINISTRAZIONE: SOTTOSTIMA DEL RISCHIO CARDIOVASCOLARE IN UN PAZIENTE AD ALTO RISCHIO

Raffaele Jiritano (a), Luca Salerno (a), Gabriele Arena (a), Ennio Abramo (a), Ciro Indolfi (c), Francesco Andreozzi (a)
(a) UNIVERSITÀ DEGLI STUDI MAGNA GRAECIA-DIPARTIMENTO DI MEDICINA E CHIRURGIA-U.O.C. MEDICINA INTERNA; (b) UNIVERSITÀ DEGLI STUDI MAGNA GRAECIA-DIPARTIMENTO DI MEDICINA E CHIRURGIA-U.O.C. MEDICINA INTERNA; (c) UNIVERSITÀ DEGLI STUDI MAGNA GRAECIA-DIPARTIMENTO DI MEDICINA E CHIRURGIA-U.O. CARDIOLOGIA

Descrizione. A.F. di anni 55 giunge alla nostra osservazione per quello che definisce un controllo routinario per modico cardiopalmo ed una minima ectasia della radice aortica (3.4 cm a 3.9 cm dal piano aortico). Riferisce uno stile di vita da sportivo, con attività aerobica praticata a livelli semiagonistici, con anamnesi cardiologica silente, rappresentata da una diagnosi di DMT2 con buon compenso glicemico (al punto da sospendere iniezioni di Dulaglutide settimanale) e dalle valutazioni per idoneità alla pratica amatoriale effettuate dal medico di medicina generale, tutte superate. Al tracciato ECG di base da noi effettuato risulta invece un quadro di scarsa progressione dell'onda R diffusamente nelle precordiali caratterizzato da QS profondi e non modificabili in V1-V3. Esegue ecocardiogramma in centro privato evidenziante non meglio definita "ipocinesia del SIV basale e della parete inferiore". Stante l'alto rischio cardiovascolare del paziente si provvede a R.O. quanto prima. Agli esami ematochimici si evidenzia un quadro di ipercolesterolemia (150 mg/dL) per cui non eseguiva terapia alcuna, e un peggioramento del controllo glicemico (HbA1c 7%). Ad eco di controllo veniva confermata l'ipocinesia del SIV mediobasale e della parete laterale basale in un quadro di cardiopatia ipertensiva. Si optava per esecuzione di Coro-TC considerata assodata l'alterazione della cinetica segmentaria: si evidenziava un quadro di ateromasia particolarmente severa con placca soft su TC estesa sull'ostio del RIVA, condizionante stenosi suboccludente ostiale del vaso, inoltre gravato da ulteriori stenosi di cui una critica al tratto medio. Su circonflessa severa stenosi ostiale da placca soft in addizione a stenosi del 50% su tratto medio. Su coronaria dx placca a binario al tratto prossimale del 60%. Eseguita coronarografia a stretto giro veniva confermato il quadro di imaging tomografico con rilevazione di flusso TIMI I su IVA. Veniva richiesta consulenza cardiochirurgica per coronaropatia trivasale con indicazione ad intervento di rivascolarizzazione chirurgica eseguita nel 10/22 con AMI sx>IVA, AMI dx>MO. Il paziente tornava a controlli nei mesi seguenti con buon performace status, assenza di sintomatologia anginosa o cardiopalmo, e recupero della capacità di sforzo. Veniva altresì riscontrato un miglioramento dei parametri biochimici dopo avvio di terapia più aggressiva per dislipidemia e DMT2.
Conclusioni. Un paziente diabetico scarsamente compliante alla terapia ipoglicemizzante è stato per anni soltanto valutato sotto il profilo metabolico, con un inquadramento cardiologico ridotto a mera formalità burocratica eseguita da non specialista. Un approccio olistico al paziente avrebbe previsto innanzitutto una gestione più aggressiva della terapia diabetologica ed una educazione dell'assistito all'importanza della stessa e degli effetti della scarsa aderenza alla stessa, in quanto il paziente appariva del tutto inconsapevole del proprio effettivo stato di salute. In aggiunta a quanto asserito, si ribadisce l'importanza della collaborazione tra cardiologo/internista/diabetologo nell'inquadramento del soggetto diabetico, poiché se il paziente fosse stato da subito inviato all'attenzione dello specialista in malattie cardiovascolari non solo potenzialmente sarebbero stati identificabili i segni della coronaropatia prima che questa progredisse ad un livello di severità tale da richiedere chirurgia, ma almeno sarebbe stata avviata una terapia ipolipemizzante aggressiva ed in linea con le LG ESC ovviando ad una riscontrata tendenza del diabetologo alla cautela e al ricorso nella gestione del diabetico alla dietoterapia ed esercizio fisico, in questo caso insufficienti.

A566: THE NEW PCSK9 INHIBITOR INCLISIRAN: AN EXCEPTIONAL REDUCTION IN LDL CHOLESTEROL FROM THE FIRST PATIENTS OF OUR CENTER

Alessandro Maloberti (a, b), Anna Merlo (a), Paolo Ossola (a), Andrea Caccia (a), Andrea Busti (a), Ilaria Garofani (a), Saverio Fabbri (a), Michele Senni (a, c), Cristina Giannattasio (a, b)
(a) SCHOOL OF MEDICINE AND SURGERY, MILANO-BICOCCA UNIVERSITY, MILAN ITALY; (b) CARDIOLOGY IV, ASST GOM NIGUARDA, MILAN ITALY; (c) CARDIOVASCULAR DEPARTMENT, CARDIOLOGY UNIT, ASST PAPA GIOVANNI XXIII, BERGAMO ITALY

Background. Dyslipidemia is one of the most prominent risk factors in coronary artery disease. With the new strict target of Low Density Lipoprotein (LDL) cholesterol in secondary prevention in some patients oral medication may not be sufficient. Inclisiran is a small interfiring RNA that inhibits the hepatic PCSK-9 synthesis inducing a reduction in low-density lipoprotein levels up to 50%. Conveniently, it only requires one administration every six months.
Case description. A 53-year-old man, with no previous cardiologic history, presented to our emergency department reporting acute chest pain and left arm paresthesia developed after an emotional stress. Electrocardiogram was normal with a slightly and stable increased of high sensitivity troponin T levels (18 ng/l). The patient had the following cardiovascular risk factors: type 2 diabetes mellitus, dyslipidemia, obstructive sleep apnea syndrome, obesity (body mass index 30), sedentary lifestyle. Taking into consideration his clinical presentation and his cardiovascular risk, a coronary computer tomography was performed showing severe stenosis in Left Anterior Descending (LAD) and right coronary arteries. The subsequent coronary angiography confirms the severe stenosis in the proxymal LAD and the mild stenosis (30%) in the ri-

ght coronary artery. The LAD was treated with a drug eluting stent. At the time of the event the patient was already on therapy with rosuvastatina/ezetimibe 10/10 mg that we increased to a dosage of 20/10 mg. At the first medical examination after the hospitalization, his blood tests showed uncontrolled LDL cholesterol (70 mg/dl). We therefore decided to try lowering his cholesterol levels with addition of inclisiran. After 3 months of inclisiran therapy, his blood test showed a surprisingly decrease in cholesterol levels (total cholesterol 78 mg/dl and LDL 11 mg/dl) reaching the desirable target.
Conclusions. Inclisiran is a valid therapeutic strategy for reaching the desiderable cholesterol target in patient at high cardiovascular risk. In our first patients inclisiran, added to statin and ezetimibe therapy, successfully lowered LDL to the desirable target. Surprinsigly, it lowered LDL up to 85%, much more than expected. Further studies will be needed to identify which patients may be super responders to Inclisiran.

A567: NON-RESPONSIVENESS TO PCSK9I IN A PATIENT WITH STATIN AND EZETIMIBE INTOLERANCE AND A DIAGNOSIS OF HEFH

Stefano Romei (a), Ciro Formisano (a), Michele Bellino (a, b), Michele Tedeschi (a), Debora D´elia (a), Martina La Manna (a), Rossana Palumbo (a), Angelo Silverio (a, b), Carmine Vecchione (a, b), Gennaro Galasso (a, b)
(a) UNIVERSITÀ DEGLI STUDI DI SALERNO; (b) AOU SAN GIOVANNI DI DIO E RUGGI D'ARAGONA

We report the case of a 29-year-old female caucasian patient, smoker, family history of CAD, statins and ezetimibe intolerance (onset of myalgias after intake) with a genetic diagnosis of heterozygous familial hypercholesterolemia (HeFH). She came to the attention of our dyslipidaemia outpatient clinic due to inefficacy of current therapy with evolocumab. The diagnosis of HeFH had been made in 2022 by genetic testing. The results obtained from the blood sample had confirmed the clinical suspicion: the patient was heterozygous for the pathogenic variant c. 1646G>A - p.(Gly549Asp) located in exon 11 of the LDLR gene, which is known in the literature to cause HeFH. At the time of the visit, already on evolocumab therapy for 6 months, she had a non-response to PCSK9i documented by the persistence of high LDL-C values. Not reaching the target for her risk class, derived from the most recent ESC LG on the management of dyslipidaemia (LDL-C <70 mg/dl), after careful evaluation of the adequate subcutaneous administration of the monoclonal antibody, and having ruled out other possible causes of non-response such as renal and hepatic dysfunction or concomitant use of other drugs, the patient was classified as non-responsive to PCSK9i. For this reason, it was decided to start therapy with inclisiran and bempedoic acid, and to perform follow-up at 4 weeks. At the subsequent laboratory evaluation an initial response to the prescribed therapy was documented and the decision to continue the dual therapy with re-evaluation after a further 4-6 weeks was made. Intolerance to statins has a prevalence of 9.1%, while intolerance to ezetimibe is almost unknown, with very few cases reported in the literature. Equally rare and not well delineated is non-responsiveness to soluble PCSK9 monoclonal antibodies, documented only by a few case reports. Our case shows the treatment ineffectiveness of three platforms for modulation of LDL-cholesterol metabolism, but also the possibility of effectively undertaking both inhibition of cholesterol synthesis and inhibition of soluble PCSK9 by pharmacological modulation aimed at new therapeutic targets.

EPIDEMIOLOGIA E POLITICA SANITARIA

A568: CARDIOVASCULAR EVENTS AFTER EXACERBATIONS OF CHRONIC OBSTRUCTIVE PULMONARY DISEASE: RESULTS FROM THE EXACOS-CV STUDY IN ITALY

Silvia Calabria (a), Giulia Ronconi (a), Letizia Dondi (a), Leonardo Dondi (a), Irene Dell´anno (a), Clementine Nordon (b), Kirsty Rhodes (b), Paola Rogliani (c), Nello Martini (a), Aldo Pietro Maggioni (a, d)
(a) FONDAZIONE RICERCA E SALUTE (RES) - RESEARCH AND HEALTH FOUNDATION, ROMA, ITALY; (b) BIOPHARMACEUTICALS MEDICAL, ASTRAZENECA, CAMBRIDGE, UK; (c) UNIT OF RESPIRATORY MEDICINE, DEPARTMENT OF EXPERIMENTAL MEDICINE, UNIVERSITY OF ROME "TOR VERGATA", ROME, ITALY; (d) ANMCO RESEARCH CENTER HEART CARE FOUNDATION, FIRENZE, ITALY

Introduction. Acute exacerbations of chronic obstructive pulmonary disease (AECOPD) can increase the risk of severe cardiovascular (CV) events.
Objective. Assess the incidence rate (IR) of CV events and their risk associated with different time periods after a moderate or severe AECOPD.
Methods. From 01/01/2015 to 12/31/2018, COPD patients aged ≥45 with data available since 2013 were selected (index date) in the Fondazione Ricerca e Salute's database. Demographics and comorbidities (at index date and within a 2-year look-back period) were described. Within different periods after a moderate or severe AECOPD (1-7, 8-14, 15-30, 31-180, 181-365 days), first severe non-fatal CV events and death (IR) and their association (hazard ratio – HR, through Cox proportional hazard model) with post-AECOPD time periods were assessed.
Results. Among 216,864 COPD patients, 69,620 (32%) had ≥1 AECOPD during follow-up. A high proportion were male (>55%), aged on average>73 and had CV, metabolic and psychiatric comorbidities. At least one CV event occurred during follow-up in 46,214 (21%) COPD patients. Of 10,269 patients (IR: 15.8/100 person-years; 95%CI 15.5-16.1) experiencing a CV event within 365 days post-AECOPD, the IR was 252.1/100 person-years within the first 7 days and decreased to 16.3 person-years at 8-14 days and 5.6 at 181-365 days. Deaths from any cause occurred in 55,470 patients, of which 4,661 were in-hospital CV-related. Based on the Cox proportional model analysis, the risk of severe CV events significantly increased within the first week after the AECOPD (HR: 34.3, 95%CI: 33.1-35.6) and remained elevated up to 12 months (HR: 1.1, 95%CI: 1.02-1.13), compared to unexposed periods.
Conclusions. COPD patients experience high risk of severe CV events after AECOPD, which may be prevented by early interventions.

A569: PREVALENCE, EPIDEMIOLOGY AND RISK FACTORS OF HEALTHCARE ASSOCIATED INFECTIONS IN CARDIAC INTENSIVE CARE UNIT

Margherita Casiraghi (a), Federica Saitta (a), Gian Marco Dacquino (a), Andrea Imporzani (a), Chiara Lauri (a), Caterina Facciolo (b), Alberto Limido (b), Roberto De Ponti (a)
(a) UNIVERSITÀ DEGLI STUDI DELL'INSUBRIA; (b) OSPEDALE DI CIRCOLO E FONDAZIONE MACCHI, VARESE - ASST SETTE LAGHI

Background. Infections represent an extremely common complication in intensive care unit patients, causing prolonged hospitalization and increased mortality. In the scientific literature, seldom studies described the epidemiology of infections in Cardiac Intensive Care Unit (CICU) and the main risk factors for their occurrence.
Methods. A monocentric retrospective study has been conducted evaluating the prevalence of infections, their main pathogenic agents and the main risk factors associated with their occurrence in patients admitted in the CICU at the Hospital of Varese (Lombardia, Italy) between December 1st, 2021 and December 31st, 2022. Patients whit a hospitalization in the previous 7 days or patients admitted to the CICU after being in another unit for more than 48 hours were excluded.
Results. In the selected period, 520 patients were enrolled, with a mean age of 70 ± 13 years and a male predominance (363, 70%). The average length of stay was of 4 ± 5 days. An infection occurred in 135 patients (26%): 39% were sepsis, 38% were urinary tract infections (UTI), 29% were pneumonia, 4% were infections related to the presence of a central venous catheter (CVC). A total of 409 cultural exams were performed, 116 (28%) of them tested positive: 59 (51%) for Gram-negative bacteria, 43 (37%) for Gram-positive bacteria and 11 (9%) for fungi. Piperacillin/Tazobactam was the most frequently prescribed antibiotic (35%). Mortality resulted to be higher in infected patients (7/135, 5% vs. 4/385, 1%, p 0.004). In the table below, a univariate and multivariate analysis of the factors most frequently associated with the development of infections in the CICU patients is shown.
Conclusions. Infections are a frequent complication in CICU and they are an important cause of increased morbidity, mortality and hospitalization costs. Sepsis and urinary tract infections were the most common types of healthcare associated infection, mainly caused by Gram-negative bacteria. In our study, a longer stay in CICU and the presence of a urinary catheter or a CVC were independent predictors of the occurrence of infection. Action should be taken to improve evidence-based preventive practices and to reduce as much as possible this significant complication.

	Unadjusted		Adjusted	
Variables	OR [95% CI]	p value	OR [95% CI]	p value
Days in CICU	1.31 [1.22-1.40]	**< 0.001**	1.14 [1.07-1.23]	**0.002**
Left ventricular ejection fraction	0.95 [0.93-0.96]	**< 0.001**	0.98 [0.97-1.00]	1.128
Oncologic or hematologic disease	1.33 [0.83-2.11]	0.322	1.29 [0.72-2.28]	0.471
Immunosuppressive therapy	1.37 [0.67-2.84]	0.471	1.35 [0.55-3.31]	0.585
Chronic kidney disease	2.11 [1.48-3.01]	**0.001**	1.07 [0.68-1.70]	0.800
Urinary catheter	8.94 [5.96-13.4]	**< 0.001**	3.80 [2.29-6.32]	**< 0.001**
Central venous catheter	9.33 [6.31-13.8]	**< 0.001**	2.03 [1.14-3.60]	**0.043**
Diabetes mellitus	1.27 [0.89-1.80]	0.272	0.81 [0.51-1.29]	0.459
Chronic obstructive pulmonary disease	2.39 [1.50-3.79]	**0.002**	1.68 [0.93-3.03]	0.149
Non-invasive ventilation	7.15 [4.37-11.69]	**< 0.001**	1.47 [0.80-2.71]	0.302
Mechanical ventilation	6.89 [4.21-11.3]	**< 0.001**	1.65 [0.87-3.11]	0.199

A570: DO SOCIO-ECONOMIC AND HEALTH ORGANIZATION FACTORS INFLUENCE SEX DIFFERENCES IN RE-HOSPITALIZATION OF HEART FAILURE PATIENTS? A REAL-WORLD EXPERIENCE

Federico Fortuni (a, b), Giulio Spinucci (a), Paolo Biagioli (a), Marzia Maltempi (a), Filippo Massei (a), Federico Gobbi (a), Benedetta Casini (a), Sara Morroni (a), Erberto Carluccio (a), Giuseppe Ambrosio (a)
(a) CARDIOLOGY AND CARDIOVASCULAR PATHOPHYSIOLOGY, SANTA MARIA DELLA MISERICORDIA HOSPITAL, UNIVERSITY OF PERUGIA, PERUGIA, ITALY.; (b) SC CARDIOLOGIA E UTIC, OSPEDALE SAN GIOVANNI BATTISTA, FOLIGNO (PG), ITALY.

Background. Several sex-specific differences regarding phenotype prevalence, clinical characteristics, risk factors, etiology, and therapeutic response have been described in heart failure (HF) patients. However, differences in prognosis between men and women with HF in a real-world setting are under-investigated. In particular, the possible contributions of socio-economic and health organization factors have not been previously explored.

Methods. We analyzed the administrative database of all consecutive patients discharged with a primary diagnosis of HF from 2018 to 2020 in the Umbria region. Cox regression analyses were performed to assess independent predictors of HF re-hospitalization during the follow-up.
Results. A total of 6411 patients were included, 3175 men (49.5%) and 3236 (50.5%) women. Compared with men, women were older (84 [79-89] vs 80 [72-86] years), more likely to live alone, had a lower level of education, a more disadvantaged socioeconomic status, and were less likely to be hospitalized in a cardiology ward (all P values ≤0.01). During a median follow-up of 10 months (IQR, 3-21), 1497 patients (23%) were re-hospitalized due to HF. In the entire cohort, the following characteristics were associated with higher risk of HF re-hospitalization: age, level of care of the discharging hospital (primary- versus secondary- or tertiary-level hospital), living in a rural versus urban area, length of hospital stay during the index event, and male gender (unadjusted HR 1.12; 95% CI 1.01-1.23; P=0.035; Figure 1A). By multivariable analysis, after correcting for potential confounders, male gender remained independently associated with an increased risk of HF re-hospitalization (adjusted HR 1.18; 95% CI 1.06-1.31; P=0.002; Figure 1B), together with age and length of hospital stay during the index event.
Conclusions. Age and length of hospital stay during the index event are the main drivers of re-hospitalization in HF patients, whereas socioeconomic status and level of education and care did not contribute. However, despite being younger and having a shorter length of hospital stay during the index event, men with HF are at higher risk of HF re-hospitalization compared to women.

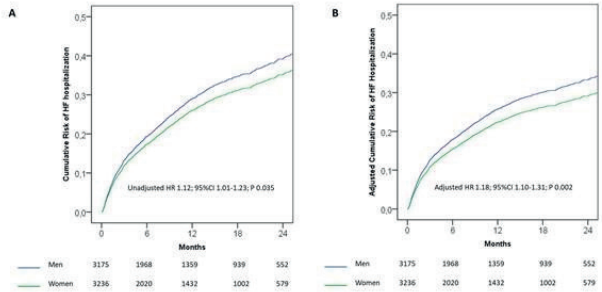

A571: ORAL ANTICOAUGULATION MONITORING NURSING SERVICE ORGANIZATION: FIVE YEARS EXPERIENCE IN A HIGH-VOLUME CENTER

Isabella Bertoldo (b), Gentian Denas (c), Chiara Colledan (b), Francesco Antonini Canterin (b), Leopoldo Pagliani (a)
(a) I.O.V.- ISTITUTO ONCOLOGICO VENETO I.R.C.C.S.; (b) OSPEDALE DI ALTA SPECIALIZZAZIONE DI MOTTA DI LIVENZA; (c) UNIVERSITÀ DI PADOVA

Background. Oral anticoagulant therapy (OAT) is the treatment of choice in thromboembolic prevention in patients with AF. Starting from the indications of the regional laws that outline the Diagnostic Therapeutic Path, the need arose in our territory to create a divisional clinic dedicated to the diagnosis and treatment of AF. The task of the team (Cardiologists, Nurses, GPs, secretariat) was to monitor the number of patients being treated with DOACs through the treatment plan (PT) of AIFA (Italian Medicines Agency); verify adherence to regional guidelines, analyze adherence to therapy; prepare a protocol for the management of complications and emergencies; ensure that the departments and services authorized to prescribe DOACs are taken care of, in close collaboration with GPs who have become active prescribers since June 2020 and are also involved in patient follow-up; taking care of the training of the prescribers themselves and the education of patients through hospital meetings dedicated to guided counseling and, finally, monitoring the pharmaceutical expenditure of the NAO on the total prescriptions of the Territorial Health Unit (ULSS) of competence in compliance with the established regional indicators.
Methods. In our hospital, the pilot project started in 2017 (7632 patients currently in FU). In the three-year period 2017-19, an average of 700 therapeutic plans were collected for renewal/first prescription per year (58.3 plans/month) to be monitored in subsequent years. In the three-year period 2020-2022, which saw the difficulty of organizing activities due to the pandemic emergency, 903, 945 and 1090 PTs were analyzed respectively with an average of 89 plans/month, maintaining almost 75% face-to-face facial visits versus telemedical contacts established in the pandemic context.
Results and Conclusions. As emerges from the data, therefore, there is a strong need to organize more and more diagnostic and therapeutic assistance pathways. Despite the emergency period and despite a framework in which local medicine could have assisted the clinical and bureaucratic effort, no reduction in the care burden has occurred and indeed the constant increase in patients intercepted makes the complexity and difficulty of a correct classification understandable clinical and managerial support of the patient with the need for OAT.

A572: CHRONIC CARE MODEL: PROACTIVE MEDICINE TO PREVENT CARDIOVASCULAR DISEASES. THE APULIAN POPULATION AGED BETWEEN 65 AND 75 YEARS

Roberta Panarelli (a), Cosima Caputo (a), Giovanna Cavino (a), Scarpa Antonio (a), Lucia Giordano (a), Pasquale Palmiero (a)
(a) MEDICAL SCHOOL, UNIVERSITY OF BARI, BRINDISI, ITALY

The Chronic Care Model (CCM) was born by MacColl Institute for Healthcare Innovation, and developed through a National Program for "Improving Chronic Illness Care". It accurately identifies the fundamental variables that make a systemic approach to chronic diseases possible; moving all the levers organizational and operational aspects to promote an appropriate approach on the part of operators. It is based on: community resources, healthcare organizations, self-care support for lifestyles and pharmacological therapy; team organization with the definition of tasks, guidelines respect, and an informative system to give population-based assistance, with pathology registers; all interconnected. Expected results are a patient aware, informed, and satisfied who interacts with a trained and proactive team, for high-quality primary care and improvements in the health of the population. Chronic patients need a very high level of support within their community to best maintain their health and function levels how much as long as possible. The current Italian system of primary care presents a series of criticisms that prevent, an effective response to this need, both at a clinical management level for little attention to prevention, the little habit of planning treatments and entrusting them to only medical and at the level of follow-up, both in terms of patient empowerment because it assists patients affected by acute and chronic diseases by the same care pathway. Our aim is to detect if the Apulian population knows and puts into practice the correct lifestyles to prevent chronic diseases, investigating habits in a sample population aged between 65 years, when the individual becomes old, according to WHO guidelines, and 75 years, the age in which the Italian Society of Geriatric proposes to delay the beginning of old age. The investigation takes place through a questionnaire of 36 questions, that were selected from the following validated questionnaires: Istat - National Statistical System "Multipurpose statistical survey on households Aspects of daily life"; PASSI – Progress of Health Authorities in Italy "PASSI 2014 Questionnaire"; ISS – Smoking, Alcohol and Drugs Observatory – OSSFAD "Lifestyle evaluation questionnaire"; National Research Council - Institute of Clinical Physiology "ESPAD-Italy 2014 - The European School Survey Project on Alcohol and Other Drugs". The tool, completely anonymous and in which sensitive data are not processed, consists of 36 questions formulated with self-anchoring, dichotomous, and multiple-choice answers. The questionnaire is divided into sections that deal with different thematic areas useful for detecting fundamental information related to the daily life and habits of individuals. The main information contents of the tool are General Data Section by age, educational qualification, profession, weight, and height; Section 1 - Movement and physical activity; Section 2 - Eating styles; Section 3 - Beverage consumption; Section 4 - Tobacco consumption; Section5 - Use of psychotropic substances; Section 6 – Health, detecting the health condition of the person interviewed, what chronic diseases they may be suffering from and whether they need advice on healthy lifestyles. The results will be communicated during the 84° Italian Society of Cardiology National Congress.

GENETICA E BIOLOGIA MOLECOLARE

A573: A COMBINED CLINICAL, MOLECULAR AND MUSCLE BIOPSY APPROACH TO UNVEIL PREVALENCE AND CLINICAL FEATURES OF RARE NEUROMUSCULAR AND MITOCHONDRIAL DISEASES IN PATIENTS WITH CARDIOMYOPATHIES

Ippolita Altobelli (a), Michele Lioncino (a), Emanuele Monda (a), Martina Caiazza (a), Vincenzo Simonelli (b), Claudia Nesti (c), Alfredo Mauriello (a), Alberta Budillon (d), Alessandro Di Santo (e), Giorgia Bruno (j), Antonio Varone (j), Vincenzo Nigro (f), Filippo Maria Santorelli (c), Giuseppe Pacileo (g), Maria Giovanna Russo (h), Giulia Frisso (i), Simone Sampaolo (d), Giuseppe Limongelli (a)
(a) INHERITED AND RARE CARDIOVASCULAR DISEASES UNIT, DEPARTMENT OF TRANSLATIONAL MEDICAL SCIENCES, UNIVERSITY OF CAMPANIA LUIGI VANVITELLI, AORN DEI COLLI, MONALDI HOSPITAL, NAPLES, ITALY ERN GUARD-HEART; (b) NEUROLOGY UNIT, AORN DEI COLLI, MONALDI HOSPITAL, NAPLES, ITALY; (c) MOLECULAR MEDICINE, IRCCS STELLA MARIS FOUNDATION, PISA, ITALY; (d) DEPARTMENT OF ADVANCED MEDICAL AND SURGICAL SCIENCES, END DIVISION OF NEUROLOGY, CENTER FOR RARE DISEASES AND INTERUNIVERSITY CENTER FOR RESEARCH IN NEUROSCIENCES, UNIVERSITY OF CAMPANIA LUIGI VANVITELLI, NAPLES, ITALY; (e) NEUROMUSCULAR OMNICENTRE (NEMO), SERENA ONLUS, A.O.R.N. DEI COLLI, "V. MONALDI", NAPLES; (f) DEPARTMENT OF PRECISION MEDICINE, UNIVERSITY OF CAMPANIA "LUIGI VANVITELLI", NAPLES, ITALY; (g) HEART FAILURE UNIT, DEPARTMENT OF CARDIOLOGY, AORN DEI COLLI-MONALDI HOSPITAL, NAPLES, ITALY; (h) PAEDIATRIC CARDIOLOGY UNIT, UNIVERSITY OF CAMPANIA LUIGI VANVITELLI, AORN DEI COLLI, MONALDI HOSPITAL; (i) DEPARTMENT OF MOLECULAR MEDICINE AND MEDICAL BIOTECHNOLOGY, UNIVERSITY OF NAPLES "FEDERICO II", NAPLES, ITALY; (j) DEPARTMENT OF NEUROSCIENCES, PEDIATRIC NEUROLOGY UNIT, SANTOBONO-PAUSILIPON CHILDREN'S HOSPITAL, NAPLES, ITALY

Background. The study aims to evaluate the role of genetic testing, in addition to a comprehensive cardiological and neuromuscular evaluation to identify a neuromuscular or mitochondrial aetiology in patients with cardiomyopathies (CMPs).
Methods. Consecutive CMP patients with an increase of serum creatine phosphokinase (CK) levels underwent a comprehensive neuromuscular evaluation, including the study of the extent of muscle strength, needle electromyography, and if required (high suspicion of neuromuscular disease, hsNMD), muscle biopsy (MB) and genetic testing.
Results. Among 395 CMPs patients who fulfilled inclusion criteria, 24 (6%) showed serum CK elevation: 19 (79%) with dilated cardiomyopathy: 5 (20%) with hypertrophic cardiomyopathy. Among the 24 selected patients, 11 (45%) showed a hsNMD pattern and underwent MB and genetic testing. MB showed a myopathic pattern in all the examined patients (in combination with an altered oxidative metabolism in 4, other metabolic features in 4, the presence of diffuse mini-cores in 2, and non-specific characteristics in a single case). Genetic testing allowed a definite diagnosis in 7 (63%): 2 patients showed a disease-causing mutation in MYH7 (MYH7-related cardiomyopathy): 2 patients harboured biallelic variants ACAD9 gene: and single cases had variants in MT-TL1 (the so called "MELAS" mutation) DES (desminopathy) and MTO1.
Conclusions. A combined clinical, molecular and muscle biopsy approach allowed a definitive diagnosis in 63% of hsNMD patients, suggesting the additional value of multimodal approaches in otherwise undefined CMP. The addition of genetic testing to a comprehensive neuromuscular evaluation allowed to identify aetiology in 29% of CMP patients with increased serum CK levels.

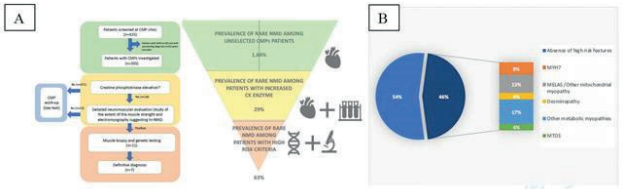

Figure 1 (A) Study flow chart (B) Clinical phenotypes of the study patients with increased serum CK. Among the selected patients, 46% showed a *high-risk NMD* pattern. These patients underwent further examinations, comprehensive of genetic test.

A574: ROLE OF ATAXIA TELANGIECTASIA MUTATED (ATM) IN GLUCOSE AND LIPID METABOLISM IN THE HEART

Roberta Paolillo (a), Stefania D'Apice (a), M. Caterino (b, c), A. Pezone (e), Danila Ioele (a), Pina Polese (a), Cinzia Perrino (a), Ve. Avvedimento (b), Giovanni Esposito (a), M. Ruoppolo (b, c), A. Lombardi (e), N. Boccella (a)
(a) DIPARTIMENTO DI SCIENZE BIOMEDICHE AVANZATE UNIVERSITÀ DEGLI STUDI DI NAPOLI FEDERICO II; (b) DIPARTIMENTO DI MEDICINA MOLECOLARE E BIOTECNOLOGIE MEDICHE UNIVERSITÀ DEGLI STUDI DI NAPOLI FEDERICO II; (c) CEINGE BIOTECNOLOGIE AVANZATE SCARL, NAPOLI ITALIA; (d) ISTITUTO DI BIOCHIMICA E BIOLOGIA CELLULARE (IBBC), NATIONAL RESEARCH COUNCIL NAPOLI ITALIA; (e) DIPARTIMENTO DI BIOLOGIA UNIVERSITÀ DEGLI STUDI DI NAPOLI FEDERICO II

Backround. Cardiomyocytes cannot repair DNA lesions with DNA replication and rely for their survival on efficient sensors and effectors that orchestrate DNA damage response (DDR). Ataxia Telangiectasia Mutated (ATM) protein kinase is the most important sensor of oxidative stress and DNA damage response (DDR). There are conflicting opinions in the literature regarding role of ATM in the heart. We hypothesise that ATM might controls and regulates the heart's energy metabolism and remodelling.
Methods. We analyzed the effects of ATM inactivation on cardiomyocyte hypertrophy, cardiac function, DDR and metabolism. We used ATM-mutated mice ($Atm^{-/-}$) and their respective wild-type littermates ($Atm^{+/+}$) under sham conditions or after pressure overload by transverse aortic constriction (TAC).
Results. Under sham conditions, $Atm^{-/-}$ mice showed hypertrophy of cardiomyocytes, re-expression of fetal genes and a heart-specific metabolic signature characterized by altered glycolysis favouring a significant accumulation of pyruvate, branched-chain amino acids and short- and medium-chain acyl-carnitines. The levels of the first and second glycolytic enzymes, hexokinase-2 (HK2) and phosphofructokinase (PFK) were elevated before or after TAC in $Atm^{-/-}$ mice (FIG. 1 A, B). These data show that ATM inactivation results in the blockade and imbalance of glucose oxidation, presumably caused by intracellular glucose reduction. This implies an accumulation of pyruvate in the cytosol due to negative regulation of mitochondrial pyruvate transporters and the enzymes that process it (FIG. 1C). Because of the metabolic blockade of pyruvate, fatty acid oxidation was inefficient and led to acyl-carnitine accumulation and insulin resistance (FIG. 1 D). These metabolic alterations were constitutively present in $Atm^{-/-}$ mice, and were amplified by TAC, which rapidly induced heart failure in $Atm^{-/-}$ mice compared to $Atm^{+/+}$.
*p<0.02; **p<0.001; ***p<0.0001; ****p<0.00001

Conclusions. These results prove that ATM regulates the levels of critical enzymes involved in pyruvate metabolism in the heart. The metabolic block due to ATM inactivation accelerates heart failure.

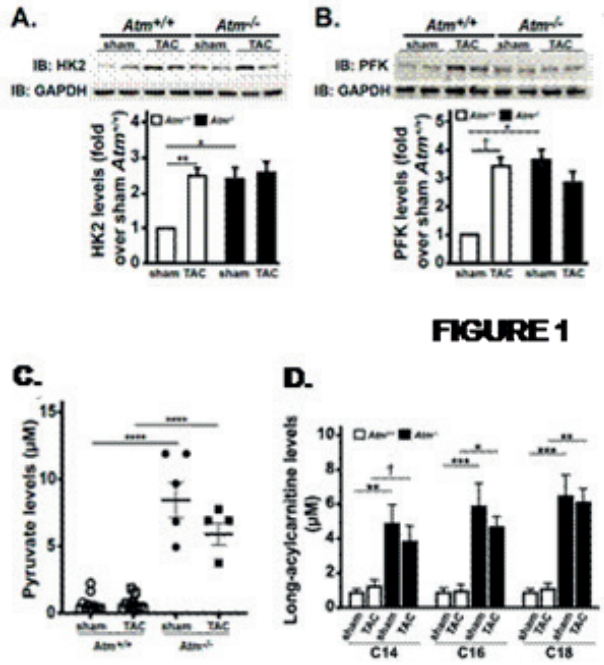

FIGURE 1

A575: ROLE OF MITOCHONDRIAL A KINASE ANCHOR PROTEINS IN GUT-HEART AXIS DURING CARDIOVASCULAR AGING

Danila Ioele (a), Stefania D'Apice (a), Roberta Paolillo (a), Lorena Coretti (c), Adriano Lama (c), Pina Polese (a), Raffaella Iaccarino (a), Tommaso Pentella (a), Giuseppina Mattace Raso (c), Maria Pina Mollica (b), Francesca Lembo (c), Giovanni Esposito (a), Cinzia Perrino (a)
(a) DIPARTIMENTO DI SCIENZE BIOMEDICHE AVANZATE UNIVERSITÀ DEGLI STUDI DI NAPOLI FEDERICO II; (b) DIPARTIMENTO DI BIOLOGIA UNIVERSITÀ DEGLI STUDI DI NAPOLI FEDERICO II; (c) DIPARTIMENTO DI FARMACIA UNIVERSITÀ DEGLI STUDI DI NAPOLI FEDERICO II

Background. A Kinase Anchor Proteins (AKAPs) convey cAMP signals at specific intracellular locations. Mitochondria-targeted AKAPs (mitoAKAPs) regulate multiple mitochondrial functions in cardiomyocytes and endothelial cells. While mitochondrial dysfunction and oxidative stress are involved in ageing and in the regulation of gut barrier function and microbiota composition, the role of mitoAKAPs in gut-heart axis during aging is still poorly understood.
Objective: The purpose of this study was to determine that role of mitoAKAPs in the complex interaction between intestinal permeability, the composition of gut microbiota and cardiac dysfunction during ageing.
Methods. Cardiac function was evaluated by transthoracic echocardiography in 6-month-old (6m), 12-month-old (12m) and 24-month-old (24m) wild-type (wt) mice and in genetically modified mice with partial deletion of the Akap1 gene ($Akap1^{+/-}$). To evaluate gut barrier integrity, we analyzed expression levels of intestinal junction proteins occludin (Ocln) and zonulin (Tjp1) in colonic samples from all groups. To investigate in vivo intestinal permeability, we analyzed circulating levels of FITC dextran D4000 (D) after administration by oral gavage in all experimental groups. Gut microbiota composition was analyzed by Illumina Mi-Seq analysis. Bioinformatic analysis was performed to identify the microbial signature of the groups under investigation. Finally, faecal microbiota transplantation (FMT) was performed for five weeks to test whether modification of gut microbiota composition can affect cardiac function.
Results. Cardiac function was significantly reduced in 12m and 24 m $Akap1^{-/-}$ mice compared to wt (Fig. 1A), as shown by reduced left ventricle% fractional shortening (FS%). This finding was associated to increased intestinal permeability, as indicated by reduced mRNA levels of Ocln and Tjp1, and increased D traslocation across intestinal epitelium into blood in 24m $Akap1^{+/-}$ mice compared to wt (Fig. 1B). Through microbial signature analysis, we identified in 24m $Akap1^{+/-}$ mice a significant increase of Ruminococcus Torques species and a significant decrease in Blautia producta. After FMT, feces from 24m $Akap1^{+/-}$ mice induced cardiac dysfunction in 6m wt mice, while feces from 6m wt mice ameliorated cardiac dysfunction 24m $Akap1^{+/-}$ mice (Fig. 1, C-D).
Conclusions. Partial deletion of the Akap1 gene plays a crucial role in the modulation of cardiac function during ageing, and in gut-heart axis; ma-

nipulation of gut microbiota composition affects gut permeability and cardiac function, suggesting that mitoAKAPs could represent an important diagnostic and therapeutic target for cardiac and gut dysfunction.

Fig. 1

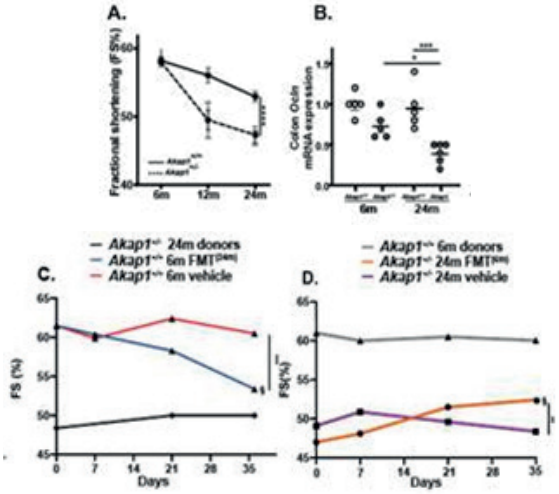

A576: CASQ2 AUGMENTATION MITIGATES CPVT IN A MURINE MODEL: A TRANSLATIONAL STUDY FROM IN SILICO PREDICTION TO IN VIVO PROOF-OF-CONCEPT

Alessandro Trancuccio (a, b, c), Rossana Bongianino (b), Federico Angriman (a, b), Marco De Negri (b), Andrea Mazzanti (a, b, c), Demetrio Santiago (c), Silvia Priori (a, b, c)
(a) DEPARTMENT OF MOLECULAR MEDICINE, UNIVERSITY OF PAVIA; (b) MOLECULAR CARDIOLOGY UNIT, IRCCS ICS S. MAUGERI, PAVIA; (c) CENTRO NACIONAL DE INVESTIGACIONES CARDIOVASCULARES, MADRID

Background. Gain-of-function RYR2 mutations represent the most common cause of Catecholaminergic Polymorphic Ventricular Tachycardia (CPVT). Most of these mutations increase RyR2 sensitivity to sarcoplasmic reticulum (SR) Ca^{2+}, leading to abnormal diastolic SR Ca^{2+} release during adrenergic stimulation.

Purpose. We aimed to explore if augmentation of calsequestrin (CASQ2) to enhance SR Ca^{2+} buffering could counteract this common CPVT mechanism, potentially offering a gene therapy strategy applicable to all RYR2 mutations.

Methods. We used in silico modeling to predict the minimum effective dose of CASQ2 augmentation to suppress adrenergically-triggered SR Ca^{2+} release in CPVT. We adapted the Morotti et al. mouse model to mimic CPVT, introducing mutant RyR2 subunits with increased SR Ca^{2+} sensitivity (Figure, A). We simulated differential efficacy of gene therapy by gradually increasing CASQ2 levels. In vivo, we administered an adeno-associated virus (AAV) carrying the CASQ2 gene to $RyR2^{R4496C/+}$. Two months later, we performed an arrhythmia induction test with adrenergic stimulation and quantified CASQ2 protein levels by Western blot (WB).

Results. Our mathematical model predicted that 1.5-fold increase in CASQ2 levels was efficacious in suppressing spontaneous SR Ca^{2+} release during adrenergic stimulation in CPVT mouse cardiomyocytes (Figure, B). In vivo, AAV-CASQ2 prevented ventricular arrhythmias during adrenergic stimulation in all of cases, as compared to control animals (Figure, C). Remarkably, WB analysis of CASQ2 confirmed that even low levels of increase (<2-fold) were sufficient to prevent the arrhythmogenic manifestations, in line with in silico prediction (Figure, D).

Conclusions. Our translational in silico-to-in vivo approach serves as proof-of-concept that low level CASQ2 overexpression effectively prevents the arrhythmogenic phenotype in a murine model of RYR2-CPVT.

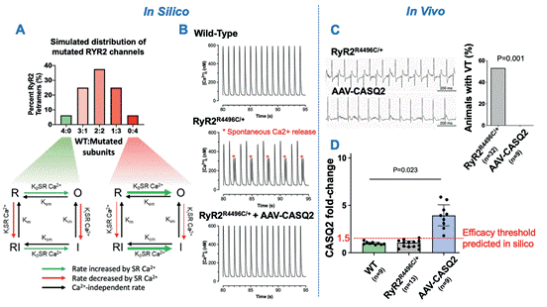

A577: THE ROLE OF OPA1 AND MITOCHONDRIAL DYNAMICS IN THE BIOLOGY OF RESIDENT CARDIAC STROMAL CELLS

Claudia Cozzolino (a), Vittorio Picchio (a), Erica Floris (a), Luca D'Ambrosio (a), Francesca Pagano (b), Giacomo Frati (a), Sebastiano Sciarretta (a), Isotta Chimenti (a)
(a) SAPIENZA UNIVERSITÀ DI ROMA-DIPARTIMENTO DI SCIENZE E BIOTECNOLOGIE MEDICO-CHIRURGICHE; (b) CONSIGLIO NAZIONALE DELLE RICERCHE-ISTITUTO DI BIOCHIMICA E BIOLOGIA CELLULARE

Background. Resident cardiac stromal cells (CSCs) are the main cell type responsible for fibrosis and remodeling in the heart which respond to pathological stimuli by activation and differentiation into myofibroblasts. Mitochondrial morphology and function are crucial for tissue homeostasis which is regulated by the balance between fission and fusion. Optic Atrophy 1 (OPA1) is a conserved dynamin-related GTPase protein, involved in inner mitochondrial membrane fusion and exerting cardioprotective functions. The role of OPA1 in the phenotype and function of CSCs is still unknown.

Purpose. To investigate the mitochondrial dynamics in CSCs, and whether OPA1 modulation can affect the phenotype and paracrine functions of resident CSCs under stress conditions.

Methods. CSCs were isolated from 4-week-old wild type (WT) mice by explant culture and exposed to two different stress conditions: nutrient deprivation (ND, 0.1% FBS, 0mM glucose), or ischemia-like (ND in 1% O2). Mitotrackers orange (CMTMRos) and green (FM) were used for fluorescence and flow cytometry analysis. MiNA batch analysis macro was used for image network quantification. Standard Western Blot techniques were used for OPA1 quantification.

Results. CSCs were exposed to ND for 2h, 4h, 6h, 8h. We observed a time-dependent increase in mitochondria network formation, peaking at 6 hours, which was subsequently followed by mitochondrial fission at 8 hours, as assessed by immunofluorescence microscopy using MitoTracker Orange. Image analysis conducted with the MiNA macro corroborated these findings, indicating increased branch length mean (CTR:1.00±0.04 vs ND:1.24±0.06) and network branches mean after 6 hours (CTR: 1.60±0.08 vs ND: 1.84±0.11), suggesting mitochondrial fusion activation. Conversely, after 8 hours, both parameters declined, suggesting mitochondrial fission (CTR: 1.30±0.03 vs ND: 1.07±0.08, and CTR: 1.84±0.11 vs ND: 1.64±0.15). Subsequently, CSCs were exposed to ischemia-like stress for 6h and 16h. The immunofluorescence microscopy revealed mitochondrial fission in Mitotracker orange-stained cells, confirmed by reduced mean fluorescence intensity per cell (6h: 0.82-fold, and 16h: 0.5-fold), as a measure of decreased mitochondrial activity compared to the control. This reduction was also confirmed via microplate reader analysis (6h: 0.75-fold, and 16h: 0.79-fold). MiNa analysis further affirmed a decreasing trend in network branch mean at the 16h time point. Flow cytometry analysis after ischemia-like on the AnnV-/7A-AD- live gated cells stained with Mitotracker green indicated an increase in mitochondrial mass (16h: 2.06-fold), hinting at changes in mitochondrial number and/or volume. Western blot analysis revealed an increase in OPA1 protein levels at 6 hours (1.34-fold), followed by restoration to control levels after 16 hours. Isolation of CSCs from OPA1-overexpressing mice, and parallel treatments of wt cells with a specific OPA1-targeting siRNA are ongoing to investigate the protective and anti-fibrotic effects of OPA1-mediated fusion on the phenotype of CSCs.

Conclusions. Our findings indicate that ND and ischemia-like conditions induce mitochondrial network fragmentation in CSCs, associated to reduced mitochondrial activity and alterations in mitochondrial mass. The observed transient increase in OPA1 protein levels at 6 hours suggests that stressed CSCs may activate mitochondrial fusion as a compensatory mechanism to counteract the effects of stress conditions.

A578: THE ROLE OF OPA1 IN RISK FACTOR-INDUCED ENDOTHELIAL DYSFUNCTION

Luca D'Ambrosio (b), Maurizio Forte (a), Sonia Schiavon (b), Leonardo Schirone (b), Daniele Vecchio (b), Giacomo Frati (b), Sebastiano Sciarretta (b)
(a) IRCCS NEUROMED, POZZILLI, ITALY; (b) DEPARTMENT OF MEDICAL AND SURGICAL SCIENCES AND BIOTECHNOLOGIES, SAPIENZA UNIVERSITY OF ROME, LATINA, ITALY

Background. The endothelium plays paramount functions for the maintenance of vascular homeostasis, and endothelial dysfunction is a key hallmark of cardiovascular disorders. Accumulating lines of evidence demonstrated that impairment of mitochondrial dynamics leads to myocardial damage and cardiac disease progression in a variety of disease models. These findings suggest that modulation of mitochondrial dynamics may be considered as a valid therapeutic strategy in cardiovascular disease. Optic Atrophy 1 (OPA1) is the master regulator of mitochondrial inner membrane fusion. This process has a cardioprotective function. The role of OPA1 in endothelial cell function regulation during cardiovascular stress is not clear.

Purpose. To investigate whether OPA1 protein modulation impacts on endothelial cell angiogenic functions in response to common cardiovascular risk factors.

Methods. Data were collected in human umbilical vein endothelial cells (HUVECs) treated with high glucose (HG), oxidized LDL (ox-LDL), or

cigarette smoke condensate (CSC) to simulate type 2 diabetes, hypercholesterolemia, and smoking. At the end of treatments, Western Blot analysis, Mitotracker Assay, and JC1 assay were performed to investigate OPA1 protein levels, mitochondrial network appearance, and mitochondrial damage. Moreover in vitro angiogenesis function was studied via Matrigel assay. Endothelial function was assessed by measuring endothelial-dependent vasorelaxation of mesenteric arteries mounted on pressure myograph.

Results. After treating HUVECs with HG, ox-LDL, and CSC, proteins were extracted, and western blot analysis was performed. After 4 hours of treatment, OPA1 protein levels increase (CTR vs HG/ox-LDL/CSC: *p<0,05), whereas after 6h OPA1 levels decrease (CTR vs HG/CSC: *p<0,05; CTR vs ox-LDL: **p<0,01), finally returning to baseline levels after 8 hours. Mitotracker data showed a disruption of the mitochondrial network already 2 hours after treatment, while after 4 hours the network is restored and maintained for up to 8 hours. JC1 assay shows that 2 hours of treatment increased the mitochondrial membrane polarization, a sign of increased activity, which was partially attenuated at 4, 6, and 8 hours. Conversely, at longer time points of exposure to risk factors (24 and 48 hours), western blot analysis and Mitotracker assay showed an increase in OPA1 protein levels, which was associated with preserved mitochondrial network. Data collected by Matrigel assay showed that OPA1 silencing reduces HUVEC angiogenic function at baseline and significantly aggravates risk factors-induced angiogenesis inhibition (CTR vs HG/ox-LDL/CSC: **p<0,01). Finally, preliminary data demonstrated that OPA1 overexpression attenuates HG-induced endothelial dysfunction in mesenteric arteries from Tg mice ex vivo.

Conclusions. This study demonstrates that OPA1 levels in endothelial cells are modulated by risk factors and affect mitochondrial network and function. OPA1 is needed to maintain endothelial function in response to stress. OPA1 may represent a new potential therapeutic target to preserve mitochondrial activity and endothelial function in response to stress.

A579: DECIPHERING THE ROLE OF EXTRACELLULAR VESICLES IN HYPERTROPHIC AND DILATED CARDIOMYOPATHIES

Andrea Faggiano (a, b), Alessandra Rizzuto (b), Chiara Macchi (c), Stefania Paganini (b), Margherita Calcagnino (a), Massimiliano Ruscica (c), Stefano Carugo (a, b)

(a) DEPARTMENT OF CARDIO-THORACIC-VASCULAR DISEASE, FOUNDATION IRCCS CA GRANDA OSPEDALE MAGGIORE POLICLINICO OF MILAN, 20122, MILAN, ITALY; (b) DEPARTMENT OF CLINICAL SCIENCES AND COMMUNITY HEALTH, UNIVERSITY OF MILAN, 20122, MILAN, ITALY; (c) DEPARTMENT OF PHARMACOLOGICAL AND BIOMOLECULAR SCIENCES "RODOLFO PAOLETTI", UNIVERSITY OF MILAN, 20133, MILAN, ITALY

Background. According to the 2023 ESC dedicated guidelines, morphological traits and functional characteristics are clinically employed to categorize 5 distinct cardiomyopathy phenotypes: HCM, DCM, NDLVC, ARVC and restrictive cardiomyopathy. Unfortunately this phenotypic approach is incapable of describing the evolving nature of cardiomyopathies and/or their aetiological complexity. The lack of specific biomarkers for each cardiomyopathy represents a gap in this clinical field. Extracellular vesicles (EVs) are membrane-bound particles released by all cell types, in both physiological and pathological conditions, which constitute a promising source as prognostic and diagnostic biomarkers in cardiovascular disease due to their ability to reflect the cell of origin.

Aim and Methods. Thus, aim of the present work has been to characterize EVs, extracted by blood samples, in patients with HCM (N=17), DCM (N=15) and in healthy volunteers (N=13). HCM and DCM patients were clinically followed with multimodality imaging (ECG, echo and CMR) and underwent genetic testing at Ospedale Maggiore Policlinico of Milan. EVs were isolated through ultracentrifugation (110,000 g x 90 minutes) and expressed specific EV markers (i.e., tetraspanins, b-1 integrin and Alix).

Results. The majority of the recruited patients were males, 86.7% in DCM, 70.6% in HCM and 54% among healthy controls. The average age was 45.93±16.15, 60.5 years (48.25-63.5) and 47±5 years among DCM, HCM and health volunteers, respectively. Patients with DCM carried mainly TTN, SCN5A and DSP pathogenic variants. MYH7 and MYBPC3 pathogenic variants were the most observed in patients with HCM. EV Size and concentration were 180±2.1 nm and $3.64*10^9$ EV/ml/cell count in DCM; 195.5±17 nm and $3.52*10^9$ EV/ml/cell count in HCM; 181±4.9 nm and $5.21*10^9$ EV/ml/cell count in healthy volunteers. A statistical difference was found between controls and HCM for both size (p=0.02) and concentration (p=0.0079) (see Figure). A further step was to characterize the origin of EVs (see the Table). Compared to EVs isolated from heathy volunteers, those isolated from DCM and HCM patients have a raised percentage of platelet-derived and activated-endothelial derived EVs; conversely, endothelial-derived EVs were increased in controls vs DCM and HCM.

Conclusions. EVs isolated from patients with DCM and HCM present phenotypic differences compared to healthy volunteers allowing to complement the diagnostic armamentarium so far available.

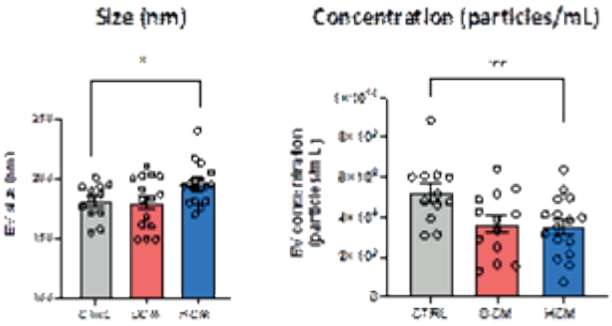

*Differences assessed by ANOVA one-way; * p<0.05; ** p<0.01*

Markers of EV parental cells

EVs (µl)	CTRL	DCM	HCM
CD14+	5.1 (3.7 - 6.1)	5.8 (3.4 - 12.8)	5 (3.3 - 12)
CD206+	2.2 (1.5 - 7.4)	2.8 (0.6 - 4.7)	2.4 (1 - 9)
CD41a+	17 (14.1 - 26.1)	40.6 (15.4 - 52)	52.7 (15 - 71)
CD202b+	7.5 (4.5 - 9.3)	3.5 (1.9 - 6.3)	3.6 (1.5 - 14)
CD62E+	25.3 (20.6 - 36.5)	33.9 (8.7 - 61)	41 (14.1 - 84)
CD309+	1.9 (1 - 4)	2.1 (1.5 - 4.8)	4.8 (0.7 - 13.3)
CD172a+	28.4 (18 - 40)	34.2 (9 - 57.5)	32.3 (18.7 - 53.4)

CD, cluster of differentiation. CD14, monocyte; CD206, macrophage; CD41a, platelet; CD202b, endothelial cell; CD62E, activated endothelial cells; CD309 endothelial progenitor cell; CD172a, cardiomyocytes; CTRL, controls.

A580: YIELD OF GENETIC TESTING IN PAEDIATRIC CARDIOMYOPATHIES: IMPLICATION FOR PHARMACOLOGICAL TREATMENT

Adelaide Ballerini (a), Alessia Gozzini (a), Francesca Girolami (a), Silvia Passantino (b), Alessia Tomberli (b), Silvia Favilli (b), Giulio Porcedda (b), Mattia Zampieri (b), Elena Bennati (b), Gaia Spaziani (b), Alberto Marchi (b), Giovanni Battista Calabri (b), Iacopo Olivotto (b, c)

(a) LAB. CARDIOGENETICA, AOU MEYER IRCCS, FLORENCE; (b) SOC CARDIOLOGIA PEDIATRICA E DELLA TRANSIZIONE AOU MEYER IRCCS, FLORENCE; (c) DIP. MEDICINA SPERIMENTALE E CLINICA, UNIVERSITÀ DEGLI STUDI DI FIRENZE, FLORENCE

Background. Paediatric cardiomyopathies (CMPs) are rare, heterogeneous and challenging conditions, often with a genetic etiology. Despite the increased diagnostic yield of Next Generation Sequencing (NGS), the genetic background of these diseases is often elusive. The assessment of aetiology is important in order to define prognosis and provide access to advanced therapies. Notably, novel approaches including small molecules and gene therapies are emerging and represent the focus of growing international efforts.

Methods. We assessed the yield of NGS genetic testing in a tertiary paediatric referral center for CMPs, in order to evaluate the prevalence of candidacy to current or emerging treatment. After genetic counselling offered to parents, genetic test was performed in 96 paediatric patients: 44 Hypertrophic Cardiomyopathy (HCM), 35 Dilated Cardiomyopathy (CMD), 14 Arrhythmogenic Cardiomyopathy (AC) and 3 Restrictive Cardiomyopathy (RCM).

Results. By NGS we identified a pathogenic/likely pathogenic variant in 35/96 patients (36,5%): 23/44 with HCM (52%), 7/35 with DCM (20%); 3/14 with AC (21%) and 2/3 with RCM (66%). The most common aetiology in HCM and DCM was sarcomeric, mostly involving MYH7, MYBPC3, TNNT2 and TTN. Among AC patients 1 DSP variant and 1 FLNC were identified. Additionally, we identified the etiology of 7 syndromic patients: 4 with Noonan Syndrome (PTPN11 and biallelic LZTR1), 2 with Danon Disease (LAMP2) and a child affected by Glycogen Storage Disease (PRKAG2). In the light of emerging treatment, 20/35 (57%) of the patients in whom a variant was identified were potentially eligible for small molecule or gene therapy; this subset represents 21% of the total cohort.

Conclusions. A molecular diagnosis could be obtained in about 40% of a paediatric cohort with cardiomyopathies; overall, about 21% of the whole cohort had genotypes potentially amenable to emerging precision therapies. Genetic testing may have direct implications for clinical management, and represents a prerequisite to evaluate candidacy for novel treatment.

Table 1

Phenotype	% P/LP	Genotype Identified	Potential treatment*
HCM N=44	52% (23/44)	N=6 MYBC3	Gene therapy
		N=8 MYH7	Myosin inhibitors
		N=1 TNNI3	X
		N=1 TPM1	X
		N=2 LAMP2	Gene therapy
		N=3 PTPN11	MEK inhibitors
		N=1 LZTR1	X
		N=1 PRKAG2	X
DCM N=35	20% (7/35)	N=1 MYH7	Myosin activators
		N=3 TNNT2	X
		N=3 TTN	X
AC N=14	21% (3/14)	N=2 DSP	X
		N=1 FLNC	X
RCM N=3	66% (2/3)	N=1 FLNC	X
		N=1 TNNT2	X

*Helms A.S., et al., Translation of New and Emerging Therapies for Genetic Cardiomyopathies, JACC, 2022
*Argirò A., et al., Gene Therapy for heart failure and cardiomyopathies, Rev. Esp. Cardiol, 2023

A581: CLINICAL AND ECHOCARDIOGRAPHIC CORRELATIONS OF A RARE CASE OF CONGENITAL HEART DISEASE DUE TO TAB2 GENE MUTATION

Alberto Guarnaccia (a), Antonio De Luca (a), Alessandro Altinier (a), Alessia Paldino (a), Matteo Dal Ferro (a), Marco Merlo (a), Gianfranco Sinagra (a)
(a) CARDIOTHORACOVASCULAR DEPARTMENT, DIVISION OF CARDIOLOGY, AZIENDA SANITARIA UNIVERSITARIA GIULIANO ISONTINA AND UNIVERSITY OF TRIESTE, TRIESTE, ITALY

A 22-year-old patient with a family history of congenital heart disease and sudden cardiac death has been undergoing cardiological follow-up since childhood due to initial detection of a bicuspid aortic valve. Since 2019, the patient has been symptomatic due to palpitations. Subsequently, the patient experienced a presyncopal episode. A slow-fast atrioventricular nodal reentry tachycardia was documented and treated with radiofrequency ablation. The patient's ECG shows an ectopic atrial rhythm with a variably short PR interval and negative T waves in the precordial leads. Echocardiography shows a moderately dilated left ventricle, preserved global systolic function, whereas the right ventricle is dilated and hypokinetic. The bicuspid aortic valve does not show stenosis nor regurgitation. Prolapse of the tricuspid valve is also present. Cardiac magnetic resonance imaging shows a septal intramyocardial late gadolinium enhancement. The haploinsufficiency of the TAK1 binding protein 2 (TAB2) gene, located on chromosome 6 (6q24-q25), is responsible for congenital heart disease. Analysis of human embryos has shown the importance of the TAB2 gene in heart development, with a preferential localization in ventricular trabeculae, endothelial cells of ventricular outflow tracts and valvular planes. Dosage-sensitive gene expression defects are associated with ventricular hypertrophy and dysfunction, morphological alterations of the interatrial and interventricular septa, and alterations in the outflow tracts and valvular planes. Conduction abnormalities with PR interval shortening and arrhythmic events, including paroxysmal supraventricular arrhythmias, have also been described.

A582: EARLY PHENOTYPIC AND PARACRINE CHANGES IN CARDIAC MESENCHYMAL STROMAL CELLS AFTER THORACIC RADIOTHERAPY AS A HALLMARK OF CARDIOTOXICITY

Vittorio Picchio (a), Roberto Gaetani (b), Francesca Pagano (c), Yuriy Derevyanchuk (b), Erica Floris (d), Claudia Cozzolino (d), Antonella Bordin (d), Elena De Falco (d), Diana Massai (e), Radia Tamarat (f), Maurizio Pesce (g), Susana Constantino Santos (h), Giacomo Frati (d), Elisa Messina (b), Isotta Chimenti (d)
(a) DEPARTMENT OF ANGIOCARDIONEUROLOGY, IRCCS NEUROMED INSTITUTE, POZZILLI, ITALY; (b) DEPARTMENT OF MOLECULAR MEDICINE, SAPIENZA UNIVERSITY OF ROME, ROME, ITALY; (c) INSTITUTE OF BIOCHEMISTRY AND CELL BIOLOGY, COUNCIL NATIONAL RESEARCH, ROME, ITALY; (d) DEPARTMENT OF MEDICAL SURGICAL SCIENCES AND BIOTECHNOLOGIES, SAPIENZA UNIVERSITY OF ROME, LATINA, ITALY; (e) DEPARTMENT OF MECHANICAL AND AEROSPACE ENGINEERING, POLITECNICO DI TORINO, TURIN ITALY; (f) INSTITUT DE RADIOPROTECTION ET DE SURETE NUCLEAIRE, FONTENAY-AUX-ROSES, FRANCE; (g) CENTRO CARDIOLOGICO MONZINO, MILANO, ITALY; (h) CENTRO CARDIOVASCULAR DE UNIVERSIDADE DE LISBOA, LISBON, PORTUGAL

Background. Radiotherapy (RT)-induced cardiac toxicity and cardiovascular diseases represent potential late complications for cancer survivors who underwent therapeutic thoracic irradiation. Thoracic RT often leads to heart irradiation, increasing the risk of heart diseases. The mechanisms involved in cardiotoxicity induced by therapeutic radiation doses are still largely unknown.
Purpose. To assess the phenotypic and paracrine features of cardiac mesenchymal stromal cells (CMSCs) at early follow-up after the end of thoracic irradiation of the heart, as an early sign and/or mechanism of cardiac toxicity anticipating late organ dysfunction.
Methods. Resident CMSCs were isolated from a rat model of thoracic irradiation with clinically relevant heart dosimetry (sham, 0.04, 0.3, or 1.2 Gy for 23 fraction), that develops delayed dose-dependent cardiac dysfunction after 1 year. Cells were isolated 6 or 12 weeks after the end of RT before any detectable phenotype in vivo, and fully characterized at transcriptional, paracrine, and functional levels.
Results. CMSCs displayed several altered features in a dose- and time-dependent trend, with the most impaired characteristics observed in those exposed in situ to the highest radiation dose with time. CMSCs isolated 12 weeks after the end of RT from the 1.2Gy groups displayed a significant reduction in the migration capacity versus sham (1.2Gy 0.84±0.05 vs sham 0.74±0.06 normalized scratch area at 14h, $p<0.05$), and a significantly reduced spheroid-forming capacity versus both sham and 0.04Gy (1.2Gy 1.03±0.11 vs sham 2.13±0.21 vs 0.04Gy 2.35±0.30 number/mm^2, $p<0.001$ ANOVA). CMSCs exposed to 1.2Gy expressed significantly higher mRNA levels of profibrotic genes (TGFB1 1.76-fold, GATA4 2.24-fold, and COL1A1 1.78-fold, $p<0.05$ vs sham or 0.04Gy). Transcriptomic analysis by deep RNA sequencing of CMSCs at 6- and 12-week follow-up evidenced a group of 49 genes significantly modulated in the 1.2Gy group at 12-week follow-up (adj $p<0.05$ vs sham). Gene ontology (GO) analysis on this gene set returned 3 significant terms related to the key fibrotic pathway of TGFβ1 signaling (GO:0007179, GO:0071560, GO:0071559; adj $p<0.01$). Screening of CMSCs conditioned media from the 1.2Gy group at 12-week follow-up revealed modulation of multiple cytokines; when used to culture the monocyte THP1 cell line, the mRNA levels of 3 classical markers of pro-inflammatory M1 phenotype increased (IL6 1.92-fold, CCL2 1.73-fold, $p<0.05$ vs sham; IL8 2.38-fold, $p<0.01$ vs sham). The same conditioned media had also reduced angiogenic support to endothelial cells (2.1±0.6x10^3 vs 7.3±0.1x10^3 mesh area, $p<0.001$ vs sham).
Conclusions. Data collected on a clinically relevant rat model of heart irradiation simulating thoracic radiotherapy suggest that early pro-fibrotic specification and paracrine alterations of cardiac stromal cells may represent a dose-dependent biological substrate for the cardiac dysfunction phenotype observed in vivo at long follow-up.

A583: ISCHEMIC HEART DISEASE AND GENETIC SUSCEPTIBILITY: HYPOTESIS OF A PROTECTIVE CROSS-TALK BETWEEN K-ATP AND ENOS

Paolo Severino (a), Andrea D´amato (a), Massimo Mancone (a), Alberto Palazzuoli (b), Marco Valerio Mariani (a), Silvia Prosperi (a), Vincenzo Myftari (a), Claudia Cestiè (a), Aurora Labbro Francia (a), Carlo Lavalle (a), Giovanni Battista Forleo (c), Lucia Ilaria Birtolo (a), Viviana Caputo (d), Fabio Miraldi (a), Cristina Chimenti (a), Roberto Badagliacca (a), Viviana Maestrini (a), Maurizio Volterrani (e), Raffaele Palmirotta (f), Francesco Fedele (a), Carmine Dario Vizza (a)
(a) DIPARTIMENTO DI SCIENZE CLINICHE, INTERNISTICHE, ANESTESIOLOGICHE E CARDIOVASCOLARI, SAPIENZA UNIVERSITÀ DI ROMA, VIALE DEL POLICLINICO 155, 00161 ROMA, ITALIA; (b) UNITÀ DI PATOLOGIA CARDIOVASCOLARE, DIPARTIMENTO CARDIOTORACICO E VASCOLARE, OSPEDALE LE SCOTTE, UNIVERSITÀ DI SIENA, 53100 SIENA, ITALIA; (c) DIPARTIMENTO DI CARDIOLOGIA, OSPEDALE UNIVERSITARIO LUIGI SACCO, 20157 MILANO, ITALIA; (d) DIPARTIMENTO DI MEDICINA SPERIMENTALE, SAPIENZA UNIVERSITÀ DI ROMA, 00161 ROMA, ITALIA; (e) IRCCS SAN RAFFAELE PISANA, ROMA; (f) DIPARTIMENTO INTERDISCIPLINARE DI MEDICINA, UNIVERSITÀ ALDO MORO DI BARI

Genetic susceptibility may influence ischemic heart disease (IHD) predisposition and affect coronary blood flow (CBF) regulation mechanisms. The aim of this study was to investigate the association among single nucleotide polymorphisms (SNPs) of genes encoding for proteins involved in CBF regulation and IHD. A total of 468 consecutive patients were enrolled and divided into three groups according to coronary angiography and intracoronary functional tests Results. G1, patients with coronary artery disease (CAD); G2, patients with coronary microvascular dysfunction (CMD); and G3, patients with angiographic and functionally normal coronary arteries. A genetic analysis of the SNPs rs5215 of the potassium inwardly rectifying channel subfamily J member 11 (KCNJ11) gene and rs1799983 of the nitric oxide synthase 3 (NOS3) gene, respectively encoding for the Kir6.2 subunit of ATP sensitive potassium (K_{ATP}) channels and nitric oxide synthase (eNOS), was performed on peripheral whole blood samples. A significant association of rs5215_G/G of KCNJ11 and rs1799983_T/T of NOS3 genes was detected in healthy controls compared with CAD and CMD patients. Based on univariable and multivariable analyses, the co-presence of rs5215_G/G of KCNJ11 and rs1799983_T/T of NOS3 may represent an independent protective factor against IHD, regardless of cardiovascular risk factors. This study supports the hypothesis that SNP association may influence the crosstalk between eNOS and the K_{ATP} channel that provides a potential protective effect against IHD.

A584: A RARE CASE OF LMNA MEDIATED CONCEALED CARDIOMYOPATHY

Andrea Faggiano (a, b), Chiara Giordano (a, b), Luigi Tassetti (d), Stefania Paganini (b), Margherita Calcagnino (a), Massimo Saviano (a), Massimiliano Ruscica (c), Alberto Pollina (a), Stefano Carugo (a, b)
(a) DEPARTMENT OF CARDIO-THORACIC-VASCULAR DISEASES, FOUNDATION IRRCS CA' GRANDA OSPEDALE MAGGIORE POLICLINICO, 20122, MILAN,ITALY; (b) DEPARTMENT OF CLINICAL SCIENCES AND COMMUNITIY HEALTH, UNIVERSITY OF MILAN, 20122 MILAN, ITALY; (c) DEPARTMENT OF PHARMACOLOGICAL AND BIOMOLECULAR SCIENCES "RODOLFO PAOLETTI", UNIVERSITY OF MILAN, 20133, MILAN, ITALY; (d) DEPARTMENT OF PERIOPERATIVE CARDIOLOGY AND CARDIOVASCULAR IMAGING, IRCCS CENTRO CARDIOLOGICO MONZINO, MILAN, ITALY

Background. While the ESC 2023 Guidelines on the management of cardiomyopathies do not explicitly recognize it as a clinical entity, there is growing evidence to suggest that malignant arrhythmias, included sudden cardiac death (SCD), may manifest before any structural changes in inherited cardiomyopathy, giving rise to what is often referred to as "concealed cardiomyopathy" (CCM). The diagnosis of CCM is obtained post-mortem or following resuscitated cardiac arrest. This diagnosis occurs when no structural cardiac abnormalities are found during autopsy or through multimodality imaging, but a causative mutation (pathogenetic or likely pathogenetic P/LP variants) on cardiomyopathy-associated genes (e.g. ACTN2, DES, DSP, MYBPC3, MYH7, PKP2, and LMNA) is identified.

Case description. We present the case of an 18-year-old male athlete who experienced a sudden cardiac arrest at rest, successfully resuscitated with external defibrillation for ventricular fibrillation. Despite a healthy medical history and no anomalies in the post-arrest ECG, comprehensive investigations ruled out electrolyte imbalances, temperature fluctuations, pH disturbances, neurological deficits, acute aortic syndromes, and acute pulmonary thromboembolism. Coronary CT angiography confirmed coronary arteries free from atherosclerotic disease. Extensive clinical and laboratory assessments for potential causes of SCD were conducted, all resulted inconclusive. Notably, cardiac magnetic resonance imaging performed seven days after the SCD showed normal morpho-functional findings, with no edema, LGE, or pathological mapping results (Figure 1). A three-generation family history unveiled a concerning event: the paternal grandmother's sudden cardiac death at age 65. Genetic testing, specifically targeted clinical exome sequencing for channelopathies, cardiomyopathies, and arrhythmic diseases, identified a LP variant in the LMNA gene, supporting the diagnosis of CCM. Thus, the temporary wearable defibrillator used during the genetic test awaiting period was replaced with a permanent subcutaneous defibrillator implant. Remarkably, the same likely pathogenic variant was identified in the patient's 55-year-old asymptomatic father, who showed no pathological findings at phenotypic screening.

Clinical considerations: Clinical dilemma arises in the management of a rare LMNA-mediated CCM case, adding to existing evidence of effective SCD risk prior to structural changes in cardiomyopathies. Now, the challenge lies in deciding whether to recommend defibrillator implantation for the proband's father, whose LMNA risk score predicts a 10% risk of SCD over the next 5 years, especially given the absence of clinical phenotype evolution for guidance.

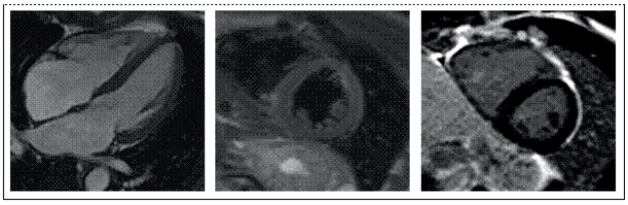

A585: STUDY OF THE PHENOTYPE AND FUNCTION OF RESIDENT CARDIAC MESENCHYMAL STROMAL CELLS IN THE CHARME KNOCK-OUT MOUSE MODEL

Erica Floris (a), Vittorio Picchio (a), Claudia Cozzolino (a), Valeria Taliani (b), Giulia Buonaiuto (b), Carmine Nicoletti (b), Monica Ballarino (b), Isotta Chimenti (a), Francesca Pagano (c)
(a) SAPIENZA UNIVERSITÀ DI ROMA - DIPARTIMENTO DI SCIENZE E BIOTECNOLOGIE MEDICO-CHIRURGICHE; (b) SAPIENZA UNIVERSITÀ DI ROMA - DIPARTIMENTO DI BIOLOGIA E BIOTECNOLOGIE "CHARLES DARWIN"; (c) CONSIGLIO NAZIONALE DELLE RICERCHE - ISTITUTO DI BIOCHIMICA E BIOLOGIA CELLULARE

Background. Charme is a murine long non-coding RNA (lncRNA) with specific expression in skeletal and cardiac muscle, presenting a human orthologue with 45% identity. This lncRNA is involved in the myogenic process, targeting many genes necessary for myocyte maturation and known to be altered in multiple congenital cardiomyopathies. Charme depletion leads to incomplete muscle differentiation. Charme-/- mice display an altered cardiac phenotype with increased wall thickness and reduced chamber dimensions due to cardiomyocyte hyperplasia. Left ventricular dilatation and reduced fractional shortening are detected in aged Charme-/- mice. Embryonic myocardial architecture reveals ventricular morphological alterations, resembling some congenital cardiomyopathies. Cardiac mesenchymal stromal cells (CMSCs) play key roles in tissue homeostasis and pathophysiology, by maintaining the extracellular matrix and by paracrine action on all myocardial cells.

Purpose. To elucidate the phenotype, paracrine function, and myofibroblast differentiation capacity of resident CMSCs in the Charme-/- mouse model.

Methods. CMSCs were isolated from 5-week-old wild-type (WT) and Charme-/- mice by explant culture, pooling at least 4 different hearts per culture.

Results. Western blot analysis on Charme-/- whole cardiac tissue showed reduced collagen I and collagen I/III protein ratio compared to WT hearts (0,17±0,1 vs 0,85±0,1 normalized OD N=4, p<0,005). Charme-/- CMSCs showed increased features of plastic phenotypes, such as enhanced spontaneous spheroid growth (123,6±11,9 vs 51,0±6,4 spheroids/well; N=8, p<0,0001) and clonogenesis efficiency (2,7±0,5-fold; N=7, p<0,05) compared to WT cells. Charme-/- CMSCs also showed increased migration ability (Charme-/-: 68,5±2,7% vs WT: 80,2±0,7% wound area; N=2, p<0,005). Flow cytometry identified a reduced proportion of the lin-/Sca1+/CD90+ active fibroblast cell population in Charme-/- versus WT CMSCs (7,4±1,6% vs 56,9±6,5%; N=6, p<0,05). The secretome of Charme-/- CMSCs revealed a general depletion in many cardioprotective cytokines, included in the KEGG term "PI3K-Akt signaling pathway" (FDR<0,0005), and classified in Gene Ontology categories of myoblast differentiation and fusion (GO:1901739, GO:1901741, GO:0045663, GO:0045661; FDR<0,05). Stimulation with TGFb-1 resulted in lower expression of fibroblast activation markers in Charme-/- CMSCs compared to WT CMSCs, as assessed by immunofluorescence staining for aSMA (0,5±0,1 vs 0,8±0,1 mean fluorescence intensity; N=6-12, p<0,05), and collagen I/III mRNA expression ratio (1,3±0,1 vs 2,2±0,4 2^-DCt; N=3, p<0,01). The secretome of TGFb1-stimulated Charme-/- CMSCs was less effective in sustaining cardiomyocyte survival versus the WT CMSC secretome (1,7±0,1 vs 1,9±0,1 normalized OD at 48h; N=5, p<0,005), coherently with the impoverished paracrine profile of Charme-/- cells.

Conclusions. Charme-/- CMSCs show a less mature phenotype associated to reduced collagen I presence in situ, reduced activation and differentiation upon stimulation, and impaired cardioprotective paracrine functions, suggesting a key role of Charme in the physiology of the cardiac stroma, possibly mediating in part the altered cardiac phenotype of Charme-/- mice.

A586: DE NOVO X-LINKED MUTATION OF DYSTROPHIN GENE IN DILATED CARDIOMYOPATHY: CLINICAL FEATURES AND IN SILICO ANALYSIS

Ilaria Ragnatela (a), Francesco Santoro (a), Maria D´apolito (a), Rosa Santacroce (a), Michele Correale (a), Maurizio Margaglione (a), Natale Daniele Brunetti (a)
(a) CARDIOLOGY UNIT, DEPARTMENT OF MEDICAL AND SURGERY SCIENCES, UNIVERSITY OF FOGGIA

Background. Dilated cardiomyopathy (DCM) is featured by left ventricular dilatation and systolic dysfunction. In 20-35% of cases, the DMC is associated with a genetic cause, with a highly variable pattern of inheritance, autosomal dominant, recessive or X-linked.

Aim. To characterize genotype and phenotype of an Italian woman affected by DCM and her family.

Methods. Clinical evaluation, ECG and echocardiogram have been performed in the proband and her relatives. Whole exome sequencing (WES) using the Illumina platform has been performed on the proband's DNA. According to the standard protocol, the variant identified with the WES was confirmed in the index case and studied in the other family members by direct capillary Sanger sequencing.

Results. The proband is a 37-years-old italian woman diagnosed with DCM at age of 33 years with severely reduced right and left ventricular systolic function (LVEF 27%) and septal fibrosis at cardiac magnetic resonance. Molecular genetic analysis identified a variant of uncertain clinical significance in the dystrophin (DMD) gene (c.10103A>G p.(Asp3368Gly)), exon 70. This variant, never described, is a missense one that replaces the amino acid aspartic acid with glycine at codon 3368 of cysteine-rich domain of the DMD protein. In silico prediction suggests that this variant could have a deleterious impact on protein structure and function (Sift: deleterious (score 0.01) and PolyPhen: probably damaging (score 0.975)). The direct capillary Sanger sequencing confirmed the presence of the mutation in the proband. However, this mutation was not found in her father, mother and sister (phenotypically healthy), therefore it was considered a de novo variant. Subsequently the mutation has been searched in her 8-years-old son, the direct sequencing confirmed the presence of the same mutation. The young patient did not present clinical and echocardiographic signs and symptoms attributable to DCM, but reported asthenia and blood chemistry tests showed increased value of CPK, therefore the diagnosis of muscular dystrophy has been assumed.

Conclusions. A novel and de novo DMD gene variant has been identified in a patient affected by DCM. DMD gene mutation may have different clinical presentations, requiring a tailored patient approach.

A587: A NOVEL DLG1 VARIANT IN A FAMILY WITH BRUGADA SYNDROME: CLINICAL CHARACTERISTICS AND IN SILICO ANALYSIS

Ilaria Ragnatela (a), Francesco Santoro (a), Maria D´apolito (a), Rosa Santacroce (a), Giorgia Cordisco (a), Girolamo D´arienzo (a), Pierluigi Pellegrino (a), Maurizio Margaglione (a), Natale Daniele Brunetti (a)
(a) CARDIOLOGY UNIT, DEPARTMENT OF MEDICAL AND SURGERY SCIENCES, UNIVERSITY OF FOGGIA

Background. Brugada syndrome (BrS) is an inherited primary channelopathy syndrome associated with sudden cardiac death. Overall, variants have been identified in eighteen genes encoding for ion channel subunits and seven genes for regulatory proteins. Recently, a missense variant in DLG1 has been found within a BrS phenotype-positive patient. DLG1 encodes for synapse associated protein 97 (SAP97), a protein characterized by the presence of multiple domains for protein–protein interactions including PDZ domains. In cardiomyocytes, SAP97 interacts with Nav1.5, a PDZ binding motif of SCN5A and other potassium channel subunits.
Aim. To characterize the phenotype of an Italian family with BrS syndrome carrying a DLG1 variant.
Methods. Clinical and genetic investigations were performed. Genetic testing was performed with whole-exome sequencing (WES) using the Illumina platform. According to the standard protocol, a variant found by WES was confirmed in all members of the family by bi-directional capillary Sanger resequencing. The effect of the variant was investigated by using in silico prediction of pathogenicity.
Results. The index case was a 74-year-old man with spontaneous type 1 BrS ECG pattern that experienced syncope and underwent ICD implantation. WES of the index case, performed assuming a dominant mode of inheritance, identified a heterozygous variant, c.1556G>A (p.R519H), in the exon 15 of the DLG1 gene. In the pedigree investigation, 6 out of 12 family members had the variant. Carriers of the gene variant all had BrS ECG type 1 drug induced and showed heterogeneous cardiac phenotypes with two patients experiencing syncope during exercise and fever, respectively. The amino acid residue #519 lies near a PDZ domain and in silico analysis suggested a causal role for the variant. Modelling of the resulting protein structure predicted that the variant disrupts an H-bond and a likelihood of being pathogenic. As a consequence, it is likely that a conformational change affects protein functionality and the modulating role on ion channels.
Conclusions. A DLG1 gene variant identified was associated with BrS. The variant could modify the formation of multichannel protein complexes, affecting ion channels to specific compartments in cardiomyocytes.

A588: GENOTYPE EVALUATION OF PATIENTS WITH BRUGADA SYNDROME: PREVALENCE AND CLINICAL FEATURES

Alessandra Margaglione (a), Francesco Santoro (a), Ilaria Ragnatela (a), Maria D´apolito (a), Rosa Santacroce (a), Natale Daniele Brunetti (a)
(a) DEPARTMENT OF MEDICAL AND SURGERY SCIENCES, UNIVERSITY OF FOGGIA

Background. Brugada syndrome (BrS) is an inherited disorder with autosomal dominant transmission, which occurs predominantly in males in the third to fourth decade of life with life threatening arrhythmias. The mutations recognized to date as causal of BrS involve mainly genes related to ion channel subunits.
Methods. In the present study, in a cohort of 26 patients with BrS, 18 probands were studied through Next Generation Sequencing (NGS). Clinical feature, echocardiographic and electrocardiographic parameters, along with the risk stratification Shanghai score were recorded.
Results. Mean age of patients was 46±14 years (96% men) and 14 out 26 (54%) patient had an ICD. When evaluating probands only, nine out of 18 (50%) patients had a genetic mutation. Ion channel mutations were found in 8 out of 9 patients (SCN5A, DLG1, KCNQ1 AKAP9, CACNB2, CAV-3, CTTN3) and a sarcomeric mutation (ACTN2) was found in one patient. There were no differences in term of age, gender and CV risk factor between patients with positive genetic testing versus negative one. However, patients with positive genetic testing had higher Shangai risk score (5.1±1.3 vs 4.1±1.6, p=0.01) and lower left ventricular global longitudinal strain (-17.1±1.6 vs 19.3±1.5% p=0.03).
Conclusions. the present patient cohort shows gene heterogeneity in patients with Brugada Syndrome, with a high prevalence of ion channel mutations. Patients with positive genetic testing seem to have a higher arrhythmic risk and slight impairment of left ventricular function.

FARMACI CARDIOVASCOLARI E NUTRACEUTICI

A589: UTILIZZO DEI PCSK9 INIBITORI IMMEDIATAMENTE DOPO UNA SINDROME CORONARICA ACUTA. DATI DAL REGISTRO AT-TARGET-IT

Sara Fontanarosa (a), Christian Basile (a), Gennaro Galasso (b), Angelo Catalano (c), Giuseppe Patti (d), Paolo Calabrò (e), Giuseppe Andò (f), Ferdinando Varbella (g), Giuseppe Musumeci (h), Saverio Muscoli (i), Francesco Giallauria (a), Italo Porto (j), Federica Marzano (a), Paola Gargiulo (a), Pasquale Perrone Filardi (a)
(a) UNIVERSITÀ DEGLI STUDI DI NAPOLI "FEDERICO II"; (b) AZIENDA OSPEDALIERA UNIVERSITARIA SAN GIOVANNI DI DIO E RUGGI D'ARAGONA; (c) PRESIDIO OSPEDALIERO MARIA SS ADDOLORATA; (d) AZIENDA OSPEDALIERO-UNIVERSITARIA "MAGGIORE DELLA CARITÀ" NOVARA; (e) UNIVERSITÀ DEGLI STUDI DELLA CAMPANIA "LUIGI VANVITELLI"; (f) UNIVERSITÀ DEGLI STUDI DI MESSINA; (g) OSPEDALE DI RIVOLI (TORINO); (h) AZIENDA OSPEDALIERA ORDINE MAURIZIANO TORINO; (i) POLICLINICO TOR VERGATA; (j) UNIVERSITÀ DEGLI STUDI DI GENOVA

Background. Gli inibitori di PCSK9 (PCSK9i), alirocumab ed evolocumab, hanno recentemente dimostrato nei pazienti con sindrome coronarica acuta (SCA) cambiamenti favorevoli nella morfologia della placca, nonché una riduzione degli eventi cardiovascolari e del colesterolo LDL. Vi è, tuttavia, carenza di dati sull'utilizzo precoce nel mondo reale di PCSK9i in pazienti con SCA.
Obiettivi. AT-TARGET-IT è un registro di fase 4 prospettico, multicentrico, coinvolgente 25 centri italiani, per valutare efficacia, sicurezza, aderenza e persistenza della terapia con PCSK9i, nonché per valutare i pattern di terapia ipolipemizzante in pazienti a rischio cardiovascolare molto alto e/o affetti da ipercolesterolemia familiare. Nella presente analisi riportiamo i dati di efficacia e sicurezza del trattamento con PCSK9i iniziato in corso di ricovero per SCA.
Metodi. Dal marzo 2020 a maggio 2023 sono stati arruolati 1815 pazienti trattati con PCSK9i. Sono state registrate caratteristiche demografiche, cliniche, terapie concomitanti e parametri di laboratorio al momento della prescrizione di PCSK9i ed ai successivi follow-up.
Risultati. Sono riportati i dati di 750 pazienti (età media 61 anni, 22% donne), di cui il 60% già affetto da sindrome coronarica cronica, seguiti per un follow-up mediano di 15 mesi. Il valore mediano di colesterolo LDL all'ingresso era di 142 mg/dl ed ha raggiunto il valore di 45 mg/dl (-67%, riduzione mediana assoluta pari a 97 mg/dl) al primo controllo effettuato dopo 37 giorni (range interquartile 33-77), permanendo invariato all'ultimo controllo. Dei 750 pazienti arruolati, 643 (86%) risultavano in trattamento con farmaci ipolipemizzanti al momento della dimissione, 163 dei quali (25%) con ezetimibe, 62 (10%) con statine e 418 (65%) con associazione statina/ezetimibe. Il target di colesterolo LDL è stato raggiunto in 507 pazienti (68%), e, in particolare, nel 50% di quelli trattati con soli PCSK9i, e nel 63% e 73%, rispettivamente, di quelli trattati con ezetimibe o statina±ezetimibe (Figura). Non si sono verificate reazioni avverse gravi.
Conclusioni. I risultati del registro AT-TARGET-IT mostrano che il trattamento precoce con PCSK9i non soltanto riduce efficacemente i valori di colesterolo LDL, ma che tali risultati vengono ottenuti già dal primo controllo precoce con un ottimo profilo di sicurezza.

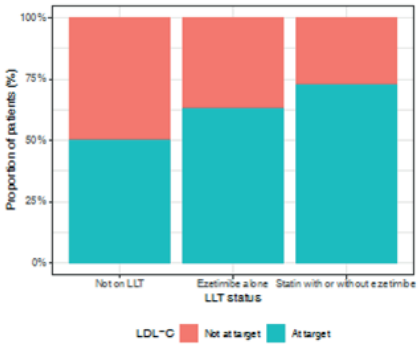

A590: EFFICACIA E SICUREZZA DI INCLISIRAN NEL REAL WORLD: RISULTATI DAL REGISTRO CHOLINET

Davide Buonocore (a), Ciro Indolfi (i), Piera Merlini (g), Marco Matteo Ciccone (j), Giuseppe Musumeci (k), Ferdinando Varbella (c), Paolo Calabrò (b), Stefano Carugo (s), Leonardo De Luca (l), Gennaro Galasso (n), Claudio Bilato (m), Mario Crisci (w), Italo Porto (r), Saverio Muscoli (u), Giuseppe Patti (t), Federica Marzano (a), Paola Gargiulo (a), Pasquale Perrone Filardi (a)
(a) UNIVERSITÀ DEGLI STUDI DI NAPOLI FEDERICO II; (b) UNIVERSITÀ DEGLI STUDI DELLA CAMPANIA LUIGI VANVITELLI; (c) OSPEDALE DI RIVOLI; (d) PRESIDIO OSPEDALIERO PESCARA; (e) UNIVERSITÀ DEGLI STUDI DI NAPOLI FEDERICO II, DIPARTIMENTO DI MEDICINA CLINICA E CHIRURGIA; (f) P.O. MARIA SS ADDOLORATA; (g) ASST GRANDE OSPEDALE NIGUARDA; (h) AOU OSPEDALE RIUNITI DI FOGGIA; (i) UNIVERSITÀ DEGLI STUDI MAGNA GRECIA - AOU MATER DOMINI; (j) UNIVERITÀ DEGLI STUDI DI BARI "ALDO MORO"; (k) AZIENDA OSPEDALIERA ORDINE MAURIZIANO; (l) AZIENDA OSPEDALIERA SAN CAMILLO-FORLANINI; (m) OSPEDALI DELL'OVEST VICENTINO; (n) AZIENDA OSPEDALIERA UNIVERSITARIA SAN GIOVANNI DI DIO E RUGGI D'ARAGONA; (o) AZIENA OSPEDALIERA UNIVERSITARIA DI PARMA; (p) POLICLINICO CASILINO; (q) OSPEDALE SS ANNUNZIATA AOU SASSARI; (r) UNIVERSITÀ DI GENOVA; (s) FONDAZIONE IRCCS CA GRANDE OSPEDALE MAGGIORE POLICLINICO; (t) AOU MAGGIORE DELLA CARITÀ DI NOVARA; (u) POLICLINICO TOR VERGATA; (v) UNIVERSITÀ DEGLI STUDI DI MESSINA; (w) AORN DEI COLLI - OSPEDALE MONALDI

Background. Inclisiran è stato recentemente introdotto nella pratica clinica in Italia, di conseguenza non sono disponibili dati di real-world di efficacia e sicurezza.

Obiettivi. Cholinet (Cholesterol inclisiran Italian network) è un registro italiano multicentrico prospettico di fase 4 coinvolgente 21 centri italiani ideato per valutare efficacia, sicurezza, aderenza e persistenza dell'utilizzo di Inclisiran, oltre che per valutare variazioni della terapia ipolipemizzante concomitante e l'associazione con variabili cliniche e demografiche.
Metodi. Da Novembre 2022 a Settembre 2023 il registro Cholinet ha arruolato pazienti in terapia con inclisiran come parte della loro regolare pratica clinica. Le caratteristiche cliniche e demografiche, le terapie concomitanti e gli esami ematochimici sono stati registrati al momento della prescrizione e nel corso del follow-up.
Risultati. Sono stati arruolati 147 pazienti (14% con FH, 30% donne, età media 64 anni), di questi 51 avevano dati di follow-up a 3 mesi, ovvero al momento della seconda somministrazione. Al momento della prescrizione di Inclisiran il valore mediano di colesterolo LDL era di 96.6 mg/dl e raggiungeva il valore di 48.8 mg/dL al terzo mese di osservazione (49% di riduzione). Tutti i pazienti in follow-up sono stati aderenti con la somministrazione a 3 mesi. Dei 147 pazienti arruolati, 129 pazienti (88%) erano in terapia ipolipemizzante, di questi 22 (17%) erano in terapia con il solo ezetimibe, 15 (12%) erano in terapia con sola statina e 92 (71%) erano in terapia con la combinazione statina/ezetimibe. Dei pazienti arruolati, 9 (6%) erano stati precedentemente trattati con evolocumab e 6 (4%) con alirocumab. Tra i pazienti valutati al follow-up di 3 mesi, 32 pazienti (62%) hanno raggiunto il target di colesterolo LDL, di questi 29 (91%) erano in terapia con inclisiran e statina±ezetimibe. Valutando la distribuzione della riduzione percentuale dei valori di colesterolo LDL emergeva una eterogeneità in parte spiegabile dalla terapia ipolipemizzante concomitante ed in parte dalla precedente esposizione ad inibitori di PCSK9 (Figura).
Conclusioni. Questi dati preliminari supportano l'utilizzo di inclisiran e mostrano una riduzione efficace dei valori di colesterolo LDL nel Real-World. Il target di colesterolo LDL è stato raggiunto nel 62% dei pazienti, ma di questi il 91% era in terapia ipolipemizzante, mostrando come la terapia di combinazione sia necessaria nella maggior parte di questi pazienti e come l'utilizzo di inclisiran non dovrebbe determinare l'interruzione o la riduzione della terapia ipolipemizzante concomitante.

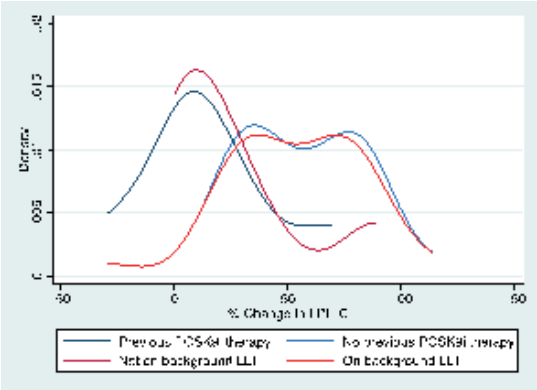

A591: LIPID MANAGEMENT IN PATIENTS AT HIGH AND VERY HIGH CARDIOVASCULAR RISK: EVIDENCE FROM ROUTINE CLINICAL PRACTICE IN ITALY (SANTORINI STUDY - THE ITALIAN COHORT)

Marcello Arca (a), Paolo Calabrò (b), Anna Solini (c),
Rosanna Gambacurta (d), Kausik K Ray (e), Alberico L Catapano (f)
(a) DEPARTMENT OF TRANSLATIONAL AND PRECISION MEDICINE, 'SAPIENZA', UNIVERSITY OF ROME_ROME_ITALY; (b) DIVISION OF CARDIOLOGY OF SANT'ANNA AND SAN SEBASTIANO HOSPITAL, UNIVERISTY OF CAMPANIA 'LUIGI VANVITELLI'_CASERTA_ITALY; (c) UNIVERSITY OF PISA SCHOOL OF MEDICINE_PISA_ITALY; (d) DAIICHI SANKYO ITALY, MEDICAL AFFAIRS_ROME_ITALY; (e) IMPERIAL COLLEGE LONDON, IMPERIAL CENTRE FOR CARDIOVASCULAR DISEASE PREVENTION_LONDON_UNITED KINGDOM OF GREAT BRETAIN & NORTHERN IRELAND; (f) UNIVERSITY OF MILAN, DEPARTMENT OF PHARMACOLOGICAL AND BIOMOLECULAR SCIENCES_MILAN_ITALY

Background. The SANTORINI study is the first since the 2019 ESC/EAS lipid guidelines which investigates how lipid management has evolved in clinical practice after lower LDL-C goal recommendations.
Methods. SANTORINI is a multinational, prospective, observational, European study (NCT04271280) conducted between March 2020 and February 2021 with a 1-year follow-up, assessing contemporary approaches to lipid management in patients at high and very high-cardiovascular (CV) risk. In this abstract, we report data on the Italian cohort.
Results. Of the 1977 patients at high and very high CV risk enrolled at a total of 125 sites in Italy, LDL-C and goal attainment was assessed in 1850 patients with LDL-C values available at both baseline and 1-year follow-up. The investigators classified 1414 (76.4%) patients as very high CV risk and 436 (23.6%) as high CV risk. At follow-up, LDL-C was reduced in both risk groups versus baseline (overall: 73.1 vs 97.9 mg/dL; high risk: 89.1 vs 110.1 mg/dL; very high risk: 68.2 vs 94.2 mg/dL). More patients reached LDL-C goals at follow-up vs baseline (high risk: 31.0% vs 22.3%, very high risk: 36.2% vs 20.4%; Table 1). The use of combination therapies increased at follow-up compared to baseline in the overall population, and in both risk categories (overall: 55.5% vs 33.8%; high risk: 48.0% vs 34.1%; very high risk: 57.7% vs 33.7%).
Conclusions. The SANTORINI study suggests that the use of combination therapies in Italian clinical practice has increased over study period. However, a majority of these patients are still far from reaching their LDL-C targets. To achieve recommended LDL-C targets, an intensified lipid lowering therapy including increased use of combination therapy should be considered.

Table 1. LDL-C levels and proportion of patients at LDL-C goal

	Overall (N=1850)		High risk (N=436)		Very high risk (N=1414)	
	Baseline	1-year follow-up	Baseline	1-year follow-up	Baseline	1-year follow-up
LDL-C, mg/dL, mean (SD)	97.9 (49.5)	73.1 (35.1)	110.1 (54.6)	89.1 (40.1)	94.2 (46.9)	68.2 (31.9)
Patients at LDL-C goal, %	21.9	44.9	22.3	33.9	20.4	36.1

LDL-C, low-density lipoprotein cholesterol.

A592: IMPACT OF ADHERENCE TO BETA-BLOCKERS AFTER ST-SEGMENT ELEVATION MYOCARDIAL INFARCTION (STEMI): RESULTS FROM THE REAL-WORLD REGIONAL REGISTRY FAST-STEMI

Giuseppe Giannino (a), Federico Giacobbe (a), Ovidio De Filippo (a), Umberto Di Vita (a), Francesco Bruno (a), Marco Nebiolo (a), Mattia Troncone (a), Umberto Annone (b), Arianna Morena (a), Ludovica Carmagnola (a), Filippo Angelini (a), Gaetano Maria De Ferrari (a), Fabrizio D´ascenzo (a)
(a) DEPARTMENT OF MEDICAL SCIENCES, UNIVERSITY OF TURIN, TURIN, ITALY; DIVISION OF CARDIOLOGY, CARDIOVASCULAR AND THORACIC DEPARTMENT, CITTA DELLA SALUTE E DELLA SCIENZA, TURIN, ITALY; (b) CIVIC HOSPITAL OF CIRIE, CIRIE, ITALY

Background. Beta-blockers are a crucial part of post-myocardial infarction (MI) pharmacological therapy. Recent studies have raised questions about their efficacy in patients without reduced left ventricular ejection fraction (LVEF). This study aims to assess adherence to beta-blockers after discharge for ST-segment elevation myocardial infarction (STEMI), predictors of poor adherence, and the impact of adherence on outcomes based on LVEF at discharge.
Methods. The retrospective registry, FAST-STEMI, evaluated real-world adherence to cardiovascular drugs, including beta-blockers, in STEMI patients discharged between 2012 and 2017. Adherence was measured by comparing purchased tablets to expected tablets over one year. Optimal adherence was defined as ≥80%. Predictors of poor adherence were assessed using logistic regression. Primary outcomes included all-cause and cardiovascular death, while secondary outcomes were myocardial infarction, major/minor bleeding events, and ischemic stroke. Impact on outcomes was analyzed using Cox multivariate analysis.
Results. The study included 4688 STEMI patients discharged on beta-blockers. Mean age was 64 ± 12.3 years, 76% were male, and mean LVEF was 49.2 ± 8.8%. Mean adherence at one year was 87.1%. Optimal adherence was associated with lower all-cause (adj HR 0.62, 95%CI 0.41-0.92, p 0.02) and cardiovascular mortality (adj HR 0.55, 95%CI 0.26-0.98, p 0.043). In LVEF <=40% patients, optimal adherence was linked to reduced cardiovascular mortality (adj HR 0.30, 95%CI 0.13-0.69, p 0.005) and all-cause mortality (adj HR 0.53, 95%CI 0.30-0.92, p 0.03). Predictors of cardiovascular mortality included older age, chronic kidney disease, male gender, and atrial fibrillation.
Conclusions. Optimal adherence to beta-blockers is associated with improved survival among STEMI patients with LVEF <=40%. This analysis offers valuable insights into the population on which health policies must be maximally focused to increase patient adherence.

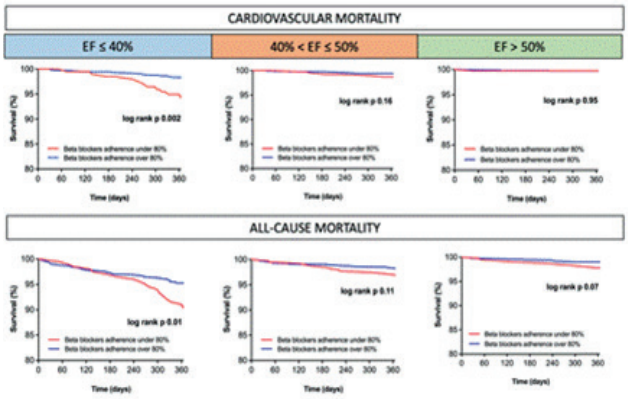

Figure 1. Kaplan-Meier curves and p-value for 1-year primary endopoints according to beta-blockers adherence in different LVEF classes.

A593: LONG-TERM EFFECTS OF MAVACAMTEN TREATMENT IN OBSTRUCTIVE HYPERTROPHIC CARDIOMYOPATHY (HCM): UPDATED CUMULATIVE ANALYSIS OF THE EXPLORER COHORT OF MAVA-LONG-TERM EXTENSION (LTE) STUDY UP TO 120 WEEKS

Pablo Garcia-Pavia (a), Artur Oreziak (b), Ahmad Masri (c), Roberto Barriales-Villa (d), Theodore Abraham (e), Anjali Owens (o), Neal Lakdawala (g), Sara Saberi (h), Andrew Wang (i), Matthew Wheeler (j), Lubna Choudhury (k), Ganesh Balaratnam (l), Shawna Fox (m), Sheila Hegde (g), Iacopo Olivotto (n)
(a) HOSPITAL UNIVERSITARIO PUERTA DE HIERRO AND CNIC, MADRID, SPAIN; (b) NATIONAL INSTITUTE OF CARDIOLOGY, WARSAW, POLAND; (c) OREGON HEALTH & SCIENCE UNIVERSITY, PORTLAND, OR, USA; (d) COMPLEXO HOSPITALARIO UNIVERSITARIO DE A CORUNA, A CORUNA, SPAIN; (e) UNIVERSITY OF CALIFORNIA SAN FRANCISCO, SAN FRANCISCO, CA, USA; (f) UNIVERSITY OF PENNSYLVANIA, PEREMAN SCHOOL OF MEDICINE, PHILADELPHIA, PA, USA; (g) BRIGHAM & WOMEN'S HOSPITAL, BOSTON, MA, USA; (h) UNIVERSITY OF MICHIGAN, ANN ARBOR, MI, USA; (i) DUKE UNIVERSITY, DURHAM, NC, USA; (j) STANFORD UNIVERSITY SCHOOL OF MEDICINE, STANFORD, CA, USA; (k) NORTHWESTERN UNIVERSITY, FEINBERG SCHOOL OF MEDICINE, CHICAGO, IL, USA; (l) BRISTOL MYERS SQUIBB, PRINCETON, NJ, USA; (m) IQVIA, DURHAM, NC, USA; (n) MEYER CHILDREN'S HOSPITAL IRCCS, UNIVERSITY OF FLORENCE, FLORENCE, ITALY; (o) UNIVERSITY OF PENNSYLVANIA, PERELMAN SCHOOL OF MEDICINE, PHILADELPHIA, PA, USA

Introduction. Mavacamten was efficacious and well tolerated in patients with obstructive HCM over a median follow-up of 62 weeks in a previous interim analysis of the ongoing MAVA-LTE study (NCT03723655) (data cut-off; August 31, 2021). Here, we report an updated cumulative analysis of the EXPLORER cohort of MAVA-LTE up to 120 weeks.
Methods. Patients who completed EXPLORER-HCM (NCT03470545) could enroll in MAVA-LTE. All patients initiated the study with mavacamten 5 mg/day per protocol; dose adjustments to 2.5, 10, or 15 mg were based on site-read Valsalva left ventricular outflow tract (LVOT) gradient and LV ejection fraction (LVEF).
Results. In total, 231 patients (median age, 61 years; 39% female) enrolled in the EXPLORER cohort of MAVA-LTE. Median time on study was 101 weeks at data cut-off (May 31, 2022) with variations due to differences in enrollment timing. At data cut-off, 215 patients remained on treatment (total adjusted exposure: 475 patient-years). Mavacamten dosing of patients who reached week 120 (n=80) was: 2.5 mg (27.5%); 5 mg (31.3%); 10 mg (26.3%); 15 mg (12.5%). Between weeks 48–120, 34 of 231 (14.7%) patients underwent dose adjustments. Mavacamten treatment showed sustained improvements in mean [SD] change from baseline to week 120 in LVOT gradients (resting, –35.3 [33.0] mmHg; Valsalva, –47.0 [37.3] mmHg), left atrial volume index (–8.5 [10.3] mL/m^2) and E/e' average (–3.9 [5.0]). At week 120, 83.5% of patients had a Valsalva LVOT gradient ≤30 mmHg. Mavacamten was associated with sustained reduction from baseline to week 120 in median (interquartile range) N-terminal pro B-type natriuretic peptide (NT-proBNP) level (458 [1104, 166] ng/L); 75.9% of patients improved by ≥1 class New York Heart Association class. Mean (SD) LVEF decreased by 9.1% (7.1) from baseline to week 120 but remained within normal range. Since the previous interim analysis (data cut-off: August 31, 2021), 1 additional transient reduction in LVEF <50% occurred resulting in temporary treatment interruption (a total of 13 patients [5.6%] experienced LVEF <50% from study initiation). The patient resumed treatment at a lower dose 4 weeks after the event. In total, 74 serious adverse events (SAE) were reported in 47 patients (20.3%). There were 18 new SAEs and 13 additional patients (5.6%) with SAEs since the previous interim analysis, including 1 new SAE (atrial fibrillation) considered drug related by the principal investigator. No new safety signals were identified. One additional death (leading to a total of 4) occurred, due to intracranial hemorrhage. Like the previous 3 deaths (due to acute myocardial infarction, cardiac arrest, and bacterial endocarditis) the event was considered unrelated to the study drug by the principal investigator.
Conclusions. Long-term mavacamten treatment up to 120 weeks showed sustained improvements in LVOT obstruction, symptoms, and NT-proBNP levels in patients with symptomatic obstructive HCM consistent with the findings of the parent study. Mavacamten treatment continues to be well tolerated.

A594: THE PROTECTIVE EFFECT OF BERGAMOT POLYPHENOLIC FRACTION ON RENO-CARDIAC DAMAGE INDUCED BY DOCA-SALT AND UNILATERAL RENAL ARTERY LIGATION IN RATS

Cristina Carresi (a), Antonio Cardamone (a), Anna Rita Coppoletta (a), Rosamaria Caminiti (a), Roberta Macrì (a), Rocco Mollace (a, c), Lorenza Guarnieri (a), Stefano Ruga (a), Saverio Nucera (a), Vincenzo Musolino (b), Micaela Gliozzi (a), Ernesto Palma (a), Carolina Muscoli (a), Maurizio Volterrani (d), Vincenzo Mollace (a)
(a) PHARMACOLOGY LABORATORY, INSTITUTE OF RESEARCH FOR FOOD SAFETY AND HEALTH (IRC-FSH), DEPARTMENT OF HEALTH SCIENCES, UNIVERSITY "MAGNA GRAECIA" OF CATANZARO, ITALY; (b) PHARMACEUTICAL BIOLOGY LABORATORY, INSTITUTE OF RESEARCH FOR FOOD SAFETY AND HEALTH (IRC-FSH), DEPARTMENT OF HEALTH SCIENCES, UNIVERSITY "MAGNA GRAECIA" OF CATANZARO, ITALY; (c) DEPARTMENT OF SYSTEMS MEDICINE UNIVERSITY TOR VERGATA OF ROME, ITALY; (d) DEPARTMENT OF CARDIOLOGY, IRCCS SAN RAFFAELE PISANA, ROME, ITALY

To date, the complex pathological interactions between renal and cardiovascular systems represent a real global epidemic in both developed and developing countries. In this context, renovascular hypertension (RVH) remains among the most prevalent, but also potentially reversible, risk factor for numerous reno-cardiac diseases in humans and pets. Here, we investigated the anti-inflammatory and reno-cardiac protective effects of a polyphenol-rich fraction of citrus bergamot (BPF) in an experimental model of hypertension induced by unilateral renal artery ligation. Adult male Wistar rats underwent unilateral renal artery ligation and treatment with deoxycorticosterone acetate (DOCA) (20 mg/kg, s.c.), twice a week for a period of 4 weeks, and 1% sodium chloride (NaCl) water (n=10). A subgroup of hypertensive rats received BPF (100 mg/kg/day for 28 consecutive days, n=10) by gavage. Another group of animals was treated with a sub-cutaneous injection of vehicle (that served as control, n=8). Unilateral renal artery ligation followed by treatment with DOCA and 1% NaCl water resulted in a significant increase in mean arterial blood pressure (MAP) which strongly increased the resistive index (RI) of contralateral renal artery flow and kidney volume after 4 weeks. Renal dysfunction also led to a dysfunction of cardiac tissue strain associated with overt dyssynchrony in cardiac wall motion. Interestingly, this pathological condition is prevented by BPF treatment. The reno-cardiac protective effect of BPF was associated with a significant reduction in serum level of some pro-inflammatory cytokines and chemokines restoring physiological levels of renal neutrophil gelatinase-associated lipocalin (NGAL) protein of the tethered kidney. In conclusion, the present results show, for the first time, that BPF promotes an efficient renovascular protection preventing the progression of inflammation and reno-cardiac damage. Overall, these data point to a potential clinical and veterinary role of dietary supplementation with the polyphenol-rich fraction of citrus bergamot in counteracting hypertension-induced reno-cardiac syndrome.

A595: IMPACT OF STATIN ADHERENCE AND INTERRUPTION WITHIN 6 MONTHS AFTER ST-SEGMENT ELEVATION MYOCARDIAL INFARCTION (STEMI): RESULTS FROM THE REAL-WORLD REGIONAL REGISTRY FAST-STEMI

Umberto Di Vita (a), Federico Giacobbe (a), Ludovica Carmagnola (a), Arianna Morena (a), Fabrizio D'Ascenzo (a), Umberto Annone (b), Ovidio De Filippo (a), Giuseppe Giannino (a), Mattia Troncone (a), Emanuele Ravetti (a), Marco Nebiolo (a), Gaeteno Maria De Ferrari (a)
(a) DIVISION OF CARDIOLOGY, DEPARTMENT OF MEDICAL SCIENCES, UNIVERSITY OF TURIN; (b) CIVIC HOSPITAL OF CIRIE', CIRIE', ITALY

Background. The impact of statin therapy on cardiovascular outcomes after ST-elevation acute myocardial infarction (STEMI) in real- world patients is understudied.
Aims. To identify predictors of low adherence and discontinuation to statin therapy within 6 months after STEMI and to estimate their impact on cardiovascular outcomes at one year follow-up.
Methods. We evaluated real-world adherence to statin therapy by comparing the number of bought tablets to the expected ones at 1 year follow-up through pharmacy registries. A total of 6043 STEMI patients admitted from 2012 to 2017 were enrolled in the FAST STEMI registry and followed up for 4,7±1,6 years; 304 patients with intraprocedural and intrahospital deaths were excluded. The main outcomes evaluated were all-cause death, cardiovascular death, myocardial infarction, major and minor bleeding events, and ischemic stroke. The compliance cut-off chosen was 80% as mainly reported in literature.

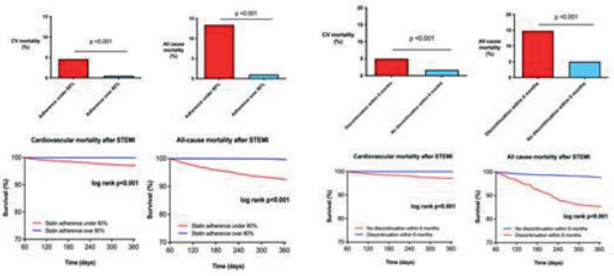

Results. From a total of 5744 patients, 418 (7,2%) patients interrupted statin therapy within 6 months after STEMI, whereas 3337 (58,1%) presented>80% adherence to statin therapy. Statin low adherence (<80%) resulted as predictor of both cardiovascular (0.1% vs 4.6%; AdjHR 0.025, 95%CI 0.008-0.079, p<0.001) and all-cause mortality (0.3% vs 13.4%; Adj HR 0.032, 95%CI 0.018-0.059, p<0.001) at 1 year follow-up. Further, a significant reduction of ischemic stroke incidence (1% vs 2.5%, p=0.001) was seen in the optimal adherent group. Statin discontinuation within 6 months after STEMI showed an increase of both cardiovascular (5% vs 1.7%; HR 2.23; 95%CI 1.37-3.65; p=0,001) and all-cause mortality (14.8% vs 5.1%, HR 2.32; 95%CI 1.73-3.11; p<0,001) at 1 year follow-up. After multivariate analysis age over 75 years old, known ischemic cardiopathy

and female gender resulted as predictors of therapy discontinuation. Age over 75 years old, chronic kidney disease, previous atrial fibrillation, vasculopathy, known ischemic cardiopathy were found to be predictors of low statin adherence.
Conclusions. In our real-world registry low statin adherence and discontinuation therapy within 6 months after STEMI were independently associated to an increase of cardiovascular and all-cause mortality at 1 year follow-up. Low statin adherence led to higher rates of ischemic stroke.

A596: CLINICAL OUTCOMES OF PATIENTS WITH REVASCULARISED PERIPHERAL ARTERY DISEASE: FINAL RESULTS OF THE RAPID STUDY

Antonio Greco (a), Claudio Laudani (a), Matteo Cavallo (a),
Antonio Bulla (a), Giuseppe Sangiorgio (a), Alessia Giaquinta (a),
Piera Capranzano (a), Valeria Calvi (a), Gaetano Isola (a),
Eugenio Pedullà (a), Rocco De Pasquale (a),
Maurizio Giacinto Uva (a), Antonio Di Cataldo (a),
Pierfrancesco Veroux (a), Corrado Tamburino (a), Davide Capodanno (a)
(a) UNIVERSITÀ DEGLI STUDI DI CATANIA

Background. Based on the VOYAGER PAD trial, patients with revascularized peripheral artery disease (PAD) can be eligible to dual pathway inhibition (DPI) with aspirin and low dose rivaroxaban. However, whether the eligibility to DPI is associated with clinical outcomes in this population remains unknown.
Aims. To assess the association of eligibility to DPI and clinical outcomes among contemporary patients hospitalised in the vascular surgery unit, and to explore predictors of adverse events in this population.
Methods. We analysed data from patients with revascularised PAD included in the prospective institutional RAPID (RivAroxaban for PerIpheral artery Disease) and applied the VOYAGER PAD criteria to identify patients eligible to DPI. Clinical outcomes were compared between patients eligible and not eligible to DPI. The primary efficacy outcome was the composite of cardiovascular death, acute limb ischemia, or unplanned limb revascularization, while the primary safety outcome was major bleeding according to the Bleeding Academic Research Consortium definition (i.e., type 3 or 5). Secondary outcomes included the individual components of the primary efficacy outcome, all-cause death, major adverse cardiovascular events (MACE) and net adverse cardiovascular events (NACE). In addition, a multivariable regression analysis was used to account for confounding factors and identify independent predictors of clinical outcomes.
Results. From May 2021 to May 2023, 196 patients (mean age 70.8±10.1 years, 75.5% male) were included in the RAPID registry. Based on VOYAGER PAD eligibility criteria, 98 patients (50.0%) were eligible to DPI. The median follow-up was 295 days (interquartile range 155-457 days). Patients not eligible to DPI had significantly higher rates of primary efficacy outcome, primary safety outcome, all-cause death, cardiovascular death, MACE and NACE. After adjustment for confounders, there were no between-group differences in the rates of the primary efficacy outcome (adjusted odds ratio [adjOR] 0.99, 95% confidence interval [CI] 0.31-3.18, p=0.99), primary safety outcome (adjOR 0.49, 95% CI 0.01-2.60, p=0.26), all-cause death (adjOR 0.79, 95% CI 0.19-3.06, p=0.73), cardiovascular death (adjOR 1.13, 95% CI 0.11-10.14, p=0.91), MACE (adjOR 0.78, 95% CI 0.24-2.51, p=0.67) and NACE (adjOR 0.54, 95% CI 0.18-1.60, p=0.27). However, atrial fibrillation emerged as an independent predictor of the primary efficacy outcome (adjOR 5.89), all-cause death (adjOR 5.83), cardiovascular death (adjOR 9.51), MACE (adjOR 1.75) and NACE (adjOR 1.63).
Conclusions. Adverse events occurred more frequently among patients with revascularised PAD not eligible to DPI than in those fulfilling the VOYAGER PAD criteria. However, this was due to a higher risk profile, and being eligible to DPI was not significantly associated with any difference in clinical outcomes after adjustment for confounding factors. According to these results, candidates to DPI have a lower risk profile than those who are not eligible, who present with additional risk factors representing exclusion criteria in VOYAGER PAD. Whether DPI would be associated with net benefit in this latter subgroup remains uncertain and warrants further investigation.

A597: EFFECTS OF PCSK-9 INHIBITORS ON ARTERIAL STRUCTURE AND FUNCTION: PRELIMINARY RESULTS

Alessandro Maloberti (a, b), Giorgio Toscani (b), Alessandro Vatta (b),
Rita Cristina Myriam Intravaia (a), Chiara Tognola (a, b),
Michela Algeri (a), Andrea Busti (b), Ilaria Garofani (a),
Martina Morelli (a), Valentina Giani (a), Matteo Fortuna (a),
Cristina Giannattasio (a, b)
(a) CARDIOLOGY IV - "DE GASPERIS" DEPARTMENT, NIGUARDA CA' GRANDA HOSPITAL, MILAN ITALY; (b) SCHOOL OF MEDICINE AND SURGERY, MILANO-BICOCCA UNIVERSITY, MILAN ITALY

Background. one of the latest chapters in the research for new and stronger lipid lowering therapies has led to the development of PCSK9 inhibitors. In addition to the benefit on lipid profile, a limited number of studies have been published showing a possible improvement in vascular function and structure following their administration.
Purpose. To evaluate the effects of PCSK9 inhibitors on structural (via carotid Intima Media Thickness – IMT) and functional (carotid-femoral Pulse Wave Velocity – cf-PWV - and brachial artery Flow Mediated Dilatation - FMD) arterial properties.
Methods. Twenty-two dyslipidemic patients with a clinical indication to PSCK9 inhibitors were prospectively recruited at the Cardiology Rehabilitation of ASST Grande Ospedale Metropolitano Niguarda Hospital (Milan, Italy). Anthropometric, clinical and therapeutic data were recorded. Each patient underwent instrumental examinations to assess cf-PWV, IMT and FMD at T0 (before the start of therapy), T1 (after 6 months) and T2 (after 12 months).
Results. in the 22 patients who reached 6 months of follow up there was a significant reduction in LDL cholesterol (from 127.8±31.7 to 47.4±29.1 mg/dl, p<0. 0001) while there was no significant difference in arterial parameters (cf-PWV: from 10.5±3.5 to 9.4±2.3 m/s, p=0.092; FMD: from 11.4±8.1 to 9.8±8.3%, p=0.407; IMT: from 775.6±192.8 to 768.7±144.7, microm, p=0.854). Similar results were also obtained in the 12 patients who reached one year of follow-up: LDL from 129.4±29.1 to 48.8±21.9 mg/dl, p<0.0001; cf-PWV from 10.4±3.3 to 10.5±2.9, p=0.874; FMD from 12.0±9.1 to 11.0±5.6%, p=0.930; IMT from 745.1±203.9 to 770.0±127.3 microm, p=0.710.
Conclusions. Our study confirm the strong LDL reduction with PCSK9 inhibitors that are needed in order to reach the targets set by the ESC 2019 guidelines. In contrast, they do not show a significant effect on arterial function and structure in terms of cf-PWV, FMD and carotid IMT.

A598: EFFICACIA DELLA TERAPIA CON TAFAMIDIS IN PAZIENTI CON AMILOIDOSI CARDIACA DA TRANSTIRETINA: VALUTAZIONE DEI PARAMETRI CLINICO-STRUMENTALI E BIOUMORALI A 6 MESI DALL'INIZIO DEL TRATTAMENTO

Giulia Marchionni (a), Silvia Stavagna (a), Jacopo Costantino (a),
Federico Ballatore (a), Antonio Lattanzio (a), Maria Alfarano (a),
Carmine Dario Vizza (a), Cristina Chimenti (a)
(a) DIPARTIMENTO DI SCIENZE CLINICHE INTERNISTICHE, ANESTESIOLOGICHE E CARDIOVASCOLARI UNIVERSITÀ LA SAPIENZA ROMA

Introduzione. La creazione di un algoritmo diagnostico non invasivo per l'amiloidosi cardiaca da transtiretina (ATTR-CA) e l'introduzione di terapie specifiche disease-modifying hanno portato un grandissimo interesse della ricerca in questo ambito: tuttavia, ad oggi nessuno studio scientifico ha mai valutato l'efficacia della terapia con Tafamidis nello stabilizzare il fenotipo ATTR-CA con un follow up a breve termine, al fine di stabilire la rapidità di azione del farmaco. Questo studio si configura quindi come uno studio pilota retrospettivo in pazienti con ATTR-CA in terapia con Tafamidis.
Obiettivi. L'endopoint primario dello studio ha l'obiettivo di dimostrare l'efficacia del farmaco nello stabilizzare la patologia ad un follow up di sei mesi dall'inizio della terapia. Gli endpoints secondari sono la valutazione dell'efficacia del Tafamidis ad un follow up di dodici mesi e dell'eventuale miglioramento della qualità della vita e della tolleranza allo sforzo fisico, sia a sei che a dodici mesi.
Materiali e metodi. Lo studio è stato condotto su 32 pazienti affetti da ATTR-CA, sia wild type (età media 80±9 anni) che ereditaria (età media 61±12 anni), con età maggiore di 18 anni ed in terapia con Tafamidis. Tra questi, sono stati valutati 22 pazienti in quanto rispettavano i criteri di inclusione e presentano un follow up a sei mesi. Per la valutazione dell'efficacia del farmaco sono state utilizzate nove variabili: classe NYHA, Kansas City Cardiomyopathy Questionnaire (KCCQ), six minute walking test (6MWT) e parametri umorali (NT-proBNP e Troponina T), ecocardiografici (spessore del SIV, FE e TAPSE) e prognostici (Columbia Score). Queste variabili sono state valutate al basale, a 6 mesi e a 12 mesi, e confrontate con i test statistici appropriati a seconda del tipo di variabile analizzata.
Risultati. I risultati ottenuti nella popolazione in esame hanno dimostrato come l'efficacia del Tafamidis nel bloccare la progressione della malattia sia apprezzabile già dopo pochi mesi dall'inizio della terapia: dopo sei mesi dall'inizio del farmaco tutte le variabili sono rimaste costanti, al contrario di quello che avverrebbe nella storia naturale della patologia. Questo beneficio clinico e strumentale è stato mantenuto anche a dodici mesi, in cui i parametri considerati risultano essere ancora stabili, sebbene in questo caso non sia stata raggiunta la significatività statistica a causa della ridotta numerosità del campione. In tutti questi pazienti, inoltre, il farmaco ha determinato un miglioramento della qualità della vita, intesa come percezione soggettiva del paziente (KCCQ) e della tolleranza allo sforzo (valutata mediante 6MWT), sia a sei che a dodici mesi di follow up.
Conclusioni. La straordinaria efficacia del Tafamidis nello stabilizzare i fenotipi di ATTR-CA ha reso questo farmaco una delle armi principali per bloccare la progressione di questa malattia e per migliorare la prognosi di questi pazienti. Questo studio ha dimostrato che i benefici di questo trattamento sono visibili già ad un follow up di 6 mesi, con stabilità dei parametri laboratoristici e strumentali e un miglioramento della qualità della vita e della tolleranza allo sforzo di tutti i pazienti, sia a sei che a dodici mesi.

A599: STATIN THERAPY AND OUTCOME IN TAKOTSUBO SYNDROME PATIENTS: RESULTS FROM THE MULTICENTER INTERNATIONAL GEIST REGISTRY

Giuseppina Novo (a), Chiara Alaimo (a), Luca Arcari (b), Thomas Stiermaier (i), Ibrahim El-battrawy (j), Luca Caciotti (c), Federico Guerra (d), Maria Beatrice Musumeci (b), Enrica Mariano (e), Giuseppe Parisi (h), Roberta Montisci (g), Ravi Vazirani (k), Alberto Perez Castellanos (l), Aitor Uribarri (m), Miguel Corbi-pascual (n), Jorge Salamanca (o), Ibrahim Akin (j), Holger Thiele (p), Natale Daniele Brunetti (f), Ingo Eitel (i), Iván J Núñez Gil (k), Francesco Santoro (f)

(a) DEPARTMENT OF HEALTH PROMOTION, MOTHER AND CHILD CARE, INTERNAL MEDICINE AND MEDICAL SPECIALTIES (PROMISE), UNIVERSITY OF PALERMO, ITALY; (b) DEPARTMENT OF CARDIOLOGY, SAPIENZA UNIVERSITY, ROME, ITALY; (c) INSTITUTE OF CARDIOLOGY, MADRE GIUSEPPINA VANNINI HOSPITAL, ROME, ITALY; (d) CARDIOLOGY AND ARRHYTHMOLOGY CLINIC, MARCHE POLYTECHNIC UNIVERSITY, ANCONA, ITALY; (e) DIVISION OF CARDIOLOGY, UNIVERSITY OF ROME TOR VERGATA, ROME, ITALY; (f) DEPARTMENT OF MEDICAL AND SURGICAL SCIENCES, UNIVERSITY OF FOGGIA, FOGGIA, ITALY; (g) SAN GIOVANNI DI DIO HOSPITAL, UNIVERSITY OF CAGLIARI, CAGLIARI, ITALY; (h) DEPARTMENT OF CARDIOLOGY, SAN PAOLO HOSPITAL, BARI, ITALY; (i) UNIVERSITY HEART CENTER LUBECK; (j) UNIVERSITY MEDICAL CENTRE MANNHEIM; (k) HOSPITAL CLINICO UNIVERSITARIO SAN CARLOS; (l) HOSPITAL UNIVESITARI SON ESPASES; (m) HOSPITAL UNIVERSITARI VALL D'HEBRON; (n) HOSPITAL UNIVERSITARIO DE ALBACETE; (o) HOSPITAL UNIVERSITARIO DE LA PRINCESA; (p) HEART CENTER LEIPZIG AT UNIVERSITY OF LEIPZIG

Background. Several studies have shown that endothelial dysfunction plays a role in the pathogenesis of Takotsubo syndrome (TTS). Given the potential benefit of statin therapy on endothelial dysfunction, we hypothesized that such treatment could improve long-term outcomes. Aim of our study was to evaluate clinical characteristics and long-term outcome of TTS patients treated with statin therapy.

Methods. Patients were enrolled in the international multicenter GEIST (GErman Italian Spanish Takotsubo) registry. Demographic data, clinical features and drug therapy at discharge were recorded. The primary study outcome was the occurrence of all-cause death at long-term follow-up.

Results. The study population included 2429 consecutive TTS patients: 1293 (53.2%) discharged on statin and 1136 (46.8%) without statin. Patients with statin were older (age 72±11 vs 69±13 years, p<0.001), with higher prevalence of hypertension (74.3% vs 60.3%, p<0.001), diabetes (21.1% vs 14.7%, p<0.001), dyslipidemia (56.1% vs 23.3%, p<0.001), history of coronary artery disease (13.3% vs 6.3%, p<0.001) and lower rates of in-hospital complications (14.7% vs 19.3%, p=0.003). Survival analysis showed similar mortality rates between groups (log-rank p=0.803). At univariable analysis, statin therapy at discharge was not associated with lower mortality (HR: 0.97, 95% CI 0.74-1.26, p=0.803). At multivariable analysis age (HR: 1.06 95%CI 1.04-1.08, p<0.001), male sex (HR: 1.83, 95% CI 1.20-2.80, p=0.005), diabetes (HR: 2.55, 95%CI 1.83-3.54 p<0.001), malignancies (HR: 2.41, 95%CI 1.68-3.44, p<0.001) and physical trigger (HR: 2.24, 95%CI 1.62-3.10, p<0.001) were associated with increased mortality.

Conclusions. Statin therapy after a TTS event was not associated with improved long-term prognosis.

A600: OUTCOME DEL TRATTAMENTO CON PCSK9-I IN PAZIENTI AD ELEVATO RISCHIO CV: RISULTATI A 12 SETTIMANE DAL REGISTRO REALIST

Giulia Pugliese (a), Fiorella Puttini (a), Emanuele Maria Renga (a), Federica Rinallo (a), Francesco Candido (a), Massimo Russo (a), Mihaela Ifrim (a), Saverio Muscoli (a), Francesco Barillà (a)

(a) U.O.C. CARDIOLOGIA POLICLINICO "TOR VERGATA"

Introduzione. L'ipercolesterolemia è uno dei principali fattori di rischio cardiovascolare ed il controllo dei livelli delle lipoproteine a bassa intensità (LDL) è uno dei principali obiettivi sia in prevenzione primaria sia in prevenzione secondaria. I PCSK9-i rappresentano la terapia farmacologica cardine in pazienti ad alto e molto alto rischio cardiovascolare (CV), con malattia aterosclerotica, in pazienti con ipercolesterolemia familiare che non raggiungono il target di LDL-c con dosaggio massimale di statine ad alta intensità ed in pazienti con intolleranza documentata alle statine.

Materiali e metodi. studio monocentrico, retrospettivo, osservazionale. Sono stati analizzati dal registro REALIST 150 pazienti ad elevato rischio CV con età>di 18 anni ed <di 80 anni, 102 uomini e 48 donne, età media 64.28 anni. 85% dei quali affetto da ipertensione arteriosa essenziale (IA), 29% affetti da diabete mellito di tipo 2 (DM2) ed il 63% con abitudine tabagica. Il 28% rientrava nel protocollo "fast track", il 20% risultava essere intollerante alle statine ed il 52% seguiva terapia ipolipemizzante come da linee guida ESC 2019. Di questi 150 pazienti il 77% era in terapia con PCSK9-i + statine+ ezetimibe, il 23% con PCSK9-i + ezetimibe vs pazienti in terapia con statine ad alta intensità (atorvastatina 80 mg). I pazienti che assumevano PCSK9-i sono stati divisi a loro volta in 3 sottogruppi in base al dosaggio dell'anticorpo monoclonale: il 50% assumeva Evolocumab 140 mg, il 45% Alirocumab 150 mg ed il 5% Alirocumab 75 mg. È stato valutato l'assetto lipidico completo ed è stata calcolata la variazione in termini percentuali e la deviazione standard. È stato eseguito il t- test di Student per valutare la significatività di ciascuna variabile.

Risultati.È stato valutato l'assetto lipidico al baseline e dopo 12 settimane di trattamento. I pazienti a cui era stato somministrato PCSK9-i + ezetimibe + statine hanno raggiunto una riduzione di LDL-c del 60% (SD +- 22.8), i pazienti a cui era stato somministato PCSK9-i + ezetimibe una riduzione di LDL-c del 41%(SD +- 19,78) rispetto ad una riduzione del 33-5% (SD +- 12.3) di LDL-c in pazienti con atorvastatina 80 mg. In particolare si è evinto che entrambi gli anticorpi monoclonale abbattono i valori di LDL- c in maniera significativa (p<0,001): alirocumab 150 mg determina una riduzione del 55% vs Evolocumab 140 mg che determina una riduzione del 60%, Non ci sono state invece sostanziali differenze di riduzione di LDL-c tra alirocumab 150 mg ed alirocumab 75 mg (p>0.001).

Conclusioni. La terapia con PCSK9-i è efficace nel raggiungimento dei valori di LDL-c. Deve essere sempre valutata l'associazione con ezetimibe e le statine ad altra intensità (rosuvastatina o atorvastatina) qualora i target non dovessero essere raggiunti. I due anticorpi monoclonali evidenziano ottima tollerabilità ed aderenza terapeutica da parte del paziente. La scelta tra i due è stabilita dal personale medico in base alle caratteristiche cliniche del paziente.

A601: DIETARY HABITS AND RISK OF CARDIAC ARRHYTHMIAS: A LITERATURE REVIEW

Michele Antonelli (b), Davide Donelli (a), Davide Lazzeroni (c), Valentina Ziveri (c), Giampaolo Niccoli (a), Diego Ardissino (a)

(a) CARDIOLOGY DIVISION, PARMA UNIVERSITY HOSPITAL, PARMA, ITALY; (b) DEPARTMENT OF PUBLIC HEALTH, AUSL-IRCCS REGGIO EMILIA, REGGIO EMILIA, ITALY; (c) PREVENTION AND REHABILITATION UNIT, IRCCS FONDAZIONE DON GNOCCHI, PARMA, ITALY

Introduction. Specific changes in dietary habits have been associated with an increased risk of cardiac arrhythmias. However, the mechanisms through which nutrition influences an individual's heart rhythm are still subject to debate. This literature review aims to provide a comprehensive overview of the most significant evidence regarding the impact of dietary modifications on the onset of heart arrhythmias.

Methods. PubMed, EMBASE and Google Scholar were searched from their inception until September 2023 for studies examining the potential effects of nutritional habits on heart rhythm abnormalities. The relevant evidence was qualitatively summarized and critically discussed in this literature review.

Results. Earlier evidence from small observational studies suggests that diets associated with rapid weight loss (generally involving a loss of 6-to-9 kg of body weight within a month) may trigger atrial flutter/fibrillation and lead to alterations in cardiac repolarization, including prolonged QT intervals and ventricular arrhythmias. Conversely, more recent evidence suggests that rapid weight loss can reduce the QT interval, potentially playing a protective and antiarrhythmic role in obese individuals. This apparent paradox can be explained by the fact that earlier studies paid less attention to the electrolyte imbalances resulting from rapid weight loss diets, which can lead to disturbances in electrolytes causing QT prolongation. Laboratory studies have shown that a high-fat diet may be associated with atrioventricular conduction delays and an increased susceptibility to sustained atrial tachycardia. Additionally, epidemiological analyses have demonstrated a link between excess weight and the onset of cardiac arrhythmias. High consumption of grain-based products, snacks, and sugar has been associated with a higher frequency of premature ventricular complexes, while fruit intake has shown an inverse correlation. The consumption of condiments and sauces may increase the likelihood of supraventricular premature complexes, whereas protein consumption appears to be inversely related to them. In general, higher intake of fruits, vegetables, and fish may help prevent arrhythmias. Although omega-3 fatty acids have demonstrated cardiovascular benefits, recent meta-analyses suggest that supplementation at doses exceeding 1 g/day may be associated with an increased risk of atrial fibrillation. Moreover, at doses exceeding 4 g/day, omega-3 fatty acid supplementation may have proarrhythmic effects in patients with a history of nonischemic ventricular arrhythmia. However, lower doses of omega-3 fatty acid supplementation appear to reduce the frequency of premature ventricular complexes. Stimulants like coffee (or other caffeine-rich foods) should be used cautiously in patients with cardiac arrhythmias due to their potential to increase sympathetic tone and ventricular excitability, consequently elevating the risk of tachyarrhythmias. Nevertheless, in healthy adults, moderate coffee consumption does not appear to significantly increase the risk of arrhythmias.

Discussion. In summary, a diet high in fats, refined carbs, and processed foods may raise the risk of cardiac arrhythmias, including through obesity. Conversely, consuming fruits, veggies, fish, and protein seems protective. The role of rapid weight loss in arrhythmias is uncertain. Stimulants should be used cautiously by high-risk individuals. Omega-3 supplementation requires medical supervision to minimize the arrhythmic risk. More research is needed to understand diet's complex role in arrhythmias, to enhance cardiovascular patient care, and refine preventive medicine and nutrition recommendations.

A602: IMBALANCE OF THALAMIC METABOLITES IN AN EXPERIMENTAL MODEL OF HYPERTENSION: ROLE OF BERGAMOT POLYPHENOLS

Antonio Cardamone (a), Cristina Carresi (c), Anna Rita Coppoletta (a), Annachiara Mollace (a), Vincenzo Musolino (b), Micaela Gliozzi (a), Vincenzo Mollace (a)

(a) PHARMACOLOGY LABORATORY, INTERREGIONAL RESEARCH CENTER FOR FOOD SAFETY AND HEALTH (IRC-FSH), DEPARTMENT OF HEALTH SCIENCES, UNIVERSITY "MAGNA GRAECIA" OF CATANZARO, ITALY; (b) PHARMACEUTICAL BIOLOGY LABORATORY, INTERREGIONAL RESEARCH CENTER FOR FOOD SAFETY AND HEALTH (IRC-FSH), DEPARTMENT OF HEALTH SCIENCES, UNIVERSITY "MAGNA GRAECIA" OF CATANZARO, ITALY; (c) VETERINARY PHARMACOLOGY LABORATORY, INTERREGIONAL RESEARCH CENTER FOR FOOD SAFETY AND HEALTH (IRC-FSH), DEPARTMENT OF HEALTH SCIENCES, UNIVERSITY "MAGNA GRAECIA" OF CATANZARO, ITALY

Cerebral metabolites are associated with different physiological and pathological processes in brain tissue. Among them, the concentrations of N-acetylaspartate (NAA) and choline-containing compounds (Cho) in the thalamic region are recognized and analysed as important predictive markers of brain impairment. The relationship among hypertension, modulation of brain metabolite levels and cerebral diseases is of recent investigation, leaving many unanswered questions regarding the origin and consequences of the metabolic damage caused in grey and white matter during hypertension. Here we provide evidence for the influence of hypertension on NAA and Cho ratios in hypertensive rat thalamus and how the use of natural occurring compounds ameliorates the balance of thalamic metabolites.

A603: ASSESSING THE REAL-WORLD IMPACT OF INCLISIRAN ON LDL-CHOLESTEROL LEVELS: EARLY MONOCENTRIC EXPERIENCE ON SEVEN PATIENTS.

Marco Covani (a, b), Gabriella Dallaglio (a, b),
Laura Torlai Triglia (c), Lorena Malpeli (a), Tonino Fabbricatore (a), Filippo Luca Gurgoglione (a, b), Angela Guidorossi (a), Michele Bianconcini (a), Giampaolo Niccoli (a, b)
(a) AZIENDA OSPEDALIERO-UNIVERSITARIA DI PARMA; (b) UNIVERSITÀ DEGLI STUDI DI PARMA; (c) UNIVERSITÀ DEGLI STUDI DI MODENA E REGGIO EMILIA

Introduction. The role of proprotein convertase subtilisin kexin 9 (PCSK9) physiology in the determination of low density lipoprotein cholesterol (LDL-c) values has been established and led to new lipid-lowering strategies. Inclisiran, a first-in-class small interfering ribonucleic acid, is able to silence PCSK9 gene expression, resulting in an increased LDL-c uptake by hepatocytes with lower LDL-c blood levels. Recent studies revealed a promising safety and efficacy profile of Inclisiran as compared to available hypolipidemic agents. However, real-world data on Inclisiran are very limited. In this study we sought to present a preliminary single-center experience with Inclisiran, assessing its impact on LDL levels over a 3-month follow-up period.

Methods. We included all patients who were taking Inclisiran at Parma University Hospital. Inclisiran was administered on top of optimal hypolipidemic therapy in patients unable to reach LDL-c levels or in lieu of other lipid-lowering agents (statins, ezetimibe, PCSK9-inhibitors, alone or in combination) for those who were intolerant to the previous medications, at the discretion of the physician. For each patient, LDL-c levels were assessed at baseline and after 3 months from the first injection of Inclisiran.

Results. The study population was composed of 7 patients (four [57.1%] males, five [71.4%] were receiving lipid lowering therapy for secondary prevention). In detail, four [57.1%] patients received Inclisiran on top of optimal hypolipidemic therapy, three [42.9%] stopped previous hypolipidemic therapy. In the overall population no difference was noted in LDL-c levels after 3-months of Inclisiran therapy (median 78 mg/dL at the baseline vs median 78 mg/dL at 3 months). Interestingly, in the subgroup of patients who received Inclisiran in addition to lipid-lowering therapy, LDL-c levels were numerically lower (median 82 mg/dL at the baseline vs 65 mg/dL after 3-months of Inclisiran therapy), while those who stopped previous hypolipidemic therapy experienced an increase in LDL-c levels (median 64 mg/dL at the baseline vs 102 mg/dL at 3 months).

Conclusions. This study sought to investigate the efficacy of Inclisiran in a real-world cohort of patients. Our results demonstrate the effectiveness of Inclisiran therapy in reducing LDL-c levels only when added on top of optimal hypolipidemic therapy. This study should be considered as "hypothesis-generating". However, the limited statistical power precludes definitive conclusions. Further studies with larger sample size and longer follow-up are needed to establish the clinical value of Inclisiran in patients with cardiovascular diseases.

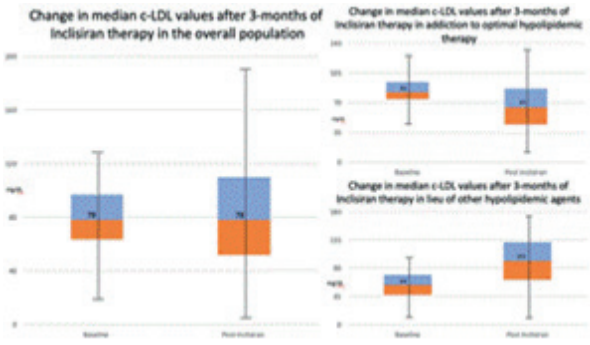

A604: EFFICACY AND SAFETY OF BERGAMOTTO IN PATIENTS WITH DIABETES MELLITUS TYPE II AND DYSLIPIDEMIA

Soccorso Capomolla (a), Antonella Capomolla (a), Josef Ranieli (a), Simone Lo Gatto (a), Valentina Pannace (a), Claudia Natale (a)
(a) DON MOTTOLA MEDICAL CENTER

Objectives. To evaluate, in diabetic patients with statin optimize therapy, the effectiveness of nutraceuticals to improve dyslipidemia management and to restore vascular flow reserve.

Background. Previous studies have shown that correct management of different coronary risk factors can reduce coronary event rates. However, significant undertreatment of diabetic patients is still found during clinical practice.

Methods. Seventyfour eligible diabetics patients, naïve on nutraceuticals were randomized to study; 37 in the placebo group and 37 in the group treated with nutraceutical supplementation. Normoglì is a nutraceutical product composed of bergamot 450 mg, Gymnema 400 mg, Phaseolamin 30 mg, and Olea Europaea 10 mg; Coronary risk profile and vascular flow reserve were evaluated at baseline and again after 12 weeks of treatment in both groups.

Results. Patients in the normogli group showed total(194±33 vs 165±42 mg/dl <0.007) and LDL cholesterol (116±33 vs 94±36 mg/dl). glycemia (128±28 vs 141±35 p<0.05), glycated hemoglobin (7,0±,88 vs 7,4±1,1 p<.0.05) and C – reactive – Protein (6.3±3.3 vs 9.1±4.1 p<0.01) significantly reduced more than the placebo group. At the end of the study, Flow-mediated dilatation (26±11 vs 16±7 p<.0005), post-ischemic flow-mediated dilatation (25±5 vs 17±5 p<.00001), post-ischemic shear rate(56±17 vs 42±19 p<.005), post-ischemic flow(197±98 vs 139±88 p<.02) and diastolic peak velocity (23±10 vs 15±10 p<.009) were significantly better than that at entry in the study and better than that of the group that had received placebo.

Conclusions. In diabetic Patients with optimized medical therapy, nutraceuticals supplementation improve the cardiovascular risk profile management and vascular flow reserve recovery.

IMAGING CARDIOVASCOLARE

A605: STRESS COMPUTED TOMOGRAPHY PERFUSION VERSUS STRESS CARDIAC MAGNETIC RESONANCE FOR THE MANAGEMENT OF SUSPECTED OR KNOWN CORONARY ARTERY DISEASE: RESOURCES AND OUTCOME IMPACT - THE STRATEGY II STUDY

Andrea Baggiano (a), Marco Guglielmo (b), Saima Mushtaq (a), Andrea Annoni (a), Alberto Formenti (a), Maria Elisabetta Mancini (a), Laura Fusini (a), Luigi Tassetti (a), Alessandra Volpe (a), Francesca Marchetti (a), Fabio Fazzari (a), Riccardo Maragna (a), Daniele Junod (a), Alberico Del Torto (a), Francesco Cannata (a), Andrea Igoren Guaricci (c), Gianluca Pontone (a)
(a) CENTRO CARDIOLOGICO MONZINO IRCCS, MILAN, ITALY; (b) UNIVERSITAIR MEDISCH CENTRUM UTRECHT, UTRECHT, THE NETHERLANDS; (c) UNIVERSITÀ DEGLI STUDI DI BARI ALDO MORO, BARI, ITALY

Background. Coronary computed tomography angiography (CCTA) is performed as non-invasive "gatekeepers" to invasive coronary angiography (ICA) but intrinsically lacks physiologic data to assess hemodynamic significance of coronary artery disease (CAD). Stress CT perfusion (Stress-CTP) is a recently evolved imaging modality able to assess inducible myocardial perfusion defects. The aim of this study is to compare resources and outcomes of combined CCTA+Stress-CTP versus stress cardiovascular magnetic resonance (Stress-CMR) in symptomatic patients with suspected or known CAD.

Methods. 624 consecutive symptomatic patients with intermediate to high risk pre-test likelihood for CAD or previous history of revascularization referred to our hospital for clinically indicated CCTA+Stress-CTP or Stress-CMR were enrolled. Stress-CTP scans were performed in 223 patients using 256-row whole heart-coverage scanner while 401 patients with clinically indicated Stress-CMR were evaluated in a 1.5-T scanner. Patient follow-up was performed at 1 year after index test performance. Endpoints were all cardiac events, as a combined endpoint of revascularization, non-fatal MI and death, and hard cardiac events, as combined endpoint of non-fatal MI and death.

Results. Patients who underwent CCTA+Stress-CTP received more revascularization (29% vs 7%, p<0.001) while no differences were found in terms of non-fatal MI and death between the two strategies. According to the predefined endpoints, CCTA+Stress-CTP group showed higher rate of all cardiac events (29% vs 10%, p<0.001) and lower rate of hard cardiac events (0.4% vs 3%, p 0.033), respectively. The cumulative costs were 1970±2506 Euro and 733±1418 Euro for the CCTA+-Stress-CTP group and Stress-CMR group, respectively, with a 63% lower costs for Stress-CMR patients as compared with CCTA+Stress-CTP patients (p<0.001).

Conclusions. The use of CCTA+Stress-CTP strategy was associated with higher referral to revascularization but with a protective trend in terms of hard cardiac events as compared to the usual strategy with lone functional evaluation.

A606: MULTIMODALITY IMAGING APPROACH FOR RIGHT ATRIAL MASS

Giorgia Benzoni (a), Francesco Paolo Perelli (a, b), Maria Consuelo Valentini (b), Denisa Muraru (a, b), Andrea Attilio Moneta (c), Michele Tomaselli (b, d), Gianfranco Parati (a, b), Camilla Torlasco (b), Luigi Badano (a, b), Roberto Brambilla (b)

(a) UNIVERSITÀ DEGLI STUDI DI MILANO-BICOCCA- SCUOLA DI SPECIALIZZAZIONE IN MALATTIE DELL'APPARATO CARDIOVASCOLARE; (b) IRCCS ISTITUTO AUXOLOGICO ITALIANO- OSPEDALE SAN LUCA; (c) IRCCS OSPEDALE GALEAZZI-SANT'AMBROGIO; (d) UNIVERSITÀ DEGLI STUDI DI MILANO-BICOCCA

A 80 years-old woman with mitral valve prolapse was evaluated with transthoracic echocardiography (TTE) due to new onset exertional dyspnea. TTE showed a right atrial mass adhering to fossa ovalis in interatrial septum, dimension 44 x 50 mm; this finding was not present at a previous examination 14 months before (Figure 1). A Transesophageal Echocardiography (TEE) confirmed dimensions of the mass and showed infiltration of free right atrial wall, without involvement of both caval vein outlet (Figure 2). The patient has been admitted to our Cardiology Unit for a better evaluation of the mass by multimodality imaging approach: Cardiac Computed Tomography (CT) showed a hypodense mass of 55x36x75mm with lipomatous-like characteristics and a non-homogeneous component with vascular-like structures, determining compression over the top and antero-lateral wall of right atrium, superior vena cava, coronary sinus and inferior vena cava (Figure 3). We performed a Cardiac Magnetic Resonance (CMR) with gadolinium which confirmed the presence of the mass, showing a T1 ubiquitarian hyperintensity of signal, a T2 isointense signal. In cine sequences a periferic "Indian ink" artifact was found: CMR was not able to confirm the nature (malignity nor benignity) of the mass yet. We also assessed a total body CT scan to exclude extra cardiac findings or metastasis which confirmed the primitive heart localization (Figure 4). After Heart Team discussion the patient underwent surgical excision of the mass with a complete reconstruction of right atrium walls and needed a Pacemaker implantation due post operative bradyarrhythmia. By histological examination a diagnosis of a partially intramuscular myocardial lipoma arising from endocardial tissue was made.

Discussion. Primary Cardiac tumors are extremely rare and in particular lipomas have a detection rate in general population <0.1%. Lipomas are histologically benign mass and symptoms referred to these findings are strictly connected to their localization. This condition needs a tailored cardiac imaging approach as no guidelines are available about the management of these rare findings: in our clinical case we tried to obtain the best tissutal characterization and morphology of the mass by a multimodality assessment. Despite our multimodality imaging approach only histological examination was able to confirm the benign nature of the mass.

Figure 1.

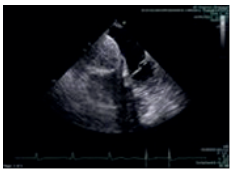

Figure 2.

Figure 3.

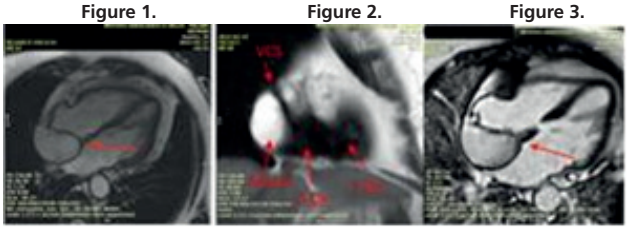

Figure 4.

A607: EVALUATING THE CONCORDANCE OF LEFT VENTRICLE VOLUMES AND FUNCTION MEASUREMENTS AMONG TWO HUMAN READERS, A FULLY AUTOMATED AI 2D SOFTWARE AND THE 3D HEART MODEL

Alberto Bettella (a), Marco Covani (a), Domenico Tuttolomondo (a, b), Sergio Suma (b), Pietro Tito Ugolotti (b), Daniele Sartorio (b), Nicola Gaibazzi (b)

(a) UNIVERSITÀ DI PARMA, PARMA (IT); (b) AZIENDA OSPEDALIERA UNIVERSITARIA DI PARMA, PARMA (IT)

Background. Echocardiography is essential in cardiovascular medicine for various purposes, including screening, diagnosis, and follow-up. Artificial intelligence (AI) has the potential to improve echocardiography by reducing variability and analysis time. While 3D echocardiography is becoming more accurate, 2D imaging remains prevalent. An automatic AI tool for 2D echocardiography would be valuable for routine clinical practice and retrospective analysis. The study aims to evaluate the concordance of left ventricle volumes and function measurements among human readers, a fully automated 2D AI software, and the 3D Heart Model™ (3DHM).

Methods. A retrospective analysis was conducted on 109 patients who underwent 2D and 3D transthoracic echocardiography at the cardiology echo lab of the University Hospital of Parma between November 1, 2022, and December 1. Left ventricle end diastolic and systolic volumes (namely LVEDV and LVESV) and ejection fraction (LVEF) were measured by two operators, 2D AI software (Us2ai™), and the 3D Heart Model. Global longitudinal strain (GLS) was also calculated with vendor's AI software and independent AI software (Us2ai). Correlation, reliability, and agreement were assessed using statistical methods.

Results. For LVEDV measurements, AI showed stronger correlation and reliability compared to human operators. However, for LVESV, the agreement between operators and AI was weaker than between operators. AI demonstrated comparable performance to human operators in measuring LVEF. The 3D Heart Model™ showed slightly inferior correlation and reliability with human readings compared to AI for LVEF measurements. The correlation between AI methods for GLS was only moderate.

Conclusions. The study demonstrates the promising potential of AI as a reliable tool for accurately assessing left ventricle volumes and left ventricular ejection fraction (LVEF) in clinical practice. By leveraging AI technology, the study reveals a significant reduction in inter-operator variability, thereby improving the consistency and reliability of these assessments. Moreover, AI may prove particularly effective for conducting retrospective bulk analyses, offering a valuable tool for comprehensive evaluations of past data.

A608: OPPORTUNISTIC ANALYSIS OF ABDOMINAL COMPUTED TOMOGRAPHY FOR PROGNOSTIC STRATIFICATION OF HOSPITALIZED PATIENTS

Stefano Benenati (a, d), Lorenzo Bianchi (b), Erika Tempo (b), Francesca Bertola (e), Sara Carpaneto (e), Benedetta Conti (e), Francesco Crupi (e), Valeria Dorindo (e), Giulia Francese (e), Giovanni Guglielmini (e), Marta Macciò (e), Ilaria Picone (e), Simone Rinaldi (e), Gabriele Rossi (e), Clary Venzano (e), Caterina Vercelli (e), Italo Porto (b, c), Alberto Stefano Tagliafico (e, f), Pietro Ameri (b, c)

(a) OXFORD HEART CENTRE, JOHN RADCLIFFE HOSPITAL, OXFORD UNIVERSITY HOSPITALS - NHS FOUNDATION; (b) DEPARTMENT OF INTERNAL MEDICINE, UNIVERSITY OF GENOA, GENOA, ITALY; (c) CARDIOVASCULARE DISEASE UNIT, IRCCS OSPEDALE POLICLINICO SAN MARTINO, GENOA, ITALY; (d) CARDIOVASCULAR DISEASE CHAIR, DEPARTMENT OF INTERNAL MEDICINE (DIMI), UNIVERSITY OF GENOA, GENOA, ITALY; (e) DEPARTMENT OF HEALTH SCIENCES, UNIVERSITY OF GENOA, GENOA, ITALY; (f) DEPARTMENT OF RADIOLOGY, IRCCS OSPEDALE POLICLINICO SAN MARTINO, GENOA, ITALY

Introduction. Computed tomography (CT) is routinely performed in hospitalized patients and may provide key information to predict prognosis.

Methods. We sought to stratify the risk of mortality at hospitalization by exploiting easily assessable CT parameters, without the need of collecting clinical data. To this scope, we retrieved the abdominal CT scans carried out in ≥18 years-old inpatients admitted to our hospital for any cause between Jan. 2019 and Jan. 2020. For subjects who had undergone more than 1 CT, we selected the earliest exam during the hospitalization period. The following variables were retrospectively evaluated by a team of 11 radiologists blinded from one another and from patients' outcome, after 2 session of dedicated training and with minimal intra and inter-observer agreement of 0.85: i) diameter of the infrarenal aorta; ii) size (mm) and composition (as expressed by Hounsfield units, HU) of the psoas muscle at the level of the third lumbar vertebra; iii) bone density, as quantified at the first lumbar vertebra. All-cause mortality at 30 days was ascertained by reviewing medical records by another 2 investigators, who did not know the results of the CT scan analyses. The infrarenal aorta was considered dilated if the diameter was>90 percentile for age and sex. The resulting dataset was randomly split in a 3:1 ratio to obtain a derivation and a validation cohort. Univariable and multivariable binary logistic regressions were run to assess independent predictors of 30-day mortality. Multivariable predictors of the endpoint at alpha 0.05 were retained in the score equation. Model discrimination and calibration were then tested in both the derivation and validation cohorts using receiving operator curves (ROC) and areas under the curve (AUC) and comparing predicted vs. observed rates of event across progressive score strata, respectively.

Results. A total of 1,920 abdominal CT scans were analyzed. The mean age of the patients was 65±19 years and 46% were female. The crude rate of 30-day all-cause mortality was 7.9%. The derivation dataset included 1,462 patients, and the validation one 458. Without adjusting, age (p<0.001), psoas size (p<0.001), psoas composition (p<0.001), bone density (p<0.001), and dilated infrarenal aorta (p=0.001) were associated with death at 30 days. At multivariable analysis, age (odds ratio [OR] 1.02, 95% confidence interval [CI] 1.007-1.04, p=0.005), psoas size (OR 0.99, 95% CI 0.997-0.998, p<0.001); psoas composition (OR 0.96, 95% CI 0.95-0.98, p<0.001) and dilated infrarenal aorta (OR 1.95, 95% CI 0.99-3.28, p=0.04) remained predictors. ROC curves showed excellent accuracy both in the derivation (AUC=0.74) and validation (AUC=0.83) dataset. Calibration was also excellent in the derivation cohort, whereas minimal events underestimation was noted in the highest score stratum of the validation dataset.

Conclusions. Opportunistic evaluation of infrarenal aorta dimension and psoas muscle size and quality, combined with age, allow effectively discriminating the risk of 30-day mortality in any hospitalized patient who undergoes abdominal CT.

A609: A RARE CASE OF ANGIOSARCOMA COMPLICATED BY ATRIAL WALL RUPTURE: CLINICAL SCENARIO AND MULTIMODAL IMAGING

Lorenzo Vilhelm Molinari (a), Maria Vittoria Caprio (a), Federica De Donno (a), Mario Di Marino (a), Andrea Ottaviani (a), Fabrizio Ricci (a, b, c), Giulia Renda (a, b), Sabina Gallina (a, b)
(a) DEPARTMENT OF NEUROSCIENCE, IMAGING AND CLINICAL SCIENCES, "G.D'ANNUNZIO" UNIVERSITY OF CHIETI-PESCARA, 66100 CHIETI, ITALY; (b) HEART DEPARTMENT, SS. ANNUNZIATA HOSPITAL, ASL 2 ABRUZZO, 66100 CHIETI, ITALY; (c) DEPARTMENT OF CLINICAL SCIENCES, LUND UNIVERSITY, 21428 MALMO, SWEDEN

75-year-old woman was admitted to our cardiology department with symptoms of acute decompensated heart failure. Transthoracic echocardiogram revealed a left ventricular ejection fraction of 60%, a dilated right ventricle with reduced global and longitudinal function (TAPSE 15 mm, fractional area change 28%). Other findings included significant tricuspid regurgitation, an enlarged right atrium, moderate pericardial effusion, and evidence of moderate systemic venous congestion (VeXUS 2). A heterogeneous mediastinal mass was also observed, encircling the right atrium and the ascending aorta, and extending to the right atrioventricular groove with encasement of the right coronary artery. Cardiac CT confirmed a large mediastinal hematoma measuring 98x78x120 mm, enveloping the ascending aorta and extending laterally to the right atrium (Figure A). Cardiac MRI confirmed the presence of a highly vascularized mass, elucidated the rupture in the roof of the right atrium (Figure B) associated with hemodynamically significant left-to-right shunt. The mass around the right coronary artery was hypointense in T1- and T2-weighted sequences and showed heterogeneous late gadolinium enhancement (Figure C). Coronary angiography revealed normal coronary arteries but identified a fistula from the right coronary artery draining into the atrioventricular groove. Surgical inspection found the right atrium substantially compromised by pathological, fragile, and necrotic tissue that was also hemorrhagic and extensively involved the pericardium. Similar tissue abnormalities were noted around the aortic root and transverse sinus. Two openings on the lateral aspect of the right atrium contributed to the large pericardial hematoma. Suspecting malignant angiosarcoma, tissue samples were sent for histological analysis, which confirmed the diagnosis of primary cardiac angiosarcoma. Patches were applied to the right atrium to restore its integrity. Unfortunately, the patient succumbed to cardiogenic shock a few days post-surgery. Angiosarcoma is the most prevalent primary cardiac malignancy in adults, accounting for 9% of all primary cardiac tumours. Typically found in the right atrium, it carries a poor prognosis due to its rapid growth. Two forms exist: focal and diffuse, with our case illustrating the latter's devastating, invasive nature. Cardiac MRI features often show a heterogeneous right atrial mass that may or may not involve the pericardium. Variations in T1-T2 weighted images and late gadolinium enhancement reflect areas of tumour tissue, necrosis, and hemorrhage. Though surgical debulking is currently the most effective palliative option, no standardized treatment protocol exists.

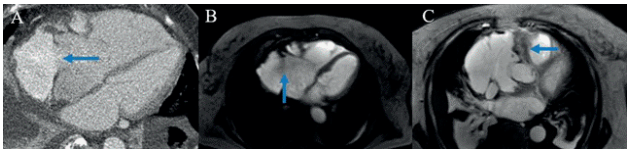

A610: NATURAL SHEAR WAVE ELASTOGRAPHY IN FONTAN PATIENTS: A NEW TOOL FOR NON-INVASIVE ASSESSMENT OF DIASTOLIC FUNCTION?

Irene Cattapan (a), Ahmed Youssef (b), Alexandra Cieplucha (b), Annette Caenen (e), Thomas Salaets (c), Marta Orlowska (e), Bjorn Cools (c), Giovanni Di Salvo (a), Werner Budts (d), Mark Gewillig (c), Jan D´hooge (e), Jens-uwe Voigt (b), Alexander Van De Bruaene (d)
(a) CARDIOLOGIA PEDIATRICA, DIPARTIMENTO DI SALUTE DELLA DONNA E DEL BAMBINO, UNIVERSITÀ DEGLI STUDI DI PADOVA, PADOVA; (b) DEPARTMENT OF CARDIOVASCULAR SCIENCES, KU LEUVEN, LEUVEN, BELGIUM; (c) DEPARTMENT OF PEDIATRIC CARDIOLOGY, UZ LEUVEN, GASTHUISBERG HOSPITAL, LEUVEN, BELGIUM; (d) DEPARTMENT OF STRUCTURAL CARDIOLOGY, UZ LEUVEN, GASTHUISBERG HOSPITAL, LEUVEN BELGIUM; (e) DEPARTMENT OF CARDIOVASCULAR IMAGING AND DYNAMICS, KU LEUVEN, LEUVEN, BELGIUM

Background. Ventricular compliance is known to have a direct impact on ventricular filling and diastolic function. Myocardial stiffness can be non-invasively assessed by using shear wave elastography (SWE), a promising new echocardiographic modality based on measuring the velocity of naturally occurring shear waves using high frame imaging. Diastolic compliance is particularly important in single ventricle physiologies corrected with Fontan circulation, where pulmonary blood flow lacks of the pulsatile flow from right ventricle.

Aim. (I) to assess feasibility of natural shear wave elastography in Fontan patients; (II) to document the observed natural shear wave speed after atrioventricular valve closure (AVVC) and outflow valve closure (OVC) in both paediatric and adult Fontan patients; (III) to compare natural shear waves speed in Fontan patients with age-matched healthy volunteers; (IV) to determine how myocardial stiffness varies with increasing age and patients clinical condition; (V) to define if shear waves velocities are related with pressure in the total cavo-pulmonary conduit assessed invasively in the Cath lab or non-invasively from peripheral venous lines.

Methods. We enrolled 47 consecutive Fontan patients: 15 children, 12 adolescents and 20 adults (mean age 19±11 years, range 3-46 y). High frame rate parasternal long-axis views were acquired using a dedicated echo machine (1367±270 frame/s). Images were processed offline with a dedicated software. Finally, we enrolled xxx age and sex matched healthy volunteers.

Results. 66% of the patients enrolled had left-dominant ventricles, while the remaining 34% was right-dominant (12 patients had tricuspid atresia, 13 DILV, 5 unbalanced AVSD, 8 HLHS, 2 DIRV, 4 pulmonary atresia with VSD, 3 PAIVS, 1 Ebstein anomaly). SWE speed measurements across the wall most like to septum was feasible in 97% of patients, both after AVVC and OVC. Average SWE velocities were significatively higher than healthy volunteers in our laboratory (5.3±1.5 m/s after AVVC vs 3.54 ± 0.93 m/s, p<0.001; 5.1±1.93 m/s after OVC vs 3.75±0.76 m/s, p<0.001). There was no correlation between shear waves velocities and age (r=0.092, p=0.54 for SW after AVVC; r=0.13, p=0.39 for SWE after OVC) and no significant difference between age groups (p=0.69 for SWE after AVVC; p=0.71 for SW after OVC). Patients with a failing Fontan showed increased SWE speed than those with a "good Fontan" (6.27 ± 1.45 m/s vs 4.85 ± 1.47 m/s; p=0.008). Ventricular dominance did not significantly influence shear waves velocities (p=0.68 for SWE after AVVC; p=0.36 for SWE after OVC). Shear waves velocities after AVVC showed a good correlation with pressure in the cavo-pulmonary conduit (r=0.55, p=0.002), while no other conventional echo parameter showed correlation with measured filling pressures (E/A r=-0.14, p=0.48; E/E' r=-0.15, p=0.41; myocardial performance index: r=-0.19, p=0.92; S/D ratio r=0.25, p=0.18; pulmonary a wave velocity r=0.14, p=0.53; pulmonary a wave duration – atrioventricular A wave duration r=-0.29, p=0.16).

Conclusions. Our findings showed, for the first time, that measurements of SWE was feasible in univentricular hearts with Fontan circulation. In those patients, myocardium appeared stiffer than normal. Our data suggest that SWE may become a useful tool for non-invasive assessment of diastolic function in univentricular hearts.

A611: SEVERE STENOSIS OF MITRAL BIOPROSTHETIC VALVE THROMBOSIS IN A PATIENT WITH HCV-RELATED CIRRHOSIS AND DUODENAL VARICEAL BLEEDING: THE DEADLY TRIAD

Salvatore Chianese (a, b), Rosangela Cocchia (b), Valentina Capone (a, b), Ciro Mauro (b), Eduardo Bossone (c)
(a) DEPARTMENT OF ADVANCED BIOMEDICAL SCIENCES, UNIVERSITY OF NAPLES FEDERICO II, 80131 NAPLES, ITALY; (b) CARDIOLOGY UNIT, A. CARDARELLI HOSPITAL, NAPLES, ITALY; (c) DEPARTMENT OF PUBLIC HEALTH, UNIVERSITY OF NAPLES FEDERICO II, 80131 NAPLES, ITALY

A 45-year-old man, smoker, and former drug addict with known HCV-related cirrhosis (Child–Pugh C), was admitted to the emergency department for shortness of breath and melena. Lab tests showed severe anemia, hepatic and renal dysfunction. Past medical history included recurrent variceal bleeding treated with cyanoacrylate injections, chronic coronary syndrome and mitral valve infective endocarditis requiring mitral valve replacement surgery (St Jude Medical bio prosthesis 29). After the initial workup with transfusion of two packed red blood cells, the patient underwent esophago-gastro-duodenoscopy, which revealed duodenal variceal bleeding, which was subsequently treated with endoscopic injection sclerotherapy. A bidimensional transthoracic Doppler echocardiography (TTE) exam was performed, which showed mitral bioprosthetic valve thrombosis (M-BPVT) with severe stenosis (mean pressure gradient: 29.9 mmHg) and right ventricle dilatation/dysfunction along with severe pulmonary hypertension (estimated systolic pulmonary artery pressure: 70 mmHg) (Figure 1). A cardiac computed tomography (CCT) provided unique views of valve dysfunction and excluded pulmonary embolism (Figure 2). A transjugular intrahepatic portosystemic shunt (TIPS) was then excluded, as it could have precipitated the patient into pulmonary oedema as a direct consequence of volume overload. For the worsening hemodynamic status, the patient was transferred to the liver intensive care where a multidisciplinary team was activated involving a cardiologist, cardiac surgeon, infectious disease specialist, pneumologist, and nephrologist. Different therapeutic interventions were evaluated: fibrinolysis was contraindicated for the extreme bleeding risk of the patient; valve replacement was excluded for the extremely high surgical risk of the procedure and valve-in-valve procedure was pending. However, the presence of a large thrombus could have led to high risk of periprocedural embolization. Eventually, the patient developed a septic shock and died of multiorgan failure. PVT represents a life-threatening cardiovascular emergency needing a prompt diagnosis and timely appropriate therapeutic intervention. The presence of severe comorbidities further complicates the clinical decision-making process, calling for a patient-tailored integrated multidisciplinary approach.

Figure 1. TTE.

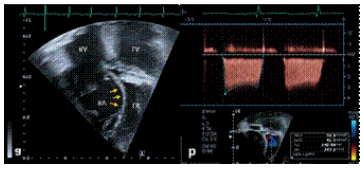

Figure 2. CCT.

A612: NOVEL METRICS FOR QUANTITATIVE ASSESSMENT OF HEART FAILURE: INSIGHTS FROM CMR IMAGING

Carmelita Cieri (a), Andrea Palermi (a), Valeria Di Mascio (b), Anna Sorella (a), Giandomenico Bisaccia (b), Andrea De Luca (a), Marzia Olivieri (b), Giulia Renda (a), Massimo Caulo (b), Cesare Mantini (b), Sabina Gallina (a), Fabrizio Ricci (b)
(a) UNIVERSITÀ DEGLI STUDI D'ANNUNZIO CHIETI-PESCARA; (b) DIPARTIMENTO DI NEUROSCIENZE, IMAGING E SCIENZE CLINICHE, UNIVERSITÀ DEGLI STUDI DI CHIETI-PESCARA, 66100 CHIETI, ITALY

Background andAims. Pulmonary blood volume index (PBVI) and cardiovascular magnetic resonance (CMR)-derived left ventricular filling pressure (CMR-wedge) are novel metrics to assess hemodynamic congestion. We aimed to assess the prognostic value of these new metrics in a cohort of consecutive clinical patients referred to our CMR unit and their correlation with non-invasive indices of myocardial fibrosis.

Methods. We conducted a prospective single-centre study enrolling clinical all-comers undergoing contrast-enhanced clinical CMR imaging. PBVI was calculated as the product of stroke volume and the number of cardiac cycles for an intravenous bolus of gadolinium contrast to pass through the pulmonary circulation measured by first-pass perfusion imaging. CMR-wedge was calculated using the formula proposed by Garg et al. (CMR-wedge=6.1352 + (0.07204*left atrial volume)+(0.02256*left ventricular mass). The primary endpoint was a composite of all-cause mortality and cardiac hospitalisation.

Results. We enrolled 262 consecutive patients (mean age 52±17; 37% female; 21% normal CMR). During a median follow-up of 30 months, 32 (12%) patients reached the primary composite endpoint. Mean CMR-wedge was 13.4±2.3 mmHg, and mean PBVI was 333±150 ml/m^2. Patients with cardiac disease presented with significantly higher CMR-wedge than controls (13.7±2.4 vs 12.5±1.9 mmHg; P=0.001), but similar PBVI (P=0.551). There was a positive correlation between CMR-wedge and indices of systolic function (p<0.001), global native T1 mapping (P=0.001), ECV (p=0.004) and indexed ECV (P=<0.001), whereas PBVI was not correlated with T1-mapping indices. Patients exhibiting a CMR-wedge ≥15 mmHg had a poorer prognosis than those with a CMR-wedge <15 mmHg. At multivariate Cox regression analysis, CMR-wedge and ECV were the sole independent predictors of the primary endpoint.

Conclusions. CMR-wedge shows potential as a valuable tool for evaluating hemodynamic congestion and risk stratification in patients with cardiac conditions. Higher levels of CMR-wedge were linked to worse outcomes and correlated with markers of myocardial fibrosis. In contrast, PBVI did not exhibit similar associations.

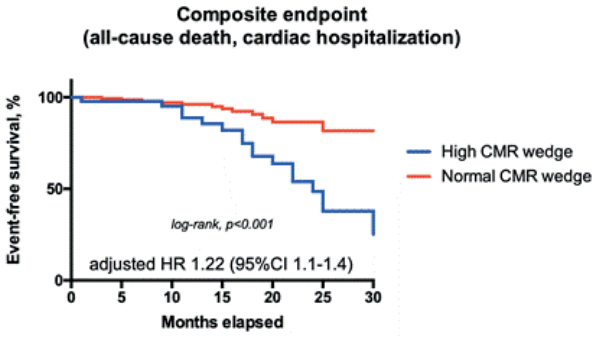

A613: RELATIONSHIP BETWEEN ECG INDICES OF MULTIPOLAR ELECTRICAL ACTIVITY OF THE HEART AND MYOCARDIAL FIBROSIS: INSIGHTS FROM CARDIOVASCULAR MAGNETIC RESONANCE IMAGING

Francesca Ciliberti (a), Carmelita Cieri (a), Davide Pirro (a), Laura Ceriello (a), Valeria Di Mascio (a), Giandomenico Bisaccia (a), Giulia Renda (a), Cesare Mantini (a), Massimo Caulo (a), Sabina Gallina (a), Fabrizio Ricci (a)
(a) DIPARTIMENTO DI NEUROSCIENZA, IMAGING E SCIENZE CLINICHE, UNIVERSITÀ DEGLI STUDI DI CHIETI - PESCARA, 66100 CHIETI, ITALY

Background. Myocardial fibrosis can directly result in tissue anisotropy, potentially triggering arrhythmias through re-entry mechanisms and associated with the development and progression of heart failure (HF). Cardiac magnetic resonance (CMR) is an established technique for assessing replacement and interstitial myocardial fibrosis by late gadolinium enhancement (LGE) imaging and T1 mapping indices, respectively. On the other hand, qualitative and semiquantitative ECG biomarkers, such as the Selvester QRS score (SQS) have been associated with the presence of myocardial fibrosis, as depicted by CMR, yet with controversial results. Recent evidence suggests that the multipolar electrical activity of the heart, which may be increased in pathologic conditions which alter the electrical activation pattern with subsequent formation of multiple disorganised vectors, can be actively quantified by real-time measurement of the cardiac electrical biomarker (CEB) index.

Purpose. To test the hypothesis about whether ECG quantitative assessment of multipolar electrical activity of the heart would reflect the presence of underlying myocardial tissue abnormalities, we investigated the relationship between CEB, SQS and different CMR tissue characterisation modules.

Methods. We conducted an observational, prospective, single-centre study in a clinical population of all-comers subjects referred for clinical CMR imaging on a 3-Tesla scanner. CEB and SQS were collected from digital ECG acquired with the Vectraplex ECG system on the same day, blinded to clinical and CMR data. We investigated the relationship between ECG biomarkers and different tissue characterisation modules (native T1 mapping, T1 mapping dispersion, T2 mapping, extracellular volume, LGE) in a total population of 103 patients undergoing ECG and CMR on the same day.

Results. Overall, we enrolled 103 individuals (mean age 48±19, women 25%), of whom 21 with normal CMR, 15 with ischemic cardiomyopathy and 67 with non-ischemic cardiomyopathy. The mean CEB index was 69±94, and increasing with age in men, but not in women. There were no significant differences related to body mass index, prevalent cardiovascular risk factors, and diagnosis subgroups, but CEB was significantly higher in patients with ST depression, T-wave inversion, and longer P wave duration (p<0.05). CEB was not associated with LGE and T2 mapping indices but showed a significant positive relationship with T1 mapping indices, including global native T1 mapping, ECV and T1 mapping dispersion (p<0.001). The strongest correlation was observed between CEB and T1 mapping dispersion (R^2=0.491; p<0.001). At multivariate linear regression analysis, CEB remained an independent predictor of all T1 mapping indices, irrespective of age, sex, standard ECG parameters and SQS (p<0.001). The Selvester score demonstrated a significant positive association with both the presence and extent of LGE (p<0.001). At multivariate linear regression analysis, SQS remained an independent predictor of LEG extent. However, SQS did not show any association with parametric mapping indices.

Conclusions. The CEB index, a novel quantitative ECG biomarker of multipolar cardiac electric forces, demonstrated good accuracy for the prediction of extracellular matrix expansion, and particularly a robust association with T1 mapping dispersion, a novel imaging biomarker reflecting structural anisotropy of the myocardium. The SQS confirmed good accuracy for LGE prediction and may be more suitable for the prediction of replacement myocardial fibrosis. Further studies are needed to confirm our findings and to evaluate the ability of the CEB index to stratify the longitudinal risk of arrhythmic events and HF-related outcomes.

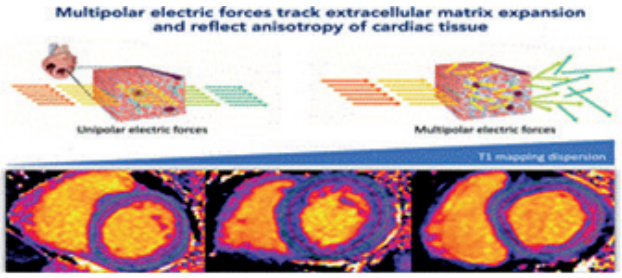

A614: ISOLATED TRICUSPID ANNULAR DISJUNCTION AND PROLAPSE: A CASE REPORT

Riccardo Colombi (a, b), Marcello Cosenza (a, b), Alessandro Faggi (b, c), Giacomo Ingallina (a), Eustachio Agricola (a, b)
(a) CARDIOVASCULAR IMAGING UNIT, SAN RAFFAELE HOSPITAL, MILAN, ITALY; (b) VITA-SALUTE SAN RAFFAELE UNIVERSITY, MILAN, ITALY; (c) DEPARTMENT OF CARDIAC SURGERY, SAN RAFFAELE HOSPITAL, MILAN, ITALY

Introduction. Tricuspid annular disjunction (TAD) has been increasingly reported in the context of concomitant left-sided morpho-functional abnormalities associated with arrhythmic mitral valve prolapse (AMVP), including mitral annular disjunction (MAD) and curling. However, isolated involvement of the right-sided annulus in the absence of concomitant significant disease of the mitral valve complex remains anecdotal at present.

Clinical case. A 70-year-old woman was referred to our Centre for an inpatient evaluation due to a one-year history of exertional dyspnoea (NYHA II), fatigue and palpitations. Her past cardiovascular history was significant for a 3-years history of atrial flutter (AF) managed with a rate-control strategy. Her physical examination revealed no remarkable

findings. Atrial flutter with suboptimal rate-control was confirmed by the electrocardiogram. Transthoracic echocardiogram (TTE) revealed myxomatous tricuspid valve degeneration and leaflets prolapse leading to severe valvular regurgitation; in addition, tricuspid annular disjunction (TAD) was suspected on the apical four-chamber view (figure, A). Right cardiac chambers were normal in size and function, including for a normal tricuspid annular diameter (TA 36 mm on apical 4-chamber view). Other findings included a non-dilated left ventricle, with a normal ejection fraction (LVEF 65%) and no regional wall motion abnormalities. Trivial mitral regurgitation due to (bi)leaflet prolapse was found. Neither mitral annular disjunction (MAD) nor curling motion of the left ventricular basal posterolateral wall were detected. The patient underwent transoesophageal echocardiography (TEE) and cardiac magnetic resonance (CMR) to better elucidate these findings. Severe tricuspid regurgitation due to diffuse leaflets prolapse and TAD were confirmed on both TEE and CMR, with the evidence of a maximum disjunction of 9 millimetres at the level of the hinge point of posterior leaflet and the posterior wall of the right ventricle (figure, B-C-D). No ventricular arrythmias were detected on continuous rhythm monitoring. Given the highly symptomatic status of the patient and the evidence of severe organic valvular regurgitation, after a multidisciplinary Heart Team discussion, the patient underwent surgical tricuspid valve repair with ring annuloplasty with mild residual post-operative regurgitation and concomitant atrial flutter ablation and left atrial appendage closure were performed.
Discussion. Tricuspid annular disjunction (TAD) has been reported as a common finding in patients with MAD and was associated with more severe left-sided annulus disjunction and mitral valve prolapse. Despite anecdotal reports among patients who experienced sustained ventricular arrythmias and even cardiac arrest, TAD was not independently associated with ventricular arrhythmias in the population of patients with arrhythmic mitral valve prolapse and MAD in observational studies. At present, given our current state of knowledge, TAD both in isolation and in association with MAD in patients with AMVP should be interpreted solely as a marker of more extensive (bi)annular disease with no implication on arrhythmic risk-stratification strategies.

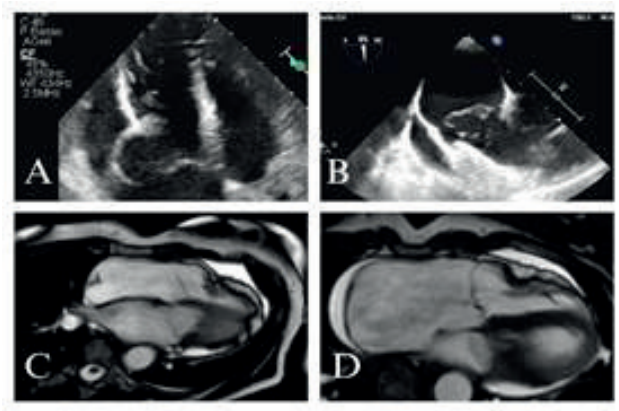

A615: COEXISTENCE OF DUAL RARE HIGH-RISK CORONARY ANOMALIES IN AN ASYMPTOMATIC ATHLETE: SHARED AORTIC ORIGIN OF THE RIGHT CORONARY AND LEFT MAIN TRUNK ABOVE THE RIGHT SINUS OF VALSALVA

Davide Donelli (a, b), Diego Ardissino (a), Luca Piccinini (c), Evelina Faragasso (b)
(a) CARDIOLOGY DIVISION, PARMA UNIVERSITY HOSPITAL, PARMA, ITALY; (b) CARDIOVASCULAR IMAGING UNIT, SALUS HOSPITAL REGGIO EMILIA, REGGIO EMILIA, ITALY; (c) CARDIOLOGY UNIT, SALUS HOSPITAL REGGIO EMILIA, REGGIO EMILIA, ITALY

Introduction. Coronary anatomical anomalies pose a tricky aspect in assessing athletes' suitability for agonistic sports, as they can remain completely silent yet significantly elevate the risk of sudden cardiac death (SCD).
Clinical presentation. A 50 y.o. male athlete presented for routine sports medicine evaluation. The patient had no past medical history or ongoing therapy. However, a family history of coronary artery disease and a daughter with dilated cardiomyopathy were noted. The patient was asymptomatic, and his vitals and blood tests were normal. Baseline ECG showed normal sinus bradycardia. Echocardiography revealed normal left ventricular (LV) dimensions, with mildly increased wall thickness and preserved ejection fraction (EF) of 60%, and no valvular anomalies. The primary concern arose from the exercise stress test, which resulted perfectly normal except for sporadic premature ventricular contractions during the warm-up and a fast couplet during the recovery phase, primarily monomorphic with a LBBB morphology and inferior axis. For this reason cardiac magnetic resonance imaging was performed, particularly considering the family history, showing normal ventricular sizes, LV EF of 56%, and no late gadolinium enhancement areas. Importantly, an anomalous origin of the left main trunk was discovered. It originated directly from the aorta higher than the aortic bulb and just above the commissure between the right and left Valsalva sinus (SoV), with an interarterial course between the aorta and the pulmonary artery, before its bifurcation. The right coronary artery also seemed to have an atypical medial origin, potentially representing a single coronary origin. Subsequently, a cardiac computed tomography was performed, confirming the anomalous anatomy, and revealing that the right coronary artery had its separate origin, albeit the two coronaries shared a sort of common ostium. This is considered to be a form of single coronary artery and it represents a potentially serious anomaly.
Conclusions. The coexistence of two rare anomalies highlights the concern surrounding rarely occurring anomalous origins of the coronary arteries, given the elevated risk of SCD they pose.

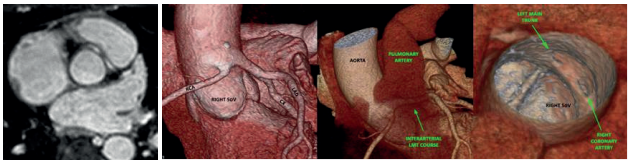

A616: INCIDENTAL DISCOVERY OF COMPLEX CORONARY ANOMALIES IN A PATIENT WITH SEVERE MITRAL REGURGITATION: SINGLE AORTIC ORIGIN OF CORONARY CIRCULATION WITH INTRASEPTAL COURSE AND FUNCTIONAL LEFT ANTERIOR DESCENDING AND CIRCUMFLEX ARTERIES

Davide Donelli (a, b), Giampaolo Niccoli (a), Evelina Faragasso (b)
(a) CARDIOLOGY DIVISION, PARMA UNIVERSITY HOSPITAL, PARMA, ITALY; (b) CARDIOVASCULAR IMAGING UNIT, SALUS HOSPITAL REGGIO EMILIA, REGGIO EMILIA, ITALY

Clinical case. A 73yo female with symptomatic severe mitral valve regurgitation with mitral valve prolapse, needing surgical repair, was admitted for preoperative coronary angiogram, which revealed a congenital coronary artery anomaly: absence of the left main coronary artery with left coronary branches originating as extensions of the right coronary artery. The coronary CT angiography confirmed a coronary artery anomaly with agenesis of the left main coronary artery (LM) coupled with a single coronary artery originating from the aorta that supplied the entire coronary circulation. This anomaly is consistent with type L group II according to the Lipton classification. The right coronary artery originated above the left Valsalva sinus and followed a course between the aorta and pulmonary artery/outflow tract of the right ventricle without having an intramural course. A tortuous vessel originating from its mid-section reached the apex of the heart and ascended the antero-septal wall of the left ventricle, giving rise to a "functional" distal left anterior descending artery (LAD). Another vessel originated from the distal main right coronary artery, traversed the interventricular septum, and emerged from the proximal antero-septal wall of the left ventricle, giving rise to a vessel hypothesized to be the proximal segment of the LAD and subsequently the circumflex (CX) branch. There was also a thin channel (possibly a fistula) between the proximal segment of the single right coronary and its distal tract at the level of the hypothesized proximal segment of the LAD.
Conclusions. Multiple, complex, and rare coronary anomalies pose a high risk both surgically and in terms of arrhythmias, and require thorough study and follow-up.

A617: THE PROGNOSTIC IMPORTANCE OF THE PRESENCE OF MULTIPLE SEVERITY CRITERIA AT THE ECHOCARDIOGRAPHIC EVALUATION OF SECONDARY TRICUSPID REGURGITATION

Giorgio Oliverio (a), Michele Tomaselli (a, b), Denisa Muraru (a, b), Marco Penso (a), Francesca Heilbron (a), Mara Gavazzoni (a, b), Sergio Caravita (a, c), Claudia Baratto (a, b), Francesco Paolo Perelli (b), Alexandra Clement (a), Noela Radu (a), Andrea Cascella (b), Alessandra Rota (b), Paolo Springhetti (d), Samantha Fisicaro (a), Gianfranco Parati (a, b), Luigi Badano (a, b)
(a) ISTITUTO AUXOLOGICO ITALIANO; (b) UNIVERSITÀ DEGLI STUDI DI MILANO BICOCCA; (c) UNIVERSITÀ DEGLI STUDI DI BERGAMO; (d) UNIVERSITÀ DEGLI STUDI DI VERONA

Background. Secondary tricuspid regurgitation (STR) is an important health problem, associated with a high rate of cardiovascular adverse

events. Current guidelines recommend assessing STR severity through a combination of qualitative, semiquantitative and quantitative echocardiographic parameters. However, in clinical practice there is frequently discordance among these parameters when defining STR severity, and how to combine them to achieve the best outcome prediction has not been clarified yet.
Aims. To evaluate the outcome of patients with relevant (at least moderate) STR when accounting for the presence and the number of regurgitation severity criteria.
Methods. A retrospective analysis of echocardiographic exams obtained from consecutive outpatients with STR was performed by experienced researchers. STR severity was evaluated using six echocardiographic parameters: the effective regurgitant orifice area (EROA>0,4cm2), the regurgitant volume (Rvol>45ml), the regurgitant fraction (RF>50%), the biplane vena contracta (VC. 7mm), the jet area (JA>10cm2), and the ratio between jet area and right atrial area (JA/RA>50%). If no criterion was met, the STR was not considered severe. One point was assigned for each parameter exceeding the severity threshold. Based on the number of parameters meeting the severity criteria, a score ranging from 0 to 6 was calculated. STR patients were classified in Group 0, (score 0-1), Group 1 (score 2-4), and Group 2 (score 5-6). The outcome was assessed using a composite endpoint of heart failure hospitalization and cardiovascular death.
Results. A total of 513 patients (mean age 75±13 years, 53% female, 41% atrial fibrillation, 38% atrial STR, 58% severe) were included in the final cohort. After a mean follow-up of 18±15 months, 195 patients (38%) reached the composite endpoint. Group 0 included 234 patients, while Group 1 and Group 2 had 238 and 41 patients, respectively. Throughout the follow-up, Group 2 experienced worst event-free survival than Group 1 and 0 (25±9% vs. 48±4% vs. 74±3% at 2 years, all p<0.001) (Figure 1).
Conclusions. The presence of multiple (>4) echocardiographic parameters used for the quantification of secondary tricuspid regurgitation meeting severity criteriaidentifies patients with worse outcomes compared to STR patients with only one or few positive criteria.

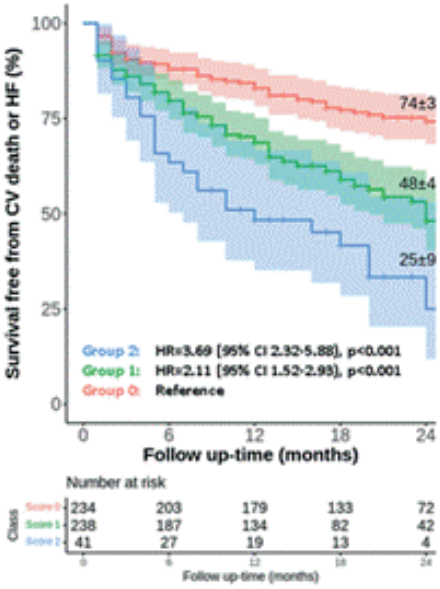

A618: CLINICAL IMPACT OF THE VOLUMETRIC QUANTIFICATION OF THE SEVERITY OF VENTRICULAR SECONDARY MITRAL REGURGITATION BY THREE-DIMENSIONAL ECHOCARDIOGRAPHY

Cinzia Pece (a), Michele Tomaselli (a, b), Giorgio Oliverio (b), Emanuele Curti (a), Paolo Springhetti (c), Salvatore Milazzo (d), Denisa Muraru (a, b), Cristina Giannattasio (a), Gianfranco Parati (a, b), Luigi P. Badano (a, b)
(a) DEPARTMENT OF MEDICINE AND SURGERY, UNIVERISTY OF MILANO-BICOCCA, MILAN, ITALY; (b) DEPARTMENT OF CARDIOLOGY, ISTITUTO AUXOLOGICO ITALIANO, IRCCS, MILAN, ITALY; (c) DEPARTMENT OF MEDICINE, DIVISION OF CARDIOLOGY, UNIVERSITY OF VERONA, VERONA, ITALY; (d) DIVISION OF CARDIOLOGY, UNIVERSITY HOSPITAL PAOLO GIACCONE, PALERMO, ITALY

Background. Quantitative assessment of ventricular secondary mitral regurgitation (v-SMR) by the effective regurgitant orifice area (EROA) and the regurgitant volume (RegVol) calculated using either the proximal isovelocity surface area (PISA) or the volumetric method by two-dimensional echocardiography (2DEVM) are dependent on several geometric assumptions leading to significant underestimation of v-SMR severity. Conversely, in patients with isolated v.SMR, the RegVol measured by three-dimensional echocardiography volumetric method (3DEVM) is independent on geometric assumptions since it is the difference between the stroke volumes of the right and the left ventricles.
Objectives. We sought to evaluate whether the EROA and the RegVol measured using 3DEVM may improve the assessment of the severity and the risk stratification in patients with v-SMR in comparison with both 2DEVM and PISA methods.
Methods. Patients with at least mild isolated v-SMR underwent 2DE, Doppler and 3DE. We compared EROA and RegVol calculated by 3DE-VM, 2DEVM, and PISA methods. The endpoint was a combined of heart failure (HF) hospitalization and death for any cause.
Results. We enrolled 182 patients (70% men, 70 ± 13 years). After a mean follow-up of 20±11 months, 86 patients (47%) reached the endpoint. Both the EROA and the RegVol calculated by 3DEVM (0.22±0.1 cm^2 and 33±17 ml, respectively) were larger than those calculated by 2DEVM (0.13±0.1 cm^2, p<0.001 and 21±13 ml¸ p<0.001, respectively) and PISA (0.14±0.1 cm^2, p<0.001 and 21±14 ml¸ p<0.001, respectively). The associations with outcome of both EROA and RegVol measured by 3DE-VM was significantly stronger than those obtained using EROA (Z=3.94, p<0.001, and Z=2.94, p=0.003) and RegVol (Z=3.81, p<0.001and Z=2.85, p=0.004) measured by PISA and 2DEVM, respectively. Patients with EROA≥0.3 cm^2 (log rank χ^2=19, p<0.001) and RegVol≥45 mL (log rank χ^2=24, p<0.001) obtained by 3DEVM had a higher incidence of the combined endpoint. At Cox multivariable analysis, EROA≥0.3 cm^2 by 3DE-VM was independently related to the combined endpoint with an HR of 2.20 (95% CI 1.19–4.04; p=0.01) and yielded the best predictive model (χ^2 32, p<0.001).
Conclusions. Quantitative assessment of v-SMR by 3DEVM provides larger EROA and REgVol, reclassifying the v-SMR severity in 26% patients. Moreover, EROA and RegVol obtained by 3DEVM were independently associated with all-cause mortality and HF hospitalization, and improved the risk stratification of patients with v-SMR compared to 2DEVM and PISA methods.

A619: CLINICAL SIGNIFICANCE OF LATE GADOLINIUM ENHANCEMENT IN ARRHYTHMOGENIC MITRAL VALVE PROLAPSE

Emanuela Sergianni (b), Andrea Villatore (a, b), Giulia Randi (b), Gaia Souryal (b), Lucia Molinari (b), Paolo Della Bella (a, b), Giovanni Peretto (a, b)
(a) IRCCS SAN RAFFAELE HOSPITAL, MILAN; (b) VITA-SALUTE SAN RAFFAELE UNIVERSITY, MILAN

Background. The clinical value of late gadolinium enhancement (LGE) at cardiac magnetic resonance (CMR) in arrhythmogenic mitral valve prolapse (MVP) is unclear.
Purpose. To investigate the relationships between LGE and clinical features in patients with MVP.
Methods. We retrospectively enrolled consecutive patients with MVP and available CMR at baseline assessment. The diagnostic work-up for arrhythmias included Holter ECG and, when available, programmed ventricular stimulation (PVS) and continuous arrhythmia monitoring by implantable loop recorder (ILR) and/or implantable cardioverter defibrillators (ICD). The endpoints of the study were: a) prevalence of LGE; b) differential VA features in LGE-positive (LGE+) vs. LGE-negative (LGE-) patients; c) occurrence of complex VA (nonsustained ventricular tachycardia, sustained ventricular tachycardia, and ventricular fibrillation) during follow-up; d) degree of mitral regurgitation.
Results. Of 30 patients (48 years-old, IQR 36-59; 69% females) with AMVP, 18 (60%) were LGE+, while the remaining (40%) were LGE-. LGE localized at the inferolateral wall and/or papillary muscles 12 cases (41%), interventricular septum in 4 (14%), and both sites in 2 (7%). Baseline left ventricular ejection fraction (LVEF) was 57% (IQR 50-63%). All patients had frequent premature ventricular contractions (PVCs) (median number per 24 hours 2000, IQR 1000-10000). Carriers of ILR or ICD were 5/30 (17%) and 11/30 (38%), respectively. By a median follow-up of 4 (IQR 2-7) years, complex VA were equally distributed between LGE+ and LGE- groups (10/18 vs. 7/11, p=0.668). However, right-bundle branch block (RBBB) morphology of VA were more frequently found in LGE+ patients (94% vs. 36%, p<0.001). In most cases, VA axis was superior, which was consistent with LGE localization. On the contrary, LGE- patients mostly exhibited left-bundle branch block (LBBB) morphology with inferior axis (45%). Finally, more than mild mitral regurgitation was significantly less common among LGE+ patients (respectively: 33% vs. 73%, p=0.039).
Conclusions. MVP-associated VA manifest irrespectively of the presence of LGE. However, VA features appear in close relationship with LGE presence and site. In spite of a comparable arrhythmic risk profile, a LGE+ status was also associated with a lower degree of mitral regurgitation.

A620: ROLE OF PERICORONARY ADIPOSE TISSUE INFLAMMATION AT CCTA AFTER HEART TRANSPLANTATION AS NON-INVASIVE DIAGNOSTIC TOOL OF CARDIAC REJECTION AND PREDICTOR OF MACE

Daniele Cavallo (a, b), Angelo Sansonetti (a, b), Ornella Di Iuorio (a, b), Francesco Pio Tattilo (a, b), Khrystyna Ryabenko (a, b), Nicole Suma (a, b), Matteo Armillotta (a, b), Damiano Fedele (a, b), Andrea Stefanizzi (a, b), Andrea Impellizzeri (a, b), Francesca Bodega (a, b), Davide Bertolini (a, b), Francesco Angeli (a, b), Sara Amicone (a, b),

Lisa Canton (a, b), Luca Bergamaschi (a, b), Marcello Casuso (a, b), Pasquale Paolisso (c), Alberto Foà (a, b), Luciano Potena (d), Marco Masetti (d), Laura Borgese (d), Marta Belmonte (e), Claudio Asta (a, b), Virginia Marinelli (a, b), Carmine Pizzi (a, b)
(a) DEPARTMENT OF MEDICAL AND SURGICAL SCIENCES-DIMEC-ALMA MATER STUDIORUM, UNIVERSITY OF BOLOGNA, BOLOGNA, ITALY; (b) CARDIOLOGY UNIT, IRCCS AZIENDA OSPEDALIERO-UNIVERSITARIA DI BOLOGNA, BOLOGNA, ITALY; (c) DEPARTMENT OF ADVANCED BIOMEDICAL SCIENCES, UNIVERSITY FEDERICO II, NAPLES, ITALY; (d) HEART FAILURE AND TRANSPLANT UNIT, IRCCS AZIENDA OSPEDALIERO-UNIVERSITARIA DI BOLOGNA, 40138 BOLOGNA, ITALY; (e) CARDIOVASCULAR CENTER AALST, OLVC-CLINIC, AALST, BELGIUM

Background. Cardiac transplantation is the definitive therapy for eligible patients with end-stage heart failure. The major limitations to survival in the post-transplant period are nonspecific graft failure, acute rejection and infection. Nowadays the standard method for surveillance of cellular and antibody-mediated rejection is represented by cardiac catheterization with biopsy. Our purpose was to evaluate if a non-invasive technique such as CT coronary angiography (CCTA), through the use of fatty attenuation index (FAI) as radiological surrogate of the inflammation of pericoronary adipose tissue could predict the presence of cardiac rejection and long-term MACE.
Aims. to identify the role of CCTA and FAI in the detection of cardiac rejection and prediction of MACE in heart transplanted patients.
Methods. The present study is a single-center, observational retrospective cohort study. We included all the heart transplanted patients who underwent a CCTA as screening method for cardiac allograft vasculopathy between 2016 and 2022. We used a specific software to measure FAI around the proximal 4 cm segments of the left anterior descending artery, right coronary artery, left circumflex artery and we used the mean value of FAI on the three coronary branches in order to identify the global cardiac inflammation. The FAI was analyzed at a threshold of –30 to – 190 Hounsfield units. We divided our population in "high FAI group'' and "low FAI group'' based on the cut off of -70 HU as previously reported. The correlation between elevated FAI values and the development of MACE during a mean follow-up of 40 months was evaluated. A sub-population of patients who underwent endomyocardial biopsy within six months from CCTA was used to demonstrate the usefulness of FAI in the non-invasive diagnosis of acute cellular and antibody-mediated cardiac rejection. We considered as relevant all the histological rejections>3A following the1990's classification.
Results. We enrolled 71 heart transplanted patients with at least one CCTA, 29 in the "high FAI group'' and 42 in the "low FAI group''. The baseline characteristics of the two populations were similar in term of major cardiovascular risk factors, sex, age and comorbidities. Patients with high FAI values had significantly high incidence of MACE compared to those with low FAI values (80% vs 20%, p-value 0,001) during the follow-up. In the population of 28 patients who performed CCTA and endomyocardial biopsy within six months, the "high FAI group'' manifested a higher prevalence of cellular and antibody-mediated cardiac rejection, compared to "low FAI group'', (78,6% vs 21,4% and 100% vs 0% respectively, p-value 0,008 and 0,001).
Conclusions. High baseline FAI values may identify a higher-risk cardiac transplant population with a greater number of MACE during the follow-up period. Furthermore, the presence of high FAI assessed by CCTA is associated with cardiac rejection. Thus, FAI may support the implementation of CCTA as trustworthy non-invasive tool in post-transplant surveillance.

A621: ANOMALOUS ORIGIN OF LEFT CIRCUMFLEX ARTERY FROM THE RIGHT SINUS OF VALSALVA: CLINICAL OUTCOMES IN A CONSECUTIVE SERIES OF MASTER ATHLETES

Blanca Prestini (a), Angelo Ratti (a, f), Davide Marchetti (f), Matteo Schillaci (f), Riccardo Terzi (a, f), Michele Gallazzi (a, f), Francesca Di Lenarda (a, f), Eleonora Melotti (f), Marco Doldi (f), Marta Belmonte (b, c), Saima Mushtaq (d), Edoardo Conte (f), Paolo Zeppilli (e), Antonio Bartorelli (f), Daniele Andreini (a, f)
(a) UNIVERSITÀ DEGLI STUDI DI MILANO - DIPARTIMENTO DI SCIENZE CLINICHE E DI COMUNITÀ; (b) CARDIOVASCULAR CENTER AALST -OLV HOSPITAL, BELGIUM; (c) UNIVERSITÀ FEDERICO II, NAPOLI - DIPARTIMENTO DI SCIENZE BIOMEDICHE E CLINICHE; (d) CENTRO CARDIOLOGIO MONZINO - MILANO; (e) UNIVERSITÀ CATTOLICA DEL SACRO CUORE - ROMA; (f) IRCCS OSPEDALE GALEAZZI SANT'AMBROGIO, CARDIOLOGIA UNIVERSITARIA - MILANO

Purpose. Aim of the study was to collect and describe a case series of consecutive master athletes in whom an anomalous origin of left circumflex artery (LCx) from the right sinus of Valsalva (ALCx) was detected at a clinically indicated coronary CT angiography CCTA) in order to establish a focused clinical management and counselling about sport activity in those subjects.
Methods. We analyzed a prospective registry of subjects referred to a clinically indicated CCTA. Information about the clinical status was obtained by previous clinical records and clinical evaluation at time of image acquisition; follow-up allowed to record symptoms, outcomes and downstream testing.
Results. The study population consisted in 14 subjects, of which one competitive athlete and 13 recreational master athletes. Mean age was of 67.2 ± 10.6 years (71% of male); follow-up lasted 6.4 ± 2.6 years. The major high-risk anatomy features (inter-arterial course, intramural segment, high take-off and slit-like ostium) were absent. None had abnormal ostial morphology and all had full retroaortic course; three subjects (21%) presented an acute take-off angle. CAD was present in 10 patients (71%). Major outcomes (cardiac hospitalization, death for all causes) recorded were not related to the anomalous LCx. Symptoms were most related to atherosclerotic CAD in different vessels whereas two subjects without CAD exhibited cardiac symptoms, without hospitalization.
Conclusions. Our study suggests that the diagnosis of ALCx, being usually associated to low-risk anatomical characteristics, could be considered a benign finding, with scarce or no implications for physically active individuals neither for recreational athletes.

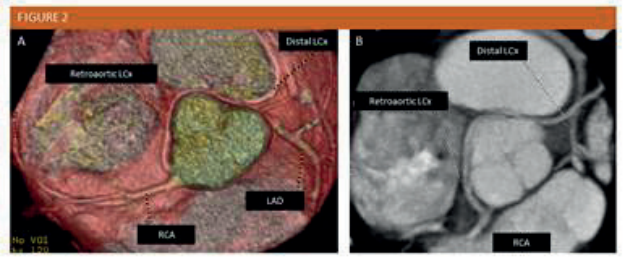

A622: A NOVEL APPROACH TO MEASURE SYNTHETIC EXTRACELLULAR VOLUME WITHOUT INVASIVE BLOOD SAMPLING: THE SHEVA-3T CMR STUDY

Anna Sorella (a), Cesare Mantini (a), Giandomenico Bisaccia (a), Melissa Foglietta (a), Darien Calvo Garcia (a), Luca D'Angelo (a), Valeria Di Mascio (a), Massimo Caulo (a), Giulia Renda (a), Sabina Gallina (a), Fabrizio Ricci (a)
(a) UNIVERSITÀ DEGLI STUDI GABRIELE D'ANNUNZIO, CHIETI

Background. Existing CMR methods for extracellular volume (ECV) measurement necessitate hematocrit level measurements which can be impractical in clinical settings. We aimed to derive and validate a multiparametric model for synthetic ECV assessment in clinical 3T CMR.
Methods. We recruited 505 consecutive patients undergoing clinical 3T CMR exam with <48h hematocrit sampling. Participants were randomly split into derivation (n=405) and validation (n=100) cohorts. Native T1 was measured in both left ventricular (LV) and right ventricular (RV) blood pools. We derived and validated a multiparametric model for synthetic hematocrit estimation, including covariates selected by multivariate linear regression analysis. Conventional ECV was calculated using standard blood hematocrit value. Synthetic ECVs were obtained from LV and RV T1 values using Fent's equation, and from the 4-factor synthetic hematocrit. We assessed the correlation, agreement, accuracy of classification and trueness between synthetic and conventional ECVs.
Results. In the derivation cohort, sex, heart rate, LV and RV native T1 values were selected as independent predictors of hematocrit and built-in a 4-factor model. The 4-factor synthetic hematocrit showed better correlation with blood sampling than LV and RV synthetic hemato-

crits (R^2:0.380; R^2:0.341; R^2:0.316, respectively). The 4-factor ECV model showed good correlation with conventional ECV, similar to LV and RV ECVs (R^2:0.834, R^2:0.823, R^2:0.815, respectively), yet yielding the lowest bias (4-factor ECV:-0.024; RV-ECV:-0.162; LV-ECV:-1.067). These findings were confirmed in the validation cohort (4-factor ECV: R^2:0.835; bias:-0.26; LV-ECV: R^2:0.807; bias:-0,38; RV-ECV: R^2:0.777; bias:-1.22). The 4-factor model exhibited substantial agreement (Cohen's kappa: 0.64) and trueness compared with conventional ECV.

Conclusions. The novel 4-factor synthetic model improves precision and trueness for hematocrit and ECV estimation. Our findings support broader utilization of synthetic ECV in 3T setting, obviating the need for invasive blood sampling while ensuring clinical accuracy and reliability.

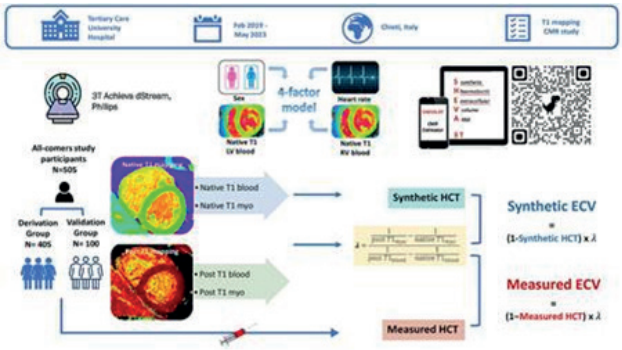

A623: INCREMENTAL PROGNOSTIC VALUE OF EFFECTIVE REGURGITANT ORIFICE AREA AND RIGHT ATRIAL STRAIN IN PATIENTS WITH ATRIAL SECONDARY TRICUSPID REGURGITATION

Alessandra Rota (a, c), Michele Tomaselli (a, c), Denisa Muraru (a, c), Alexandra Clement (d), Marco Penso (a), Noela Radu (e), Francesco Paolo Perelli (a, c), Andrea Cascella (a, c), Mara Gavazzoni (a), Antonio Sorropago (b), Sergio Caravita (a, c), Claudia Baratto (a), Samantha Fisicaro (a), Cristina Giannattasio (c), Gianfranco Parati (a, c), Luigi Badano (a, c)

(a) DEPARTMENT OF CARDIOLOGY, IRCCS ISTITUTO AUXOLOGICO ITALIANO, MILAN, ITALY; (b) DEPARTMENT OF CARDIOLOGY, POLICLINICO DI MONZA, MONZA, ITALY; (c) DEPARTMENT OF MEDICINE AND SURGERY, UNIVERSITY OF MILANO BICOCCA, MILAN, ITALY; (d) INTERNAL MEDICINE DEPARTMENT, "GRIGORE T. POPA", UNIVERSITY OF MEDICINE AND PHARMACY, IASI, ROMANIA; (e) CAROL DAVILA UNIVERSITY OF MEDICINE AND PHARMACY, PROF. DR. C. C. ILIESCU INSTITUTE, BUCHAREST, ROMANIA

Background. Although atrial-secondary tricuspid regurgitation (A-STR) is associated to more favorable prognosis compared to ventricular-secondary tricuspid regurgitation (V-STR), a significant proportion of A-STR patients experiences adverse cardiovascular outcomes. In these patients, the prognostic impact of right ventricular (RV), right atrial (RA), and right ventricle–to–pulmonary artery (RV-PA) coupling remains to be elucidated. Thus, the aims of our study were: i) to confirm the difference in prognosis between A-STR and V-STR, and ii) evaluate the prognostic significance of the interaction between A-STR severity and right heart function.

Methods. Consecutive outpatients with STR (ranging from mild to severe) were prospectively enrolled in the FUTURE 3DE study (ClinicalTrials.gov identifier: NCT05747404). STR severity was evaluated with the Doppler PISA method corrected for both the angle subtended by tricuspid valve leaflets and the relative low flow velocities. The RV function was assessed by RV ejection fraction obtained from the three-dimensional echocardiography (3DE) RV volumes. RA longitudinal strain (RAS) by 2D-speckle tracking echocardiography was used to measure RA function. The RV-PA coupling was evaluated using 3DE and computed as the ratio between RV forward stroke volume (fSV) (RV SV – regurgitant volume) and RV end-systolic volume (ESV) (fSV/ESV). The primary endpoint was a combined of heart failure hospitalization and cardiovascular death.

Results. 513 patients (mean age 75±13 years, 53% female, 41% atrial fibrillation, 38% atrial STR, 58% severe STR) were included in the final cohort. After a mean follow-up of 18±15 months, 195 patients (38%) reached the combined endpoint. Patients with V-STR had 2-fold increased risk of events compared to A-STR [hazard ratio (HR) 1.9, confidence interval (CI) 95% (1.42-2.53). A logistic regression model showed that worsening in A-STR severity (or 0.1 cm^2 increase of EROA) was associated with an increased likelihood of experiencing the composite outcome. The Kaplan-Meier curves demonstrated a higher rate of events for patients with V-STR vs A-STR (event rate at 2 years 50±7% vs 27±6%, log-rank <0.0001). After dividing the population into four groups according to STR etiology (A-STR vs. V-STR) and severity (effective regurgitant orifice area, EROA ≤0.4cm^2 and>0.4cm^2), we found that patients with V-STR and EROA>0.4 cm^2 had the highest rate of events. Conversely, patients with A-STR and EROA ≤0.4cm^2, showed the lowest rate of events respectively (event rate at 2 years 60±5% vs. 14±6%, respectively, log-rank <0.0001). Interestingly, patients with V-STR and EROA ≤0.4cm^2 and patients with severe A-STR experienced a similar cumulative rate of events (39±6% vs 43±3%, respectively, p=0.35). To further analyze the predictors of prognosis in patients with severe A-STR, we performed a Cox multivariate analysis with adjustment for RVEF and fSV/ESV, showing that RAS was the only parameter independently associated to outcomes [HR 0.97, CI95% (0.93-0.99), p=0.03].

Conclusions. Our data confirms that in patients with severe A-STR, RA function is an independent determinant of prognosis, potentially helping to identify those at increased risk of mortality or HF hospitalization. Moreover, they affirmed that patients with V-STR tendencially have a worse prognosis than those with A-STR.

A624: TIMING AND PATIENTS' POSITION DURING CUFF BLOOD PRESSURE MEASUREMENT AFFECTS MYOCARDIAL WORK PARAMETERS MEASURED BY ECHOCARDIOGRAPHY

Samantha Fisicaro (b), Michele Tomaselli (a, b), Marco Penso (b), Andrea Cascella (a, b), Alessandra Rota (a), Alessandro Menna (a), Cristina Ginnatasio (a), Gianfranco Parati (a, b), Denisa Muraru (a, b), Alexandra Clement (a, c), Luigi Badano (a, b)

(a) DEPARTMENT OF MEDICINE AND SURGERY, UNIVERSITY OF MILANO-BICOCCA,MILAN,ITALY; (b) DEPARTMENT OF CARDIOLOGY, ISTITUTO AUXOLOGICO ITALIANO, IRCCS, MILAN, ITALY; (c) INTERNAL MEDICINE DEPARTMENT, "GRIGOTR T.POPA", UNIVERSITY OF MEDICINE AND PHARMACY, IASI, ROMANIA

Background. Myocardial work (MW) is an emerging tool in echocardiography introduced to provide a more load-independent measure of left ventricular (LV) performance by incorporating afterload determination using cuff blood pressure. MW has been evaluated in a variety of clinical conditions to assess its added value compared to conventional parameters of LV performance, such as LV ejection fraction and global longitudinal strain (GLS). However, although cuff blood pressure measurement is a critical parameter to calculate MW noninvasively, there is no recommendation about when and how to measure it.

Aims. To evaluate the effects of the timing during the echo study and the patient's position on the scanning bed during the cuff blood pressure measurement on MW parameters' calculations.

Methods. 101 consecutive patients (44 women, 66±14 years) undergoing clinically indicated echocardiography were prospectively enrolled. During the echocardiographic study, the cuff blood pressure was measured 4 times using a fully automatic digital blood pressure monitor (Omron M3W) applied to the right arm and left in the same position throughout the study: BP1, before the start of the echo study, with the patient lying in the supine position; BP2, after positioning the patients on his/her left side to start the echo study; BP3, at the time of the acquisition of the three LV apical views used to measured LV GLS; and BP4, at the end of the echo study with the patient again in the supine position. GLS and the MW parameters were obtained from the apical 4-, 2-chamber, and long-axis views optimized for the left ventricle using a dedicated software package (AFI, ECHOPAC BT 204, GE Healthcare, Horten, NO).

Results. Blood pressure at BP1 was the highest among the 4 measurements. There was a significant drop between BP1 and BP2 due to the higher position of the sphygmomanometer compared to the heart. BP3 was significantly lower than BP2, and BP4 was significantly lower than BP1, particularly in the subgroup of the 37 patients with hypertension (147/83 mm Hg vs 138/81 mm Hg; p<0.001). The average GLS was -16±3%. Accordingly, MW parameters resulted in significantly different values among the measurement time points (Table)

Conclusions. Our study shows that both the timing during the echocardiography study and the position of the patient on the scanning bed are critical determinants of the measured cuff blood pressure and the resulting values of MW parameters. A standardization of measuring the cuff blood pressure values used to compute MW is needed to allow meaningful comparisons among the different studies testing the prognostic value of MW in different cardiac conditions.

	BP1	BP2	BP3	BP4	*p* value
Systolic blood pressure (mm Hg)	147±21	130±20†	122±18†‡	138±18†‡§	<0.001
Diastolic blood pressure (mm Hg	83±13	71±19†	68±12†	81±12‡§	<0.001
Global work index (mmHg%)	1929±441	1717±421†	1602±351†‡	1815±386†‡§	<0.001
Global constructive work (mmHg%)	2343±510	2083±482†	1943±382†‡	2203±432†‡§	<0.001
Global wasted work (mmHg%)	127(84-193)	105 (81-179)†	96 (74-156)†	116 (82-201)†‡§	<0.001

Values are mean±SD or median (IQR). *The p values depict differences between blood pressures and are calculated by one-way repeated measures ANOVA and Friedman test for continuous data (with normal and non-normal distribution, respectively). †p<0.05 vs. BP1 with Bonferroni's post hoc analysis. ‡p<0.05 vs. BP2 with Bonferroni's post hoc analysis. §p<0.05 vs. BP3 with Bonferroni's post hoc analysis.

A625: CORRECTING THE RIGHT VENTRICULAR EJECTION FRACTION BY THE VOLUME OVERLOAD IMPROVES THE ASSOCIATION WITH OUTCOME IN PATIENTS WITH SECONDARY TRICUSPID REGURGITATION

Alexandra Clement (b, c), Michele Tomaselli (a, b), Samantha Fisicaro (a), Andrea Cascella (a, b), Mara Gavazzoni (a, b), Alessandra Rota (a, b), Claudia Baratto (a, b), Sergio Caravita (a, b), Marco Penso (a), Noela Radu (a), Francesco Perelli (a, b), Gianfranco Parati (a, b), Denisa Muraru (a, b), Luigi Badano (a, b)

(a) DEPARTMENT OF CARDIOLOGY, ISTITUTO AUXOLOGICO ITALIANO, IRCCS, MILAN, ITALY; (b) DEPARTMENT OF MEDICINE AND SURGERY, UNIVERSITY OF MILANO-BICOCCA. MILAN, ITALY; (c) INTERNAL MEDICINE DEPARTMENT, GRIGORE T. POPA UNIVERSITY OF MEDICINE AND PHARMACY, IASI ROMANIA

Background. The evaluation of right ventricular (RV) systolic function in presence of secondary tricuspid regurgitation (STR) is of paramount importance to stratify patients' prognosis and to refine the pre-operative risk assessment. However, the chronic volume overload determined by STR may lead to an overestimation of RV systolic function assessed by conventional echocardiographic parameters. Accordingly, to overcome this limitation, we explored the association with outcome of the effective RV ejection fraction (eRVEF) that takes into account the impact of STR regurgitant volume (RegVol) on RV function.

Aims. We sought to assess whether, in patients with STR, eRVEF is better associated to outcome than TAPSE, RVEF, and RV free-wall strain (RV-FWS).

Methods. Consecutive patients with STR (ranging from mild to severe) undergoing complete 2D/3D and speckle tracking echocardiography were included. eRVEF was calculated as: forward RV stroke volume (RV-SV)/RV end-diastolic volume, where forward RVSV was obtained by subtracting the STR RegVol to the total RVSV. The endpoint was a combined of heart failure hospitalization and cardiovascular death.

Results. 513 patients (mean age 75±13 years, 53% female, 41% atrial fibrillation, 38% atrial STR, 58% severe) were included in the final cohort. After a mean follow-up of 18±15 months, 195 patients (38%) reached the combined endpoint. At receiver operating characteristic analysis, the association with outcome of eRVEF (AUC 0.73, 95%CI 0.68-0.77) was stronger than that of RVEF (AUC 0.65, 95%CI 0.60-0.70, p=0.006), RV-FWS (AUC 0.63, 95%CI 0.58-0.68, p=0.003), and TAPSE (AUC 0.64, 95%CI 0.59-0.69, p=0.01). The spline curve of mortality risk within the STR cohort showed that the value of eRVEF where the excess events rate started to grow was at the threshold of 20%. The Kaplan-Meier curves demonstrated a higher rate of events for patients with eRVEF <20% (event rate at 2 years 65 ± 6% vs 22 ±7%, log-rank <0.0001). In addition, by dividing the cohort into 4 groups according to eRVEF (higher and lower than 20%) and RVEF (higher and lower than 45%) (Figure 3), we found higher cumulative event rates in patients with both eRVEF and RVEF reduced values (event rate at 2 years 74 ± 5%, log-rank <0.0001). At univariate Cox regression analysis, eRVEF ≤20% was associated with a 3-fold increased risk of experiencing the combined outcome (HR: 3.55 [2.62-4.80], p<0.0001). After adjustment for age, STR effective regurgitant orifice area, left ventricular ejection fraction, and NYHA class, eRVEF ≤20% (HR: 2.92 [2.04-4.19]) remained independently associated to the combined endpoint.

Conclusions. eRVEF, that takes into account the impact of the volume overload determined by STR RegVol on RVEF, was significantly more closely associated with the risk of cardiac death and heart failure hospitalization than conventional echocardiographic indexes of RV function in patients with STR.

A626: THE PROGNOSTIC IMPACT OF RIGHT VENTRICULAR FUNCTION AND RIGHT VENTRICULAR-TO-PULMONARY ARTERY COUPLING IN PATIENTS WITH NON-SEVERE SECONDARY TRICUSPID REGURGITATION

Michele Tomaselli (a), Denisa Muraru (a, b), Alexandra Clement (d), Marco Penso (a), Noela Radu (d), Francesco Paolo Perelli (a, b), Mara Gavazzoni (a), Andrea Cascella (a, b), Paolo Sprighetti (c), Giorgio Oliverio (a), Alessandra Rota (a, b), Giandranco Parati (a, b), Sergio Caravita (a), Claudia Baratto (a), Luigi Badano (a, b)

(a) DEPARTMENT OF CARDIOLOGY, ISTITUTO AUXOLOGICO ITALIANO, IRCCS, MILAN, ITALY; (b) DEPARTMENT OF MEDICINE AND SURGERY, UNIVERSITY OF MILANO-BICOCCA, MILAN, ITALY; (c) DEPARTMENT OF MEDICINE, DIVISION OF CARDIOLGY, UNIVERSITY OF VERONA, VERONA, ITALY; (d) INTERNAL MEDICINE DEPARTMENT, 'GRIGORE T. POPA', UNIVERSITY OF MEDICINE AND PHARMACY, IASI, ROMANIA

Background. Although severe secondary tricuspid regurgitation (STR) is associated with a dismal prognosis, scant evidence suggests that even patients with mild/moderate STR could experience an increasing excess of cardiovascular events. In these patients, right ventricular (RV) function, and right ventricle–to–pulmonary artery (RV-PA) coupling may play a critical role in determining prognosis.

Aims. We sought to explore the association with outcome of non-severe STR by stratifying the risk across advanced parameters of RV function and RV-PA coupling.

Methods. This is a retrospective analysis of echocardiographic exams obtained from consecutive outpatients with STR (ranging from mild to severe). STR severity was evaluated measuring the effective regurgitant orifice area (EROA) using the PISA method corrected for both the angle subtended by tricuspid valve leaflets and the relative low velocities of the regurgitant jet. The RV function was assessed by calculating the RV ejection fraction (RVEF) from 3D echocardiography RV volumes, and RV free-wall longitudinal strain (RV-FWLS) by 2D speckle-tracking echocardiography. The RV-PA coupling was evaluated using 3 different indices: tricuspid annular plane systolic excursion (TAPSE)/pulmonary artery systolic pressure (PASP), RV-FWLS/PASP, and as the ratio between RV forward SV (fSV) (RV SV – regurgitant volume) and RV end-systolic volume (ESV) (fSV/ESV). The primary endpoint was a combined of heart failure hospitalization and cardiovascular death.

Results. 513 patients (mean age 75±13 years, 53% female, 41% atrial fibrillation, 38% atrial STR, 58% severe) were included in the final cohort. After a mean follow-up of 18±15 months, 195 patients (38%) reached the combined endpoint. The spline curve of mortality risk within the STR cohort showed that the value of EROA where the excess events rate started to grow was at the threshold of 0.47 cm^2. The Kaplan-Meier curves demonstrated a higher rate of events for patients with EROA≥0.47 cm^2 vs <0.47 cm^2 (event rate at 2 years 58±4% vs 30±3%, log-rank <0.0001). Non-severe STR (EROA <0.47 cm^2) was associated with a dismal outcome only in patients with impairment of both RV function [RVEF <45% and RV-FWS <21% (event rate at 2 years 56±6% and 63±5%)] and RV-PA coupling [fSV/ESV <0.42%, RV-FWS/PASP<0.48%mmHg, and TAPSE/PASP<0.45 mm/mmHg (event rate at 2 years 53±6%, 56±5% and, 61±5%)]. Conversely, the risk of events was relative reduced in patients with preserved RV function and normal RV-PA coupling. Finally, in patients with non-severe STR (EROA<0.47 cm^2) only age (0.01) and RVEF (p=0.001) remained independently associated to outcomes.

Conclusions. In patients with non-severe STR (according to EROA threshold risk values) the assessment of RV function could further stratify the risk of adverse events potentially identifying those at higher risk of either admission for heart failure or cardiovascular death.

A627: ASSOCIATION OF CORONARY COMPUTED TOMOGRAPHY ANGIOGRAPHY AND STRESS ECHOCARDIOGRAPHY WITH LONG TERM CARDIAC OUTCOME; A COMPARISON STUDY.

Domenico Tuttolomondo (a, b), Nicola Gaibazzi (b), Carmine Pizzi (c, d), Giampaolo Niccoli (a, b)

(a) UNIVERSITÀ DEGLI STUDI DI PARMA, PARMA, ITALY; (b) AZIENDA OSPEDALIERO UNIVERSITARIA DI PARMA, PARMA, ITALY; (c) UNIVERSITÀ DEGLI STUDI DI BOLOGNA, BOLOGNA, ITALY; (d) UNITÀ DI CARDIOLOGIA, IRCCS AZIENDA OSPEDALIERO UNIVERSITARIA DI BOLOGNA, BOLOGNA, ITALY

Aims. This study aimed to assess which variables on coronary computed tomography angiography (CTA) and vasodilator stress-echocardiography (SE) are best associated with long-term cardiac outcome in patients presenting for suspected chronic coronary syndrome (CCS) who performed both tests.

Methods. We identified 397 patients with suspected CCS who, between 2007 and 2019, underwent both SE and CTA within 30 days. Coronary artery calcium score (CACS) and the number of coronary arteries with diameter stenosis>50% were assessed on CTA. The presence of reversible regional wall motion abnormalities (RWMA) and reduced Doppler coronary flow velocity reserve in the left-anterior descending coronary artery (CFVR) were assessed on SE. The association of SE and CTA variables with cardiac outcome (cardiac death or myocardial infarction) was evaluated using Fine and Gray competing risk models.

Results. During a median follow-up of 10 years, 38 (9.6%) patients experienced a nonfatal myocardial infarction and 19 (4.8%) died from a cardiac cause. RWMA (HR 7.189, p<0.001) and a lower CFVR (HR 0.034, p<0.001) on SE, along with CACS (HR 1.004, p<0.001) and the number of>50% stenosed coronary vessels (HR 1.975, p<0.001) on CTA, were each associated with cardiac events. After adjusting for covariates, only CACS and CFVR remained associated (both p<0.001) with cardiac outcome.

Conclusions. Our data suggest that only CFVR on vasodilatory SE and CACS on CTA are independently and strongly associated with long-term cardiac outcome, unlike RWMA or the number of stenosed coronary arteries, usually considered the hallmarks of coronary artery disease on each test.

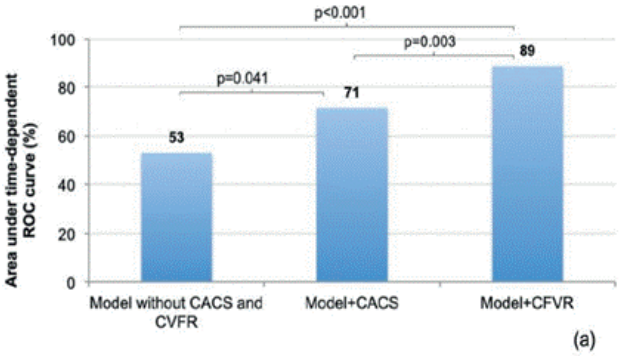

A628: BLOOD-BASED TRANSCRIPTIONAL SIGNATURES AT HOSPITAL ADMISSION ARE ASSOCIATED WITH CARDIAC MAGNETIC RESONANCE MARKERS OF STEMI PATIENTS

Andrea Baggiano (a), Luca Piacentini (a), Mattia Chiesa (a), Chiara Vavassori (a), Valentina Milazzo (a), Giancarlo Marenzi (a), Saima Mushtaq (a), Fabio Fazzari (a), Laura Fusini (a), Riccardo Maragna (a), Daniele Junod (a), Alberico Del Torto (a), Francesco Cannata (a), Andrea Igoren Guaricci (b), Gualtiero Ivanoe Colombo (a), Gianluca Pontone (a)
(a) CENTRO CARDIOLOGICO MONZINO IRCCS, MILAN, ITALY; (b) UNIVERSITÀ DEGLI STUDI DI BARI ALDO MORO, BARI, ITALY

Background. While mortality following ST-segment elevation myocardial infarction (STEMI) is declining, the number of patients developing heart failure due to STEMI is on the rise. Cardiovascular magnetic resonance (CMR) has emerged as an important imaging modality for assessing parameters of the short-term outcome, which add incremental prognostic value above traditional outcome markers alone in acute reperfused STEMI. Prognostic relevant pathways of leukocyte involvement in STEMI outcome are largely unknown. We sought to identify a set of circulating cellular transcripts measured on hospital admission that predict the short-term outcome of STEMI patients as assessed by CMR markers.
Methods. Thirty consecutive patients (24 males, 6 females, age 61 ± 10 years) admitted with STEMI at our Centre between 2012 and 2015 were enrolled in this retrospective pilot study. The whole-blood transcriptome was analysed by RNA-sequencing using total RNA isolated from peripheral blood samples drawn on hospital admission. Patients were studied with a 1.5T MR scanner within 1 week after primary PCI, and late gadolinium enhancement (LGE) mass and myocardial salvage index (MSI) were measured. K-means clustering was performed to group the samples according to the distribution of values of each CMR variable (i.e., high, medium, and low levels). We used the generalized negative binomial linear model approach with the edgeR package to perform gene-level differential expression analysis among the 3 groups of each CMR variable. To infer the biological functions of genes associated with CMR parameters, we used Gene Ontology Biological Processes terms for Gene Set Enrichment Analysis. To identify the smallest set of genes that can discriminate between groups of patients, we exploited a class of adaptive heuristic search algorithms using the GARS package.
Results. We identified specific gene expression patterns at baseline associated with high, medium, or low LGE and MSI values at 1-week follow-up. The most representative processes associated with high values of LGE were suggestive of adaptive immune response mediated by T- and B-cells, while innate immune response pathways were associated with medium-lower LGE values. We observed an association of low MSI values with adaptive immune response processes; high-medium values of MSI were, instead, associated with inflammatory-related functions. As for predictors of CMR surrogate markers of patient's outcome, we identified a set of 13 genes that classified the three LGE mass groups with an accuracy of 91%. Similarly, we identified 13 specific genes that discriminated the three MSI groups with a 100% accuracy.
Conclusions. We unveiled through RNA-sequencing data mining a set of informative transcriptional features that predict CMR phenotypes after STEMI. Overall, our results could pave the way for the identification of novel blood-based biomarkers to improve early prognosis and therapeutic decision-making in STEMI.

A629: QUANTIFICATION OF EXTRACELLULAR VOLUME WITH CARDIAC COMPUTED TOMOGRAPHY IN PATIENTS WITH DILATED CARDIOMYOPATHY

Andrea Baggiano (a), Edoardo Conte (b), Saima Mushtaq (a), Andrea Annoni (a), Alberto Formenti (a), Maria Elisabetta Mancini (a), Laura Fusini (a), Luigi Tassetti (a), Alessandra Volpe (a), Francesca Marchetti (a), Fabio Fazzari (a), Riccardo Maragna (a), Daniele Junod (a), Alberico Del Torto (a), Francesco Cannata (a), Daniele Andreini (b), Andrea Igoren Guaricci (c), Gianluca Pontone (a)
(a) CENTRO CARDIOLOGICO MONZINO IRCCS, MILAN, ITALY; (b) IRCCS GALEAZZI-SANT'AMBROGIO HOSPITAL, MILAN, ITALY; (c) UNIVERSITÀ DEGLI STUDI DI BARI ALDO MORO, BARI, ITALY

Background. Cardiac computed tomography (CCT) was recently validated to measure extracellular volume (ECV) in the setting of cardiac amyloidosis, showing good agreement with cardiovascular magnetic resonance (CMR). However, no evidence is available with a whole-heart single source, single energy CT scanner in the clinical context of newly diagnosed left ventricular dysfunction. Therefore, the aim of this study was to test the diagnostic accuracy of ECV_{CCT} in patients with a recent diagnosis of dilated cardiomyopathy, having ECV_{CMR} as the reference technique.
Methods. 39 consecutive patients with newly diagnosed dilated cardiomyopathy (LVEF <50%) scheduled for clinically indicated CMR were prospectively enrolled. Myocardial segment evaluability assessment with each technique, agreement between ECV_{CMR} and ECV_{CCT}, regression analysis, Bland-Altman analysis and interclass correlation coefficient (ICC) were performed.
Results. Mean age of enrolled patients was 62 ± 11 years, and mean LVEF at CMR was 35.4 ± 10.7%. Overall radiation exposure for ECV estimation was 2.1 ± 1.1 mSv. Out of 624 myocardial segments available for analysis, 624 (100%) segments were assessable by CCT while 608 (97.4%) were evaluable at CMR. ECV_{CCT} demonstrated slightly lower values compared to ECV_{CMR} (all segments, 31.8 ± 6.5% vs 33.9 ± 8.0%, p<0.001). At regression analysis, strong correlations were described (all segments, r=0.819, 95% CI: 0.791 to 0.844). On Bland-Altman analysis, bias between ECV_{CMR} and ECV_{CCT} for global analysis was 2.1 (95% CI: -6.8 to 11.1). ICC analysis showed both high intra-observer and inter-observer agreement for ECVCCT calculation (0.986, 95%CI: 0.983 to 0.988 and 0.966, 95%CI: 0.960 to 0.971, respectively).
Conclusions. ECV estimation with a whole-heart single source, single energy CT scanner is feasible and accurate. Integration of ECV measurement in a comprehensive CCT evaluation of patients with newly diagnosed dilated cardiomyopathy can be performed with a small increase in overall radiation exposure.

A630: ACUTE EFFECTS OF INTERRUPTION OF CARDIAC RESYNCHRONIZATION THERAPY ON LEFT VENTRICULAR MORPHO-FUNCTIONAL PARAMETERS AS ASSESSED BY CARDIAC MAGNETIC RESONANCE

Christian Basile (a), Alessandra Scatteia (b), Paolo Gallo (b), Salvatore Pezzullo (a), Carmine Pascale (b), Stefania Paolillo (a), Paola Gargiulo (a), Pasquale Perrone Filardi (a), Santo Dellegrottaglie (b)
(a) UNIVERSITY OF NAPLES "FEDERICO II"; (b) VILLA DEI FIORI HOSPITAL, ACERRA

Background. Cardiac resynchronization therapy (CRT) has become a standard treatment for patients with advanced heart failure with reduced ejection fraction (HFrEF) and left ventricular (LV) dyssynchrony. Both immediate and long-term clinical and functional improvement have been reported after CRT implementation, as well as a decrease in the mortality and hospitalization rates. A more synchronous contraction leads to a better cardiac efficiency which may result into an increased LV systolic function and a reversal of adverse LV remodeling. Recently, it has been questioned whether, once LV function has improved and reverse LV remodeling has occurred, ongoing biventricular pacing can still be necessary.
Purpose. To assess by cardiac magnetic resonance (CMR) the acute effect on LV systolic function and dimensions of discontinuing CRT after at least six months of pacing in patients with HFrEF.
Methods. The study prospectively included a small cohort of patients with HFrEF (7 males and 1 female; mean age 63.7 ± 2.5 years; ischemic etiology in 50%) receiving an MR-conditional CRT device in accordance with the existing clinical guidelines. CMR examinations have been performed before (pre-CRT) and>6 months after CRT implantation (post-CRT). Each follow-up CMR study included two full sets of cine images for the evaluation of LV systolic function and volumes obtained, respectively, before (post-CRTON) and after (post-CRTOFF) disabling the CRT therapy function on the implanted device. To warrant patient safety, each post-CRT CMR study was performed following institutional protocols based on specific guidelines for scanning patients with MR-conditional cardiac implantable electronic devices (CIEDs).
Results. No adverse events or significant changes in the CIEDs parameters (including pacing and sensing thresholds and battery level) were recorded during the follow-up CMR studies. At post-CRT evaluation, CMR image quality was judged to be at least sufficient for analysis in all patients. As compared with the basal pre-CRT study, a significant increase in LVEF was detected at the post-CRTON CMR evaluation (28,1 vs 35,0%; p<0,05) (Figure), together with a clear trend towards a decrease in LV end-diastolic volume [LVEDV] (118.72 ± 11.00 mL vs. 107.5 ± 13.86 mL; p=n.s) and LV end-systolic volume [LVESV] (87.12 ± 9.40 mL vs. 71.125 ± 11.26 mL; p=n.s.). No relevant changes were detected when re-assessing the same LV parameters by CMR immediately after switching off the CRT function (post-CRTOFF study), with persisting increase in LVEF (37.9 ± 4.5%; p<0,05 vs. pre-CRT) and tendency towards decreased LVEDV (97.3 ± 12.3 mL; p=n.s. vs. pre-CRT) and LVESV (63.0 ± 11.4 mL; p=n.s. vs. pre-CRT).
Conclusions. These preliminary findings show that favorable changes induced on LV function and remodeling by prolonged CRT in HFrEF patients are not promptly lost after the interruption of the electrical therapy.



A631: LA SCINTIGRAFIA CON MIBG NEI PAZIENTI CON ESITI DI PREGRESSA MIOCARDITE

Erika Bertella (a), Alessandro Gad (a), Rocco Mollace (a), Flavia Nicoli (a), Maria Lo Monaco (a), Federico Marchini (a), Elona Collaku (a), Martina Gotti (a), Giuseppe Medolago (a), Alessandro Zanello (a), Elvis Brscic (a), Alberto Cremonesi (a)
(a) HUMANITAS GAVAZZENI BERGAMO

Background. Il largo impiego della risonanza magnetica cardiaca nella pratica clinica corrente ha consentito di identificare numerosi pazienti con evidenti danni da pregressa miocardite, nota o misconosciuta. Da anni il tema della fibrosi miocardica ha destato interesse, essendo stato dimostrata la sua chiara correlazione con eventi aritmici nell'ambito di vari setting clinici (dalla cardiopatia ischemica alla cardiopatia dilatativa a quella ipertrofica). La scintigrafia con MIBG è una metodica è già ampiamente utilizzata nei pazienti con indicazione ad impianto di defibrillatore o che abbiano avuto uno scompenso cardiaco, è un esame che si propone di valutare l'innervazione simpatica del miocardio quale indice della suscettibilità aritmica del tessuto miocardico.
Obiettivo dello studio. Mediante utilizzo di MIBG verificare il reale rischio aritmogenico delle cicatrici non ischemiche riscontrate in pazienti sintomatici o asintomatici.
Metodi. Pazienti selezionati retrospettivamente sulla base del riscontro in RM cardiaca di esiti fibrotici miocardici a pattern non ischemico compatibile con esito di miocardite (anche senza storia di chiara miocardite pregressa), vengono sottoposti a scintigrafia miocardica con MIBG con tecnica tomografica.
Risultati. Sono stati selezionati 22 pazienti (20M, 47±14 yo) che hanno eseguito RM dal 2019 ad oggi. Il motivo dell'indicazione alla RM è stato principalmente dettato dal riscontro di extrasistolia ventricolare ad un Holter ECG (n 12, 54%), 5 pazienti hanno effettuato l'esame in seguito ad un noto evento infettivo acuto (23%, di cui 3, 14% da infezione COVID-19), tutti sintomatici per toracoalgia in fase acuta, con riscontro di rialzo di hsTNI (valore medio 437 pg/ml). I dati di RM hanno mostrato presenza di volumi ventricolari nella norma (VS 80 ml/m2, VD 81 ml/m2) e frazione d'eiezione normale (rispettivamente 56% e 53%). I valori di T1 mapping nativo sono risultati in media pari a 1013 msec (vn 950-1050). I valori di T2 mapping sono risultati alterati nei 5 pazienti che hanno eseguito la RM in fase acuta (valore medio 57 msec), senza segmentarietà. In 3 pazienti concomitava versamento pericardico non tamponante. Tutti i pazienti presentavano LGE (9 subepi, 7 midwall, 6 patchy). Tutti i pazienti sono stati sottoposti a scintigrafia miocardica con MIBG (a distanza di almeno 6 mesi dall'evento acuto): solo un caso ha dato esito positivo. Si tratta di un paziente di 57 anni che presentava il quadro più grave sia dal punto di vista clinico (all'holter registrati più di 65000 BEV con plurimi run di TPSV) sia per il quadro RM di severa disfunzione ventricolare sinistra, VS lievemente dilatato e LGE midwall a livello del setto dove concomitavano aree di ipocinesia.
Conclusioni. La scintigrafia con MIBG si conferma uno strumento utile nell'inquadramento del rischio aritmico anche in pazienti con pregressa miocardite, ridimensionando il peso clinico del riscontro occasionale di LGE non ischemico che pare di per sé non essere correlato ad un profilo di rischio aumentato.

A632: MITRO-AORTIC INTERVALVULAR FIBROSA PSEUDOANEURYSM COMPLICATED WITH DOUBLE LEFT ATRIAL AND RIGHT VENTRICLE FISTULIZATION

Gabriella Bufano (a, b), Pietro Mazzeo (a, b), Rocco Paterno (c), Eugenio Stabile (a, b)
(a) CARDIOVASCULAR DEPARTMENT, AZIENDA OSPEDALIERA REGIONALE SAN CARLO, POTENZA, ITALY; (b) CARDIOLOGY DIVISION, SAN PIO DA PIETRELCINA HOSPITAL, AZIENDA OSPEDALIERA REGIONALE SAN CARLO, MARSICOVETERE, ITALY; (c) INTERNAL MEDICINE AND PNEUMOLOGY UNIT, SAN PIO DA PIETRELCINA HOSPITAL, AZIENDA OSPEDALIERA REGIONALE SAN CARLO, MARSICOVETERE, ITALY

A 56 year-old man was admitted to the Emergency Department for pulmonary edema. He underwent Bentall's procedure at the age of 49 years due to a severe aortic regurgitation in bicuspid aortic valve. Cardiac examination revealed an holosystolic murmur IV/VI at the apex, chest X-ray showed cardiomegaly with pulmonary congestion. ECG showed sinus tachycardia with left ventricular hypertrophy. Emergent transthoracic echocardiography (TEE) was performed, showing biventricular enlargement with left ventricular ejection fraction (LVEF) of 60%. A pulsatile echo-free space was detected between the posterior aortic annulus and anterior wall of left atrium. A double systolic flow was detected at Color Doppler examination which raised the suspicion of left atrial and right ventricle fistulization. Transesophageal echocardiography was performed immediately and confirmed the findings above mentioned. Surgical consult was requested, but the patient underwent cardiogenic shock unresponsive to medical treatment and died suddenly. Pseudoaneurysm of mitro-aortic intervalvular fibrosa (MAIVF) is an uncommon but catastrophic complication of prosthetic aortic valve endocarditis. Echocardiographic assessment shows a false lumen below the aortic valve annulus at the MAIVF, which expands during systole and collapses during diastole with an internal turbulence pattern at Color Doppler and an high velocity turbulent jet flow if complicated by fistulization. Although fistulization has been described into the left atrium, double fistulization into left atrium and right ventricle is extremely rare.

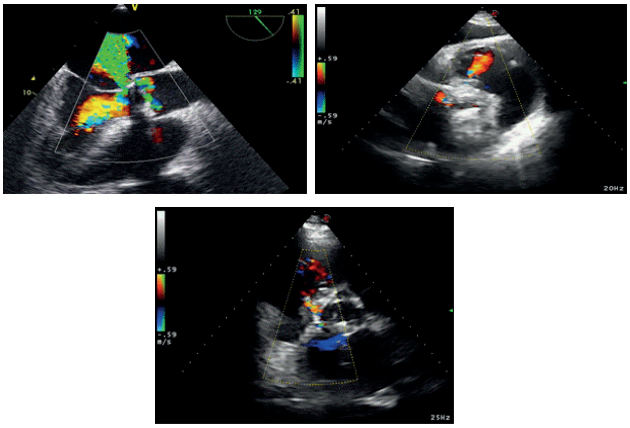

A633: A DEEP LEARNING APPROACH IN THE IDENTIFICATION OF MYOCARDIAL FIBROSIS FROM EARLY CONTRAST ENHANCED CARDIAC CT IMAGES

Maria Ludovica Carerj (b, f), Marco Penso (g), Marco Guglielmo (h), Mario Babbaro (d), Mauro Pepi (g), Enrico Caiani (e), Gianluca Pontone (f)
(a) CENTRO CARDIOLOGICO MONZINO; (b) UNIVERSITÀDEGLI STUDI DI MESSINA; (c) UNIVERSITÀ DI UTRECHT; (d) IRCSS POLICLINICO SAN DONATO; (e) ISTITUTO AUXOLOGICO ITALIANO; (f) DEPARTMENT OF PERIOPERATIVE CARDIOLOGY AND CARDIOVASCULAR IMAGING, CENTRO CARDIOLOGICO MONZINO, IRCSS; (g) DEPARTMENT OF CARDIOVASCULAR IMAGING, CENTRO CARDIOLOGICO MONZINO, IRCSS; (h) DEPARTMENT OF CARDIOLOGY, DIVISION OF HEART AND LUNGS. UTRECHT UNIVERSITY

Background. Late gadolinium enhancement (LGE) derived from cardiac magnetic resonance (CMR) has become a method of choice for the evaluation of myocardial tissue composition and detection of myocardial fibrosis. Advances in cardiac computed tomography (CCT) imaging have led to its growing role as possible alternative to CMR, because of its wider availability and suitability for patients with contraindication.
Purpose. To develop a myocardial fibrosis detection method from early contrast-enhanced CCT (CE-CCT) imaging using a deep learning (DL) approach.
Methods. Fifty consecutive patients (age: 62±10 y, male 84%) with known left ventricular dysfunction were enrolled. All patients underwent both LGE-CMR and early and delayed CE-CCT. According to the LGE-CMR patterns, patients were classified as ischemic (n=15, 30%) or non-ischemic (n=35, 70%). Scar regions were manually traced on delayed CE-CCT using LGE-CMR as reference. On early CE-CCT images, segments were extracted according to AHA 16-segment model and labeled (scar/no scar) based on the delayed CE-CCT manual tracing. A DL model was developed for automatic segmental classification.
Results. Based on 44187 segments analyzed, 71% of accuracy (ischemic: 66%; non-ischemic: 74%) for detecting scar on early CE-CCT images was achieved. In a per-segment analysis of the 16-segment AHA model, an accuracy of 91% (ischemic: 87%; non-ischemic: 93%) was obtained from early CE-CCT compared to the LGE-CMR.
Conclusions. DL on early CE-CCT acquisition may allow the detection of myocardial fibrosis, without additional contrast-agent administration or radiation exposure, thus reducing the user interaction and visual inspection with benefit in both efforts and time.

A634: VENTRICULAR ARRHYTHMIAS MORPHOLOGY IN MITRAL VALVE PROLAPSE: IS THERE A LINK WITH THE VALVE ANATOMY?

Annagrazia Cecere (a), Alberto Cipriani (a), Federico Migliore (a), Alessandro Zorzi (a), Manuel De Lazzari (a), Giulia Lorenzoni (b), Antonella Cecchetto (a), Giulia Brunetti (a), Francesca Graziano (a), Raimondo Pittorru (a), Raffaella Motta (c), Giorgio De Conti (c), Barbara Bauce (a), Domenico Corrado (a), Dario Gregori (b), Sabino Iliceto (a), Martina Perazzolo Marra (a)
(a) CARDIOLOGY UNIT; DEPARTMENT OF CARDIAC, THORACIC, VASCULAR SCIENCES AND PUBLIC HEALTH, UNIVERSITY OF PADUA, PADUA, ITALY; (b) UNIT OF BIOSTATISTICS, EPIDEMIOLOGY AND PUBLIC HEALTH; DEPARTMENT OF CARDIAC, THORACIC, VASCULAR SCIENCES AND PUBLIC HEALTH, UNIVERSITY OF PADUA, PADUA, ITALY; (c) RADIOLOGY UNIT, UNIVERSITY OF PADUA - AZIENDA OSPEDALIERA, PADUA, ITALY

Background. Mitral valve prolapse (MVP) may be associated with ventricular arrhythmias (VA), even in the absence of significant valvular regurgitation. Curling, mitral annulus disjunction (MAD) and myocardial fibrosis (late gadolinium enhancement, LGE) may account for arrhythmogenesis. VA arising from left ventricular basal inferolateral wall and papillary

muscles, site of MVP-induced fibrosis, present a typical morphology with right bundle branch block (RBBB) and dominant R waves in V1. We hypothesized that the presence of VA with RBBB morphology in MVP patients is expression of more severe mitral morpho-functional alterations.
Objectives. We investigated, in MVP patients without significant regurgitation, the role of morpho-functional abnormalities in the production of a specific VA pattern.
Methods. 108 MVP patients (66 females; median age: 48 years) without significant regurgitation were included. All patients underwent 12-lead ECG, 12-lead 24-hour ECG Holter, exercise stress test and cardiac magnetic resonance (CMR). Patients were divided into two groups (arrhythmic and no-arrhythmic MVP), according to the presence of VA with a RBBB pattern. According to the EHRA Expert Consensus Statement, in the arrhythmic MVP group, a subgroup with "severe" VA (ventricular tachycardia (VT) runs ≥180 bpm and/or history of sustained VT/ventricular fibrillation) was also identified.
Results. 62 patients (39 females; median age: 43 years) with arrhythmic MVP showed: i) higher MAD (median length: 6 versus 3.2 mm; p=0.017), ii) higher prevalence of curling (79% versus 52%), iii) higher prevalence of LV LGE (79% versus 52%; p=0.012). Patients with severe VA (34 patients; 23 females; median age: 42 years) showed more pronounced morpho-functional alterations, in terms of MAD (7.0 mm versus 4.6 mm, p=0.004) and presence and severity of curling (respectively, 91% versus 64%, p=0.010 and 4 versus 3 mm, p=0.004), compared to those without severe VA.
Conclusions. In MVP patients the occurrence of VA with RBBB morphology is the expression of more severe morphological, mechanical and tissue alterations.

A635: UN MODELLO DI DEEP LEARNING PER LA PREVENZIONE DEGLI EVENTI ARITMICI MAGGIORI NEI PAZIENTI AFFETTI DA CARDIOMIOPATIA DILATATIVA

Mattia Corianò (a), Corrado Lanera (a), Laura De Michieli (a), Martina Perazzolo Marra (a), Sabino Iliceto (a), Dario Gregori (a), Francesco Tona (a)
(a) UNIVERSITÀ DEGLI STUDI DI PADOVA, DIPARTIMENTO DI SCIENZE CARDIO-TORACO-VASCOLARI E SANITÀ PUBBLICA

Background. La previsione di eventi aritmici maggiori (MAEs) nei pazienti affetti da cardiomiopatia dilatativa (CMP-D) è un argomento molto dibattuto ed oggetto di numerose ricerche. Modelli computazionali e di intelligenza artificiale (AI) costituiscono delle tecnologie in grado di offrire un significativo miglioramento in termini di predizione di MAEs.
Obiettivi. In questo "proof-of-concept" proponiamo un prototipo di modello di deep learning, realizzato con l'obiettivo di predire e rappresentare una curva di rischio individuale di MAEs in pazienti affetti da CMP-D.
Metodi. In questo studio retrospettivo osservazionale sono stati raccolti dati di 154 pazienti affetti da CMP-D afferiti presso il nostro centro dal 2000 al 2019. Il modello è stato realizzato utilizzando dati multidimensionali di risonanza magnetica cardiaca (sequenze Cine in 3 e 4 dimensioni, immagini LGE in 2 e 3 dimensioni) e variabili cliniche. L'endpoint MAE è stato definito come composito di morte cardiaca improvvisa, arresto cardiaco da fibrillazione ventricolare, tachicardia ventricolare sostenuta o determinante instabilità emodinamica, scarica appropriata di defibrillatore cardiaco impiantabile. Il training e la validazione del modello sono avvenuti nel 70% del campione, ed il test nel restante 30%. La performance del prototipo è stata valutata mediante AUROC ed Harrell's C.
Risultati. Dopo 30 epoche di addestramento, il modello ha performato con un valore di Harrell's C di 0.42-0.77 nella fase di validazione e di 0.12-0.68 nella fase di test. La capacità di discriminazione del modello, espressa in termini di AUROC, è stata del 73.56% nella fase di validazione e del 60.12% nella fase di test.
Conclusioni. è stato realizzato un prototipo di modello di deep learning in grado di analizzare insieme il movimento cardiaco, le caratteristiche tissutali e le variabili cliniche determinando una stima del rischio di MAEs nei pazienti affetti da CMP-D. Esso rappresenta una novità nel campo della prevenzione della morte improvvisa nelle CMP-D. Una successiva fase di training con un dataset più esteso ed una validazione esterna sono necessarie per rendere tale prototipo un tool di utilità clinica largamente diffuso.

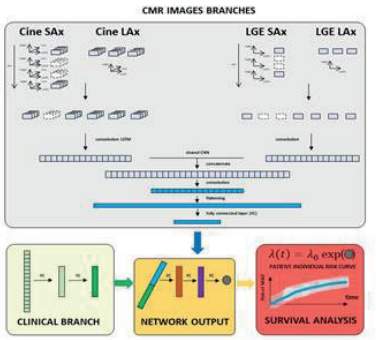



A636: UTILITÀ DELLA ANGIO CT CORONARICA NELLA VALUTAZIONE DELLA CAV DOPO TRAPIANTO CARDIACO

Elena Cozza (a), Nicola Pradegan (b), Carlo Maria Dellino (a), Filippo Amato (a), Maria Teresa Savo (a), Chiara Tessari (b), Irene Cao (b), Giorgio De Conti (c), Raffaella Motta (c), Gino Gerosa (b), Sabino Iliceto (a), Valeria Pergola (a), Giulia Mattesi (a), Francesco Tona (a)
(a) UNITÀ DI CARDIOLOGIA, DIPARTIMENTO DI SCIENZE CARDIO-TORACO-VASCOLARI E SANITÀ PUBBLICA, UNIVERSITÀ DEGLI STUDI DI PADOVA; (b) UNITÀ DI CARDIOCHIRURGIA, DIPARTIMENTO DI SCIENZA CARDIO-TORACO-VASCOLARI E SANITÀ PUBBLICA, UNIVERSITÀ DEGLI STUDI DI PADOVA; (c) UNITÀ DI RADIOLOGIA, DIPARTIMENTO DI MEDICINA, UNIVERSITÀ DEGLI STUDI DI PADOVA

Introduzione. La coronarografia con tomografia computerizzata (CCTA) si presenta come una promettente alternativa non invasiva nella valutazione della Coronary Allograft Vasculopathy (CAV) nei pazienti sottoposti a trapianto cardiaco ortotopico (OTC), offrendo vantaggi clinici ed economici rispetto alle tecniche invasive tradizionali.
Scopo dello studio. 1) valutare la non inferiorità della CCTA rispetto alla coronarografia (ICA); 2) analizzare il beneficio della strategia guidata dalla CCTA rispetto all'ICA in termini di costi, tempo di ospedalizzazione, dose di radiazioni, tempo di scopia e mezzo di contrasto somministrato (mdc).
Metodi. Da marzo 2021 a febbraio 2023, durante la pandemia correlata all'infezione da Sars-Cov2, per ridurre il numero di ospedalizzazioni e, alla luce dell'elevato valore predittivo negativo della CCTA, abbiamo eseguito il monitoraggio della CAV mediante la sola CCTA in circa il 50% dei pazienti sottoposti a OTC. Pertanto, abbiamo analizzato in modo retrospettivo i dati clinici, strumentali e di laboratorio di 260 pazienti cardio-trapiantati; 115 pazienti sono stati sottoposti a CCTA e 145 pazienti sono stati sottoposti ad ICA. Sono stati sottoposti preferenzialmente a CCTA i pazienti che avevano già eseguito il primo controllo angiografico post-OTC con ISHLT-CAV inferiore ad 1. Di questi due gruppi di pazienti abbiamo confrontato il dosaggio di radiazioni in mSv e di mdc, il tempo di scopia, il tempo di ospedalizzazione, i costi del ricovero e l'accuratezza diagnostica.
Risultati. Nessuna delle CCTA è risultata non valutabile e la visualizzazione dei tratti distali e delle diramazioni principali delle arterie epicardiche non è stata significativamente differente. L'accuratezza diagnostica è stata simile tra CCTA e ICA (95% versus 100%; p=0,169). CCTA e ICA non hanno mostrato differenze significative in termini di complicanze vascolari (0 versus 3; p 0.116). Rispetto all'ICA, la CCTA ha richiesto meno ore di ospedalizzazione (8.8 ± 0.8 ore versus 24.9 ± 13,2 ore; p<0,0001), costi inferiori (238 ± 0 euro/paziente versus 4252,54 ± 55993,63 euro/paziente; p<0,0001), minore utilizzo di mdc (59.7 ± 8.3 ml versus 96.6 ± 40.2 ml; p<0,001), un tempo significativamente inferiore di scopia (298 ± 255 secondi versus 359 ± 358 secondi; p 0.04) ed un minor numero di radiazioni emesse (3.8 ± 3.1 mSv versus 4.9+/-7.5 mSv; p 0.027).
Conclusioni. la CCTA si è dimostrata una metodica efficace e vantaggiosa per il follow-up dei pazienti sottoposti a TCO nella valutazione della CAV.

A637: LEFT ATRIO-VENTRICULAR COUPLING INDEX AS A PREDICTOR OF DIASTOLIC DYSFUNCTION IN PATIENTS AFTER MYOCARDIAL INFARCTION

Giulia De Zan (a, b), Philippe Van Rosendael (b), Kim Ricken-pierens (c), Gabija Pundziute (c), Ibrahim Danad (b), Arco Teske (b), Maarten Jan Cramer (b), Dirk Van Osch (b), Lysette Broekhuizen (b), Pim Van Der Harst (b), Erik Lipsic (c), Giuseppe Patti (a), Marco Guglielmo (b)
(a) DIPARTIMENTO CARDIO-TORACO-VASCOLARE, OSPEDALE MAGGIORE DELLA CARITÀ, NOVARA, ITALIA; (b) DIPERTIMENTO DI CARDIOLOGIA, UNIVERSITY MEDICAL CENTER UTRECHT, UTRECHT, PAESI BASSI; (c) DIPARTIMENTO DI CARDIOLOGIA, UNIVERSITY MEDICAL CENTER GRONINGEN, GRONINGEN, PAESI BASSI

Background. Following myocardial infarction (MI), patients with diastolic dysfunction (DD) and preserved left ventricular ejection fraction (LVEF) face a more adverse prognosis compared to those with similar-sized infarctions but no DD. While cardiovascular magnetic resonance (CMR) has not traditionally been considered for DD assessment, recent data suggest that parameters such as left atrium peak reservoir strain

(PRS) and the left atrio-ventricular coupling index (LACI) could serve as potential CMR markers for DD.

Methods. Our primary aim was to evaluate the predictive capabilities of CMR-derived LA strain and LACI for DD in post-MI patients. As a secondary objective, we sought to establish a correlation between CMR-derived LACI and echocardiography-derived LACI. Patients for this prospective study were identified from the image database of the Groningen Intervention study for the Preservation of cardiac function with STS after STEMI (GIPS-IV) trial. We used the data of 146 patients who underwent CMR and echocardiography on the same day and after 4 months from the MI. For both CMR and echocardiography, LACI was calculated as the LA end-diastolic volume divided by the LV end-diastolic volume. PRS was measured using feature tracking CMR. Echocardiography was used to assign patients to different grades of DD according to the algorithm for the assessment of diastolic function recommended by the American Society of Echocardiography and the European Association of Cardiovascular Imaging.

Results. A grade of DD>1 was detected in 15 (10%) of the patients. Patients with DD>1 exhibited significantly larger LV and LA volumes in both imaging methods, while their LVEF was notably lower. CMR-measured LA strain (21.1 ± 3.7% vs. 15.4 ± 7.6%, p=0.025) and LACI on both CMR (0.21 ± 0.11 vs. 0.34 ± 0.13, p<0.001) and echocardiography (0.27 ± 0.10 vs. 0.39 ± 0.14, p<0.001) were respectively lower and higher in the group of patients with DD. In univariable analysis, LV volumes, LA volumes, LVEF, and LACI measurements from both echocardiography and CMR were associated with a grade of DD>1. Regarding CMR parameters, LA reservoir strain, LA EF, global and radial longitudinal strain, ECV, and the extent of LGE all showed significant associations with DD. However, in multivariate analysis, only LACI from both CMR (OR=1.157, 95% CI: 1.036-1.292, p=0.010) and echocardiography (OR=1.109, 95% CI: 1.019-1.206, p=0.016) emerged as independent predictors of DD>1. Receiver Operating Characteristic (ROC) curves demonstrated an AUC of 0.849 for CMR-LACI and 0.784 for echo-LACI (see Figure).

Conclusions. LACI measured on CMR and on transthoracic echocardiography is an independent predictor of DD. LACI can represent an easy and fast parameter to help assessing DD in post MI patients.

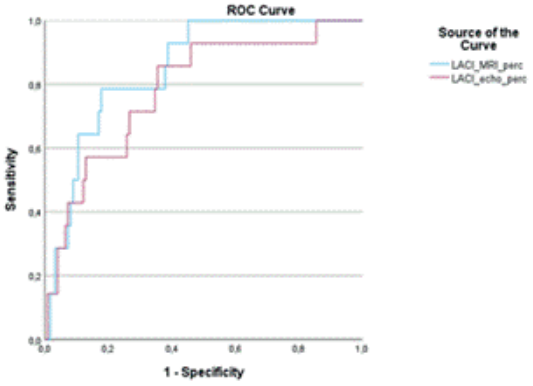

A638: AN ATYPICAL CASE OF NON-EPICARDIAL MINOCA

Gabriella Di Giovine (a), Alberto Cereda (a), Gabriele Franchina (a), Alessandro Minardi (a), Matteo Rocchetti (a), Cristina Conca (a), Silvia Tresoldi (b), Barbara Conconi (a), Maurizio Cariati (b), Stefano Lucreziotti (a)

(a) CARDIOVASCULAR DEPARTMENT, ASST SANTI PAOLO E CARLO, MILANO; (b) DIAGNOSTIC AND INTERVENTIONAL RADIOLOGY CENTER, ASST SANTI PAOLO E CARLO, MILANO

A 76-year-old woman with metabolic syndrome presented to the emergency department with chest pain after a violent argument with her husband. EKG showed sinus rhythm, qs in D3 and AVF, with poor R wave progression in antero septal leads and no ST-T wave abnormalities (Figure 1).

Echocardiography. revealed an ejection fraction (EF) of 55% with akinesia of mid and apical interventricular septum. Troponin was on the rise and the patient was taken for catheterization on suspicion of ACS.

Coronary angiography showed healthy coronary arteries, with the exception of a mild grade stenosis of mid left anterior descending artery (LAD) and ventriculography confirmed akinesia of mid and apical interventricular septum (IVS) with hyperkinesia of the remaining medium and basal segments (Figure 2). Clinical history and coronary findings suggested the diagnosis of atypical (focal) Takotsubo cardiomyopathy (TC) but in the presence of wall motion abnormality (WMA) in the distribution area of LAD the doubt of MINOCA of epicardial coronary cause remained. During observation in Cardiac Unit EKG changes with T wave inversion from v1 to v6 and in D3 and AVF (Figure 3), but the patient remained asymptomatic and stable. There was a simultaneous echocardiographic improvement.

Cardiac magnetic resonance. (CMR) showed normal EF without WMA, T2w and T2 mapping sequences presented diffuse edema of anterior, septal and inferior mid and apical segments with smoldering LGE in the same parts (Figure 4). Ventricular function recovery, WMA regression and large extension of edema, not matching with one vessel disease aborted myocardial infarction (AMI), validated the hypothesis of TC with an atypical focal presentation, but interestingly with a more typical extension of edema at CMR. The patient was then discharged with no more DAPT.

Conclusions. Our final diagnosis, thanks to CMR, was of an atypical form of TC with a focal pattern at presentation.

Discussion. The diagnosis of type 2 myocardial infarction is increasing, and distinctions between types of MINOCA have prognostic and therapeutic significance. In the presence of atypical presentations, CMR offers diagnostic accuracy and can clarify etiology in the sub-distinctions of MINOCA. In doubtful cases, respecting the Hippocratic hierarchy "diagnosis first, then therapy", CMR offers accuracy and discriminate between "epicardial and non-epicardial" MINOCA with benefit for the patient who is treated with the best evidence-based therapy.

Bonus track for CMR lovers. Our case appears at a first sight, using only echocardiographic data and ventriculography, a focal TC, however CMR revealed a larger extension of the reversible damage with a more common distribution involving the mid and apical segments saving only the lateral wall. Finally, an additional challenge must be highlighted: in our case both T2w and LGE sequences were positive, this is not typical of standard TC presentation, characterized by the presence of edema and the absence of LGE. However, in literature, analogous cases have been described, with no difference in function recovery. Nevertheless, it usually happened when CMR is acquired in the acute setting and is associated with a significantly lower LGE signal intensity in TC patients than in STEMI patients.

A639: QUANTIFICATION OF MITRAL REGURGITATION IN MITRAL VALVE PROLAPSE BY 3D VENA CONTRACTA AREA: DERIVED CUT-OFF VAUES AND COMPARISON WITH 2D MULTIPARAMETRIC APPROACH

Giorgio Fiore (a), Giacomo Ingallina (a), Francesco Ancona (a), Carlo Gaspardone (a), Federico Biondi (a), Davide Margonato (a), Michele Morosato (a), Martina Belli (a), Annamaria Tavernese (a), Stefano Stella (a), Eustachio Agricola (a)

(a) IRCCS OSPEDALE SAN RAFFAELE - CARDIOVASCULAR IMAGING UNIT

Background. Echocardiographic quantification of mitral regurgitation (MR) severity grade in mitral valve prolapse (MVP) is challenging and an integrative multiparametric approach is suggested by current guidelines. 3D vena contracta area (3D VCA), derived by 3D color-Doppler echocardiography, has been proposed as alternative method. However, data defining the cut-off values of severity and validation in the subset of patients with MVP are scarce.

Aims. To validate the 3D VCA method, derived by 3D transesophageal color-Doppler echocardiography (3D-TEE), in a large cohort of patients with MVP, in order to define the cut-off values of severity grading using 2D multiparametric approach as reference standard.

Methods. 1138 patients with at least moderate MR who underwent TEE were included. 3D VCA and EROA-PISA were measured, the cut-off values for the prediction of severe MR were estimated by receiver operating curve (ROC) and areas under the curve (AUC) were compared. Guideline-suggested multiparametric approach was used as reference standard.

Results. 3D VCA was significantly larger than EROA-PISA (0.63 cm2 vs 0.44cm2 p<0.05). Pearson's test showed a good linear correlation between 3D VCA and EROA-PISA (r=0.62, p<0.05). 3D VCA had an AUC of 0.95 (0.93 – 0.95); EROA-PISA an AUC of 0.95 (0.93 – 0.96). No significant differences in AUCs were found (p>0.05). Optimal cut-off values for the prediction of severe MR were 0.45cm2 for 3D VCA (specificity 0.87; sensitivity 0.90) and 0.37cm2 for EROA-PISA (specificity 0.94; sensitivity 0.85). Using the guideline-suggested cut-off value of 0.40cm2 for EROA-PISA as reference, 3D VCA showed an AUC of 0.84 (0.80 – 0.89) with an optimal cut-off value of 0.5cm2 (sensitivity 0.78, specificity 0.78).

Conclusions. The data of the present study suggest 0.45 cm2 as the best cut-off value of 3D VCA to define severe MR in patients with MVP. 3D VCA showed an optimal agreement with the reference standard multiparametric approach.

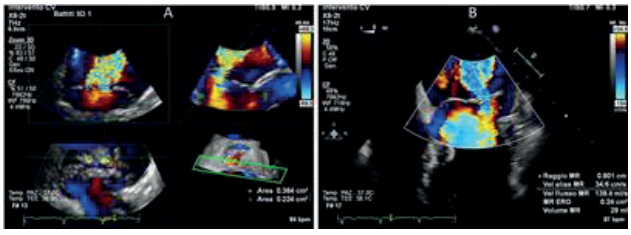

Figure 1. 3D VCA vs EROA-PISA.

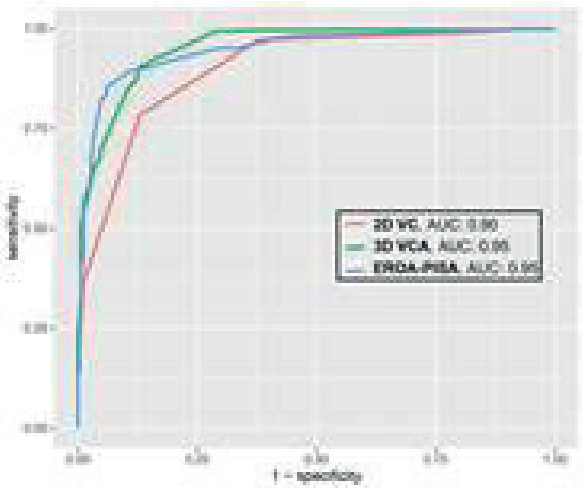

Figure 2. Best cut-off values according to ROC curves.

A640: DEEP LEARNING BASED QUANTIFICATION OF EPICARDIAL ADIPOSE TISSUE VOLUME IN STRESS CARDIAC MAGNETIC RESONANCE PREDICT MAJOR ADVERSE CARDIOVASCULAR EVENTS IN PATIENTS WITH KNOWN OR SUSPECTED CORONARY ARTERY DISEAS

Marco Guglielmo (a, b), Marco Penso (c),
Maria Ludovica Carerj (d), Carlo Maria Giacari (d), Alessandra Volpe (d), Laura Fusini (d), Andrea Baggiano (d), Saima Mushtaq (d), Andrea Annoni (d), Francesco Cilia (d), Fabio Fazzari (d), Alberto Formenti (d), Antonio Frappampina (d), Paola Gripari (d), Maria Elisabetta Mancini (d), Valentina Mantegazza (d), Riccardo Maragna (d), Francesca Marchetti (d), Luigi Tassetti (d), Francesca Baessato (f), Valentina Corino (c, d), Andrea Guaricci (e), Alexia Rossi (g, h), Chiara Rovera (i), Marianna Fontana (j), Ivo Van Der Bilt (a, b), Pim Van Der Harst (a), Enrico Caiani (c), Mauro Pepi (d), Gianluca Pontone (d)
(a) DEPARTMENT OF CARDIOLOGY, DIVISION OF HEART AND LUNGS, UTRECHT UNIVERSITY, UTRECHT UNIVERSITY MEDICAL CENTER, UTRECHT, THE NETHERLANDS; (b) DEPARTMENT OF CARDIOLOGY, HAGA TEACHING HOSPITAL, THE HAGUE, THE NETHERLANDS; (c) DEPARTMENT OF ELECTRONICS, INFORMATION AND BIOMEDICAL ENGINEERING, POLITECNICO DI MILANO, MILAN, ITALY; (d) DEPARTMENT OF PERIOPERATIVE CARDIOLOGY AND CARDIOVASCULAR IMAGING, CENTRO CARDIOLOGICO MONZINO, IRCCS, MILAN, ITALY; (e) DEPARTEMENT OF INTERDISCINPLINARY MEDICINE CARDIOLOGY UNIVERSITY UNIT, UNIVERSITY HOSPITAL POLYCLINIC OF BARI, BARI, ITALY; (f) DEPARTMENT OF CARDIOLOGY, SAN MAURIZIO REGIONAL HOSPITAL, BOLZANO, ITALY; (g) DEPARTMENT OF NUCLEAR MEDICINE, UNIVERSITY HOSPITAL, ZURICH, ZWITZERLAND; (h) CENTER FOR MOLECULAR CARDIOLOGY, UNIVERSITY OF ZURICH, ZURICH, ZWITZERLAND; (i) DEPARTMENT OF CARDIOLOGY, CIVIC HOSPITAL OF CHIVASSO, TURIN, ITALY; (j) NATIONAL AMYLOIDOSIS CENTRE,, UNIVERSITY COLLEGE LONDON, ROYAL FREE HOSPITAL, LONDON, UK

Background. Increased epicardial adipose tissue (EAT) volume quantified with cardiac magnetic resonance (CMR) has been associated with the development of major adverse cardiac events (MACE). We sought to investigate the additional prognostic role of EAT volume in patients with known or suspected coronary artery disease (CAD) undergoing CMR imaging.
Methods. 702 consecutive patients (age: 63±10 y, male 84%) with known or suspected CAD underwent clinically indicated stress CMR. Using a new deep learning (DL) algorithm, EAT volume was segmented and quantified on short-axis stack steady state free precession (SSFP) images. Firstly, we manually traced EAT in a training set of 300 patients. Secondly, we applied our segmentation network on a validation set of 402 patients. Finally, we applied the DL algorithm to the overall population (n=702). EAT volume, normalized for the body mass index (EAT volume index), was compared to standard clinical and imaging variables for the prediction of MACE defined as non-fatal myocardial infarction and cardiac deaths.
Results. 52 patients (7.4%) developed MACE during a follow-up of 5.8±1.2 years. Left ventricular ejection fraction (LVEF) <50% (HR 1.939 [95% CI 1.093-3.441]), p=0.024, late gadolinium enhancement (LGE) presence (HR 2.806 [95% CI 1.439-5.473]), p=0.02 and EAT volume index ≥2.2 (HR 7.890 [95% CI 4.385-14.195]), p<0.001 were independent predictors of MACE. Adding EAT volume index in a model including LVEF and LGE provided a significant improvement in predicting the endpoint with a Harrell C statistic of 0.75.
Conclusions. fully automated EAT volume measured by DL provides additional prognostic information on top of standard clinical and imaging parameters.

A641: ECHOCARDIOGRAPHIC REFERENCE RANGES FOR NON-INVASIVE MYOCARDIAL WORK INDICES IN HEART TRANSPLANT PATIENTS

Federico Landra (a), Lorenzo Tanzi (b), Chiara Fusi (a), Luca Martini (a), Maria Barilli (a), Carlotta Sciaccaluga (a), Enrico Emilio Diviggiano (a), Maria Concetta Pastore (a), Marta Focardi (a), Luna Cavigli (a), Flavio D'Ascenzi (a), Giulia Elena Mandoli (a), Serafina Valente (a), Matteo Cameli (a)
(a) UNIVERSITY HOSPITAL OF SIENA "POLICLINICO SANTA MARIA ALLE SCOTTE"; (b) UNIVERSITY OF SIENA

Background. Non-invasive myocardial work (MW) is a relatively novel echocardiographic method with increasing fields of application. Normal reference ranges of MW indices in a healthy population have already been determined but these may differ in patients who have undergone a heart transplant (HTX). PURPOSE To obtain the reference ranges for 2D echocardiographic indices of MW for HTX patients and to compare them with the results of the EACVI NORRE study regarding healthy volunteers.
Methods. All consecutive HTX patients admitted to the University Hospital of Siena (Italy) under Day Hospital regimen from September 2019 to May 2022 who performed endomyocardial biopsy (EMB) were considered. Patients with echocardiographic exam or brachial artery cuff pressure unavailability, history of rejection, history of coronary artery vasculopathy (CAV) and either acute cellular rejection (ACR) or acute antibody-mediated rejection (AMR) at EMB were excluded. Non-invasive MW calculation through Speckle-tracking Echocardiography (STE) was retrospectively performed for included patients. Further, MW analysis results were compared to those from the EACVI NORRE study.
Results. Out of 176 HTX patients who had performed EMB and had available echocardiographic and blood pressure data, 35 patients were excluded because of history of rejection, 4 patients because of history of CAV and 55 patients because of either ACR or AMR at EMB. Therefore, study population consisted of 82 HTX patients (68.3% male, median age 53 (46 – 62) years). Median age from HTX was 5 (2 – 22) months. Mean global work efficiency (GWE, 84 ± 8%), global work index (GWI, 1447 ± 409 mmHg%), global constructive work (GCW, 2067 ± 423 mmHg%) and median global wasted work (GWW, 310 (217 – 499) mmHg%) did not differ between sex categories (p-value>0.05). Each of these indices significantly differed from those reported in the EACVI NORRE study (p-value <0.001), with lower GWI, GCW, GWE and higher GWW in the HTX population.
Conclusions. This study provides reference ranges for non-invasive MW indices in a HTX population free from transplant-related complications which are different from those regarding a population of healthy volunteers.

A642: EXERCISE ECHOCARDIOGRAPHYTO EVALUATE THE DIASTOLIC FUNCTION IN HYPERTROPHYC CARDIOMIOPATHY

Denise Cristiana Faro (a), Adriana Gravina (a), Valentina Losi (a), Ines Paola Monte (a)
(a) CHIRMED DEPARTMENT, UNIVERSITY OF CATANIA

Background. Exercise echocardiography (EchoEx) is an increasingly used methodology to stratify risk in patients with hypertrophic cardiomyopathy (HCM), by quantifying the gradient of the left ventricular outflow tract (LVOT) and in the diagnostic iteration of heart failure with preserved ejection fraction to unmask diastolic dysfunction.
Objective: Our aim was to perform a multiparametric evaluation during EchoEx in patients with non-obstructive HCM in order to identify early diastolic dysfunction.
Methods. 22 patients (age 50±13y) with non-obstructive HCM at rest, asymptomatic or with NYHA 2/3 but indeterminate diastolic dysfunction and a control group matched for age (n=22), were subjected to EchoEx via a semi-supine ergometer bed, according to the Bruce protocol increment load and HCM views. At rest, at 50% effort, at the peak of effort, and 5 minutes into recovery were evaluated the following echocardiographic parameters: ventricular volumes and EF, E/e' ratio, LAVi, PAPs and LVOT gradient. Images were acquired using GE E95 Echo System. The presence of ECG signs and symptoms of ischemia, dyspnea, the amount of work in Watts, the double product (DP), the percentage of the max HR target achieved, and the total duration of the test were evaluated. Statistical analyses were performed using SPSS ver.26 software, with significance set at P<0.05.
Results. 59% of patients were in NYHA class I, 27.3% in class II, and 13.6% in class III. In HCM patients, the exercise test was submaximal in 73% (interrupted due to onset of muscle fatigue in 41%, and due to dyspnea in 14%), with a lower percentage of the max HR target achieved (78.5±11.2% vs 88.5±8%, P=0.001), significantly less average work (122±36 W vs 157±58 W, P=0.02), as well as the DP (24304±825 vs 29812±477, P=0.008) and the METS achieved (5.6±2 vs 9.05±1.4, P≤0.001). At baseline echocardiographic examination, HCM patients showed significant differences only in LAVi (P<0.001), with no significant difference in PAPs or the E/e' ratio. During stress, the E/e' ratio and LAVi were significantly higher in the HCM group (P=0.018 and P<0.001), with an increase during effort of the E/e' ratio by 11.3% (higher than 14 in 4 patients), in contrast with the physiological reduction that occurred in the control group (Δ -19.4%, P=0.02). Stress PAPs was higher in the HCM group (34±14.7mmHg vs 29.6±9.7, P=0.25), but with a significantly larger Δ stress/baseline (+58.3% vs +24.9%, P=0.001). The average stress LVOT gradient did not reach significant values (18.4±17.5 mmHg,

Δ +160%); however, 2 patients reached a gradient>50 mmHg during effort. No HCM patient had a sudden drop in BP at the peak or end of effort, nor ventricular arrhythmias or ischemia.
Conclusions. Our study highlighted reduced exercise tolerance in patients with HCM, and the role of the test in defining the degree of diastolic dysfunction. Exercise echocardiography is a versatile, low-cost technique that does not use ionizing radiation, with high diagnostic accuracy and a high degree of repeatability in the follow-up of these patients.

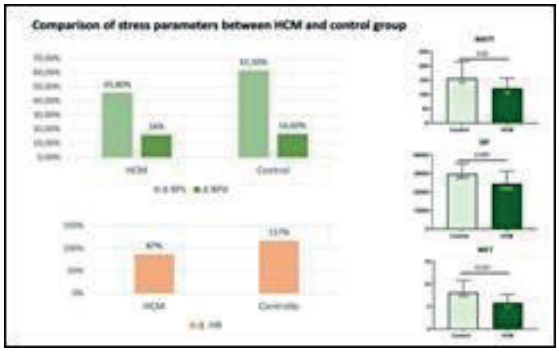



A643: THE PREVALENCE AND CLINICAL ROLE OF TRICUSPID VALVE PROLAPSE ASSOCIATED WITH SEVERE ORGANIC MITRAL REGURGITATION: RESULTS FROM A LARGE REAL-WORLD COHORT

Michele Morosato (a, b), Davide Margonato (a), Vincenzo Rizza (a, b), Silvana Di Maio (a, b), Marco Gamardella (a, b), Ludovica Bognoni (a, b), Leila De Lorenzo (a, b), Maddalena Saghir (a, b), Francesco Ancona (a), Stefano Stella (a), Giacomo Ingallina (a), Annamaria Tavernese (a), Martina Belli (a), Francesco Maisano (b, c), Michele De Bonis (b, c), Eustachio Agricola (a, b)
(a) CARDIOVASCULAR IMAGING UNIT, SAN RAFFAELE HOSPITAL, MILAN, ITALY; (b) VITA-SALUTE SAN RAFFAELE UNIVERSITY, MILAN, ITALY; (c) CARDIAC SURGERY UNIT, SAN RAFFAELE HOSPITAL, MILAN, ITALY

Background. Tricuspid valve (TV) prolapse in the context of concomitant organic mitral valve (MV) disease is a poor defined clinical entity, whose clinical and echocardiographic associated characteristics are mostly unknown due to paucity of published data.
Purpose. To clarify the prevalence, the characteristics and the clinical implication of TV prolapse in a large cohort of patients suffering from severe organic mitral regurgitation.
Methods. Clinical and echocardiographic characteristics were collected among patients suffering from severe organic MV disease, evaluated at our center from November 2018 and November 2022. Exclusion criteria were previous mitral valve surgery, severe aortic valvulopathy, concomitant MV endocarditis and poor acoustic window for tricuspid regurgitation (TR) evaluation.
Results. 884 patients were included in our study, 834 (94%) of whom underwent echocardiographic transesophageal evaluation. Eligible patients presented concomitant TR graded as none/trace in 183 (21%), mild in 427 (48%), moderate in 207 (23%), moderate to severe in 26 (3%) and severe in 41 (5%). Organic TR due to valve prolapse was the most common etiology (487 patients, 55%), followed by functional atrial TR (172 patients, 19%) and by functional ventricular TR (42 patients, 5%), while TR etiology was not evaluable in 183 (21%) patients. Compared to the other etiologies, patients with TV prolapse were younger (mean age 63.2±14.1, p<0.001 for all), paucisymptomatic (NYHA class I in 28%, p<0.001 for all), with more advanced MV organic disease (bi-leaflet myxomatous degeneration in 63%, p<0.001 for all) but with less hemodynamically relevant TR (>mild TR in 30%, p<0.001 for all) and less tricuspid annulus dilatation (p=0.016 and p<0.001 for ventricular and atrial functional TR, respectively). After multivariable analyses, only advanced myxomatous degenerative MV disease (OR 2.2, CI 1.05- 4.62, p value=0.035) remained independently associated with the presence of concomitant tricuspid valve prolapse. MV surgery was performed in 785 (89%) patients, with an intra/periprocedural mortality of 0.2%, while 132 (15%) patients underwent simultaneous TV intervention (131 annuloplasty procedures, 99.2%, 1 TV repair, 0.8%). At multivariable analyses, tricuspid annulus dilatation (OR 3.68, CI 2.05- 6.62, p<0.001) and>mild TR (OR 9.30, CI 5.10-16.95, p<0.001), but not concomitant TV prolapse (OR 1.11, CI 0.97- 1.60, p=0.118), were independently associated with subsequent TV surgical intervention.
Conclusions. In a large cohort of patients suffering from severe organic MV disease, systematically screened through transesophageal echocardiographic evaluation, TV prolapse is a prevalent finding. Compared to the other etiologies of TR, patients with concomitant TV prolapse present with an advanced staged of degenerative myxomatous MV disease, but with less severe TR. These novel results suggest the need for an increased inspection of the TV apparatus in the context of surgical assessment of MV disease.

A644: PAEDIATRIC MARFAN SYNDROME: WHAT CARDIOVASCULAR MAGNETIC RESONANCE CAN TELL US?

Sara Moscatelli (a), Federico Fortuni (b), Nitha Naqvi (a), Raad Mohiaddin (a), Duddley Pennell (a), Inga Voges (c), Sylvia Krupickova (a)
(a) ROYAL BROMPTON AND HAREFIELD HOSPITALS; (b) LEIDEN UNIVERSITY MEDICAL CENTER; (c) UNIVERSITY HOSPITAL SHLESWSWIG-HOLSTEIN

Background. Marfan syndrome (MFS) is an autosomal dominant genetic multisystem disorder of connective tissue; DUE TO mutations in gene of fibrillin-1, component of elastic fibres. Scientific literature has documented a widespread impact on cardiac function in ADULTS with MFS. Nevertheless, the full extent of this phenomenon, especially in the pediatric population, remains unclear. The objective of the present study was to investigate cardiac function in MFS pediatric population referred to Cardiac Magnetic Resonance (CMR) Unit at Royal Brompton Hospital, London, UK, using both standard and advanced CMR parameters to uncover any pertinent information related to paediatric age group.
Methods. Patients aged ≤18 years between March 1999 and June 2023 were included. CMR scans were performed at 1.5T scanner (2 patients at 3T). CVI42 software was used for volumetric and strain analysis. Strain values were compared to published pediatric normal centile values.
Results. Thirty-eight patients with median age of 15 years (IQR 11-16) were included; 16 (43%) were female. Indexed left ventricular (LV) end-diastolic volume (EDVi), indexed LV end-systolic volume (ESVi), ejection fraction (EF) and indexed mass, respectively, were: 89±20ml/m^2, 34±10 ml/m^2, 62±6%, 64±12g/m^2. LVEDVi was mildly increased in 9 patients and moderately in 3, LVESVi mildly increased in 11 and moderately in 1, EF was mildly decreased in 2 patients. Indexed right ventricular (RV) EDVi, RVESVi and EF, respectively, were: 87±17 ml/m^2, 39±11 ml/m^2, 57±7%. RVEDVi was mildly increased in 2 patients and moderately in other 2, RVESVi mildly increased in 2, moderately in 7, EF was mildly impaired in 5 patients. Two patients had bicuspid aortic valve and 6 mild aortic regurgitation. Nine patients had mild mitral regurgitation, 2 moderate and 2 severe, 11 patients had mitral valve prolapse (1 post Alfieri repair). Twenty-four patients had dilated aortic root, 5 of them severely. LV global radial strain was mean 30±6%, LV circumferential strain -17 ±4%, and LV longitudinal strain -17 ±3%. LV longitudinal strain was decreased in 2 and increased in 6 patients, LV global circumferential strain was decreased in 29 and LV global radial strain was increased in 14 patients. Among the 22 patients with normal indexed LV volumes and EF, 15 had decreased circumferential strain and 2 of those had also decreased longitudinal strain. Interestingly out of 15 patients with impaired circumferential strain, 4 had increased global radial strain.
Conclusions. The majority of pediatric MFS patients (82%) showed signs of compromise in LV myocardial function when assessed using both standard and advanced parameters. However, advanced techniques uncovered large proportion of patients (39%) affected by myocardial impairment which was not detected using conventional parameters. Therefore, myocardial strain could be used as early predictor of LV subclinical impairment.

A645: SPECKLE TRACKING ECHOCARDIOGRAPHY PROVIDES ADDITIVE VALUE TO DIFFERENTIATE PULMONARY HYPERTENSION ASSOCIATED WITH LEFT HEART OR LUNG DISEASE IN PATIENTS PRESENTING WITH DYSPNOEA

Maria Concetta Pastore (a), Simona Pavoncelli (a), Mara Toscano (a), Andrea Renzelli (a), Alessia Culcasi (a), Giulia Elena Mandoli (a), Luna Cavigli (a), Paolo Cameli (b), Marta Focardi (a), Flavio D'Ascenzi (a), Matteo Cameli (a)
(a) DEPARTMENT OF MEDICAL BIOTECHNOLOGIES, DIVISION OF CARDIOLOGY, UNIVERSITY OF SIENA, SIENA, ITALY; (b) RESPIRATORY DISEASE UNIT, DEPARTMENT OF MEDICAL SCIENCES,SIENA UNIVERSITY HOSPITAL, SIENA, ITALY

Background. The diagnostic pathway of pulmonary hypertension (PH) is complex and requires noninvasive and invasive measures for certain diagnosis. Differential diagnosis between left heart disease (group 2) and pulmonary disease (group 3) as PH etiology is also challenging. The latest European society of cardiology (ESC) guidelines recommend a com-

prehensive echocardiographic evaluation for suspected PH, and the use of several basic echocardiographic indices of left ventricular (LV) and left atrial (LA) function to assess cardiac etiology of PH. Speckle tracking echocardiography (STE) has emerged as a more sensitive technique to evaluate myocardial performance in different clinical settings and has been recommended by ESC documents for the diagnosis of HFpEF. The aim of this study was to assess the potential value of STE to predict left heart disease in patients presenting with dyspnoea and PH.
Methods. Consecutive outpatients with dyspnoea with efforts and subsequent diagnosis of PH were retrospectively enrolled. Inclusion criteria were New York heart association (NYHA) class ≥II, LV ejection fraction ≥50%, echocardiographic evidence of systolic pulmonary artery pressure ≥35 mmHg and tricuspid regurgitant velocity (TRV) ≥2.8 ms, known diagnosis of PH with relative etiology (heart failure with preserved ejection fraction, HFpEF or lung diseases i.e. sarcoidosis, idiopathic pulmonary fibrosis, chronic obstructive lung disease). Patients underwent clinical, biohumoral and echocardiographic evaluation. STE was performed offline by an experienced operator blinded to other data. Primary endpoint was the prediction of HFpEF among the patient population.
Results. Overall, 145 patients were enrolled (80 with HFpEF, 65 with lung disease). Mean age was 75±12 years, 53% were female. Patients with HFpEF were older (77±10 vs. 68±14 years, p<0.0001) and had higher LA volume (93±37 vs. 64±31 ml, p<0.0001), E/E' by tissue Doppler imaging (TDI) (15±5 vs. 9±3, p<0.0001), mitral regurgitation (MR) grading (p=0.002), with lower tricuspid regurgitation (TR) grading (p=0.004). Regarding STE parameters, patients with HFpEF had lower peak atrial longitudinal strain (PALS) (15 ± 8 vs. 24 ± 11%, p<0.0001) and LV global longitudinal strain (-13 ± 9 vs. -17 ± 6%, p=0.009) compared to patients with lung diseases. Right ventricular strain did not show significant differences (p=0.23) LA stiffness, calculated as the ratio between E/E' and PALS, which is known as an index of LA dysfunction and fibrosis, was higher in patients with HFpEF than in patients with lung diseases (median LA stiffness=1.09 [confidence interval (CI)=0.64-1.73] 0. Vs.0.35 [CI=0.20-0.59], p<0.0001). With receiver operating characteristic curves, both E/E' and global PALS provided a good prediction for HFpEF (AUC 0.73 and 0.79 respectively), but their combination to calculate LA stiffness significantly enhanced the predictive power (AUC=0.83) with an optimal cutoff value ≥0.53. With multivariate analysis including age, LA volume, LV GLS, LA stiffness, mitral and tricuspid regurgitation grade, LA stiffness≥0.53 (RR=19.14, confidence interval 5.86-62.55) was the only independent predictor of HFpEF in our cohort of patients with PH (Fig.1).
Conclusions. STE may aid differential diagnosis of etiology between left heart disease and pulmonary disease in patients with PH. The combination of TDI E/E' and PALS to calculate LA stiffness offers the most accurate prediction of PH with cardiac etiology.

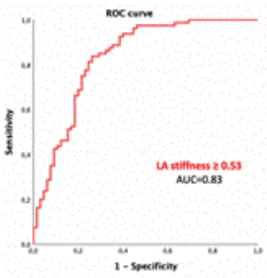

variable	RR	p value
age	3.53	0.06
LA volume	0.36	0.54
LV GLS	0.19	0.66
LA stiffness ≥ 0.53	19.14	<0.0001
MR grading	3.37	0.66
TR grading	2.39	0.12

A646: HOW MANY CLUES MAKE AN EVIDENCE? AN UNUSUAL CASE OF ABORTED CARDIAC ARREST DUE TO MITRAL VALVE PROLAPSE

Laura Piscitelli (a), Antonio Gianluca Robles (b, c),
Roberto Costantino (a), Luigi Sciarra (c), Silvio Romano (c),
Domenico Chieppa (b)
(a) CARDIOLOGY UNIT PERRINO HOSPITAL, BRINDISI ITALY; (b) CARDIOLOGY UNIT, BONOMO HOSPITAL, ANDRIA, ITALY; (c) DEPARTMENT OF LIFE, HEALTH ADN ENVIRONMENTAL SCINECES, UNIVERSITY OF L'AQUILA, ITALY; (d) RADIOLOGY UNIT, SAN NICOLA PELLEGRINO PTA TRANI, ITALY

There is an increasing awareness on the association between mitral valve prolapse (MVP) and sudden cardiac death. Mitral annular disjunction (MAD) is a phenotypic risk feature that can help in risk stratification. We present a case of a 58-year-old woman who experienced an out-of-hospital cardiac arrest caused by ventricular fibrillation interrupted by a DC-shock. No coronary lesions were documented. Transthoracic echocardiogram documented a bileaflet myxomatous MVP. Frequent episodes of non-sustained ventricular tachycardia with right bundle branch block morphology and superior axis were registered at monitor. CMR surprisingly, revealed the presence of MAD with systolic curling of the posterior leaflet. No myocardial oedema was found but there was a focal increase of T1 mapping values in inferior basal wall and a non-ischemic pattern of late gadolinium enhancement (LGE) was described. The presence of many clues (Barlow's disease together with negative inferior T waves, MAD with systolic curling, and inferior non-ischemic LGE) built evidence: a diagnosis of aborted cardiac arrest due to Arrhythmic Mitral Valve Prolapse (AMVP) with MAD and LGE was made. Finally, a defibrillator has been implanted. This clinical case focuses on the rare clinical onset with ventricular fibrillation in a patient with Barlow's disease and MAD as the only "evident cardiomyopathy". The AMVP is a well-known phenomenon and a rare cause of SCD, but risk stratification of affected patients is still challenging. For arrhythmic risk stratification of MVP with MAD, multimodality imaging is a fundamental diagnostic tool to find out the disease behind many cardiac arrests of unknown cause.

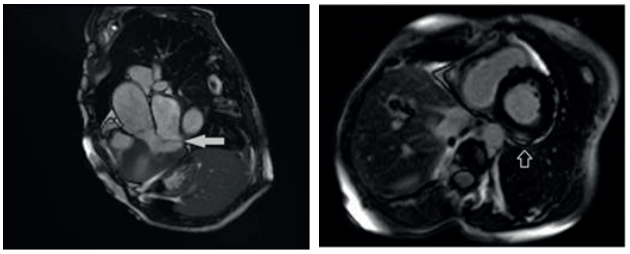

A647: COMPARISON OF DIFFERENT METHODS FOR QUANTIFICATION OF MYOCARDIAL SCAR IN HYPERTROPHIC CARDIOMYOPATHY

Maria Cristina Procopio (a), Isabella Leo (a), Clarissa Daros Borguezan (a), Giandomenico Bisaccia (a), Roberto Licordari (a, b), Chiara Bucciarelli-ducci (a)
(a) ROYAL BROMPTON AND HAREFIELD HOSPITALS, GUY´S AND ST THOMAS´ NHS FOUNDATION TRUST, LONDON, UK; (b) DEPARTMENT OF CLINICAL AND EXPERIMENTAL MEDICINE, UNIVERSITY OF MESSINA, MESSINA, ITALY

Objectives. The aim of our study was to compare the reproducibility of four different late gadolinium enhancement (LGE) quantification techniques in patients with Hypertrophic Cardiomyopathy (HCM).
Background. Contrast-enhanced cardiac magnetic resonance imaging (CMR) is the gold-standard modality to assess myocardial scar through LGE detection. The amount of myocardial fibrosis is proportional to the risk of future cardiovascular adverse outcomes, and one of the criteria for implantable cardioverted defibrillator (ICD) implantation in primary prevention when is ≥15% of LV mass, according to the current European Society of Cardiology Guidelines on Cardiomyopathies. Currently, but there are various methods of analysis but data about the best method to quantify LGE are sparse.
Methods. 50 HCM patients (apical pattern, n=20; other phenotypical patterns, n=30) undergoing CMR were assessed. LGE was quantified using 4 different techniques: 5SD method, 6SD method, full width half method (FWHM) and manual method. The same measurements were repeated after one month by the same operator. Mean LGE volume and intra-observer reproducibility were assessed.
Results. There was no statistically significant difference between LGE volume measured by the four methods (FWHM, 5SD, 6SD and manual methods). The manual assessment was the most reproducible method to quantify LGE in patients with HCM [ICC of 0.87 (95%CI 0.78-0.92)]. The method with threshold of 5SD above the mean signal intensity (SI) of the remote myocardium provided the best agreement when compared with visual assessment.
Conclusions. Manual quantification of fibrosis is a reproducible method in patients with Hypertrophic Cardiomyopathy. Among semiautomatic methods, use of a threshold of 5SD above the mean SI of remote myocardium is the most reliable to visual assessment. Whether these LGE quantification methods have different diagnostic and prognostic impact should be further investigated.

A648: PREDICTORS OF ADVERSE CARDIAC EVENTS OF CORONARY MYOCARDIAL BRIDGING DIAGNOSED WITH COMPUTED TOMOGRAPHY ANGIOGRAPHY

Angelo Ratti (a, b), Blanca Prestini (b), Carlo Gigante (a, b),
Maria Laura Novembre (a, b), Giovanni Monizzi (a, c),
Angelo Mastrangelo (a), Pasquale Paolisso (a), Davide Marchetti (a),
Matteo Schillaci (a), Edoardo Conte (a), Andrea Baggiano (c),
Saima Mushtaq (c), Gianluca Pontone (c), Paolo Zeppilli (d),
Antonio Bartorelli (a, c), Daniele Andreini (a, b)
(a) IRCCS OSPEDALE GALEAZZI SANT'AMBROGIO - MILANO; (b) UNIVERSITÀ DEGLI STUDI DI MILANO - DIPARTIMENTO DI SCIENZE CLINICHE E DI COMUNITÀ; (c) CENTRO CARDIOLOGICO MONZINO IRCCS - MILANO; (d) UNIVERSITÀ CATTOLICA DEL SACRO CUORE - ROMA

Aims. Myocardial bridging (MB) is a frequent congenital anomaly of the epicardial coronary arteries commonly considered a benign condition. However, in some cases a complex interplay between anatomical, clinical and physiology factors may lead to adverse events, including sudden cardiac death. Coronary CT angiography (CCTA) emerged as the gold standard noninvasive imaging technique for the evaluation of MB. Aim of the study was to evaluate MB prevalence and anatomical features in a large population of patients who underwent CCTA for suspected CAD

and to identify potential anatomical and clinical predictors of adverse cardiac events at long-term follow-up.
Methods and Results. Two-hundred and six patients (mean age 60.3±11.8 years, 128 male) with MB diagnosed at CCTA were considered. A long MB was defined as ≥25 mm of overlying myocardium, whereas a deep MB as ≥2 mm of overlying myocardium. The study endpoint was the sum of the following adverse events: cardiac death, bridge-related acute coronary syndrome, hospitalization for angina or bridge-related ventricular arrhythmias and MB surgical treatment. Of the 206 patients enrolled in the study, 9 were lost to follow-up, whereas 197 (95.6%) had complete follow-up (mean 7.01±3.0 years) and formed the analytic population. Nineteen bridge-related events occurred in 18 patients (acute coronary syndrome in 7, MB surgical treatment in 2 and hospitalization for bridge-related events in 10). Typical angina at the time of diagnosis and long MB resulted as significant independent predictors of adverse outcome (OR of 3.29; CI954% 1.05-10.31, p=0.04 for typical angina; OR of 4.05, CI95% 1.06-15.53, p=0.04 for long bridge, respectively).
Conclusions. Coronary CT angiography can identify MB and characterize anatomical features with an impact on patient prognosis. Typical angina and MB length ≥25 mm were independent predictors of cardiac events.

A649: A NEGLECTED BIOMARKER IMAGING IN CARDIO-ONCOLOGY: A CASE REPORT

Matteo Rocchetti (a), Gabriella Di Giovine (a), Alessandro Minardi (a), Andrea Spangaro (a), Elena Sala (a), Cinzia Vece (a), Ludovica Senese (a), Alberto Cereda (a)
(a) CARDIOVASCULAR DEPARTMENT, ASST SANTI PAOLO E CARLO, 20153, MILANO, ITALY

A man with a prominent cancer history came to our attention with typical chest pain.
Cardio-oncological history. Past medical history comprised an hemicolectomy for the presence of large bowel adenocarcinoma pT3 N0 G2 R0 (AJCC, Ed.VIII; 2017) with no sign of metastatic disease at the CT performed before surgery. After eradication the patient underwent adjuvant treatment with Capecitabine (8 cycle) with no complication. Before the beginning of adjuvant treatment, the patient underwent an echocardiogram which showed preserved ejection fraction (EF>65%) with no a wall motion abnormality (WMA) and no relevant valvopathies. Total body CT scan after completion of chemotherapy treatment showed no sign of disease recurrence and patients started regular oncological follow up.
Cardiological history. Soon after the end of adjuvant therapy the patient complained shortness of breath during exercise, basal ECG showed no clear sings of ischemic suffering. The patient underwent an ergometric test, with the appearance of a clear ischemia associated with chest pain at the peak of the stress. Coronary angiography showed a Tri vessel disease with near occlusion of the proximal tract of descending artery, high and intermediate stenosis of the left artery at the proximal and intermediate tract and sub occlusion of the distal tract of the right coronary artery. The patient was therefore presented to the cardio surgery team and underwent bypass graft which improved his condition and currentely he is asymptomatic under regular cardiological follow up.
Key point of the clinical case. The patient had a first chest-abdomen CT scan before hemicolectomy and adjuvant therapy with capecitabine (known to increase the risk of suffering from ischemic disease) where coronary and aortic calcifications were clearly evident. Despite the presence of atypical anginal symptoms, the radiological data was neglected. The reassurance of the exercise test further masked the suggestive symptom of CAD. At the second chest CT scan which confirmed the regression of the oncological disease, the significant progression of the aorto-coronary calcific burden was neglected. Only a fortuitously positive exercise test directed clinicians on the right diagnostic path. Coronary/vascular calcium was overlooked and would have allowed for better preventative medical therapy and tragic coronary plaque in stabilization during surgery/chemotherapy. Oncological patients notably follow intense radiological programs. CT scans used for the staging and the follow up of cancer patients can offer with a closer look interesting data about basal coronary artery disease and its possible progression especially during cardiotoxic therapy.
Conclusions. CT scan performed during routine oncological treatments and follow up might offer data not only about the patient's cancer. Our clinical case shows an instance of neglected information which could have been harvested to assess the patients's cardiovascular risk before the appearance of the symptoms. This biomarker might help clinician to assess which patients are in need of a more intense cardiological follow up and preventive therapy. Alongside, calcium score might be used as a fraility index and a more objective mean for assessment coronary artery health.

A650: MULTIMODALITY IMAGING AND FULL PHYSIOLOGY IN A CASE OF MINOCA

Erika Tempo (a), Riccardo Scalamera (a), Antonia Buongiorno (a), Sofia Hassan (a), Paolo Archetti (a), Gianluca Anastasia (a), Sara Seitun (c), Rocco Vergallo (a, b), Italo Porto (a, b)
(a) DEPARTMENT OF INTERNAL MEDICINE, UNIVERSITY OF GENOVA, GENOVA, ITALY; (b) CARDIOVASCULAR DISEASE UNIT, CARDIAC, THORACIC AND VASCULAR DEPARTMENT, IRCCS OSPEDALE POLICLINICO SAN MARTINO, GENOVA, ITALY; (c) DEPARTMENT OF RADIOLOGY, IRCCS OSPEDALE POLICLINICO SAN MARTINO, GENOVA, ITALY

Background. Myocardial infarction with non-obstructive coronary arteries (MINOCA) is a condition where a patient shows electrocardiogram (ECG) changes, elevated cardiac biomarkers, and symptoms suggestive of acute myocardial infarction, but coronary angiography reveals no flow-limiting lesions. MINOCA encompasses a diverse group of diseases with varying underlying pathological mechanisms.
Case summary. We present the case of a 44-year-old woman who was admitted to the cardiology department with chest pain, ECG changes, and elevated Troponin I levels, suggestive of non-ST-segment elevation myocardial infarction (NSTEMI). Cardiac echography showed preserved global left ventricle (LV) contractile function with hypokinesia of the medial-distal anterior wall. Cardiac CT scan ruled out spontaneous coronary dissection (SCAD) but revealed a non-severely obstructive (<50%) atherosclerotic plaque in the mid tract of the left anterior descending artery (LAD). Coronary angiography revealed mild diffuse coronary atherosclerosis with an intermediate focal stenosis of LAD downstream a first diagonal branch (D1) of early origin and intermediate stenosis in the mid-distal tract of the LAD. Intracoronary imaging using optical coherence tomography (OCT) of the LAD showed fibrolipidic plaques without signs of rupture or macroscopic thrombotic appositions in the mid-distal tract (MLA 2.3 mm^2, AS 40%) and distal to D1 (MLA 5.1 mm^2). Yet, an irregular vessel wall surface with microthrombi was observed at the site of distal lesion, suggestive of a focal plaque erosion. Functional evaluation using a pressure wire on the LAD indicated baseline Pd/Pa of 0.95, resting full-cycle ratio (RFR) of 0.93, and fractional flow reserve (FFR) with intra venous adenosine of 0.83, suggesting a hemodynamically insignificant stenosis. Pullback during hyperemia documented a gradual fall in blood pressure due to diffuse atherosclerosis. In addition, an evaluation of the microcirculation was performed, revealing coronary flow reserve (CFR) of 2.2 and index of microcirculatory resistance (IMR) of 25, indicating resistance in the microcirculation with values at the high limits of the norm. Finally, a provocative test with intracoronary acetylcholine, with increasing doses (20, 50, and 100 mcg), was carried out. From the second dose onward, the patient experienced precordial pain, ECG alterations, without epicardial spasm, suggesting a picture compatible with microvascular spasm that completely resolved after intracoronary nitrates administration. Ultimately, cardiac MRI was performed, which highlighted recent ischemic outcomes in the medial-distal anterior wall and mid-apical inferior wall, identifiable as the territory of the LAD, with a transmurality index>70%. Based on the information gathered, a diagnosis of MINOCA was made.
Conclusions. By combining multimodality imaging with a thorough study of microcirculation physiology, we gained valuable insights that enhanced our understanding and facilitated the accurate diagnosis and treatment of this case of MINOCA. This integrated approach proves to be extremely useful in managing effectively this complex condition.

A651: MID-VENTRICULAR HYPERTROPHY WITH TURBULENT FLOW AND UNUSUAL CW-DOPPLER PATTERN: LOOK CAREFULLY AT THE APEX!

Anna Tribuzio (a, b, c), Matteo Bellettini (a, b, c), Alessandro Vairo (a, c), Gianluca Alunni (c), Gaetano Maria De Ferrari (a, b)
(a) DIVISION OF CARDIOLOGY, CARDIOVASCULAR AND THORACIC DEPARTMENT, CITTA DELLA SALUTE E DELLA SCIENZA HOSPITAL, TURIN, ITALY; (b) DEPARTMENT OF MEDICAL SCIENCES, UNIVERSITY OF TURIN, TURIN, ITALY; (c) DIVISION OF ADVANCED CARDIOVASCULAR ECHOCARDIOGRAPHY, CARDIOVASCULAR AND THORACIC DEPARTMENT, CITTÀ DELLA SALUTE E DELLA SCIENZA HOSPITAL, TURIN, ITALY

55-year-old female without previous cardiological history was resuscitated from cardiac arrest due to ventricular tachycardia interrupted by DC shock. Transthoracic echocardiography (TTE) showed severe left ventricular hypertrophy with systolic obliteration of mid-cavity. Turbulent color-Doppler (CD) pattern (figure 1) was observed at mid-chamber level with a peculiar double-peaked continuous-wave Doppler spectrum known as "Doppler systolic signal void" (figure 2). This pattern, described for the first time by Nakamura et al.- JACC 1992, may be a marker of concealed apical aneurysm; it is characterized by an early-systolic peak followed by late-systolic flow cessation, caused by midventricular dynamic obstruction, and a second peak provoked by paradoxical diastolic flow due to the release of blood trapped inside the apical aneurysm. This phenomenon can be also visualized with M-mode CD. Careful morphologic 2D - 3D TTE and cardiac MRI (figure 3) confirmed the presence of apical aneurysm, not identified at first glimpse. Akinetic apical aneurysm is associated with higher risk of ventricular arrhythmias and sudden cardiac death in HCM patients. Its detection could be challenging to image with 2D TTE. "Doppler systolic signal void" pattern should raise the suspicious of apical aneurysm allowing its diagnosis and a better arrhythmic risk stratification.

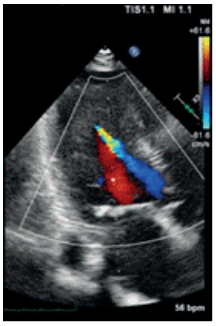

Figure 1.

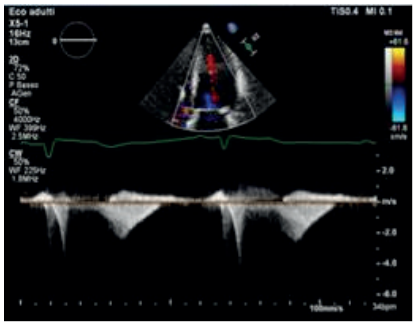

Figure 2.

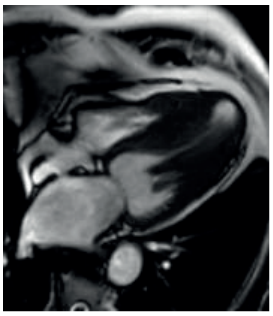

Figure 3.

A652: RIGHT VENTRICULAR - PULMONARY ARTERY UNCOUPLING IMPROVEMENT EARLY AFTER MITRAL TRANSCATHETER EDGE-TO-EDGE REPAIR AND ITS PROGNOSTIC IMPLICATIONS: A SINGLE-CENTER RETROSPECTIVE OBSERVATIONAL STUDY

Andrea Viceré (a), Domenico Galante (b), Di Giusto Federico (a), Edoardo Petrolati (a), Gianluca Anastasia (a), Ciro Pollio Benvenuto (a), Vincenzo Viccaro (a), Chiara Giuliana (a), Simona Todisco (a), Francesco Bianchini (a), Francesco Burzotta (a), Cristina Aurigemma (a), Antonella Lombardo (a), Gabriella Locorotondo (a), Francesca Graziani (a), Carlo Trani (a), Antonio Maria Leone (a)

(a) UNIVERSITÀ CATTOLICA DEL SACRO CUORE - POLICLINICO UNIVERSITARIO A. GEMELLI I.R.C.C.S.; (b) OSPEDALE FATEBENEFRATELLI ISOLA TIBERINA - GEMELLI ISOLA

Objectives. Our study sought to investigate the role of TAPSE/PAsP improvement early after Mitral Transcatheter edge-to-edge repair (M-TEER) and the prognostic impact on symptoms and major cardiovascular events (MACE) of Right Ventricular - Pulmonary Artery (RV-PA) uncoupling after M-TEER.

Background. The prognostic implications of RV-PA uncoupling before M-TEER are well documented, but data are lacking on the impact of M-TEER over TAPSE/PAsP improvement and the role of its measurement after the procedure.

Methods. We analyzed 45 patients with moderate-to-severe or severe mitral regurgitation who underwent M-TEER and had both pre and early (median of 3 days) post-procedure TAPSE/PAPs measurement. The primary outcome was the percentage reduction in RV-PA uncoupling. Secondary outcomes included: MACE, defined as a composite of death and heart failure hospitalization; the percentage of mean value of KCCQ improvement and the percentage of NYHA class improvement.

Results. We both searched for the best cut-off to predict cardiovascular events in our cohort, using ROC curve analysis (0.371), and utilized an already literature validated cut-off (0.274). M-TEER had a significant impact in reducing RV-PA uncoupling with both cut-offs: 11 patients (24.4%) had TAPSE/PAsP<=0.274 pre-procedure and just 3 (6.6%) after it (p-value 0.02); 22 patients (48.9%) had TAPSE/PAsP<=0.371 pre-procedure and 13 patients (28.9%) after it (p-value 0.051). Patients with RV-PA uncoupling (cut-off 0.274) post M-TEER had a higher percentage of MACE (100% vs 35.7%), which nearly reached statistical significance (p value 0.058), and a non statistically significant lower percentage of NYHA class improvement (75.5% vs 33.3%, p value 0.229) and mean value of KCCQ improvement (12.9+/-12.3 vs 0, p value 0.156). Patients with RV-PA uncoupling defined by a cut-off of 0.371 had a statistically significant lower percentage of mean value of KCCQ improvement (15.2+/-12.3 vs 4.6+/-9.1, p value 0.02), a non statistically significant lower percentage of NYHA class improvement (76.9% vs 50%, p value 0.09) and a non statistically significant higher percentage of MACE (40% vs 30.8%, p-value 0.537).

Conclusions. M-TEER significantly reduces RV-PA uncoupling in patients with moderate-to-severe and severe mitral regurgitation. Studies with a broader population must be implemented to properly investigate the prognostic impact of TAPSE/PAsP measurement post M-TEER.

A653: THE ROLE OF THREE-DIMENSIONAL TRANSOESOPHAGEAL ECHOCARDIOGRAPHY (3D TEE) IN TAVI PREOPERATIVE PLANNING: A HEAD-TO-HEAD COMPARISON WITH MULTIDETECTOR COMPUTED TOMOGRAPHY (MDCT)

Paola Siena (a), Rossella Alemanni (b), Paolo Basile (a), Nicolò Soldato (a), Paola Spatuzza (b), Albino Vallabini (b), Maurizio Braccio (b), Eleonora Russo (b), Michele Palladino (b), Nunzio Gallo (b), Giulio Giovanni Cavalli (c), Andrea Igoren Guaricci (a), Marco Matteo Ciccone (a), Mauro Cassese (b)

(a) CARDIOVASCULAR DISEASE SECTION, INTERDISCIPLINARY DEPARTMENT OF MEDICINE (DIM), UNIVERSITY OF BARI ALDO MORO, UNIVERSITY HOSPITAL CONSORTIUM POLYCLINIC OF BARI, BARI; (b) DIVISION OF HEART SURGERY, EMERGENCY AND CRITICAL CARE DEPARTMENT, "CASA SOLLIEVO DELLA SOFFERENZA" RESEARCH HOSPITAL, SAN GIOVANNI ROTONDO; (c) DEPARTMENT OF CARDIAC SURGERY, "S. ORSOLA" UNIVERSITY HOSPITAL, IRCCS BOLOGNA, BOLOGNA

Introduction. Transcatheter aortic valve implantation (TAVI) has become a valid alternative to surgical replacement of symptomatic severe aortic disease in elderly patients with high surgical risk. The success of this procedure depends on the accurate measurement of both the aortic annulus (AoA) and the aortic root (AoR). Multidetector Computed tomography (MDCT) is the gold standard imaging diagnostic tool used in the preoperative planning to define AoA sizing and the feasibility of the procedure. However, MDCT may not be suitable in same circumstances such as patients' allergy to radiocontrast agents, kidney function impairment, severe breathlessness or arrhythmias. Our aim was to compare three-dimensional transesophageal echocardiography (3D TEE) sizing of AoA and AoR with MDTC measurements.

Methods. From January 2023 to August 2023 were enrolled 48 patients with symptomatic severe aortic stenosis (AS) or regurgitation (AR) referred to our hospital for TAVI. Each patient underwent MDCT and 3D TEE with the acquisition of the following measurements: AoA maximum diameter (max-D), AoA minimum diameter (min-D), AoA perimeter (PER), AoA area (AREA), Valsava Sinus diameter (VS-D), sino-tubular junction diameter (STJ-D), AoA-left main coronary ostium (LM) distance and AoA-right coronary ostium (RO) distance.

Results. The median age of the study population was 81 years (IQR 9), with a slight prevalence of female sex (60% of cases). A New York Heart Association (NYHA) class equal or more than III was present in all patients. AS [3D planimetric AVA median (IQR 0.43) 0.62 cm^2] was found in 33 patients, meanwhile severe AR [3D Vena Contracta Area median 0.40 cm^2 (IQR 0.17)] was present in 15 cases. Only 3 patients had a reduced left ventricular ejection fraction. A bicuspid aortic valve was observed in 17% of cases. Strong correlations were observed between 3D TEE and MDCT measurements (min-D r=0.75, p<0.001; PER r=0.79, p<0.001; AREA r=0.78, p<0.001; VS-D r=0.90, p<0.001; STJ-D r=0.90, p<0.001), moderate for RO distance (r=0.83; p=0.002) and for max-D (r=0.61, p<0.001). A weak correlation was found for LM distance (r=0.42; p=0.043). The Bland-Altman analysis pointed out a good agreement between the measurements obtained using the two methods. In particular, the best results were obtained for AREA [bias: 0.3 mm^2; Level of Agreement (LOA): -0.9, 1.7] and min-D (bias: 0.1 mm; LOA: -4.1, 4.3). A lower agreement was observed for LM distance (bias: 1.3 mm; LOA: -5.6,8.2).

Discussion and Conclusions. There are few data supporting the role of 3D TEE in the preoperative assessment for TAVI. Previous studies analyzed only AoA dimensions, showing contrasting results. Our preliminary results demonstrated that 3D TEE may be a valid alternative imaging modality in patients unsuitable for MDCT during the preoperative evaluation for TAVI. Measurements of AoA and AoR obtained with 3D TEE are nearly close to MDCT values. However, further analysis in our ongoing study will assess the accuracy of 3D TEE in the choice of prosthetic valve size as compared to MDCT.

A654: LONG-TERM CARDIAC REMODELING PREDICTION: THE ROLE OF CARDIAC MAGNETIC RESONANCE

Marco Bernardi (c), Luigi Spadafora (c), Gianmarco Sarto (c), Erica Rocco (b), Beatrice Simeone (b), Francesco Versaci (a), Sebastiano Sciarretta (b)

(a) DIVISION OF CARDIOLOGY, SANTA MARIA GORETTI HOSPITAL, LATINA, ITALY; (b) UOC DI UTIC/CARDIOLOGIA UNIVERSITARIA, ISTITUTO ICOT DI LATINA, SAPIENZA UNIVERSITÀ DI ROMA, POLO PONTINO; (c) SCUOLA DI SPECIALIZZAZIONE IN MALATTIE DELL'APPARATO CARDIOVASCOLARE, SAPIENZA UNIVERSITÀ DI ROMA

Introduction. Cardiovascular Magnetic Resonance (CMR) plays a pivotal role in contemporary cardiology, yet its specific utility in correctly classifying cardiac diseases and in predicting long-term left ventricular remodeling in patients without coronary artery diseases still needs to be fully clarified in real-life settings.

Methods. We conducted a retrospective analysis of patients admitted to Santa Maria Goretti Hospital in Latina, Italy, from 2017 to 2022 who underwent CMR. This study focused on patients admitted for myocardial infarction or evidence of cardiomyopathy or heart failure but excluding those with significant coronary artery lesions assessed by coronary angiography or with diagnosis of myocarditis. A total of 82 patients met the inclusion/exclusion criteria. We assessed the presence of late gado-

linium enhancement (LGE) in this cohort and distinguished between ischemic LGE (i-LGE) and non-ischemic LGE (ni-LGE) patterns. Furthermore, we examined how the presence of different patterns of LGE correlated with different left ventricular echocardiography and CMR function parameters (e.g., left ventricular end-diastolic diameter (LVEDD); ejection fraction (FE); left ventricular end-diastolic volume (LVEDV); stroke volume (SV)) at baseline (T0) and follow-up (FU).
Results. Among the analyzed patients, 59% exhibited no LGE, 27% had ni-LGE, and 14% had i-LGE. While we identified trends in risk factors among the i-LGE patients, they remained not statistically significant. We observed a significant difference in baseline troponin levels (p=0.023) and peak troponin levels (p=0.007) between patients with no LGE and those with i-LGE. Furthermore, our analysis unveiled significant differences in T0 EF (p=0.004), FU CMR EF (p=0.005), and FU LVEDD (p=0.046) between the patients with ni-LGE and those with no LGE. Linear regression analysis demonstrated that ni-LGE served as a negative predictor of T0 EF (p=0.004; coeff=-10.93) and FU EF (p=0.009; coeff=-11.62), while serving as a positive predictor of FU LVEDD (p=0.032; coeff=18.48). In addition, ni-LGE emerged as a predictor of T0 EF and FU EF reduction in multivariate regression analysis, even after accounting for age and sex. i-LGE was not found to significantly influence long-term ventricular remodeling parameters.
Conclusions. In a cohort of patients with unspecified cardiomyopathy, with no evidence of myocarditis or significant artery lesions, a subset exhibited i-LGE, potentially due to INOCA-related causes. While i-LGE did not substantially impact ventricular remodeling parameters, ni-LGE seems to be an independent predictor of baseline and long-term cardiac function. CMR resulted to be crucial for clarifying diagnosis and estimating prognosis in this patient population.

A655: FIBROELASTOMA AORTICO: UNA CAUSA ATIPICA DI ANGINA

Chiara Bianchi (a), Giulia Passarini (a)
(a) U.O. CARDIOLOGIA, UNIVERSITÀ DEGLI STUDI DI FERRARA

Una paziente di 71 anni con storia fibrillazione atriale in DOAC giunge all'attenzione medica per l'insorgenza da circa due mesi di episodi di dolore toracico oppressivo della durata di circa 5-10 minuti non correlati allo sforzo. L'elettrocardiogramma non manifesta segni di ischemia. All'ecocardiogramma transtoracico e al successivo approfondimento transesofageo si riscontra una massa rotondeggiante a margini sfrangiati, di circa 10x12 mm, peduncolata, adesa al versante aortico della valvola aortica sulla cuspide coronarica sinistra in prossimità della commissura con la cuspide non coronarica. Tale formazione è situata in prossimità dell'ostio dell'arteria coronaria sinistra, risulta marcatamente mobile e appare prendere contatto con l'ostio coronarico in fase sistolica. Per le caratteristiche ecocardiografiche della formazione si sospetta la diagnosi di fibroelastoma. La posizione della massa rende rischiosa l'esecuzione di uno studio coronarografico, pertanto, per escludere una patologia coronarica, la paziente esegue una CoroTC che risulta nella norma. Il fibroelastoma è la seconda neoplasia benigna per incidenza dopo il mixoma. Si localizza tipicamente sulla valvola aortica (~30%) e meno frequentemente sulle valvole mitrale, tricuspide o polmonare. Presenta una tipica morfologia papillare e peduncolata (ad "anemone di mare") che predispone alla formazione di trombi tra le fronde ed alla loro embolizzazione distale verso il distretto coronarico o verso altri distretti sistemici; la localizzazione aortica può inoltre provocare l'ostruzione degli osti coronarici, determinando – come nel caso della nostra paziente – sintomatologia anginosa, ma anche sincopi e morte improvvisa. La localizzazione atrioventricolare può correlare invece con ostruzione al riempimento ventricolare, edemi polmonari ricorrenti e disfunzione ventricolare destra, ma anche con disturbi del sistema di conduzione su base compressiva, come ad esempio blocchi atrioventricolari completi. In caso di pazienti sintomatici la terapia consiste nell'escissione chirurgica della massa.

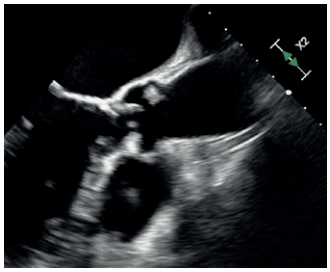

A656: SIMULATORE DI ECOCARDIOGRAFIA TRANS-ESOFAGEA: LA NUOVA FRONTIERA DELLA FORMAZIONE?

Lorenzo Bianchi (a), Paolo Costa (a), Gian Marco Rosa (a, b), Gian Paolo Bezante (a, b), Vered Gil Ad (b), Italo Porto (a, b)
(a) DIPARTIMENTO DI MEDICINA INTERNA, UNIVERSITÀ DI GENOVA, GENOVA, ITALIA; (b) UNITÀ DI MALATTIE CARDIOVASCOLARI, IRCCS OSPEDALE POLICLINICO SAN MARTINO, GENOVA, ITALIA

Introduzione. Negli ultimi anni è emersa l'importanza del training teorico-pratico, basato su sistemi di simulazione avanzata, nell'apprendimento di competenze specifiche in ambito medico. Le prove di efficacia di tale addestramento in ecocardiografia transesofagea (TE) sono scarse.
Obiettivi. Valutare l'impatto del training al simulatore per l'ecocardiografia TE nell'interpretazione diagnostica delle immagini e nell'acquisizione delle proiezioni secondo il protocollo standard della società americana di ecocardiografia (ASE) e della società europea di ecocardiografia (EACVI).
Metodi. 290 cardiologi ospedalieri e specializzandi all'ultimo anno (rispettivamente 95.2% e 4.8%) hanno partecipato al corso teorico-pratico di imaging cardiaco transesofageo di due giorni (14 ore) presso il centro di simulazione e formazione avanzata (SIMAV) dell'Università di Genova da maggio 2018 a maggio 2023, con un'interruzione di 18 mesi a causa della pandemia da COVID-19. I discenti erano divisi in gruppi da 15 partecipanti per ogni sessione e poi in sottogruppi da 5 in 3 postazioni a rotazione: un primo gruppo lavorava al simulatore US Mentor Simbionix Surgical Science (Sweden AB) mediante esecuzione di esami con casi clinici (come dissezione aortica e infarto) e acquisizione delle proiezioni secondo il protocollo delle società internazionali, un secondo gruppo osservava chi era al simulatore con discussione interattiva e un terzo gruppo seguiva lezioni frontali anche con casi clinici. All'inizio del corso è stato eseguito un test a risposta multipla con domande morfologico-funzionali e interpretazione diagnostica di immagini TE di procedure interventistiche strutturali, per testare le abilità di diagnosi pre-training. Dopo aver completato il corso teorico-pratico è stato ripetuto nuovamente lo stesso test teorico per valutare l'impatto delle abilità acquisite. Le domande del test erano divise in: anatomiche, basate sul riconoscimento di strutture cardiache e doppler/funzionali, per lo studio di device e/o protesi intracardiache.
Risultati. La popolazione di medici aveva un'età media di 45.2 ±11.1 anni, 164 erano maschi (57%) e 126 femmine (43%). Alla fine del training tutti erano in grado di completare la sequenza delle 28 proiezioni dell'esame ecocardiografico transesofageo standard (ASE ed EACVI). Si evidenziava un notevole incremento dei punteggi dopo il corso di formazione (p<0.0001). Le sottoanalisi mostravano un ruolo di rilievo delle domande morfologiche, infatti, l'errore di almeno 3 di queste nel primo test portava un miglioramento dopo il training (p<0.0001).
Conclusioni. Gli specialisti in cardiologia che hanno eseguito il training con simulatore avanzato hanno dimostrato un significativo miglioramento sia nell'interpretazione morfologica che nella diagnostica delle immagini TE. È stato altresì osservato un significativo miglioramento nell'acquisizione delle proiezioni del protocollo standard delle maggiori società di imaging cardiovascolare (ASE, EACVI). Questi risultati dovrebbero perciò incoraggiare un maggiore utilizzo della formazione avanzata con simulatori ecografici non solo per i cardiologi clinici ma e soprattutto nei corsi di specializzazione in malattie dell'apparato cardiovascolare e non solo (Medicina Interna, Anestesiologia e Rianimazione...).

A657: PROGNOSTIC SIGNIFICANCE OF LEFT VENTRICULAR GLOBAL LONGITUDINAL STRAIN ON ALL CAUSE MORTALITY AMONG PATIENTS WITH MODERATE AORTIC STENOSIS

Maria Vittoria Caprio (a), Federica De Donno (a), Giandomenico Bisaccia (a), Fabrizio Ricci (a, b, c), Giulia Renda (a, b), Sabina Gallina (a, b)
(a) DEPARTMENT OF NEUROSCIENCE, IMAGING AND CLINICAL SCIENCES, "G.D'ANNUNZIO" UNIVERSITY OF CHIETI-PESCARA, 66100 CHIETI, ITALY; (b) HEART DEPARTMENT, SS. ANNUNZIATA HOSPITAL, ASL 2 ABRUZZO, 66100 CHIETI, ITALY; (c) DEPARTMENT OF CLINICAL SCIENCES, LUND UNIVERSITY, 21428 MALMO, SWEDEN

Background and Aim. Aortic valve stenosis (AS) is the most common valve disease in developed countries. Several recent studies showed that, contrary to historical belief, patients with moderate AS also have a poor prognosis, with rapid disease progression which does not alter left ventricular (LV) ejection fraction until a later stage. In the present systematic review and meta-analysis, we sought to evaluate whether LV global longitudinal strain (GLS) might serve as a prognostic indicator in patients with moderate aortic stenosis.
Methods. We performed a systematic search of all studies enrolling patients with moderate AS undergoing echocardiographic evaluation of LV-GLS which reported on rates of all-cause death in patients with preserved compared to reduced LV-GLS, and collected data regarding the LV-GLS acquisition methodology and threshold implemented, along with relevant clinical information for each study sample. Adjusted effect sizes along with their confidence intervals were pooled in a random-effects model through the generic inverse variance method. Funnel plot asymmetry was visually inspected and small-study effects were assessed by means of Egger's test, with a p<.10 threshold of significance.
Results. Out of 81 identified citations, 33 were discarded as irrelevant. 48 potentially relevant articles were scrutinized, and 19 were excluded as not fulfilling the review inclusion criteria. Thus, a total of 5 studies published between 2014 and 2022 were identified, resulting in an overall pooled population of 1, 360 patients followed up for an average of 3.5 years (IQR 2.6-4.6). One study enrolled mixed patient populations of moderate and severe AS. Hazard ratios from multivariable analyses were pooled, which included adjusting for LV ejection fraction or stroke volume in 3 studies. Compared with those with preserved GLS, patients with reduced GLS had a 2-fold increase in risk of all-cause death (RR

1.65, 95%CI 1.14-2.40, p=0.008). The random-effects model yielded a high proportion of total variability due to between-study heterogeneity (I^2=93%). Inspection of a funnel plot revealed potential for small-study effects, further corroborated by Egger's test (p=0.02).
Conclusions. In variably adjusted analyses, LV-GLS showed potential to predict worse prognosis exemplified by all-cause mortality, but the body of evidence on the matter is mainly composed of nonrandomized observational studies. Future randomized clinical trials should investigate whether an LV-GLS-guided approach is feasible and effective in ameliorating long-term clinical outcomes among patients with moderate AS.

A658: ACUTE PULMONARY THROMBOEMBOLISM AND ISCHEMIC STROKE IN A YOUNG WOMAN: WHAT'S IN THE HEART?

Ludovica Carmagnola (a, b), Matteo Bellettini (a, b), Alessandro Vairo (a, b), Gaetano Maria De Ferrari (a, b)
(a) UNIVERSITÀ DEGLI STUDI DI TORINO; (b) OSPEDALE MOLINETTE

We describe the case of a 46-year-old woman with a silent past medical history, who presented to our emergency department for sudden onset of dyspnea and palpitations. On first clinical assessment was reported type 1 respiratory failure, sinus tachycardia, hypocapnic alkalosis, normal range of lactates. At chest CT scan was diagnosed acute pulmonary thromboembolism (PTE) and lung lesion suggestive of cancer; absence of echographic and clinical signs of deep vein thrombosis (DVT). The following day, she developed sudden onset of transitory aphasia and right arm plegia. On baseline brain CT scan was documented hypodensity of the left frontal region as from upper terminal branches of left middle cerebral artery (MCA) stroke. Transcranial Doppler with bubble test was performed on suspicion of patent foramen ovale (PFO), without micro-embolic signs (MES) both at baseline and after Valsalva maneuver. Transthoracic echocardiography (TTE) showed structurally normal heart, preserved flows, no shunt at color Doppler. As more sensitive imaging method, we performed a transesophageal echocardiography (TOE) to investigate intracardiac embolic sources. It pointed out an isoechogenic formation (4.7 x 5. 4 mm) adherent to free margin of right coronary cusp of the aortic valve (Image A, bi-plane mode B), suspicious for endocarditis. In addition, a voluminous isoechogenic formation (23 x 10 mm, bi-plane mode C, D) was found in the right ventricle, adhered with a wide base of implantation to the endocardium and to the tricuspidal subvalvular apparatus. The interatrial septum was morphologically normal with no evidence of shunt on ColorDoppler. Considering the absence of clinical or laboratoristics signs of active infection and the presence of prothrombotic state due to pulmonary neoplasm, the diagnosis of marantic endocarditis was defined. Onco-hematologic and cardiac surgery counseling was performed, with an indication to perform anticoagulation with subcutaneous heparin and re-evaluation at 30 days with TOE (follow-up will be available at the time of the congress).
Conclusions. PTE and acute ischemic stroke are common disorders with high morbidity and mortality, rarely presenting together. When this co-occurrence happens, it is usually a result of paradoxical embolism through PFO. Marantic endocarditis, associated with neoplastic hypercoagulable states, is a more rare, understudied, and underdiagnosed entity, which may cause ischemic stroke in the context of PTE. Therefore, in this clinical scenario, a TOE should be performed even in presence of a negative Transcranial Doppler.

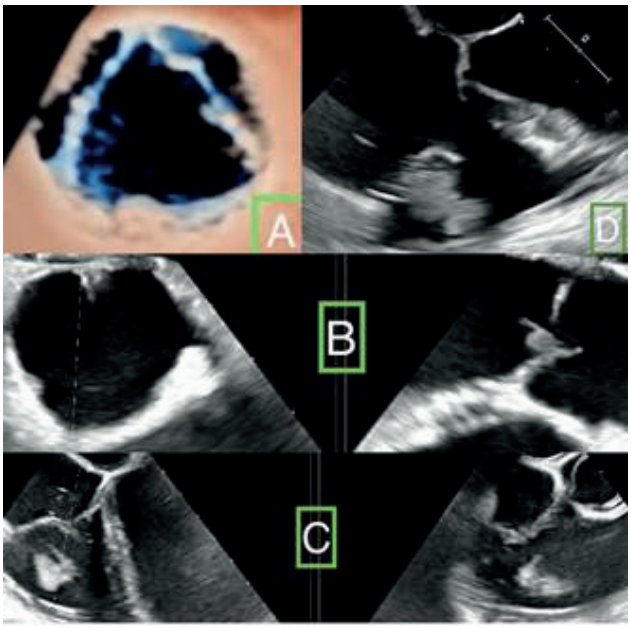

A659: MYOCARDIAL DEFORMATION ABNORMALITIES IN ARRHYTHMOGENIC CARDIOMYOPATHY: THE ROLE OF CARDIAC MAGNETIC RESONANCE.

Annagrazia Cecere (a), Martina Pezzella (a), Barbara Bauce (a), Domenico Corrado (a), Alessandro Zorzi (a), Alberto Cipriani (a), Manuel De Lazzari (a), Riccardo Bariani (a), Ilaria Rigato (a), Kalliopi Pilichou (b), Stefania Rizzo (b), Gaetano Thiene (b), Giulia Lorenzoni (c), Dario Gregori (c), Raffaella Motta (d), Giorgio De Conti (d), Cristina Basso (b), Sabino Iliceto (a), Martina Perazzolo Marra (a)
(a) CARDIOLOGY UNIT; DEPARTMENT OF CARDIAC, THORACIC, VASCULAR SCIENCES AND PUBLIC HEALTH, UNIVERSITY OF PADUA, PADUA, ITALY; (b) CARDIOVASCULAR PATHOLOGY UNIT; DEPARTMENT OF CARDIAC, THORACIC, VASCULAR SCIENCES AND PUBLIC HEALTH, UNIVERSITY OF PADUA, PADUA, ITALY; (c) UNIT OF BIOSTATISTICS, EPIDEMIOLOGY AND PUBLIC HEALTH; DEPARTMENT OF CARDIAC, THORACIC, VASCULAR SCIENCES AND PUBLIC HEALTH, UNIVERSITY OF PADUA, PADUA, ITALY; (d) RADIOLOGY UNIT; UNIVERSITY OF PADUA - AZIENDA OSPEDALIERA, PADUA, ITALY

Background. Arrhythmogenic cardiomyopathy (AC) is characterized by ventricular morpho-functional alterations, including systolic dysfunction, chamber dilation, fat infiltration and myocardial fibrosis. Myocardial strain, assessed by cardiac magnetic resonance (CMR) feature-tracking, allows to evaluate myocardial deformation, even in patients with preserved systolic function. However, myocardial strain and the role of morpho-functional alterations on myocardial deformation in AC patients haven't been fully investigated.
Purpose. The primary aim of the study was to evaluate the myocardial deformation in patients with definite diagnosis of AC. Secondly, we assessed the role of ventricular morpho-functional abnormalities, just described in AC patients, in the myocardial deformation impairment.
Methods. 69 consecutive patients (43 males; median age: 34 years) with a definite diagnosis of AC were enrolled. Patients with borderline or possible AC diagnosis were excluded. According to the Padua Criteria, patients were further subdivided on the basis of phenotypic variants: biventricular, left- and right-dominant variants. Morpho-functional analysis were performed. Myocardial deformation was assessed with evaluation of biventricular global radial, longitudinal and circumferential strain.
Results. 53 patients (34 males; median age: 34 years) had biventricular disease, 12 patients presented a left-dominant disease (6 males; median age: 32 years) and 4 patients (3 males; median age: 38 years) had only a right involvement of the disease. Patients with biventricular disease presented a reduced left ventricular (LV) global longitudinal strain (-14,2 versus -16,95 and -17,4, p<0.001) and reduced right ventricular (RV) global radial strain (12 versus 16 and 17, p:0.048), when compared with patients with the involvement of only LV or RV. Interestingly, the impairment of LV myocardial deformation was mainly due to the presence of LV dysfunction (for all radial, longitudinal and circumferential strain, p<0.001). Conversely, for the RV, the dilation was the main determinant of RV myocardial deformation abnormalities (for global radial and circumferential strain, p<0.001 and for circumferential strain p:0.019)
Conclusions. AC is associated with an impairment of myocardial deformation, regardless of clinical phenotype of disease. Different mechanisms seem to be involved in the myocardial deformation impairment for the two ventricles. Further studies are needed to confirm these results.

A660: PHENOTYPIC CHARACTERIZATION OF MITRAL ANNULAR DISJUNCTION IN MITRAL VALVE PROLAPSE: IMPLICATIONS FOR ARRHYTHMIC RISK STRATIFICATION

Giorgio Fiore (a), Vincenzo Rizza (a), Giacomo Ingallina (a), Francesco Ancona (a), Carlo Gaspardone (a), Federico Biondi (a), Davide Romagnolo (a), Davide Margonato (a), Annamaria Tavernese (a), Martina Belli (a), Stefano Stella (a), Eustachio Agricola (a)
(a) IRCCS OSPEDALE SAN RAFFAELE

Background. Mitral annular disjunction (MAD), commonly evaluated at end-systole, has been associated with malignant ventricular arrhythmias and sudden death. However, frame by frame analysis of echocardiographic images allows to distinguish between an atrial displacement of the posterior mitral valve leaflet hinge point both in diastole and systole (True-MAD, Fig 1) or in systole only (Pseudo-MAD, Fig 2). The prevalence of True-MAD and Pseudo-MAD in patients with mitral valve prolapse (MVP) and their association to other pro arrhythmogenic features is not known.
Aims. To assess the prevalence of True-MAD and Pseudo-MAD in patients with MVP evaluated by transthoracic echocardiography (TTE), assess their association with other features of arrhythmic risk and myocardial fibrosis and to validate TTE in terms of accuracy and reliability compared to cardiac computed tomography (CCT) or cardiac magnetic resonance (CMR) (reference standards).
Methods. Consecutive patients who underwent TTE for MVP at our referral center were included. True-MAD and Pseudo-MAD were independently assessed by two expert cardiologists blinded to each other using TTE parasternal long axis view. Accuracy and intra/inter rater reliability of TTE were assessed.

Results. Six-hundred-three patients were included. True-MAD prevalence was 7% (n=42), while Pseudo-MAD prevalence was higher (37%, n=221, p<0.05). Accordingly, 221 of 263 (84%) of patients classically classified as MAD would have been reclassified as Pseudo-MAD. Pseudo-MAD showed increasing prevalence and systolic length with higher mitral regurgitation (MR) severity grade (23% for mild MR, 36% for moderate MR, 44% for severe MR, p<0.05; 6 ± 2 mm for mild MR; 8 ± 2 mm for moderate MR; 10 ± 2mm for severe MR, p<0.05), while True-MAD prevalence was similar in all the grades of MR. Both Pseudo-MAD and True-MAD were associated to systolic curling, Pickelhaube sign and fibrosis at CMR with a stronger association for Pseudo-MAD. TTE showed an overall accuracy of 0.88 (0.80 – 0.94) with Cohen K 0.81 (0.71 – 0.92), a substantial inter-rater agreement of 0.87 (0.81 – 0.92) with Cohen K 0.76 (0.67 – 0.86) and an almost perfect intra-rater agreement of 0.93 (0.84 – 0.98) with Cohen K 0.85 (0.72 – 0.98).
Conclusions. True-MAD, unlike Pseudo-MAD, is rare in patients with MVP. Pseudo-MAD is strongly associated to the grade of MR and other echocardiographic features of arrhythmic risk. TTE is an accurate and reliable first line method to assess mitral annulus morphology in MVP.

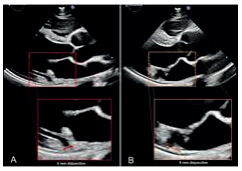

Figure 1. True-MAD.

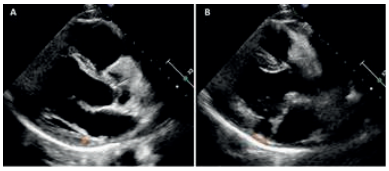

Figure 2. Pseudo-MAD.

A661: VALUE OF LEFT ATRIAL STRAIN IN CARDIAC AMYLOIDOSIS AND IN SARCOMERIC CARDIOMYOPATHY

Denise Cristiana Faro (a), Giancarlo Trimarchi (b), Fabrizio De Gaetano (a), Concetta Zito (b), Mariapaola Campisi (c), Valentina Losi (a), Lucio Teresi (b), Gianluca Di Bella (b), Corrado Tamburino (a), Cesare De Gregorio (b), Ines Monte (a)
(a) DEPT. SURGICAL AND MEDICAL-SURGERY SPECIALITIES, UNIVERSITY HOSPITAL OF CATANIA; (b) DEPT. CLINICAL AND EXPERIMENTAL MEDICINE, UNIVERSITY HOSPITAL OF MESSINA; (c) AZ.OSP. PROVINCICALE DI CATANIA, SANTA MARIA E SANTA VENERA HOSPITAL, ACIREALE

Background. Left atrial (LA) function is critical for assessing left ventricular filling in various cardiovascular conditions. Hypertrophic cardiomyopathies are characterized by increased LV thickness, diastolic dysfunction, elevated filling pressures, LA dilatation and progressive dysfunction to heart failure and arrhythmias. This study evaluates LA function and deformation using speckle tracking echocardiography (STE) in patients with cardiac amyloidosis (CA) or sarcomeric hypertrophic cardiomyopathy (HCM) and correlates the three LA strain parameters with LV-mass, diastolic and systolic function, and LV-GLS.
Methods. Ours is a retrospective, observational study conducted from January 2019 to December 2022. 100 patients were included: 33 with transthyretin CA and 34 with HCM, selecting a similar population by left ventricular ejection fraction. 33 subjects of similar age formed the control group (Co). Clinical evaluation, ECG, and transthoracic echocardiography (TTE) were performed and evaluated chamber dimensions, systolic and diastolic function. TTE images were analyzed in post-processing using EchoPac software for left ventricular global longitudinal strain (LV-GLS) and LA strain (LAS) quantification, including LA-reservoir, LA-conduit, and LA-contraction strain.
Results. The ATTR-CA group exhibited significantly impaired LA function compared to HCMs and Co groups, with LAS-reservoir median values of –9%, LAS-conduit –6.7%, and LAS-contraction –3%; this impairment was consistent even in the CA subgroup with preserved EF. LA strain parameters correlated with LV mass index, LA volume index, E/e', and LV-global longitudinal strain and were found to be associated with atrial fibrillation and exertional dyspnea.
Conclusions. LA function assessed by STE is significantly impaired in CA patients compared to HCMs patients and controls. These findings highlight the potential supportive role of STE in the early detection and management of the disease.

	CA N = 33	HCM N = 34	Co N = 33
EF, %	53 (40.5–58.5)	63.5 (58–69)	60 (56.5–63)
LVMi (g/sqm)	150 (123.5–188.5)	130.2 (117.2–153)	79 (68–96.5)
E/e'	16.3 (11.7–21.4)	10 (7.2–14.2)	6.5 (6–8.1)
LAVi (mL/sqm)	43.3 (37.4–53)	40 (37.5–57.2)	25.6 (20.6–30.5)
LAPSE mm	18 (15–21)	23 (20.5–25)	23 (20–26)
LV-GLS, %	12 (–10, –14.2)	15 (–11.7, –18)	19 (–18, –20.5)
LAS-reservoir, %	9 (5.8–16.6)	14.5 (9.7–25)	32 (25–38)
LAS-conduit, %	6.7 (–4.2, –8.6)	9 (–4.9, –15.3)	15 (–12.1, –18.5)
LAS-contract., %	–3 (–0.9, –10.3)	–6 (–3, –9.7)	–14.3 (–10.5, –19.5)

A662: CHANGES IN ATRIAL STRAIN IN LEFT ATRIAL APPENDAGE CLOSURE: RESULTS OF A PROSPECTIVE, MONOCENTRIC STUDY.

Letizia Moretti (a), Clara Geminiani (a), Chiara Ghiglieno (a), Roberta Rosso (a), Anna Degiovanni (a), Leonardo Grisafi (a), Giuseppe Patti (a)
(a) AOU MAGGIORE DELLA CARITÀ DI NOVARA

Background. Percutaneous left atrial appendage closure (LAAC) has proven to be an effective and safe alternative to oral anticoagulation (OAC) for cardioembolic stroke prevention in patients with non-valvular atrial fibrillation (NVAF) and contraindication to OAC. Since the impact of LAAC on Left Atrial function remains poorly characterized, we sought to assess the impact of LAA closure on LA function evaluating changes in LA strain by transthoracic echocardiography, after LAAC.
Methods. The study included 59 patients undergoing LAAC in a single center between October 2019 and April 2023. The echocardiographic parameters evaluated were: Peak Atrial Longitudinal Strain (PALS), Peak Atrial Contraction Strain (PACS), Left Atrial Volume index (LAVI), Left ventricular ejection fraction (LVEF), E/e' ratio, tricuspid anulus systolic velocity (S'), Left ventricular end-diastolic diameter, Left atrial antero-posterior diameters, LV mass, pulmonary artery systolic pressure (PAPS). PACS was obtained only in patients with sinus rhythm at the time of examinations. Comprehensive transthoracic echocardiography evaluation was performed at four different time intervals (baseline, 6 hours, 24 hours and 30 days after procedure). All data were analyzed using the software: Philips QLAB ComPACS and GE Echopac.
Results. No statistically significant changes were observed in PALS (16,53 ± 8,67 vs 17,10 ± 7,41, p=0,64) and LAVi (47,28 ± 18,12 vs 53,34 ± 26,04 p=0,09) after LAAC, either early after the procedure (6h and 24h) or at 30-day follow-up. Compared to baseline, PACS has a significant reduction at 6h (4.73 ± 2.20 vs 8.89 ± 4.14, p=0.02) and 24h (12.04 ± 5.29 vs 3.77 ± 5.05 p<0.001) after the procedure. This is compatible with the implantation of the device in the left atrium. PACS values returned similar to baseline levels at 30 days (11.58 ± 6.63 to 7.37 ± 7.20 p=0.24).
Conclusions. Our study shows that LAAC has no impact on LA function in terms of distensibility and contractility, except for a transient, early reduction of contractile function. It may be explained by atrial compensation and remodeling mechanisms and regresses at 30 days after the intervention.

A663: QUANTIFICATION OF GRANULAR SPARKLING AT ECHOCARDIOGRAPHY IN PATIENTS WITH TRANSTHYRETIN-RELATED CARDIAC AMYLOIDOSIS USING RADIOMIC AND MATHEMATICAL MORPHOLGY FEATURES

Sara Mori (a), Marco Canepa (a, b), Italo Porto (a, b), Pier Filippo Vianello (b), Cristina Campi (c), Maria Pia Sormani (d), Noemi Montobbio (d), Matteo Cameli (e), Giulia Elena Mandoli (e), Francesca Rubina Ginetti (e)
(a) DEPARTMENT OF INTERNAL MEDICINA (DIMI), UNIVERSITY OF GENOA, GENOA, ITALY; (b) CARDIOVASCULAR UNIT, IRCCS OSPEDALE POLICLINICO SAN MARTINO, GENOA, ITALY; (c) DIPARTIMENTO DI MATEMATICA (DIMA) UNIVERSITÀ DI GENOVA, GENOVA, ITALY; (d) BIOSTATISTICS UNIT, DEPARTMENT OF HEALTH SCIENCES (DISSAL), UNIVERSITY OF GENOA, GENOA, ITALY; (e) DEPARTMENT OF MEDICAL BIOTECHNOLOGIES, DIVISION OF CARDIOLOGY, UNIVERSITY OF SIENA, SIENA, ITALY

Granular sparkling is a well-known echocardiographic feature found in patients with transthyretin-related cardiac amyloidosis (ATTRCA). However, there is no objective technique for quantifying this feature, which therefore remains a qualitative, elusive and ultimately unreliable imaging characteristic. The aim of this study is to statistically and geometrically characterise granular sparkling as a volumeindependent texture property of the myocardium in patients with ATTR-CA. We collected echocardiogram video-clips in parasternal long axis and 4-chamber view of 58 patients with ATTR-CA wild type, and 60 age- and gender-matched patients without any known cardiac disease except hypertension, followed at San Martino Hospital, Genoa, and Le Scotte Hospital, Siena. For each video-clip, one end-diastole and one end-systole frame was extracted and annotated by an expert to identify a regionof-interest (ROI) within the interventricular septum (IVS). Left ventricle chamber masks were also extracted, and used as a brightness reference to enforce invariance w.r.t. the settings of the specific ultrasound system. Many established radiomic textural features are also heavily volume-confounded. We analysed the ROI texture by extracting a subset of volume-invariant radiomic features, as well as morphological granulometry features. We then fitted a support vector machine (SVM) classifier to discriminate between ATTR-CA and controls based on the computed textural features. The texturebased classifier predicted the diagnosis with a cross-validated accuracy of 80%. Moreover, mathematical morphology analyses revealed a significantly smaller grain size in the IVS tissue of patients with ATTR-CA as compared to controls (mean±SEM: 0.152 ± 0.007 vs. 0.184 ± 0.007 cm, p=0.0012). Our results confirm the presence of morphological differences in the IVS tissue between ATTR-CA patients and healthy controls detectable from echocardiography, with a more distinctly granular texture associated with cardiac amyloidosis. A potential secondary objective to be evaluated in the future will be to ascertain whether the degree of granularity correlates with the severity of the disease within the group of patients with ATTR-CA.

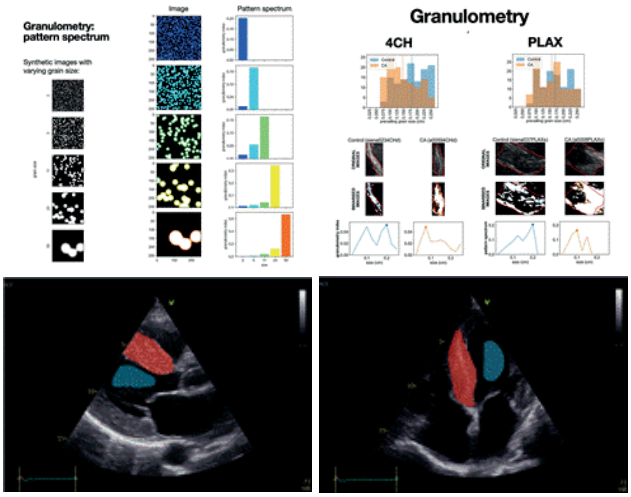

A664: MIGLIORAMENTO DELLA FUNZIONE SISTO-DIASTOLICA VENTRICOLARE SINISTRA PRE- E POST-CHIRURGIA BARIATRICA VALUTATO MEDIANTE ECOCARDIOGRAFIA SPECKLE TRACKING

Maurizio Collantoni (a), Maria Concetta Pastore (a), Cristina Ciuoli (b), Giulia Elena Mandoli (a), Luna Cavigli (a), Elisa Giacomin (a), Flavio D'Ascenzi (a), Matteo Cameli (a), Marta Focardi (a)
(a) DEPARTMENT OF MEDICAL BIOTECHNOLOGIES, DIVISION OF CARDIOLOGY, UNIVERSITY OF SIENA, SIENA, ITALY; (b) SECTION OF ENDOCRINOLOGY, DEPARTMENT OF MEDICAL, SURGICAL AND NEUROLOGICAL SCIENCE, UNIVERSITY OF SIENA, SIENA, ITALY

Background. È stato visto che la perdita repentina di peso nel paziente obeso determina una precoce riduzione della massa del ventricolo sinistro (VS) ed un miglioramento della funzione sisto-diastolica. L'ecocardiografia speckle tracking (STE), ha dimostrato un valore aggiunto nel fornire informazioni quantitative e riproducibili sulla funzione ventricolare ed atriale sinistra. Lo strain del VS ed atriale sinistro (AS) si sono dimostrati marker di rimodellamento miocardico e sono raccomandati dalla società europea di cardiologia (ESC) per la stima della funzione diastolica e diagnosi di scompenso cardiaco diastolico, il cui fenotipo tipico è rappresentato dal paziente obeso. Tuttavia, poche evidenze esistono circa il ruolo della STE nel paziente obeso. Lo scopo del nostro studio è quello i cambiamenti della funzione di VS ed AS, analizzati mediante STE, in pazienti sottoposti ad intervento di chirurgia bariatrica dal basale a 3 mesi dall'intervento.
Metodi. In questo studio prospettico sono stati arruolati pazienti consecutivi candidati a chirurgia bariatrica in valutazione preoperatoria presso i nostri ambulatori. Sono stati esclusi pazienti con note patologie cardiovascolari pre-esistenti e fibrillazione atriale al momento dell'arruolamento. I pazienti sono stati sottoposti ad ecocardiografia completa di STE prima dell'intervento e rivalutati clinicamente e mediante ecocardiografia a 3 mesi circa dall'intervento. Come endpoint primario è stato valutato un eventuale miglioramento della funzione sistolica e diastolica del VS misurate con parametri di ecocardiografia base e STE.
Risultati. La popolazione in studio era composta da 21 pazienti (età media 39±11 anni, 81% sesso femminile, n=17). Al basale i pazienti presentavano normali valori di funzione sistolica misurati mediante frazione d'eiezione del VS (59±2%). Dopo 3 mesi dal trattamento chirurgico bariatrico, è stata evidenziata una considerevole perdita di peso (94±12 kg vs. 124±20 kg, p<0.0001) nella popolazione in studio. Inoltre, i pazienti presentavano differenze significative nei parametri di spessore del VS dal basale a 3 mesi (setto interventricolare=10.3±1.2 vs. 9.4±1.5 mm, p=0.002; parete posteriore=10±1.2 vs. 9±1.3, p=0.008), si time (indice di funzione diastolica, 259±66 vs. 232±73, p<0.0001 ms). Riguardo i parametri STE, è stato mostrato un trend di miglioramento dello strain del VS (-17.6±8.3 vs. -20.4±2.1%, p=0.11) e dello strain di resevoir dell'AS (PALS, 39±8 vs. 40±10,% p=0.78) ed un miglioramento significativo dello strain di contrazione dell'AS (PACS, 13.1±3 vs. 16±3.7%, p<0.0001).
Conclusioni. I risultati di questo studio pilota suggeriscono che la perdita di peso indotta dalla chirurgia bariatrica produca un rimodellamento precoce delle camere cardiache con un miglioramento della funzione sistolica e diastolica ventricolare sinistra. Tali risultati dovranno essere confermati analizzando una maggiore numerosità di popolazione.

A665: ROLE OF CT SCAN IN NEWBORNS AND INFANTS WITH CONGENITAL HEART DISEASES

Alice Pozza (a), Irene Cattapan (a), Jennifer Fumanelli (a), Elena Reffo (a), Martina Avesani (a), Roberta Biffanti (a), Domenico Sirico (a), Alessia Cerutti (a), Biagio Castaldi (a), Giovanni Di Salvo (a)
(a) PEDIATRIC CARDIOLOGY UNIT, DEPARTMENT OF WOMEN'S AND CHILDREN'S HEALTH, UNIVERSITY OF PADUA

Background. Despite advances in diagnosis and surgical care, congenital heart defects (CHD) remain one of the leading causes of death in infants. Improvements in diagnostic techniques brought to a better understanding of CHD, thus allowing a more comprehensive clinical and surgical management. Echocardiography (Echo) remains the leading imaging modality in children diagnosed with CHD because of easy availability, limited costs and safety. In recent years a larger interest regarding the use of computed tomography scan (CT) in pediatric cardiology has been achieved. However, CT use is generally limited because of safety concerns (risk for ionizing radiation, need for sedation) and low image quality due to motion's artifacts.
Purpose. Aim of this study was to evaluate the differences in diagnostic performance of Echo and CT; to compare the capability of each imaging modality, focusing in how clinical and surgical management are affected accordingly to each imaging technique.
Methods. Retrospective longitudinal single center study, involving 22 patients aged <1 year (11 newborns, 11 infants) diagnosed with CHD between 2020-2023. Newborns diagnosed with CHD undergone Echo in early days' life (mean days 1.5) and results were further discussed in cardiologic multidisciplinary meeting to evaluate future surgical plan. For those whose cardiac anatomy was challenging a CT was performed (mean age 10 days). Infants diagnosed with CHD underwent CT just before surgery (mean age 162.91 days) as part of the surgical planning. We compered these data with the most recent Echo assessment. We revised the main indications to perform an advanced imaging and compared the final reports of Echo and CT. We tried to understand whether CT reports addressed a different surgical approach if compered to Echo indications.
Results. In newborn population main indications for CT were evaluation of coronary artery anatomy (4), multiple aorto-pulmonary artery collaterals (2), great vessels abnormalities (3 aortic arch anomalies, 1 pulmonary artery anomaly, 1 anomalous venous return). Comparison between Echo and CT showed good agreement in 6 cases, while in 5 cases CT add more details to diagnosis. In infants CT were performed in case of challenging coronary artery anatomy (2), anomalous venous returns (3); better definition of intracardiac anatomy (6). In 7 cases Echo and CT reports were comparable, whereas disagreed in 4 cases. Disagreement in the reports were mainly due to coronary artery anomalies and definition of pulmonary venous return anatomy. However, only in one case CT findings significantly changed the surgical plan for patients.
Conclusions. In both population intracardiac anatomy was well depicted either by Echo or CT. According to literature, CT plays an incremental value in the assessment of extra-cardiac and vascular anatomies, notoriously difficult to be assessed by Echo. On the other hand, Echo is superior to CT to assess valvular anatomy and function. Indeed, in those cases CT was not performed. In conclusion, multimodality imaging is of paramount importance to plan the surgical and interventional management of complex CHD. A full knowledge of tip and tricks of the available tools is mandatory for practitioners dealing with CHD.

A666: DUAL APICAL HYPERTROPHIC CARDIOMYOPATHY AND ENDOMYOCARDIAL FIBROSIS PATHOLOGY

Chiara Martini (a), Davide Maria Scordo (a), Lorenzo Vilhelm Molinari (a), Sabina Gallina (a), Fabrizio Ricci (a)
(a) UNIVERSITÀ "G. D'ANNUNZIO" CHIETI - PESCARA

A 66-year-old man was referred to our cardiology unit for worsening shortness of breath on exertion. ECG showed sinus rhythm, QS complex in lead V1 and V2 and diffuse negative symmetric T waves (Panel A). Echocardiography revealed thickened apical segments with obliteration of the left ventricular cavity and a mobile intraventricular isoechoic mass of 40x35 mm (Panel B, asterisk). Low-molecular-weight-heparin and warfarin were immediately started. Blood tests documented absolute eosinophil count of 4500/μL. After a thorough workup ruled out causes for secondary eosinophilia, a diagnosis of hypereosinophilic syndrome was suspected. CMR imaging documented the presence of relative apical hypertrophy with abnormal baso-apical tapering of left ventricular wall thickness, papillary muscle apical displacement, elongated anterior mitral valve leaflet and revealed major diagnostic criteria of endomyocardial fibrosis with a layer of subendocardial late gadolinium enhancement lining the apical segments of both ventricles with superimposed intracavitary thrombosis (Panels C to H). Endomyocardial biopsy obtained from the right ventricular septum confirmed the fibrous thickening of the endocardium and presence of focal areas of myofibrillar disarray and replacement fibrosis. The patient was discharged on warfarin but declined steroid treatment and genetic testing. Six-month follow-up was uneventful with partial resolution of left ventricular thrombosis. We present a case of dual apical hypertrophic cardiomyopathy and endomyocardial fibrosis pathology in a patient with idiopathic hypereosinophilic syndrome, a rare disorder with frequent cardiac involvement featuring endocardial fibrous tissue proliferation. Treatment is mainly directed towards prevention and management of chronic heart failure, arrhythmia, pulmonary hypertension, and thromboembolic events.

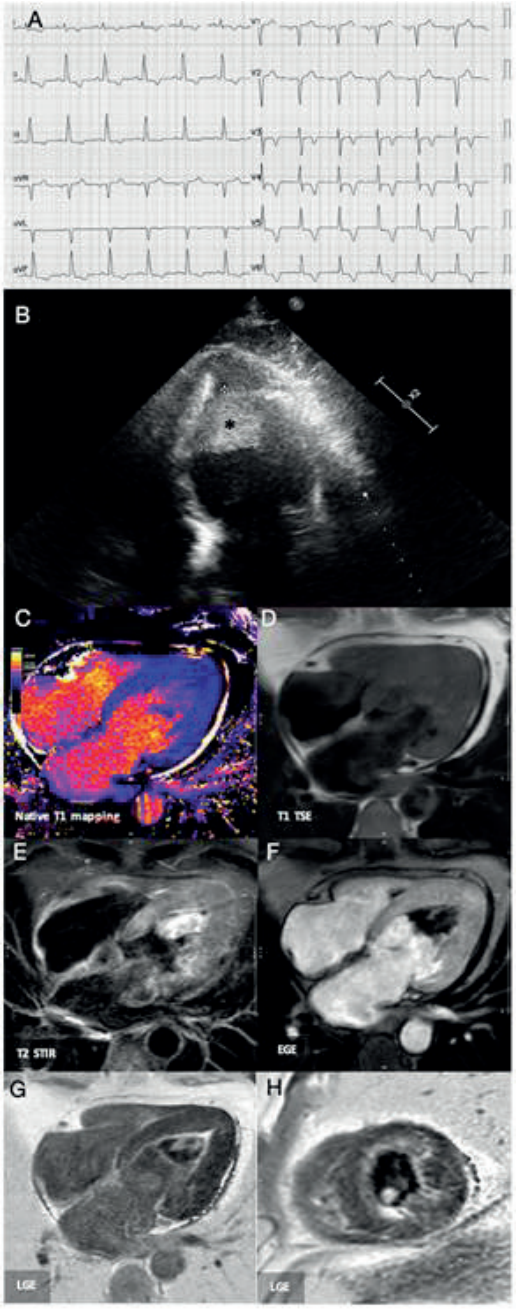

A667: SINUS VENOSUS ATRIAL SEPTAL DEFECT MISDIAGNOSED AS PATENT FORAMEN OVALE: WHEN BUBBLES LIES.

Vincenzo Riverso (a), Andrea Carbone (a), Jessica Ielapi (a), Angelo Leone (b), Daniela Chiappetta (b), Oscar Serafini (b), Mario Leporace (d), Francesco Greco* (b), Alberto Polimeni* (b, c)
(a) DIVISION OF CARDIOLOGY, DEPARTMENT OF MEDICAL AND SURGICAL SCIENCES, 'MAGNA GRAECIA' UNIVERSITY, 'RENATO DULBECCO' HOSPITAL, CATANZARO, ITALY; (b) DIVISION OF INTERVENTIONAL CARDIOLOGY, 'ANNUNZIATA' HOSPITAL, COSENZA, ITALY; (c) DEPARTMENT OF PHARMACY, HEALTH AND NUTRITIONAL SCIENCES, UNIVERSITY OF CALABRIA, COSENZA, ITALY; (d) DIVISION OF NUCLEAR MEDICINE, 'MARIANO SANTO' HOSPITAL, COSENZA, ITALY

Background. Sinus venosus atrial septal defect (SVASD) is a rare cardiac abnormality, provoking a right-to-left shunt (RLS) at the atrial level. Occasionally, cryptogenic stroke (CS) may be the first presentation of an atrial septal defect (ASD).
Discussion. There are multiple mechanisms by which ASCS may produce both false-positive and false-negative results for presence of PFO. In the case presented, the event was initially thought to be related to a PFO on bubble contrast TTE, however, the absence of RLS following the change of contrast injection site made the diagnosis less clear. The difference between femoral and antecubital injection was significant. This may be caused by different inflow patterns to the right atrium (RA): SVASD is usually located at the junction of the RA and superior vena cava (SVC), facilitating contrast passage to the left atrium with by injection via the antecubital vein of the arm, whereas inferior vena caval flow is directed towards the RA septum, and is therefore more likely to pass through the PFO if present.
Conclusions. Misinterpretation of ASCS can lead to incorrect diagnosis, subjecting patients to additional or inappropriate procedures and their inherent risk. In patients in whom the diagnosis remains uncertain after echocardiographic assessment, cardiac CT and MRI may provide complementary information to characterize an ASD and associated abnormalities.

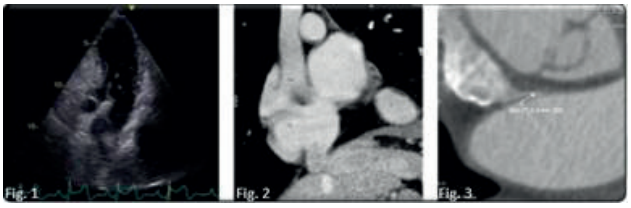

A668: INCIDENTAL FINDING OF A GIANT CORONARY SINUS IN A PATIENT WITH UNEXPLAINED SYNCOPE

Cristina Sasso (a), Maria Vincenza Polito (c), Alessandra Coppola (b), Marisa Malinconico (c), Michele Ciccarelli (a), Carmine Vecchione (a), Gennaro Galasso (a)
(a) DEPARTMENT OF MEDICINE, SURGERY AND DENTISTRY, UNIVERSITY OF SALERNO, BARONISSI, SALERNO, ITALY; (b) DIVISION OF RADIOLOGY, A.O.U. SAN GIOVANNI DI DIO E RUGGI D'ARAGONA, P.O. CAVA DE' TIRRENI, SALERNO, ITALY; (c) DEPARTMENT OF CARDIOLOGY, A.O.U. SAN GIOVANNI DI DIO E RUGGI D'ARAGONA, P.O. CAVA DE' TIRRENI, SALERNO, ITALY

Background. A dilated coronary sinus may be observed during transthoracic echocardiography (TTE) and, when present, should lead to the suspicion of Persistent Left Superior Vena Cava (PLSVC). It is the most common congenital anomaly of thoracic venous system, diagnosed in only 0.3%–0.5% of the general population. It drains into the right atrium via the coronary sinus in 90% of cases and is usually asymptomatic. However, in some cases, a dilated coronary sinus may be a potential cause of conduction disorders (AV block, junctional rhythm) due to stretching and compression of the AV node and His bundle.
Case presentation. A 63-years-old male was admitted to our Emergency Department for syncope. He referred that a similar event, not further investigated, occurred five years before. Hemodynamic parameters, clinical examination and ECG were normal. TTE showed preserved EF without abnormalities of regional kinesis and valvular diseases were excluded. Interestingly, in parasternal long and short axis view and in four, two and three chambers apical view, a dilatated coronary sinus (max diameter 1.6 x 1.5 cm) was detected. Thus, agitated saline injection from left arm was administered, showing sequential opacification of coronary sinus and right atrium. Hypothesizing the presence of PLSVC, a contrast-enhanced computer tomography (CT) was performed that confirmed the diagnosis and excluded other vascular abnormalities. Finally, we performed a transesophageal echocardiography (TEE) to exclude other congenital heart disease (such as atrial septal defects, unroofed coronary sinus). No syncope or arrhythmias occurred during hospitalization and loop recorder implantation was planned in case of recurrent events of syncope.
Conclusions. PLSVC is often incidentally diagnosed also in advanced age and should be suspected by the presence of a dilated coronary sinus. Agitated saline injection from both arms, monitoring its sequential arrival in the coronary sinus and right atrium, is a simple method to increase the suspicion. More advanced imaging techniques are recommended for a more comprehensive evaluation and for a definitive diagnosis, very useful in patients who will undergo cardiopulmonary bypass, catheter or pacemaker lead placement or left subclavian vein cannulation and in cases of inexplicable conduction disorders.

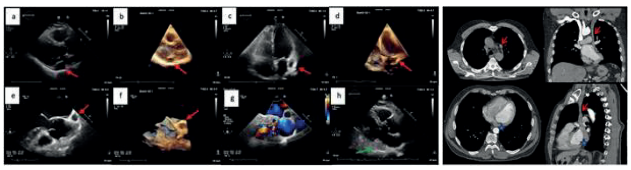

A669: MULTIMODALITY IMAGING FOR CARACTHERIZATION OF CARDIAC THIMOMA

Matteo Spoladori (a), Giulia Grassa (c), Andrea Agostinelli (c), Anselmo Alessandro Palumbo (b), Walter Serra (a)
(a) CARDIOLOGY UNIT UNIVERSITY HOSPITAL OF PARMA; (b) RADIOLOGY UNIT UNIVERSITY HOSPITAL OF PARMA; (c) HEART SURGERY INSTITUTE UNIVERSITY HOSPITAL OF PARMA

In July 2023, a 56-year-old woman presented at our center after a routine cardiology check-up in which an echocardiogram revealed a mobile, pedunculated oval formation, approximately 2 by 2 cm in size, located within the right atrium at the interatrial septum. Despite her condition, the patient showed no symptoms and displayed good cardiac performance. Her previous medical history included ovarian and intestinal endometriosis, polycythemia vera, and a thymoma diagnosis in 2015. The thymoma was initially detected through an MRI performed due to a tamponade of blood within the pericardium. To address the issue, two attempts were made in 2015 and 2016 to remove the mass through a median sternotomy. Subsequently, the patient underwent successful cycles of chemotherapy. Follow-up PET-CT scans revealed no recurrence until 2021 when a transesophageal echocardiogram indicated the presence of a mobile, irregularly shaped mass, measuring about 7 by 5 cm, adjacent to the tricuspid valve. Another surgical intervention was conducted to remove the mass, which was found to have originated from the coronary sinus. Histological analysis confirmed that the intracardiac mass was consistent with a B3 thymoma. Throughout her hospitalization, the patient experienced intermittent episodes of atrial fibrillation, which were managed using pharmacological cardioversion. Upon arrival at our center, the patient remained asymptomatic in cardiovascular terms. During her stay, a CT scan of the chest and abdomen confirmed the existence of a 21x22 mm mobile, pedunculated, rounded mass Fig 1-2. Moreover, heterogeneous tissue was observed anterior to the ascending thoracic aorta. A PET scan, utilizing labeled fluorodeoxyglucose, exhibited tracer accumulation areas within the right atrium and in the anterior mediastinum, situated anterior to the ascending aorta. Notably, a cerebral CT scan displayed no significant pathological findings. The subsequent day, a transesophageal echocardiogram (TEE) reaffirmed the presence of a mobile, rounded, mulberry-like, pedunculated mass originating from the coronary sinus, with a maximum diameter of 23x22 mm (Fig3-4-5). Tissue Doppler imaging confirmed mechanical activity within the mass. In light of these findings, which indicated a recurrence of the known thymoma with infiltration of the right atrial wall, the coronary sinus, and possibly the anterior wall of the ascending aorta, a multidisciplinary team, including cardiothoracic surgeons, oncologists, radiotherapists, and radiologists, collectively reviewed the case. Given the high surgical risk associated with a potentially extensive and demolishing reoperation and the limited likelihood of complete eradication, the patient and her family agreed to pursue a therapeutic approach involving chemotherapy combined with positron therapy. Thymomas are malignant neoplasms derived from the epithelial component of the thymus with an annual incidence 0.15 to 0.19/100,000[1]. Commonly they occur in middle-aged adults patients with symptoms due to mass effect, neuromuscular disorders (myasthenia gravis), paraneoplastic or metastases, and are sometimes found incidentally during thoracic imaging. Multidisciplinary treatment approach is vital. In the circumstance of cardiac involvement, surgery may still play a role in the patient management depending on degree and location of involvement.

References

Hsu C-H, Chan JK, Yin C-H, et al. Trends in the Incidence of Thymoma, Thymic Carcinoma, and Thymic Neuroendocrine Tumor in the United States. PloS One 2019;14:e0227197.

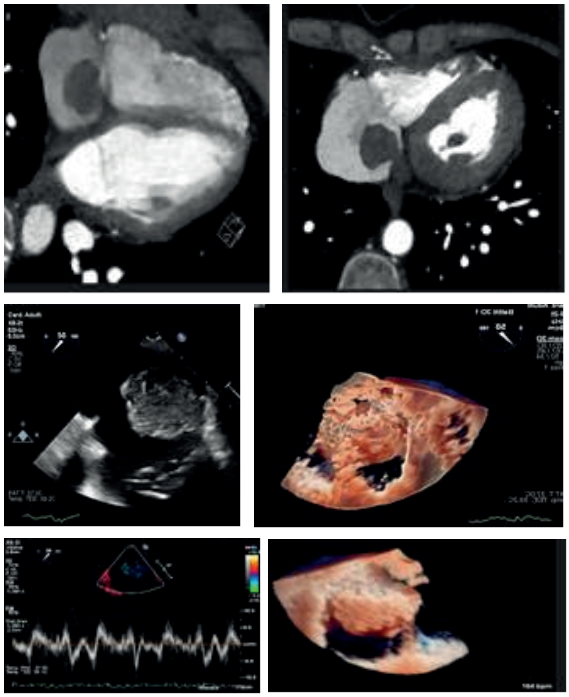

A670: LO STRAIN ATRIALE NEI PAZIENTI CON SCLEROSI SISTEMICA: UNO STUDIO CASO-CONTROLLO

Giulia Stronati (a), Federico Paolini (a), Michele Alfieri (a), Leonardo Brugiatelli (a), Gianmarco Bastianoni (a), Alessandro Barbarossa (a), Samuele Principi (a), Alice Frangione (a), Edlira Rrapaj (a), Devis Benfaremo (b), Gianluca Moroncini (b), Michela Casella (a), Antonio Dello Russo (a), Federico Guerra (a)
(a) CLINICA DI CARDIOLOGIA ED ARITMOLOGIA, OSPEDALI RIUNITI "ANCONA", UNIVERSITÀ POLITECNICA DELLE MARCHE; (b) CLINICA MEDICA, OSPEDALI RIUNITI "ANCONA", UNIVERSITÀ POLITECNICA DELLE MARCHE

Background. Systemic sclerosis (SSc) is a chronic autoimmune disease characterized by small vessel vasculopathy, autoantibodies production and exaggerated extracellular matrix deposition, leading to extensive tissue fibrosis. Cardiac involvement in SSc, albeit often asymptomatic, is frequent and represents a negative prognostic factor. Speckle tracking global longitudinal strain (GLS) has proved itself to be an effective tool to identify the presence and the progression of subclinical SSc-related cardiomyopathy, defined as a primary heart condition affecting both the right and left ventricle. The aim of our study was to assess whether SSc-related cardiomyopathy affects not only the ventricles but also the right (RA) and left atria (LA) in patients with SSc and no overt cardiac disease nor pulmonary hypertension.
Methods. Observational prospective study enrolling all consecutive patients with SSc age- and gender-matched 1:1 to healthy controls. Patients with structural heart disease, heart failure, atrial fibrillation and pulmonary hypertension were excluded. For every patient, standard echocardiographic parameters and speckle-tracking derived variables were registered. The reservoir function (from the end of ventricular contraction to to mitral valve opening), conduit function (from mitral valve opening through the onset of atrium contraction) and contraction function (from the onset of atrium contraction to the end of ventricular diastole) were assessed via GLS. Zero strain reference was set at left ventricular end diastole.
Results. Fifty-two SSc patients and matched controls were consecutively enrolled. Left ventricular ejection fraction (66.5%±7.4% vs. 66.1%±5.9%; p=ns) right fractional area change (49.4%±9.6% vs. 49.2%±9.2%; p=ns) and mean sPAP (29.0%±5.3% vs. 24.4%±4.1%; p=ns) were well within the normal range and similar between SSc patients and controls. Right atrial reservoir function (35.0%±7.3% vs. 42.3%±8.5%; p=.024) and contraction function (14.8%±4.3% vs. 18.5%±4.1%; p=.034) were significantly lower in SSc patients when compared to matched controls. No difference was seen in right atrial conduit function or left atrial strain. In patients with SSc RA reservoir (r=.194; p=.033) and conduit function are directly associated to right ventricular GLS (r=.174; p=.036). LA reservoir (r=.260; p=.008) and conduit function (r=.271; p=.006) are directly associated with left ventricular GLS. No association was observed between contraction function and GLS in both left and right chambers. Moreover, RA and LA reservoir (r=.358; p=.02), conduit (r=.525; p=.004) and contraction functions (r=.30; p=.0.18) are directly correlated.
Conclusions. While no significant difference was seen between cases and controls in terms of common echocardiographic parameters, RA reservoir and contraction function assessed through GLS were significantly impaired in patients with SSc. The correlation between impaired atrial and ventricular GLS in SSc could represent another indirect evidence of SSc-related heart global involvement.

A671: RIGHT-SIDED FUNCTION IN SYSTEMIC SCLEROSIS: NEW INSIGHT BY STANDARD AND ADVANCED ECHOCARDIOGRAPHY

Lucia Tricarico (a, c), Ester Bevere (c), Deborah Villani (c), Francesca Croella (c), Debora Ruggeri (c), Celeste Migliozzi (c), Luciano Umberto Rossi (c), Mattia Granato (c), Michele Granatiero (c), Antonio Vitullo (c), Rossella De Luca (c), Raffaele Capasso (c), Laura Giannetti (c), Gianluca Poliso (c), Simone Puglisi (c), Michele Correale (a), Massimo Iacoviello (a, c), Addolorata Corrado (b, c), Francesco Paolo Cantatore (b, c), Natale Daniele Brunetti (a, c)
(a) DEPARTMENT OF CARDIOLOGY, POLICLINICO RIUNITI FOGGIA; (b) DEPARTMENT OF RHEUMATOLOGY, POLICLINICO RIUNITI FOGGIA; (c) DEPARTMENT OF MEDICAL AND SURGICAL SCIENCES, UNIVERSITY OF FOGGIA

Background. Systemic sclerosis (SSc), an uncommon autoimmune disorder, adversely impacts the body's connective tissue. This results in an immune system malfunction, provoking inflammation and excessive collagen production. While it primarily impacts the skin, it can also involve internal organs, including the heart. The right ventricle can be particularly susceptible to damage in individuals with systemic sclerosis, especially when pulmonary hypertension develops as a complication. Cardiovascular complications in SSc significantly impact both mortality and quality of life.
Aim of the study. To analyze echocardiographic parameters related to right heart function in SSc patients and compare them with those of the healthy adult population to identify potential differences.
Methods. Patients with SSc were followed up between February 2022 and June 2023. At the same time healthy individuals with similar characteristics were enrolled. Multiparametric standard and advanced echocardiography were performed in an outpatient setting.
Results. Sixty-seven patients with SSc (mean age 60.58 ± 10.06, female sex 94%) and forty-eight healthy individuals (mean age 57.98 ± 11.05, female sex 92%) were recruited for the study. Among the SSc patients, 11 exhibi-

ted a TR velocity>280 msec and a TAPSE <16 mm. Statistically significant differences between SSc patients and healthy individuals were observed in the following echocardiographic parameters: pulmonary trunk diameter (21.4 ± 3.47 mm vs 20.89 ± 2.64 mm, p value 0.023), RVOT act (112.69 ± 31.12 vs 135.63 ± 23, p value 0.057), TAPSE (22.60 ± 2.64 mm vs 24.81 ± 3.6 mm, p value 0.017), TR velocity (250.95 ± 44.94 vs 229.83 ± 23.12, p value 0.019), systolic TR gradient (26.10 ± 10.49 mmHg vs 21.37 ± 4.44 mmHg, p value 0.032), sPAP (31.4 ± 11.5 mmHg vs 26.38 ± 4.44 mmHg, p value 0.038), and RA area (21.17 ± 3.66 vs 14.27 ± 2.24, p value 0.036). When comparing SSc patients with TR velocity>280 msec to those without, the following variables were statistically significant: systolic TR gradient (39.72 ± 18 mmHg vs 23.42 ± 5.37 mmHg, p value 0.007), RAP (5.91 ± 3.01 vs 5.18 ± 0.93, p value 0.002), sPAP (45.64 ± 20.96 mmHg vs 28.61 ± 5.51 mmHg, p value 0.004), and RA strain (26.52 ± 9.64 vs 26.3 ± 5.52, p value 0.046).

Conclusions. Our study revealed altered echocardiographic parameters related to right heart function in SSc patients without pulmonary hypertension. This highlights the importance of an early multiparametric assessment. To validate these findings, additional multicenter studies are required.

A672: NOT ONLY AN ACUTE MYOCARDIAL INFARCTION: A SUSPICIOUS LEFT VENTRICULAR OUTPOUCHING

Michele Trichilo (a), Elisabetta Tonet (a), Rita Pavasini (a), Martina De Raffele (a), Giulia Passarini (a)
(a) AZIENDA OSPEDALIERO-UNIVERSITARIA DI FERRARA

Clinical case. A 57 years-old female with multiple cardiovascular risk factors presented to the Emergency Department (ED) for persistent angina; in her clinical history she underwent percutaneous coronary intervention (PCI) with stenting of the medium-proximal tract of the Left Anterior Descendent (LAD) artery in 2010 because of an anterior myocardial infarction. Electrocardiogram did not show any acute ischemic alterations of the ST segment. Troponin curve suggested an acute myocardial infarction; laboratory tests did not reveal further issues. First emergency transthoracic echocardiography (TTE) described a hypertrophic left ventricle with a preserved left ventricular ejection fraction; segmental wall kinetic was preserved as well. The patient was diagnosed with non-ST segment elevation acute myocardial infarction and due to ongoing and unresponsive chest pain underwent an emergent coronary angiography: left coronary system showed good results of the previous percutaneous revascularization on LAD, whilst proximal tract of right coronary artery showed a critic coronary stenosis treated with PCI and stenting. The TTE performed in Coronary Intensive Care Unit confirmed the findings of the first exam, pointing out an apical left ventricular hypertrophy and revealed an outpouching of the left ventricular apex suspicious for an aneurysm (Fig. 1). Intraventricular muscle bands were not described. Contrast TTE was than performed to better define the features of the new finding (Fig. 2). During ventricular systole it tended to develop a small expansion, whilst during ventricular diastole no changes occurred, so that it was defined as an apical left ventricular aneurysm (ALVA). Given the suspect of an apical hypertrophic cardiomyopathy (ApHCM) cardiac Magnetic Resonance Imaging (c-MRI) was performed, describing a left ventricular hypertrophy of the medial and apical segments, with a maximum thickness of the apical septum of 16 mm, alongside with tendency to apical obliteration and mild-enhancement of the hypertrophic regions. The c-MRI confirmed the presence of an apical ventricular aneurysm, where transmural late gadolinium enhancement (LGE) was detected.

Discussion. Acquired ALVA is an abnormal finding complicating ApHCM in about 15% of cases. The most frequent differential diagnoses include ALVA originating after an acute myocardial infarction or after an acute myocarditis. In some cases, ALVA could be due to the presence of an intraventricular septal band or could be idiopathic. Multimodality imaging, such as c-MRI along with a detailed history collection can be helpful in identifying the cause of ALVA in those patients in which more than one etiology seems reasonable.

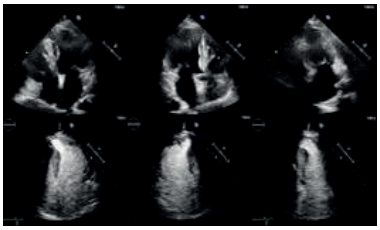

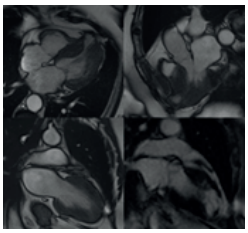

A673: EPICARDIAL FAT THICKNESS AND MYOCARDIAL WORK ANALYSIS N THE ASSESSMENT OF LEFT VENTRICULAR FUNCTION IN NORMAL WEIGHT AND OVERWEIGHT PATIENTS WITH PRESERVED EJECTION FRACTION

Giancarlo Trimarchi (a), Francesca Lofrumento (a), Giovanni Taverna (a), Maurizio Cusmà Piccione (a), Roberta Manganaro (a), Olimpia Trio (a), Cesare De Gregorio (a), Gianluca Di Bella (a), Scipione Carerj (a), Concetta Zito (a)
(a) DEPARTMENT OF CLINICAL AND EXPERIMENTAL MEDICINE,CARDIOLOGY UNIT, UNIVERSITY OF MESSINA, MESSINA, ITALY

Background. Due to its proximity to the myocardium and its high metabolic activity, epicardial adipose tissue plays a significant role in cardiovascular diseases. The measurement of epicardial fat thickness (EFT) has emerged as an important parameter in assessing cardiometabolic risk. EFT is typically measured from the parasternal long axis view as the space between the outer wall of the myocardium and the visceral layer of the pericardium on the free wall of the right ventricle at end-systole. EFT is strongly associated with metabolic syndrome, insulin resistance, coronary artery disease, and subclinical atherosclerosis. In this context, a novel echocardiographic tool called myocardial work (MW), that incorporates left ventricular (LV) afterload into the analysis of global longitudinal strain (GLS), provides valuable insights into LV function and better assesses its impairment in patients with increased EFT.

Aim. To evaluate the impact of epicardial fat thickness on LV function, assessed by myocardial work analysis, in normal weight and overweight patients.

Methods. 80 patients were retrospectively enrolled, distinguishing between 31 pts with EFT>5 mm and 49 pts with EFT <5 mm. All patients underwent brachial cuff blood pressure measurement, and a complete transthoracic echocardiogram was performed to measure EFT and calculate GLS and MW Parameters: Global Work Index (GWI); Global Constructive Work (GCW); Global Wasted Work (GWW) and Global Work Efficiency (GWE).

Results. No differences were found between patients with EFT>5 mm and those with EFT<5 mm regarding age (46,6±11,1 vs 45±12 yrs; p=0,06), sex (23 vs 25 male pts; p=0,06), systolic blood pressure (133,3±19 vs 126,1±14 mmHg; p=0,06) and heart rate (69±13 vs 71±12 bpm; p=0,3); while in the first group there were significantly higher values of BMI (29±4 vs 21±2 Kg/m^2; p=0,0001), diastolic blood pressure (82±13 vs 74±10 mmHg; p=0,004), mean arterial pressure (98±15 vs 91±11 mmHg; p=0,02), prevalence of smoking habit (55 vs 17%; p=0,03), dyslipidemia (51 vs 17%; p=0,002) and diabetes (16 vs 2%; p=0,03). LV mass index (78±15 vs 68±22 g/m^2; p=0,04) is significantly higher in patients with EFT>5 mm, while there was no significant difference between the two groups regarding systolic myocardial velocity (S') at Tissue Doppler Imaging (10±1,6 vs 10±1,7 cm/sec; p=0,7) and ejection fraction (FE) (60±5 vs 59±6%; p=0,2). GLS (-19±1,7 vs -20±1,8%; p=0,04) is reduced in its absolute value in patients with EFT>5 mm. Regarding myocardial work parameters, GWI (1916 ± 275 vs 1887 ± 261 mmHg%; p=0,6) and GCW (2303 ± 300 vs 2279 ± 328 mmHg%; p=0,7) didn't statistically differ between the two groups, while patients with EFT>5 mm had lower values of GWE (93 ± 2,6 vs 95 ± 1,6%; p=0,0002) and higher values of GWW (143 ± 79 vs 98 ± 44 mmHg%; p=0,001). Regarding correlations, EFT directly correlates to GLS (r=0,23; p=0,04) and GWW (r=0,34; p=0,002) and it inversely correlates to GWE (r=-0,38; p<0,0001).

Conclusions. The diagnosis of early LV dysfunction in patients with increased epicardial fat thickness can be improved by incorporating advanced echocardiographic techniques like myocardial work.

A674: RENAL CELL CARCINOMA WITH VENOUS TUMOUR TROMBUS IN RIGHT ATRIUM AND INFERIOR VENA CAVA: THE IMPORTANCE OF THREE DIMENSIONAL TRANSOESOPHAGEAL ECHOCARDIOGRAPHY

Paolo Basile (a), Cataldo Davide Memmola (b), Mara Piccolo (b), Giorgia Falco (a), Adriana Argentiero (a), Daniele Maselli (b), Vincenzo Pestrichella (b), Marco Matteo Ciccone (a), Andrea Igoren Guaricci (a), Sabino Iliceto (c)
(a) UO CARDIOLOGIA UNIVERSITARIA, DIPARTIMENTO INTERDISCIPLINARE DI MEDICINA (DIM), UNIVERSITÀ DEGLI STUDI DI BARI ALDO MORO, AOU POLICLINICO DI BARI, BARI; (b) MATER DEI HOSPITAL, BARI; (c) UNIVERSITÀ DEGLI STUDI DI PADOVA, PADOVA

Introduction. Renal cell carcinoma (RCC) represents a common type of urogenital cancer. It is characterized by a high biological tendency to vascular invasion with the development of venous tumour thrombus (VTT) involving the renal vein or the inferior vena cava (IVC). In rare cases it may extent to the right atrium (RA). VTT is associated with a relevant risk of venous congestion and distal embolism. With this clinical case we sought to emphasize the importance of a detailed evaluation of the right heart chambers and the VCI in patients with RCC.

Case presentation. A 77-years-old man, with arterial hypertension and smoking habit, went to the emergency room for fever and worsening dyspnoea. Laboratory tests showed an increase of white blood cells, C-reactive protein and D-dimer with normal troponins. The ECG was unremarkable. The transthoracic echocardiogram (TTE) displayed normal systolic function without segmental wall motion abnormalities. Moreover, the right chambers had normal dimensions and function with the presence of a solid mass of circular shape, regular margins and slightly heterogeneous into the RA near the origin of the IVC, which appeared

dilated and, also, occupied by the mass. The transoesophageal echocardiography (TEE) with the aid of three-dimensional images, confirmed the suspicion raised with TTE and allowed to define that the mass in the RA, with a heterogeneous echotexture and regular margins, was not freely floating but it was closely adherent to RA wall with evidence of a cleavage plane, as it appeared adhered to the wall of the IVC, suggesting the presence of a metastasized tumour. The multi-detector computed tomography (MDTC) chest scan with intravenous contrast revealed the presence of a massive pulmonary embolism (PE). Moreover, a deeper evaluation of the left kidney revealed a big solid mass with a diameter of about 10 cm suspected for RCC. The patient started a parenteral anticoagulant therapy and after two weeks underwent an open radical nephrectomy with a complete extraction of the mass in RA and IVC based on a multidisciplinary surgical approach involving urologists and cardiac surgeons. No complications occurred in the post-operative period.
Discussion. RCC represents the seventh cause of cancer worldwide, with a significant mortality rate of about 30-40%. The development of a VTT in the renal vein and the IVC occurs in up to 10% of cases and the further invasion of the RA in more than 1% of cases. It was reported in literature that a more extended VTT was correlated to worse outcomes. During the diagnostic workup TEE plays a key role in the staging of the disease, providing useful information on the characteristics of the VTT in the IVC and right heart chambers, such as dimensions, fragility adherence and mobility. MDCT is essential for a morphologic assessment of the primitive tumour and, in case of clinical suspicion, it may rule out PE, due to the risk of embolic events in case of VTT. A multimodality imaging approach is crucial for the definition of the surgical strategy. Open surgery with cardio-pulmonary bypass remains the most effective treatment in this advanced stage of disease, although recent published results suggest the feasibility of robotic-assisted surgery. In addition, a multidisciplinary surgical approach is advisable to obtain the best long-term results.
Conclusions. In patients with RCC a thorough multimodality imaging assessment of the IVC and the right chambers, with the key role of TEE, is crucial for the correct staging of the patient during the diagnostic workup and the surgical planning.

A675: HIATRIAL HERNIA

Francesca Besson (a), Alessandro Marongiu (a),
Piergiuseppe Agostoni (a)
(a) UNIVERSITÀ STATALE DI MILANO

Una paziente di 82 anni, nota per diabete mellito tipo II, dislipidemia, ipertensione arteriosa, fibrillazione atriale permanente, cardiopatia ischemica cronica sottoposta a plurime rivascolarizzazioni e BPCO, veniva ricoverata in regime di elezione per ripresa di angina pectoris. La paziente veniva sottoposta ad un ecocardiogramma trans-toracico di controllo, nel quale sorprendentemente veniva segnalata la presenza di una dubbia immagine isoecogena non mobile (di dimensioni 63 x 32 mm in A3C) a margini irregolari di verosimile pertinenza extracardiaca, che impattava la parete inferiore in toto dell'atrio sinistro e il setto interatriale inferiore, in assenza di un chiaro piano di clivaggio e senza evidenza di impatto emodinamico. In considerazione della possibile presenza di una massa extra- o intra-cardiaca in assenza di precedenti anamnestici, si decideva di approfondire il quadro mediante esecuzione di TC torace senza e con mezzo di contrasto. Dall'esame radiologico eseguito non emergeva alcuna eteroplasia, bensì la presenza di una voluminosa ernia iatale con risalita nel mediastino posteriore della pressoché totalità del fondo gastrico, a contenuto disomogeneo, con ristagno di ingesti e stretto rapporto di contiguità con la parete posteriore dell'atrio sinistro. Una volta fugato ogni dubbio, la paziente procedeva ad esecuzione di coronarografia e angioplastica del tronco comune ostiale. La successiva degenza si svolgeva in assenza di complicanze e la paziente veniva infine dimessa con l'indicazione ad eseguire videat chirurgico e/o visita gastroenterologica in tempi brevi. In letteratura sono stati descritti numerosi esempi di sospette masse atriali all'ecocardiogramma, che si sono rivelate poi essere l'impronta di un'ernia iatale: la particolarità di questi reperti è la loro riproducibilità in pazienti diversi, con immagini ecocardiografiche che risultano perfettamente sovrapponibili tra loro nei vari casi presi in esame. Per agevolare la diagnosi è stato proposto in passato un peculiare tentativo di ecocardiogramma con contrasto: mediante la somministrazione per via orale di una bevanda gassata, dopo pochi secondi si è assistito ad un cospicuo passaggio di bolle all'interno della sospetta "massa" atriale, ottenendo quindi una inusuale conferma diagnostica. Raramente sono stati documentati sintomi di compressione cardiaca in presenza di ernia iatale; sintomi come sincope o dispnea possono manifestarsi se l'ernia è particolarmente voluminosa, tipicamente dopo un pasto abbondante.

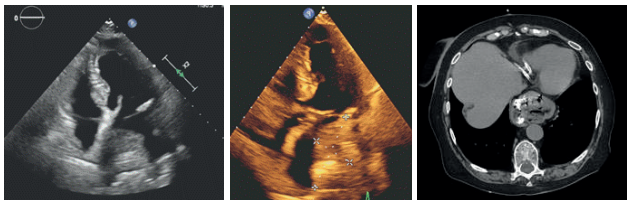

A676: ECHOCARDIOGRAPHIC PREDICTORS OF NT-PROBNP VALUE IN PATIENTS WITH PLASMA CELL DISORDERS

Nicola Cangiano (a), Cosimo Salvatici (a)
(a) DIPARTIMENTO SCIENZE MEDICHE CHIRURGICHE E NEUROSCIENZE SIENA

Background. Plasma cell disorders include an heterogeneous group of disease such as MGUS, multiple myeloma and his classification, systemic light-chain AL amyloidosis characterized by a B cell clone proliferation and by the serum and/or urine monoclonal component. In this case, cardiac involvement is described as the most important prognostic factor, and it's well known the peptide type B (NT-proBNP) is a predictor of overall survival (OS) in patients with multiple myeloma. In particular a cut off of 300 ng/L predicting OS. The aim of the study is to identify echocardiographic parameters that correlate with NT-proBNP values.
Methods. Ninety-nine patients were prospectively included in the study. 34 patients were diagnosed for smoldering myeloma, 56 patients showed a multiple myeloma (MM), 8 have a monoclonal gammopathy of undetermined significance (MGUS) and 1 patient showed a systemic AL amyloidosis. All patients underwent first and second-level imaging including STE and the biohumural profile was assessed too.
Results. We divided our population in two groups according to the NT-proBNP cut-off value. A value>300 ng/dL was collected in 29 patients and in 70 patients was less than 300 ng/L. Among the echocardiographic parameters Left atrial volume index (LAVI), Relative wall thickness (RWT), Atrial stifness, E/e' and relative apical sparing pattern (RELAPS) mean values were higher in the group of NT-proBNP<300. Apical sparing pattern (AUC: 0.66; 95% CI 0.53-0.79), right wall thickness (RWT) (AUC: 0.69; 95% CI0.57-0.81), E/e' (AUC: 0.78 95% CI 0.67-0.88), LAVI) (AUC: 0.75; 95% CI 0.63-0.86), showed the best correlation with NT-ProBNP values.
Conclusions. Echocardiographic assessment is very important to diagnose cardiovascular involvement in patients with Plasma cell disorders. In our population apical sparing pattern, LAVI, Atrial Stifness E/è wer the strongest predictors of NTproBNP values and might have a prognostic role in this patients.

A677: MULTIMODALITY ASSESSMENT OF LEFT VENTRICULAR WALL THICKNESS IN HYPERTROPHIC CARDIOMYOPATHY

Stefano Frittella (a), Stefano Figliozzi (a), Federico Guerini (b),
Carlo Guarino (a), Vincenzo Battaglia (a), Federica Catapano (a),
Elena Bozzo (a), Riccardo Mantovani (a), Carlo Pivato (a),
Renato Maria Bragato (a), Giulio Stefanini (b), Gianluigi Condorelli (b),
Marco Francone (b), Lorenzo Monti (a)
(a) IRCSS HUMANITAS RESEARCH HOSPITAL; (b) HUMANITAS UNIVERSITY

Background. The measurement of maximum left ventricular wall thickness (MLVWT) plays a crucial role in diagnosis, prognosis, and decision-making of patients with Hypertrophic Cardiomyopathy (HCM). No robust methodological recommendation exists for MLVWT assessment in daily practice; therefore, we sought to test the correlation, reproducibility, and accuracy of trans-thoracic-echocardiography (TTE), Cardiac-magnetic-resonance (CMR) and ECG-gated computed tomography (CT) in MLVWT measurements.
Methods. We retrieved the full datasets of 23 HCM patients undergoing TTE, CT and CMR within 12 months. The MLVWT was manually assessed by expert readers. Intra-observer, inter-observer, and inter-modality agreement of MLVWT were evaluated using Bland–Altman plots considering CMR as the gold-standard technique.
Results. Mean MLVWT was 17.8 mm at TTE, 19.7 mm at CMR, and 20.6 mm at CT. The reproducibility in MLVWT measurements was higher for CMR (intra-observer bias=-0.09 mm, 95% LOA: +1.5, -1.6 mm; inter-observer bias=+-0.2 mm with 95% LOA: +4.6, -5.0 mm) and CT (intra-observer bias=-0.09 mm, 95% LOA: +2.1, -2.3 mm; inter-observer bias=+0.4 mm with 95% LOA: +4.1, -3.3 mm) than TTE (intra-observer bias=-1.4 mm, 95% LOA: +4.0, -6.9 mm; inter-observer bias=-0.17 mm with 95% LOA: +5.8, -6.2 mm). There was a very good correlation in MLVWT measurements across different modalities (r=0.89 for CT vs. CMR; 0,84 for TTE vs. CT; 0.80 for TTE vs. CMR; all p<0.001), however CT showed a better accuracy (bias=+1.22 mm; LOA 95%: -3.00, +5.44 mm) than TTE (bias=+2.30 mm; LOA 95%: -7.60, +3.00 mm) compared to CMR. More than 20% of difference in MLVWT values was found in 2 (9%) patients between CT and CMR, 4 (17%) patients between TTE and CMR; in 10 (44%) patients between TTE and CT.
Conclusions. Considering CMR as the reference standard in MLVWT measurement of HCM patients, TTE resulted to be less accurate than CT, and showed lower reproducibility compared to CT and CMR.

A678: CARDIAC MAGNETIC RESONANCE FOR EARLY ATRIAL LESION VISUALIZATION POST ATRIAL FIBRILLATION RADIOFREQUENCY CATHETER ABLATION

Marco Guglielmo (a, b), Sophie Rier (b), Giulia De Zan (a, c),
Jeroen Van Heijden (b), Vincent Van Driel (b), Hemanth Ramanna (b),
Pim Van Der Harst (a), Ivo Van Der Bilt (a, b)
(a) DEPARTMENT OF CARDIOLOGY, DIVISION OF HEART AND LUNGS, UTRECHT UNIVERSITY, UTRECHT UNIVERSITY MEDICAL CENTER, UTRECHT, THE NETHERLANDS; (b) DEPARTMENT OF CARDIOLOGY, HAGA TEACHING HOSPITAL, THE HAGUE, THE NETHERLANDS; (c) DEPARTMENT OF TRASLATIONAL MEDICINE, UNIVERSITY OF EASTERN PIEDMONT, NOVARA, ITALY

Background. Incomplete atrial lesions resulting in pulmonary vein-left atrium reconnection after pulmonary vein antrum isolation (PVAI), are related to atrial fibrillation (AF) recurrence. Unfortunately, during the PVAI procedure, fluoroscopy and electroanatomic mapping cannot accurately determine the location and size of the ablation lesions in the atrial wall and this can result in incomplete PVAI lesions (PVAI-L) after radiofrequency catheter ablation (RFCA).
Aim. We seek to evaluate whether cardiac magnetic resonance (CMR), immediately after RFCA of AF, can identify PVAI-L by characterizing the left atrial tissue.
Methods. Ten patients (63.1±5.7 years old, 80% male) receiving a RFCA for paroxysmal AF underwent a CMR before (<1 week) and after (<1 hour) the PVAI. Two-dimensional dark-blood T2-weighted short tau inversion recovery (DB-STIR). Three-dimensional inversion-recovery prepared long inversion time (3D-TWILITE) and three-dimensional late gadolinium enhancement (3D-LGE) images were performed in order to visualize PVAI-L.
Results. The PVAI-L was visible in 10 patients (100%) using 3D-TWILITE and 3D-LGE. Conversely, On DB-STIR, the ablation core of the PAVI-L could not be identified because of a diffuse high signal of the atrial wall post-PVAI. Microvascular obstruction was identified in 7 (70%) patients using 3D-LGE.
Conclusions. CMR can visualize PVAI-L immediately after the RFCA of AF even without the use of contrast agents. Future studies are needed to understand if the use of CMR for PVAI-L detection after RFCA can improve the results of ablation procedures.

A679: A NOVEL THREE-DIMENSIONAL MAPPING SYSTEM FOR CARDIAC MAGNETIC RESONANCE-GUIDED RADIOFREQUENCY ABLATION OF CAVOTRICUSPID ISTHMUS: AN EARLY EXPERIENCE

Giulia De Zan (a, c), Marjolein De Jongh (b), Marco Guglielmo (a, b), Sophie Rier (b), Vincent Van Driel (b), Hemanth Ramanna (b), Pim Van Der Harst (a), Ivo Van Der Bilt (a, b)
(a) DEPARTMENT OF CARDIOLOGY, DIVISION OF HEART AND LUNGS, UTRECHT UNIVERSITY, UTRECHT UNIVERSITY MEDICAL CENTER, UTRECHT, THE NETHERLANDS; (b) DEPARTMENT OF CARDIOLOGY, HAGA TEACHING HOSPITAL, THE HAGUE, THE NETHERLANDS; (c) DEPARTMENT OF TRANSLATIONAL MEDICINE, UNIVERSITY OF EASTERN PIEDMONT, NOVARA, ITALY

Introduction. Radiofrequency catheter (RF) ablation has become a widely used for the treatment of cardiac arrhythmias. However, long-term results in terms of arrhythmia recurrence are still suboptimal. Cardiac magnetic resonance (CMR) has proved to represent a valuable radiation-free tool to overcome this limitation, offering tissue visualization, improved assessment of arrhythmia structural substrate, navigation of catheters and real time monitoring of ablation lesion formation. Real-time interventional cardiac magnetic resonance (iCMR) enables to acquire imaging and electrical data in the same co-ordinate system using a single modality. However, a satisfactory electro-anatomical mapping software is unfortunately still under lacking in clinical practice. \
Aims. To describe the safety and ability of a novel iCMR software (NorthStar-MR, Imricor Medical Systems, Minnesota, USA) to perform three dimensional (3D) mapping in patients undergoing cavotricuspid isthmus (CTI) ablation.
Methods and Results. After anesthesia induction, sterile draping, and vascular access to the femoral vein patients are transferred to the iCMR suite and ECG-triggered respiratory-navigated 3D steady state free precession (SSFP) sequences are acquired to get a full volume anatomy of the heart. From this acquisition NorthStar-MR obtains a 3D shell of the right atrium and cava veins, which is integrated into the navigation system. The 3D volume map serves during the procedure for active tracking of the catheters. A dedicated tracking sequence allows for detection of the catheter position and this data is superimposed on the 3D heart-volume. CMR-guided CTI ablation using NorthStar-MR was performed successfully and without complications in 3 patients.
Conclusions. NorthStar-MR appears to be a promising new mapping system for CTI ablation.

A680: RIGHT VENTRICULAR DYSFUNCTION ASSESSED THROUGH CARDIAC MAGNETIC RESONANCE AS PROGNOSTIC PREDICTOR IN SYSTEMIC SCLEROSIS

Federica Illuminato (a), Rodrigo Fernandez (d), Alfredo Guillen Del Castillo (c), Filipa Valente (b), Lucia Rodriguez-Eyras (b), Carmen Pilar Simeon-Aznar (c), Jose Fernando Rodriguez Palomares (b), Francesco Barillà (a)
(a) DEPARTMENT OF MEDICAL SCIENCES - UNIVERSITY OF ROME TOR VERGATA; (b) CARDIOVASCULAR IMAGING DEPARTMENT - UNIVERSITY HOSPITAL "VALL D'HEBRON"; (c) INTERNAL MEDICINE DEPARTMENT - UNIVERSITY HOSPITAL "VALL D'HEBRON"; (d) CARDIOVASCULAR DISEASE - PONTIFICAL CATHOLIC UNIVERSITY OF CHILE

Systemic sclerosis (SSc) is an autoimmune disease with several multiorgan involvement. Pulmonary arterial hypertension and cardiac involvement are common and impact prognosis. Cardiac magnetic resonance (CMR) allows an accurate evaluation of right ventricular function and previous research suggests that right ventricular involvement predicts prognosis in SSc patients. Our study aimed to assess RVD prevalence in SSc patients, identify RVD predictors, and analyze its impact on cardiovascular events. In this retrospective study, we included patients diagnosed with SSc and followed-up in a specialized unit. We collected clinical, ECG, hemodynamic and imaging data, including baseline CMR studies. RVD was defined as a right ventricular ejection fraction ≤52% in men and ≤51% in women, and subclassified as mildly (>41%), moderately (30-40%) and severely abnormal (<30%). (Petersen, S. E. et al. Eur Heart J - Cardiovasc Imaging. 2019). Pulmonary function tests were also performed. Patients were monitored for a composite endpoint consisting of death and/or hospitalization due to heart failure (HF) and/or ventricular arrhythmia. We assessed the predictors of this endpoint using Cox regression analysis. The study included 91 patients with SSc, primarily female (83%), with a mean age of 60 ± 12 years. Most had a limited cutaneous subtype (67%). RVD prevalence was 35% (72% mild dysfunction, 22% moderate, and 6% severe). Patients with RVD had lower right ventricular strain (-15.4% vs. -25%; p<0.001) and more frequent late gadolinium enhancement (LGE) in the left ventricle (40.6% vs. 13.8%; p=0.004). In the multivariate analysis, pulmonary artery trunk dilation (PAT) (HR 1.48; p=0.029) and reduced diffusing lung capacity for CO (HR 1.08; p=0.038) were predictors of RVD, while absence of ischemic heart disease (HR 0.06; p=0.035) and a higher LVEF (OR 0.56; p=0.023) were protective characteristics. During a mean follow-up of 50 months, patients with RVD had higher rates of heart failure hospitalization (41% vs. 16%; p=0.001) and all-cause mortality (53% vs. 22%; p<0.003). No ventricular arrhythmias occurred. The composite event of death and/or heart failure hospitalization was more frequent in these patients (HR 3.44; p<0.001). RVD is common among SSc patients, with LV dysfunction and PAT dilation (as a marker of pulmonary hypertension) identified as independent factors for RVD detectable through CMR. RVD is linked to increased adverse clinical events and decreased survival.

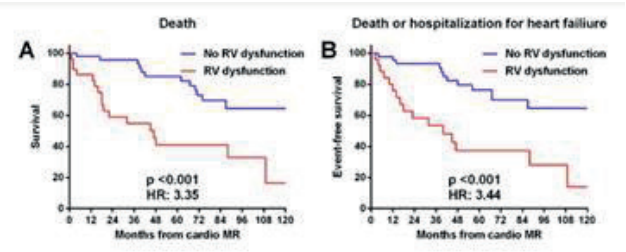

A681: RIGHT VENTRICULAR-PULMONARY ARTERY COUPLING ASSESSED BY TWO DIMENSIONAL STRAIN PREDICTS IN-HOSPITAL COMPLICATIONS IN TAKOTSUBO SYNDROME

Giulia La Vecchia (a), Giulia Iannaccone (a, b), Marco Giuseppe Del Buono (a, b), Massimiliano Camilli (a, b), Daniela Pedicino (b), Tommaso Sanna (a, b), Antonella Lombardo (a, b), Gaetano Antonio Lanza (a, b), Francesca Graziani (b), Antonio Maria Leone (a), Filippo Crea (a, b), Rocco Antonio Montone (b)
(a) DEPARTMENT OF CARDIOVASCULAR AND PULMONARY SCIENCES, CATHOLIC UNIVERSITY OF SACRED HEART, LARGO FRANCESCO VITO 1, ROME 00168, ITALY; (b) DEPARTMENT OF CARDIOVASCULAR MEDICINE, FONDAZIONE POLICLINICO UNIVERSITARIO A.GEMELLI IRCCS, ROME, ITALY

Background. Takotsubo syndrome (TTS) is a clinical condition characterized by a reversible left ventricular (LV) systolic and/or diastolic dysfunction leading to serious in-hospital complications, including heart failure, life-threatening arrhythmias and death. Right ventricular (RV) function may be impaired in the acute phase of the disease. The aim of our study is to investigate the prognostic impact of RV systolic dysfunction as assessed by RV strain and right ventricular-to-pulmonary artery (RV-PA) coupling in patients with TTS.
Methods. Consecutive TTS patients were prospectively enrolled. In all patients, standard and speckle transthoracic echocardiography was performed within 48 hours from the hospital admission. RV function was assessed by RV global longitudinal strain (RV-GLS) and RV free wall strain (RV-FWS) and RV-PA coupling was measured as the ratio of either tricuspid annular plane systolic excursion (TAPSE), RV-GLS or RV-FWS to pulmonary artery systolic pressure (PASP). In-hospital complications (acute heart failure, life-threatening arrhythmias and death from any cause) were collected.
Results. A total of 80 patients were analysed (71 ± 11.3 years, female 77.5%) and in-hospital complications occurred in 32 (40.0%). Patients who experienced in-hospital complications had lower LV ejection fraction (LVEF), lower TAPSE to PASP, RV-FWS/PASP and RV-GLS/PASP values. At multivariate analysis, only lower LVEF (OR 1.1 95% CI [1.03–1.17], p=0.002) and lower RV-GLS/PASP (OR 12.08 95% CI [1.42–102.97], p=0.023) were confirmed independent predictors of in-hospital complications. Receiving operators characteristics (ROC) analysis showed as optimal cut-off value of RV-GLS/PASP to predict in-hospital compli-

cations ≤0.48%/mmHg, with a sensitivity and specificity of 75% and 60% respectively; area under the curve (AUC) 0.696 (95% CI [0.57–0.82], p=0.002). This cut-off value allowed to identify 18% of patients who experienced in-hospital complications but presented with preserved LVEF (≥50%).

Conclusions. RV-PA coupling as assessed by RV-GLS/PASP may help in identifying TTS patients at higher risk of cardiovascular complications with an additional prognostic value than LVEF alone.

A682: PROGNOSTIC SIGNIFICANCE OF LATE GADOLINIUM ENHANCEMENT IN FABRY DISEASE: A SYSTEMATIC REVIEW AND META-ANALYSIS

Davide Mansour (a), Fabrizio Ricci (a, b, c), Giandomenico Bisaccia (a), Lorenzo Vilhelm Molinari (a), Michele Di Mauro (d), Giulia Renda (a), Mohammed Y. Khanji (e, f, g), Sabina Gallina (a)

(a) DEPARTMENT OF NEUROSCIENCE, IMAGING AND CLINICAL SCIENCES, "G. D'ANNUNZIO" UNIVERSITY OF CHIETI-PESCARA, CHIETI, ITALY; (b) DEPARTMENT OF CLINICAL SCIENCES, LUND UNIVERSITY, MALMÖ, SWEDEN; (c) FONDAZIONE VILLA SERENA PER LA RICERCA, CITTÀ SANT'ANGELO, ITALY; (d) CARDIO-THORACIC SURGERY UNIT, HEART AND VASCULAR CENTRE, MAASTRICHT UNIVERSITY MEDICAL CENTRE (MUMC), CARDIOVASCULAR RESEARCH INSTITUTE MAASTRICHT (CARIM), MAASTRICHT, THE NETHERLANDS; (e) NEWHAM UNIVERSITY HOSPITAL, BARTS HEALT NHS TRUST, GLEN ROAD, PLAISTOW, LONDON, UNITED KINGDOM; (f) BARTS HEART CENTRE, BARTS HEALT NHS TRUST, WEST SMITHFIELD, LONDON, UNITED KINGDOM; (g) NIHR BARTS BIOMEDICAL RESEARCH CENTRE, WILLIAM HARVEY RESEARCH INSTITUTE, QUEEN MARY UNIVERSITY, LONDON, UNITED KINGDOM

Fabry disease (FD) is a rare X-linked lysosomal storage disorder caused by pathogenic variants in the α-galactosidase A gene leading to inappropriate accumulation of globotriaosylceramide within several organs. Prevalence at birth is approximately 1:15,000, but FD is an underdiagnosed condition, and the true prevalence may be higher. Cardiac involvement is frequent and associated with heightened cardiovascular morbidity and reduced life expectancy. The intracellular accumulation of glycosphingolipids, chronic inflammation, and microvascular dysfunction are early features of the disease and key pathophysiological components driving the natural history of Fabry cardiomyopathy through sequential phases of storage, cellular hypertrophy, and myocardial fibrosis. Cardiovascular magnetic resonance (CMR) enables accurate differential of left ventricular hypertrophy and provides precise assessment of morphological, functional, and tissue characterization of cardiac involvement in FD. Late gadolinium enhancement (LGE) imaging is an established and highly reproducible technique to detect the presence of replacement myocardial fibrosis with close correlation to histopathology. In Fabry cardiomyopathy, LGE is usually identified at a later stage of disease, usually seen at the basal inferolateral segment of the left ventricle and with mid-wall distribution, yet different patterns and earlier occurrences have been described. Whilst T1 mapping is useful to detect early cardiac involvement in the accumulation phase of FD, progressive pseudonormalization of T1 relaxation times occurring in subsequent stages - which are dominated by inflammation, hypertrophic response, and fibrotic changes – confounds its prognostic utility. LGE imaging yields relevant diagnostic information in FD, yet outcome data are scarce, and the overall prognostic significance remains unclear. Accordingly, we performed a systematic review and meta-analysis of observational studies to clarify whether LGE portends excess cardiovascular morbidity and mortality in patients with FD. Our systematic review retrieved observational studies published up until March 2023 that reported outcome data of major adverse cardiovascular events (MACE: cardiovascular mortality, stroke, heart failure, and arrhythmic events) in patients with FD undergoing CMR imaging for suspected cardiac involvement. This systematic review and meta-analysis was planned, conducted, and reported according to the 2020 PRISMA statement for design, analysis, and reporting of meta-analyses of randomized and observational studies. Risk ratios (RR) were pooled in a generic inverse variance meta-analysis to compute summary effect sizes of MACE in patients with and without evidence of LGE. Each study estimate of the relative treatment was given a weight that was equal to the inverse of the variance of the effect estimate, i.e., 1 divided by the squared standard errors of the mean. Heterogeneity of the effect across studies was evaluated by using Cochran's Q and I2 statistics. A value of I2>50% was taken as indicating significant heterogeneity. We performed study-level meta-regression analysis to explore the effect of clinically relevant covariates (age, sex and percentage of patients treated with enzyme replacement therapy or oral chaperone) on the association between LGE and MACE. We identified 5 studies and included a pooled population of 506 patients with FD (42% men, 44±3 years). Median follow-up duration was 4.8 years (IQR 4.5-4.9; 2413 patient-years). The prevalence of LGE was 52.4%, and 129 MACEs were ascertained. The presence of LGE in our pooled cohort was associated with a four-fold increase in the risk of MACE (RR: 4.8; 95% confidence interval 3.20-7.22; I2=18%; P<0.001)(Figure 1A). Univariate meta-regression analysis showed no significant association between the RR of MACE and study-level confounders, including age (p=0.06), sex (p=0.987), and the proportion of patients receiving enzyme replacement therapy and/or oral chaperone (p=0.916; Figure 1B). Overall, these results provide evidence of a significant association between presence of LGE and increased 5-year risk of MACE in FD, irrespective of treatment received. Future studies should assess the efficacy of early treatment of Fabry cardiomyopathy to prevent occurrence of irreversible fibrosis. Additionally, research should examine the role of LGE and emerging CMR parameters, like T1 mapping dispersion, in guiding personalized treatment for female and male Fabry patients. These studies should also evaluate the impact of early therapy initiation on scar development and clinical outcomes.

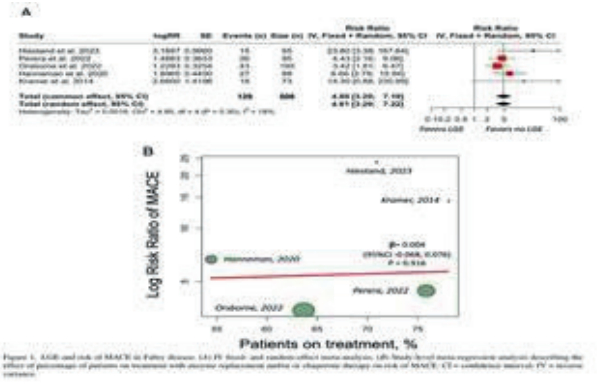

A683: STRAIN IMAGING UNVEILS RIGHT AND LEFT VENTRICULAR INVOLVEMENT IN ARRHYTHMOGENIC CARDIOMYOPATHY

Barbara Bauce (a), Giulia Mattesi (a), Petra Deola (b), Riccardo Bariani (a), Nicolò Martini (a), Sabino Iliceto (a), Raffaella Motta (c), Valeria Pergola (a)

(a) DEPARTMENT OF CARDIAC, THORACIC, VASCULAR SCIENCES AND PUBLIC HEALTH, UNIVERSITY OF PADUA; (b) CARDIOLOGY DIVISION, SAN BASSIANO HOSPITAL, BASSANO DEL GRAPPA; (c) UNIT OF RADIOLOGY, DEPARTMENT OF MEDICINE, UNIVERSITY OF PADUA

Background. Arrhythmogenic cardiomyopathy (AC) is a genetically inherited cardiac condition characterized by fibro-fatty infiltration, electrical instability, and systolic dysfunction. Myocardial involvement in AC often begins in the subepicardial layers, making it challenging to detect using conventional echocardiography. Advanced parameters, such as speckle tracking-derived strain and mechanical dispersion (MD), show promise for a more precise evaluation of these patients.

Methods. Between April 2021 and August 2022, we conducted echocardiographic assessments on a cohort of 56 patients diagnosed with right-dominant, biventricular, or left-dominant AC. We evaluated right ventricular (RV) function using longitudinal strain. Left ventricular (LV) function was assessed through global longitudinal strain (GLS). In a subgroup of 21 patients with LV involvement who had recently undergone cardiac magnetic resonance (CMR) or coronary CT angiography, we conducted an additional analysis. This involved calculating mechanical dispersion (MD) and comparing the distribution of reduced LV segmental longitudinal strain with late gadolinium or iodine enhancement.

Results. Regarding RV function, RV free wall longitudinal strain was significantly reduced in right-dominant (median: -16.9%; IQR: -19.2 to -15.5%) and biventricular forms (median: -16.7%; IQR: -18 to -12.9%), compared to normal values and left-dominant forms (median: -23.7%; IQR: -24.6 to -22.6%; p-value <0.001). Concerning LV function, there was a significant reduction in LV GLS in left-dominant (median: -19.1%; IQR: -20.5 to -18.8%) and biventricular forms (median: -18.1%; IQR: -19.8 to -15.9%) compared to right-dominant forms (median: -20.9%; IQR: -23 to -19.3%; p-value 0.043 and 0.002, respectively). Although the median LV GLS fell within the normal range in all three AC groups, the additional analysis of 21 patients with biventricular and left-dominant forms revealed an increased MD value (median: 49; IQR: 45-59 msec). Moreover, the reduction in segmental strain correlated with the distribution of late enhancement on CMR or coronary CT angiography in 72% of cases, with particular involvement noted in the inferolateral mid and basal wall regions.

Conclusions. Advanced echocardiographic parameters such as strain and MD hold the potential to enhance the accuracy of echocardiographic assessments for detecting right and left ventricular involvement in AC.

A684: A NOVEL FORMULA FOR ESTIMATING LEFT VENTRICULAR OUTFLOW TRACT DIAMETER

Carlo Gaspardone (b, d), Michele Morosato (a, d), Davide Antonio Morciano (a, d), Riccardo Mager (a, d), Alessandro Fasolino (e), Luca Baldetti (a), Davide Romagnolo (a, d), Giorgio Fiore (c, d), Giacomo Ingallina (c), Francesco Ancona (c), Stefano Stella (c), Cosmo Godino (b), Eustachio Agricola (c, d)

(a) CARDIOTHORACIC DEPARTMENT, IRCCS SAN RAFFAELE SCIENTIFIC INSTITUTE, MILAN, ITALY; (b) CARDIOLOGY UNIT, IRCCS SAN RAFFAELE SCIENTIFIC INSTITUTE, MILAN, ITALY; (c) CARDIAC IMAGING UNIT, IRCCS SAN RAFFAELE SCIENTIFIC INSTITUTE, MILAN, ITALY; (d) VITA-SALUTE SAN RAFFAELE UNIVERSITY, MILAN, ITALY; (e) DEPARTMENT OF MOLECULAR MEDICINE, UNIVERSITY OF PAVIA, PAVIA, ITALY

Background. Stroke volume (SV) estimation by transthoracic echocardiography (TTE) is essential for non-invasive hemodynamic assessment and valve disease severity grading. The most used TTE method for SV estimation requires the measurement of left ventricular outflow tract diameter (LVOTd) and flow velocity data. However, the accuracy of LVOTd measurement is affected by several factors (e.g., poor acoustic window) and is prone to errors. This study aimed to derive and validate, in the largest unselected patient series to date, a novel formula to estimate the LVOTd from gender and body size parameters. To ensure both high accuracy and ease of clinical implementation, we developed a free smartphone-based app for rapid bedside calculation.
Methods and Results. We analyzed data from 688 consecutive patients [393 (57%) men; mean age 73±12 years] referred to San Raffaele hospital for TTE from September to December 2022. We divided the overall cohort into a derivation cohort (the first 3/4 of the population, 516 patients) and a validation cohort (last 1/4 of the population, 172 patients). In the former, we derived the estimated $LVOTd_{NEW}$ formula from gender, height and weight with a linear regression model providing the best fit (r=0.72, p<.001; mean difference 0.03±1.35 mm). In the validation cohort, the estimated $LVOTd_{NEW}$ did not differ significantly from and correlated strongly with the measured LVOTd (21.1±1.4 mm vs. 21.1±1.9 mm, p=.77; mean difference 0.08±1.40 mm; r=0.71, p<.001).
Conclusions. In this study, we derived and validated a new formula to estimate the LVOTd from gender, height, and weight with high accuracy. The estimated $LVOT_{NEW}$ may be used as a benchmark and alternative option when this measurement is difficult with TTE. Our formula can be computed with a specifically created free smartphone-based app which also includes hemodynamic and aortic stenosis assessment (https://echocalc.me/).

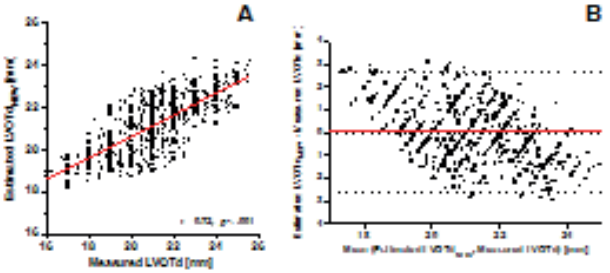

A685: UNEXPECTED RIGHT ATRIAL MASS IN A YOUNG WOMAN: AN UNPLEASANT SURPRISE

Sara Mastroberardino (a), Francesco Piccirillo (a), Matteo Fiorentino (a), Francesco Grigioni (a), Gian Paolo Ussia (a)
(a) UNIVERSITÀ CAMPUS BIO-MEDICO DI ROMA

Introduction. Atrial masses represent a diagnostic challenge as the differential diagnosis includes a broad spectrum of formations. Thrombus is the most common form of atrial mass, whereas cardiac tumors, benign or malignant, are rare. We reported a case of a young woman with high-grade endometrial stromal sarcoma, complicated by cardiac metastatic dissemination.
Case report. A previously healthy woman of 36-years old, without medical history, underwent abdominal ultrasound due to frequent menorrhea. As suspicious uterine formation was observed, an abdomen magnetic resonance (MRI) was performed, showing a large formation located in correspondence of uterine corpus and fundus, compatible with fibroma. Indeed, she underwent hysterectomy plus bilateral salpingectomy, and the subsequent histological examination revealed a high-grade endometrial stromal sarcoma (ESS). Consequently, the patient was hospitalized to undergo a total body computed tomography (CT) for tumor staging and to start chemotherapy (potential cardio-toxic). A trans-thoracic echocardiogram (TTE) showed normal function of left ventricle, without valvulopathies. However, in correspondence of right atrium (RA) roof, a large, rounded mass, hypomobile and iso/hyper-echogenic, without extension into Superior Vena Cava, was detected (Fig 1). The total body CT confirmed the presence of a hypodense mass in the RA (Fig 2), and secondary lesions within left large pectoral muscle and right inferior lung lobe were founded. Thus, a Cardiac MRI was performed, showing a solid formation, with lobulated margins and oval morphology, at the level of the posterior wall of the RA, of about 2.5 x 1.8 cm and with longitudinal extension of about 3 cm, hypomobile and with a wide implant base. The lesion appeared heterogeneously hypo-isointense in T1-weighted images and hyperintense in T2-weighted images (Fig 2); in Delayed-Enhancement acquisitions, the formation resulted hyper-intense, especially in long-inversion recovery sequences. Indeed, considering clinical condition, right atrial location and morphological features, the diagnosis of secondary lesion of the ESS was entertained. First-line chemotherapy regimen was started. At 3-months follow-up the patient remained asymptomatic; at TTE, the cardiac mass resulted unchanged. Unfortunately, after 13 months, the patient died.
Conclusions. A multimodality imaging approach is crucial for a non-invasive evaluation of atrial masses and subsequent appropriate therapeutic strategy.

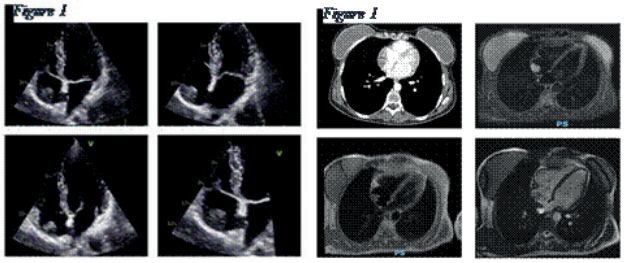

A686: HEART INVOLVEMENT IN HYPOTHYROIDISM: A MYOCARDIAL WORK STUDY

Martina Pucci (a), Vittoria Gammaldi (a), Velia Iadevaia (a), Adelaide Iervolino (a), Luca Maria Capece (a), Marina Iacono (a), Mariateresa Pontoriero (a), Daniele Paoletta (a), Roberta Esposito (a)
(a) DEPARTMENT OF CLINICAL MEDICINE AND SURGERY, FEDERICO II UNIVERSITY HOSPITAL, NAPLES

Background. From 2022 AHA/ACC/HFSA Guideline for the Management of Heart Failure it's known that hypothyroidism is a potential cause of heart failure (HF) and a factor precipitating HF hospitalization. On the basis of understanding of the cellular mechanisms of thyroid hormone action on the heart and cardiovascular system, it is possible to explain the changes in cardiac output, cardiac contractility, blood pressure, vascular resistance and rhythm disturbances that result from thyroid dysfunction.
Objectives. The aim of the study is to clarify the hemodynamic changes caused by thyroid dysfunction in patients with different degrees of hypothyroidism using advanced echocardiographic techniques. Pressure-volume loop analysis is essential in order to understand relationships among preload, afterload and myocardial contractility. However, despite their utility, invasive pressure-volume loops are often impractical in routine clinical practice. Myocardial work is an emerging tool in echocardiography that incorporates left ventricular afterload into global longitudinal strain analysis.
Methods. The study population includes 48 patients with several degrees of hypothyroidism (mild, moderate, severe and in compensation during drug therapy with levotiroxine) in absence of risk factors for cardiovascular diseases and 102 healthy controls with euthyroidism, comparable in age and sex. Echo-Doppler assessment was realized according to the standards of the European Association of Cardiovascular Imaging (EACVI) standardization of the echo report. Myocardial work assessment was performed with EchoPAC: the initial step was obtaining transthoracic views for GLS analysis; then valvular event times have been assessed through pulsed wave (PW) doppler analysis of transmitral and transaortic flow and adjusted manually through visual assessment from the apical long-axis view. Four values are calculated: global work index (GWI), average myocardial work based on the pressure-strain loop; global constructive work (GCW), positive work performed by a segment in systole and negative work (segment lengthening) during isovolumic relaxation; global wasted work (GWW), negative work (segment lengthening) during systole and positive work (segment shortening) during isovolumic relaxation; global work efficiency (GWE):GCW/(GCW+GWW). Continuous normally distributed variables were compared by using the Student t-test. A probability value <0.05 was considered statistically significant. Analyzes were performed with SPSS version 25 (IBM Corporation, Somers, New York).
Results. Comparing hypothyroidism patients with euthyroidism subjects, a significant increase in left ventricular mass indexed (LVMi) (35.10 ± 9.22 vs 30.41 ± 7.32, p-value=0.002), a significant reduction in ejection fraction (EF) (60.14 ± 6.98 vs 66.51 ± 6.32, p-value <0.001), a significant worsening of diastolic parameters such as e' septal, e' lateral and E/e' ratio (7.66 ± 2.44 vs 6.60 ± 1.43, p-value <0,001) were found by standard echocardiographic analysis; regarding the evaluation of myocardial work, a significant increase in GWW (155.46 ± 112.03 vs 64.38 ± 30.05, p-value <0,001) was found with a significant reduction in GWI (2010.42 ± 381.46 vs 2269.35 ± 318.09, p-value <0,001), GCW (2246.64 ± 414.09 vs 2554.62 ± 314.79, p-value <0,001) and GWE (92.71 ± 4.42 vs 96.86 ± 1.27, p-value <0,001). A comparison analysis was also carried out in the group of hypothyroid patients subdividing them into two groups on the basis of TSH values: a group with hypothyroidism in good compensation during therapy and a group with TSH values>10 mU/ml. This analysis showed a statistically significant reduction in GWE (89.80 ± 5.28 vs 94.33 ± 2.91, p-value: 0.007) with a statistically significant increase in GWW (236.20 ± 128.46 vs 110.61 ± 72.34, p-value: 0.003) in patients with average TSH value equal to 34.55 ± 22.86 mU/ml.
Conclusions. This study carried out on subjects in the absence of cardiovascular risk factors highlights how thyroid function plays a central role

in regulating cardiac performance. The importance of the recognition of the effects of thyroid disease on the heart derives from the observation that restoration of normal thyroid function most often reverses the abnormal cardiovascular hemodynamics.

A687: TROMBOSI VS ENDOCARDITE, UN'ODISSEA DIAGNOSTICA

Giulia Sgherzi (a), Dalila Nappa (a), Rachele Manzo (a), Maddalena Immobile Molaro (a), Ciro Santoro (a), Paola Gargiulo (a), Stefania Paolillo (a), Federica Ilardi (a), Giovanni Esposito (a)
(a) UNIVERSITÀ DEGLI STUDI DI NAPOLI "FEDERICO II"

Introduzione. Le masse intracardiache costituiscono un riscontro spesso occasionale durante controlli clinici di routine. Sebbene l'ecocardiografia transtoracica e transesofagea abbiano un ruolo centrale nell'indirizzare il processo diagnostico e terapeutico, l'integrazione con tecniche di imaging multimodale e con dati anamnestici e clinico-laboratoristici è fondamentale nella diagnosi differenziale delle masse di dubbia eziologia.

Descrizione caso clinico. Il paziente AL, uomo di 86 anni è affetto da ipertensione arteriosa, dislipidemia, fibrillazione atriale permanente in terapia con NAO, stenosi mitralica di origine reumatica ed è portatore di pacemaker bicamerale. In anamnesi riportava recente ricovero per ictus ischemico complicato da infarcimento emorragico in corso di terapia con NAO e successivo accesso al PS per insufficienza respiratoria acuta causata da polmonite nosocomiale. Ad un controllo cardiologico ambulatoriale presso la nostra struttura eseguiva ecocolorDoppler cardiaco transtoracico (ETT) che mostrava massa iperecogena adesa al lembo posteriore della valvola mitrale (2.4x1.2 cm) come da verosimile vegetazione, determinante steno-insufficienza di grado severo. Riferiva, inoltre, di aver effettuato poche settimane prima una estrazione dentaria in assenza di un'adeguata profilassi antibiotica. All'ecocolorDoppler cardiaco trans-esofageo (ETE) eseguito durante l'ospedalizzazione, si confermava la presenza di immagine iperecogena sessile adesa ai lembi mitralici e si evidenziava, inoltre, la concomitante presenza di formazione trombotica in auricola sinistra. Il paziente,apiretico e con indici di flogosi ed emoculture negative, veniva pertanto, sottoposto a PET-TC che escludeva la presenza di aree ad aumentata attività metabolica intracardiaca compatibili con vegetazioni di natura endocarditica. Di conseguenza, la diagnosi di endocardite veniva esclusa e si sospendeva la terapia antibiotica. Dopo circa 20 giorni veniva eseguito ETT di controllo, con riscontro di massa sul versante ventricolare del lembo anteriore mitralico, modificata sia per dimensione (2.0 x 1.0 cm) che per localizzazione (adesa all'apparato sottovalvolare), rispetto al controllo precedente, compatibile con formazione trombotica. Il giorno stesso si verificava embolizzazione in arteria iliaca comune sinistra,trattata mediante embolizzazione tramite catetere di Fogarty. Il paziente veniva, infine, dimesso in terapia anticoagulante con Warfarin ed è in attuale discreto compenso clinico al follow-up.

Discussione. Il caso si presta a considerazioni di diagnostica differenziale per cui solo l'integrazione di anamnesi approfondita, clinica, esami di laboratorio ed imaging di secondo livello possono condurre ad una diagnosi definitiva. Il reperto anamnestico di malattia reumatica in assenza di adeguata profilassi antibiotica e la recente polmonite suggerivano una natura endocarditica della lesione. Al contrario, il riscontro laboratoristico di emoculture ed indici di flogosi negativi e clinico di apiressia, in aggiunta all'evidenza di concomitante trombosi auricolare, facevano decadere il sospetto di endocardite.

A688: UN CASO DI TAKOTSUBO FOCALE COMPLICATA DA ANEURISMA

Donatella Tansella (a), Enrico Forlin (a), Angela Susana (a)
(a) UNIVERSITÀ DEGLI STUDI DI PADOVA - DIPARTIMENTO DI SCIENZE CARDIO TORACO VASCOLARI

La sindrome di Takostubo è una forma di insufficienza cardiaca acuta e reversibile, non ischemica caratterizzata da una disfunzione sistolica regionale del ventricolo sinistro che va successivamente incontro a recupero funzionale. Esistono differenti forme di sindrome di Takotsubo, classificate sulla base delle alterazioni della cinetica; uno tra i più rari pattern è quello focale (1,5%) in cui vi sono ipo/acinesie regionali. La RMN è fondamentale per la diagnosi differenziale con forme di miocardite o infarto miocardico acuto. Donna di 86 anni senza precedenti cardiologici di rilievo e fattori di rischio cardiovascolari, accedeva in PS per dolore toracico retrosternale, non irradiato; in anamnesi non eventi di stress psicofisico. L'ecocardiogramma all'ingresso mostrava funzione di pompa biventricolare conservata in presenza di un aspetto aneurismatico della parete inferiore media. L'ECG all'ingresso non mostrava alterazioni della ripolarizzazione. Si riscontrano elevati valori all'ingresso di TnI con picco pari a 2776 ng/L. La paziente veniva sottoposta a coronarografia che mostrava assenza di lesioni angiograficamente critiche, decorso intramiocardico di DA con milking sistolico. Veniva quindi eseguita RMN cardiaca che metteva in luce un ventricolo sinistro di normali dimensioni e funzione sistolica conservata (FE 58%) con una focale discinesia della parete inferolaterale; aumento dei valori globali di T1 e T2, con valori più alti proprio a livello della parete inferiore media. Dopo somministrazione di MdC in fase precoce, non deficit di perfusione miocardica. Nelle sequenze postcontrastografiche sfumato LGE nelle regioni di maggior edema. Si concludeva quindi per un quadro suggestivo di cardiomiopatia di Takotsubo focale. Durante la degenza si assisteva inoltre a modificazione del tracciato elettrocardiografico con insorgenza di onde T negative in sede inferiore (II-III-aVF), con tendenza ai bassi voltaggi e comparsa di onde Q nelle medesime sedi. La comparsa di onde Q nella sindrome di Takostubo è stata riscontrata in circa un 32% di pazienti ed è correlata all'edema miocardico, con tendenza alla regressione di tali anomalie del tracciato nel corso del tempo, contestualmente alla ripresa della normale cinesi ventricolare e al riassorbimento dell'edema.

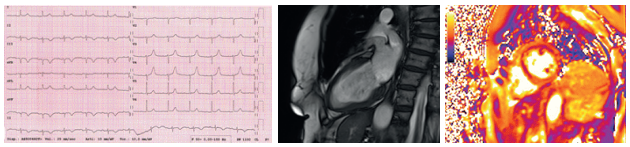

A689: LATERAL HYPERTROPHIC CARDIOMYOPATHY: A CASE REPORT

Emanuela Belmonte (a), Luca Arcari (a), Giovanni Camastra (a), Federica Ciolina (b), Massimiliano Danti (b), Stefano Sbarbati (b), Salvatore Donato Musarò (a), Luca Cacciotti (a)
(a) UNITÀ DI CARDIOLOGIA, OSPEDALE MADRE GIUSEPPINA VANNINI, ROMA; (b) UNITÀ DI RADIOLOGIA, OSPEDALE MADRE GIUSEPPINA VANNINI, ROMA

Hypertrophic cardiomyopathy (HCM) is the most common genetic cardiovascular disorder, often presenting with asymmetrical septal hypertrophy, though more heterogeneous phenotypes have been described. Here we report the case of a young patient, affected by arterial hypertension, presenting to the emergency department with chest pain, electrocardiographic changes and troponin rise. Further diagnostic work-up ruled out ischemic heart disease and lead to the diagnosis of a rare HCM phenotype affecting the lateral wall of the left ventricle. Magnetic resonance imaging proved to be a reliable diagnostic test in this case thanks to its tissue characterization ability, allowing the identification of diffuse fibrosis through native T1 napping, edema through T2 mapping and replacement fibrosis with late gadolinium enhancement. Coexistence of arterial hypertension with atypical HCM forms emerged from several multicentric studies, though further research is needed to fully clarify the complex interactions between arterial hypertension and phenotypic expression of HCM.

A690: FIRST APPLICATION OF THE HYPERDOPPLER ECHOCARDIOGRAPHIC TECNIQUE TO THE STUDY OF THE VORTICAL FLOW IN ASCENDING AORTA WITH BICUSPID VALVE

Andrea Fiorencis (a), Elena Tadres (a)
(a) STUDIO MEDICO DR FIORENCIS

Background. The study of the ascending aorta is commonly performed during the echocardiographic examination, particularly in patients with bicuspid aortic valves (BAV) in which aortic dilatation may be present. Magnetic resonance studies have demonstrated how the particular anatomy of the BAV generates a markedly eccentric jet in the ascending aorta. This jet would cause an increase in wall stress with the formation of vortex flows in the ascending aorta, favoring the aortic dilatation. For the first time we have applied the new Hyper-Doppler technique to understand the vortical flows of the ascending aorta in patients with BAV and identified a standard Color-Doppler sign of vorticity related to aortic aneurysm.

Methods. 10 normal subjects, 10 patients with BAV were studied with standard Color-Doppler technique. The Hyper-Doppler technique was applied in all normal subjects and in patients presenting flow abnormality at Color-Doppler. BAV without significant stenosis or regurgitation were selected. The diameter of the ascending aorta and the valve morphology were evaluated by standard 2D echocardiographic images. The blood flow in the aortic arch was analyzed from the suprasternal view with Color-Doppler and Hyper-Doppler technique with the aim of characterizing the distribution pattern of velocity vectors and kinetic energy. Flow data were correlated with ascending aorta diameter.

Results. Normal subjects were 50% male (25 ± 2 y.o), patients with bicuspid aortic valve were 4 males (46 ± 9 y.o.). In all cases it was possible to study the aortic arch using the standard Color-Doppler technique. In normals the Hyper-Doppler technique reveals a uniform vector distribution of velocities and kinetic energy during ventricular systole. In 3 patients affected by bicuspid aortic valve the Color-Doppler revealed the simultaneous presence of a flow towards and away from the probe during proto- and mid-systole in the ascending aorta. These patients had an increased ascending aorta diameter 2.5 ± 0.1 cm/m^2. Hyper-Doppler confirmed a vortical flow with asymmetric distribution of kinetic energy in the anterior portion of the aorta. In the other cases of bicuspid aorta no aortic vortical flows were detected and the aortic diameter was within the limits (ascending aorta 1.7 ± 0.1 cm/m^2). The flow dynamic was independent by valve morphology.

Conclusions. In this series of cases we have studied for the first time the flow dynamics in the ascending aorta with the Hyper-Doppler technique. The technique has proved to be easily applicable and capable of identifying flow abnormalities in the ascending aorta of BAV. It also clarified the flow dynamic of Color-Doppler images proposing a new easily detectable marker of turbulence and wall stress.

A691: I PATTERN ECOCARDIOGRAFICI DI INVECCHIAMENTO DEL CUORE PREDICONO GLI EVENTI CARDIOVASCOLARI E NON CARDIOVASCOLARI E RIFLETTONO L'ETÀ BIOLOGICA: LO STUDIO SARDINIA

Antonello Ganau (a), Matteo Floris (a), Pier Sergio Saba (a), Giuseppe Damiano Sanna (a), Guido Parodi (a), Francesco Cucca (a)
(a) UNIVERSITÀ DI SASSARI

Obiettivi. L'età è un fattore di rischio maggiore per le malattie cardiovascolari (CV) e per altre malattie degenerative non CV. Poiché le persone invecchiano a velocità diverse, è stato introdotto il concetto di età biologica come misura personalizzata del deterioramento funzionale dell'organismo, distinta dall'età cronologica o anagrafica. Sono state analizzate le correlazioni tra l'età cronologica e alcuni tratti quantitativi ecocardiografici di struttura e funzione del cuore, allo scopo di rilevare eventuali differenze nelle velocità di invecchiamento del cuore e valutare se tali differenze assumano valore prognostico e riflettano l'età biologica.
Metodi. In 2614 soggetti sani sono state misurate le correlazioni lineari dell'età con la massa, la geometria e la funzione diastolica ventricolare sinistra, il volume atriale sinistro e la dimensione della radice aortica. Gli intervalli di tolleranza al 95% di ciascuna correlazione hanno consentito di identificate tre diverse traiettorie di invecchiamento, classificate come pattern di invecchiamento cardiaco "lento", "normale" e "accelerato". L'endpoint primario comprendeva eventi CV maggiori fatali e non fatali, mentre l'endpoint secondario composito comprendeva gli eventi CV, eventi non CV e morte da tutte le cause. Abbiamo calcolato l'età fenotipica del cuore (HeartPhAge) come predittore dell'età biologica, e la differenza tra HeartPhAge e età cronologica per quantificare il gap di età biologica.
Risultati. Il pattern di invecchiamento cardiaco lento è stato riscontrato nel 8,7% dei partecipanti sani, il pattern normale nel 76,8% e il pattern accelerato nel 14,3%. Le curve di Kaplan-Meier dei pattern di invecchiamento divergevano significativamente (P=0,0001) per entrambi gli endpoint primario e secondario, con il tasso di eventi più basso nel modello lento, intermedio nel modello normale e più alto nel modello accelerato. Nel modello di Cox dei rischi proporzionali, i pattern di invecchiamento cardiaco hanno predetto sia l'endpoint primario (P=0,02) che quello secondario (da P=0,03 a P<0,0001), indipendentemente dall'età cronologica e dai fattori di rischio. Rispetto all'età cronologica, l'età fenotipica del cuore (HeartPhAge) è risultata essere 9 anni più giovane nel pattern di invecchiamento lento e 4 anni più vecchia nel pattern accelerato (entrambi P<0,0001), mentre è risultata sovrapponibile nel pattern normale.
Conclusioni. L'ecocardiogramma-Doppler standard consente di rilevare il pattern di invecchiamento del cuore (lento, normale o accelerato), che ha valore predittivo di eventi CV e non CV e riflette l'età biologica. I pattern ecocardiografici di invecchiamento forniscono un nuovo strumento per calibrare e personalizzare i tempi e l'intensità della prevenzione, indipendentemente da età anagrafica e fattori di rischio, soprattutto nei soggetti clinicamente sani ma con invecchiamento accelerato.

A692: LEFT VENTRICULAR ASSIST DEVICE IMPLANTATION TO THE SUBCLAVIAN ARTERY - ECHOCARDIOGRAPHIC FLOW ANALYSIS

Razvan Berghi (a), Daisy Pavoni (b), Massimo Maiani (b), Igor Vendramin (b), Gianfranco Sinagra (a)
(a) CARDIOTHORACIC DEPARTMENT - ASUGI; (b) CARDIOTHORACIC DEPARTMENT - ASUFC

Left ventricular assist device (LVAD) therapy is an effective strategy to treat advanced heart failure as bridge or destination therapy. The third-generation centrifugal pumps have allowed to pioneer alternative and less invasive implantation techniques. Starting from the classic sternotomy access and ascending aorta-outflow graft, now implantations via mini-thoracotomy and with alternative outflow graft sites (subclavian artery, innominate artery, descending/abdominal aorta) are possible. These new techniques are suitable for patients with hostile anatomy and poor clinical status. The role of echocardiography is fundamental for patient evaluation. A correct assessment of device functioning requires flow analysis of the cannulas. Current guidelines advise that normal flow should be laminar, unidirectional, with inflow velocities <1.5m/s and outflow velocities <2m/s. Our patient is a 37yo woman (BMI 19 km/m2) who was admitted to our Cardiology Department with large anterior STEMI caused by LAD dissection. The patient underwent a long hospitalization characterized by hemodynamic instability which required inotropic and AV-ECMO support. As soon as the patient was weaned from ECMO, in consideration of the severe LV dysfunction (EF 20%), an LVAD (HMIII) was successfully implanted as bridge-to-transplantation via left-thoracotomy with a subclavian artery outflow graft. During the follow-up period, posing the echo-probe in the supraclavicular fossa allowed us to examine the outflow cannula characterized by flow peak velocities ~2,5 m/s and by the typical "artificial pulse" pattern of HMIII. It is reasonable that normal subclavian-outflow graft velocities could be slightly higher than the normal ascending aorta-outflow graft velocities (<2 m/s) in keeping with the smaller diameter of the vessel. To our knowledge, no study has ever been done on flow analysis of alternative outflow-graft LVAD patients. No official recommendation exists regarding this matter. The alternative LVAD implantation techniques will be increasingly used worldwide. For this reason, it could be useful organizing large-scale studies to define flow patterns cut-offs of normality in these patients. Defining the correct echocardiographic techniques and the normality cut-offs would be useful in our clinical practice in order to spot device malfunctions and correct them in time.

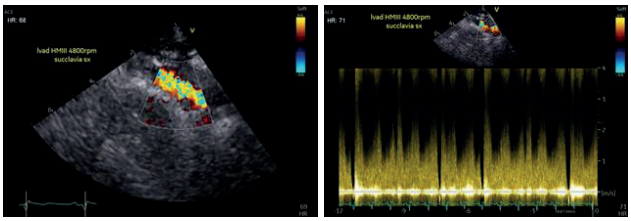

A693: DISFUNZIONE VENTRICOLARE DESTRA E CORREZIONE CHIRURGICA DELLA VALVOLA TRICUSPIDE: SPAZIO PER L'ECOCARDIOGRAFIA DA STRESS?

Marta Pasquero (a), Pier Paolo Bocchino (b), Carol Gravinese (b), Paolo Boretto (b), Matteo Bellettini (a), Filippo Angelini (b), Gaetano Maria De Ferrari (a)
(a) DEPARTMENT OF MEDICAL SCIENCES,UNIVERSITY OF TURIN,TURIN,ITALY; (b) DIVISION OF CARDIOLOGY, CARDIOVASCULAR AND THORACIC DEPARTMENT, "CITTÀ DELLA SALUTE E DELLA SCIENZA" HOSPITAL, TURIN,ITALY

L'ecocardiostress ha un ruolo prognostico additivo nella valutazione preoperatoria dei pazienti con cardiopatia valvolare sinistra, ma mancano dati circa il suo ruolo nella valutazione della riserva contrattile destra nei pazienti in attesa di correzione dell'insufficienza tricuspidale (IT). Riportiamo il caso di una giovane donna di 50 anni con cardiopatia valvolare reumatica plurioperata: nel 1994 commissurotomia aortica, mitralica e tricuspidalica; nel 1998 sostituzione valvolare aortica con bioprotesi per endocardite infettiva; nel 1999 sostituzione mitro-aortica con protesi meccaniche per distacco di protesi e plastica tricuspidale; nel 2003 sostituzione valvolare mitralica con protesi Carbomedics 27 per disfunzione protesica e re-do di plastica tricuspidalica (Sovering 23). Concomitano cardiopatia ischemica cronica e malattia delle vie di conduzione (BAV II grado tipo 1 e BBD). La paziente veniva ricoverata a giugno 2023 per scompenso cardiaco wet & warm NYHA IV prevalentemente destro, con severa congestione periferica ed ascite. All'ecocardiogramma: VS con compressione sistodiastolica, FE 51%; protesi aortica normofunzionante; VD dilatato (area TD 24 m2), severamente ipocinetico (TAPSE 9 mm, S' 4 cm/s,FAC 25%), con scarso adattamento al carico di lavoro (load adaptation index 16, RVCPI 108 mm*mmHg, ePAPI 1.1); IT torrenziale, gradiente VA destro 15 mmHg; pletora cavale con sistolizzazione del flusso sovraepatico. Si avviava terapia medica decongestionante con diuretico endovena a boli refratti (furosemide 240 mg/die + 400 mg/die canreonato), nitroglicerina ev e supporto inotropo (dobutamina 2.5 y).A compenso ottimizzato, in presenza di IT torrenziale e ventricolo destro disfunzionante, eseguivamo i seguenti accertamenti, al fine di definire la miglior strategia terapeutica: ecocardiografia trans-esofagea, che mostrava IT massiva da dilatazione dell'anello ed ampio flail del lembo settale non idonea a correzione edge-to-edge, angioTC total-body,senza reperti di rilievo, e cateterismo cardiaco destro, che documentava un normale regime pressorio polmonare e resistenze arteriolari nei limiti (wedge 12 mmHg, PAP 25/15/18 mmHg, RAP 11 mmHg, PAPI 0.9, RVSWI 4,8) con indice cardiaco ridotto (2.14 l/min/mq) ed ecostress con dobutamina con presenza di riserva contrattile ventricolare destra (aumento dello SV del 21%, FAC 28%>39%). Alla luce della giovane età della paziente, delle caratteristiche anatomo-funzionali della tricuspide, dell'assenza di ipertensione polmonare, e stante la presenza di riserva contrattile ventricolare destra, si sottoponeva la paziente ad intervento di sostituzione valvolare tricuspidale con bioprotesi (SJ Epic 27 mm) a cuore battente in minitoracotomia con buon esito, senza failure ventricolare destro post-cardiochirurgico e decorso post-operatorio regolare. Al follow-up a 3 mesi dall'intervento buon recupero funzionale (NYHA II), con buon funzionamento protesico e parziale rimodellamento inverso del ventricolo destro (riduzione dell'area telediastolica a 14 cmq, incremento della FAC a 30%). In conclusione, nel caso riportato l'ecocardiografia da stress farmacologico, documentando riserva contrattile ventricolare destra, si è dimostrata un importante ausilio nel predire l'assenza di failure ventricolare destra nell'immediato periodo post-chirurgico in una paziente a rischio operatorio aumentato; l'ecostress sembra pertanto presentare prospettive attraenti nella valutazione della riserva funzionale destra nei pazienti con disfunzione ventricolare destra e severa IT in valutazione per intervento correttivo valvolare. Studi futuri saranno necessari per definire la riserva contrattile ventricolare destra e validarne il ruolo prognostico in studi ampi a medio-lungo termine.

A694: PIVOTAL ROLE OF CONTRAST ECHOCARDIOGRAPHY IN THE MULTIMODAL DIAGNOSIS OF PRIMARY MEDIASTINAL DIFFUSE LARGE B-CELL LYMPHOMA: A CASE REPORT

Davide Donelli (a), Gianluca Signoretta (a), Diego Ardissino (a), Giampaolo Niccoli (a), Nicola Gaibazzi (a)
(a) CARDIOLOGY DIVISION, PARMA UNIVERSITY HOSPITAL, PARMA, ITALY

Clinical case. A 35yo female presented to the emergency room with symptoms of dyspnea, retrosternal pain, low-grade fever and profuse sweating. She had a complex medical history including fibromyalgia, allergic asthma, rheumatoid arthritis and early menopause. She has undergone multiple surgical interventions related to severe endometriosis. She also underwent a subtotal colectomy for chronic constipation. Bloodwork resulted normal. The thoracic CT scan revealed a well-defined, homogeneously hyperdense mass measuring 56x50x54 mm in the left anterior paramediastinal region. The mass was adhered to the ventricles and exerted a mass effect on the surrounding structures. No vascular occlusions were noted. The findings warranted further evaluation through cardiological assessment and ultrasound to potentially identify it as a pericardial cyst. Contrast echocardiography indicated vascularization of the mass in the anterior mediastinum, which extended from the left pulmonary vein to the right ventricle, mildly compressing the common trunk of the pulmonary artery. Upon contrast injection, the mass displayed two different layers: a superficial hyper-vascularized layer approximately 1.5 cm thick and a nearly avascular central mass. A distinct cleavage plane was observed, at least at the level of the pulmonary trunk. The PET scan was indicative of a necrotic core and revealed focal uptake in the right axillary lymph nodes. The biopsy of the mass subsequently confirmed the diagnosis of primary mediastinal diffuse large B-cell lymphoma. After interdisciplinary discussion, the patient was slated for treatment following the R-DaEPOCH regimen.
Conclusions. The case underlines the critical role of contrast echocardiography in multidisciplinary diagnostic approaches for complex cases. This imaging method not only provided additional structural details about the mass but also supplied valuable vascular information, and served as an essential bridge between initial CT findings and subsequent PET and biopsy results.

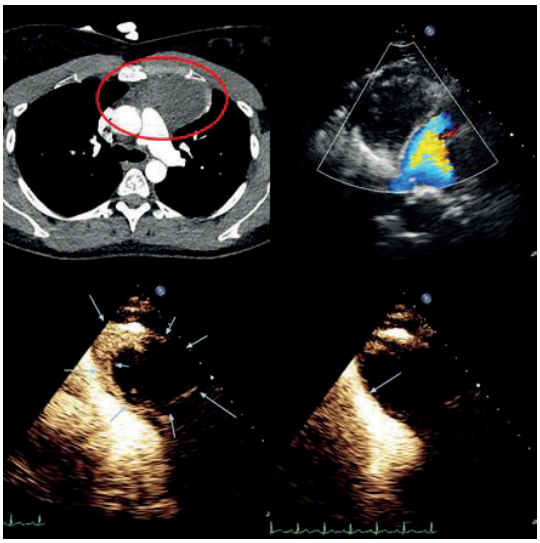

A695: QRS COMPLEX DURATION AND MYOCARDIAL SCINTIGRAPHY WITH SPECT PERFUSION ARTIFACTS OCCURENCE IN PATIENTS WITH LEFT BUNDLE BRANCH BLOCK

Andrea Melani (a), Giulia Elena Mandoli (a), Maria Concetta Pastore (a), Luna Cavigli (a), Giacomo Merello (a), Matteo Cameli (a), Flavio D'Ascenzi (a), Carlo Renato Pondrelli (c), Paolo Bertelli (b), Marta Focardi (a)
(a) DIPARTIMENTO DI BIOTECNOLOGIE MEDICHE, DIVISIONE DI CARDIOLOGIA, UNIVERSITÀ DEGLI STUDI DI SIENA; (b) UOC MEDICINA NUCLEARE, AZIENDA OSPEDALIERA UNIVERSITARIA SENESE; (c) UOC MEDICINA INTERNA E DELLA COMPLESSITÀ, AZIENDA OSPEDALIERA SENESE

Background. In patients with left bundle branch block (LBBB), myocardial perfusion defects and left ventricular functional abnormalities can occur especially in the territory of the left anterior descending coronary artery despite the absence of vessel obstruction. In literature the relationship between QRS duration and ECG-gated single photon emission computed tomography (SPECT) findings has not been clearly elucidated.
Purpose. The aim of the study was to examine the association between the QRS duration and the occurrence of LBBB-related perfusion artifacts in myocardial scintigraphy with SPECT in patients with LBBB.
Methods. We retrospectively screened the ECG of 85 consecutive patient with complete LBBB who underwent technetium-99m tetrofosmin electrocardiography-gated SPECT, from December 2017 to January 2023. All patients underwent dipyridamole gated SPECT with 1-day protocol. The retrospective ECG analysis was performed by a Cardiologist, and QRS complex duration at the baseline ECG trace was manually measured and averaged over three leads (DII, V1 and V5). The SPECT imaging analysis was performed by a Nuclear Medicine radiologist, and we retrospectively identified the presence of LBBB-related perfusion artifacts.
Results. The final population was composed by 53 patients (45% women, 55% men). The patients with LBBB and perfusion artifacts on SPECT imaging had significantly longer QRS mean duration at rest compared to patients with LBBB and no perfusion artifacts on SPECT imaging ($P<0.0001$). QRS duration assessment at baseline ECG was found to be a valuable approach to predict perfusion artifacts in SPECT evaluation (AUC 0.84); furthermore, we proposed a cut-off of QRS duration over which the occurrence of SPECT perfusion artifact is expected to be likely (142 ms, sensitivity 0.89 and specificity 0.62).
Conclusions. The data showed that the occurrence of SPECT myocardial perfusion artifacts significantly correlate to QRS duration in patients with LBBB. A simple QRS duration assessment on the baseline ECG trace could help to select subjects who are likely to benefit from SPECT imaging despite LBBB.

A696: UNVEALING HIDDEN PARTS OF THE HEART USING 3D AND CONTRAST ENHANCED ECHOCARDIOGRAPHY. WHY NOT?

Marika Martini (a), Chiara Palermo (a), Maria Teresa Savo (a), Silvia Romano (a), Giulia Mattesi (a), Antonella Cecchetto (a), Sabino Iliceto (a), Valeria Pergola (a)
(a) DIPARTIMENTO DI SCIENZE CARDIO-TORACO-VASCOLARI E SANITÀ PUBBLICA, UNIVERSITÀ DI PADOVA

Introduction. Left ventricular thrombosis (LVT) is a possible complication (3-9%) in patients with reduced ejection fraction (EF) due to ischemic heart disease (IHD), both in the acute or in the chronic phase, or less frequently in dilated, non-ischemic cardiomyopathy. It's a major risk factor for systemic thromboembolism so its diagnosis is of paramount importance to allow proper anticoagulant therapy. Contrast enhanced echocardiography (CEE) increases the detection of LVT (64% vs. 35% in contrast vs. non-contrast echo), while 3 D echocardiography (3DE) is known to improve the visualization of the apex. The combination of 3DE with CEE is rarely used in the detection of LVT.
Clinical case presentation. An 80-year-old man came to our echo-lab with a history of previous IHD (s/p graft and PTCA) and aortic valve replacement (bioprosthesis). Last TTE showed severe LV EF reduction, severe bioprosthesis dysfunction and apical LVT (figure A). Proper anticoagulant therapy was started. At our one-month control, the 3DE with multiplanar reconstruction was dubious about the persistence of a small apical LVT (figure B). CEE was administered to improve endocardial border definition. Combining 3DE with CEE administration, using multiplanar reconstruction (figure C) and surface rendering (figure D) we clearly evidenced undoubtable LVT resolution.
Conclusions. Using the combination of 3DE with CEE can improve the diagnostic accuracy in detecting LVT due to a more comprehensive visualization of the apical region, overcoming the limitations of the two diagnostic tools used separately. Further studies will be needed to compare its accuracy with Cardiac Magnetic Resonance, that is the gold-standard technique for LVT detection.

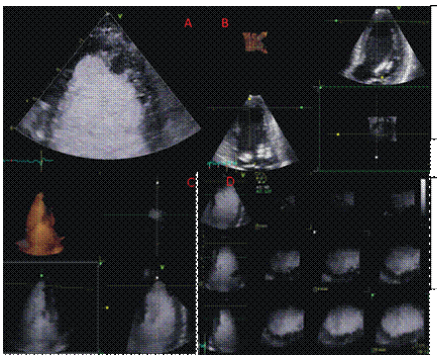

Figure A. 2D-contrast echocardiography showing LV apical thrombus.
Figure B. 3D multiplanar post-processing revealing dubious apical LVT.

Figure C. 3D-multiplanar post-processing and
Figure D. 2D-surface rendering excluding LVT.

A697: FUNCTIONAL ASSESSMENT OF DUAL-ENERGY CORONARY CT ANGIOGRAPHY THROUGH IODINE MAPS: IS IT THE MOMENT?

Antonino Micari (a), Tommaso D'Angelo (b), Manuela Ajello (a), Gianluca Di Bella (a), Silvio Mazziotti (b), Antonio Micari (a), Giuseppe Andò (a)
(a) CARDIOLOGY UNIT, DEPARTMENT OF CLINICAL AND EXPERIMENTAL MEDICINE, UNIVERSITY OF MESSINA, AOU POLICLINICO G. MARTINO, MESSINA, ITALY; (b) DIAGNOSTIC AND INTERVENTIONAL RADIOLOGY UNIT, BIOMORF DEPARTMENT, AOU POLICLINICO G. MARTINO, MESSINA, ITALY.

Thanks to increased CT scanner performance and availability, coronary CT angiography (CCTA) has seen an increased use in the evaluation in

patients with chest pain and suspected coronary artery disease (CAD). In recent years the technique has expanded its usefulness not only as an anatomical but also as a functional test, thanks to the possibility of estimating the fractional flow reserve (FFR) directly from CT datasets. Nonetheless, the development of more sophisticated CT scanners has also made it possible to acquire CCTA with dual-energy imaging techniques. We report the case of a 57-year-old patient with no history of cardiovascular disease except for hypertension, who had episodes of atypical angina. Resting electrocardiogram, echocardiography and serum cardiac biomarkers were normal. Due to the chest pain and the intermediate pre-test probability of coronary artery disease, we decided to further investigate by requesting a CCTA. The examination was performed with a dual-energy CT system (Philips IQon Spectral CT) and showed a moderate stenosis (i.e. 50-55%) extended in the proximal and middle portions of the left anterior descending (LAD) artery, caused by a mixed plaque (Figure 1, red arrows). Left circumflex (LCx) artery showed a focal mild stenosis in the distal segment. Since CCTA is an anatomical technique, it would not normally be possible to evaluate the hemodynamic impact of the stenosis. However, we took advantage of dual-energy imaging through the evaluation of iodine density maps. This technique allows to assess not only the attenuation but also the concentration of contrast medium in the single voxels and represent it in color-coded maps. In the basal (Figure 2) and mid (Figure 3) short-axis slices of the left ventricle, iodine density was reduced in the anteroseptal segments at both levels if compared with the mean of the other segments (1.14 mg/ml vs 1.85 mg/ml), demonstrating a reduced first-pass perfusion. This evaluation wasn't possible in conventional images, where the attenuation was comparable for all segments. Subsequently, the patient underwent coronary angiography which confirmed the presence of atheromatous lesions along the LAD, in the proximal and middle segments (Figure 4, red arrowheads). The hemodynamic significance was then confirmed using contrast FFR (cFFR=0,73). Given the age and coronary anatomy, revascularization with coronary artery bypass grafts was indicated, and the patient underwent surgery a few weeks later with clinical benefit. Our case demonstrates that iodine concentration maps derived from dual-energy CCTA datasets may be useful in the assessment of the hemodynamic effect of coronary stenosis, potentially improving the diagnostic usefulness and the accuracy of CCTA in borderline stenosis.

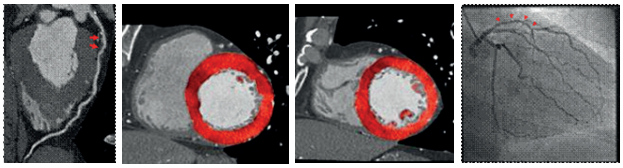

A698: ATYPICAL SITE OF INFECTIVE ENDOCARDITIS

Silvia Moscardelli (a), Francesca Bursi (a), Marco Stracqualursi (a), Maurizio Losito (b), Andrea Garatti (c), Marco Guazzi (a)
(a) UNIVERSITÀ DEGLI STUDI DI MILANO; (b) OSPEDALE SAN PAOLO, MILANO; (c) IRCCS POLICLINICO SAN DONATO, MILANO

The patient is a multi-drug addicted 23-year-old man, homeless, infected with Hepatitis C Virus (genotype 1a), recently diagnosed positive for Human Immunodeficiency Virus (HIV) but currently untreated. His past medical history included several accesses to the emergency room (ER) for venipuncture bleeding and during the last one, he escaped immediately after the placement of a central venous access, that he used to infuse drugs. After about 14 days from the last hospital access, he came back at our ER because of fever, cough, and dyspnea. Imaging evaluation showed multifocal pneumonia and sub-segmental pulmonary thromboembolism (PE). The compression ultrasound showed no evidence of thrombus while transthoracic echocardiography (TTE) showed a large polylobed mass with inhomogeneous texture occupying 2/3 of the dilated right atrium (RA), the transesophageal echocardiography (TEE) showed that the mass was composed of three parts, one was non-mobile and two were mobile. The immobile mass was adherent to the RA wall immediately after the opening of the inferior vena cava (IVC) and extended up to the tricuspid annulus; here two additional voluminous and mobile masses, partly mamillated and partly serpiginous, were implanted and projected during the cardiac cycle into the RV. The round mobile portion measured approximately 14x12 mm, the filamentous portion was approximately 33x6 mm. The tricuspid leaflets appeared thin with normal diastolic opening and minimal valvular regurgitation on Color Doppler. No adherent masses were found on the other valvular systems, which appeared continent. Interatrial septum was intact. Blood cultures resulted positive for multi-sensitive S. Aureus and S. Pyogenes. These findings were compatible with concomitant thrombotic and infective endocarditis (IE) of the outlet of the IVC and the RA. Due to multiple lung embolization along with persistence of large dimensions of the infected mass, the patient underwent surgical removal of the mass. In addition, a reconstruction of outlet of the IVC and of the atrial wall with patches of heterologous pericardium was performed. Histological examination confirmed the septic nature of the thrombus. No major complications occurred in the post-operative course. The patient started a comprehensive rehabilitation process, wishing he will stop using intravenous drugs, given the high recurrence rates of IE in this category of patients. We reported a case of right sided IE in an intravenous drug abuser with concomitant HIV seropositivity. The interesting aspect of our case was the atypical site of IE: the outlet of the IVC and the right atrium with the complete preservation of the tricuspid valve whose leaflets appeared thin with normal diastolic opening, without significant regurgitation on Color Doppler.

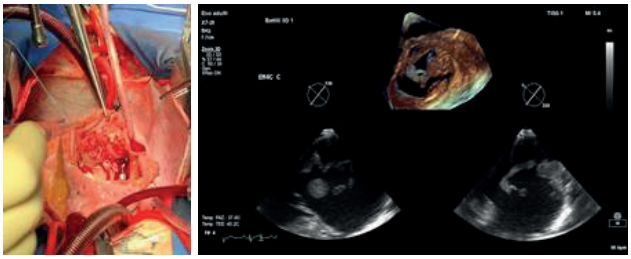

A699: MULTI-MODALITY IMAGING CHARACTERIZATION OF MYOCARDIAL DAMAGE IN COVID-19 WITH ATYPICAL CLINICAL PRESENTATION

Stefano Frittella (a), Stefano Figliozzi (a), Leandro Di Caccamo (a), Anastasia Celata (a), Vincenzo Battaglia (a), Dario Donia (a), Giuseppe Pinto (a), Carlo Pivato (a), Riccardo Mantovani (a), Lorenzo Monti (a), Marco Francone (b), Giulio Stefanini (b), Renato Maria Bragato (a), Gianluigi Condorelli (b)
(a) IRCSS HUMANITAS RESEARCH HOSPITAL; (b) HUMANITAS UNIVERSITY

Background. As a result of "immunothrombosis", which is a process characterized by the interaction between activated neutrophils, monocytes, platelets and the coagulation cascade, micro- and macro-thrombotic complications may occur in patients affected by Covid-19. These complications have been mainly described in patients with severe pneumonia or other major risk factors for thrombosis (i.e., older age, obesity, thrombophilia, cancer, major surgery).

Case summary. A 37-year-old male, unvaccinated for SARS-COV2, was referred to our institution for dysarthria. He referred sore throat one week before and denied fever, chest pain, dyspnoea, and syncope. Biochemical examinations showed elevated D-dimer (10670 ng/ml) and Troponin-I (2052 ng/ml), a slight increase of White blood cells (11380/mm^3) and CRP (CRP 3.9 mg/dl), negative PCT, and positive swab test for SARS-COV2. Brain MRI revealed multiple diffuse ischemic spots. Multiple splenic and kidney infarctions were found at total-body CT, which also detected bilateral pulmonary embolism and a ground-glass parenchymal consolidation in the right inferior lobe. In the suspicion of patent foramen ovale (PFO), the patient underwent trans-thoracic and trans-oesophageal echocardiography, which confirmed the PFO and unveiled an arboreous intracavitary floating mass of 40 x 35 x 17 mm attached to the apex of the right ventricle (RV), suspected of cardiac thrombus. At Cardiac Magnetic Resonance (CMR), the mass was slightly hyperintense in T2-w images and did not show enhancement in late sequences after contrast, confirming the suspicion of a fresh thrombus. Moreover, a focal, transmural area of late gadolinium enhancement in the basal posterior wall showed markedly elevated values of native-T1 (=1105 msec) and T2-mapping (=59 msec), in keeping with a recent embolic infarct. No abnormalities were found at the screening for thrombophilia, which evaluated antithrombin III, functional fibrinogen, C3, C4, LAC, reuma test, ANA, anti-ds-DNA, ANCA, ENA, EMA and antiphospholipid antibodies. The patient was discharged in stable clinical conditions with full-dosage anticoagulation (i.e., firstly with Enoxaparin and then with Rivaroxaban 15mg twice daily for 20 days then increased to 20 mg twice daily). At follow-up brain MR performed three weeks after discharge there was stability of radiological lesions and a trans-thoracic echocardiography after three months of anticoagulant therapy showed complete resolution of the intracardiac thrombus.

Discussion. The present case highlights: i) SARS-COV2 infection as a dramatic trigger for intracardiac thrombus, in the absence of comorbidities, severe pneumonia, or other thrombophilic factors; ii) multi-modality cardiac imaging, including CMR, to unveil the underlying mechanisms of myocardial damage in patients with Covid-19, guiding tailored and effective treatments.

A700: AORTIC BIOPROSTHESIS IN MITRAL POSITION: A GO-WITH-THE-FLOW DIAGNOSTIC APPROACH

Adelaide Iervolino (a), Luca Maria Capece (a), Martina Pucci (a), Velia Iadevaia (a), Marina Iacono (a), Mariateresa Pontoriero (a), Daniele Paoletta (a), Roberta Esposito (a)
(a) DEPARTMENT OF ADVANCED BIOMEDICAL SCIENCES, FEDERICO II UNIVERSITY HOSPITAL, NAPLES, ITALY

Case presentation. A 40 years-old woman was admitted to our outpatient department for a post-surgical follow-up visit. The patient had undergo-

ne mitral valve replacement three years before with a 29 mm inverted Resilia bioprosthesis for failure of previous mitral valve repair. She did not complain of any symptom and reported a good exercise tolerance. At the heart auscultation, a diastolic 3/6 Levine murmur was heard.

Echocardiographical evaluation. Echocardiography showed a nicely placed aortic bioprosthesis on the mitral leaflets in absence of any paravalvular leak or residual regurgitation. Nevertheless, increased CW doppler transmitral gradients (mean PG 9.4 mmHg) and absence of the A wave were noted with high hemodynamical patient state and visible structural valve alteration being ruled out. Thus, mitral valve area (MVA) was calculated through planimetry, continuity equation and PHT, showing different results but with none of them fulfilling valve stenosis criteria. A small reduction in systolic function (EF 47%) and regional basal akinesia were also noted on the inferior, posterior, and anterolateral walls of the left ventricle. Global longitudinal strain was calculated to be 12% with the bull eye showing the corresponding distribution. Ischemic insult after the operation and valve-linked basal motion alterations were hypothesized.

Further investigations. Previous medical examinations were exhibited by the patient. In three years of regular follow-ups, not only the transvalvular gradient showed no significant alteration, being in the range of 8 to 9 mmHg, but also the LV systolic function had always been mildly reduced. At the images comparison, the same segmental akinesias were noted since the surgery. The patient was requested a myocardial scintigraphy and provided with optimized guideline-directed medical therapy, including beta blockers and ACE inhibitors.

Discussion. Prosthetic valve evaluation must be directed carefully, especially in patients with aortic prosthetic valve in mitral position. Regular cut-offs used for determining mitral stenosis cannot be considered in reason of the diversity of the aortic prosthesis' effects on the transmitral flow, this showing the need to investigate and determine new, specific ones. Furthermore, higher-than-normal transmitral gradients should not rise concern, unless increasing over time and correlation with clinical conditions should always be made, even when diastolic and systolic alterations are present. Given the lower rates of this surgical intervention, we should share more clinical data and manifest the strong need for a consensus between physicians of this challenging prosthetic valve evaluation.

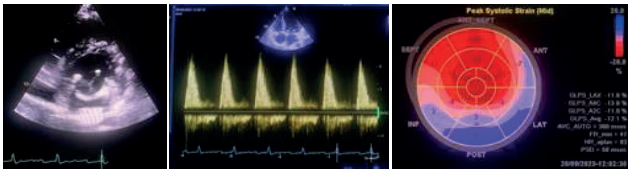

A701: THE ROLE OF CMR IN HCM: FROM CLINICAL PRACTICE TO GUIDELINES

Maria Lo Monaco (a), Rocco Mollace (a), Flavia Nicoli (a), Alessandro Gad (a), Federico Marchini (b), Elvis Elvino Brscic (a), Alberto Cremonesi (a), Elona Collaku (c), Alessandro Zanello (c), Enzo Angeli (c), Erika Bertella (a)
(a) CARDIOLOGY DIVISION, HUMANITAS GAVAZZENI HOSPITAL, BERGAMO, ITALY; (b) CENTRO CARDIOLOGICO UNIVERSITARIO, AZIENDA OSPEDALIERO-UNIVERSITARIA ARCISPEDALE S.ANNA, FERRARA; (c) RADIOLOGY DIVISION, HUMANITAS GAVAZZENI HOSPITAL, BERGAMI, ITALY

Introduction. Hypertrophic cardiomyopathy (HCM) is a common inherited disorder, with a prevalence of 0.2% in the general population. Previous studies have reported that the prevalence of epicardial coronary artery disease (CAD) in HCM ranged from 10 to 53%. Myocardial bridging (MB) is a phenomenon that occurs when coronary arteries course through myocardial tissue rather than, as is normal, on the surface of the myocardium. MB in an adult with HCM is a rare congenital coronary artery anomaly and it is often detected incidentally.

Clinical case. A 62-year-old female patient with known hypertension, followed up with ramipril 5 mg tablet, was admitted to our Emergency Department for palpitation. In the 12-lead ECG taken, atrial flutter, heart rate 140/min, left ventricular hypertrophy and strain pattern in the precordial leads were observed. Blood pressure was 130/65 mmHg. Significant change was observed in the laboratory findings of the patient (hsTnI at the first detection was 35994,60 ng/ml). In the transthoracic echocardiography, ventricular systolic function was within normal limits with apical hypokinesia, and the left ventricular ejection fraction was 55% (measured by the Simpson method). A thickening reaching 17 mm was observed in the left ventricular basal segment, no gradient increase was observed in the left ventricular outflow tract. Valve functions and pericardium were normal. Coronary angiography (CA) was done in the same day because of the patient's laboratory and echocardiography findings. CA excluded coronary artery disease. The right coronary system was dominant The right coronary artery (RCA), left main coronary artery (LMCA), and left anterior descending (LAD) had a normal origin, length, and luminal diameter. There was a long myocardial bridge localized on the middle tract of the LAD. CA showed a subtotal occlusion of the bridge in systole. The patient underwent to cardiac magnetic resonance (CMR). T2-weighted cardiac magnetic resonance (CMR) identifies edematous myocardium subjected to ischemia in anterior segments. Contrast-enhanced CMR with late-gadolinium enhancement (LGE) showed extensive non ischemic LGE (38% LV myocardium). Patient was discharged after ICD implantation. Metoprolol was added to the current treatment of the patient.

Conclusions. We present a case of MB with myocardial ischemia in an adult with HCM as diagnosed by coronary angiography and extensive edema and non ischemic LGE as showed by CMR. Treatment was given to relieve symptoms and to prevent sudden cardiac death and a follow-up strategy was determined. CMR was essential to evaluate ischemia and to assess the extent and distribution of hypertrophy and myocardial fibrosis, as recent guidelines recommend before alcohol septal ablation, myectomy or ICD implantation.

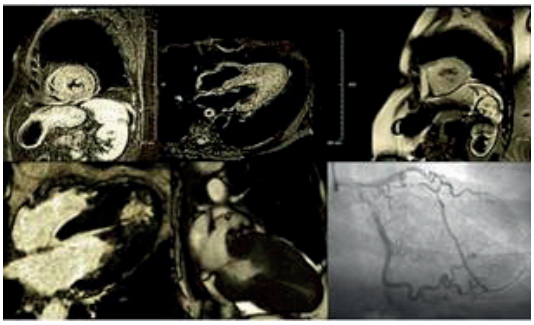

A702: UNUSUAL LEG EDEMIZATION FOLLOWING PERCUTANEOUS CLOSURE OF PATENT FORAME OVALE: A CASE REPORT

Gloria Santangelo (a), Gabriele Tumminello (a), Ferdinando Loiacono (a), Francesco Giangiacomi (a, b), Stefano Carugo (a, b)
(a) DEPARTMENT OF CARDIO-THORACIC-VASCULAR DISEASE, FOUNDATION IRCCS CA' GRANDA OSPEDALE MAGGIORE POLICLINICO, MILANO, ITALY; (b) DEPARTMENT OF CLINICAL SCIENCES AND COMMUNITY HEALTH, UNIVERSITY OF MILAN, 20122 MILANO, ITALY

A 74-year-old Caucasian woman, underwent closure of a patent foramen ovale (PFO) two weeks before due to platypnea-orthodeoxia syndrome, presented to the emergency department with isolated bilateral leg edema. Abdominal and chest ultrasound excluded pleural effusion and ascites. Upon admission, the patient was found to have new-onset atrial fibrillation with adequate heart rate. The echocardiography revealed normal dimensions and functioning of both ventricles, without significant any valvular disease and pericardial effusion. However, it showed a narrowing of the inferior vena cava (IVC), located approximately 3 cm before the right atrium with an accelerated blood flow(PANEL A-B). In order to investigate the presence of IVC thrombosis, a contrast-enhanced computed tomography scan was performed, which ruled out the presence of a blood clot. Nevertheless, a narrowing of IVC was confirmed, without external compression or hepatic and suprahepatic vein dilation (PANEL C). Intravenous furosemide was administered with resolution of leg edema. In the suspicion of pulmonary hypertension or right ventricle dysfunction existing before the closure of PFO, which became clinically evident after the closure of a presumed "stretched PFO," a right heart catheterization was performed. It revealed normal pulmonary systolic and mean pressure, right atrial pressure, pulmonary capillary wedge pressure and cardiac output. Furthermore, a shunt between right and left circulations was ruled out with invasive Qp/Qs determination. A venous angiography was performed to better evaluate the morphology of the narrowing (PANEL D). Moreover, the gradient across the constriction was invasively determined during inspiration and expiration, and resulted of 4 mmHg. The hypothesis that the narrowed IVC was responsible for bilateral leg edema appeared to be more likely. We hypothesize that the closure of PFO lead to an increase in right atrial pressure, which, despite remaining in the normal range, contributed to determine an increase in lower limb venous pressure together with the pre-existent narrowed IVC. Indeed, the patient reported an improvement in respiratory symptoms after the closure of PFO and her blood oxygen saturation remained normal, which is consistent with the interruption of the right-to-left atrial shunt. Therefore, the absence of the right-to-left shunt and the increase in pressure of IVC determined an increase in venous pressure before the narrowing, leading to bilateral leg edema. To our knowledge, this is the first description of isolated bilateral leg edema following percutaneous closure of PFO in association with pre-existent narrowing of IVC. In this case diuretic therapy resulted effective in treating symptoms. Otherwise, an interventional treatment with self-expandable stent may be considered in case of resistance to medical therapy, hypothesizing a similar approach to that used for patients with Budd-Chiari syndrome (BCS), where short-segment stenosis of hepatic veins or the inferior vena cava can be treated with an angioplasty with or without stent implantation to restore hepatic and splanchnic blood flow.

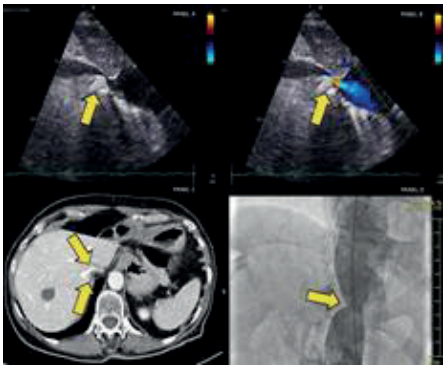

A703: PSEUDOANEURYSM OF THE MITRAL-AORTIC INTERVALVULAR FIBROSA: THE IMPORTANCE OF WELL-TIMED SURGERY

Rachele Manzo (a), Dalila Nappa (a), Andrea Mariani (a), Domenico Angellotti (a), Maddalena Immobile Molaro (a), Domenico Simone Castiello (a), Giulia Sgherzi (a), Fiorenzo Simonetti (a), Ciro Santoro (a), Marisa Avvedimento (a), Raffaele Piccolo (a), Anna Franzone (a), Federica Ilardi (a), Giovanni Esposito (a)
(a) UNIVERSITY OF NAPLES FEDERICO II

Introduction. Prosthetic valve endocarditis (PVE) is a relatively uncommon but serious complication, occurring in about 1-6% of patients, especially after biological valve replacement surgery. It represents the 20-30% of all cases of infective endocarditis (IE) with a reported in-hospital mortality of 20-40%. Uncomplicated and late PVE generally undergo conservative management; however, the identification of high-risk features (i.e. local complications, heart failure, etc) is mandatory for the referral to surgery, with important implications on outcomes.

Case presentation. A 59-year-old patient presented to the emergency room due to severe dyspnea, six months after surgical aortic valve replacement with a biological prosthesis for severe aortic regurgitation; no history of postoperative infection was reported. Hemodynamic was stable, but a III/VI Levine aortic diastolic murmur was detected. Transthoracic echocardiography showed normal intra-prosthetic gradients and severe aortic regurgitation of unclear mechanism. On transesophageal echocardiography (TEE) no prosthesis degeneration or vegetation was found, but a severe posterior para-valvular leak was detected by color-Doppler. A thin-walled pulsatile cavity protruding into the left atrium and consistent with a pseudoaneurysm in the mitral-aortic intervalvular fibrosa (MAIVF) was identified (Panel A, B). It was in communication with the LVOT, expanding in early-systole and collapsing in diastole (Panel C); this finding was even confirmed at computed tomography (Panel D). Blood tests resulted negative for active inflammation or infections and blood cultures tested negative. At first, the patient refused reintervention but, three months later, due to the evidence of new-onset echo-dense material suggestive of vegetation (Panel E) at TEE, urgent surgery was performed. Intraoperative analysis revealed large vegetation on the ventricular aspect of the sewing ring, with spared prosthetic leaflets (Panel F) and a destroyed MAIVF. Prosthetic cultures tested positive for Staphylococcus hominis spp hominis growth. A clear uncontrolled infection should always be an indication for urgent surgery. Instead, in the suspicion of local complications of infective endocarditis, close clinical and echocardiographic follow-up should be performed even without evidence of vegetation or positive blood cultures. Indeed, a conservative treatment related to the absence of a definite diagnosis of endocarditis could have exposed the patient to the risk of vegetation embolization or pseudoaneurysm rupture.

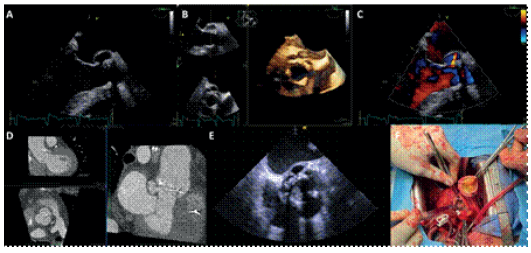

A704: IMAGING MULTIMODALE NELLA DIAGNOSI DIFFERENZIALE DI MINOCA

Angelo Melpignano (a), Giulia Passarini (b), Antonella Scala (a), Gabriele Guardigli (b)
(a) UNIVERSITÀ DEGLI STUDI DI FERRARA; (b) AZIENDA OSPEDALIERO-UNIVERSITARIA DI FERRARA

Paziente donna, 73 anni, ipertesa, dislipidemica ed ex fumatrice, si presenta presso il pronto soccorso per dolore toracico tipico comparso a riposo, persistente da alcune ore. L'ECG risultava negativo per segni di ischemia. Agli esami ematochimici: PCR 2,15; $hsTnI_0$ 1799 ng/L e $hsTnI_1$ 3747 ng/L. Giunta in reparto si eseguiva ecocardiografia transtoracica, che non mostrava difetti di cinetica segmentaria, con una frazione di eiezione (FE) del ventricolo sinistro nei limiti, senza ulteriori reperti di rilievo. Il giorno seguente veniva eseguito studio coronarografico con riscontro di ateromasia diffusa delle arterie coronariche in assenza di lesioni angiograficamente significative. Nel sospetto di MINOCA (myocardial infarction with non-obstructive coronary arteries) veniva eseguito anche imaging intracoronarico mediante OCT (optical coherence tomography) che metteva in evidenza una placca intermedia al tratto medio dell'arteria discendente anteriore, in assenza di caratteristiche suggestive per instabilità di placca (erosione o rottura) o per dissezione spontanea. Si proseguiva contestualmente con prove di funzionalità coronarica: FFR (fractional flow reserve) 1.01 (cut-off 0.80), CFR (coronary flow reserve) 3.0 (cut-off 2.0) ed IMR (index of microvascular resistence) 46 (cut-off 25), con evidenza di disfunzione del microcircolo coronarico. A completamento veniva eseguita RM cardiaca, che ha mostrato edema delle pareti laterale e infero-laterale medio-basale del ventricolo sinistro nelle sequenze T2 con presenza di LGE (late gadolinium enhancement) a distribuzione meso-subepicardica, nelle medesime regioni, reperti strumentali tipicamente espressione di miocardite. Il termine MINOCA accomuna sotto la stessa definizione clinica (infarto miocardico in assenza di ostruzione coronarica) molteplici possibili eziologie, le quali possono differire molto tra loro per valore prognostico e applicazione terapeutica. Il percorso diagnostico nel MINOCA è spesso complesso e prevede l'applicazione di numerose metodiche includendo imaging intra-coronarico, test funzionali per lo studio coronarico e test vasomotori, concludendo, infine, con lo studio mediante risonanza magnetica (RM) cardiaca. Questo caso mostra la complessità dei possibili scenari clinici, nonché la possibilità che più patologie possano essere concomitanti rendendo fondamentale l'integrazione dell'imaging multi-modale con i test funzionali per arrivare ad una corretta diagnosi.

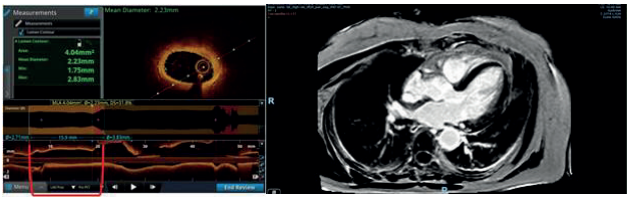

A705: TROMBOSI SU DISPOSITIVO DI CHIUSURA DI AURICOLA SINISTRA

Sofia Meossi (a), Alice Vitagliano (a), Chiara Pedone (a), Enrica Perugini (a), Gianni Casella (a)
(a) OSPEDALE MAGGIORE CARLO ALBERTO PIZZARDI - AUSL BOLOGNA

Introduzione. La chiusura percutanea di auricola sinistra costituisce una valida opzione terapeutica nella prevenzione dello stroke in pazienti con fibrillazione atriale e controindicazione alla terapia anticoagulante orale. La principale complicanza post-procedura è rappresentata dalla trombosi sul dispositivo, la cui prevenzione, diagnosi e trattamento sono ancora oggi oggetto di dibattito.

Case report. Riportiamo il caso di un paziente maschio di 75 anni affetto da fibrillazione atriale permanente e recente emorragia cerebrale temporo-parieto-occipitale in corso di anticoagulante orale diretto, per cui era stata posta indicazione a chiusura percutanea di auricola sinistra, eseguita con device Watchman 35 mm e senza complicanze periprocedurali. Alla luce dell'elevato rischio emorragico, il paziente era stato dimesso con singola terapia antiaggregante con Clopidogrel 75 mg (previo precarico con 300 mg). A 40 giorni dall'impianto è stata eseguita ecocardiografia transesofagea di controllo che ha evidenziato la presenza di una estesa formazione trombotica adesa al dispositivo di chiusura dell'auricola sinistra (22x17mm) altamente mobile, reperto non evidenziabile all'ecografia transtoracica. Il paziente è stato ricoverato in regime di urgenza in UTIC e, in considerazione dell'elevato rischio emboligeno della trombosi, è stato sottoposto a terapia anticoagulante con eparina non frazionata, previa esecuzione di TC encefalo che escludeva eventi ischemici/emorragici acuti e successivamente a eparina a basso peso molecolare a dosaggio anticoagulante. Durante la degenza di due settimane sono state ripetute due TC encefalo che escludevano segni di emorragia intracranica in atto ed è stata eseguita ecocardiografia transesofagea con riscontro di netta riduzione della formazione trombotica (13x9mm). All'ecocardiografia transesofagea eseguita a distanza di un mese non risulta più visualizzabile la formazione trombotica sul device, per cui è stata sospesa la terapia anticoagulante in atto ed iniziata una doppia terapia antiaggregante con Clopidogrel e ASA, programmando un ulteriore controllo transesofageo a tre mesi.

Conclusioni. La trombosi sul dispositivo di chiusura di auricola sinistra è la principale complicanza in grado di vanificare questa strategia terapeutica. La profilassi antitrombotica post-procedura è ancora fonte di dibattito nelle sue tempistiche e modalità e deve essere personalizzata

sul singolo paziente in base al profilo di rischio trombotico ed emorragico. Nella diagnosi precoce di una eventuale trombosi sul dispositivo gioca un ruolo fondamentale il follow-up tramite ecocardiografia transesofagea, essenziale per ridurre la probabilità di fenomeni embolici e adottare una tempestiva terapia anticoagulante.

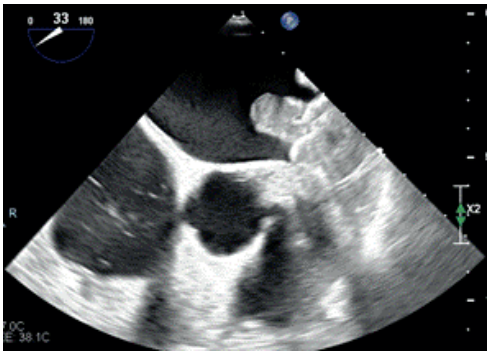

A706: MULTI-MODALITY IMAGING UNVEILING A COMPLEX LANDSCAPE: ASYMPTOMATIC PATIENT WITH SUSPECTED ARVD, PROGRESSIVE RIGHT CHAMBERS DILATION, ANOMALOUS PULMONARY VENOUS RETURN, ATRIAL SEPTAL DEFECT, BOVINE AORTIC ARCH AND ANOMALOUS CORONARY ORIGIN

Davide Donelli (a, b), Diego Ardissino (a), Evelina Faragasso (b)
(a) CARDIOLOGY DIVISION, PARMA UNIVERSITY HOSPITAL, PARMA, ITALY; (b) CARDIOVASCULAR IMAGING UNIT, SALUS HOSPITAL REGGIO EMILIA, REGGIO EMILIA, ITALY

Clinical case. A 38-year-old asymptomatic male with no other comorbitidies was in follow-up since age 23 due to an ECG with a RBBB and a slightly visible epsilon wave on V1, which raised suspicions for Arrhythmogenic Right Ventricular Dysplasia (ARVD). Over 15 years, the echocardiograms showed stable left ventricular function but progressive dilation and hypertrophy of the right heart chambers. Initially, the right ventricle was at the upper limits of normal size. A decade later, both the right atrium and ventricle were mildly dilated. Throughout this period, transesophageal echocardiograms found no abnormalities. By the latest exam, the dilation and wall thickening in the right ventricle had become more pronounced, raising concerns for potential underlying evolving pathology. Cardiac magnetic resonance (CMR) showed a normal left ventricle with an ejection fraction (EF) of 66%. The right ventricle was enlarged but maintained a normal EF of 64% without signs of wall bulging. Importantly, no late gadolinium enhancement was observed, indicating an absence of fibrosis or myocardial fat infiltration. Unusual findings included a Qp/Qs ratio of 1.9, suggesting a left-to-right shunt, and evidence of anomalous pulmonary venous return (PAPVR) involving at least one upper right pulmonary vein draining into the superior vena cava. An associated interatrial defect of the sinus venosus type and a likely bovine aortic arch were also noted. Further study with computed tomography (CT) confirmed the presence of PAPVR, where the venous system of the upper and middle lobes of the right lung drained into the superior vena cava near its entrance into the right atrium. The anomalous form of interatrial septal defect (ASD) with subsequent right chamber dilation and the bovine aortic arch were confirmed as well. Moreover, an anomalous "slit-like" origin of the right coronary artery from the left Valsalva sinus with an interarterial course was revealed.

Conclusions. The patient had a range of cardiovascular abnormalities needing further evaluation and potentially requiring surgery. The case highlights the importance of comprehensive, multi-modality imaging in cardiovascular disease.

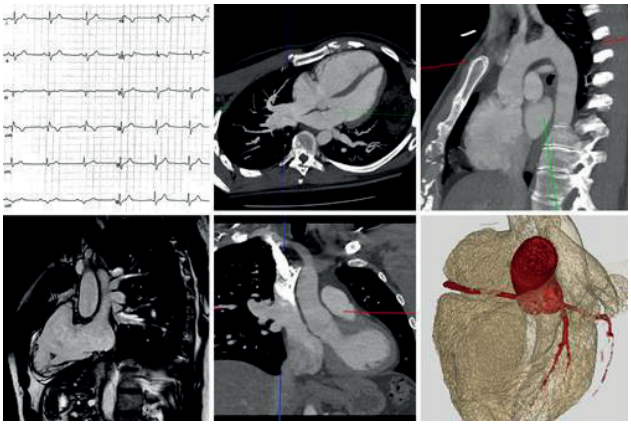

A707: UNA RARA ESTENSIONE DEL FIBROELASTOMA PAPILLARE

Manuel Freschini (a), Federica Pesce (a), Marco Giuranna (a), Ketty Savino (a)
(a) CARDIOLOGIA E FISIOPATOLOGIA CARDIOVASCOLARE - UNIVERSITÀ DEGLI STUDI DI PERUGIA

Introduzione. Il fibroelastoma papillare è una neoplasia endocardica primitiva benigna. Origina prevalentemente dall'endocardio valvolare, con localizzazione più frequente sulla valvola aortica, più raramente dall'endocardio ventricolare, dai muscoli papillari e dalle corde tendinee. Nella maggior parte dei casi la diagnosi è occasionale. Tuttavia, dato il suo elevato rischio embolico, manifestabile con ictus ischemico e dispnea, è consigliato il trattamento di escissione chirurgica.

Caso clinico. Uomo, 56 anni, fumatore, affetto da diabete mellito, ipertensione arteriosa, aneurisma dell'aorta ascendente e pregresso ictus ischemico, giunge in pronto soccorso per dolore toracico persistente, irradiato posteriormente. La TC torace esclude la sindrome aortica acuta, il tracciato ECG e la determinazione seriata della TnHS non mettono in evidenza una sindrome coronarica acuta; anche l'ecoscopia è negativa per alterazioni della cinesi regionale; tuttavia, visualizza una massa adesa al lembo anteriore mitralico fluttuante nel LVOT. Per la definizione diagnostica si esegue ecocardiografia integrata transtoracica e transesofagea che conferma l'ectasia dell'aorta ascendente (50 mm) in assenza di flap intimale. Sull'apparato valvolare mitralico, ad impianto lungo la porzione anulare del lembo anteriore si visualizza una massa iperecogena, delle dimensioni di circa 30x13 mm, costituita da multiple formazioni ad ecogenicità omogenea (A,B,C), a superficie regolare, con apparente coinvolgimento delle corde tendinee tese fra il muscolo papillare antero-laterale ed il LAM, ampiamente fluttuante nel LVOT (B,D) ma senza ostruzione all'efflusso ventricolare. Le caratteristiche ecografiche sembravano compatibili con fibroelastomi multipli. Date le caratteristiche della massa, il pregresso ictus ischemico e la giovane età, il paziente veniva sottoposto, dopo coronarografia, a resezione chirurgica della massa e sostituzione dell'aorta ascendente con protesi vascolare. Al momento della resezione i lembi dell'apparato mitralico apparivano normali per morfologia; a livello del LAM, in prossimità della commissura postero-mediale, si evidenziava l'ampia formazione, infiltrante alcune corde tendinee, a consistenza elastica, ramificata e fluttuante. La formazione veniva rimossa e la valvola riparata. L'intervento si è concluso con l'asportazione dell'aorta ascendente ectasica e la sostituzione con protesi vascolare. L'esame istologico ha messo in evidenza tessuto ricco di frammenti di tessuto connettivo, parzialmente rivestiti da endotelio con estese aree di degenerazioni mixoide, pertanto, veniva confermata la diagnosi di fibroelastomi multipli.

Discussione. Le peculiarità del caso clinico sono la localizzazione sull'apparato valvolare mitralico con il coinvolgimento delle corde tendinee e le notevoli dimensioni.

Conclusioni. L'imaging ecocardiografico ha consentito un'accurata diagnosi ed ha indirizzato al corretto approccio terapeutico.

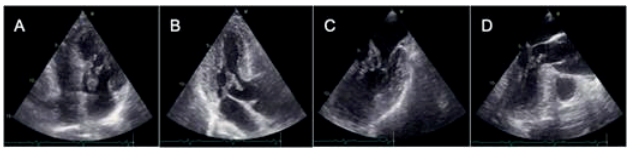

A708: L'APPARENZA INGANNA: UN CURIOSO CASO DI CARDIO(MIO)PATIA

Gabriele Guidi Colombi (a), Alberto Cossu (b), Simone Biscaglia (a), Gianluca Campo (a), Elisabetta Tonet (a)
(a) CARDIOLOGY UNIT, AZIENDA OSPEDALIERO-UNIVERSITARIA DI FERRARA; (b) UNIVERSITY OF FERRARA

Background. La cardiomiopatia ipertrofica (HCM) è la patologia cardiaca geneticamente trasmessa più frequente a livello mondiale. Il suo inquadramento diagnostico va da un'anamnesi familiare dettagliata, passando per l'esecuzione di esami strumentali, come Ecocardiografia e Risonanza Magnetica (RM) cuore, fino all'esecuzione di test genetici. Nonostante questo, rimane una diagnosi di esclusione, che prende in considerazione sia quelle entità cliniche, di origine sistemica o cardiaca, che possono causare un inspessimento del ventricolo sinistro (ipertensione arteriosa, valvulopatia aortica, acromegalia), sia le cosiddette fenocopie dell'HCM, patologie che, in assenza di altre cause, portano a un inappropriato aumento degli spessori di parete (M. di Anderson Fabry, Amiloidosi). Il percorso verso la diagnosi più probabile è però più insidioso di quello che si pensi.

Caso clinico. Uomo di 50 anni con in anamnesi dislipidemia e ipertensione farmacorestistente da circa 15 anni (PAS domiciliare 180 mmHg); familiarità per CAD (nonno materno deceduto per infarto a 67 anni) e per morte improvvisa (nonno paterno deceduto a circa 50 anni, e cugino I grado intorno ai 60 anni con un cuore, a detta sua, "ingrossato"). Per l'insorgenza di sintomatologia dispnoica eseguiva alcuni accertamenti cardiologici: all'ECG RS, segni di ipertrofia ventricolare sinistra e onde T negative da V1-V3; all'ecocolordoppler cardiaco si riscontrava un quadro di ipertrofia ventricolare sinistra (DTDtd 48 mm, SIVtd 16 mm, PPtd 11 nm), con FE del Vsn conservata; bulbo aortico e tratto ascendente di normali dimensioni.

Il quadro ecocardiografico era suggestivo cardiopatia a fenotipo ipertrofico non ostruttivo, per cui si programmava l'esecuzione di RM cardiaca. All'RM: globale ipertrofia di grado lieve con tendenza all'asimmetria per prevalenza del setto medio-basale e configurazione sigmoidea del setto stesso (spessore max setto basale 21 mm, parete laterale 12 mm), senza evidenza di ostruzione dinamica dell'LVOT. Evidenza di plurimi foci di LGE a distribuzione mesocardica patchy maggiormente in parete laterale e sede basale. Alla Coro TC nessun segno di coronaropatia. In entrambi le metodiche non erano presenti quei reperti morfologici suggestivi di HCM come anomalie dell'apparto valvolare mitralico e dei muscoli papillari, presenza di cripte miocardiche, rimodellamento atriale sinistro alla RM, oppure la presenza di ponte miocardico alla Coro-TC. Nel forte sospetto di HCM, venivano escluse, mediante esami specifici, altre cause di ipertrofia ventricolare sinistra, le cosiddette fenocopie sopracitate. Infine, data la storia familiare di morte cardiaca improvvisa, veniva svolta un'analisi molecolare del pannello di geni associati all'HCM (che per il 60% dei probandi ha trasmissione AD), la quale dava risultato negativo, suggerendo improbabile un'eventuale trasmissione genetica di HCM. Nonostante il quadro strumentalmente suggestivo di HCM, il substrato patologico veniva ricondotto all'espressione di una cardiopatia ipertensiva con segni di overload pressorio. In questo caso, infatti, la presenza di LGE alla RM non deve far frettolosamente concludere per cardiomiopatia in quanto esso può rappresentare un segno di sovraccarico inveterato.
Discussione. Differenziare la cardiopatia ipertensiva non trattata e la HCM può essere molto complesso, soprattutto in quei casi che si presentano con un'ipertrofia asimmetrica del ventricolo sinistro. La diagnosi differenziale risulta fondamentale e si basa sull'integrazione di dati anamnestici, tecniche di imaging e indagini genetiche.

A709: NEW ONSET CARDIAC MURMUR AND EXERTIONAL DIYSPNEA IN AN APPARENTLY HEALTHY CHILD: A RARE LOCALIZATION OF OBSTRUCTIVE MYXOMA IN RIGHT VENTRICLE OUTFLOW TRACT WITHOUT PULMONARY EMBOLIZATION: A CASE REPORT

Carolina D´anna (a), Alberto Villani (a), Antonio Ammirati (a), Paola Francalanci (a), Laura Ragni (a), Aurelio Secinaro (a), Marcello Chinali (a), Antonella Santilli (a), Paolo Guccione (a), Lorenzo Galletti (a), Gianluca Brancaccio (a)
(a) OSPEDALE PEDIATRICO BAMBINO GESÙ ROMA

Myxomas are slowly growing benign neoplasms which are rare in children. Up to 80% can be located in the left atrium and generate symptoms such as embolism, cardiac failure, fever and weight loss. Rarely, myxomas can be detected in the right ventricle outflow tract, causing arrhythmias, pulmonary emboli and sudden death. We report the case of a 13-year-old healthy child brought to the Emergency Department (ED) of the Children's Hospital Bambino Gesù, Rome, for recent dyspnea, chest pain on exertion and new onset cardiac murmur. Patient underwent medical examination and echocardiogram with the finding of a rounded and lobulated voluminous mass in the right ventricle outflow tract (RVOT) which caused severe obstruction. The contrast computed tomography (CT) scan confirmed the presence of a heterogeneously enhancing soft-tissue mass occupying the RVOT with no evidence of pulmonary embolization. The mass was surgically excised, and the pathologic examination confirmed our suspicion of myxoma. Our experience suggests that myxoma can have mild clinical symptoms, the presentation may be non-specific, and diagnosis can be a challenge. Careful examination and a diagnostic imaging workup, primarily with the transthoracic echocardiogram, are needful to make a rapid differential diagnosis and to better manage surgical treatment and follow-up.
References
Int J Environ Res Public Health. 2022 Oct 8;19(19):12888.

IPERTENSIONE ARTERIOSA

A710: DKK3 UNA NUOVA GLICOPROTEINA IN GRRADO DI MODULARE I LIVELLI DI PRESSIONE ARTERIOSA IN MODELLI SPERIMENTALI ATTRAVERSO L'ASSE VEGF/AKT/ENOS

Albino Carrizzo (a, b), Carla Busceti (b), Paola Di Pietro (a), Antonio Damato (b), Michele Ciccarelli (a), Sebastiano Sciarretta (c), Massimo Volpe (c), Speranza Rubattu (b, c), Ferdinando Nicoletti (b, c), Carmine Vecchione (b, c)
(a) UNIVERSITÀ DEGLI STUDI DI SALERNO; (b) IRCCS NEUROMED; (c) UNIVERSITÀ LA SAPIENZA DI ROMA

Dickkopf-3 (Dkk3) è una glicoproteina secreta nota per la sua attività pro-apoptotica e angiogenica. Il ruolo di Dkk3 nell'omeostasi cardiovascolare è in gran parte sconosciuto. È interessante notare che il gene Dkk-3 mappa all'interno di un segmento cromosomico legato al fenotipo ipertensivo nei ratti spontaneamente ipertesi (SHR). Abbiamo utilizzato topi Dkk3-/- e ratti SHR resistenti all'ictus (sr) e a rischio di ictus (sp) per esaminare il ruolo di Dkk3 nella regolazione della pressione sanguigna (BP). Abbiamo utilizzato vettori lentivirali (LV) per indurre l'espressione di Dkk3 nei topi knockout o per indurre la sovraespressione o il silenziamento di Dkk3 nei modelli di ratti SHR. La delezione genetica di Dkk3 nei modelli murini ha generato un aumento della pressione arteriosa ed ha evocato la compromissione della vasodilatazione endotelio-dipendente indotto dall'acetilcolina nelle arterie mesenteriche di resistenza. Queste alterazioni sono state ripristinate recuperando l'espressione di Dkk3 sia in periferia che nel sistema nervoso centrale (SNC). Dkk3 era necessaria per l'espressione costitutiva del fattore di crescita vascolare endoteliale (VEGF) e l'azione di Dkk3 sulla BP e sulla vasorilassazione endotelio-dipendente era mediata dalla via della fosfatidilinositolo-3-chinasi stimolata da VEGF, che portava all'attivazione dell'ossido nitrico sintasi endoteliale (eNOS) sia nelle arterie di resistenza che nel SNC. La funzione regolatoria di Dkk3 sulla BP è stata confermata in SHRsr e SHRsp, in cui è stato dimostrato che sia l'overespressione periferica che nel tronco encefalico erano in grado di normalizzare i livelli pressori. Negli SHRsr, l'espressione di Dkk3 indotta dal lentivirus (LV) nel SNC ha ridotto in larga misura la BP, mentre il knock-down di Dkk3 ha ulteriormente aumentato i livelli di pressione arteriosa. Negli SHRsp sottoposti a dieta ipersodica, l'espressione di Dkk3 indotta da LV nel SNC ha mostrato un sostanziale effetto antipertensivo e ha ritardato l'insorgenza di ictus. Questi risultati dimostrano che Dkk3 agisce come regolatore periferico e centrale della pressione arteriosa promuovendo l'espressione di VEGF e attivando l'asse ipotensivo VEGF/Akt/eNOS.

A711: CARDIOLOGICA HYPERTENSIVE EMERGENCIES: REAL WORLD DATA COMPARED TO GUIDELINES INDICATIONS

Alessandro Maloberti (a, b), Rita Cristina Myriam Intravaia (a), Chiara Tognola (a, b), Lorenzo De Censi (b), Andrian Elisa (b), Michele Galasso (a), Michela Algeri (a), Valentina Colombo (a), Cristina Giannattasio (a, b)
(a) CARDIOLOGY IV, "DE GASPERIS" DEPARTMENT, NIGUARDA CA' GRANDA HOSPITAL, MILAN ITALY; (b) SCHOOL OF MEDICINE AND SURGERY, MILANO-BICOCCA UNIVERSITY, MILAN ITALY

Background. The 2018 ESH guidelines have revised the therapeutic goals of cardiological Hypertensive Emergencies (HE) with an indication for a more intensive (target <140/90 mmHg) and rapid (immediate) Blood Pressure (BP) reduction. Cardiac acute organ damage during HE includes acute myocardial infarction, pulmonary edema, unstable angina pectoris and aortic dissection. However, how much these indications have been applied in clinical practice to date it's unknown.
Aims. The first purpose of our study is to analyze the prevalence and clinical characteristics of cardiological HE in our institution. The second purpose is to compare the year before the release of the 2018 guidelines (2017) with the subsequent years (2019) trying to verify adherence to guidelines.
Methods. This is a single-center retrospective study conducted at the Niguarda Hospital. All patients aged ≥18 years with Systolic BP≥180 mmHg and/or a Diastolic BP ≥120 mmHg with Cardiological Emergency were enrolled. From the Emergency Department (ED) data clinical, anamnestic, blood pressure, symptoms, drug treatment and target achievement were registered.
Results. Patients with BP>180/120 mmHg in 2017 were 706 out of a total of 73795 accesses (0.96%) and 601 over 67273 (0.89%) in 2019. 246 (34.84%) in 2017 were HE of which 144 (58.53%) were cardiological: aortic dissection 1 (0.69%), acute coronary syndrome 52 (36.11%), acute pulmonary edema 35 (24.30%), cardiac decompensation 91 (63.19%). During 2019 similar figures were founded with 286 (47.58%) HE of which 286 (47.58%) were cardiological: aortic dissection 2 (1.43%), acute coronary syndrome 43 (30.93%), acute pulmonary edema 20 (14.39%), cardiac decompensation 76 (54.68%). The reduction in BP obtained in ED was significantly greater in 2017 than in 2019 (44.7±31.4 vs 35.4±24.5 mmHg, p=0.011) with a lower target reaching in 2019 (28.9 vs 51.4%, p<0.001). Pulmonary edema is the cardiological HE on which a greater pressure reduction is obtained and therefore in which the target set by the guidelines is more frequently reached.
Conclusions. The recommendation for a more intense and rapid BP reduction in cardiological HE seems to be not accepted from ED clinicians that persist to reduce BP accordingly to previous guidelines.

A712: ACUPUNCTURE IN ARTERIAL HYPERTENSION: EVALUATION OF ITS EFFICACY WITH BOTH OFFICE AND AMBULATORY BLOOD PRESSURE MEASUREMENT

Cristina Migliarese (a), Alessandro Maloberti (a, b), Rita Cristina Myriam Intravaia (a), Chiara Tognola (a, b), Roberto Gatto (c), Michela Algeri (a), Elena Gualini (a), Cristina Giannattasio (a, b)
(a) CARDIOLOGY IV, "A. DE GASPERIS" DEPARTMENT, OSPEDALE NIGUARDA CA' GRANDA, MILAN ITALY; (b) SCHOOL OF MEDICINE AND SURGERY, MILANO-BICOCCA UNIVERSITY, MILAN ITALY; (c) CENTRO STUDI SO WEN ETS, MILAN ITALY

Introduction. A possible alternative to pharmacological antihypertensive therapies in grade 1 low risk hypertensive patients or in those experienced drugs adverse effects could be acupuncture.
Aim. We focused on its possible effects on BP both as Office BP (OBP) and as Ambulatory BP Monitoring (ABPM) evaluating it before starting a 6 weeks twice weekly (total 12 session) acupuncture cycle and after 2 months from its completion.

Methods. In this prospective study we treated with acupuncture 45 patients: 24 of them presents high-normal BP values and low cardiovascular risk while 21 patients were on anti-hypertensive drug with slightly uncontrolled BP values (from 140 to 145 mmHg for Systolic BP – SBP – and/or from 90 to 95 mmHg for Diastolic BP – DBP).
Results. Regarding SBP, a significant reduction have been observed for office values (from 134.2±15.7 to 125.1±12.2, p=0.03), and for ABPM 24h (from 131.1±10.7 to 126.0±10.1, p=0.01) and day-time values (from 134.7±10.5 to 127.1±18.4, p=0.02). For DBP, only ABPM 24h and day-time values showed significant changes (from 85.3±9.1 to 82.1±7.5, p=0.03; and from 88.5±9.3 to 85.7±7.8, p=0.02). Within session SBP decrease was -5.8 mmHg (-3.75%) during the first session while it falls to -2.1 mmHg (-1.25%) and stands firmly under 2 mmHg for all the next session. At the last session SBP reduction was -1.9 mmHg (-1.6%).
Conclusions. We found a significant reduction in office, 24h and day-time ABPM SBP determined by a 6-weeks twice weekly acupuncture cycle that lasts at least for the first two months after its completion.

MALATTIE DEI VASI

A713: PREDICTIVE ROLE OF LEFT VENTRICULAR GLOBAL LONGITUDINAL STRAIN IN PATIENTS UNDERGOING CAROTID ARTERY STENTING

Dalila Nappa (a), Federica Ilardi (a), Rachele Manzo (a), Andrea Mariani (a), Domenico Angellotti (a), Maddalena Immobile Molaro (a), Domenico Simone Castiello (a), Giulia Sgherzi (a), Fiorenzo Simonetti (a), Ciro Santoro (a), Marisa Avvedimento (a), Raffaele Piccolo (a), Anna Franzone (a), Eugenio Stabile (b), Giovanni Esposito (a)
(a) UNIVERSITY OF NAPLES FEDERICO II; (b) AZIENDA OSPEDALIERA REGIONALE SAN CARLO DI POTENZA

Background. Atherosclerosis is a systemic vascular disorder and frequently involves more vascular beds within the same patient. A strong correlation between carotid obstructive disease (COD) and coronary artery disease (CAD) has been described. Detection and treatment of preclinical CAD in patients with COD may improve long-term outcomes and survival. Left ventricular (LV) global longitudinal strain (GLS) is a sensitive echocardiographic tool in the discrimination of significant CAD even in the absence of wall motion abnormalities. However, the predictive role of reduced GLS in COD patients is still unknown.
Purpose. This prospective study aims to investigate the utility of GLS to predict CAD in a cohort of patients with preserved systolic function, without history of myocardial revascularization, and significant carotid artery disease undergoing carotid artery stenting (CAS).
Methods. All patients underwent echocardiographic assessment before angiography, including GLS analysis. Angiograms were interpreted by experienced operators, blinded to the results of the echocardiographic examinations. History of CAD, LVEF <50%, resting wall motion abnormalities, cardiomyopathies, moderate-to-severe valvular heart disease, left bundle-branch block and suboptimal quality of speckle-tracking analysis were identified as exclusion criteria.
Results. Of 125 patients scheduled for CAS, a total of 36 patients (mean age 69.7 ± 9.6 years, 52.8% males) with COD and preserved LVEF (>50%) were enrolled. After coronary angiography, CAD was detected in 18 (50%) patients (55.6% one-vessel, 33.3% two-vessels, 11.1% three-vessels disease). Significant lower GLS was observed in CAD patients, compared to those without CAD (20.1 ± 3.5% vs 22.4 ± 2.6%, p=0.037), despite comparable values of LVEF (60.3 ± 4.3% vs 61.2 ± 3.1%, p=0.457). At ROC curve analysis, the best GLS value associated with significant CAD was 19.8% (sensitivity 50%, specificity 88%, area under the curve=0.704, p=0.037]. We found that GLS>19.8% was able to discriminate 61.5% of patients with a normal coronary tree, while 80% of patients with impaired GLS had significant CAD at coronary angiography. Moreover, GLS reduction in CAD patients was progressive with increasing vessels affected (p=0.004) (Figure).
Conclusions. Although CAD may still be present in a small amount of patients with GLS values within the normal range, a value ≤19.8% identifies with 88% of specificity and positive predictive value those who should undergo CA before carotid stenosis treatment because at high risk of CAD. Its non-invasiveness, high reproducibility and broad availability make GLS a reliable tool for CAD screening in COD population.

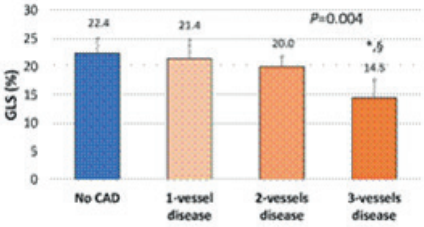

A714: RVOT COMPRESSION BY RIGHT VALSALVA SINUS ANEURYSM

Mirella Ricci (a), Mario Di Marino (a), Kristian Galanti (a), Lorenzo Molinari (a), Cesare Mantini (a), Martina Primavera (b), Massimo Di Marco (b), Leonardo Paloscia (b), Umberto Benedetto (a), Fabrizio Ricci (a), Giulia Renda (a), Sabina Gallina (a)
(a) DEPARTMENT OF NEUROSCIENCE, IMAGING AND CLINICAL SCIENCE, "G. D'ANNUNZIO" UNIVERSITY, CHIETI-PESCARA, ITALY; (b) CARDIOLOGY AND ICCU DEPARTMENT, SANTO SPIRITO HOSPITAL, PESCARA, ITALY

A 77-year-old Caucasian man with history of hypertension and type 2 diabetes presented to the emergency department for recurrent syncope spells. ECG documented an anterior ST segment elevation myocardial infarction and a 2:1 AV infra-Hisian block. A transthoracic echocardiogram (TTE) showed significantly reduced left ventricular function (EF 45%), related to apical akinesia and hypokinesia of the anterior wall, mild mitral regurgitation, moderate aortic and tricuspid regurgitation, and a large right sinus of Valsalva aneursym (RSOVA)(Fig.A). Coronary angiography showed total occlusion of left anterior descending artery as the culprit lesion treated with a drug-eluting stent. Due to refractory AV block, a pacemaker was implanted. Cardiac CT confirmed the presence of a large, thin-walled RSOVA displacing the right coronary artery, yet without compressing nearby structures (Fig.B-D, 3D reconstruction). The Heart team evaluated the case and the surgeon successfully performed a modified Bentall procedure. In the first post-operative day a VV-ECMO was positioned due to concurrent pneumonia and hemodynamic instability. Postoperative TTE revealed dilated right ventricle, reduced indices of RV function (TAPSE 10 mm, RVS' 7 cm/s, FAC 25%), severe tricuspid regurgitation, D-shaped interventricular septum in keeping with RV overload and pulmonary hypertension (PAPs 70 mmHg). These echocardiographic findings were related to a dynamic RVOT obstruction (PG 54 mmHg, Vmax 3.6 m/s, also confirmed by invasive tight heart catheterisation, and due to recurrent swelling of the RSOVA (Fig. E and F). A further procedure was performed to evacuate the essudative, sero-hematic content of the aneurysm, followed by definitive closure using surgical glue. Repeat TTE confirmed the effectiveness of the surgery, resulting in the extinction of the dynamic obstruction. (Fig. E and F). The surgeon drained again the aneurysm also using Redon drain to facilitate sero-hematocrit fluid removal and sealed it with surgical glue, eventually resolving the RVOT obstruction.

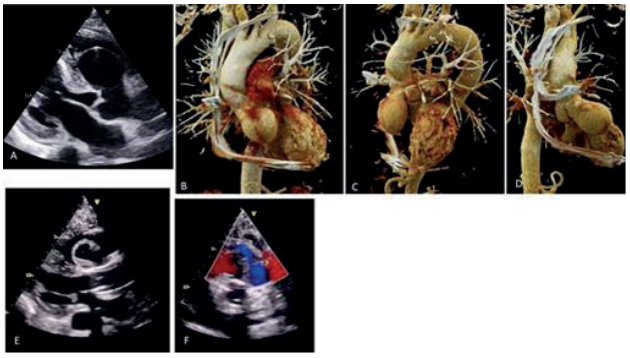

A715: SYSTEMIC ACUTE VENOUS THROMBOEMBOLIC DISEASE: FOCUS ON PATIENTS SEEN BY CARDIOLOGISTS

Paolo Costa (a), Eugenio Sessarego (a), Alessandro Troccolo (a), Luca Barca (a), Veronica Vecchiato (a), Matteo Sarocchi (b), Paolo Spallarossa (b), Pietro Ameri (b), Roberta Della Bona (b), Italo Porto (b), Giorgio Ghigliotti (b)
(a) CHAIR OF CARDIOVASCULAR DISEASES, DEPT. OF INTERNAL MEDICINE AND SPECIALTIES (DI.M.I.), UNIVERSITY OF GENOVA, ITALY; (b) CHAIR OF CARDIOVASCULAR DISEASES, DEPT. OF INTERNAL MEDICINE AND SPECIALTIES (DI.M.I.), UNIVERSITY OF GENOVA, ITALY AND CARDIOLOGY UNIT, CARDIOTHORACIC AND VASCULAR DEPT., IRCCS OSPEDALE POLICLINICO SAN MARTINO, GENOVA, ITALY

Background. Venous thromboembolic disease (VTE) is a leading cause of Cardiovascular mortality.Treatment strategies for this condition are described in Guidelines, but single Centers may differently apply them. Recently for mostly inherited thrombophilias the advice has been given for "no testing anymore" in most situations of VTE.
Objectives. To investigate: 1) VTE-type distribution (Unprovoked, Provoked, K-associated); 2) frequency of Triggers and of comorbidities, levels of Cardiac Biomarkers in relation to the three subsets of VTE; 3) features associated to use of Lytic therapy (LT), 4) search for thrombophilia and 5) prevalence of RF associated to potential CETPH development.
Methods. Single Center Retrospective study in 145 VTE Pts admitted in the Cardiology Ward of our Policlinic Hospital (2016-2021). In addition to VTE-type, our Pts were also subdivided in Low Risk (LR), Int. Low/High (Int LR/IntHR) and High Risk Groups (HR) of early death (30 days) according to 2019 ESC Guidelines. True candidates for advanced diagnostic

work-up for CETPH are selected with the use of the CTEPH prediction score of Klok.
Results. Median Age (IQ) of our Pts was 73 (58.8-81.3), 54.5% were males. 12 (8.3%) belongs to HR, 84 (57.9%) to Int. HR, 40 (27.6%) to Int.LR and 9 (6.2%) to LR. Seventy-three (50.3%), 56 (38.6%) and 16 (11.1%) VTE pts belonged to Unprovoked, Provoked, K-associated Groups. VTE triggers frequently reported: Age>70 (58%), High TnI, pro-BNP, D-dimer levels and low EF were associated to the HR Groups (intHR and HR). LT was performed in 16.6% of Pts: 58.3% coming from the HR, 16,7% coming from the HR, 7.5% coming from the LR Group. The search of FV Leiden (31.9%), Prothrombin G20210A (29.8%) and APL Ab (32.6%) is similarly distributed between Unprovoked and Provoked VTE. Comparing two temporal windows (2016-2018 vd 2019-2021): search for FV Leiden (36.3% vs 26.2%) and for Prothrombin G20210A (32.5% vs 26.1%) decreased and search for APL Ab (17.5% vs 50.7%) increased. Regarding potential CETPH development, Klok score>6 was present only in the unprovoked subgroup (63.4% of pts within this subgroup).
Conclusions. Unprovoked VTE represents the most frequent type of VTE in our Cardiology ward. Mostly of our VTE Pts are aged and belong to a HR/Int HR Group. LT is not restricted to HR Pts, suggesting that signs of RV dysfunction and clinical gestalt play a role for the choice to deliver this drug. Search for FV Leiden and for Prothrombin G20210A is still frequent (one out of four VTE pts) and is not restricted to Unprovoked VTE subset. CETPH screening in follow-up should be proposed for the subset with unprovoked TEP.

A716: THROMBOPROPHYLAXIS RATES AMONG ACUTELY ILL MEDICAL PATIENTS: THE ITALIAN EXPERIENCE

Enrico Maggio (a), Gianpaolo Vidili (b), Angela Sciacqua (c), Chiara Cogliati (d), Rosella Di Giulio (e), Sciaila Bernardini (f), Paolo Ciacci (a), Federica Orlando (a), Ilaria Maria Palumbo (a), Arianna Pannunzio (a), Arianna Magna (a), Chiara Bagnato (a), Cristina Caltabiano (a), Chiara Schipa (a), Maria Boddi (g), Giovanni Di Minno (h), Lorenzo Falsetti (i), Evaristo Ettorre (a), Pasquale Pignatelli (a), Francesco Violi (a), Lorenzo Loffredo (a)
(a) DEPARTMENT OF CLINICAL INTERNAL, ANESTHESIOLOGICAL AND CARDIOVASCULAR SCIENCES, SAPIENZA UNIVERSITY OF ROME, VIALE DEL POLICLINICO 155, 00161 ROME; (b) DEPARTMENT OF CLINICAL AND EXPERIMENTAL MEDICINE, UNIVERSITY OF SASSARI. SASSARI, ITALY; (c) DEPARTMENT OF MEDICAL AND SURGICAL SCIENCES, UNIVERSITY MAGNA-GRAECIA OF CATANZARO, CATANZARO, ITALY; (d) DEPARTMENT OF BIOMEDICAL AND CLINICAL SCIENCES, L. SACCO HOSPITAL, ASST FATEBENEFRATELLI SACCO, UNIVERSITY OF MILAN, MILAN, ITALY; (e) DEPARTMENT OF INTERNAL MEDICINE, INTERNAL MEDICINE UNIT, MAGGIORE HOSPITAL, BOLOGNA, ITALY; (f) DEPARTMENT OF INTERNAL MEDICINE, AUSL DELLA ROMAGNA, S. MARIA DELLE CROCI HOSPITAL, 48121, RAVENNA, ITALY; (g) EXPERIMENTAL AND CLINICAL DEPARTMENT, UNIVERSITY OF FLORENCE, FLORENCE, ITALY; (h) DEPARTMENT OF CLINICAL MEDICINE AND SURGERY, FEDERICO II UNIVERSITY, NAPLES, ITALY; (i) INTERNAL AND SUB-INTENSIVE MEDICINE DEPARTMENT, A.O.U. "OSPEDALI RIUNITI", ANCONA, ITALY
Background. Randomized controlled trials have demonstrated the effectiveness of thromboprophylaxis in hospitalized medical patients with a high cardiovascular risk. Limited data are available regarding the prevalence of patients receiving prophylactic doses of anticoagulants in real-world settings. The objective of this study is to evaluate the incidence of thromboprophylaxis in hospitalized patients
Methods. We conducted a prospective observational study to assess the risk factors associated with DVT in acutely ill hospitalized medical patients upon admission and discharge. We performed compression ultrasonography (CUS) on proximal lower limb veins within 48 hours of admission and at discharge to identify DVT cases. Patients with COVID-19, those receiving anticoagulant therapy, undergoing surgical procedures, diagnosed with acute symptomatic DVT (SDVT), or acute pulmonary embolism were excluded. We collected patient demographics upon hospitalization, IMPROVE scores, and/or PADUA scores. High risk patients were defined according IMPROVE≥3 or PADUA score ≥4.
Results. Out of 2248 patients (1160 males, 1088 females; mean age 71 ± 16 years), 1056 (47%) exhibited a high thrombotic risk profile. The median length of hospitalization was 13 ± 12 days. 272 out of 1056 high risk patients (25,8%) and 69 out of 1183 low risk patients (5,8%) undergone on anticoagulant prophylaxis. Patients receiving anticoagulant prophylaxis were older, had longer hospital stays and higher levels of IMPROVE score and PADUA score. Additionally, they experienced a higher incidence of heart or respiratory failure, pneumonia, and reduced mobility. A logistic regression analysis revealed that age, neoplasia, reduced mobility, heart or respiratory failure and pneumonia were independently associated with the anticoagulant prophylaxis. Notably, during their hospital stay, a total of 16 patients (0,7%) with negative CUS results at admission developed DVT; 12 out of these 16 patients were at high risk and only 4 of these 12 patients were treated with anticoagulant thromboprophylaxis.
Conclusions. This study demonstrates that a small percentage of high-risk patients receive prophylactic doses of anticoagulants during their hospitalization for acute medical conditions.

Age	RR: 1,012	IC 95% 1,002-1,022	**0,014**
Neoplasia	RR: 1,599	IC 95% 1,160-2,179	**0,004**
Reduced mobility	RR: 5,357	IC 95% 4,087-7,021	**<0,0001**
Heart or respiratory failure	RR: 1,437	IC 95% 1,077-1,917	**0,014**
Pneumonia	RR: 1,562	IC 95% 1,139-2,142	**0,006**

A717: FIRST CASE OF INTRAMURAL HEMATOMA AND CONCOMITANT PULMONARY EMBOLSIM AFTER PACEMAKER IMPLANTATION: A CASE REPORT

Guido Del Monaco (a, b), Antonio Taormina (a),
Alessandro Giaj Levra (a, b), Lorenzo Monti (a), Antonio Frontera (a)
(a) CARDIO CENTER, HUMANITAS RESEARCH HOSPITAL, 20089, ROZZANO (MI); (b) DEPARTEMENT OF BIOMEDICAL SCIENCES, HUMANITAS UNIVERSITY, 20090, PIEVE EMANUELE (MI)
A 67-year-old female presented to the emergency department for syncope. 12-lead ECG at admission revealed junctional rhythm at 46 bpm. The patient had no reversible causes of AV block, therefore she underwent pacemaker implantation. At the first attempt of subclavian vein puncture, the patient experienced transient back pain while advancing the guidewire, thereby the needle and the wire were immediately removed. Vital signs remained stable. The following procedure was successful and two-chamber pacemaker was placed. Postoperatively, the patient reported dyspnea and chest pain. The patient was immediately brought to perform a chest CT scan (Figure) which showed left pleural effusion with hematic density and a new-onset aortic intramural hematoma (IMH) without any active bleeding source. Additionally, pulmonary embolism (PE) in the right inferior lobar artery was detected. No signs of hemodynamic instability were present. Bed-side echocardiography didn't show right ventricular failure nor dilation. Due to the presence of bleeding complications, anticoagulant therapy at optimal dosage could not be started to treat PE. Therefore, an inferior vena cava filter was placed. After multidisciplinary consultation considering hemodynamic stability and high surgical risk, IMH was treated conservatively. Periodical CT scans showed a gradual resolution of IMH and pulmonary embolism. The patient was discharged after three weeks, asymptomatic and in stable clinical condition. At two-months CT-scan performed from discharge, IMH appeared completely resolved.

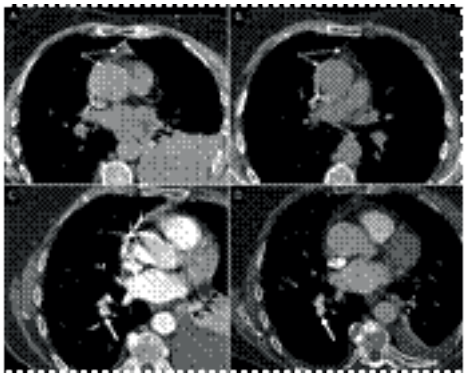

Figure. Panel A and C: acute phase; Panel B and D: 2 months follow-up. A: high attenuation and thickening of the aortic wall (about 3- 3,5 mm) associate with fat stranding of the periaortic anterior fat (dotted arrows). In B and D (2 months follow-up) the aortic wall is normal and the fat attenuation is almost normalized.

A718: PREVALENCE OF LEFT MAMMARY ATERTY DISEASE IN PATIENTS UNDERGOING CORONARY ANGIOGRAPHY FOR SUSPECTED CORONARY ARTERY DISEASE: A META-ANALYSIS AND META-REGRESSION STUDY.

Luca Siega Vignut (a, b), Federico Angriman (a, b), Massimo Imazio (b)
(a) POSTGRADUATE SCHOOL OF CARDIOVASCULAR MEDICINE UNIVERSITY OF TRIESTE; (b) DEPARTMENT OF CARDIOLOGY, AZIENDA SANITARIA UNIVERSITARIA FRIULI CENTRALE, UDINE. ITALY
Objectives. Left internal mammary artery (LIMA) to bypass the left anterior descending artery has demonstrated to improve survival in multivessel coronary artery disease, but its routine selective angiography during index coronary angiography is seldom performed as LIMA is rarely diseased. The aim of this study is to evaluate the prevalence of LIMA disease in patients undergoing coronary angiography for suspected coronary artery disease and to appraise possible predictors.
Methods. A systematic literature review and meta-analysis was conducted using PubMed and Cochrane databases. All studies reporting prevalence of LIMA disease in patients undergoing coronary angiography for suspected coronary artery disease were included. The primary endpoint was the prevalence of LIMA disease while secondary endpoints

were the prevalence of left subclavian artery disease, adjunctive contrast medium administration, fluoroscopy time and complication rates. Meta-regression analysis was performed on the primary endpoint.
Results. Of the 2300 studies published until May 2023, 10 studies for a total of 1475 patients were included. LIMA disease prevalence was 1.8% (95% CI; 1.2%-2.7%) in the entire cohort, whereas we reported a rate of subclavian artery disease of 7.6% (95% CI, 6-9.5%). At univariate meta-regression analysis, only age was directly correlated with LIMA disease (β 0.0814; 95% CI, 0.0002-0.1626; p=0.049)
Conclusions. LIMA was found to be diseased in 1.8% of the observed cohort. No significant correlation was found between LIMA pathology and classic risk factors for atherosclerosis, exception made for age. Due to the low level of predictability of the disease, the ease of the procedure and its relative safety, LIMA angiographic assessment might be considered in selected patients candidate to CABG at older age.

A719: ECTASIA CORONARICA. QUALE È IL GIUSTO APPROCCIO?

Donatella Tansella (a), Davide Betta (b)
(a) UNIVERSITÀ DEGLI STUDI DI PADOVA; (b) OSPEDALE CA' FONCELLO TREVISO

L'ectasia coronarica è una dilatazione delle arterie coronarie, in cui il diametro dell'arteria è ≥1.5 volte maggiore rispetto a quello del segmento vascolare integro adiacente e viene coinvolto il vaso per più del 50% della sua lunghezza. Il meccanismo eziopatogenetico sottostante non è ancora del tutto chiarito; negli adulti la patologia è causata soprattutto dall'aterosclerosi coronarica o dal danno di parete provocato dall'impianto di stent. Cause più rare sono: uso di cocaina, infezioni sistemiche, probabilmente anche la suscettibilità genetica gioca un ruolo importante e i processi infiammatori cronici con attivazione di metalloproteasi e rimodellamento della tonaca vascolare. È stata dimostrata una stretta associazione tra ectasia coronarica e sindrome coronarica acuta; in questo contesto le scelte interventistico-terapeutiche sono ancora motivo di ampio dibattito e il trattamento va individualizzato in base alle caratteristiche fenotipiche del singolo paziente. Uomo di 63 anni, senza precedenti cardiologici di rilevo allertava il 118 per dolore toracico da sforzo, gravativo retrosternale, irradiato al giugulo. All'ECG evidenza di sopraST nelle derivazioni inferiori, motivo per cui il paziente veniva centralizzato presso il nostro nosocomio. In ecoscopia acinesia della parete infero-posteriore medio apicale, FE 40%. Picco di TnI 1800 ng/L. Alla coronarografia riscontro di ampia ectasia della coronaria destra che appariva occlusa al tratto prossimale-medio, veniva quindi eseguita tromboaspirazione efficace con recupero della pervietà del vaso con somministrazione di Tirofiban ev. Si procedeva successivamente a sospensione di Tirofiban, somministrazione di Aspirina e Clopidogrel e infusione di eparina, successivamente shiftata a Coumadin. A differenza della malattia coronarica aterosclerotica, i dati relativi alle opzioni terapeutiche nei pazienti con patologia ectasiante sono pochi. Il trattamento non è stato ancora sufficientemente studiato e strandardizzato. È ragionevole ipotizzare che gli eventi coronarici siano da attribuire all'occlusione trombotica del vaso aneurismatico e/o alla diffusa e ripetuta microembolizzazione nei segmenti più distali, quindi la terapia antiaggregante piastrinica è consigliabile in tutti i casi di ectasia coronarica; il dilemma del clinico rimane l'uso di farmaci anticoagulanti. Alcuni studi hanno dimostrato una riduzione della ricorrenza di eventi nei pazienti trattati anche con anticoagulanti. È pratica comune riservare tale trattamento ai pazienti a rischio più elevato (es. malattia multivasale o ricorrenza di eventi nonostante duplice terapia antiaggregante). Riconoscendo i limiti delle attuali conoscenze in merito all'ectasia coronarica, l'approccio va individualizzato sulla base dei rischi e benefici.

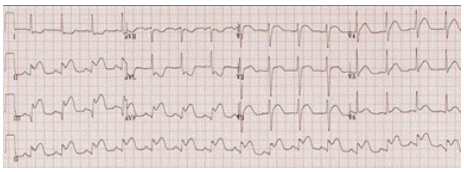

MALATTIE DEL MIOCARDIO E DEL PERICARDIO

A720: LONG-TERM EFFICACY AND SAFETY OF TAILORED PROLONGED IMMUNOSUPPRESSIVE THERAPY IN BIOPSY-PROVEN IMMUNE-MEDIATED MYOCARDITIS: A SINGLE CENTER PROPENSITY WEIGHTED STUDY

Andrea S. Giordani (a), Anna Baritussio (a), Davide Marcolongo (a), Cristina Vicenzetto (a), Giuseppe Tarantini (a), Massimo Napodano (a), Giuseppe Toscano (d), Dario Gregori (b), Gloria Brigiari (b), Patrizia Bartolotta (b), Monica De Gaspari (c), Cristina Basso (c), Sabino Iliceto (a), Alida Lp Caforio (a), Renzo Marcolongo (a)
(a) CARDIOLOGIA, DIPARTIMENTO DI SCIENZE CARDIO-TORACO-VASCOLARI E SANITÀ PUBBLICA, UNIVERSITÀ DI PADOVA; (b) STATISTICA, DIPARTIMENTO DI SCIENZE STATISTICHE, UNIVERSITÀ DI PADOVA; (c) PATOLOGIA CARDIOVASCOLARE, DIPARTIMENTO DI SCIENZE CARDIO-TORACO-VASCOLARI E SANITÀ PUBBLICA, UNIVERSITÀ DI PADOVA; (d) CARDIOCHIRURGIA, DIPARTIMENTO DI SCIENZE CARDIO-TORACO-VASCOLARI E SANITÀ PUBBLICA, UNIVERSITÀ DI PADOVA

Background. Standardized regimens of immunosuppressive therapy (IS) in biopsy-proven (BP) lymphocytic myocarditis with heart failure (HF) were effective in small trials.
Aim. To evaluate tailored and prolonged IS efficacy and safety in a cohort of BP immune-mediated myocarditis patients, irrespective of histology and clinical presentation.
Methods. Consecutive BP myocarditis patients treated with a long-term (median 20 months) tailored IS on top of optimal medical therapy (OMT) were compared with a propensity score-weighted control group of OMT non-IS patients, considering age, gender, left ventricular ejection fraction (LVEF), New York Heart Association (NYHA) class and histology. The primary outcome was a composite of death or heart transplant (HTx) and the secondary one a composite of variation of biventricular function, NYHA class and myocarditis relapse.
Results. 91 IS patients were compared with 267 non-IS patients. IS patients more frequently had an extra-cardiac immune-mediated disease (35% vs 9.7%, p<0.001), lower baseline LVEF (on echocardiography 35% vs 43%, p=0.01, cardiac magnetic resonance 28% vs 47%, p=0.037, on cardiac catheterization 33% vs 44%, p=0.023, respectively), lower right ventricular fractional area change (34% vs 41%, p<0.001) and higher frequency of active lymphocytic, eosinophilic and giant cell myocarditis (71% vs 58%, p<0.001, 12% vs 1.1%, p<0.001, and 6.6% vs 1.5%, p<0.001) compared to non-IS patients. Tailored IS mainly included prednisone and azathioprine as first-line (62%) and prednisone and mycophenolate mofetil as second-line therapy (61%). At long-term follow up, no difference was observed in the primary outcome between the two groups (5 years survival 93% in IS vs 87% in non-IS patients, p=0.31); IS patients presented similar biventricular function (Figure 1) and NYHA class to non-IS patients, despite having a higher relapse rate.
Conclusions. Prolonged tailored IS is effective and safe in BP immune-mediated myocarditis irrespective of histology and clinical presentation. IS patients, despite having lower biventricular function and a higher risk profile at baseline and a higher relapse rate, showed normalized biventricular function and a similar survival compared to their propensity-score weighted controls at long-term follow up.

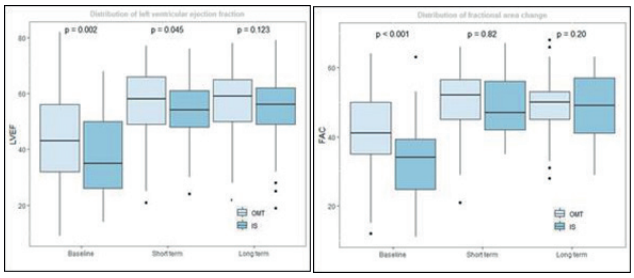

A721: EVALUATION OF DISEASE PROGRESSION IN PATIENTS WITH ATTR AMYLOIDOSIS WITH CARDIOMYOPATHY FOLLOWING TREATMENT WITH PATISIRAN: POST-HOC ANALYSIS OF THE APOLLO-B STUDY

Gianluigi Guida (a), Shaun Bender (b), Kelley Capocelli (b), Thibaud Damy (c), Brian Drachman (d), Mazen Hanna (e), Patrick Jay (b), Claudio Mesquita (f), Laura Obici (a), Michael Polydefkis (g), Zubair Shah (h), Pedro Vellosa-schwartzmann (i)
(a) AMYLOIDOSIS RESEARCH AND TREATMENT CENTER, IRCCS FONDAZIONE POLICLINICO SAN MATTEO; (b) ALNYLAM PHAMACEUTICALS, CAMBRIDGE, MA; (c) REFERRAL CENTER FOR CARDIAC AMYLOIDOSIS, HOPITAL HENRI MONDOR, CRETEIL, FRANCE; (d) DEPARTMENT OF CARDIOVASCULAR MEDICINE, PENN PRESBYTERIAN MEDICAL CENTRE, PHILADELPHIA, PA; (e) DEPARTMENT OF CARDIOVASCULAR MEDICINE, CLEVELAND CLINIC, CLEVELAND, OH; (f) HOSPITAL PRO-CARDIACO, NUCLEAR MEDICINE, RIO DE JANEIRO, BRAZIL; (g) DEPARMENT OF NEUROLOGY, JOHNS HOPKINS UNIVERSITY SCHOOL OF MEDICINE, BALTIMORE, MD; (h) DEPARTMENT OF CARDIOVASCULAR MEDICINE, UNIVERSITY OF KANSAS MEDICAL CENTER, KANSAS CITY, KS; (i) UNIMED HOSPITAL, RIBEIRAO PRETO, SAO PAULO, BRAZIL; ADVANCED RESEARCH CENTRE, CAPED, RIBEIRAO PRETO, SAO PAULO, BRAZIL

Introduction. Transthyretin-mediated (ATTR) amyloidosis is a progressive, fatal disease in which cardiac deposition of transthyretin (TTR) amyloid commonly manifests as cardiomyopathy. Patisiran, an RNA interference therapeutic that reduces TTR synthesis, is approved for the treatment of hereditary ATTR amyloidosis with polyneuropathy. The Phase 3 APOLLO-B study (NCT03997383) evaluated the clinical efficacy and safety of patisiran in patients with ATTR amyloidosis with cardiomyopathy (CM).
Purpose. This post-hoc analysis evaluated disease progression in APOLLO-B patients following treatment with patisiran vs placebo, based on the European Society of Cardiology (ESC) expert consensus on monitoring patients with ATTR amyloidosis with CM every 6–12 months using three domains: Clinical/Functional, Laboratory Biomarker, and Imaging/Electrocardiography (ECG).

Methods. Patients with ATTR amyloidosis with CM were randomized (1:1) to intravenous patisiran 0.3 mg/kg or placebo every 3 weeks for 12 months. Disease progression was defined at Month 12 (M12) relative to baseline using Clinical/Functional criteria (≥1 heart failure-related hospitalization, increased New York Heart Association class ≥1, decline in Kansas City Cardiomyopathy Questionnaire ≥5, or decline in 6-minute walk test ≥30 metres), Laboratory Biomarker criteria (increased N-terminal prohormone B-type natriuretic peptide ≥30% and absolute change ≥300 ng/L, troponin I ≥30%, or ATTR disease stage ≥1), and Imaging/ECG criteria (conduction disturbances or change in left ventricular wall thickness ≥2 mm, change in diastolic dysfunction grade ≥1, or change in systolic function measurements). One marker from each domain provides the minimum criteria for disease progression.
Results. At M12, the patisiran group (N=180) had improved odds of no disease progression compared with the placebo group (N=178; odds ratio [OR] 1.4; 95% confidence interval [CI] 0.77, 2.55). The patisiran group had benefits in Clinical and Functional markers vs placebo at M12 (OR 1.58; 95% CI 1.03, 2.42). Patisiran also showed favorable changes in Laboratory Biomarkers vs placebo at M12 (OR 2.14; 95% CI 1.33, 3.43) and a favorable trend in Imaging assessments/ECG vs placebo at M12 (OR 1.31; 95% CI 0.80, 2.15).
Conclusions. In this post-hoc analysis of APOLLO-B, fewer patisiran-treated patients had disease progression with respect to clinical, functional, and biomarker parameters vs placebo. The risk of disease progression was lower by Clinical/Functional and Laboratory Biomarker composite criteria, and trended lower by individual criterion from the ESC consensus statement among patisiran-treated patients at 12 months vs placebo patients. Long-term follow-up will further assess the impact of patisiran in patients with ATTR amyloidosis with CM.

A722: EXCERCISE INTENSITY AND CARDIAC DISEASE DEVELOPMENT IN CARRIERS OF TITIN VARIANTS

Giulio Savonitto (a), Alessia Paldino (a), Martina Setti (a, c), Maria Perotto (a), Cinzia Radesich (a), Arianna Berra (b), Irena Tavcar (a), Marco Merlo (a), Matteo Dal Ferro (a), Gianfranco Sinagra (a)
(a) DIVISION OF CARDIOLOGY, CARDIOVASCULAR DEPARTMENT, ASUITS, TRIESTE, ITALY; (b) UNINERSITÀ DEGLI STUDI DI TRIESTE, FACOLTÀ DI MEDICINA E CHIRURGIA, TRIESTE, ITALY; (c) DEPARTMENT OF CARDIOLOGY, UNIVERSIITY OF VERONA, VERONA, ITALY

Background. While the exacerbating effect of physical exercise and its correlation with arrhythmic outcomes have been demonstrated for Arrhythmogenic Cardiomyopathy in the context of desmosomal variants, there is currently a lack of information regarding the impact of physical exercise on carriers of titin (TTN) variants.
Purpose. We aimed to investigate the relationship between exercise duration and intensity in the development of cardiac manifestation in subjects with a Likely Pathogenic (LP) or Pathogenic (P) variant of TTN.
Methods. We interviewed 117 LP/P TTN variants' carriers regarding their regular physical activity from youth until diagnosis (type of activity, hours/week, weeks/months, months/years, and number of years of excercise). Based on the median amount of METs per week, subjects were classified as High-intensity athletes (>24.5 METs/week) or No-High-intensity athletes (≤24.5 METs/week). We studied the relationship between exercise intensity and disease development (defined as ejection fraction (EF) <50%), age of disease onset, recording of ventricular arrhythmias at ECG-Holter [number of premature ventricular contractions (PVCs)/24h, ventricular couplets/24h, and non-sustained ventricular tachycardia (NSVT)/24h], electrocardiographic abnormalities (presence of left bundle branch block, right bundle branch block, Q waves, negative T waves), NYHA class, and the presence of late gadolinium enhancement (LGE) at cardiac magnetic resonance imaging (MRI).
Results. Among the 117 participants (74% male, mean age 44±16), 58 (50%) were High-intensity athletes, were more frequently male (85% vs. 15%, p=0.008) and presented with lower baseline heart rates (70 bpm vs. 77 bpm, p=0.047). At the time of diagnosis, there were no significant differences between the two groups in terms of age, presence of negative phenotypes, family history of sudden cardiac death, history of myocarditis, and alcohol abuse. Additionally, both the High-intensity and No-High-intensity groups exhibited similar baseline ECG abnormalities and NYHA class. There was no significant difference between the two groups regarding the development of systolic dysfunction (OR 0.780, 95%CI 0.367-1.657, P=0.519). ECG-Holter findings also showed no significant difference in the 24h quantity of PVCs (OR 0.638, 95%CI 0.216-1.882, P=0.416), ventricular couplets (OR 0.474, 95%CI 0.041-5.453, p=0.549), or NSVT (OR 0.452, 95%CI 0.038-5.399). The groups also exhibited a similar prevalence of LGE on MRI (OR 1.221, 95% CI 0.478-3.124, P=0.676). Comparable results were obtained when using median values for METs/year, METs/lifetime, and total exercise hours/lifetime as the division variables, or when categorizing patients based on the presence of ≥4 hours of vigorous exercise/week [≥1440 metabolic equivalents (METs×minutes/week)] for a minimum of 6 years.
Conclusions. In carriers of LP/P variants of TTN, engaging in highly intense physical activity does not significantly affect the age of onset of systolic dysfunction or the severity of presentation in terms of arrhythmic or structural aspects. Further studies will be needed to explore the relationship between intense physical exercise and hard survival endpoints in individuals carrying an LP/P TTN variant.

A723: CHARACTERISTCS OF PRESSURE/STRAIN LOOP DERIVED GLOBAL MYOCARDIAL WORK INDEX IN NON-OBSTRUCTIVE HYPERTROPHIC CARDIOMYOPATHY AND ATTR-WT CARDIAC AMYLOIDOSIS WITH PRESERVED EJECTION FRACTION: A PRELIMINARY REPORT

Giancarlo Trimarchi (a), Denise Cristiana Faro (b), Concetta Zito (a), Fabrizio De Gaetano (b), Mariapaola Campisi (a), Valentina Losi (b), Corrado Tamburino (b), Gianluca Di Bella (a), Ines Paola Monte (b), Cesare De Gregorio (a)
(a) DEPARTMENT OF CLINICAL AND EXPERIMENTAL MEDICINE, UNIVERSITY HOSPITAL OF MESSINA, MESSINA, ITALY; (b) DEPARTMENT OF SURGERY AND MEDICAL-SURGICAL SPECIALTIES, UNIVERSITY HOSPITAL OF CATANIA, CATANIA, ITALY

Objectives. Pathophysiology of hypertrophic cardiomyopathy (HCM) and transthyretin amyloid cardiomyopathy (ATTR-CM) are continuously under investigation. Those patients may present with a similar hypertrophic phenotype and between-disease differentiation can be challenging during the routine clinical investigation or conventional echocardiography. Speckle-tracking derived global longitudinal strain (GLS) allows better understanding left ventricular (LV) functional discrepancies, but it is a load-dependent marker. More recently, myocardial work (MW) has been suggested as an innovative ultrasound-derived tool that overcomes such limitation by the integrated pressure/strain loop analysis, providing novel functional indices. Among all these, we investigated the global work index (GWI), which is the total work performed from the mitral valve closure until its opening, plus isovolumetric contraction and relaxation, and the global constructive work (GCW), as the work performed during systole, included isovolumic muscle shortening and early relaxation lengthening, in both hypertrophic phenotypes, specifically in HCM vs ATTR patients with preserved LV ejection fraction (ATTRpEF).
Methods. Eighty-three patients, 29 with HCM (aged 57 ± 17 years) and 32 with ATTR-CM (aged 70 ± 11 years, 32% mutated, 68% wild-type, 72% males) in class NYHA 1 or 2 and similar degree of LV mass index, were investigated at two Clinical Centers (Messina and Catania University Hospitals) by strain-echocardiography.
Results. Based on the LVEF ≤0.50 (ATTRrEF) or>0.50 (ATTRpEF), 14 patients (44%) entered the former subgroup and 18 (56%) the latter one, respectively. Overall, GWI and GCW were higher in HCM than in ATTR-CM patients (p<0.001). Pairwise comparison demonstrated that GWI was significantly greater in HCM than in ATTRpEF patients (1,442±404 mm Hg% vs 1,175±322 mm Hg%, respectively), who showed just a mild difference in GCW (1,633±440 vs 1,420±355 mm Hg%, respectively) and GLS (-14+4 vs -13+3%, respectively) (Figure).
Conclusions. This preliminary study demonstrates that GWI (and GCW to a lesser extent) is more impaired than GLS alone in all ATTRpEF patients compared with non-obstructive HCM patients with similar hypertrophic phenotype. Main findings likely confirm the global functional impairment of ATTR-CM, worthy to be investigated in wider patient populations.

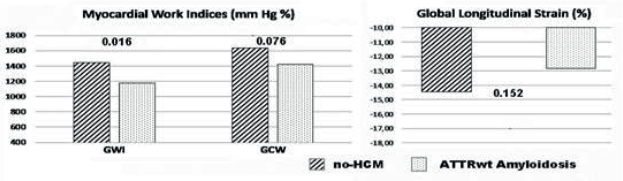

A724: CHARACTERIZATION AND NATURAL HISTORY OF RECURRENT MYOCARDITIS, A MULTICENTRIC INTERNATIONAL RETROSPECTIVE STUDY (REMYO)

Chiara Baggio (a), Giulio Savonitto (a), Valentino Collini (e), Piero Gentile (h), Jessica Artico (g), Raffaella Mistrulli (f), Maurits Sikking (d), Stephane Heymans (d), Annagrazia Cecere (b), Camillo Autore (f), Martina Perazzolo Marra (b), Massimo Imazio (e), Enrico Ammirati (h), Marco Merlo (c), Gianfranco Sinagra (c)
(a) POSTGRADUATED SCHOOL OF CARDIOVASCULAR MEDICINE UNIVERSITY OF TRIESTE, CENTRE FOR DIAGNOSIS AND TREATMENT OF CARDIOMYOPATHIES, CARDIOVASCULAR DEPARTMENT, AZIENDA SANITARIA UNIVERSITARIA GIULIANO ISONTINA (ASUGI), TRIESTE, ITALY; (b) DEPARTMENT OF CARDIAC, THORACIC AND VASCULAR SCIENCE AND PUBLIC HEALTH, UNIVERSITY OF PADUA, PADUA, ITALY; (c) CENTRE FOR DIAGNOSIS AND TREATMENT OF CARDIOMYOPATHIES, CARDIOVASCULAR DEPARTMENT, AZIENDA SANITARIA UNIVERSITARIA GIULIANO ISONTINA (ASUGI), TRIESTE, ITALY; (d) DEPARTMENT OF CARDIOLOGY, CARDIOVASCULAR RESEARCH INSTITUTE MAASTRICHT (CARIM), MAASTRICHT UNIVERSITY MEDICAL CENTRE, MAASTRICHT, NETHERLANDS; (e) CARDIOLOGY AND CARDIOTHORACIC DEPARTMENT, UNIVERSITY HOSPITAL SANTA MARIA MISERICORDIA, ASUFC, UDINE, ITALY; (f) CLINICAL AND MOLECULAR MEDICINE DEPARTMENT, SAPIENZA UNIVERSITY OF ROME, ITALY; (g) INSTITUTE OF

CARDIOVASCULARE SCIENCE, UNIVERSITY COLLEGE OF LONDON, UK; (h) DE GASPERIS CARDIO CENTRE, NIGUARDA HOSPITAL, MILAN, ITALY

Aims. Acute myocarditis (AM) is a heterogeneous disease, which in some cases can manifest with multiple inflammatory episodes, defined as recurrent myocarditis (RM). However, RM remains poorly characterized, and data regarding their clinical course and prognosis are limited. Furthermore, in the last years emerging evidence suggests that RM may represent a clinical presentation of certain cardiomyopathies, emphasizing the importance of a comprehensive clinical and genetic investigation in these patients. The present study aimed to characterize the natural history and prognostic value of recurrent episodes of AM.

Methods and Results. A total of 243 consecutive patients with a diagnosis of AM, admitted to nine international tertiary referral cardiac centres were included in the study. The population was divided into two groups for comparison: the RM group, consisting of 124 patients with at least two episodes of AM, and the single myocarditis (SM) group comprising 119 patients. For both groups diagnosis was confirmed through either cardiac magnetic resonance (CMR) or endomyocardial biopsy (EMB). The primary outcome measure was a composite endpoint that included the first occurrence of all-cause mortality, heart transplant, new onset heart failure (HF) or left ventricular (LV) dysfunction, and major ventricular arrhythmias (MVAs). Secondary outcomes were HF-related and arrhythmic-related endpoints. Baseline characteristics of the two populations were similar, encompassing comorbidities, clinical presentation, and imaging findings. Notably, patients with RM were younger and had a higher prevalence of autoimmune diseases and associated pericarditis during their first episode of AM. Moreover, comparing the two inflammatory episodes in the RM population, the recurrence exhibited an increased extent of late gadolinium enhancement (LGE) on CMR, with a more frequent ring-like pattern and antero-septal distribution. Over a median follow-up period of 39 months, RM was associated with a worse prognosis compared with SM (p=0.025), especially regarding the development of HF and LV dysfunction (p=0.03). Furthermore, the presence of a positive genetic background (49 patients, 27 in RM and 12 in SM population, respectively) was significantly associated with unfavourable outcomes (p=0,03).

Conclusions. To our knowledge, this study represents the largest cohort of patients with CMR and/or EMB- proven RM to date. Our findings highlight that the presence of multiple episodes of myocarditis is associated with poorer prognosis, conferring a particularly increased risk of HF and development of LV dysfunction. In these patients, genetic testing assumes a fundamental role in further risk stratification.

A725: AMILOIDOSI CARDIACA E STRATIFICAZIONE DEL RISCHIO TROMBOEMBOLICO

Virginia Eustachi (a, b), Pier Filippo Vianello (a, b), Marco Canepa (a, b), Italo Porto (a, b)

(a) UNIVERSITÀ DEGLI STUDI DI GENOVA; (b) IRCCS OSPEDALE POLICLINICO SAN MARTINO

L'amilodosi sistemica rappresenta un gruppo di malattie eterogenee caratterizzate dall'accumulo extracellulare di proteine fibrillari insolubili in diversi organi, tra cui il cuore. L'infiltrazione di amiloide causa un'importante ventaglio di manifestazioni cardiovascolari; diversi studi autoptici e in vivo hanno riportato una prevalenza considerevole di trombosi endocavitaria anche in pazienti in ritmo sinusale o in corso di terapia anticoagulante. Uomo di 77 anni, affetto da amiloidosi cardiaca da transtiretina wild-type in follow-up presso l'Ambulatorio Cardiomiopatie dell'Ospedale Policlinico San Martino da Marzo 2021. La diagnosi di amiloidosi cardiaca avvenne a Novembre 2020 secondo i criteri "non-biopsy" dopo accertamenti effettuati per astenia, dispnea per sforzi moderati e ipotensione ortostatica. Alla prima visita presso il nostro Centro, il paziente si presentava in classe NYHA II e in terapia con 100 mg/die di furosemide. All'ECG ritmo sinusale con bassi voltaggi periferici ed all'ecocardiogramma marcata ipertrofia simmetrica del ventricolo sinistro con funzione sistolica ai limiti inferiori e "apical sparing". Il pattern transmitralico risultava di tipo restrittivo con onda a di bassa ampiezza. Veniva avviata terapia con tafamidis. A Gennaio 2022 rivalutazione presso l'Ambulatorio dopo peggioramento del compenso cardiocircolatorio con conseguente aumento della terapia diuretica. All'ECG flutter atriale atipico per cui avviava terapia anticoagulante con apixaban 5 mg. Il paziente ha presentato una progressiva ingravescenza della dispnea fino a necessitare un ricovero ospedaliero a Giugno 2022; all'ecocardiogramma evidenza di severa disfunzione sistolica del ventricolo sinistro. In ottica di rythm-control è stato eseguito un ecocardiogramma transesofageo pre-cardioversione elettrica con riscontro di trombosi endoauricolare nonostante l'avvio di apixaban da circa 5 mesi. Dopo la dimissione il paziente ha presentato un miglioramento delle condizioni cliniche in terapia di mantenimento con alte dosi di furosemide e SGLT2-inibitore. A Novembre 2022, dopo circa 10 mesi di terapia anticoagulante, veniva programmata ecocardiografia transesofagea per verificarne l'efficacia: evidenza di auricola con depositi trombotici. Veniva pertanto sostituito apixaban con warfarin in considerazione di un più ampio spettro di azione sulla cascata coagulativa. All'ultima visita il paziente riferiva miglioramento della dispnea ma un peggioramento del dolore lombare dovuto a un'invalidante stenosi spinale. All'ECG persistenza di tachiaritmia atriale, all'ecocardiogramma lieve miglioramento della funzione sistolica (FEVS 40%). In considerazione dell'elevato rischio tromboembolico, a Giugno 2023 effettuava TC cuore per studio dell'auricola e valutazione dell'albero coronarico: il paziente presenta una malattia coronarica trivasale con stenosi critica subocclusiva dell'arteria coronaria destra media, stenosi significative all'origine della coronaria discendente anteriore, stenosi critica post-ostiale della coronaria circonflessa; l'auricola si presenta trombizzata nonostrante sei mesi di warfarin e INR in range. Il paziente prosegue attualmente follow-up semestrale clinico-strumentale; alla luce della disfunzione del ventricolo sinistro e della severa malattia coronarica, l'eventuale intervento neurochirurgico risulta attualmente proibitivo nonostante l'evidente impatto sulla qualità di vita. Tale caso clinico esemplifica l'elevato rischio tromboembolico dei pazienti con amiloidosi cardiaca rispetto alla popolazione generale. La TC cardiaca è uno strumento non invasivo che può valutare contemporaneamente lo stato coronarico e la trombosi endoauricolare rendendola un'interessante tecnica di screening per tale popolazione.

A726: IMPACT OF PATISIRAN ON HEALTH STATUS AND QUALITY OF LIFE IN PATIENTS WITH TRANSTHYRETIN CARDIAC AMYLOIDOSIS

Simone Longhi (on Behalf Of) (a), Shaun Bender (b), Kelley Capocelli (b), Edileide De Barros Correia (c), Per Eldhagen (d), Mazen Hanna (e), Toru Hashimoto (f), Patrick Jay (b), Parag Kale (g), Sumeet Mitter (h), Laura Obici (i), Zubair Shah (j), Matthew White (b)

(a) CARDIOLOGY UNIT, CARDIAC THORACIC AND VASCULAR DEPARTMENT, IRCCS AZIENDA OSPEDALIERO-UNIVERSITARIA DI BOLOGNA; (b) ALNYLAM PHARMACEUTICALS, CAMBRIDGE, MA, USA; (c) INSTITUTO DANTE PAZZANESE DE CARDIOLOGIA, SAO PAULO, BRAZIL; (d) KAROLINSKA UNIVERSITY HOSPITAL SOLNA, STOCKHOLM, SWEDEN; (e) THE CLEVELAND CLINIC FOUNDATION, CLEVELAND, OH, USA; (f) YUSHU UNIVERSITY HOSPITAL, FUKUOKA, JAPAN; (g) CENTER FOR ADVANCED HEART AND LUNG DISEASE BAYLOR UNIVERSITY MEDICAL CENTER, DALLAS, TX, USA; (h) MOUNT SINAI HOSPITAL, NEW YORK, NY, USA; (i) AMYLOIDOSIS RESEARCH & TREATMENT CENTER, FONDAZIONE IRCCS POLICLINICO SAN MATTEO DI PAVIA, PAVIA, ITALY; (j) UNIVERSITY OF KANSAS MEDICAL CENTER, KANSAS CITY, KS, USA

Introduction. APOLLO-B is a Phase 3 study of patisiran in patients with transthyretin (ATTR) cardiac amyloidosis (NCT03997383), which demonstrated a significant benefit in functional capacity (6-MWT), and health status and quality of life (QoL) (KCCQ-OS) with patisiran vs placebo at Month (M) 12.

Hypothesis. Patisiran improves health status and QoL in the daily lives of patients with ATTR cardiac amyloidosis vs placebo.

Methods. Patients were 18–85 years old with ATTR amyloidosis and a medical history of heart failure (HF) due to ATTR cardiomyopathy, with ≥1 prior hospitalization for HF or current clinical evidence of HF. Patients were randomized (1:1) to intravenous patisiran 0.3 mg/kg or placebo every 3 weeks. These post-hoc analyses evaluated percentage of responders reporting ≥5-point improvement in KCCQ-OS, and change from baseline in 4 KCCQ domains and questions within the domains.

Results. 359 patients received study drug (patisiran, N=181; placebo, N=178): median age (range), 76 (41, 85) years; male, 89%; wild-type ATTR, 80%; 25% were on tafamidis at baseline. At M12, patisiran showed significant benefit vs placebo in KCCQ-OS (LS mean [SEM] change from baseline: patisiran, 0.30 [1.26]; placebo, –3.41 [1.28]; LS mean [SEM] difference: 3.71 [1.80]; p=0.0397). A ≥5-point improvement in KCCQ at M12 was more frequent with patisiran vs placebo (34.1 vs 24.0%: difference [95% CI] 10.1% [0.7, 19.5]). Improvement vs placebo was consistent across domains, with LS mean differences [95% CI] in change from baseline (patisiran – placebo) in Physical Limitations (2.75 [–1.24, 6.74]), Total Symptoms (4.55 [0.75, 8.34]), QoL (4.27 [–0.12, 8.65]), and Social Limitations (2.76 [–2.21, 7.73]). Categorical changes from baseline to M12 demonstrated greater percentages of placebo-treated patients reporting worsening for questions in each domain, including activities requiring greater cardiometabolic demand. In patients with values at baseline and M12, notably greater percentages (>5%) of placebo- vs patisiran-treated patients reported worsening (percent difference; n=placebo/patisiran) for questions related to Walking 1 Block on Level Ground (10%; n=159/162), Frequency and Burden of Dyspnea (9.5% and 7.6%; n=164/170), Frequency of Orthopnea (9.6%; n=163/170), Feeling about Spending the Rest of Their Life with HF the Way It Is Right Now (6.4%; n=164/170), and Intimate Relationships (6.3%; n=88/86). Improvement from baseline was reported by greater percentages (>5%) of patisiran-treated patients (percent difference; n=patisiran/placebo) in Enjoyment of Life Limited Due to HF (12.8%; n=170/164) and Hobbies/Recreational Activities (6.0%; n=141/143).

Conclusions. In APOLLO-B, improvements in health status and QoL with patisiran vs placebo were apparent across all 4 KCCQ domains. Greater percentages of patisiran-treated patients had KCCQ-OS improved by ≥5 points at M12 and they more often reported improvements in QoL, and ability to enjoy life and perform hobbies/recreational activities. More placebo-treated patients reported worsening in walking on level ground, HF symptoms and QoL.

A727: LA SINDROME DEL CUORE INFRANTO

Camilla Matese (a), Elisa Venturoli (a), Federica Frascaro (a), Samuela Carigi (b), Federica Baldazzi (b), Michele Fabrizio (b), Paolo Cimaglia (a), Marco Zuin (a), Andrea Gardi (b), Veronica Moriconi (b), Annamaria Di Cesare (b), Francesco Contorni (b), Rossella Ruggiero (b), Roberta Campana (b), Filippo Ottani (b)
(a) UNIVERSITÀ DI FERRARA; (b) CARDIOLOGIA RIMINI

Introduzione. Una delle complicanze più temibili della cardiomiopatia di Takotsubo (TTS) è rappresentata dalla perforazione miocardica. Gli attuali dati epidemiologici indicano una incidenza di tale complicanza intorno allo 0.5% dei casi, specialmente nelle donne anziane ed ipertese. Il presente caso clinico descrive un caso di TTS in una donna anziana complicato dalla rottura della parete libera del ventricolo sinistro.
Caso clinico. Una donna di 78 anni, ipertesa da anni, accedeva in pronto soccorso per dolore toracico tipico insorto qualche ora dopo un importante stress emotivo. L'ECG mostrava complessi QS con persistente sopraslivellamento del tratto ST in sede anteriore. Durante il "primary assessment" in dipartimento di emergenza, il quadro emodinamico evolveva improvvisamente in un'attività elettrica senza polso. Dopo ripristino del ritmo sinusale mediante manovre rianimatorie, l'ecoscopia evidenziava severo tamponamento pericardico ubiquitario (TD max 2-3 cm) associato alla presenza di flusso doppler apicale trans miocardico, suggestivo per rottura di cuore. Previo a massivo riempimento volemico, posizionava un pigtail pericardico e la paziente veniva trasferita in sala operatorio cardiochirurgica. Mediante sternotomia mediana si procedeva a chiusura della lacerazione ventricolare apicale mediante apposizione di patch con completa risoluzione della lesione e buon risultato finale. Al fine di escludere una causa ischemica, la paziente veniva sottoposta a coronarografia, la quale riscontrava coronarie epicardiche esenti da lesioni emodinamicamente significative. Il decorso post-operatorio si è svolto regolarmente, senza complicanze e con buon recupero da parte della paziente.
Conclusioni. La rottura della parete ventricolare sinistra rappresenta una rara (circa 0.5% dei pazienti) complicanza della TTS, specialmente nelle donne anziane. Red flags suggestivi di tale evenienza, seppur non specifici, sono rappresentati dalla persistenza di un sopra-slivellamento del tratto ST, elevati livelli degli indici di miocardiocitonecrosi, e elevate pressioni di riempimento ventricolare.

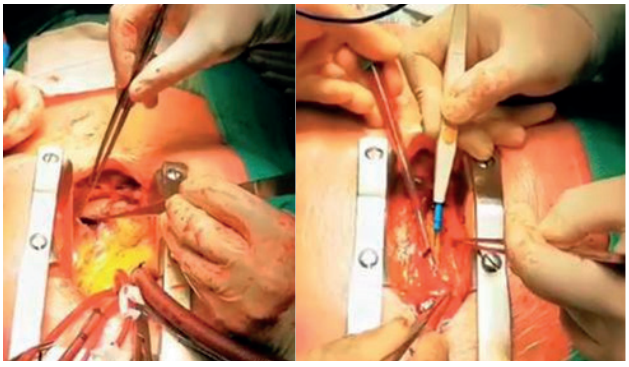

A728: APPLICABILITY, PERFORMANCE AND PROGNOSTIC VALUE OF POLYGENIC RISK SCORES IN DILATED CARDIOMYOPATHY: A PRELIMINARY ANALYSIS

Maddalena Rossi (a), Matteo Dal Ferro (a), Alessia Paldino (a), Pio D´adamo (c), Ilaria Gandin (b), Nikita Baracchini (a), Carola Pio Loco Detto Gava (a), Marco Merlo (a), Gianfranco Sinagra (a)
(a) CARDIOVASCULAR DEPARTMENT, AZIENDA SANITARIA UNIVERSITARIA GIULIANO-ISONTINA, UNIVERSITY OF TRIESTE, ITALY; (b) BIOSTATISTICS UNIT, UNIVERSITY OF TRIESTE, ITALY; (c) INSTITUTE FOR MATERNAL AND CHILD HEALTH IRCCS BURLO-GAROFOLO, UNIVERSITY OF TRIESTE, ITALY

Background. Some genome-wide association studies (GWAS) have uncovered the role of common genetic polymorphisms in influencing cardiac structure and function, also contributing to the genetic architecture of Dilated Cardiomyopathy (DCM). However no dedicated studies have ever investigated the diagnostic and prognostic value of polygenic risk scores (PRSs) in DCM.
Aims. To evaluate the performance and prognostic value of PRSs in a large cohort of DCM patients.
Methods. This was a retrospective study including a total of 300 DCM patients analyzed by next-generation sequencing (NGS) and microarray analysis. We tested four PRSs developed from a GWAS of cardiac magnetic resonance imaging-derived left ventricular (LV) measurements in UK Biobank participants: body-surface-area (BSA) indexed LV end-diastolic volume PRS (LVEDVi PRS), BSA-indexed LV end-systolic volume PRS (LVESVi PRS), BSA-indexed stroke volume PRS (SVi PRS), LV ejection fraction PRS (LVEF PRS). Moreover we tested a PRS derived from a three DCM-GWAS meta-analysis: PRS_D. The following composite outcome measures were assessed: 1) all-cause mortality; 2) heart failure (HF)–related death, heart transplantation, or destination left ventricular assist device implantation (DHF/HTx/VAD); and 3) sudden cardiac death/sustained ventricular tachycardia/ventricular fibrillation (SCD/VT/VF).
Results. LVEDVi PRS was found to significantly influence LVEDVi (P=0.010) and LVESVi (P=0.035) of our population, while SVi PRS was found to be significantly associated with LVEDVi (P=0.003), LVESVi (P=0.047) and BSA-indexed LV mass (P=0.002). PRS_D showed a significant positive association with LVEF (P=0.014) and right ventricle fractional area change (P=0.038). All these results were confirmed after adjustment for age and sex, without any differences between patients carriers or non carriers of pathogenic/likely pathogenic (P/LP) monogenic variants. A higher PRS_D was significantly associated with a better overall survival and a lower occurrence of SCD/VT/VF (P=0.004), also in a multivariable analysis, adjusted for sex, age, LVEF at baseline, familial hystory of SCD and NGS positive for a P/LP variant in arrhythmic genes. The others PRSs were not significantly associated with adverse clinical outcomes.
Conclusions. To the best of our knowledge this is the first study investigating the performance and prognostic value of previously developed PRSs in a large cohort of DCM patients. Our evidence suggests that common genetic variants might play a role in determining cardiac structure and function, overall survival and arrhythmic outcomes in DCM and therefore that PRSs could improve the diagnostic and prognostic assessment of the disease.

A729: IMPLEMENTATION AND DEFINITION OF THE PROGNOSTIC ROLE OF FAMILY SCREENING IN NON-HYPERTROPHIC LEFT CARDIOMYOPATHIES

Eva Del Mestre (a), Alessia Paldino (a), Carola Pio Loco Detto Gava (a), Matteo Dal Ferro (a), Marco Merlo (a), Gianfranco Sinagra (a)
(a) AZIENDA SANITARIA UNIVERSITARIA GIULIANO ISONTINA, OSPEDALIERA UNIVERSITÀ DEGLI STUDI DI TRIESTE

Background. Dilated cardiomyopathy (DCM) and arrhythmogenic left dominant cardiomyopathy (ALVC) are hereditary cardiac disorders that overlap phenotypically and genetically as non-hypertrophic left ventricular cardiomyopathy (LV-CMP). Familial screening (FS) aims to detect early cardiac manifestations in at-risk relatives. However, the ability of FS to improve prognosis and whether ECG and basic echocardiogram are sufficient for predicting disease and events remain uncertain.
Methods. A retrospective study enrolled 492 first-degree relatives of non-hypertrophic LV-CMP probands from 1991 to 2022. Data on family history, ECG, echocardiogram, global longitudinal strain (GLS), and Holter ECG were collected. Genetic testing was offered to relatives with LP/P variants. Disease manifestation was defined as the development of left ventricular systolic dysfunction (LVSD) (EF <50%). Univariable and multivariable analyses identified causative factors and disease predictors. Primary outcomes were all-cause death and heart transplantation; secondary outcomes were sudden cardiac death and major ventricular arrhythmias.
Results. One-third of relatives had baseline LVSD. Among initially unaffected relatives, 36% developed LVSD during a median follow-up of 53 months, typically at the age of 39 years. Family history and genetic background were significant causative factors for disease development. Combining Holter ECG and GLS with ECG and echocardiogram improved risk assessment for LVSD (C-index 0.78, p=0.012). FS-detected relatives had lower rates of primary events (non-FS: 37%, FS: 14%, p<0.001) and secondary arrhythmic events (non-FS: 38%, FS: 13%, p<0.001).
Conclusions. First-degree relatives of non-hypertrophic LV-CMP probands are at high risk for disease development, typically between ages 25-55. Family history and LP/P variants are key causative factors. Enhancing FS with Holter ECG and GLS helps identify at-risk relatives. FS plays a crucial role in preventing arrhythmic events, highlighting the need to incorporate new diagnostic tools for improved risk stratification and personalized screening intervals.

A730: TTN-INDUCED CARDIOMYOPATHY: BEYOND DCM. AN ITALIAN REGISTRY.

Maria Perotto (a, b), Cinzia Radesich (a, b), Alessia Paldino (a), Michele Lo Casto (a, b), Ilaria Gandin (c), Andrea Faggiano (d), Stefano Carugo (d), Marco Canepa (e), Edoardo Bertero (e), Elena Biagini (k), Silvia Palmieri (k), Irene Ruotolo (k), Michele Edmin (f), Andrea Barison (f), Iacopo Olivotto (g), Alessandra Fornaro (g), Samuela Carigi (m), Matteo Beltrami (l), Martina Setti (h), Flavio Ribichini (h), Enrico Ammirati (i), Piero Gentile (i), Valentina Giani (i), Cinzia Forleo (j), Andrea Guaricci (j), Marco Merlo (a), Matteo Dal Ferro (a), Gianfranco Sinagra (a)
(a) CARDIOVASCULAR DEPARTMENT, AZIENDA SANITARIA UNIVERSITARIA GIULIANO ISONTINA (ASUGI), UNIVERISTY OF TRIESTE, ITALY. MEMBER OF ERN GUARD-HEART.; (b) POSTGRADUATE SCHOOL OF CARDIOVASCULAR MEDICINE, UNIVERSITY OF TRIESTE, TRIESTE, ITALY; (c) BIOSTATISTICS UNIT, UNIVERSITY OF TRIESTE, TRIESTE, ITALY; (d) CARDIOLOGY UNIT, INTERNAL MEDICINE DEPARTMENT, IRCCS CA' GRANDA OSPEDALE MAGGIORE POLICLINICO DI MILANO, UNIVERISTY OF MILAN, MILAN, ITALY; (e) CARDIOLOGY UNIT, CARDIOTHORACIC AND VASCULAR DEPARTMENT, IRCCS OSPEDALE POLICLINICO SAN MARTINO, UNIVERSITY OF

GENOVA, GENOVA, ITALY; (f) FONDAZIONE TOSCANA GABRIELE MONASTERIO, PISA, ITALY; (g) CAREGGI UNIVERISTY HOSPITAL, FLORENCE, ITALY; (h) VERONA UNIVERSITY HOSPITAL, VERONA, ITALY; (i) DE GASPERIS CARDIO CENTER, NIGUARDA HOSPITAL, MILAN, ITALY; (j) UNIVERISTY HOSPITAL POLICLINICO OF BARI, BARI, ITALY; (k) CARDIOLOGY UNIT, IRCCS OSPEDALE SANT'ORSOLA, UNIVERSITY OF BOLOGNA, BOLOGNA, ITALY; (l) SAN GIOVANNINI DI DIO HOSPITAL, FIRENZE, ITALY; (m) OSPEDALE INFERMI DI RIMINI, AUSL ROMAGNA, ITALY

Background. Titin (TTN) truncating variants (tv) represent the most prevalent genotype underlying Dilated Cardiomyopathy (DCM). Recent molecular studies provided initial evidence about distinct pathogenic mechanisms of different protein truncating sites (A-band vs non-A-band), possibly related to the presence or absence of truncated peptides. Yet, to date, the site of protein truncation does not seem to influence clinical phenotype or outcomes. However, previous studies on TTNtv enrolled only patients with DCM: the genetic, clinical, and prognostic features of TTN-induced cardiomyopathy beyond DCM phenotype have not been elucidated.

Methods. We established a national multi-center registry including all carriers of pathogenic or likely pathogenic TTNtv, irrespective of their phenotypic expression at onset. TTNtv were classified according to their site in the adult cardiac isoform of the protein (A-band vs non-A-band group). The primary outcome was a composite of all-cause mortality and heart transplantation, for which Kaplan-Meier survival curves were created. Cumulative incidence function curves were derived for two secondary outcomes: (i) heart failure-related death/HT/left ventricular assist device implantation (LVAD) and (ii) sudden cardiac death (SCD) or first major ventricular arrhythmia (MVA, life- threatening ventricular arrhythmia).

Results. The study enrolled 210 patients (77% probands, 76% males) from ten Italian referral centers for heart failure and cardiomyopathies, 78% A-band variant carriers and 22% non-A band variant carriers. At baseline, DCM phenotype was observed in 93% of patients in the A-band group and 82% of patients in the non-A-band group. After a median follow-up of 106 [49-120] months, the primary endpoint was similar in the two groups. However, the risk of SCD/MVAs was significantly higher in the non-A-band group compared with the A-band group (19.5% vs 10%, p=0.048). Furthermore, there was a trend for higher occurrence of heart failure events in the A-band group. Interestingly, in a multivariable model including gender, left ventricular ejection fraction (LVEF) at baseline was associated with the risk of SCD/MVAs in the A-band group (HR 0.95; 95% CI, 0.92-0.99; p=0,009) but not in the non-A-band group (HR 0.97; 95% CI, 0.93-1.02; p=0,2).

Conclusions. TTN-induced cardiomyopathy may present differently according to the specific site in which the truncating variant occurs. Specifically, TTNtv in the non-A-band region seem to produce a more arrhythmogenic phenotype. These results could potentially lead to consider TTN truncation site as a novel parameter for a more precise risk stratification.

A731: IMPACT OF GLA VARIANT CLASSIFICATION ON ESTIMATED PREVALENCE OF FABRY DISEASE: A SYSTEMATIC REVIEW AND META-ANALYSIS OF SCREENING STUDIES

Emanuele Monda (a), Gaetano Diana (a), Francesca Graziani (b), Marta Rubino (a), Athanasios Bakalakos (h), Ales Linhart (c), Dominique P. Germain (d), Maurizio Scarpa (e), Elena Biagini (f), Maurizio Pieroni (g), Perry Elliott (h), Giuseppe Limongelli (a)
(a) INHERITED AND RARE CARDIOVASCULAR DISEASE UNIT, DEPARTMENT OF TRANSLATIONAL MEDICAL SCIENCES, UNIVERSITY OF CAMPANIA "LUIGI VANVITELLI" NAPLES, ITALY; (b) DEPARTMENT OF CARDIOVASCULAR SCIENCES, FONDAZIONE POLICLINICO UNIVERSITARIO A. GEMELLI, IRCSS, ROME, ITALY; (c) 2ND DEPARTMENT OF MEDICINE - DEPARTMENT OF CARDIOVASCULAR MEDICINE, FIRST FACULTY OF MEDICINE, CHARLES UNIVERSITY AND GENERAL UNIVERSITY HOSPITAL, PRAGUE, CZECH REPUBLIC; (d) DIVISION OF MEDICAL GENETICS, APHP PARIS SACLAY UNIVERSITY, UNIVERSITY OF VERSAILLES, MONTIGNY, FRANCE; (e) REGIONAL COORDINATOR CENTRE FOR RARE DISEASES, UNIVERSITY HOSPITAL OF UDINE, UDINE, ITALY; (f) CARDIOLOGY UNIT, CARDIAC THORACIC AND VASCULAR DEPARTMENT, IRCCS AZIENDA OSPEDALIERO-UNIVERSITARIA DI BOLOGNA, BOLOGNA, ITALY; (g) CARDIOVASCULAR DEPARTMENT, SAN DONATO HOSPITAL, AREZZO, ITALY; (h) INSTITUTE OF CARDIOVASCULAR SCIENCE, UNIVERSITY COLLEGE LONDON, LONDON, UK

Background. The diagnosis of Fabry disease (FD) has relevant implications related to the management. In this systematic review and meta-analysis, we aimed to investigate the prevalence of FD in high-risk populations and newborns and evaluate the impact of different GLA variant classifications on the estimated prevalence of FD.

Methods. We searched the EMBASE and Pubmed databases on February 21, 2023. Observational studies evaluating the prevalence of FD and reporting the identified GLA variants were included. Studies were categorized into the following settings: left ventricular hypertrophy (LVH)/hypertrophic cardiomyopathy (HCM); end-stage renal disease (ESRD) requiring dialysis or renal transplantation/chronic kidney disease (CKD); stroke; cardiac conduction disturbance requiring pacemaker (PMK); small-fiber neuropathy; newborn screening. GLA variants were re-evaluated for their pathogenicity significance using the ACMG criteria and the ClinVar database. Pooled prevalence of FD among the different settings was calculated.

Results. Of 3,941 studies identified, 110 met the inclusion criteria. The pooled prevalence of FD was significantly different according to the clinical setting and criteria used for the pathogenicity assessment. Using the ACMG criteria, the pooled prevalence was 1.2% in patients with LVH/HCM (26 studies, 10,080 patients screened), 0.3% in ESRD/CKD (38 studies, 62,050 patients screened), 0.7% in stroke (25 studies, 15,295 patients screened), 0.7% in AVB/SND requiring PMK (3 studies, 1,033 patients screened), 1.0% in small-fiber neuropathy (3 studies, 904 patients screened), and 0.01% in newborns (15 studies, 1,1108,793 newborns screened). The pooled prevalence was different if the GLA variants were assessed using the ClinVar database, and most patients with a discrepancy in the pathogenicity assignment carried one of the following variants: p.A143T; p.D313Y; and p.E66Q.

Conclusions. This systematic review and meta-analysis describe the prevalence of FD among newborns and high-risk populations, highlighting the need for a periodic reassessment of the GLA variants in the context of recent clinical, biochemical, and histological data.

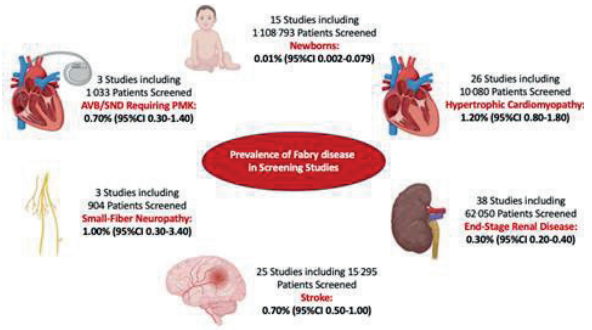

A732: NATURAL HISTORY OF HYPERTROPHIC CARDIOMYOPATHY IN NOONAN SYNDROME WITH MULTIPLE LENTIGINES

Emanuele Monda (a), Aaron Prosnitz (b), Aiello Rossella (a), Michele Lioncino (a), Gabrielle Norrish (c), Martina Caiazza (a), Fabrizio Drago (d), Meaghan Battie (e), Marco Tartaglia (d), Maria Giovanna Russo (a), Steven D. Colan (e), Giulio Calcagni (d), Bruce D. Gelb (f), Juan Pablo Kaski (c), Amy E. Roberts (e), Giuseppe Limongelli (a)
(a) INHERITED AND RARE CARDIOVASCULAR DISEASES UNIT, DEPARTMENT OF TRANSLATIONAL MEDICAL SCIENCES, UNIVERSITY OF CAMPANIA "LUIGI VANVITELLI", NAPLES, ITALY; (b) CONGENITAL HEART CENTER, LEVINE CHILDREN'S HOSPITAL, ATRIUM HEALTH, CHARLOTTE, NC, USA; (c) INSTITUTE OF CARDIOVASCULAR SCIENCE, UNIVERSITY COLLEGE LONDON, LONDON, UK; (d) DEPARTMENT OF PEDIATRIC CARDIOLOGY AND CARDIAC SURGERY, BAMBINO GESÙ CHILDREN'S HOSPITAL, IRCCS, ROME, ITALY; (e) DEPARTMENT OF CARDIOLOGY AND DIVISION OF GENETICS, DEPARTMENT OF PEDIATRICS, BOSTON CHILDREN'S HOSPITAL, BOSTON, MA, USA; (f) MINDICH CHILD HEALTH AND DEVELOPMENT INSTITUTE AND THE DEPARTMENT OF PEDIATRICS AND GENETICS AND GENOMIC SCIENCE, ICAHN SCHOOL OF MEDICINE AT MOUNT SINAI, NEW YORK, NY, USA

Background. We aimed to examine clinical features, and outcomes of consecutive molecularly characterized patients with Noonan syndrome with multiple lentigines (NSML) and hypertrophic cardiomyopathy (HCM).

Methods. A retrospective, longitudinal multicenter cohort of consecutive children and adults with a genetic diagnosis of NSML and HCM between 2002 and 2019 was assembled. We defined a priori three different patterns of left ventricular remodeling during follow-up: 1. an increase ≥15% of the maximal left ventricular wall thickness (MLVWT), both in mm and z-score (progression); 2. a reduction ≥15% of the MLVWT, both in mm and z-score (absolute regression); 3. a reduction ≥15% of the MLVWT z-score with a stable MLVWT in mm (relative regression). The primary study endpoint was a composite of cardiovascular death, heart transplantation, and appropriate ICD-shock.

Results. The cohort comprised 42 patients with NSML and HCM, with a median age at diagnosis of 3.5 (interquartile range [IQR], 0.2-12.3) years. Freedom from primary endpoint was 92.7% (95% confidence interval [CI] 84.7-100%) 1 year after presentation and 80.9% (95%CI 70.1-90.7%) at 5 years. Patients with MLVWT z-score more than 13.7 showed reduced survival compared with those with less than 13.7. During a median follow-up of 3.7 years (IQR 2.6-7.9), absolute regression was the most common type of left ventricular remodeling (n=9, 31%), followed by progression (n=6, 21%), and relative regression (n=6, 21%).

Conclusions. These findings provide insights into the natural history of left ventricular hypertrophy, and can help inform clinicians regarding risk stratification and clinical outcomes in patients with NSML and HCM.

A733: GENDER DIFFERENCES IN ANDERSON-FABRY DISEASE: ANAYSIS OF CARDIAC PHENOTYPE IN WOMEN AT A MULTIDISCIPLIARY REFERENCE CENTER

Denise Cristiana Faro (a), Fabrizio De Gaetano (a), Elvira Maria Torrisi (a), Valentina Losi (a), Margherita Stefania Rodolico (b), Ines Paola Monte (a)

(a) CHIRMED DEPARTMENT, UNIVERSITIY OF CATANIA; (b) CNR-IRIB PALERMO, SECTION OF CATANIA

Background. Anderson-Fabry Disease (AFD), a rare multisystemic lysosomal storage disease, is caused by GLA gene mutation leading to α-galactosidase A (α-Gal A) deficiency. AFD exhibits an X-linked inheritance pattern, with a more pronounced and early-onset phenotype in males. The phenotypic manifestation in females is variable due to cellular mosaicism resulting from lyonization of the X chromosome, insidious and severe, particularly about heart.

Objective: To assess the differences in cardiac manifestations of AFD in women (F) versus men (M), in relation to the type of mutation involved: classical (CL), late onset [LO] or variants of uncertain significance [VUS]).

Methods. We examined 75 AFD patients (56 F, 19 M) referred to the Fabry Disease Reference Center at the "G. Rodolico" University Hospital in Catania. Diagnosis was made by measuring α-Gal A enzyme activity (for M) and genetic analysis of GLA through PCR, along with periodical lyso-GB-3 monitoring. Patients underwent a medical history including family tree, ECG, basic and advanced echocardiography (tissue Doppler and Speckle tracking [STE] with global longitudinal strain [GLS] and mechanical dispersion [MD] analysis). A subgroup underwent dynamic ECG and cardiac magnetic resonance (CMR) with contrast and study of LGE. Data was analyzed using SPSS ver.26.

Results. The overall 75 AFD subjects had an average age of 44.52 ± 16.03 years; 13 had hypertrophy (AFD-LVH) and 62 didn't. Females, representing 75% of the sample, were on average older compared to M (46.4±16.2 vs 38.8±14.6, P=0.07); 41% were affected by VUS, 35.7% LO, and 16.1% CL. Males had 42.1% VUS, 36.8% LO, and 21% CL. Females showed significantly higher α-Gal A values (median 8 vs 1.8 nmol/ml/h, P<0.001) and slightly lower lyso-Gb3 levels (1.5 [IQR 1.1-1.7] vs 1.9 [1.5-17.3] nmol/l, P=0.017). 70% of F were in NYHA class I and 30% in class II, while in M, 84% were in class I and 16% in class II. 10/55 F and 3/20 M presented a LVH phenotype. Females showed lower LVMi values compared to M (P=0.03) and better GLS (-19% vs -17%, P=0.02), 7.1% ventricular arrhythmias (vs 10.5% among M), and 8.9% atrial fibrillation (vs 10.5% of M). At CMR, performed in 14 patients, fibrosis (LGE) was present in 50% of the examined F, versus 87% of M. In AFD-LVH group, 40% of F presented CL mutation, 30% VUS, and 20% LO. Patients with ventricular arrhythmias (3, one of whom died) and LVH and major GLS and MD alterations all had classical mutation. Significant differences were found in α-Gal A levels (8.8 nmol/ml/h vs 0.3 nmol/ml/h) and LVMi values (111 g/mq vs 227 g/mq), and also better GLS (-12.8% vs -10%) and lower MD (70 vs 87 msec), although not significantly (P respectively 0.16 and 0.69). Even in the group without LVH, significant differences persisted in α-Gal A and lyso-GB3 levels (P=0.002 and 0.03), as well as in LVMi (60.5 vs 77.5 g/mq, P=0.006) and GLS values (-20% vs -17%, P=0.02).

Conclusions. Our analysis highlighted in women older age, a lower degree of lysoGB3 deposition and hypertrophy, and lesser GLS compromise, consistent with a later onset of disease. The most severe cardiac patterns were associated with classical mutations, while those with VUS showed more subtle manifestations. In males, the early alteration of GLS, even in the absence of hypertrophy, further underlines the role of subclinical damage in this pathology.

	AFD tot F (N=56)	AFD tot M (N=19)	P-value
AGE	46,4 ± 16,2	38,8 ± 14,6	0,07
CLASSICAL MUTATION	9 (16,1%)	4 (21,1%)	
LATE ONSET	20 (35,7%)	7 (36,8%)	
VUS	23 (41,1%)	8 (42,1%)	
ALFA-GAL (nmol/ml/h)	8 [4,7-13,6]	1,8 [0,3-3,35]	< 0,001
LYSO-GB3 (nmol/l)	1,5 [1,1-1,7]	1,9 [1,5-17,3]	0,017
AR-V	4 (7,1%)	2 (10,5%)	
FA	5 (8,9%)	2 (10,5%)	
LVMi (g/mq)	66 [54-86,2]	78 [73-96]	0,03
GLS, %	-19 [-17, -22]	-17 [-14, -20]	0,02
MD (ms)	38 [29-50]	41 [29-60]	0,67
LGE+, n(%)	3 [50% of CRM]	7 [87,5%]	
LGE segments	3 [1-3]	2 [2-5]	

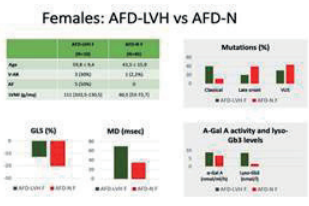

A734: ELECTROCARDIOGRAPHIC RED FLAGS IN CARDIAC TUMOURS

Damiano Fedele (a, b), Francesco Angeli (a, b), Francesca Bodega (a, b), Sara Amicone (a, b), Nicole Suma (a, b), Andrea Impellizzeri (a, b), Ornella Di Iuorio (a, b), Francesco Pio Tattilo (a, b), Daniele Cavallo (a, b), Khrystyna Ryabenko (a, b), Lisa Canton (a, b), Davide Bertolini (a, b), Angelo Sansonetti (a, b), Matteo Armillotta (a, b), Alberto Foà (a, b), Luigi Lovato (d), Luca Bergamaschi (a, b), Pasquale Paolisso (c), Carmine Pizzi (a, b)

(a) UNITÀ DI CARDIOLOGIA - IRCCS AZIENDA OSPEDALIERA-UNIVERSITARIA DI BOLOGNA; (b) DIPARTIMENTO DI SCIENZE MEDICHE E CHIRURGICHE (DIMEC) - ALMA MATER UNIVERSITÀ DEGLI STUDI DI BOLOGNA; (c) UNITÀ DI CARDIOLOGIA CLINICA E IMAGING INTRAVASCOLARE - OSPEDALE GALEAZZI - SANT'AMBROGIO DI MILANO; (d) UNITÀ DI RADIOLOGIA D'EMERGENZA, ONCOEMATOLOGIA E CARDIO-TORACO VASCOLARE DELL'ADULTO E PEDIATRICA - IRCCS AZIENDA OSPEDALIERA-UNIVERSITARIA DI BOLOGNA

Background. Cardiac tumours comprehend several histopathological categories, including malignancies, that often require a multimodality imaging approach in order to reach a diagnosis. EKG is a simple technique, but its role in the diagnostic pathway of cardiac masses has not been systematically investigated.

Aims. To identify electrocardiographic red flags predictive of malignancy in patients with cardiac tumours.

Methods. Patients with histologically proven cardiac tumours were included. Pseudo-tumours, infective endocarditis, and pacemaker-dependent patients were excluded. The first available EKG was retrospectively analysed. Univariate and multivariate regression analyses were carried out to select EKG abnormalities predictive of malignancy. Finally, all-cause mortality was assessed.

Results. The study cohort included 247 patients, of whom 98 (39.7%) were affected by malignant cardiac tumours, either primitive or metastatic lesions. Heart rate was higher in patients with malignancies (p<.001), mainly in the context of sinus tachycardia (p=.001). Bradyarrhythmias were more frequent in malignant tumours (p=.007), in particular for junctional rhythm (p=.002) and first-degree atrioventricular block (p=.036). Patients affected by malignancies presented more frequently a right axial deviation (p=.003), low QRS voltages (p<.001), pathological Q-waves (p=.045), and ischaemic-like repolarization abnormalities, either ST-segment deviation (p<.001) or T-wave inversion (p=.001). At the multivariate analysis higher heart rate, low QRS voltages, bradyarrhythmias, and ischaemic-like repolarization abnormalities resulted as independent predictors of malignancy. After a median follow-up of 22 months, 81 patients died (32.8%). In a Cox regression model, a "malignancy-oriented EKG" (i.e., with at least one of the independent predictors of malignancy) was an independent predictor of all-cause death (HR 4.26 [95% CI 2.56-7.07], p-value <.001) after correction for age, sex, hypertension, diabetes mellitus, and peripheral artery disease.

Conclusions. EKG may support a diagnosis of malignancy in patients with cardiac tumours. In particular, in our cohort we identified some electrocardiographic red flags that were predictive of malignant cardiac tumours and, when present, were linked to worse outcomes.

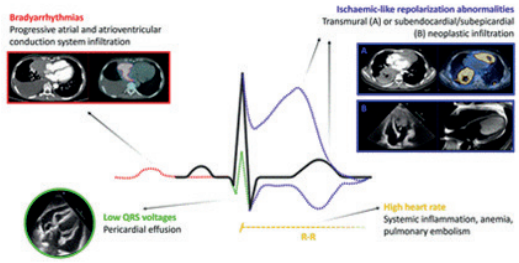

A735: ECHOCARDIOGRAPHIC FEATURES OF CARDIAC MASSES

Virginia Marinelli (a, b), Ornella Di Iuorio (a, b), Khrystyna Ryabenko (a, b), Daniele Cavallo (a, b), Francesco Pio Tattilo (a, b), Claudio Asta (a, b), Marcello Alvarez Casuso (a, b), Andrea Impellizeri (a, b), Nicole Suma (a, b), Damiano Fedele (a, b), Francesca Bodega (a, b), Lisa Canton (a, b), Sara Amicone (a, b), Matteo Armillotta (a, b), Angelo Sansonetti (a, b), Andrea Stefanizzi (a, b), Francesco Angeli (a, b), Luca Bergamaschi (a, b), Carmine Pizzi (a, b)

(a) CARDIOLOGY UNIT - IRCCS - AZIENDA OSPEDALIERA UNIVERSITARIA DI BOLOGNA; (b) DEPARTMENT OF MEDICAL AND SURGICAL SCIENCES - DIMEC - ALMA MATER STUDIORUM, UNIVERSITY OF BOLOGNA

Background. The echocardiographic parameters needed for a complete evaluation of cardiac masses are not yet completely known.

Objectives. To elaborate a multiparameters score with echocardiographic features of CMs which can help in prediction of malignancy.

Methods. We evaluated 286 consecutive patients in an observational cohort study from 2004 to 2022. These patients underwent a standard echocardiographic examination for suspicion of cardiac mass. The confirm of diagnosis was obtained histologically or, in case of cardiac thrombi, with radiological evidence of thrombus resolution after adequate anticoagulant therapy. Logistic and multivariable regression analysis was performed to confirm the ability of 6 echocardiographic parameters to discern the malignant masses from the benign ones. The unweighted count of these parameters was used as a numerical score, between 0 and 6, identifying a cut-off>3 comparing sensitivity and specificity with histological exam. Classification tree analysis (CTA) was used to identify the capability of these echocardiographic parameters to discriminate subgroups of patients with a differential risk of malignancy.

Results. Benign masses were more frequently characterized by having a peduncle, being mobile and adherent to the atrial septum. CTA identified infiltration as the best discriminator of malignancy, followed by non-left location and sessile form. The percentage correctly classified by CTA as malignant was 87.5%. The concordance between observer readings and cardiac mass histology ranged between 85.1-91.5%. The presence of at least 3 echocardiographic parameters was associated with a lower survival.

Conclusions. In the approach to the diagnosis of cardiac masses, these echocardiographic parameters can help to accurately predict malignancy, selecting cases that require second level investigations and reducing the diagnostic delay in this complex clinical scenario.

A736: SGLT2 INHIBITORS IN TRANSTHYRETIN AMYLOID CARDIOMYOPATHY

Aldostefano Porcari (a, b), Francesco Cappelli (c), Christian Nitsche (d), Daniela Tomasoni (d, e), Giulio Sinigiani (f), Simone Longhi (g), Luca Bordignon (b), Ahmad Masri (l), Matteo Serenelli (h), Marcus Urey (m), Beatrice Musumeci (i), Alberto Cipriani (f), Marco Canepa (j), Simone Longhi (g), Cristina Chimenti (n), Mattia Zampieri (c), Valentina Allegro (b), Yousuf Razvi (a), Rishi Patel (a), Adam Ioannou (a), Muhammad U Rauf (a), Aviva Petrie (a), Carol Whelan (a), Michele Emdin (k), Marco Merlo (b), Marco Metra (e), Gianfranco Sinagra (b), Philip N Hawkins (a), Julian D Gillmore (a), Marianna Fontana (a)

(a) NATIONAL AMYLOIDOSIS CENTRE, UNIVERSITY COLLEGE OF LONDON, ROYAL FREE CAMPUS, LONDON, UK; (b) CENTRE FOR DIAGNOSIS AND TREATMENT OF CARDIOMYOPATHIES, CARDIOVASCULAR DEPARTMENT, AZIENDA SANITARIA UNIVERSITARIA GIULIANO-ISONTINA (ASUGI), UNIVERSITY OF TRIESTE, TRIESTE, ITALY; (c) CARDIOMYOPATHY UNIT, CAREGGI UNIVERSITY HOSPITAL, UNIVERSITY OF FLORENCE, FLORENCE, ITALY; (d) DIVISION OF CARDIOLOGY, DEPARTMENT OF INTERNAL MEDICINE II, MEDICAL UNIVERSITY OF VIENNA, VIENNA, AUSTRIA; (e) CARDIOLOGY, ASST SPEDALI CIVILI DI BRESCIA AND DEPARTMENT OF MEDICAL AND SURGICAL SPECIALTIES, RADIOLOGICAL SCIENCES AND PUBLIC HEALTH, UNIVERSITY OF BRESCIA, BRESCIA, ITALY; (f) DEPARTMENT OF CARDIO-THORACO-VASCULAR SCIENCES AND PUBLIC HEALTH, UNIVERSITY OF PADUA, PADUA, ITALY; (g) CARDIOLOGY UNIT, IRCCS AZIENDA OSPEDALIERO-UNIVERSITARIA DI BOLOGNA, BOLOGNA, ITALY; (h) CARDIOLOGIC CENTRE, UNIVERSITY OF FERRARA, CONA, ITALY; (i) DEPARTMENT OF CLINICAL AND MOLECULAR MEDICINE, FACULTY OF MEDICINE AND PSYCHOLOGY, SAPIENZA UNIVERSITY, ROME, ITALY; (j) CARDIOVASCULAR UNIT, IRCCS OSPEDALE POLICLINICO SAN MARTINO, GENOVA, ITALY; (k) ISTITUTO DI SCIENZA DELLA VITA, SCUOLA SUPERIORE SANT'ANNA, PISA, ITALIA; (l) KNIGHT CARDIOVASCULAR INSTITUTE, OREGON HEALTH AND SCIENCE UNIVERSITY, PORTLAND, OR, USA; (m) CARDIAC ELECTROPHYSIOLOGY SECTION, DIVISION OF CARDIOLOGY, DEPARTMENT OF MEDICINE, UNIVERSITY OF CALIFORNIA, SAN DIEGO, LA JOLLA, CALIFORNIA, USA; (n) DEPARTMENTO OF CARDIOVASCULR AND RESPIRATORY DISEASES, NEPHROLOGY, ANESTHESIOLOGY AND GERIATRIC SCIENCES, POLICLINICO UMBERTO I, SAPIENZA UNIVERSITY OF ROME, ROME, ITALY

Background. The value of heart failure (HF) medications in transthyretin amyloid cardiomyopathy (ATTR-CM) is debated. The aims of this study were to assess dosages, discontinuation rates, efficacy and association with prognosis of sodium–glucose cotransporter 2 inhibitors (SGLT2-i).

Methods. A retrospective analysis of all patients diagnosed with ATTR-CM between 2016-2022 and treated with SGLT2-i at 14 centres.

Results. The study cohort comprised 520 patients with ATTR-CM: 260 treated with SGLT2-i and 260 propensity score matched patients not treated with SGLT2-i. Treatment with SGLT2-i was well tolerated, with a low discontinuation rate (5%). At 12 months, treatment with SGLT2-i was associated with a lower degree of worsening in dyspnoea, in NT-proBNP, eGFR, reduced new initiation of loop diuretic and lower increase in loop diuretic doses. During a median follow-up of 28 months (IQR 16-47), SGLT2-i therapy was associated with a reduced risk of all-cause mortality (HR 0.49 [95% CI 0.31-0.77], p=0.002), cardiovascular (CV) mortality (HR 0.40 [95% CI 0.24-0.69], p=0.00093), HF hospitalization (HR 0.56 [95% CI 0.34-0.92], p=0.022) and the composite outcome of CV mortality and HF hospitalization (HR 0.47 [95% CI 0.32-0.69], p=0.00013). The association among SGLT2-i treatment and outcomes was confirmed in a pre-specified subgroup of patients with a left ventricular ejection fraction (LVEF)>40% (p=0.002 for all-cause mortality, p=0.00093 for CV mortality, p=0.022 for HF hospitalizations and p=0.00013 for the composite outcome) and a LVEF ≤40% (p=0.037 for CV mortality and p=0.048 for the composite outcome).

Conclusions. SGLT2-i treatment was well tolerated and was associated with a lower degree of worsening in dyspnoea, NT-proBNP, eGFR and less new diuretic requirement over time. SGLT2-i treatment was associated with reduced risk of all-cause mortality and CV mortality, and HF hospitalization in the overall ATTR-CM population. These findings require confirmation in prospective randomized controlled trials.

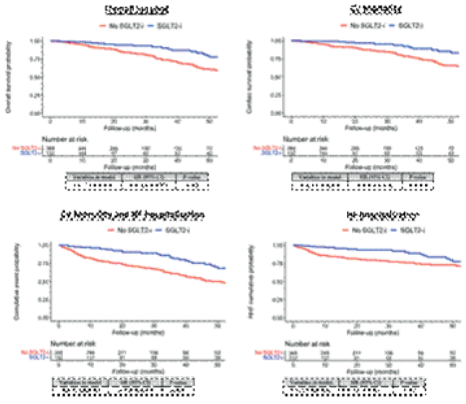

A737: COMPARISON OF HEART FAILURE AND DISEASE-SPECIFIC STAGING SYSTEMS FOR PROGNOSTIC STRATIFICATION IN ATTR-CM

Serena Steffan (a), Aldostefano Porcari (a), Alberto Aimo (b), Matteo Serenelli (c), Daniela Tomasoni (e), Laura De Michieli (d), Alberto Cipriani (d), Vincenzo Castiglione (b), Anna Cantone (c), Valentina Allegro (a), Riccardo Saro (a), Giovanni Battista Bonfioli (e), Giulio Sinigiani (d), Giuseppe Vergaro (b), Marco Metra (e), Michele Emdin (b), Gianfranco Sinagra (a), Marco Merlo (a)

(a) CENTRE FOR DIAGNOSIS AND TREATMENT OF CARDIOMYOPATHIES, CARDIOVASCULAR DEPARTMENT, AZIENDA SANITARIA UNIVERSITARIA GIULIANO-ISONTINA (ASUGI), UNIVERSITY OF TRIESTE, TRIESTE; (b) HEALTH SCIENCE INTERDISCIPLINARY CENTER, SCUOLA SUPERIORE SANT'ANNA, PISA; (c) CARDIOVASCULAR CENTER, UNIVERSITY OF FERRARA, FERRARA; (d) DEPARTMENT OF CARDIAC, THORACIC AND VASCULAR SCIENCES AND PUBLIC HEALTH, UNIVERSITY OF PADUA, PADUA; (e) CARDIOLOGY, ASST SPEDALI CIVILI DI BRESCIA AND DEPARTMENT OF MEDICAL AND SURGICAL SPECIALTIES, RADIOLOGICAL SCIENCE AND PUBLIC HEALTH, UNIVERSITY OF BRESCIA, BRESCIA

Background. Transthyretin amyloid cardiomyopathy (ATTR-CM) is an emerging cause of heart failure (HF) and mortality. Different disease-specific staging systems using serum biomarkers have been developed to predict survival. Whether those scores outperform predictive accuracy of HF prognostic scores has never been investigated so far. We sought to compare the performance of HF vs ATTR-CM staging systems for prognostic stratification.

Methods. Data from consecutive patients diagnosed with ATTR-CM at four Italian Centres for diagnosis and treatment of ATTR-CM (Trieste, Pisa, Ferrara, Brescia and Padua) between June 2016 and June 2022 were retrospectively evaluated. All patients underwent clinical evaluation, blood tests, echocardiography and TTR genotyping. Two HF staging systems, (a) cardiac and comorbid conditions HF (3C-HF) and (b) MAGGIC, and 3 ATTR-CM specific staging systems, (c) National Amyloidosis Centre (NAC), (d) Grogan et al., and (e) Kristen et al. were measured. The study outcome was all-cause mortality. Discrimination was measured by receiving operator curves (ROC) analysis. Patients were censored at entry in clinical trial or start of specific treatments.

Results. The study population included 380 patients with ATTR-CM: median age 80 [75-84] years at diagnosis, 15.7% females, 93.4% wild-type ATTR-CM, 26.9% with NYHA class III-IV symptoms, median IVS thickness 17 mm [15-19], and LVEF 53% [45-60]. Median scores with interquartile range (IQR) for each staging system were: 24 [20-28] for MAGGIC, 14 [8-21] for 3C-HF, 2 [1-2] for NAC, 1 [0-1] for Grogan et al. and 1 [0-2] for Kristen et al. Over a median follow up of 21 [12-35] months, 31.1% (n=118) of patients died. ROC analysis using all-cause death as outcome of interest provided the following area under the curve (AUC) for each staging system considered: 0.673 [0.612-0.733] for 3C-HF, 0.748 [0.692-0.805] for MAGGIC, 0.822 [0.728-0.923] for NAC, 0.717 [0.661-0.772] for Grogan et al., and, for 0.700 [0.583-0.818] for Kristen et al.

Conclusions. The NAC stage system had the best AUC for prediction of survival in ATTR-CM compared to other HF and disease-specific staging systems. Further studies will establish if the NAC stage model has better calibration for outcome prediction compared to other staging systems.

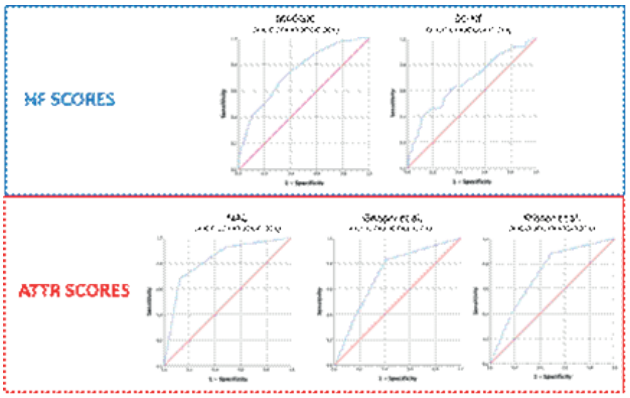

A738: AL AMYLOIDOSIS WITH CARDIAC INVOLVEMENT AND VENTRICULAR ARRHYTHMIAS

Nicola Di Nunno (a), Francesco Santoro (a), Ilaria Ragnatela (a), Grazia Casavecchia (a), Matteo Gravina (a), Michele Correale (a), Natale Daniele Brunetti (a)

(a) CARDIOLOGY UNIT, DEPARTMENT OF MEDICAL AND SURGERY SCIENCES, UNIVERSITY OF FOGGIA

Introduction. Cardiac involvement is not rare in storage diseases such as amyloidosis, with a prevalence of approximately 50% for the light chain (AL) and 30% in the trans-thyretin form (aTTR); the prevalence of ventricular arrhythmias varies from 5 to 27% in the AL forms and about 17% in the aTTR forms.

Case report. We report the case of a 53-year-old woman, admitted to the emergency room for syncope and effort dyspnea. On physical examination, heart sounds were normal; mild crackles at the pulmonary bases were however found. Admission ECG showed sinus rhythm, low peripheral lead voltages, and diffuse asymmetric negative T-waves. On blood tests, increased HS-troponin (313 ng/l) and NT-ProBNP levels (13,800 pg/ml), and proteinuria (475 mg/dl) were found. Echocardiogram revealed severe left ventricular hypertrophy with normal intracavitary dimensions, preserved systolic function (LVEF 55%), myocardial "sparkling" appearance and reduced LV-GLS (-6.5%), except for the apical segments ("apical sparing"), with suspected cardiac amyloidosis. As recommended by 2021 ESC guidelines on Heart Failure, amyloidosis work up was followed; increased kappa and lambda light chains, free and bound in serum, levels were found. At protein electrophoresis a wide gamma zone revealed to be composed, after immune-fixation, of monoclonal lambda component and diffuse kappa-lambda bands. Bone scintigraphy confirmed a mild radioisotope myocardial uptake (Perugini score 1). Cardiac MRI was also performed; PSIR sequences showed predominantly transmural myocardial fibrosis of both ventricles (non-ischemic pattern) and absence of myocardial edema. Iliac crest biopsy revealed 40% cellularity of which 25% represented by CD38 positive mature plasma cells with cytoplasmic lambda/kappa ratio in favor of lambda chains. During hospitalization, two episodes of ventricular fibrillation were effectively treated with DC shock, reason why patient underwent ICD implantation. The patient was discharged after 5 weeks in treatment with pantoprazole 20 mg, bisoprolol 1.25 mg, amiodarone 200 mg, furosemide 25 mg BID, rosuvastatin/ezetimibe 20/10 mg, metformin 500 mg BID and linagliptin 5 mg; 6 month follow up was uneventful.
Conclusions. AL amyloidosis is a multifactorial storage disease that often involves the heart causing even fatal arrhythmias. Early diagnosis and correct assessment of the extent of the disease can improve patient's prognosis.

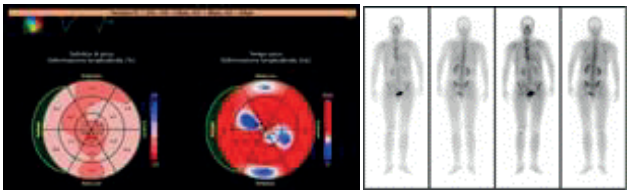

A739: RIGHT VENTRICULAR STRAIN IN CARDIAC AMYLOIDOSIS

Giulia Saturi (a), Alberto Ponziani (a), Antonella Accietto (a), Alessandro Giovannetti (a), Irene Ruotolo (a), Giuseppe Sena (a), Andrea Zaccaro (a), Angelo Giuseppe Caponetti (a), Vanda Parisi (a), Nazzareno Galiè (a), Elena Biagini (a), Christian Gagliardi (a), Simone Longhi (a)
(a) IRCCS POLICLINICO DI S ORSOLA

Background. Cardiac amyloidosis (CA) is caused by the deposition of insoluble protein fibrils in the extracellular space of cardiomyocytes. The three most common etiologies are hereditary transthyretin (ATTRv), wild type transthyretin (ATTRwt) and light chain amyloidosis (AL). Left ventricular global longitudinal strain (LVGLS) measured with speckle-tracking echocardiography has been well described and it appears to be significantly lower in patients with CA than in those with other hypertrophic phenotypes, with a typical "apical sparing" pattern. Furthermore, LVGLS can predict prognosis among patients with CA beyond LVEF. Few studies investigated the right ventricular longitudinal strain (RVGLS) pattern in ATTR-CA population and its prognostic value.
Purpose. The aim of this study is to describe RV involvement in patients with ATTR-CA with the use of speckle-tracking analysis and to explore its prognostic implications.
Methods. We retrospectively analyzed echocardiographic 2D images of 404 patients with both invasive or non-invasive diagnosis of CA evaluated between 1995 and 2021 at Tertiary Referral Amyloidosis Centre. Strain analysis were obtained using commercially available 2D strain software (TomTec 2D Software). Finally, univariate and multivariate cox regression analyses were used to analyze variables related with the occurrence of clinical events such as heart failure and death.
Results. 106 patients had ATTRwt, 104 ATTRv and 138 AL. The median age of our cohort of 221 patients with ATTR-CA was 70.9 years old (77.9 for ATTRw, 61.4 ATTRv and 65.2 AL, p<0.0001) and they were predominantly males (76.7% of study population, 88.3 for ATTRwt, 74% for ATTRv and 65.2% for AL patients, p<0.0001). Median LVEF was of 58% with no significative difference between the three etiologies. At speckle tracking echocardiography, LVGLS was reduced (median LVGLS: -12.2%; 12% in ATTRwt, 12.7% in ATTRv, 13.2% in AL). Furthermore, speckle-tracking analysis showed impaired right ventricular longitudinal function in the three etiologies. The median right ventricular four-chamber strain including the ventricular septum (RV4CSL) was -12.3% in the ATTRwt group, 15.6% in the ATTRv and 13.5% in the AL group, p: 0.031; the right ventricular free wall strain (RVFWLS) was -16.3% in the ATTRwt group, -19.8% in the ATTRv and -16.8% in the AL group. In our population study, a right ventricular apical sparing pattern was not observed, as the median right ventricular apical ratio (RVAR) was 0.5, with no substantial differences between etiologies. In the multivariate Cox proportional hazard analysis, RVGLS and LVGLS were independently associated with heart failure (respectively HR: 1.14, 95% CI: 1.008-1.280, p:0.036 and HR: 1.13, 95%CI: 1.062-1.207, p<0.0001). Finally, we explored the association between echocardiographic features and death. At univariate analysis, RVGLS and RVFWLS showed a strong correlation with death (respectively HR 1.06; 95%CI 1.025-1.088, p<0.0001 and HR: 1.037 95%CI: 1.012-1.062, p:0.003) but they did not predicts death at our multivariable regression analysis in which only LVGLS and sPAP showed and independent association.
Conclusions. Right ventricular longitudinal is an emerging parameter to evaluate right ventricular dysfunction beyond conventional echocardiographic features as it appears significantly impaired in patients with ATTR-CA. In this setting, RVFWSL might have not only a diagnostic role, but also a prognostic power, although further data from larger cohorts are needed.

A740: LEFT ATRIO-VENTRICULAR COUPLING INDEX: A NOVEL DIASTOLIC FUNCTION PARAMETER IN CARDIAC AMYLOIDOSIS

Stefano Sforna (a), Cinzia Zuchi (a), Anna Mengoni (a), Alessandro Lupi (a), Chiara Belardinelli (a), Giuseppe Ambrosio (a), Erberto Carluccio (a)
(a) CARDIOLOGY AND CARDIOVASCULAR PATHOPHYSIOLOGY, SANTA MARIA DELLA MISERICORDIA HOSPITAL, UNIVERSITY OF PERUGIA, ITALY

Background. Left atrio-ventricular coupling index (LACI) is a novel parameter coupling left atrial (LA) to left ventricular (LV) volumes at end-diastole and has the capability to capture alterations in LV diastolic properties. The aim of this study was to evaluate, in patients with cardiac amyloidosis (CA), the relationship between LACI and LV diastolic function.
Methods. Sixty-three patients with confirmed CA (mean age 79±10 years) were compared with seventy healthy people (mean age 39±16 years). Echocardiography in CA patients was performed at the time of the diagnosis and LACI was measured by the ratio between LA to LV volumes at end-diastole. Diastolic function was characterized according to current guidelines and classified into five groups (normal, grade I, grade II, grade III and indeterminate).
Results. In patients with CA, LACI was significantly higher than in controls, even after adjustment for age, gender and body mass index (0.28±0.04 vs 0.60±0.04, P<0.0001). A cut-off value of 0.45 was able to discriminate between the two populations with a sensitivity of 95% and a specificity of 94% (figure 1, area under ROC curve=0.98). In patients with CA, LACI resulted significantly correlated with LV filling pressures as estimated by E/e' ratio (beta=0.65, P<0.0001) and pulmonary artery systolic pressure (beta=0.63, P<0.0001). When these parameters were used to define diastolic dysfunction according to current guidelines, LACI significantly increased as diastolic dysfunction worsened (figure 2, P for trend <0.0001).
Conclusions. Left atrio-ventricular coupling index is a novel index able to discriminate between normal and diseased patients and, in cardiac amyloidosis, it shows good correlation with diastolic dysfunction and LV filling pressures.

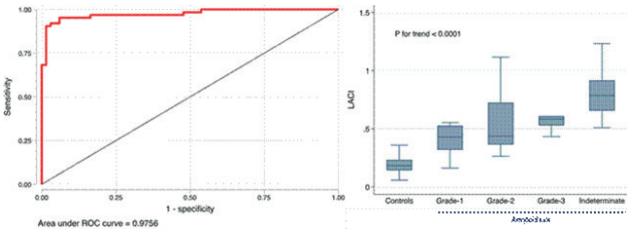

A741: STUDIO RETROSPETTIVO MONOCENTRICO: CONFRONTO TRA "CRITERI DI MARCUS" E "CRITERI DI PADUA" PER LA DIAGNOSI DI CARDIOMIOPATIA ARITMOGENA

Nicole Speziali (b), Silvia Castelletti (a), Valeria Rella (a), Paolo Cerea (a), Martino Meda (a), Silvia Ravaro (a), Sabrina Salerno (a), Davide Mariani (a), Luigi Badano (a, b), Denisa Muraru (a, b), Gianfranco Parati (a, b), Lia Crotti (a, b)
(a) IRCCS ISTITUTO AUXOLOGICO ITALIANO - OSPEDALE SAN LUCA; (b) UNIVERSITÀ DEGLI STUDI MILANO BICOCCA - DIPARTIMENTO DI MEDICINA E CHIRURGIA

Background. La cardiomiopatia aritmogena è una cardiomiopatia ereditaria caratterizzata da sostituzione fibroadiposa del tessuto cardiaco e da un aumentato rischio di aritmie ventricolari maligne e morte cardiaca improvvisa. Per anni si è pensato che essa coinvolgesse solamente il ventricolo destro e talvolta tardivamente il ventricolo sinistro. La diagnosi si basava sui criteri di Marcus et al. del 2010. Tuttavia, è diventato sempre più evidente che spesso la malattia è biventricolare e ci sono anche forme isolate del ventricolo sinistro. Per tale ragione, nel 2020 è stato proposto un aggiornamento dei criteri diagnostici dal gruppo di Padova (Padua criteria).

Obiettivi. Confrontare i due principali protocolli diagnostici per cardiomiopatia aritmogena.
Metodi. Sono stati valutati retrospettivamente tutti i pazienti inviati consecutivamente tra il 2015 e il 2023 presso il nostro Centro Cardiomiopatie. I pazienti sono stati suddivisi in diagnosi "definitiva", "borderline" o "possibile" di malattia in accordo con i due protocolli diagnostici. Sono invece stati esclusi dallo studio tutti i pazienti giunti con un sospetto di cardiomiopatia aritmogena in cui si è diagnosticata un'altra patologia.
Risultati. Sono stati inclusi in totale 111 pazienti, 38 di sesso femminile e 73 di sesso maschile, con età media: 49±18 anni. Il 90% dei pazienti è stato sottoposto ad analisi genetica e in 49 pazienti è stata riscontrata una mutazione patogenetica/verosimilmente patogenetica o una variante di incerto significato, mentre in 52 pazienti la genetica è risultata negativa per i geni ad oggi noti alla base della malattia. Il 28% dei pazienti aveva almeno un familiare con genetica positiva, mentre il 24% aveva familiarità per morte cardiaca improvvisa. Tra i pazienti il 37% riferiva sintomi correlati alla patologia quali cardiopalmo, astenia e dispnea, ma solamente 11 presentavano una classe NYHA ≥II. Inoltre, 5 pazienti hanno avuto un arresto cardiaco, 12 un episodio di tachicardia ventricolare sostenuta documentata e 16 almeno un episodio sincopale di origine aritmica. L'applicazione dei criteri di Padova permette di arrivare ad una diagnosi definitiva nel 49% dei pazienti, contro il 25% che si ottiene applicando i criteri di Marcus (p<0,001). Le diagnosi che vengono perse applicando i criteri di Marcus sono soprattutto quelle delle forme ventricolari sinistre o biventricolari, ma in misura minore anche alcune ventricolari destre.
Conclusioni. I criteri di Padova, in parte grazie al contributo della caratterizzazione tissutale fornita dalla risonanza magnetica, sono risultati più sensibili nell'identificare la cardiomiopatia aritmogena e hanno permesso di riclassificare la diagnosi del 53% dei pazienti dello studio.

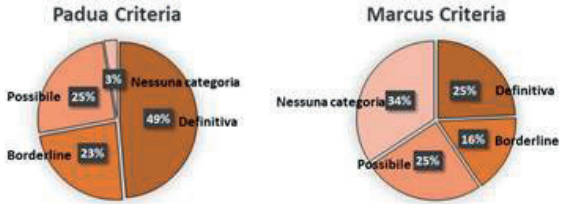

Differenze tra i due protocolli per ogni categoria di diagnosi.

Diagnose	Criteria	VD	VS	Biventricular
Definitive	Padua	10	7	37
	Marcus	8	2	17
Borderline	Padua	9	4	13
	Marcus	7	3	8
Possible	Padua	12	4	12
	Marcus	10	2	16

A742: UN "CARDIOMYOPATHY MINDSET" PER RAGGIUNGERE LA DIAGNOSI CORRETTA

Giacomo Tini (a), Federico Follesa (a), Riccardo Scirpa (a), Ludovica De Fazio (a), Lorenzo Mazzocchi (a), Edoardo Cittadini (a), Alessandro Cianca (a), Francesco Perulli (a), Damiano Venturiello (a), Erika Pagannone (a), Emanuele Barbato (a), Beatrice Musumeci (a)
(a) CARDIOLOGIA, DIPARTIMENTO DI MEDICINA CLINICA E MOLECOLARE, SAPIENZA UNIVERSITÀ DI ROMA, AZIENDA OSPEDALIERA UNIVERSITARIA SANT'ANDREA

Introduzione. La diagnosi differenziale delle aritmie ventricolari sostenute include un ampio spettro di patologie; tuttavia, non sempre si giunge ad una definizione eziologica (i.e., 'aritmie ventricolari idiopatiche'). Una adeguata integrazione di dati clinici, anamnestici, elettrocardiografici e di imaging cardiaco può aiutare ad identificare cause anche rare sottostati le aritmie ventricolari.
Caso clinico. Un uomo di 51 anni, ex-fumatore, senza altri fattori di rischio cardiovascolari (CV) né precedenti cardiologici di rilievo, veniva condotto presso il Pronto Soccorso dell'Azienda Ospedaliera Universitaria Sant'Andrea (Roma) in seguito a comparsa di cardiopalmo e presincope durante attività sportiva. L'ECG mostrava una tachicardia ventricolare alla FC di 230 bpm, a morfologia a blocco di branca destra. Il paziente veniva sottoposto a DC shock con pronto ripristino di ritmo sinusale. L'ECG post-cardioversione mostrava diffuso sottoslivellamento del tratto ST, regredito poi nell'arco dei minuti successivi; l'ecoscopia cardiaca una focale acinesia della parete infero-posteriore medio-basale. Veniva quindi effettuata coronarografia, che tuttavia mostrava coronarie epicardiche esenti da lesioni. Nella giornata successiva, ad una anamnesi approfondita, emergevano i seguenti dati: (1) il padre del paziente, all'età di 49 anni, aveva sofferto di un arresto cardiaco rianimato, ed era stato successivamente sottoposto ad impianto di defibrillatore automatico, sebbene in assenza di una diagnosi eziologica CV; (2) nel 2018, in corso di pre-ospedalizzazione per una operazione chirurgica minore, il paziente era stato sottoposto ad accertamenti cardiologici per evidenza di onde T negative in V5-6 all'ECG, tra cui un ecocardiogramma ed una scintigrafia miocardica, riferite "negative". L'ECG del paziente, inoltre, mostrava ritmo sinusale bradicardico, un normale intervallo AV, frammentazione del QRS in inferiore, T negative-piatte in I, II, III, aVF, e negative in V4-6, bassi voltaggi periferici. L'ecocardiogramma confermava la presenza di una area assottigliata ed acinetica in sede infero-posteriore medio-basale del ventricolo sinistro, che per altro appariva normocinetico, non dilatato, non ipertrofico. L'area di acinesia nel ventricolo sinistro appariva compatibile con la zona di origine della aritmia ventricolare. L'insieme di questi reperti relativi all'anamnesi familiare e personale, all'ECG e l'ecocardiogramma, così come la presentazione aritmica hanno portato a formulare un sospetto diagnostico di cardiomiopatia aritmogena a prevalente coinvolgimento del ventricolo sinistro. È stata eseguita una risonanza magnetica cardiaca che ha confermato la diagnosi ed in particolare mostrato: lieve riduzione della frazione di eiezione del ventricolo sinistro (45%) in presenza di acinesia ed assottigliamento della parete infero-posteriore medio-basale, segni di alterazione del segnale in T1 sulla parete libera del ventricolo destro e della parete inferiore del ventricolo sinistro compatibili con infiltrazione adiposa, late gadolinium enhancement subepicardico a livello della parete infero-postero-laterale medio-basale (aspetto "ring-like").
Conclusioni. Un approccio clinico "cardiomyopathy-oriented", così come peraltro suggerito dalle recenti linee guida europee dedicate, può permettere di identificare fenotipi rari di cardiomiopatia. In specifici scenari clinici, come il riscontro di aritmie ventricolari altrimenti definite idiopatiche, è sempre necessario approfondire l'iter diagnostico in presenza di specifiche 'red flags', che vanno opportunamente indagate, al fine di giungere ad una diagnosi definitiva.

A743: PREVALENCE OF WORSENING ATRIAL MECHANICS AND OUTCOME IN PATIENTS WITH CARDIAC AMYLOIDOSIS IN SINUS RHYTHM

Alessandro Tropea (a), Chiara Zocchi (d), Carlo Fumagalli (b, f), Mattia Zampieri (c), Andrea Imperatrice (a), Carlotta Mazzoni (b), Giacomo Tini (a), Gianni Pedrizzetti (e), Giulia Biagioni (b), Annamaria Del Franco (b), Alessia Argirò (b), Maria Beatrice Musumeci (a), Francesco Cappelli (b)
(a) CARDIOLOGY, CLINICAL AND MOLECULAR MEDICINE DEPARTMENT, FACULTY OF MEDICINE AND PSYCHOLOGY, SAPIENZA UNIVERSITY OF ROME; (b) CARDIOMYOPATHY UNIT, CARDIOTHORACOVASCULAR DEPARTMENT, CAREGGI UNIVERSITY HOSPITAL, UNIVERSITY OF FLORENCE; (c) DEPARTMENT OF EXPERIMENTAL AND CLINICAL MEDICINE, MEYER CHILDREN HOSPITAL, UNIVERSITY OF FLORENCE; (d) CARDIOVASCULAR DEPARTMENT, SAN DONATO HOSPITAL, AREZZO; (e) DEPARTMENT OF ENGINEERING AND ARCHITECTURE, UNIVERSITY OF TRIESTE; (f) DEPARTMENT OF ADVANCED MEDICAL AND SURGERY SCIENCES, UNIVERSITY OF CAMPANIA "LUIGI VANVITELLI", NAPLES

Introduction. Cardiac Amyloidosis (CA) increases the risk of cardio-embolic events, even without atrial fibrillation (AF). This may be due to early atrial involvement, leading to atrial dysfunction, reduced blood flow, and coagulation activation. Our study aims to look for the prevalence of atrial paralysis and correlate cardiac magnetic resonance (CMR)-derived feature tracking (FT) atrial indices with echocardiographic parameters, assessing whether they predict new-onset AF in patients with CA and in stable sinus rhythm.
Methods. From 2019 to 2022, patients with confirmed CA diagnoses (both transthyretin [ATTR-CA] - variant [v] or wild type [wt], and light chain [AL-CA]) at two referral centers underwent CMR evaluation. Cine sequences in the 2-chamber view were analyzed using an advanced imaging software (MM Medical Imaging Systems, v. 4.0) to derive LA functional parameters, including LA emptying fraction (LAEF), global longitudinal and circumferential strain (GLS, GCS), LA reservoir (LASr), LA conduit (LAScd), LA contraction (LASct). Atrial paralysis was defined by LAEF<14%. Additional analysis covered peak strain (PKS) of LA roof, inferior and anterior walls, echocardiographic diastolic parameters like LA volume indexed (LAVi), E wave, A wave, mitral deceleration time, E/A ratio, septal and lateral wall E' waves and E/E' ratio. Patients underwent 6-month follow-up visits and 24-hour ECG Holter monitoring. Patients with phenocopies or MRI-to-echocardiogram intervals exceeding 3 months were excluded.
Results. Fifty-two patients were enrolled in the study (mean age 72+10 years, 73% male). A total of 34 had ATTR-CA (vATTR-CA: 12/34, wtATTR-CA 22/34), while 18 had AL-CA. The mean LAEF was 30+14% (LAEF<14%: N=12, 23%). Patients with atrial paralysis had lower mean A-waves (44.9+11.8 cm/s vs 69.5+18.7 cm/s p<0.001). At FT analysis, patients with LAEF<14% had worse GLS (4.0%+-3.0% vs 15.1%+7.2% p<0.001), GCS (3.7%+3.2% vs 16.8%+9% p<0.001), LASr (6.0+-2.5% vs 21.6+8.3 p<0.001), LASct (-2.9%+1.7% vs -12.3%+5.5% p<0.001), LAScd (-3.3%+1.5% vs -9%+4.8% p<0.001). Roof PKS showed the highest degree of worsening deformation values among patients with atrial paralysis (5.0%+2.8% vs 22.4%+10.1% p<0.001). Among echocardiographic parameters, only the A-wave showed good discrimination for atrial paralysis (ROC-AUC: 0.846): values <48 cm/s had a sensitivity and specificity of 83% and 89%, respectively. At 24+21 months follow up, 20

patients developed incident AF with an increased risk for patients with LAEF<14% (OR: 1.8, 95% C.I. 1.2-2.9).
Conclusions. In our population of CA patients in sinus rhythm referred to CMR, prevalence of atrial paralysis was high, affecting as much as 1-in-5 patients and was predicted by reduced A-wave values and FT parameters derived by CMR. In patients in sinus rhythm, LAEF<14% was a powerful predictor of incident AF.

A744: NO REVERSE REMODELING FOLLOWING TAFAMIDIS TREATMENT FOR 1 YEAR

Alberto Aimo (a), Iacopo Fabiani (b), Federico Bargagna (b), Giorgia Panichella (a, c), Elisa Poggianti (b), Claudia Taddei (b), Olena Chubuchna (b), Vincenzo Castiglione (b), Michele Emdin (a, b), Giuseppe Vergaro (a, b)
(a) SCUOLA SUPERIORE SANT'ANNA, PISA; (b) FONDAZIONE TOSCANA GABRIELE MONASTERIO, PISA; (c) OSPEDALE CAREGGI, FIRENZE

Background. The transthyretin (TTR) stabilizer tafamidis is the only approved treatment for patients with TTR cardiac amyloidosis (ATTR-CA) and exclusive cardiac involvement. Besides a supplementary analysis of the phase III ATTR-ACT trial, no information is available on the effects of tafamidis treatment on cardiac remodeling.
Methods. Patients with ATTR-CA treated with tafamidis underwent comprehensive echocardiographic examinations at baseline and 1 year, including 4-chamber speckle-tracking analysis and an estimate of pulmonary artery wedge pressure and pulmonary vascular resistance through a validated formula. Continuous variables were compared through the Wilcoxon signed-rank test, and categorical variables through the Chi square test.
Results. Eighteen patients receiving tafamidis were evaluated (17 with wild-type ATTR-CA and 1 with the Phe64Leu mutation, 89% men, median age 80 years [interquartile range 77-83], 61% National Amyloidosis Center stage I). Among all the variables examined, only few significant differences emerged, namely: left ventricular mass index (from 180 g/m^2 [157-216] to 201 [170-215]; p=0.042), cardiac index (from 2.1 L/min/m^2 [1.9-2.3] to 1.7 [1.5-2.2]; p=0.019), right ventricular free-wall strain (from 16% [13-17] to 13% [11-15]; p=0.002), and right atrial longitudinal strain (from 11% [6-13] to 9 [6-13]; p=0.032). There was also a slight increase in the grade of aortic regurgitation.
Conclusions. The TTR stabilizer tafamidis does not seem able to induce reverse remodeling, i.e., an improvement of cardiac structure and function. Reverse remodeling might require a profound reduction of circulating TTR through gene silencers and/or the removal of cardiac amyloid deposits through monoclonal antibodies.

A745: KOWARETAKOTSUBO: ROTTURA DI CUORE IN CORSO DI CARDIOMIOPATIA DI TAKOTSUBO, CASE REPORT

Carlo Barsali (a), Federico Dell´aquila (a), Gianluca Cortis (a), Michela Zuccanti (a), Angela Maria Gurgo Di Castelmenardo (a), Beatrice Musumeci (a), Damiano Magrì (a), Emanuele Barbato (a)
(a) DIPARTIMENTO DI MEDICINA CLINICA E MOLECOLARE, LA SAPIENZA UNIVERSITÀ DI ROMA, AOU SANT'ANDREA, UNITÀ DI CARDIOLOGIA

Background. La cardiomiopatia di Takotsubo (CT), anche conosciuta come "Sindrome del cuore infranto", consiste in una forma acquisita, acuta e reversibile di disfunzione ventricolare sinistra, caratterizzata solitamente da anomalie cinetiche dei segmenti apicali del cuore. Colpisce tipicamente donne in post-menopausa, con un tipico incremento di incidenza nei mesi estivi. La prognosi della CT non è così favorevole come era stata inizialmente descritta: numerosi studi e metanalisi registrano una mortalità intraospedaliera simile a quella riportata per la sindrome coronarica acuta con sopraslivellamento del tratto ST, mentre, la mortalità extraospedaliera, risulta essere decisamente superiore rispetto alla popolazione sana e di pari età. Sebbene la fisiopatologia della CT sia complessa ed ancora non completamente nota, vari studi sostengono il ruolo centrale del sistema catecolaminergico nel contesto dell'asse cuore-cervello. Complicanze rare e potenzialmente fatali sono le aritmie ventricolari, lo shock cardiogeno acuto e la rottura di cuore. Quest'ultima complicanza, in particolare, risulta più frequente nei pazienti anziani, di sesso femminile e con un persistente sovraslivellamento del tratto ST.
Case report. Riportiamo il caso di una donna di 91 anni che giungeva in Pronto Soccorso (PS) in seguito ad episodio pre-sincopale associato ad epigastralgia persistente da oltre 24 ore. All'ingresso in PS si presentava ancora sintomatica ed in buon compenso emodinamico. La paziente riferiva di essere affetta da ipertensione arteriosa e negava ulteriori fattori di rischio e precedenti cardiologici di rilievo. Riferiva inoltre di aver avuto 5 giorni prima un importante lutto in famiglia. All'elettrocardiogramma (ECG) riscontro di fibrillazione atriale alla risposta ventricolare media di 107 bpm, onde QS in sede anteriore con contestuale sopraslivellamento del tratto ST di 3-4 mm da V2 a V6 e in DII, DIII e aVF. Agli esami ematici: Troponina I ad alta sensibilità: 8255 à 11050 pg/ml (picco). All'ecocardiogramma riscontro di acinesia dell'apice e dei settori medi che apparivano assottigliati e marcata riduzione della funzione sistolica globale del ventricolo sinistro (FE 20%). In considerazione del quadro clinico e strumentale veniva eseguita una coronarografia in urgenza che rilevava circolo coronarico esente da stenosi angiograficamente significative. Si effettuava inoltre la ventricolografia che evidenziava il classico aspetto ad "Apical Ballooning". Al termine della procedura la paziente veniva ricoverata presso il reparto di terapia intensiva cardiologica per la prosecuzione delle cure. Durante il decorso si assisteva ad una progressiva diminuzione degli enzimi di miocardionecrosi e ad un miglioramento delle condizioni cliniche generali. Tuttavia, all'ECG si osservava un lieve aumento del sopraslivellamento del tratto ST nelle derivazioni sopracitate. All'Ecocardiogramma, inoltre, permaneva il riscontro di acinesia dei segmenti apicali. In 4° giornata si verificava un arresto cardiaco in corso di attività elettrica senza polso (PEA) per cui si effettuavano le manovre di rianimazione cardiopolmonare (RCP) e, contestualmente, si eseguiva un ecocardiogramma che documentava la presenza di un versamento pericardico massivo (circa 3 cm) circonferenziale, non presente al precedente controllo ecocardiografico (effettuato circa 2 ore prima dell'evento), associato a rottura della porzione setto-apicale del ventricolo sinistro.
Conclusions. La CT è una patologia complessa, talvolta caratterizzata da complicanze potenzialmente fatali, il che impone la necessità di prestare particolare attenzione nei confronti dei pazienti con caratteristiche cliniche e strumentali predisponenti ad eventi avversi.

A746: INVERTED TAKOTSUBO SYNDROME IN PATIENT WITH CONTRAST-INDUCED ENCEPHALOPATHY AFTER TRANSCATHETER AORTIC VALVE IMPLANTATION

Chiara Belardinelli (a), Stefano Sforna (a), Matteo D´ammando (b), Claudio Cavallini (b)
(a) CARDIOLOGY AND CARDIOVASCULAR PATHOPHYSIOLOGY, SANTA MARIA DELLA MISERICORDIA HOSPITAL, UNIVERSITY OF PERUGIA, PERUGIA, ITALY; (b) DEPARTMENT OF CARDIOLOGY, SANTA MARIA DELLA MISERICORDIA HOSPITAL, PERUGIA, ITALY

Introduction. TakoTsubo syndrome (TTS) is an acute cardiac disease that can be triggered by different stressful events and can be associated with many neurological conditions, due to the known connection existing between heart and brain, although its pathophysiological mechanism is not completely understood yet.
Case report. A 83-year-old male patient, with severe aortic stenosis (peak velocity 4,61 m/s, mean gradient 53 mmHg), preserved ejection fraction (EF 55%) and anomalous origin of left coronary artery from right coronary sinus was admitted to our ward to perform transcatheter aortic valve implantation (TAVI). The procedure was completed without complications but, despite being hemodynamically stable, the patient remained disorientated in space and time with retrograde amnesia about peri-operative period. Brain CT scan showed no acute intracranial abnormalities and the neurologist concluded for a post-procedural confusional state due to a suspected contrast-induced encephalopathy (CIE); neurological symptoms completely disappeared within a few hours, so magnetic resonance was not performed. Postoperative transthoracic echocardiography (TTE) showed hypokinesis of basal segments and apical hypercontractility with mild reduction in left ventricular ejection fraction (EF 40%). Those findings could be attributed to inverted TTS and our hypothesis was reinforced by rapid increase and decrease in high sensitive troponin levels (HsTn peak value: 1452 ng/l – normal value 2,3 – 19,8 ng/l), T waves inversion in V4-V6, DI, aVL leads on electrocardiogram (EKG) and prompt improvement of left ventricular wall motion and ejection fraction at TTE (at discharge: EF 50%).
Discussion. Typically patients with TTS are admitted to the emergency room with acute cardiac symptoms arising after a stressful event (primary TTS). However, events occurring in patients hospitalized for other diseases are increasing (secondary TTS), particularly in those with neurological conditions, as observed in our case. Furthermore, TTE did not show the typical apical hypokinesis. In this rarer variant wall motion abnormalities are reversed compared to the classic form, with basal segments hypokinesis and apical hypercontractility (hence the name of inverted TTS). The existence of a correlation between different triggering events and the variant developed has yet to be proven.
Conclusions. TTS incidence is increasing; it is therefore important to analyze cases with unusual presentations to add new knowledges about a condition that is not yet fully understood.

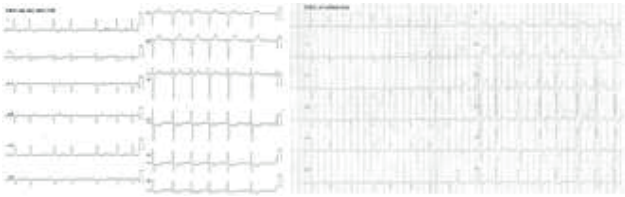

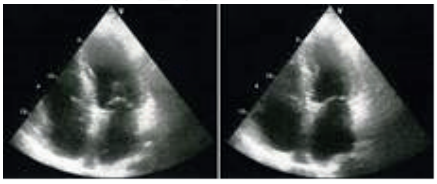

A747: REAL-WORLD CANDIDACY TO MAVACAMTEN IN A CONTEMPORARY HYPERTROPHIC OBSTRUCTIVE CARDIOMYOPATHY POPULATION

Edoardo Bertero (a), Chiara Chiti (c), Maria Alessandra Schiavo (d), Giacomo Tini (e), Paolo Costa (a), Giancarlo Todiere (f), Barbara Mabritto (g), Lorenzo-lupo Dei (h), Alessia Giannattasio (i), Davide Mariani (j), Carla Lofiego (k), Caterina Santolamazza (l), Emanuele Monda (m), Giovanni Quarta (n), Davide Barbisan (o), Giulia Elena Mandoli (p), Marco Canepa (a, b), Massimo Mapelli (q), Maurizio Sguazzotti (r), Francesco Negri (s), Simona De Vecchi (t), Michele Ciabatti (,), Daniela Tomasoni (u), Andrea Mazzanti (v), Francesca Marzo (w), Cesare De Gregorio (x), Claudia Raineri (y), Pier Filippo Vianello (z), Alberto Marchi (c), Raffaello Ditaranto (d), Andrea Barison (f), Andrea Giammarresi (n), Gaetano Maria De Ferrari (y), Silvia Priori (v), Marco Metra (u), Maurizio Pieroni (,), Giuseppe Patti (t), Massimo Imazio (s), Enrica Perugini (r), Piergiuseppe Agostoni (q), Matteo Cameli (p), Marco Merlo (o), Gianfranco Sinagra (o), Michele Senni (n), Giuseppe Limongelli (m), Enrico Ammirati (l), Fabio Vagnarelli (k), Lia Crotti (j), Luigi Badano (j), Chiara Calore (i), Federica Re (,), Giuseppe Musumeci (g), Michele Emdin (f), Emanuele Barbato (v), Beatrice Musumeci (v), Camillo Autore (z), Elena Biagini (d), Italo Porto (a, b), Iacopo Olivotto (c)

(a) CARDIOVASCULAR UNIT, DEPARTMENT OF INTERNAL MEDICINE, UNIVERSITY OF GENOVA; (b) CARDIOVASCULAR UNIT, IRCCS OSPEDALE POLICLINICO SAN MARTINO, GENOVA; (c) CARDIOMYOPATHY UNIT, CAREGGI UNIVERSITY HOSPITAL, FIRENZE; (d) CARDIOLOGY UNIT, CARDIO-THORACO-VASCULAR DEPARTMENT, IRCCS AZIENDA OSPEDALIERO UNIVERSITARIA DI BOLOGNA; (e) DEPARTMENT OF CLINICAL AND MOLECULAR MEDICINE, SAPIENZA UNIVERSITY OF ROME; (f) CARDIOLOGY AND CARDIOVASCULAR MEDICINE, FONDAZIONE TOSCANA GABRIELE MONASTERIO, PISA; (g) DIVISION OF CARDIOLOGY, AZIENDA SANITARIA OSPEDALIERA ORDINE MAURIZIANO, TORINO; (h) CARDIOLOGY UNIT, DEPARTMENT OF LIFE, HEALTH AND ENVIRONMENTAL SCIENCES, UNIVERSITY OF L'AQUILA; (i) DEPARTMENT OF CARDIAC, THORACIC, AND VASCULAR SCIENCES AND PUBLIC HEALTH, UNIVERSITY OF PADOVA; (j) DEPARTMENT OF CARIOVASCULAR, NEURAL AND METABOLIC SCIENCES, UNIVERISTY OF MILANO-BICOCCA, ISTITUTO AUXOLOGICO ITALIANO, MILANO; (k) DEPARTMENT OF CARDIOLOGY, LANCINI CARDIOVASCULAR CENTER, MARCHE UNIVERSITY HOSPITAL, ANCONA; (l) DIPARTIMENTO CARDIOLOGICO "A. DE GASPERIS", OSPEDALE CA' GRANDA, AO NIGUARDA, MILANO; (m) INHERITED AND RARE CARDIOVASCULAR DISEASE, DEPARTMENT OF TRANSLATIONAL MEDICAL SCIENCES, UNIVERSITY OF CAMPANIA "LUIGI VANVITELLI", MONALDI HOSPITAL, NAPOLI; (n) CARDIOLOGY DEPARTMENT, ASST PAPA GIOVANNI XXIII, BERGAMO; (o) CARDIOVASCULAR DEPARTMENT, AZIENDA SANITARIA UNIVERSITARIA GIULIANO-ISONTINA (ASUGI) AND UNIVERSITY OF TRIESTE; (p) DEPARTMENT OF MEDICAL BIOTECHNOLOGIES, DIVISION OF CARDIOLOGY, UNIVERSITY OF SIENA; (q) CENTRO CARDIOLOGICO MONZINO, MILANO; (r) CARDIOLOGY UNIT, CARDIAC THORACIC AND VASCULAR DEPARTMENT, IRCCS AZIENDA-OSPEDALIERA UNIVERSITARIA DI BOLOGNA; (s) CARDIOLOGY DEPARTMENT, UNIVERSITY HOSPITAL "SANTA MARIA DELLA MISERICORDIA", AZIENDA SANITARIA UNIVERSITARIA INTEGRATA FRIULI CENTRALE, UDINE; (t) UNIVERSITY OF EASTERN PIEDMONT, DIVISIONE OF CARDIOLOGY, MAGGIORE DELLA CARITÀ HOSPITAL, NOVARA; (u) CARDIOLOGY, ASST SPEDALI CIVILI AND DEPARTMENT OF MEDICAL AND SURGICAL SPECIALTIES, UNIVERSITY OF BRESCIA; (v) DEPARTMENT OF MOLECULAR MEDICINE, UNIVERSITY OF PAVIA; (w) CARDIOLOGY UNIT, INFERMI HOSPITAL, RIMINI; (x) DEPARTMENT OF CLINICAL AND EXPERIMENTAL MEDICINE, UNIVERSITY HOSPITAL OF MESSINA; (y) DIVISION OF CARDIOLOGY, DEPARTMENT OF CARDIOVASCULAR AND THORACIC MEDICINE, AOU CITTÀ DELLA SALUTE E DELLA SCIENZA DI TORINO, TORINO; (z) DEPARTMENT OF CARDIOLOGY AND RESPIRATORY SCIENCES, SAN RAFFAELE CASSINO; () CARDIOVASCULAR DEPARTMENT, SAN DONATO HOSPITAL, AREZZO; () CARDIOLOGY DIVISION, CARDIOMYOPATHIES UNIT, ST. CAMILLO HOSPITAL, ROME, ITALY

Background. Two-thirds of patients with HCM present an obstructive phenotype (HOCM) defined by left ventricular outflow tract obstruction (LVOTO). In the EXPLORER-HCM trial, the myosin inhibitor mavacamten demonstrated to reduce LVOTO and improve functional capacity in symptomatic HOCM patients.

Aims. To characterize a real-world (RW) cohort of HOCM patients, compare their characteristics with the EXPLORER-HCM trial population, and assess their eligibility to mavacamten according to EXPLORER-HCM entry criteria and current European guidelines.

Methods. We included HOCM patients under active follow-up (at least one visit in the last 12 months) at 25 Italian HCM outpatient clinics and with significant LVOTO (defined as a peak LVOT gradient ≥30 mmHg at rest or ≥50 mmHg after Valsalva maneuver or exercise) despite medical therapy or surgery. Information on medical and family history, echocardiography, cardiopulmonary exercise testing (CPET), and MT at the last visit were registered. Continuous variables were compared by Student's t test and binary ones by Chi-square test.

Results. The 25 HCM outpatient clinics participating in this survey actively follow up 1,706 patients with a history of LVOTO (HOCM). During a median time of 5.37 years from HCM diagnosis to the last clinical evaluation, pharmacological or surgical treatment reduced or resolved LVOTO in 1,044 (61.7%) of these patients, whereas 662 patients had significant LVOTO despite treatment (Figure 1). Compared to the EXPLORER-HCM trial population, RW HOCM patients were older (62±14 vs 59±12, p=0.02) and had a lower BMI (26.8±5.3 vs 29.7±4.9, p<0.0001). A history of atrial fibrillation (AF) was more common among RW patients (21.5% vs 9.8%, p=0.002). At echocardiography, LVEF was on average 8% lower (66±7% vs 74±6%, p<0.0001), LVOTO gradients at rest were higher (60±27 vs 52±29 mmHg, p=0.003), and left atrial volume was larger in RW patients vs the EXPLORER-HCM ones (LAVI 49±16 vs 40±12 mL/m^2, p<0.0001). Only 115 (17%) RW patients performed CPET at least once; in these patients, the pVO_2 was similar to the EXPLORER-HCM population (19.0±4.5 vs 18.9±4.9 mL/Kg/min, p=0.82). Of the 662 RW HOCM patients included in this study, 339 (51%) would be eligible for treatment with mavacamten according to ESC guidelines, the most common reasons for exclusion being class NYHA I (n=190) and LVOT gradient <50 mmHg (n=163). If EXPLORER-HCM trial entry criteria were applied (including age≥18 years, LVEF≥55%, and paroxysmal AF at screening), the number of patients potentially eligible to mavacamten treatment would decrease to 324 (48.9%) (Figure 1).

Conclusions. The results of this survey indicate that approximately 50% of RW HOCM patients with persistent LVOTO fulfill EXPLORER-HCM entry criteria and would therefore be eligible to treatment with mavacamten.

A748: SERIAL CHANGES IN CPET PARAMETERS IN UNTREATED PATIENTS WITH TRANSTHYRETIN CARDIAC AMYLOIDOSIS

Alessia Argirò (a), Maria Vittoria Silverii (b), Costanza Burgisser (b), Francesco Fattirolli (b), Samuele Baldasseroni (b), Carlo Di Mario (c), Mattia Zampieri (a), Giulia Biagioni (a), Carlotta Mazzoni (a), Chiara Chiti (a), Marco Allinovi (a), Andrea Ungar (b), Federico Perfetto (a), Francesco Cappelli (a)

(a) TUSCAN REGIONAL AMYLOIDOSIS CENTRE, CAREGGI UNIVERSITY HOSPITAL, FLORENCE, ITALY; (b) CARDIAC REHABILITATION UNIT, DEPARTMENT OF EXPERIMENTAL AND CLINIC MEDICINE, UNIVERSITY OF FLORENCE, FLORENCE, ITALY; (c) DIVISION OF INTERVENTIONAL STRUCTURAL CARDIOLOGY, CARDIOTHORACOVASCULAR DEPARTMENT, CAREGGI UNIVERSITY HOSPITAL, FLORENCE, ITALY

Background. Transthyretin amyloid cardiomyopathy (ATTR-CM) is associated with a progressive reduction of functional capacity. The progression of cardiopulmonary exercise testing (CPET) parameters over time is still unknown.

Methods. In this study 55 patients with ATTR-CM underwent two serial cardiological evaluation and CPET in a National Referral Center for cardiac amyloidosis (Careggi University hospital, Florence).

Results. Forty-three patients (78%) had wild type ATTR. Median age was 80 (76-83) years, 50 patients (91%) were men. At baseline median peak oxygen consumption (pVO2) was 15 (12-18) ml/kg/min, percentage of predicted pVO2 (%ppVO2) was 71 (60-83)% and VE/VCO2 slope was 31 (26-34). After a median follow-up of 14 (13-16) months, pVO2,%ppVO2 and VE/VCO2 slope were significantly worsened (-1.29ml/kg/min, CI -1.85 to -0.74, p<0.01, -4.5% CI -6.9 to -2.02, p<0.01, 8.6 CI 6 to 11, p<0.01, respectively). Furthermore, exercise time (-39 seconds, CI -59 to -19, p<0.01), exercise tolerance (-0.47 METs, CI -0.69 to -0.2, p<0.01) and peak systolic pressure (-10.8 mmHg, CI -16.2 to -5.4, p<0.01) were significantly reduced. The worsening in CPET variables did not correspond to a significant change in echocardiographic parameters.

Conclusions. Cardiorespiratory response to exercise significantly worsened over a short period of time in patients with ATTR-CM. Serial CPET may be useful to identify early disease progression.

A749: LATE GADOLINIUM ENHANCEMENT SEGMENT DISTRIBUTION IN HYPERTROPHIC CARDIOMYOPATHY WITH PRESERVED SYSTOLIC FUNCTION

Antonia Luisa Buongiorno (a), Lucia Guerisoli (a), Stefano Albani (b, d), Antonio De Luca (c), Barbara Mabritto (b), Sergio Bongioanni (b), Edoardo Bertero (a), Roberta Della Bona (a), Marco Canepa (a), Marco Merlo (c), Italo Porto (a), Gianfranco Sinagra (c), Giuseppe Musumeci (b)

(a) CARDIOVASCULAR DISEASE UNIT, IRCCS OSPEDALE POLICLINICO SAN MARTINO, GENOVA; (b) CARDIOLOGY DEPARTMENT, AZIENDA OSPEDALIERA ORDINE MAURIZIANO UMBERTO I, TORINO; (c) CARDIOVASCULAR DEPARTMENT, AZIENDA SANITARIA UNIVERSITARIA GIULIANO-ISONTINA, TRIESTE; (d) DIVISION OF CARDIOLOGY, UMBERTO PARINI REGIONAL HOSPITAL, AOSTA

Background. Hypertrophic cardiomyopathy (HCM) is characterized by myocardial fibrotic replacement that can be detected and quantified by contrast-enhanced cardiac magnetic resonance (MRI) with late gadolinium enhancement (LGE). LGE is a well-known predictor of adverse cardiovascular (CV) outcomes. So far, data about LGE segment distribution and its prognostic value are scarce.

Methods. On a large cohort of HCM patients followed in 2 Italian HCM referral centers (Mauriziano Hospital; Cattinara University Hospital), we retrospectively collected clinical and imaging data from 347 consecutive patients with preserved systolic function (LVEF ≥50%) who underwent CMR assessment from January 2005 to December 2021. The presence of LGE and the segment distribution according to the American Heart Association (AHA) 17-segment model were analyzed. CV events (CV death;

major ventricular arrythmia, MVA; hospitalization for heart failure, HHF; heart transplant, HT) during a long-term follow up (mean 7 ± 3 years) were recorded. Our aim was to evaluate the CV events incidence according to LGE segment distribution.
Results. In our population, 211 patients (61%) presented LGE. Seven patients were excluded because the LGE segment distribution was not available, leaving 204 patients (59%) included in the analysis. LGE was most frequently in the basal segments (200, 98%). In particular, segments 1 (129, 63%), 2 (56, 27%) 3 (61, 30%) 4 (35, 17%), 5 (11, 5.4%) were mostly affected by myocardial fibrosis. 108 patients (53%) presented LGE exclusively in non-septal segments although the left ventricular maximal wall thickness (LMWT) was located in the septal ones (20 mm [17; 22]). LGE segment distribution and CV events incidence according to it are presented in Figure 1. No differences in CV events occurrence were detected when we compared patients according to septal- and no-septal LGE involvement (respectively, 17% vs 14%, p=0.70). Among no-septal LGE patients who experienced adverse events, LGE was mostly detected in the inferior basal wall (7/15, 47%) and they mainly suffered from HHF (6/7, 86%).
Conclusions. In our population of HCM patients with preserved LVEF, LGE was frequently localized in segments different from the most hypertrophic ones. The distribution of LGE does not appear to be predictive of adverse CV events, although inferior basal wall involvement may be associated with a higher incidence of HHF. Nevertheless, further studies are needed.

Figure 1
LGE segment distribution (a) and CV events incidence according to fibrotic replacement (b)

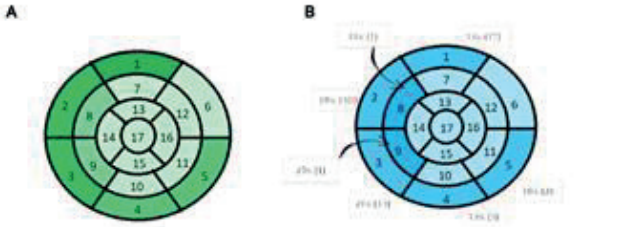

Panel a represents how frequently in each segment LGE was detected (*according to the intensity of the color*). ***Panel b*** represents the incidence of CV events (*intended as composite endpoint of HF, HT, CV death and MVAs/SCD*) for each segment
Abbreviations: CV, cardiovascular; HF, heart failure; MVAs, major ventricular arrhythmias; SCD, sudden cardiac death

A750: PAZIENTI AFFETTI DA CARDIOMIOPATIA IPERTROFICA PORTATORI DI DEFIBRILLATORE: CARATTERISTICHE CLINICHE E OUTCOME

Yasmine Caldarella (a), Alessia Giannattasio (a), Riccardo Bariani (a), Barbara Bauce (a), Domenico Corrado (a), Sabino Iliceto (a), Chiara Calore (a)
(a) DIPARTIMENTO DI SCIENZE CARDIO-TORACO-VASCOLARI E SANITÀ PUBBLICA, UNIVERSITÀ DEGLI STUDI DI PADOVA

Background. La cardiomiopatia ipertrofica è una patologia ereditaria del muscolo cardiaco caratterizzata da un aumentato rischio di aritmie ventricolari e arresto cardiaco. L'impianto del defibrillatore (transvenoso o sottocutaneo) nei pazienti affetti ha cambiato la storia naturale della patologia, consentendo una riduzione significativa della mortalità per morte cardiaca improvvisa (fino allo 0,5% per anno). La stratificazione del rischio aritmico si basa attualmente su un approccio multiparametrico, che tenga conto di caratteristiche anamnestiche, cliniche e di dati ricavati dalle tecniche di imaging (in particolare la risonanza magnetica cardiaca), considerati singolarmente o in combinazione.
Metodi. In questo studio monocentrico, è stata eseguita un'analisi descrittiva delle caratteristiche della popolazione dei pazienti affetti da cardiomiopatia ipertrofica portatori di defibrillatore afferenti all'ambulatorio dedicato presso il centro per le Cardiomiopatie Aritmiche dell'Azienda Ospedale-Università di Padova, sottoposti a valutazione tra gennaio 2019 e dicembre 2022.
Risultati. Nell'ambito di una popolazione di 274 pazienti con cardiomiopatia ipertrofica, il gruppo dei portatori di defibrillatore è risultato composto da 65 soggetti, di cui 45 (69%) di sesso maschile, con un'età media di 59 anni. La maggior parte dei pazienti (81%) è risultata portatrice di un defibrillatore transvenoso. L'impianto del defibrillatore è stato effettuato in prevenzione secondaria nel 12% dei casi (8 pazienti con arresto cardiaco rianimato). Nell'ambito dei fattori favorenti l'impianto di defibrillatore: il 18% presentava familiarità per morte cardiaca improvvisa, il 29% aveva avuto una sincope non spiegata, il 21% risultava affetto da una forma massiva di ipertrofia e il 18% aveva una frazione di eiezione inferiore al 50%, il 69% presentava run di TVNS all'ECG secondo Holter delle 24 ore ed il 43% mostrava alla risonanza magnetica cardiaca un late gadolinium enhancement molto esteso (definito come>15% della massa miocardica); solamente il 6% presentava aneurisma apicale. Nel 43% dei casi erano presenti due fattori di rischio aritmico, nel 15% tre fattori ed infine nel 12% vi era la combinazione di 4 o più fattori di rischio. L'età media all'impianto è risultata pari a 51 anni. La durata media del follow up (definita come tempo dall'impianto del defibrillatore all'ultima valutazione specialistica) è risultata pari a 8 anni. Nell'ambito di questa popolazione, sono state erogate terapie appropriate nel 15% dei pazienti (10 soggetti), con un sottostante ritmo da tachicardia ventricolare sostenuta nel 80% dei casi (8 pazienti, mentre 2 pazienti presentavano un sottostante ritmo da fibrillazione ventricolare). Tra coloro che hanno avuto interventi del defibrillatore, solo 2 pazienti (20%) avevano ricevuto indicazione all'impianto in prevenzione secondaria. Come complicanze correlate al device, 3 pazienti (4%) hanno avuto degli shock inappropriati, mentre in 8 casi (12%) vi sono state altre complicanze, prevalentemente infezioni e failure dell'elettrocatetere. Tra i pazienti portatori di defibrillatore, 4 soggetti (6%) sono deceduti (2 casi di morte per scompenso cardiaco, 1 caso di morte per shock settico, 1 caso di morte per stroke ischemico).
Conclusioni. Sebbene si tratti di uno studio osservazionale limitato alla casistica di un singolo centro di riferimento, questo studio offre delle interessanti informazioni riguardo le caratteristiche, l'incidenza di eventi e l'outcome, sia in termini di interventi che di complicanze, di una cospicua popolazione di pazienti con cardiomiopatia ipertrofica portatori di ICD.

A751: CARDIAC TRAITS AND GENOTYPE-PHENOTYPE CORRELATION AMONG PATIENTS AFFECTED BY LAMINOPATHIES: A PROSPECTIVE STUDY

Maria Cristina Carella (a), Paolo Basile (a), Michele Luca Dadamo (a), Francesca Amati (a), Eugenio Carulli (b), Francesco Loizzi (d), Sandro Sorrentino (c), Marco Dicorato (a), Stefano Ricci (a), Rosanna Bagnulo (c), Matteo Iacoviello (c), Vincenzo Ezio Santobuono (a), Andrea Igoren Guaricci (a), Nicoletta Resta (c), Marco Matteo Ciccone (a), Cinzia Forleo (a)
(a) CARDIOVASCULAR DISEASE SECTION, INTERDISCIPLINARY DEPARTMENT OF MEDICINE (DIM), UNIVERSITY OF BARI ALDO MORO, UNIVERSITY HOSPITAL CONSORTIUM POLYCLINIC OF BARI, BARI; (b) INTERNAL MEDICINE SECTION, DEPARTMENT OF PRECISION AND REGENERATIVE MEDICINE AND IONIAN AREA (DIMEPRE-J), UNIVERSITY OF BARI ALDO MORO, UNIVERSITY HOSPITAL CONSORTIUM POLYCLINIC OF BARI, BARI; (c) MEDICAL GENETICS UNIT, DEPARTIMENT OF PRECISION AND REGENERATIVE MEDICINE AND IONIAN AREA (DIMEPRE-J), UNIVERSITY OF BARI ALDO MORO, UNIVERSITY HOSPITAL CONSORTIUM POLYCLINIC OF BARI, BARI; (d) CARDIOLOGY UNIT, "SS. ANNUNZIATA" HOSPITAL, TARANTO

Background. Evidence on arrhythmic risk stratification in patients with LMNA-related dilated cardiomyopathy (DCM) and hypokinetic non-dilated cardiomyopathy (HNDCM) is constantly evolving. Knowledge on this hot topic can influence clinical decisions concerning implantable cardioverter defibrillator (ICD) therapy: in accordance with international guidelines on the prevention of sudden cardiac death (SCD), the indications for ICD implantation do not follow the canonical criteria. ICD implantation in primary prevention should be considered (class of recommendation: IIa; level of evidence: B) in patients with a pathogenic mutation in LMNA gene, if the estimated 5-year risk of life-threatening ventricular arrhythmia (VA) is ≥10% and in the presence of non-sustained ventricular tachycardia (NSVT) or LVEF <50% or atrioventricular (AV) conduction delay. Risk prediction score for malignant VA (MVA) in Laminopathies is based on Wahbi model, which includes non-missense LMNA mutation, whose role as an established risk factor for sudden cardiac death has often been questioned.
Methods. We conducted a study to investigate the association between adverse outcomes and the type of LMNA mutation (missense or non-missense) in a single-center cohort of 54 patients. Upon enrolment in the study, all patients underwent a clinical evaluation consisting of anamnestic data collection, vital signs monitoring and symptom analysis, 12-lead ECG, 24-hour Holter ECG monitoring, transthoracic echocardiogram and cardiac magnetic resonance. In addition, intracardiac devices were monitored and programmed. The major cardiac endpoints (MACE) were cardiac death, heart transplantation, and MVA, defined as sustained ventricular tachycardia (VT), ventricular fibrillation (VF), SCD (occurring within 1 hour of acute symptoms), or appropriate treatment (antitachycardia pacing or shock) by an ICD. The minor cardiac endpoints were worsening of heart failure functional class, AV block of any degree or any other form of intra- or atrioventricular conduction disturbance, supraventricular or ventricular tachyarrhythmias or any structural or functional echocardiographic abnormality.
Results. The study included 20 probands (37%). The median age at the first clinical manifestation was 37 ± 15 years. The mutation type of the LMNA gene was distributed as follows: missense in 26 patients (48%), insertions in 16 (30%), deletions in 5 (9%), nonsense in 6 (11%) and frameshift in 1 (2%). No alternative splicing mutations were identified. Among the 26 (48%) missense mutation carriers, 2 (8%) died, 4 (15%) were admitted to the heart transplant list or underwent transplantation, and 8 (31%) received appropriate ICD shocks (with a composite rate of cardiovascular adverse events of 35%). No statistically significant differences in cardiovascular adverse events were identified between the missense and non-missense groups (p value=0.598). An interesting result emerging from our study is that no association was identified between non-missense mutations and a worse cardiac phenotype.

Conclusions. Our data raises consideration on the current guideline recommendations and could suggest that some missense mutations also deserve special attention when the risk of SCD is estimated. However, prospective multicenter data are still lacking and are advisable.

A752: BIOHUMORAL AND ECHOCARDIOGRAPHIC CORRELATES OF TAFAMIDIS TREATMENT IN TRANSTHYRETIN CARDIAC AMYLOIDOSIS

Vincenzo Castiglione (a, b), Alberto Aimo (a, b), Veronica Musetti (a, b), Silvia Masotti (b), Chiara Sanguinetti (c), Claudio Passino (a, b), Michele Emdin (a, b), Maria Franzini (c), Giuseppe Vergaro (a, b)
(a) HEALTH SCIENCE INTERDISCIPLINARY CENTER, SCUOLA SUPERIORE SANT'ANNA, PISA, ITALY; (b) FONDAZIONE TOSCANA GABRIELE MONASTERIO, PISA, ITALY; (c) DEPARTMENT OF TRANSLATIONAL RESEARCH AND NEW TECHNOLOGIES IN MEDICINE AND SURGERY, UNIVERSITY OF PISA, PISA, ITALY

Background. Tafamidis stabilizes the transthyretin (TTR) tetramer slowing transthyretin cardiac amyloidosis (ATTR-CA) progression. The effect of tafamidis on circulating levels of TTR and the associated retinol-binding protein 4 (RBP4), as well as on other biohumoral and echocardiographic markers of cardiac involvement is yet to be clarified.
Purpose. We aimed to assess changes in biohumoral and echocardiographic findings after initiation of tafamidis treatment in ATTR-CA patients.
Methods. Twenty-six ATTR-CA patients (25 ATTR wild type and 1 ATTR variant; 96% males, age 81 [76-82] years; ejection fraction - EF - 50% [45-55]) underwent a clinical, biohumoral (TTR, RBP4, creatinine, troponins and natriuretic peptides, renin, aldosterone, catecholamines) and echocardiographic assessment prior to receiving tafamidis and after 3 and 6 months of treatment. Fourteen patients completed the 6-month follow-up. A historical cohort of 7 ATTR-CA patients (all ATTR wild type males; median age 81 [79-90] years; EF 50% [45-57]) untreated with tafamidis and with available data on TTR and RBP4 at 6 months apart served as controls.
Results. TTR levels significantly increased from baseline (22.4 [19.1-24.7] mg/dL) to 3 months post-tafamidis (29.6 [26.4-34.7] mg/dL, p<0.001), reaching a plateau at 6 months (32.8 [25.7-36.3] mg/dL, p=0.289). Conversely, RBP4 levels remained stable following tafamidis introduction (baseline: 5.28 [4.25-6.08] mg/dL; 3 months: 4.19 [4.74-5.68] mg/dL, p=0.063 vs. baseline; 6 months: 4.98 [4.35-5.95] mg/dL, p=0.091 vs. 3 months). Cardiac biomarker levels and neurohormones did not change significantly between baseline and 6 months post-tafamidis, with the sole exception of an increase in aldosterone (baseline: 72 [48-100] ng/dL; 6 months: 91 [73-181] ng/dL, p=0.028). Creatinine slightly increased between the 2 timepoints (baseline: 1.21 [0.92-1.36] mg/dL; 6 months: 1.40 [1.15-1.65] mg/dL, p=0.013). Functional (baseline EF 50% [45-55]; 6-month EF: 50% [49-56], p=0.422) and structural (baseline left ventricular mass index - LVMI - 183 [130-214] g/m^2; 6-month LVMI 167 [125-229] g/m^2, p=0.950) echocardiographic parameters remained unchanged at the 2 assessments. In patients not receiving tafamidis, TTR levels remained stable at 6 months (baseline: 22.3 [20.1-25.6] mg/dL; 6 months: 22.4 [20.2-27.7] mg/dL, p=0.866).
Conclusions. Tafamidis consistently increases TTR levels by 3 months in ATTR-CA patients, reflecting its stabilizing effect on TTR. Measurement of TTR, but not RBP4, might serve as a surrogate for tafamidis efficacy. Nonetheless, a follow-up longer than 6 months may be needed to detect eventual changes in cardiac and neurohormonal biomarkers as well as echocardiographic parameters post-tafamidis introduction.

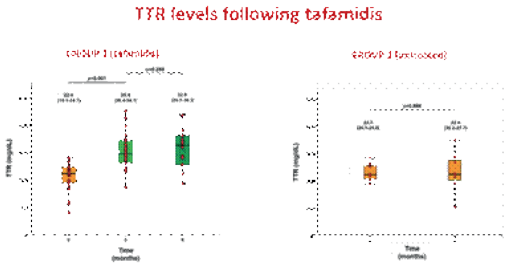

A753: A CASE OF CARDIAC METASTASIS OF MELANOMA

Angelica Cersosimo (a), Marianna Adamo (a), Gianmarco Arabia (a), Carlo Mario Lombardi (a), Marco Metra (a), Enrico Vizzardi (a)
(a) UNIVERSITY OF BRESCIA

Aims. Melanoma is a malignant neoplasm of melanocytes that accounts for the majority of skin cancer deaths despite comprising less than 5% of all cutaneous malignancies. Metastatic melanoma is responsible of a poor prognosis, with a median survival of 9 months and a long-term survival rate of 10%.
Methods. We describe a case of a 39-year-old woman with chest pain described as sharp, left sided, associated with dyspnea (NYHA III) during the previous two months. On physical examination she had blood pressure 80/40 mmHg, heart rate 78 bpm. She was oriented, apiretic and eupnoic. Her electrocardiogram showed sinus rhythm and incomplete right bundle branch block without ischemic changes. The patient had a history of melanoma excision with negative sentinel lymphnode in 2020 (pT2aN0M0). In the emergency room, a transthoracic echocardiogram (TTE) was performed and showed sessile mixed echogenic mass in the right ventricle almost completely occluding the apex and the right ventricular outflow tract (RVOT). The right ventricle appeared dilated, the pulmonary systolic pressure (PASP) was 65-70 mmHg, no alterations affecting the valvular systems and the left ventricle. She was admitted to intensive care unit. She underwent a brain, chest and abdomen computerized tomography (CT) which was negative. A cardiac magnetic resonance (RM) was performed and showed right ventricular volumes increased (170 ml end diastolic, 118 ml end diastolic), with 30% ejection fraction. The right ventricle is almost occupied by an expansive intracavitary formation with growth towards the outflow tract up to the pulmonary arterial trunk and its main branches. The lesion is adherent and non-cleaving from the mid-cavity interventricular septum, has a hyperintense signal on T2 sequences and demonstrates gradual enhancement after contrast in the dynamic perfusion phases with persistence of inhomogeneous enhancement in late sequences. The lesion is compatible with possible metastasis. No alterations in the left ventricle occurred. After discussing the case in heart team, in consideration of the positive anamnesis for melanoma excision and the size of the intracavitary mass, the patient underwent cardiac surgery to excise the right ventricular mass with good results. No complications after surgery occurred. The histological examination showed the positivity of the lesion only to the BRAF marker. She was therefore also directed towards oncological support. Postoperative TTE and cardiac RM were normal. 6 months after surgery, cardiac RM showed no evidence of disease.
Conclusions. Despite the better surveillance and diagnostic, prognostic, and preventative measures, the landscape of melanoma continues to progress. Clinical trials continuing to address nodal staging, completion lymphadenectomy, and appropriate margin selection will shape future surgical standards. Immunotherapies provide new therapeutic options and reliably improve overall survival.

A754: EFFICACY AND SAFETY OF COLCHICINE FOR THE TREATMENT OF PERICARDITIS WITH MYOCARDIAL INVOLVEMENT

Valentino Collini (a), Alessandro Andreis (b), Federico Angriman (a, c), Luca Siega Vignut (a, c), Marzia De Biasio (a), Massimo Imazio (a)
(a) S.C. CARDIOLOGIA DI UDINE; (b) S.C. CARDIOLOGIA TORINO; (c) SCUOLA DI SPECIALITÀ MALATTIE CARDIOVASCOLARI, TRIESTE

Background. Clinical trials have evaluated the efficacy and safety of colchicine only in simple pericarditis, excluding cases of concomitant myocarditis.
Objectives. To evaluate the efficacy and safety of colchicine for the treatment of the first attack of acute pericarditis with concomitant myocardial involvement.
Methods. Double-centre retrospective cohort study, analysing consecutive patients admitted for first attack of pericarditis with myocarditis. Patients who received colchicine in addition to conventional therapy constituted the study group, while patients who received only conventional therapy constituted the control group. The primary efficacy end point was the time to the first recurrence. Propensity score matching was used to generate 2 groups of patients with similar baseline characteristics. Colchicine-associated side effects were analysed as safety end-point.
Results. A total of 175 patients (mean age 46 (SD 40) years, 25% females, 88% with idiopathic/viral etiology, 79 (45%) treated with colchicine) were included. After a median follow up of 25.3 (IQR 8.3 - 45.6) months, 58 (33%) patients had recurrences. The propensity score generated 73 pairs of patients. In this population a lower incidence of recurrence (respectively 19% vs. 45%; p=0.001) and a longer event-free survival (p=0.05) was observed among patients receiving colchicine. In multivariable analysis women (HR 2.28, 95% CI 1.23 to 4.24; p=0.009) and corticosteroid use (HR 2.17, 95% CI 1.12 to 4.19; p=0.021) were independent risk factors for recurrences. Colchicine-associated side effects were mild and occurred in 3 (2%) patients.
Conclusions. In patients with first attack of pericarditis associated with myocardial involvement, colchicine was safe and efficacious for the reduction of recurrences.

Figure 1. Event-free survival according to colchicine use in the two cohorts after propensity-score matching.

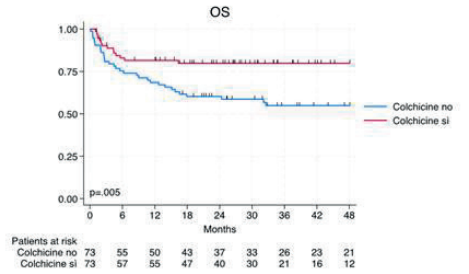

A755: ACUTE CORONARY SYNDROME IN CARDIAC AMYLOIDOSIS: A CASE REPORT

Laura De Michieli (a), Donatella Tansella (a), Monica De Gaspari (a), Andrea Pauro (a), Giulio Sinigiani (a), Stefania Rizzo (a), Mila Della Barbera (a), Sabino Iliceto (a), Martina Perazzolo Marra (a), Tamara Berno (a), Cristina Basso (a), Alberto Cipriani (a)
(a) DEPARTMENT OF CARDIAC, THORACIC, VASCULAR SCIENCES AND PUBLIC HEALTH

Clinical history. A 72-year-old man with unremarkable past medical history and no significant cardiovascular risk factors presented to our hospital complaining of new-onset chest pain, with typical angina characteristics; the electrocardiogram showed atrial fibrillation with rapid ventricular response (140 bpm) and diffuse ST-depression (with specular ST elevation in aVR). No clinical signs of heart failure were observed. Serial testing of cardiac biomarkers revealed a significant increase of high sensitivity cardiac troponin I values from 1138 ng/L to 37714 ng/L. Transthoracic echocardiogram showed a severely dilated and non-hypertrophic left ventricle (LV) with depressed systolic function (ejection fraction 30%) in the presence of diffuse hypokinesia. He underwent urgent coronary angiography with evidence of non-obstructive coronary artery disease. Given the severe impairment of LV systolic function of unknown origin and a progressive deterioration of clinical conditions, endomyocardial biopsy was deemed required. Specimen analysis showed positive results at Congo red staining, suggestive of amyloid infiltration. Amyloid burden was quantified as approximately 45%, with a prevalent vascular/perivascular localization; mild replacement type fibrosis, myocardial vacuolization, signs of inflammation (15 CD3+ mm^2 and 28 CD68+ mm^2) were also detected. Subsequent immunogold electron microscopy completed the diagnosis as immunoglobulin lambda light chain amyloidosis (AL). After these unexpected results, all diagnostic procedures were focused on clinical characterization and staging of AL amyloidosis, including laboratory investigations showing elevated serum immunoglobulin free light chain (FLC) lambda (272 mg/L) with a differential between involved and uninvolved FLC of 241 mg/L, urine electrophoresis showing lambda Bence Jones proteinuria, brain natriuretic peptide 1622 ng/L. Bone marrow biopsy showed a significant increase of plasma cells, diagnostic for multiple myeloma, and specific hematological chemotherapy was started accordingly.
Conclusions. Although uncommon, patients with AL cardiac amyloidosis can present with an acute coronary syndrome. Amyloid vascular/perivascular involvement combined with myocardial toxicity typical of AL amyloidosis may be the substrate of acute myocardial injury. AL cardiac amyloidosis should be considered in the differential diagnosis of patients with acute myocardial infarction and non-obstructive coronary artery disease.

A756: DIAGNOSTIC IMPLICATIONS FOR DCM AND NDLVC FROM 2023 ESC GUIDELINES

Riccardo Fracassi (a), Ana Luisa Calixto Rodrigues (b), Deni Kukavica (a, b), Alessandro Trancuccio (a, b), Alessandra Gualco (b), Maira Marino (b), Massimo Morini (b), Mirella Memmi (b), Patrick Gambelli (b), Carlo Napolitano (a, b), Andrea Mazzanti (a, b), Silvia Giuliana Priori (a, b)
(a) UNIVERSITÀ DEGLI STUDI DI PAVIA; (b) ICS MAUGERI PAVIA

Background. Dilated cardiomyopathy (DCM) is a heterogeneous entity with diverse etiological and phenotypic manifestations. The 2016 DCM diagnostic criteria failed to diagnose the early stages of the disease, limiting timely interventions. In 2023, European Society of Cardiology (ESC) updated the diagnostic criteria to include patients with left ventricular (LV) dilatation and an LV ejection fraction (LVEF) <50%. Moreover, a novel clinical entity called non-dilated LV cardiomyopathy (NDLVC) was devised to include patients with LV systolic dysfunction in the absence of dilatation. The prevalence of DCM and NDLVC diagnosis according to the new definition is currently unknown.
Purpose. To compare the prevalence of DCM and NDLVC according to the 2023 criteria to the prevalence as per the 2016 criteria; and to assess the relative genetic background.
Methods. Since 2000 until 2022, consecutive probands with a referral diagnosis of suspected DCM were included into a dedicated database. All patients underwent a clinical, echocardiographic, and genetic evaluation. Diagnosis of DCM according to the 2016 criteria ("2016 DCM") was defined as LVEF <45% and LV end-diastolic diameter (LVEDD)>58 mm for males or>52 mm for females. Diagnosis of DCM according to 2023 criteria ("2023 DCM") was made in the presence of LVEF <50% and LV dilatation. NDLVC ("2023 NDLVC") was defined as LVEF <50% without dilatation. The prevalence of positive diagnoses according to the 2016 and the 2023 criteria was compared. The genetic background, defined as the presence of a pathogenic (P) or likely pathogenic (LP) mutation on one of the causative genes, was compared among the diagnostic groups. Statistical analysis was performed using RStudio Version 4.1.1 (Boston, MA, USA).
Results. 127 probands (97/127 males [76%], mean age 49±12 years) with a diagnostic suspicion of DCM were referred to our center. Of these, 69/127 (54%) individuals (56/69 males [81%], mean age 51±11 years) met the "2016 DCM" diagnostic criteria. In these 69 patients, genetic analysis identified a P/LP mutation in 15/69 (22%) with LMNA gene mutations being most common (5 of 15 genotype positive patients, 33%), followed by DSP (2/15, 13%) and RBM20 (2/15, 13%). Application of the "2023 DCM" diagnostic criteria led to a diagnosis in 78/127 (61%) patients, with 9/127 (7%) more patients being diagnosed with DCM (2 male patients with high-risk genotypes). Diagnosis of NDLVC was made in 29/127 (23%) patients (23/29 males [79%], mean age 40±8 years), such that a significantly larger proportion of patients had a clinically actionable diagnosis (102/127 patients with 2023 criteria vs. 69/127 patients with 2016 criteria, p<0.001). In NDLVC patients, genetic analysis identified a P/LP mutation in 7/29 (24%) with LMNA gene mutations being most common (4 of 29 genotype positive patients, 14%). Relevantly, the comparative yield of genetic testing was not different between "2023 DCM" (17/78, 22%) and "NDLVC" groups (7/29, 24%; p=0.796).
Conclusions. In our cohort, the application of 2023 guidelines led to a 12% increased diagnostic yield of DCM as compared to 2016 criteria. Overall, the use of 2023 guidelines significantly increased the clinical actionability as an additional 23% of patients were diagnosed with NDLVC. The similarity of genetic background suggests that DCM and NDLVC do represent a clinical spectrum, thus encouraging earlier therapeutic intervention in the latter group.

A757: PREDICTORS OF MAJOR BLEEDING IN TRANSTHYRETIN CARDIAC AMYLOIDOSIS

Alessandro Giovannetti (a), Annamaria Del Franco (c), Chiara Chiti (c), Alberto Ponziani (a), Irene Ruotolo (a), Giulia Biagioni (c), Carlotta Mazzoni (c), Giulia Saturi (a), Antonella Accietto (a), Mattia Zampieri (c), Carmine Pizzi (a, d), Elena Biagini (a, d), Simone Longhi (a, d), Francesco Cappelli (b, c)
(a) DIMES - DIPARTIMENTO DI MEDICINA SPECIALISTICA, DIAGNOSTICA E SPERIMENTALE - ALMA MATER STUDIORUM UNIVERSITÀ DI BOLOGNA; (b) DEPARTMENT OF EXPERIMENTAL AND CLINICAL MEDICINE - UNIVERISTY OF FLORENCE; (c) TUSCAN REGIONAL AMYLOID CENTER, CAREGGI UNIVERISTY HOSPITAL, FLORENCE; (d) U.O. CARDIOLOGIA, IRCSS AZIENDA OSPEDALIERO-UNIVERISITARIA DI BOLOGNA

Background. Atrial fibrillation has a high prevalence in patients with cardiac amyloidosis (CA) which frequently needs for anticoagulant therapy (OAC). The OAC benefit in prevention of thromboembolic events must be weighed against bleeding events that are already described in immunoglobulin light chains CA. However, there is no data about predictors of major bleeding in transthyretin CA (ATTR-CA).
Methods. We analyzed retrospectively 393 ATTR-CA patients (64 ATTR-mutated and 329 ATTRwild-type) evaluated in two European referral centers during a median follow-up of 24 months. The endpoint of the study was the evaluation of predictors of major bleeding according with ISTH (International Society on Thrombosis and Haemostasis) classification using clinical, instrumental and laboratory data.
Results. Out of 393 patients (median age of 79 years (IQR 74–83) and 87,5% of male gender) 329 patients (83,7%) were diagnosed with CA-ATTRwt and 64 (26,3%) patients with CA-ATTRm. Patients with NYHA I, II or III-IV functional class were respectively 96 (24,4%), 220 (56%) and 77 (19,6%); 175 (44,5%) patients had chronic kidney disease with an eGFR <60 ml/min and 62 (15,8%) had diabetes and dyslipidemia. The median of hemoglobin, NT-proBNP, left ventricle thickness and CHA2DS2-VASc score were 13,5 g/dL (IQR 12,4-14,8), 2406 pg/mL (IQR 997-4536), 17 mm (IQR-15-19) and 4 (IQR 3-5) respectively. 184 (46,8%) patients were on OAC therapy at first evaluation and 88 (22,4%) patients started OAC during the follow up. Major bleeding occurred in 30 patients (7,6%) during follow-up. After univariate analysis, at multivariate analysis heart failure hospitalization (HR 2.5, 95% CI, 1.47-4.22, p<0.001), history of bleeding (HR 3.1, 95% CI, 0.92-9.06, p=0.049) and CHA2DS2-VASc score (HR 1.42, 95% CI, 1.06-1.93, p=0.022) as a combination, and hemoglobin (HR 0.56, 95% CI, 0.44-0.77, p<0.001), diabetes mellitus (HR 3.43, 95% CI, 1.19-9.48, p=0.018) and left ventricle thickness (HR 1.28, 95% CI, 1.07-1.54, p=0.009) as another remained as indipendent predictors of major bleeding in patients with ATTR-CA.
Conclusions. Major bleedings in ATTR-CA are more frequent in patients with high hypertrophy phenotype, anemia or previous bleeding, diabetes mellitus, high CHA2DS2-VASc score and heart failure. These features could help clinicians in balancing the risks of thromboembolism and bleeding, particularly when OAC should be started.

A758: EVIDENZE DI "HOT PHASE" ALL'IMAGING IN UNA CARDIOMIOPATIA ARITMOGENA LEFT DOMINANT

Cosimo Granitto (a), Giulia Passarini (b), Gabriele Guardigli (b), Matteo Arzenton (a)
(a) UNIVERSITÀ DEGLI STUDI DI FERRARA; (b) AZIENDA OSPEDALIERO-UNIVERSITARIA DI FERRARA

Caso clinico. Paziente di 49 anni senza precedenti anamnestici di rilievo. Durante pranzo al ristorante con la famiglia insorgenza di arresto cardiocircolatorio da fibrillazione ventricolare, trattato in loco con defibrillazione e manovre rianimatorie con ripresa del ROSC in 15 minuti. All'elettrocardiogramma evidenza di ritmo sinusale con onde T negative nelle derivazioni precordiali sinistre. Agli esami ematici riscontro di significativo rialzo degli enzimi di danno miocardico e di ipopotassiemia

(K 2.8 mmol/ml). Veniva eseguita coronarografia con riscontro di albero coronarico esente da lesioni significative. All'ingresso in UTIC eseguito ecocardiogramma che mostrava ventricolo sinistro lievemente dilatato, ipocinesia della parete inferiore media e della parete posterolaterale medio-apicale con frazione di eiezione ai limiti inferiori di norma. Per ulteriore approfondimento diagnostico si eseguiva RM cardiaca che confermava i difetti di cinetica regionale riscontrati all'ecocardiogramma e segnalava in queste aree presenza di sostituzione adiposa e di LGE non ischemico a distribuzione sub-epicardica ("stria pattern") esteso anche alla parete anteriore basale con distribuzione tipica "ring-like". Segnalato inoltre, a livello della parete laterale medio-basale ed inferiore media, coesistente quota di edema miocardico. Assenza di alterazioni morfostrutturali delle sezioni destre. Tali reperti strumentali sono risultati compatibili con cardiomiopatia aritmogena in variante left-dominant e coesistenza di segni di miocardite in quadro suggestivo per "hot phase". Come da linee guida si procedeva ad impianto di ICD e a prelievo ematico per indagine genetica.

Discussione. La cardiomiopatia aritmogena è una malattia genetica associata nella maggior parte dei casi a mutazioni di proteine desmosomiali e caratterizzata da progressiva sostituzione fibro-adiposa del miocardio, che predispone all'insorgenza di aritmie ventricolari e morte improvvisa. Sebbene in passato si riteneva che fosse una malattia esclusiva del ventricolo destro, negli ultimi anni sono state descritte varianti che interessano precocemente e prevalentemente il ventricolo sinistro, definite "Left dominant". Inoltre la progressione della malattia sembrerebbe manifestarsi con "hot phases", ovvero fasi di riacutizzazione nel contesto della malattia stabile, che possono essere silenti o caratterizzate da quadri clinici simil-miocarditici con alterazioni dinamiche all'ECG, rialzo degli enzimi cardiaci e aritmie fatali. Tali acutizzazioni di carattere infiammatorio sono riscontrabili alla risonanza magnetica cardiaca come aree di edema miocardico in contesto di sostituzione fibro-adiposa sub-epicardica più tipica della patologia.

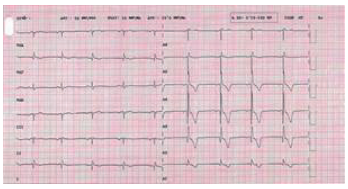

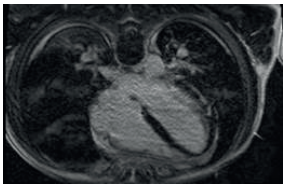

A759: DOMINO EFFECT IN TAKOTSUBO: ALWAYS BENIGN CARDIOMYOPATHY?

Giustina Iuvara (a), Salvatore Bonanno (a), Federica Cocuzza (a), Angelo Dimartino (a), Nicola Ferrara (a), Giuseppe Dattilo (a), Pasquale Crea (a), Antonio Micari (a), Gianluca Di Bella (a), Scipione Carerj (a)

(a) DIPARTIMENTO DI MEDICINA CLINICA E SPERIMENTALE, UOC DI CARDIOLOGIA CON UTIC, UNIVERSITÀ DEGLI STUDI DI MESSINA, MESSINA, ITALIA

Background. The etiology of TakoTsubo cardiomyopathy, defined as a transient left ventricular disfunction in absence of significant coronary artery stenosis still remains unclear. This syndrome mainly occurs in postmenopausal women and is often associated with emotional or physical stress, such as interventional procedures (for example pacemaker implantation), and it is likely triggered by an increase in adrenergic tone accounting for transient myocardial disfunction. The TakoTsubo cardiomyopathy has usually a benign course with prompt recovery of ventricular function in few days.

Case report. We report the case of a 83 years old female patient, without relevant cardiological history. She was admitted to the emergency department due to the onset of dyspnoea during mild exertion. On arrival a 12-lead ECG was performed with evidence of sinus rhythm, third-degree AV block and junctional escapement rhythm at 38 bpm. The day after she underwent dual chamber pacemaker implantation without any acute complication. Echocardiogram performed immediately after the procedure showed no pericardial effusion and normal left ventricular rejection fraction. Before discharge the ECG showed anomalous concordant negative T waves during paced ventricular rhythm suggesting myocardial ischaemia. Patient was completely asymptomatic. A new echocardiogram was performed revealing apical ipoakinesia and hyperkinesia of basal segments of left ventricular with depression of ejection fraction. Rise in troponine confirmed our suspicion. Thus the patient underwent coronary angiogram that showed absence of obstructive coronary artery disease suggesting the diagnosis of Takotsubo cardiomyopathy. Two days later the patient suffered by transient cerebral ischemic event (diplopia). The echocardiogram was performed revealing a thrombotic formation in the apex of the left ventricle. Anticoagulation therapy with NFH and then with OAC was undertaken. In the following days, peripheral vascular ischemia occurred by non-critical stenosis due to embolization of the thrombus. Echocardiography at this time showed the complete disappearance of the thrombus from LV apex. The patient was discharged asymptomatic with complete resolution of the peripheral arterial thrombus-embolism. One month later left ventricular ejection fraction was completely restored and OAC was stopped.

Conclusions. The incidence of TTS after pacemaker implantation is not so rare. With this case we want to emphasise the importance of the echocardiogram before discharge, and of the myocardionecrosis enzyme assay in patients at high risk of developing TTS. The development of other complications (e.g. intraventricular thrombus formation) may remain undetected and lead to even fatal consequences.

A760: QUADRO CLINICO-STRUMENTALE IN PORTATORI DI VARIANTI A CARICO DEL GENE RBM20: UNA CASISTICA ITALIANA

Rossella Manai (b), Veronica Dusi (b), Filippo Angelini (a), Stefano Pidello (a), Pierpaolo Bocchino (a), Guglielmo Gallone (b), Giulia Gobello (b), Andrea Saglietto (b), Davide Castagno (b), Andrea Faggiano (c), Margherita Calcagnino (d), Stefania Paganini (e), Stefano Carugo (c), Matteo Anselmino (b), Carla Giustetto (b), Giulia Margherita Brach Del Prever (b), Valeria Bracciama´ (f), Silvia Deaglio (b), Claudia Raineri (a), Gaetano Maria De Ferrari (b)

(a) DIVISION OF CARDIOLOGY, CARDIOVASCULAR AND THORACIC DEPARTMENT "CITTÀ DELLA SALUTE E DELLA SCIENZA " HOSPITAL TURIN; (b) DEPARTMENT OF MEDICAL SCIENCES, UNIVERSITY OF TURIN; (c) DEPARTMENT OF CLINICAL SCIENCES AND COMMUNITY HEALTH, UNIVERSITY OF MILANO; (d) DEPARTMENT OF CARDIO-THORACIC-VASCULAR DISEASE, FOUNDATION IRCCS CA GRANDA OSPEDALE MAGGIORE POLICLINICO; (e) MEDICAL GENETICS, UNIVERSITY OF MILANO; (f) IMMUNOGENETICS AND TRANSPLANT BIOLOGY SERVICE, CITTÀ DELLA SALUTE E DELLA SCIENZA HOSPITAL

Introduzione. RNA-binding motif protein 20 (RBM20) regola lo splicing post-trascrizionale di diversi geni tra cui geni sarcomerici e altri geni cruciali per l'omeostasi cardiaca. Le varianti di RBM20 sono una rara causa di cardiomiopatia (CMP), ma la correlazione genotipo-fenotipo è ancora elusiva, cosi come la stratificazione del rischio aritmico e di scompenso.

Obiettivi. Descrivere la correlazione genotipo-fenotipo e il rischio aritmico in pazienti con varianti di RBM20.

Metodi. Si tratta di uno studio bicentrico in cui sono stati inclusi tutti i pazienti portatori di varianti patogenetiche/verosimilmente patogenetiche (P/VP) o varianti di incerto significato (VUS) a carico del gene RBM20. Dodici pazienti (5 maschi, di 8 famiglie) erano portatori di una variante in eterozigosi di RBM20, compresi 8 con singola variante patogenetica o verosimilmente patogentica, 4 con VUS di RBM20, associata a una seconda VUS su un altro gene relato a CMP.

Risultati. Dal punto di vista genetico, sono state identificate 2 varianti P/VP (Arg636His e Arg634Gln) in 8 soggetti appartenenti a 4 famiglie differenti famiglie, tutte localizzate nell'esone 9 (hotspot di malattia); per quanto riguarda le VUS, una soltanto è risultata localizzata nell'esone 9. La maggior parte dei dodici pazienti (pz) studiati (75%) aveva una storia familiare positiva per morte improvvisa. L'età media alla diagnosi era più bassa nei portatori di varianti P e VP in confronto ai portatori di VUS (30±15 vs 44±5 years, p=0.03); non sono state identificate altre differenze statisticamente significative tra i 2 gruppi. L'età alla diagnosi e'risultata simile in maschi (34±16 anni) e femmine (33±11 anni, p=0.9). Alla diagnosi 66% aveva una classe NYHA>1 (41% NYHA III o IV), 100% presentava fenotipo dilatativo-ipocinetico, l'FE media era di 32.5±11%. La risonanza magnetica cardiaca (RM), disponibile in 7 pz, mostrava fibrosi non ischemica in 4 (57%). Alla presentazione, 4 pz avevano già avuto episodi di tachicardia ventricolare non sostenuta (TVNS), 1 era in flutter atriale (FLA) tipico comune, 1 presentava blocco AV (BAV) di primo grado. Il follow up mediano è stato di 2 anni (IQR 2-5). In 7 pz (64%) è stato impiantato un ICD a 43± 11 anni; 11 pazienti sono stati trattati con betabloccante, 3 pazienti con amiodarone per TVNS (in un caso sostituito con mexiletina per tireotossicosi), 1 paziente con mexiletina. Dei 4 pz non impiantati, una aveva 12 anni ed è stata trapiantata dopo pochi mesi dalla diagnosi, gli altri 3 avevano una FE tra il 40 ed il 45%, nessuno aveva avuto TVNS e solo 1 presentatava minima fibrosi alla RM. Durante il follow-up, un pz è stato sottoposto ad ablazione di FLA, una pz è stata sottoposta a trapianto cardiaco a 13 anni; 6 pz (tutti con ICD) hanno avuto TVNS durante il FU, tre pz hanno avuto TV maggiori, in due casi trattate con interventi appropriati dell'ICD, tre aritmie atriali parossistiche (in un caso trattata con successo con isolamento delle vene polmonari) e nessuno ha sviluppato BAV avanzati. Una paziente è stata sottoposta a denervazione cardiaca simpatica bilaterale per plurimi interventi dell'ICD.

Conclusioni. Questa è la prima coorte italiana di pazienti con CMP associata a varianti di RMB20. In questa casistica, le varianti sono associate con una precoce manifestazione di fenotipo cardiaco, sia nei maschi che nelle femmine, con CMP dilatativa e insufficienza cardiaca. Nessuno dei pazienti ha sviluppato BAV avanzati, un terzo ha avuto aritmie atriali, la maggior parte ha manifestato TVNS e 3 pazienti hanno avute aritmie ventricolari maggiori trattate dal device, in terapia.

A761: EOSINOPHILIC GRANULOMATOSIS WITH POLYANGIITIS PRESENTING AS SEVERE HEART DYSFUNCTION AND INTRA-CARDIAC THROMBOSIS

Sara Mastroberardino (a), Andrea Segreti (a), Lorenzo Frau (a), Luca D´antonio (a), Danilo Ricciardi (a), Alessandro Appetecchia (a), Francesco Grigioni (a), Gian Paolo Ussia (a)

(a) UNIVERSITÀ CAMPUS BIO-MEDICO DI ROMA

Introduction. Eosinophilic granulomatosis with polyangiitis (EGPA), formerly Churg-Strauss syndrome, is a rare vasculitis of small-medium blo-

od vessels characterized by asthma, hypereosinophilia, cardiac failure, renal involvement, and peripheral neuropathy. We reported a case of a young woman with critical cardiovascular, neurological, and respiratory involvement.

Case report. A 45-year-old woman, affected by bronchial asthma and nasal polyposis, experiencing dyspnea and paresthesia on the left lower limb, underwent a total body PET-CT which demonstrated left segmental pulmonary thromboembolism, lung pseudo-nodular infiltration, and pericardial and pleural effusions. Thus, she entered Emergency Department in mediocre general conditions. Hepatomegaly, left lower limb hot and edematous, painless, but with paresthesia, were observed. The ECG revealed sinus tachycardia, low QRS voltages in the peripheral leads, normal AV and IV conduction, poor r-wave progression in the precordial leads, and diffuse repolarization abnormalities. The trans-thoracic echocardiography showed dilatated and hypokinetic right (RV) and left ventricle (LV) with severe reduction of global systolic function (LV ejection fraction, LVEF=20%), bi-atrial dilation, circumferential pericardial effusion and thrombotic stratification at the apex (Fig 1A). Blood test examination displayed severe eosinophilia, raised NT-Pro BNP and troponin I levels. A heart/coronary CT was performed, documenting epicardial coronaries free from significant atheromatous pathology but confirming the presence of endocavitary thrombosis. In addition, a cardiac MRI showed a dilated cardiomyopathy with a severe reduction in systolic biventricular function (LVEF fraction=14%, RVEF=26%), late gadolinium enhancement in the sub-endocardial area with diffuse involvement of the mid-apical ventricular segments and in the infra-myocardial area at the level of the lower basal and mid-apical intraventricular septum, as in fibrotic outcomes (Fig 1B). The subsequent total body CT scan confirmed the known thromboembolism, pulmonary lesions and pleuro-pericardial effusion (Fig 1C); cardiogenic liver cirrhosis, and thrombosis of the right uterine vein and left gonadal vein were also reported. The auto-antibodies blood testing showed negativity for ANCA. In the presence of bronchial asthma, nasal polyposis, motoneuritis, and hypereosinophilia, we diagnosed ANCA-negative eosinophilic vasculitis with cardiac involvement. Genetic testing was negative for FIP1L1-PDGFRA, excluding treatment with imatinib. Thus, we started immunosuppression therapy with corticosteroids and cyclophosphamide. However, albeit optimal medical treatment for ventricular dysfunction, the implantation of a subcutaneous cardiac defibrillator was required.

Conclusions. The possible cardiac manifestations in the context of EGPA may be several, particularly in patients with ANCA-negative disease. Therefore, clinicians should have a high clinical suspicion as cardiac involvement in the context of EGPA results in a poor prognosis if not diagnosed and adequately treated.

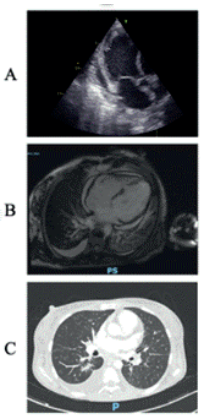

A762: PROGRESSION AND PROGNOSTIC SIGNIFICANCE OF ELECTROCARDIOGRAPHIC FINDINGS IN PATIENTS WITH CARDIAC AMYLOIDOSIS

Alessia Argiro´ (a, b), Mattia Zampieri (a, b), Carlotta Mazzoni (a, b), Carlo Fumagalli (a, b), Michela Baccini (j), Alessandra Mattei (j), Alberto Cipriani (c), Laura De Michieli (c), Aldostefano Porcari (d), Gianfranco Sinagra (d), Marco Merlo (d), Giacomo Tini (e), Beatrice Musumesi (e), Domitilla Russo (e), Pier Filippo Vianello (f), Marco Canepa (f), Roberto Licordari (g), Gianluca Di Bella (g), Claudio Rapezzi (h, i), Federico Perfetto (a), Francesco Cappelli (a, b)
(a) TUSCAN REGIONAL AMYLOIDOSIS CENTRE, CAREGGI UNIVERSITY HOSPITAL, FLORENCE, ITALY; (b) CARDIOMYOPATHY UNIT, CAREGGI UNIVERSITY HOSPITAL, FLORENCE, ITALY; (c) DEPARTMENTE OF CARDIAC, THORACIC ANC VASCULAR SCIENCES AND PUBLIC HEALTH, UNIVERSITY OF PADUA, ITALY; (d) CENTER FOR DIAGNOSIS AND TREATMENT OF CARDIOMYOPATHIES, CARDIOVASCULAR DEPARTMENT, AZIENDA SANITARUA UNIVERSITARIA GIULIANO-ISONTINA (ASUGI), UNIVERSITY OF TRIESTE, ITALY; (e) DEPARTMENT OF CLINICAL AND MOLECULAR MEDICINE, SAPIENZA UNIVERSITY, ROME, ITALY; (f) CARDIOVASCULAR UNIT, DEPARTMENT OF INTERNAL MEDICINE, UNIVERSITY OF GENOVA, OSPEDALE POLICLINICO SAN MARTINO IRCCS, GENOVA, ITALY; (g) DEPARTMENT OF CARDIOLOGY, UNIVERSITY OF MESSINA, MESSINA, ITALY; (h) CARDIOTHORACIC DEPRATMENT, UNIVERSITY OF FERRARA, ITALY; (i) MARIA CECILIA HOSPITAL, GVM CARE&RESEARCH, COTIGNOLA, RAVENNA, ITALY; (j) DEPARTMENT OF STATISTICS, COPUTER SCIENCE, APPLICATIONS (DISIA), UNIVERSITY OF FLORENCE, FLORENCE, ITALY

Objectives. To evaluate the change of the main electrocardiographic (ECG) characteristics and their prognostic role across the three main subtypes of cardiac amyloidosis (light chain, AL, hereditary and wild-type transthyretin amyloidosis, ATTRv and ATTRwt).

Methods. Multicenter, retrospective study performed in 6 referral centers for cardiac amyloidosis. Clinical and ECG data were collected at first and last evaluation.

Results. 356 patients were included (AL n=105, ATTRv=50, ATTRwt=201). Median age was 76 (67-81) years and 271 (74%) were men. At baseline patients with ATTRwt showed more frequently conduction abnormalities compared to AL (1°st degree AV block n=51 (40%) vs n=13 (34%), p<0.01; left bundle branch block n=23 (11%) vs n=2 (2%) p<0.01), patients with AL more often had low QRS voltage (n=58 (55%), in ATTRv n=17 (34%), in ATTRwt n=67 (33%), p value <0.01) and T wave inversion compared to ATTR (n=39 (37%), in ATTRv n=9 (18%),in ATTRwt n=37 (18%)). After a median follow up of 15 (8-26) months the adjusted differences in mean PR, QRS interval, total, peripheral and precordial QRS score were similar across subtypes of amyloidosis. The adjusted odds for the development of RBBB were higher in AL compared to ATTRwt (Odds ratio 4.7 [1.5-15]). QRS duration at baseline remained independently associated with patient survival in the overall population even after adjustment for relevant clinical variables (HR 1.78 CI 1.13-2.8, p<0.01).

Conclusions. Progression of the ECG alterations seems similar across amyloidosis' subtypes. QRS duration could be a marker of more advanced disease.

A763: LARGE LEFT VENTRICLE PSEUDOANEURYSM COMPLICATING CARDIAC ECHINOCOCCOSIS: FIRST DESCRIPTION.

Michele Granatiero (a), Marco Mele (b), Nunzio Gallo (c), Mauro Cassese (c), Lucia Tricarico (b), Natale Daniele Brunetti (a)
(a) DEPARTMENT OF MEDICAL AND SURGICAL SCIENCES, UNIVERSITY OF FOGGIA, FOGGIA, ITALY; (b) CARDIOTHORACIC DEPARTMENT, POLICLINICO RIUNITI UNIVERSITY HOSPITAL, FOGGIA, ITALY; (c) HEART SURGERY DEPARTMENT, CASA SOLLIEVO DELLA SOFFERENZA, SAN GIOVANNI ROTONDO, FOGGIA, ITALY

A 24-year-old woman from Eastern Europe was seen at our out-patient clinic for exertional breathlessness. Her medical history included 3 surgical interventions to remove hydatid cysts from the brain, the spleen and the kidneys between 2018 and 2020. No trauma was reported. Her physical examination was unremarkable. ECG showed mild and non-specific changes of ST-T tract. Transthoracic echocardiogram revealed a clear defect of the lateral wall of the left ventricle (LV) communicating with a large cavity. A bi-directional flow between LV and aneurysmatic cavity was detected so a pseudoaneurysm was suspected. After a few days the patient was admitted to the cardiac surgery department because of a concrete risk of rupture of the suspected pseudoaneurysm. Cardiac computed tomography (CT) confirmed a large cavity with a narrow orifice and excluded coronary abnormalities. Cardiac Magnetic Resonance was not performed due to the possible presence of not Magnetic Resonance-compatible clips. Finally, the patient underwent cardiac surgery in extracorporeal circulation: the pseudoaneurysm was resected and the ventricular wall defect was directly sutured. Five days later, she was discharged without any complications. Patho-histological findings on the cavity wall confirmed a LV pseudoaneurysm.

Discussion. A pseudoaneurysms is a ventricular free wall perforation that is locally contained by adjacent pericardium and adhesions[1]. Diagnosis is challenging: congestive heart failure, chest pain and dyspnea are the most frequently reported symptoms, but>10% of patients are asymptomatic. The risk of rupture is estimated to be between 30 and 45%, thus a surgical approach is often required[2]. In the current case, we excluded the most common cause of pseudoaneurysm (e.g. myocardial infarction, cardiac surgery or trauma) taking into account the medical history and the results of imaging tests. In our opinion, Echinococcus reached the myocardium via the coronary circulation. Then, a cyst expanded toward epicardium leading to a discrete rupture of the ventricular free wall. That breach did not result in a catastrophic pericardial tamponade because of contention of the adjacent pericardium. Apparently no similar cases have ever been reported.

References

Libby P., et al. Braunwald's Heart Disease, A Textbook of Cardiovascular Medicine 12th ed, Elselvier, 2021;
Frances C., et al. Left ventricle pseudoaneurysm. JACC 1998;32:557-6.

A764: ROLE OF ARRHYTHMIC PHENOTYPE IN PROGNOSTIC STRATIFICATION AND MANAGEMENT OF DILATED CARDIOMYOPATHY

Martina Setti (a), Marco Merlo (a), Marta Gigli (a), Laura Munaretto (a), Alessia Paldino (a), Davide Stolfo (a), Carola Pio Loco (a), Kristen Medo (c), Caterina Gregorio (d), Antonio De Luca (a), Sharon Graw (c), Matteo Castrichini (e), Antonio Cannatà (a), Flavio Luciano Ribichini (b), Matteo Dal Ferro (a), Matthew Taylor (c), Gianfranco Sinagra (a), Luisa Mestroni (c)

(a) CENTER FOR DIAGNOSIS AND TREATMENT OF CARDIOMYOPATHIES, CARDIOVASCULAR DEPARTMENT, ASUGI, UNIVERSITY OF TRIESTE, ITALY; (b) DIVISION OF CARDIOLOGY, DEPARTMENT OF MEDICINE, UNIVERSITY OF VERONA, ITALY; (c) CARDIOVASCULAR INSTITUTE AND ADULT MEDICAL GENETICS PROGRAM, UNIVERSITY OF COLORADO ANSCHUTZ MEDICAL CAMPUS, AURORA CO, USA; (d) BIOSTATISTIC UNIT, UNIVERSITY OF TRIESTE, ITALY; (e) DEPARTMENT OF CARDIOVASCULAR MEDICINE, MAYO CLINIC, ROCHESTER, MINNESOTA, USA

Aims. Dilated cardiomyopathy/hypokinetic non-dilated cardiomyopathy with arrhythmic phenotype (AR-DCM/HNDCM) combines phenotypical aspects of dilated cardiomyopathy/hypokinetic non-dilated cardiomyopathy (DCM/HNDCM) and predisposition to ventricular arrhythmias, typical of arrhythmogenic cardiomyopathy (ACM). The definition of AR-DCM/HNDCM is not universally accepted, leading to uncertainty in the identification of high-risk patients. This study aimed to assess the prognostic impact of arrhythmic phenotype in risk stratification and the correlation of arrhythmic markers with high-risk arrhythmogenic gene variants in DCM/HNDCM patients.

Methods and Results. In this multicenter study, DCM/HNDCM patients with available genetic testing were analyzed. The following arrhythmic markers, present at baseline or within one year from enrollment, were tested: unexplained syncope, rapid nonsustained ventricular tachycardia (NSVT), ≥1000premature ventricular contractions/24hours or ≥50ventricular couplets/24hours. LMNA, FLNC, RBM20, and desmosomal pathogenic or likely-pathogenic gene variants were considered high-risk arrhythmogenic genes. The primary endpoint was a composite of sudden cardiac death and major ventricular arrhythmias (SCD/MVA). We studied 742 DCM/HNDCM patients (45±14 years, 34% female, 410 (55%) with LVEF<35%). During a median follow-up of 6 years [IQR 1.6-12.1], unexplained syncope and NSVT were the only arrhythmic markers associated with SCD/MVA and the combination of the two markers carried a significant additive risk of SCD/MVA, independently of left ventricular ejection fraction and NYHA class. The probability of identifying an arrhythmogenic genotype rose from 8% to 30% if both early syncope and NSVT were present.

Conclusions. In DCM/HNDCM patients, the combination of early detected NSVT and unexplained syncope increases the risk of life-threatening arrhythmic outcomes and can aid the identification of carriers of malignant arrhythmogenic genotypes.

A765: DISENTANGLING THE HETEROGENEITY OF DILATED CARDIOMYOPATHY: USE OF UNSEPERVISED CLUSTERING FOR MIXED-DATA TYPE IN THE SEARCH OF NOVEL CLINICAL SUB-PHENOTYPES

Alessia Paldino (a, c), Ilaria Gandin (a), Giovanni Baj (b), Denise Zaffalon (c), Andrea Pezzato (c), Marco Merlo (c), Matteo Dal Ferro (c), Giulia Barbati (a), Gianfranco Sinagra (c)
(a) DEPARTMENT OF MEDICAL SCIENCES, UNIVERSITY OF TRIESTE, TRIESTE, ITALY; (b) DEPARTMENT OF MATHEMATICS AND GEOSCIENCES, UNIVERSITY OF TRIESTE, TRIESTE, ITALY; (c) CARDIOTHORACOVASCULAR DEPARTMENT, AZIENDA SANITARIA UNIVERSITARIA GIULIANO ISONTINA,TRIESTE,ITALY

Introduction. Dilated cardiomyopathy (DCM) is a significant cardiac disorder, responsible for roughly 20% of 5-year mortality rates. Despite its severity, the absence of precise prognostic risk models for DCM remains a critical knowledge gap. Genetic factors contribute substantially, with around 30% of cases linked to pathogenic mutations. Clinical variability and the presence of overlapping features with arrhythmogenic cardiomyopathy further challenge traditional classification[1].

Aims. This study employs rigorous scientific methods to uncover novel DCM sub-phenotypes by analyzing data from initial cardiological assessments using unsupervised clustering techniques.

Methods. We analyzed a longitudinal dataset of 409 DCM patients, all undergoing genetic testing, with a median follow-up of 100 months (IQR [51, 185]). Variables encompassed clinical parameters, electrocardiogram (ECG) metrics, Holter monitoring data, and imaging results. The study faced two primary challenges: a large number of variables (p=102) and mixed data types. We utilized an innovative two-step approach: 1) applying a recent mixed data-oriented extension of principal component analysis[2] for dimensionality reduction and 2) employing agglomerative hierarchical clustering on the first 11 principal components, determining k=2 clusters as optimal using average silhouette width criteria.

Results. Through a post-hoc cluster representation technique, we characterized a smaller cluster (Gr2, n=75) characterized by individuals with preserved left ventricle muscle thickness and a high prevalence of left bundle branch block. A multivariate cause-specific Cox model incorporating nine established risk factors demonstrated a significantly reduced risk of life-threatening arrhythmic events in Gr2 (HR=0.21, 95% CI [0.08, 0.54]). Genetic analysis revealed a lower incidence of causative mutations in Gr2 compared to Gr1 (15% vs. 47%, p<0.001), with none associated with conventional arrhythmogenic DCM genes (DSP, PKP2, LMNA), in line with recent research[3].

Conclusions. This study, employing dimensionality reduction and scientifically robust unsupervised clustering for mixed-data types, identified two novel DCM subphenotypes marked by distinct disease progression and genetic etiologies. Further validation in an external cohort promises to enhance the scientific foundation for refining the conventional phenotype-based classification of cardiomyopathies.

References

A Paldino, M Dal Ferro et al. Prognostic Prediction of Genotype vs Phenotype in Genetic Cardiomyopathies. J Am Coll Cardiol. 2022 Nov, 80 (21) 1981–1994.
Marie Chavent, Vanessa Kuentz-Simonet, Amaury Labenne et al. Multivariate Analysis of Mixed Data: The R Package PCAmixdata. PREPRINT (v5) available at arXiv: 1411.4911.
L Escobar-Lopez, JP Ochia, A Royuela et al. Clinical Risk Score to Predict Pathogenic Genotypes in Patients With Dilated Cardiomyopathy. J Am Coll Cardiol. 2022 Sep 20,80(12) 1115-1126.

A766: GENETIC AND PHENOTYPIC CHARACTERIZATION OF NEXILIN (NEXN) RELATED CARDIOMYOPATHY

Maria Perotto (a, b), Alessia Paldino (a), Francesco Mazzarotto (c), Giulia Barbati (d), Job A.j. Verdonschot (e, f), Mohammed Akhtar (g), Perry Elliott (g), Juan Pablo Ochoa (h), Pablo Garcia Pavia (h), Robért Sepp (i), Sanjay Prasad (j), Momina Yazdani (j), Ezster Dalma Palinkas (i, k), Francesca Girolami (k), Iacopo Olivotto (k), Victoria N Parikh (l), Diane Fatkin (m), Neal Lakdawala (n), William J Mckenna (o), Marta Gigli (a), Davide Stolfo (a, p), Francesca Brun (a), Chiara Collesi (r), Mauro Giacca (r, t), Serena Zacchigna (r), Giovanni Maria Severini (s), Stefania Lenarduzzi (s), Giorgia Girotto (q, s), Paolo Gasparini (q, s), Matthew Rg Taylor (u), Luisa Mestroni (u), Marco Merlo (a), Gianfranco Sinagra (a), Matteo Dal Ferro (a)
(a) CARDIOVASCULAR DEPARTMENT, AZIENDA SANITARIA UNIVERSITARIA GIULIANO ISONTINA (ASUGI), UNIVERSITY OF TRIESTE, ITALY. MEMBER OF ERN GUARD-HEART; (b) POSTGRADUATE SCHOOL OF CARDIOVASCULAR MEDICINE UNIVERSITY OF TRIESTE, ITALY; (c) DEPARTMENT OF MOLECULAR AND TRANSLATIONAL MEDICINE, UNIVERSITY OF BRESCIA, ITALY; (d) BIOSTATISTICS UNIT, UNIVERSITY OF TRIESTE, ITALY; (e) DEPARTMENT OF CLINICAL GENETICS, MAASTRICHT UNIVERSITY MEDICAL CENTER, MAASTRICHT, THE NETHERLANDS; (f) DEPARTMENT OF CARDIOLOGY, CARDIOVASCULAR RESEARCH INSTITUTE (CARIM), MAASTRICHT UNIVERISTY MEDICAL CENTRE, THE NETHERLANDS, MEMBER OF ERN GUARD-HEART; (g) ST BATHOLOMEW'S HOSPITAL, BARTS HEART CENTRE, LONDON, UK; (h) HEART FAILURE AND INHERITED CARDIAC DISEASES UNIT, DEPARTMENT OF CARDIOLOGY, HOSPITAL UNIVERSITARIO PUERTA DE HIERRO, IDIPHISA, MADRID, SPAIN; (i) SECOND DEPARTMENT OF INTERNAL MEDICINE AND CARDIOLOGY CENTRE, UNIVERSITY SZEGED, HUNGARY; (j) ROYAL BROMPTON HOSPITAL, IMPERIAL COLLEGE, LONDON, UK; (k) CARDIOMYOPATHY UNIT, CAREGGI UNIVERISTY HOSPITAL, FLORENCE, ITALY; (l) STANFORD CENTER FOR INHERITED CARDIOVASCULAR DISEASE, CALIFORNIA; (m) MOLECULAR CARDIOLOGY DIVISION, VICTOR CHANG CARDIAC RESEARCH INSTITUTE, SYDNEY, NSW, AUSTRALIA; (n) DEPARTMENT OF MEDICINE, BRIGHAM AND WOMEN'S HOSPITAL, HARVARD MEDICAL SCHOOL, BOSTON, MA, USA; (o) INSTITUTE OF CARDIOVASCULAR SCIENCE, UNIVERISTY COLLEGE LONDON, UK; (p) DIVISION OF CARDIOLOGY, DEPARTMENT OF MEDICINE, KAROLINSKA INSTITUTET, STOCKHOLM, SWEDEN; (q) DEPARTMENT OF MEDICINE, SURGERY AND HEALTH SCIENCES, UNIVERSITY OF TRIESTE, TRIESTE, ITALY; (r) INTERNATIONAL CENTER FOR GENETIC ENGINEERING AND BIOTECHNOLOGY (ICGEB), TRIESTE, ITALY; (s) INSTITUTE FOR MATERNAL AND CHILD HEALTH, IRCCS BURLO GAROFOLO, TRIESTE, ITALY; (t) KING'S COLLEGE LONDON, BRITISH HEART FOUNDATION CENTRE OF REASEARCH EXCELLENCE, SCHOOL OF CARDIOVASCULAR MEDICINE AND SCIENCES, LONDON, UK; (u) CARDIOVASCULAR INSTITUTE AND ADULT MEDICAL GENETICS PROGRAM, UNIVERSITY OF COLORADO ANSCHUTZ MEDICAL CAMPUS, AURORA, CO, USA

Background. Clinical and genetic features of Nexilin (NEXN) related cardiomyopathies (CMPs) are largely uncharacterized. At present, the strength of the gene-disease association for NEXN is moderate for Dilated Cardiomyopathy (DCM), limited for Hypertrophic Cardiomyopathy (HCM), and unevaluated for arrhythmogenic Cardiomyopathy (ACM). More evidence is needed to establish a definite genotype-phenotype association.

Aim. We sought to investigate 1) the causative role of NEXN gene in CMPs, and 2) its phenotypic expression and prognostic profile.

Methods. All patients carrying NEXN variants, recruited in 12 international referral centres, were classified according to reported phenotype and genetic variant. The GnomAD filtering allele frequency to define variants as rare was set according to previous studies on genetic CMPs. Burden enrichment testing of rare NEXN variants was performed in two study case-cohorts of patients, one of HCM cases (n=1740) and one of DCM-ACM (n=3053), in comparison with the GnomAD population of non-Finnish Europeans (NFE). Clinical phenotypes and outcomes of patients carrying validated variants were described. Two previously established cohorts of patients with Titin (TTN)- and Filamin C(FLNC)-related CMP were used for prognostic comparison.

Results. Data from 88 patients were collected. Forty-three patients were excluded due to being carriers of non-rare NEXN variants (n=25) and/or pathogenic variants in other genes (n=18). NEXN rare variants were not enriched in the HCM case cohort. NEXN truncating variants (tv) resulted significantly enriched in the DCM-ACM disease-cohort with a prevalence of 0,42% vs 0,09% in GnomAD NFE (p=0.0001), whereas non-truncating ones were not. Patients with non-hypertrophic phenotypes carrying NEXNtv (n=16), plus a further patient carrying a homozygous p.G650del variant were thus considered affected by NEXN-related CMP (NEXN-CMP). Out of 17 patients with NEXN-CMP, 88% were probands, 53% we-

re males and the median age at diagnosis was 45 (IQR 36-55). At baseline, the most prevalent phenotypes were DCM (59%) and ACM (41%) and NYHA I class was common (71%). Left ventricular (LV) indexed End Diastolic Volume was mildly increased (69mL, IQR 46-87) and ejection fraction mildly reduced (LVEF 44%, IQR 31-53). Myocardial fibrosis was reported for up to 64% of patients, median ventricular ectopic beats were 515/24h (IQR 43-5071). During a median follow of 45 months (IQR 11-130), 9 patients were implanted with an ICD, 1 patient died and 4 (25%) had malignant ventricular arrythmias (MVA). When compared to a cohort of patients with TTN-CMP, patients with NEXN-CMP showed MVA earlier, and with higher LVEF, whereas no significant differences were found against FLNC-CMP.

Conclusions. NEXNtv showed significant disease association with non-hypertrophic CMP phenotypes. NEXN-CMP is characterized by mild LV dilation and dysfunction, uncommon heart failure, but frequent myocardial fibrosis and ventricular arrythmias. These findings from the largest cohort of NEXN variants carriers strongly contribute to define the causative role of this rare genotype and its related phenotype.

A767: PREVALENCE AND CLINICAL SIGNIFICANCE OF RIGHT VENTRICULAR PULMONARY ARTERIAL UNCOUPLING IN CARDIAC AMYLOIDOSIS

Giuseppe Palmiero (a), Emanuele Monda (a), Federica Verrillo (a), Francesca Dongiglio (a), Martina Caiazza (a), Marta Rubino (a), Michele Lioncino (a), Gaetano Diana (a), Erica Vetrano (a), Adelaide Fusco (a), Annapaola Cirillo (a), Alfredo Mauriello (a), Giovanni Ciccarelli (b), Luigi Ascione (c), Maria Luisa De Rimini (d), Michele D´alto (b), Giuseppe Cerciello (e), Antonello D´andrea (f), Paolo Golino (b), Paolo Calabrò (a), Eduardo Bossone (g), Giuseppe Limongelli (a)

(a) INHERITED AND RARE CARDIOVASCULAR DISEASES UNIT, DEPARTMENT OF TRANSLATIONAL MEDICAL SCIENCES,UNIVERSITY OF CAMPANIA "LUIGI VANVITELLI", NAPLES, ITALY; (b) VANVITELLI CARDIOLOGY UNITY, MONALDI HOSPITAL, NAPLES, ITALY; (c) DIVISION OF CARDIOLOGY, MONALDI HOSPITAL, NAPLES, ITALY; (d) DEPARTMENT OF NUCLEAR MEDICINE, MONALDI HOSPITAL, NAPLES, ITALY; (e) HAEMATOLOGY UNIT, DEPARTMENT OF CLINICAL MEDICINE AND SURGERY, UNIVERSITY OF NAPLES "FEDERICO II", NAPLES, ITALY; (f) DEPARTMENT OF CARDIOLOGY AND INTENSIVE CORONARY CARE, UMBERTO I HOSPITAL, NOCERA INFERIORE, ITALY; (g) DEPARTMENT OF PUBLIC HEALTH, UNIVERSITY OF NAPLES "FEDERICO II", NAPLES, ITALY

Background. This study aims to evaluate the prevalence and the clinical significance of the right ventricular pulmonary arterial (RV-PA) uncoupling in patients with cardiac amyloidosis (CA).

Methods. The study population consisted in 92 consecutive patients with CA (age 71.1±12.2 years, 71% males; 47% with immunoglobulin light chain (AL), 53% with transthyretin [ATTR]). A pre-specified tricuspid anulus plane systolic excursion on pulmonary arterial systolic pressure (TAPSE/PASP) value <0.31 mm/mmHg was used to define RV-PA uncoupling and to dichotomize the study population.

Results. Thirty-two patients (35%) showed RV-PA uncoupling at baseline evaluation (15/44 [34%] AL and 17/48 [35%] ATTR). Patients with RV-PA uncoupling, in both AL and ATTR, showed worse NYHA functional class, lower systemic blood pressure, and more pronounced left ventricular and RV systolic dysfunction than those with RV-PA coupling. During a median follow-up of 8 months (IQR 4-13), 26 patients (28%) experienced cardiovascular death. Patients with RV-PA uncoupling showed lower survival at 12 months follow-up than those with RV-PA coupling (42.7% [95%CI 21.7-63.7%] vs. 87.3% [95%CI 78.3-96.3%], p-value<0.001). Multivariate analysis identified high-sensitivity troponin I values (HR 1.01 [95%CI 1.00-1.02] per 1 pg/mL increase; p-value 0.013) and TAPSE/PASP (HR 1.07 [95%CI 1.03-1.11] per 0.01 mm/mmHg decrease; p-value 0.002) as independent predictors of cardiovascular death.

Conclusions. RV-PA uncoupling is common among patient with CA, and it is a marker of advanced disease and worse outcome. This study suggests that TAPSE/PASP ratio has the potential to improve risk stratification and guide management strategies in patients with CA of different etiology and advanced disease.

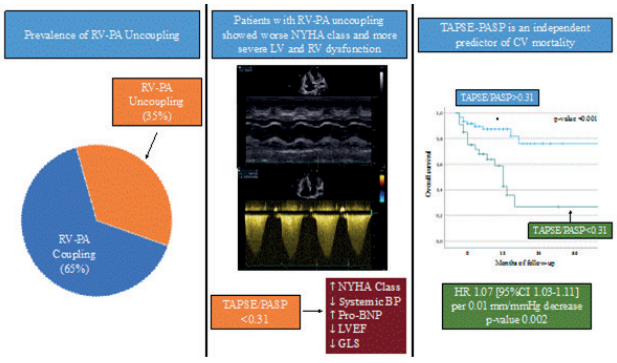

A768: SPECKLE-TRACKING GLOBAL LONGITUDINAL STRAIN AS A PREDICTOR OF CLINICAL OUTCOME IN PATIENTS WITH IDIOPATHIC INFLAMMATORY MYOPATIES

Federico Paolini (a, b), Giulia Stronati (a, b), Leonardo Brugiatelli (a, b), Michele Alfieri (a, b), Gianmarco Bastianoni (a, b), Antonio Dello Russo (a, b), Maria Giovanna Danieli (a, c), Gianluca Moronicini (a, c), Federico Guerra (a, b)

(a) UNIVERSITÀ POLITECNICA DELLE MARCHE; (b) CLINICA DI CARDIOLOGIA E ARITMOLOGIA DI ANCONA; (c) CLINICA MEDICA ANCONA

Background. idiopathic inflammatory myopathies (IIM) are a systemic immune-mediated disease characterized by a variety of clinical presentations. IIM mainly target skeletal muscle; however other organs may be affected by the disease. It is, in fact, known that cardiac involvement in IIM is frequent albeit initially subclinical. Heart involvement is IIM frequently represents the cause of death for patients affected by the disease, with manifestations which include both heart failure and conduction defects. Previous studies have demonstrated how speckle-tracking-derived global longitudinal strain (GLS) used to assess myocardial deformation is significantly lower in IIM compared to healthy controls, therefore, representing a cost-effective tool to investigate subclinical heart involvement.

Methods. We enrolled all consecutive patients with a confirmed diagnosis of IIM and no overt cardiac disease sent to our Cardiology Clinic between June 2016 and January 2022. All patients underwent full evaluation, including clinical, ECG and echocardiographic assessment as well as GLS calculation both at baseline and follow-up appointments. The primary endpoint was a composite of death and cardiovascular events.

Results. 41 consecutive patients (30 females, 59±18 years) with IIM were consecutively enrolled and followed up for a median of 8 years (4-11 years). During follow-up, a progressive worsening of LVEF (-4%; p=.03) and left GLS (LGLS: +3%; p=.04) was shown, along with an increase in atrial volumes (iLAV: +8 cm2/m2; p=.02; iRAV: +10 cm2/m2; p=0.01) and estimated filling pressures (E/e': +2; p=.01). A left GLS (LGLS)>-16% predicted the composite endpoint with a sensitivity of 80% and a specificity of 67% (AUC 0.74). Estimated survival from the composite endpoint was 85% for the normal LGLS group and 35% for the impaired LGLS group (Figure 1). Right GLS was not significantly associated with the primary endpoint.

Conclusions. Heart involvement is becoming a major cause of death in patients with myositis. Data reported that subclinical heart involvement, characterized by biochemical and instrumental modifications, is estimated to affect around 70% of patients with myositis. Cardiac involvement in IIM is often subclinical in the early stages of the disease. GLS has been proven to be an effective tool to predict heart disease. Our results show that GLS worsens over time and can be used as a possible predictor of death and cardiovascular events in this population.

A769: CORRELATION BETWEEN LEFT ATRIAL STRAIN AND DIFFERENT SCORES TO ASSESS FUNCTIONAL CAPACITY IN CARDIAC AMYLOIDOSIS

Maria Concetta Pastore (a), Elisa Giacomin (a), Mariangela Vigna (b), Matilde Lambardi (a), Federica Marrese (a), Davide Discenza (a), Gian Luca Ragazzoni (a), Giulia Elena Mandoli (a), Luna Cavigli (a), Flavio D'Ascenzi (a), Ciro Indolfi (b), Matteo Cameli (a), Marta Focardi (a)

(a) DEPARTMENT OF MEDICAL BIOTECHNOLOGIES, DIVISION OF CARDIOLOGY, UNIVERSITY OF SIENA, SIENA, ITALY; (b) DIVISION OF CARDIOLOGY, DEPARTMENT OF MEDICAL AND SURGICAL SCIENCES, MAGNA GRAECIA UNIVERSITY, CATANZARO, ITALY

Background. Cardiac amyloidosis (CA) is an infiltrative cardiomyopathy with high physical and psychological impact for patients. It develops progressive decline in cardiac diastolic and, in severe cases, systolic function, resulting in a gradual onset of heart failure (HF) symptoms with deterioration of functional abilities and quality of life (QoL). Kansas City Cardiomyopathy Questionnaire (KCCQ) is a validated method to assess functional capacity in CA. However, some author claims that it may be excessively reliant on psychological factors. Speckle tracking echocardiography (STE) has emerged as a reliable technique to show early impairment of left ventricular (LV) systolic and diastolic function in CA. Particularly, left atrial (LA) strain is a marker of LV filling pressures and HF symptoms.

Objective: In this pilot observational study, our objective was to assess the correlation between LA strain and currently available scores assessing functional capacity in patients with HF. Furthermore, we aimed to examine their association with NTproBNP levels in patients affected by CA.

Methods. We consecutively enrolled outpatients with CA during their follow-up visits. These patients underwent clinical, biohumoral assessments and echocardiographic evaluations, including STE. Additionally, on the same day, we administered the Kansas City Cardiomyopathy Questionnaire (KCCQ) score, Minnesota living with HF questionnaire (MLWHFQ), Duke Activity Status Index (DASI) and Health-related quality of life (HrQoL) score. Correlation analysis was performed employing Pearson's coefficient and linear regression analysis to evaluate the relationship between the acquired data.

Results. Overall, 21 patients diagnosed with CA (17 ATTR, 5 AL) were included in the study. Mean age was 78±9.6, only 9% (n=2) were female. While most patients exhibited a normal LV) ejection fraction (55±8%), LV global longitudinal strain was overall reduced (GLS=-14 ± 4%). The median peak atrial longitudinal strain (PALS) was 14 [interquartile range=8;24]%. Average KCCQ and MLWHFQ score was 70 ± 22 and 36 ± 25 Finally mean DASI score was 23 ± 13 with relative average estimated Mets 5 ± 1. Among the proposed questionnaires, PALS demonstrated a substantial positive correlation only with DASI score (Fig 1, P=0.45, R^2=0.2, p-value=0.039). Importantly, MLWHFQ score had a strong positive correlation with N-terminal pro brain natriuretic peptide (NTproBNP) as a marker of congestion (P=0.68, R^2=0.47, p value=0.002. Also, PALS and NTproBNP were correlated, as shown in previous studies (P=0.5, R-squared 0.24, p=0.04).
Conclusions. our findings highlight a higher correlation between LA strain, as sensitive index of elevated LV filling pressures in CA, and DASI score as compared to KCCQ. Moreover, MLWHFQ was the best score correlating with NTproBNP as marker of congestion and HF symptoms. Even though there is the need of bigger studies to confirm these findings, this emphasizes the potential role of MLWHFQ and DASI score as more objective measures to evaluate functional status and congestion in CA.

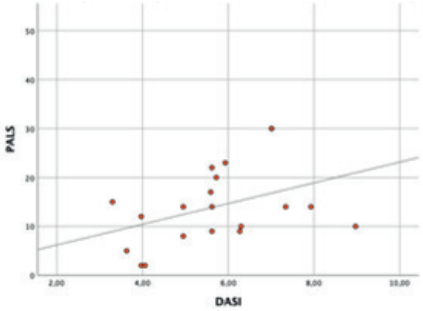

A770: VENTRICULAR ARRHYTHMIAS IN VIRAL MYOCARDITIS: RELATIONSHIPS BETWEEN ECG PATTERNS AND MYOCARDIAL INFLAMMATORY STAGE

Giovanni Peretto (a), Elisa Carturan (b), Stefania Rizzo (b), Andrea Villatore (a), Monica De Gaspari (b), Cristina Basso (b), Simone Sala (a), Paolo Della Bella (a)
(a) IRCCS OSPEDALE SAN RAFFAELE, MILANO; (b) OSPEDALE UNIVERSITARIO DI PADOVA, PADOVA

Background. Clinical features and risk stratification of patients with viral myocarditis (VM) complicated by ventricular arrhythmias (VA) are still unknown.
Aim. To describe arrhythmia patterns and outcomes in patients with VM and early-onset VA.
Methods. From a cohort of 796 clinically-suspected myocarditis, we identified patients with VM proven by endomyocardial biopsy and evidence of VA by 24 hours of hospitalization. Patients with polymorphic VA (P-VA) were compared to those with monomorphic VA (M-VA). The incidence of major adverse events (MAE), including all-cause death, complicated heart failure, advanced atrioventricular blocks, or major VA, was evaluated by 24-month prospective follow-up, and compared with a matched group of virus-negative myocarditis.
Results. Of patients with VM (n=74, mean age 47±16 years, 66% males, LVEF 51±13%), 20 (27%) presented with major VA (VT/VF), and 32 (44%) had P-VA. Patients with P-VA more commonly had evidence of acute infection (24/32 vs. 10/42, p=0.004) and experienced greater occurrence of MVA by discharge (15/32 vs. 2/42, p<0.001). Instead, the incidence of MAE by 24 months was higher in patients with M-VA (17/42 vs. 2/28, p=0.002), who more frequently showed cardiomyopathic features, and outcomes comparable with virus-negative myocarditis (Log rank p=0.929). Presentation with VT/VF was independently associated with MAE (by discharge: HR 4.7, 95%CI 1.6-14.0, p=0.005; by 24 months: HR 6.3, 95%CI 2.3-17.6, p<0.001).
Conclusions. In patients with VM, P-VA point to acute infection and early adverse outcomes, whereas M-VA suggest underlying cardiomyopathy and greater incidence of MAE by 24 months. Presentation with VT/VF is independently associated with MAE.

A771: ROLE OF ICD IMPLANT IN LEFT VENTRICULAR NON COMPACTION CARDIOMYOPATHY

Giulia Randi (b), Andrea Villatore (a, b), Lucia Molinari (b), Emanuela Sergianni (b), Paolo Della Bella (a), Giovanni Peretto (a, b)
(a) SAN RAFFAELE HOSPITAL, MILAN; (b) VITA-SALUTE SAN RAFFAELE UNIVERSITY, MILAN

Background. Left ventricular non compaction (LVNC) is characterized with unpredictable risk of malignant ventricular arrhythmias (MVA).
Purpose. We aimed to stratify the risk of MVA, and assess the role of ICD implant, in a cohort of patients with LVNC cardiomyopathy.
Methods. The study cohort consisted of 27 patients with a diagnosis of LVNC (mean age 39±15y, 63% males) undergoing regular, prospective follow up at a referral center for arrhythmia management. LVNC was diagnosed with echocardiogram and cardiac magnetic resonance, according to recognized criteria. ICDs were implanted either in primary or secondary prevention by combining the experience of the center with international guideline reccomendations for nonischemic cardiomyopathies. The primary study endpoint was the occurrence of MVA (including VF, sustained VT, appropriate ICD therapy) by 83-month median follow up.
Results. Eleven patients (41%) underwent ICD implant as secondary (n=6) or primary prevention (n=5, including two cases with MVA induced by invasive electophysiological test). The remaining 16 patients, including 8 cases with negative electrophysiological test, did not undergo ICD implant, and were monitored by 1/y Holter ECGs (n=14) or loop recorders (n=2). By 83 months, 4 patients (15%) experienced appropriate ICD shocks for MVA. No other MVA were recorded, and no unexplained syncope or palpitation suggesting MVA were documented in patients without implantable cardiac devices. Of the 4 patients experiencing MVA, 3 (75%) had baseline MVA occurring either spontaneously or (n=1) or by electrophysiological test (n=2), as opposed to those with uneventful follow-up (n=23), p=0.001. The difference in outcomes was significant even by comparing patients with inducible (n=2) vs. non-inducible MVA by electrophysiological test (n=8). As opposed, baseline features, including age, gender, NC/C ratio, and hyper-trabeculation sites were comparable between patients with and without follow-up MVA (all p>0.05).
Conclusions. Our preliminary data suggest that arrhythmic risk stratification in LVNC cardiomyopathy is driven by either spontaneous or induced MVA, more than by clinical and imaging features.

A772: CLINICAL OUTCOME OF IMPLANTABLE CARDIOVERTER DEFIBRILLATOR IN ARRHYTHMOGENIC CARDIOMYOPATHY WITH LEFT VENTRICLE INVOLVEMENT: 3-YEAR FOLLOW-UP

Raimondo Pittorru (a), Alberto Cipriani (a), Carlo Agostini (a), Martina Perazzolo Marra (a), Alessando Zorzi (a), Barbara Bauce (a), Manuel De Lazzari (a), Sabino Iliceto (a), Domenico Corrado (a), Federico Migliore (a)
(a) UNIVERSITÀ DEGLI STUDI DI PADOVA - DIPARTIMENTO DI SCIENZE CARDIO-TORACO-VASCOLARI

Background. Arrhythmogenic cardiomyopathy (ACM) is a genetic heart muscle disease characterised by fibrofatty replacement of the myocardium that predisposes to ventricular arrhythmias (VAs) and sudden death. Multiple ACM variants have been recognized: the right-dominant, the left-dominant (L-ACM) and the biventricular (biv-ACM). Implantable cardioverter-defibrillator (ICD) is the most effective therapy for interruption of potentially lethal VAs. There is limited data guiding the selection between subcutaneous (S-ICD) and transvenous (TV-ICD) as a preventive strategy for ACM patients with L- and biv-ACM. The aims of this study were to investigate the predictors of shock and compare the clinical outcomes among S- and TV-ICD in this specific group of ACM.
Methods. The study population included a consecutive series of patients with ACM diagnosed according to the 2020 International criteria, receiving S-ICD implantation with two-incision intermuscular technique or TV-ICD. Clinical characteristics and outcome data including major arrhythmic events (defined as ventricular fibrillation or ventricular tachycardia), ICD interventions and complications were collected.
Results. 58 ACM patients (males n=38 [66%], median age at implantation 34 years [22-48], 8 with L-ACM, 14 with S-ICD) were enrolled. During a median follow-up of 41 months (22-75), the rate of appropriate shocks did not differ between ICD groups (n=4 (29%) in S-ICD, n=17 (39%) in TV-ICD; p=0.50). No significant associations were found between clinical features and major arrhythmic events successfully treated with appropriate ICD intervention. Inappropriate interventions occurred in 21% S-ICD and 23% of TV-ICD carriers (p=1.00). Extra-cardiac oversensing (myopotential) during effort represented the only cause of inappropriate shock (IS) in the S-ICD group, while in the TV-ICD group the main cause of IS was supraventricular tachycardia, occurring in 7 patients. Device-related and lead-related complications were more frequent in the TV-ICD vs S-ICD population (23% vs 0%, p=0.038). The leading causes of TV-ICD-related complications were lead failure (n=7) and pocket infection (n=3).
Conclusions. In patients with L-ACM and biv-ACM, the ICD is equally effective in cardioversion of major arrhythmic events in both TV- and S-ICD recipients. Long term complications more frequently affect TV-ICD carriers.

A773: VENTRICULAR ARRHYTHMIAS IN A UNEXPECTED CARDIAC MAGNETIC RESONANCE

Raimondo Pittorru (a), Donatella Tansella (a), Alberto Cipriani (a), Stefania Rizzo (c), De Gasperi Monica (c), Michael Salama (a), Giorgio De Conti (b), De Lazzari Manuel (a), Federico Migliore (a), Cristina Basso (a), Sabino Iliceto (a), Martina Perazzolo Marra (a)
(a) UNIVERSITÀ DEGLI STUDI DI PADOVA - DIPARTIMENTO DI SCIENZE CARDIO-TORACO-VASCOLARI; (b) UNIVERSITÀ DEGLI STUDI DI PADOVA - UNITÀ DI

RADIOLOGIA, DIPARTIMENTO DI MEDICINA; (c) UNIVERSITÀ DEGLI STUDI DI PADOVA - DIPARTIMENTO DI SCIENZE CARDIO-TORACO-VASCOLARI- UNITÀ DI PATOLOGIA CARDIOVASCOLARE

Background. Electrical storm in a widespread inflammation of the myocardium represent a very challenging condition and recognizes a broad spectrum of etiology.

Case presentation. A 59-year-old man, without significant prior medical history, came to our attention because, following an emergent hernioplasty procedure, he displayed anterior ST-segment elevation and elevated troponin levels (150.000 ng/L). An echocardiogram revealed an estimated left ventricular ejection fraction (EF) of 39% with anterior hypokinesia. Coronary angiography showed no abnormalities. Cardiac magnetic resonance imaging demonstrated ring-like edema and ring-like late gadolinium enhancement in the left ventricle on T2-weighted and PSIR sequences, with no involvement of the right ventricle. Additionally, there was an increase in extracellular volume. Despite several laboratory tests to investigate infectious or autoimmune causes, the etiology remained inconclusive. To further explore the cause, an endomyocardial biopsy was performed. However, the patient experienced an unstable electrical storm three days later.

Management: Recurrent ventricular tachycardia (VT) was initially treated with esmolol, amiodarone, and procainamide, but with limited success. Due to VT-induced hemodynamic instability, the patient was sedated with propofol and intubated. Endomyocardial biopsy (EMB) confirmed lymphocytic myocarditis. In light of the hemodynamic instability and refractory electrical storm, the patient was promptly cannulated for veno-arterial extracorporeal membrane oxygenation (VA-ECMO) and started on methylprednisolone. Although there was an apparent resolution of VT, the patient experienced new episodes, necessitating percutaneous stellate ganglion block and an upgraded treatment plan that included mycophenolate mofetil. Given the high burden of arrhythmias, severe ventricular dysfunction, and the lack of response to medications, the patient is now awaiting cardiac transplantation.

Conclusions. Transmural edema and ring-like late gadolinium enhancement (LGE) in the early phase are predictors of a poor prognosis. In cases of hemodynamic deterioration and refractory electrical storms, it is crucial to promptly initiate mechanical support. Cardiac transplantation remains the sole treatment option for individuals who do not respond to antiarrhythmic and immunosuppressive drugs.

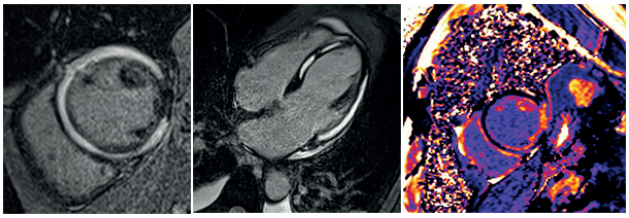

A774: RING-LIKE EDEMA IN HOT-PHASE ARRYHTHMOGENIC CARDIOMYOPATHY

Raimondo Pittorru (a), Riccardo Bariani (a), Alberto Cipriani (a), Manuel De Lazzari (a), Alessandro Zorzi (a), Federico Migliore (a), Monica De Gaspari (b), Stefania Rizzo (b), Cristina Basso (b), Ilaria Rigato (a), Giorgio De Conti (c), Raffaella Motta (c), Kalliopi Pilichou (b), Sabino Iliceto (a), Domenico Corrado (a), Barbara Bauce (a), Martina Perazzolo Marra (a)

(a) UNIVERSITÀ DEGLI STUDI DI PADOVA - DIPARTIMENTO DI SCIENZE CARDIO-TORACO-VASCOLARI; (b) UNIVERSITÀ DEGLI STUDI DI PADOVA - DIPARTIMENTO DI SCIENZE CARDIO-TORACO-VASCOLARI - UNITÀ DI PATOLOGIA CARDIOVASCOLARE; (c) UNITÀ DI RADIOLOGIA, UNIVERSITÀ DEGLI STUDI DI PADOVA - AZIENDA OSPEDALIERA DI PADOVA

Clinical presentation. An 18-year-old man was admitted due to recurring chest pain and persistent release of troponin (maximum 22,500 ng/dL). In September 2021, following an episode of syncope, an electrocardiogram revealed T-wave inversion in the right precordial leads. During the stress test, no arrhythmias were observed. The ECG-Holter monitoring showed isolated and monomorphic premature ventricular contractions with a left bundle branch block-like morphology and an inferior axis. Subsequently, cardiac magnetic resonance imaging (CMR) revealed hyperintensity in the midwall/subepicardial region of the infero-lateral wall of the left ventricle and the inferior and lateral walls of the right ventricle on T2-weighted STIR images. Initially these findings were interpreted as indicative of acute myocarditis. An elevated T1 mapping value was also recorded. The patient was discharged with an inflammatory therapy regimen consisting of aspirin and colchicine. However, after two months, he returned due to chest pain and an increased troponin levels. Another CMR was deemed required to reassess the cardiac injury of this patient. CMR findings: CMR with SSFP cine imaging, black blood T1-weighted and TIRM, T1 and T2 parametric mapping, and late gadolinium enhancement imaging was performed. 4-chamber SSFP cine images demonstrated left ventricle mildly dilated with an indexed left ventricular end-diastolic volume of 105 ml/m2 with anterolateral hypokinesia. The right ventricular present bulges in the lateral wall. There was mildly reduced biventricular systolic function. T1-weighted fast-spin echo (FSE) black blood imaging with and without fat saturation suggested subepicardial fat infiltration of the anterolateral left ventricular wall and of the diaphragmatic wall right ventricle. TIRM imaging - the most original finding - revealed a subepicardial/intramural ring-like pattern edema in the left ventricle wall. On late gadolinium enhancement imaging, there was subepicardial to mid-wall enhancement at the left ventricular lateral, anterior and apex segments. These findings were consistent with arrhythmogenic cardiomyopathy (acute phase) with biventricular involvement. Hook sign LGE in sarcoidosis typically involves subepicardial or midmyocardial layers with direct extension from the basal interventricular septum into the right ventricle

Learning outcomes:

- This is the first case in which ring-like pattern edema has been described in a patient with acute phase of arrhythmogenic cardiomyopathy.
- To stress the importance of CMR in differential diagnosis between myocarditis and left-sided genetic cardiomyopathies.

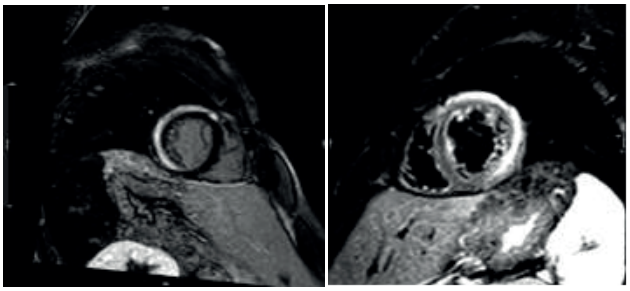

A775: REDEFINING CARDIAC INVOLVEMENT IN SYSTEMIC IMMUNOGLOBULIN LIGHT CHAIN AMYLOIDOSIS AND TREATMENT IMPLICATIONS

Aldostefano Porcari (a, c), Ambra Masi (a), Ana Martinez-naharro (a), Yousuf Razvi (a), Rishi Patel (a), Adam Ioannou (a), Giulio Sinigiani (b), Stefano Filisetti (d), Muhammad U Rauf (a), Brendan Wisniowski (a), Tushar Kotecha (a), Dan Knight (a), Gianfranco Sinagra (c), Sriram Ravichandran (a), Oliver Cohen (a), Shameem Mahmood (a), Philip N Hawkins (a), Julian D Gillmore (a), Ashutosh Wechalekar (a), Marianna Fontana (a)

(a) NATIONAL AMYLOIDOSIS CENTRE, DIVISION OF MEDICINE, UNIVERSITY COLLEGE OF LONDON, ROYAL FREE HOSPITAL, LONDON, UK; (b) DEPARTMENT OF CARDIO-THORACO-VASCULAR SCIENCES AND PUBLIC HEALTH, UNIVERSITY OF PADUA, PADUA, ITALY; (c) CENTRE FOR DIAGNOSIS AND TREATMENT OF CARDIOMYOPATHIES, CARDIOVASCULAR DEPARTMENT, AZIENDA SANITARIA UNIVERSITARIA GIULIANO-ISONTINA (ASUGI), UNIVERSITY OF TRIESTE, TRIESTE, ITALY; (d) CARDIOLOGY UNIVERSITY DEPARTMENT, HEART FAILURE UNIT, IRCCS POLICLINICO SAN DONATO, MILAN, ITALY

Background. Cardiac amyloid infiltration (CA) is the key determinant of survival in systemic AL amyloidosis. We aimed to assess, (i) the differences between serum biomarkers, echocardiography and CMR with ECV mapping in characterising cardiac involvement, (ii) the independent role of these approaches to predict prognosis, (iii) the role of ECV mapping to guide treatments strategies.

Methods. Study subjects comprised of consecutive patients newly-diagnosed with systemic AL amyloidosis between 2015-2021 who underwent echocardiography, cardiac biomarkers, and CMR with ECV mapping at the time of diagnosis. Haematological response (HR) at 1 and 6 months was defined according to validated criteria. The primary outcome was mortality.

Results. Five-hundred sixty AL patients were included. The different approaches produced different results in terms of presence and severity of cardiac infiltration (CA present from 48.2% to 93%). Over 40.5 months [IQR 9-58], all different approaches to assess cardiac involvement were associated with mortality ($p<0.001$), but only ECV was independently associated with mortality ($p<0.001$). In the landmark analysis at 1-month, patients with ECV≤0.30 and with ECV 0.31-0.40 had an excellent long-term survival regardless of the achieved HR ($p=0.92$ and $p=0.08$, respectively), whilst in patients with ECV>0.40 survival was dependent on the depth of the HR ($p<0.001$). In the landmark analysis at 6 months, patients with ECV≤0.30 had excellent survival regardless of the achieved HR and patients with ECV 0.31-0.40 had excellent survival if achieving at least a PR (inter-group $p=0.006$ in NR vs PR). In patients with ECV 0.41-0.50 and ECV>0.50 long-term survival was excellent only among patients achieving CR (inter-group $p<0.05$ in CR vs VGPR). Reaching a deep HR at 1 month was associated with better survival compared to 6 months in the cohort with ECV>0.40 ($p<0.05$), but not in patients with ECV≤0.40.

Conclusions. ECV mapping in systemic AL amyloidosis is the only independent predictor of prognosis when assessed with all approaches cur-

rently used to define CA. ECV mapping can define optimal depth and rapidity of the HR for each patient and inform treatment strategies.



A776: IMAGING ECOCARDIOGRAFICO AVANZATO NELLA VALUTAZIONE DEI PAZIENTI CON AMILOIDOSI CARDIACA: CONFRONTO TRA PARAMETRI DI RISONANZA MAGNETICA CARDIACA E STRAIN VENTRICOLARE SINISTRO

Gian Luca Ragazzoni (a), Maria Concetta Pastore (a), Elisa Giacomin (a), Francesca Susini (a), Alessandro Campora (a), Federica Marrese (a), Giulia Elena Mandoli (a), Luna Cavigli (a), Matteo Cameli (a), Flavio D'Ascenzi (a), Serafina Valente (a), Marta Focardi (a)
(a) UNIVERSITÀ DI SIENA, DIPARTIMENTO DI BIOTECNOLOGIE MEDICHE, DIVISIONE DI CARDIOLOGIA

Background. Le amiloidosi cardiache sono un gruppo eterogeneo di malattie caratterizzate dalla deposizione extracellulare di sostanza amiloide. Le due forme piu comuni di amiloidosi sono: l'amiloidosi AL, e la forma aTTR. Dal punto di vista diagnostico l'ecocardiografia è un importante metodica di studio, risulta utile nella diagnosi di coinvolgimento cardiaco in quanto è in grado di evidenziare un aumento degli spessori parietali e un pattern diastolico di tipo restrittivo. L'analisi speckle tracking consente di individuare alterazioni precoci della funzione sistolica anche con FE conservata, inoltre ci consente di evidenziare il caratteristico pattern di "apical sparing". La RMC è un esame di secondo livello che viene eseguito nei pazienti con sospetto di amiloidosi cardiaca consentendo di valutare la presenza di LGE e quindi di sostanza amiloide e la sua distribuzione.
Obiettivi. lo scopo di questo studio è di valutare la correlazione tra i valori di strain e i dati di localizzazione ed estensione del LGE nei soggetti con amiloidosi cardiaca.
Metodi.sono stati analizzati 32 pazienti riferiti al nostro centro che presentavano un coinvolgimento cardiaco e sono stati sottoposti a visita cardiologica, ECG, ecocardiografia standard, avanzata e RMC. Lo strain longitudinale ventricolare e atriale sinistro è stato correlato alla presenza di LGE alla RMC.
Risultati. Il GLS medio dei pazienti è -14 ± 4,1%. Il pattern caratteristico di apical sparing è presente nel 67,7% dei pazienti presi in esame. La quantità di LGE correla in maniera statisticamente significativa con l'aumento del GLS (p<0,001), inoltre la presenza di LGE correla in maniera statisticamente significativa con i valori di GLS in 9 segmenti su 17. Lo strain atriale correla in maniera statisticamente significativa con l'aumento dei segmenti interessati da fibrosi. (PALS p 0,002 e PACS p 0,007)
Conclusioni. L'utilizzo dell'ecocardiografia avanzata con analisi speckle tracking sia ventricolare che atriale consente di valutare in maniera più accurata la funzione cardiaca; inoltre correla in maniera statisticamente significativa con la quantità di LGE e può pertanto essere un valido strumento per stimare l'entità dell'infiltrazione. Questo studio ha anche mostrato risultati promettenti nell'utilizzo dello strain ventricolare per identificare la localizzazione dell'infiltrazione. Sono comunque necessari studi con una coorte più ampia per validare definitivamente questa correlazione.

A777: CHEST PAIN IN CARDIAC AMYLOIDOSIS

Andrea Roggio (a), Laura De Michieli (a), Filippo Donato (a), Alberto Cipriani (a)
(a) DIPARTIMENTO DI CARDIOLOGIA

Background. Cardiac amyloidosis (CA) is an uncommon disease characterized by the infiltration of amyloid fibrils in the myocardial interstitium; precursor proteins can be light chains (AL) or transthyretin (ATTR). Common clinical manifestations include heart failure (HF) with preserved ejection fraction, hyperkinetic arrhythmias, or atrioventricular conduction blocks. However, these patients can present also with more diverse clinical manifestations including chest pain and suspected acute coronary syndrome (ACS).
Case report. 84-years-old woman with systemic hypertension and a history of previous bilateral carpal tunnel surgery. She complained of dyspnea for mild to moderate exertion for about a year. Due to worsening dyspnea (NYHA class III), new onset chest pain and palpitations, she presented to the Emergency Department in our Center. The ECG revealed new-onset atrial fibrillation (heart rate 110 bpm) with nonspecific ventricular repolarization changes and diffuse low QRS voltages. The echocardiogram showed left ventricular hypertrophy with mild reduction in ejection fraction, apical akinesis with decreased longitudinal shortening, hypertrophic and dilated right ventricle, and mild circumferential pericardial effusion. At laboratory tests, high-sensitive cardiac troponin I was 2848 ng/L at first evaluation and it rose to 17364 ng/L at further measurements. A chest CT angiography was negative for pulmonary embolism, and the patient was admitted to the cardiac intensive care unit for ACS. Invasive coronary angiography showed coronary arteries without significant stenoses, with a doubtful occlusion of a thin recurrent apical branch. Ventriculography confirmed the mild depression of ejection fraction and segmental apical kinetic abnormalities. The diagnosis of Myocardial Infarction with Non-Obstructive Coronary Arteries (MINOCA) was established. Given the clinical presentation, the instrumental and laboratory findings, cardiac amyloidosis was suspected. Serum and urine immunofixation and serum free light chains (sFLC) were normal, ruling out the presence of a monoclonal gammopathy. A scintigraphy with bone-avid tracer showed increased tracer uptake in the cardiac area (Perugini grade 2) with higher concentration in the septal wall and in the basal inferior and basal lateral walls. A cardiac magnetic resonance imaging could not be performed due to claustrophobia. Thus, a diagnosis of MINOCA due to possible distal coronary embolization in concurrent ATTR-CA was achieved.
Conclusions. we report a clinical case of MINOCA in a patient with ATTR-CA. In this patient, in addition to chronic myocardial injury from amyloid infiltration, the patient had acute myocardial injury related to the MINOCA event. We suspect that MINOCA due to coronary embolism was triggered by an elevated thromboembolic risk related to ATTR-CA, in the context of new onset atrial fibrillation. It should be reminded that, although patients with ATTR-CA frequently manifest HF symptoms, they can also present with chest pain and suspected ACS. Specifically, our group previously reported that, in patients with ATTR, chest pain seems to be more commonly attributable to coronary artery disease, while in AL, to vascular/perivascular amyloid involvement. Moreover, episodes of chest pain in patients with CA appears to increase the risk of future HF hospitalization. This case underlines how the diagnostic process of patients with suspected ACS diagnosed with MINOCA should aim at identifying the etiological causes and involve pathogenetic mechanisms in order to initiate the most appropriate treatment for the individual patient.

A778: MYOCARDITIS, CORONARY ARTERY DISSECTION, OR BOTH? A JUVENILE ENIGMA

Elena Sala (a), Alberto Cereda (a), Gabriella Di Giovine (a), Barbara Conconi (a), Andrea Spangaro (a), Matteo Rocchetti (a), Stefano Marzorati (b), Stefano Lucreziotti (a)
(a) U.O.C. CARDIOLOGIA, OSPEDALE SAN CARLO BORROMEO, MILANO; (b) OSPEDALE DI CIRCOLO E FONDAZIONE MACCHI, VARESE

A 26 year old man was admitted to the Coronary Care Unit for severe, non-irradiated, oppressive anterothoracic pain, worsened by inspiration. He had no relevant pathological history, but reported an episode of gastroenteritis the week before. EKG showed sinus rhythm and accelerated idioventricular rhythm phases. Blood pressure and 2D echo were normal. Inflammation indeces were negative, troponin reached a peak of 2026 ng/L. Despite the absence of inflammation signs, our first guess was myocarditis. CMR (cardiac magnetic resonance) was performed: T2-weighted short-tau inversion recovery (T2w-STIR) images showed edema of the middle inferior wall and of the mid-basal anterior and anterolateral wall, while T1-weighted post gadolinium images showed transmural enhancement of the mid-basal anterior, antero lateral and inferior walls with a dubious origin from the sub endocardium in the anterior and anterolateral segments; left ventricle ejection fraction was 55%. Invasive coronary angiography (ICA) was performed to rule out ischemic etiology: LAD showed a very thin lumen in its periphery, with two diagonal side branches with amputated appearance, collateralized by marginal branches. Such appearance made us think of healing dissections and then it turned out that the patient have been working out with heavy weights the day before: we therefore considered spontaneous coronary artery dissection (SCAD). Such hypothesis was consistent with the absence of inflammations indices, but didn't explain the basal and middle inferior involvement that CMR had shown. On the other hand, the angiographic finding may be consistent with peripheral vascular suffering linked to myocarditis induced inflammation. Intravascular imaging was not performed to prevent the lesions from becoming more proximal. Due to the small diameter of the vessel at the site of the lesions, coronary CT would not have provided further information. To date, we haven't found univocal interpretation. Anti-remodeling therapy with ACEi and beta blockers was administered, in addition to acetylsalicylic acid. CMR will be performed in two months and may provide fur-

ther results once the edema will be reabsorbed. ICA will be repeated to make sure that distal coronary blood flow is improved.

Take home messages.

- Myocarditis can also occur with no signs of inflammation.
- In myocarditis it has been demonstrated that slower distal coronary blood flow may occur, due to the increase in peripheral vascular resistance linked to the presence of edema.
- In the acute phase, especially if CMR is performed very early, the large amount of edema can make the enhancement transmural, masking the site of origin of the damage.

A779: INCREASED RIGHT AMYGDALA ACTIVITY DURING THE HYPER-ACUTE PHASE OF TAKOTSUBO SYNDROME

Ilaria Ragnatela (a), Francesco Santoro (a), Rosa Cetera (a), Damiano D'Alessandro (a), Natale Daniele Brunetti (a)
(a) CARDIOLOGY UNIT, DEPARTMENT OF MEDICAL AND SURGERY SCIENCES, UNIVERSITY OF FOGGIA

Background. Takotsubo syndrome (TTS) is a heart failure syndrome featured by transient left ventricular dysfunction due to emotional or physical trigger. Recent studies showed that patients that will develop TTS have increased activity of brain emotional areas as amygdala.

Case report. A 66-year-old woman affected by ovarian carcinoma with multiorgan metastasis has been admitted to the Neurology Department due to recurrent episodes of motor aphasia followed by prolonged decreased level of consciousness. She underwent brain magnetic resonance and electroencephalogram (EEG) that were normal. Laboratory test and cardiological evaluation were normal. Cerebrospinal fluid cytology was positive for cancer cells. Two days later, the patient underwent brain 18-fluorodeoxyglucose positron emission tomography/computed tomography that highlighted relative hypermetabolism in the right amygdala (A) and areas of relative hypometabolism bilaterally in the fronto-parietal and parieto-occipital cortex (B). Few hours after this exam, the patient became suddenly comatose (Glasgow Coma Scale=3), laboratory tests were normal except for increased levels of high-sensitive troponin I (1254.3 ng/L). The ECG showed sinus rhythm and ST elevation in V2–V3, while echocardiogram revealed reduced left ventricular ejection fraction (35%) with apical ballooning. Coronary angiogram was normal. In the meantime, brain CT scan and EEG were repeated and were normal. During hospitalization, cardiological parameters turned normal within 10 days. Therefore, TTS diagnosis associated to leptomeningeal carcinomatosis was made. Unfortunately, after 28 days, the patient died due to acquired pneumonia.

Conclusions. We report during the hyperacute phase of TTS an increased activity of the right amygdala, a brain area that is associated with negative emotions.

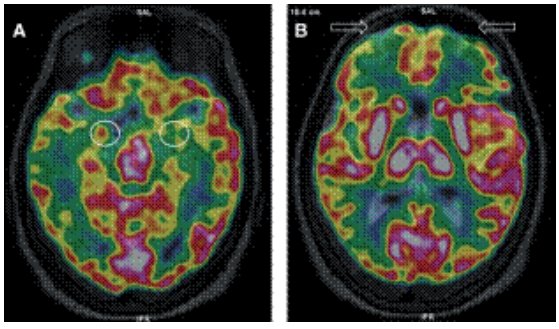

A780: HIGH SENSITIVITY TROPONIN INCREASE IN ANDERSON-FABRY DISEASE: TWO DIFFERENT PATHOPHYSIOLOGICAL MECHANISMS

Maria Alessandra Schiavo (a, b), Camilla Torlasco (c), Raffaello Ditaranto (a, b), Vanda Parisi (a, b), Di Nicola Federico (a, b), Ludovica Barile (a, b), Costantina Catalano (a, b), Riccardo Baldassarre (a, b), Luigi Lovato (d), Fabio Niro (d), Maddalena Graziosi (a), Irene Salamon (e), Nazzareno Galiè (a), Elena Biagini (a)
(a) CARDIOLOGY UNIT, IRCCS AZIENDA OSPEDALIERO-UNIVERSITARIA DI BOLOGNA, ITALY; (b) DEPARTEMENT OF EXPERIMENTAL, DIAGNOSTIC AND SPECIALTY MEDICINE, UNIVERSITY OF BOLOGNA, BOLOGNA, ITALY; (c) ITALIAN AUXOLOGICAL INSTITUTE SAN LUCA HOSPITAL, MILAN, ITALY; (d) UNIVERSITY HOSPITAL OF BOLOGNA S. ORSOLA-MALPIGHI POLYCLINIC, BOLOGNA, ITALY; (e) ALMA MATER STUDIORUM, UNIVERSITY OF BOLOGNA, DIMES (DEPARTEMENT OF EXPERIMENTAL, DIAGNOSTIC AND SPECIALTY MEDICINE), BOLOGNA, ITALY

Background. The role of high-sensitivity troponin (hs-Tn) in Anderson-Fabry disease (AFD) is not defined yet, few studies have found its increase in a relevant proportion of AFD patients, in whom it tended to be chronically elevated. An association between elevated hs-Tn levels and high T2 mapping (T2m) on cardiac magnetic resonance (CMR) has recently been noted. However, still little is known about its role in AFD and the possible pathophysiological mechanisms of its increase.

Purpose. To investigate the relationship among high-sensitivity troponin I (hs-TnI), T2m and left ventricular (LV) mass in FD patients and the effect of enzyme replacement (ERT) on hs-TnI, T2m and LV mass.

Methods. Fourty-six FD patients (59% females; 49 years [34-62]), undergoing CMR (1.5Tscan: cines, T2 mapping, LGE) and hs-TnI analysis were retrospectively evaluated. Of these, 30 patients had repeated CMR and hs-TnI dosage after 12 months. At 12 months, 20 patients were on chronic therapy (more advanced disease), while 10 (40% with LV hypertrophy) started therapy early after the first CMR.

Results. At baseline, hs-TnI was increased in 18 (39%) patients (67% females, 89% with LV hypertrophy) and it remained elevated at follow up. Left ventricular hypertrophy (LVH) was present in 24 patients (52%). T2m values, either global or at the inferolateral wall, were increased relative to the local normal range in 5 patients only (all females, 4 with LVH and one without hypertrophy). A significant positive correlation was seen between hs-TnI and T2m values (R 0.382, p=0.008), and an even stronger one between hs-TnI and cardiac mass (R 0.726, p<0.001), which remained significative at multivariable regression analysis. No correlation was found between T2m and cardiac mass. In subgroup analysis, a significant difference in T2m values was seen in patients with elevated hs-TnI compared to those with normal hs-TnI (53ms [51-56] vs 50ms [49–52], p 0.0003), while no significant difference was seen in T2m based on the presence or absence of LVH (52ms [49-53] vs 50ms [49-52], p 0.183). At follow-up, there was neither significant change in T2m, degree of LVH and hs-TnI, nor differences between the two groups (chronic ERT versus starting ERT).

Conclusions. A considerable number of our AFD patients have chronically elevated hs-TnI values. Hs-TnI elevation independently correlates both with T2m and LVH. The pathophysiological mechanism of myocardial damage appears to be twofold, on the one hand it correlates with edema and inflammation (T2m), on the other with the severity of the disease in terms of LVH. The reason why T2m is elevated in few patients (all females), some with more advanced disease (LVH), others at earlier stages (no LVH), is not known and requires investigation. These hypotheses and their potential implication on disease management will need to be assessed in future research, with longer follow up and wider patient's cohort.

A781: PROGNOSTIC VALUE OF VENTRICULAR-ARTERIAL UNCOUPLING IN CARDIAC AMYLOIDOSIS

Giulio Sinigiani (a), Laura De Michieli (a), Lisa Portalone (a), Andrea Pauro (a), Alessandro Comincioli (a), Sabino Iliceto (a), Donato Mele (a), Martina Perazzolo Marra (a), Alberto Cipriani (a)
(a) DEPARTMENT OF CARDIO-THORACO-VASCULAR SCIENCES AND PUBLIC HEALTH, UNIVERSITY OF PADUA, PADUA, ITALY

Introduction. Cardiac amyloidosis (CA) is an infiltrative cardiomyopathy, characterized by deposition of misfolded proteins, most commonly transthyretin (ATTR - CA) or immunoglobulin light chains (AL – CA). Characteristics and clinical meaning of left (LV) and right (RV) ventricular-arterial coupling is poorly investigated.

Methods. this is a monocentric, retrospective, observational study enrolling patients diagnosed with AL – CA or ATTR – CA between January 1st, 2018, and December 31st, 2022 undergoing a rest echocardiogram at diagnosis. LV arterial coupling (LVAC) was defined as the ratio between end systolic and anterograde stroke volumes, whereas RV arterial coupling (RVAC) as the ratio between RV systolic function (evaluated using either tricuspid annular plane systolic excursion (TAPSE) or fractional area change (FAC)) and the systolic pulmonary artery pressure (sPAP). Primary endpoint was cardiovascular death. Patients were followed up to May 31st, 2023.

Results. overall, 184 patients (82% males, median age of 76 years, 59 AL – CA and 125 ATTR – CA) were included. In AL – CA, after a median follow up of 19 months (12 – 38), 24 (41%) patients died. Compared to survivors, in non-survivors LVAC resulted significatively worse (0.89 vs 0.80, p=0.049). No differences were observed in RVAC among the two groups. At multivariable analysis, LVAC emerged as independent predictor of mortality (HR 2.34, 95% CI 1.03 – 5.30, p=0,01). A threshold value for LVAC of 0.783 well stratified the survival probability at 12 months (78% vs 90%, log rank p=0.034). In ATTR – CA, after a median follow up of 11 months (6 – 16), 20 (16%) patients died. Compared to survivors, in non-survivors RVAC was significatively worse, either when evaluated with TAPSE/sPAP (0.39 vs 0.55 mm/mmHg, p=0.001) or FAC/sPAP (0.96 vs 1.10%/mmHg, p=0.02). No differences were observed in LVAC among the two groups. At multivariable analysis, RVAC emerged as independent predictor of mortality, either when evaluated with TAPSE/sPAP (HR 0.03, 95% CI 0.002 – 0.540, p=0.02) or FAC/sPAP (0.20, 95% CI 0.04 – 0.87, p=0.03). A threshold value of 0.31 mm/mmHg for TAPSE/sPAP and 0.78%/mmHg for FAC/sPAP well stratified the survival probability at 12 months (77% vs 97%, log rank p=0.004; 83% vs 97%, log rank p=0.001, respectively).

Conclusions. Ventricular-arterial uncoupling is common in CA and has independent prognostic significance. Poor survival was significantly observed in ATTR-CA with low RVAC and in AL-CA with low LVAC.

A782: A RARE CASE OF ROSAI-DORFMAN DISEASE MIMICKING AN ACUTE PERICARDITIS

Niccolò Siviero (a), Mattia Corianò (a), Giacomo Prete (a), Davide Barbisan (c), Marta Possamai (b), Carlo Cernetti (b), Nicola Gasparetto (b)
(a) CARDIOLOGY UNIT, DEPARTMENT OF CARDIAC, THORACIC, VASCULAR SCIENCES AND PUBLIC HEALTH, UNIVERSITY OF PADUA, ITALY; (b) CARDIOLOGY UNIT, CARDIO-NEURO-VASCULAR DEPARTMENT, CA' FONCELLO HOSPITAL, TREVISO, ITALY; (c) CARDIOTHORACOVASCULAR DEPARTMENT, UNIVERSITY HOSPITAL CATTINARA, ASUGI AND UNIVERSITY OF TRIESTE, ITALY

A 54-year-old man was admitted to the hospital with a three-day history of chest pain aggravated by deep inspiration and the supine position and relieved by the sitting position. In the preceding month, he experienced fatigue, profuse perspiration, and, a few days prior to admission, a fever (peaking at 38°C). He had no significant prior medical history. The electrocardiogram revealed sinus tachycardia, right bundle branch block, and diffuse T-wave abnormalities. Laboratory examination showed elevated C-reactive protein (8.32 mg/dL) and a mild elevation in troponin T (23 ng/L). Echocardiography was performed, revealing a mild circumferential pericardial effusion (maximum thickness 9 mm) without other cardiac abnormalities. Suspecting acute myopericarditis, the patient was initiated on anti-inflammatory therapy with ibuprofen and colchicine, and he was discharged after a few days. During a follow-up visit one month later, the patient was asymptomatic and afebrile, but he reported the development of a lump in the suprapubic region. Echocardiography showed an intrapericardial mass involving the antero-lateral wall of the left ventricle and the right ventricular outflow tract (RVOT). Further advanced imaging studies were warranted. A chest computed tomography (CT) scan revealed a nonhomogeneous pericardial mass with a longitudinal diameter of approximately 10 cm and transverse dimensions of 9.4 cm x 7 cm, encircling the left ventricle, left atrial appendage, RVOT, left main coronary artery at its bifurcation, left anterior descending artery, and the ramus intermedius. Cardiac magnetic resonance imaging confirmed the presence and dimensions of a solid intrapericardial expansive mass, demonstrating hypointensity on T1-weighted sequences and hyperintensity on T2-weighted sequences, with homogeneous late gadolinium contrast enhancement. Subsequently, a CT-PET with fluorodeoxyglucose (FDG) was performed, revealing increased metabolic activity (SUV max 14.42) within the mass. Additionally, there was heightened FDG uptake in a subcutaneous nodule in the hypogastric region and in two lymph nodes in the sternal region. A biopsy of the subcutaneous nodule was then performed, and histopathological analysis of the sample demonstrated the presence of Rosai-Dorfman disease, a rare form of non-Langerhans cell histiocytosis, characterized by accumulation of large pale hystiocites showing the emperipolesis phenomenon. After a multidisciplinary team discussion, we opted for a surgical removal of the pericardial mass.

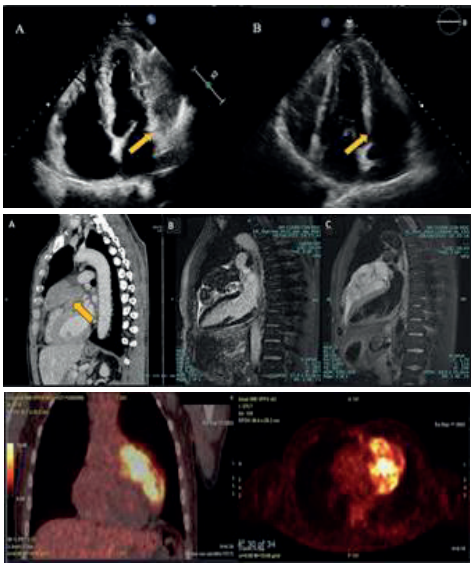

A783: A RARE CASE OF CONSTRICTIVE PERICARDITIS AND RAPID PROGRESSION OF VALVULAR DISEASE IN PATIENT WITH END STAGE RENAL DISEASE AND REACTIVE AMYLOIDOSIS.

Eugenio Trovarelli (a), Anna Mengoni (a), Cinzia Zuchi (a), Andrea Santucci (b), Rocco Sclafani (b), Erberto Carluccio (a), Giuseppe Ambrosio (a)
(a) CARDIOLOGIA E FISIOPATOLOGIA CARDIOVASCOLARE, AZIENDA OSPEDALIERO UNIVERSITARIA SANTA MARIA DELLA MISERICORDIA, PERUGIA; (b) S. C. CARDIOLOGIA, AZIENDA OSPEDALIERO UNIVERSITARIA SANTA MARIA DELLA MISERICORDIA, PERUGIA

Case report. In 2022, a 61 years old male patient was admitted for worsening renal function: reactive amyloidosis was diagnosed. During hospitalization, trans-thoracic echocardiogram showed mild aortic insufficiency and mild mitral insufficiency. One year later, the patient was admitted for signs and symptoms of heart failure and diuresis contraction. Renal function had further deteriorated to the extent that he required hemodialytic treatment. Echocardiogram showed worsening valvular pathology: aortic and mitral insufficiency become severe while aortic and mitral stenosis moderate. There was also a restrictive diastolic pattern with elevated filling pressure but medial mitral annulus tissue-Doppler demonstrated elevated early diastolic velocities (e'). Severe pulmonary hypertension with severe tricuspid insufficiency and severe right ventricular (RV) dysfunction were also present. Size and function of left ventricle (LV) were normal. The pericardium was hyperechogenic and there was partially organized pericardial effusion too. A trans-esophageal echocardiogram confirmed the degree of severity of valvulopathy, and chest computer tomography confirmed pericardial calcifications. Suspecting constrictive pericarditis, the patient underwent cardiac catheterization. It showed the matching of RV and LV pressure traces, enhanced ventricular interdependence, and dip-and-plateau pattern (or square root sing), confirming diagnosis.

Discussion. The particularity of this case lies not only in its remarkable complexity, but also in the rapidity with which the heart disease evolved. Although the most common causes of constrictive pericarditis are post cardiac surgery, radiation therapy, and tuberculosis, constrictive pericarditis can also occur in end-stage renal disease patients. The most likely mechanism of this rapid progression may lie in the elevated blood values of phosphate and calcium secondary to worsening renal failure. Hyperphosphatemia has been described as a key factor in vascular and other extra skeletal calcification and a risk factor for cardiovascular mortality. A crucial event is a phenotype switch of vascular smooth muscle cells to osteoblast-like cells which is induced through a number of different stimuli like hyperphosphatemia and hypercalcemia. Pro-inflammatory cytokines that are increased in chronic kidney disease and in reactive amyloidosis have pro-osteogenic potential.

Conclusions. This is the first case reported in literature, of constrictive pericarditis and rapid progression of multiple calcific valvulopathy in dialysis patients, probably caused by a chronic inflammatory state and electrolyte imbalance.

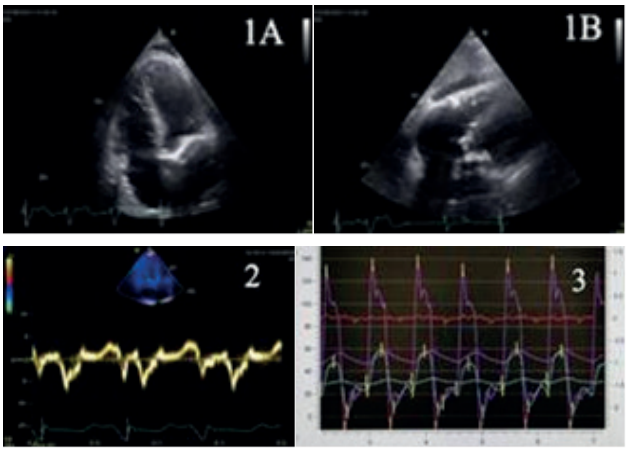

Figure 1. (A, B) Pericardial thickening, pericardial effusion; aortic and mitral calcification.
Figure 2. Medial mitral annulus tissue-Doppler: elevated early diastolic velocities (e').
Figure 3. Dip and plateau pressure trace in constrictive pericarditis.

A784: UNA CARDIOMIOPATIA FUORVIANTE: L'IMPORTANZA DELLE RED FLAGS NELLA DIAGNOSI DI AMILOIDOSI CARDIACA

Andrea Zaccaro (a), Giulia Saturi (a), Alberto Ponziani (a), Irene Ruotolo (a), Antonella Accietto (a), Giuseppe Sena (a), Alessandro Giovannetti (a), Christian Gagliardi (a), Elena Biagini (a), Nazzareno Galiè (a), Simone Longhi (a)
(a) IRCSS POLICLINICO SANT'ORSOLA MALPIGHI - ALMA MATER STUDIORUM UNIVERSITÀ DI BOLOGNA

Uomo, 78 anni, affetto da ipertensione arteriosa di grado lieve, con storia di extrasistolia ventricolare da anni e parestesie alle ultime due dita di entrambe le mani mai indagate. In anamnesi cardiologica recente ricovero per edema polmonare acuto sintomatico per dispnea ed edemi declivi con riscontro all'ecocardiogramma di moderata disfunzione sistolica del ventricolo sinistro (FE 40%) con ipocinesia ai segmenti infero-posteriori basali e lieve ipertrofia parietale concentrica (SIV td 1,3 cm), disfunzione diastolica di I grado, valvole ispessite con insufficienza mitralica lieve, insufficienza aortica eccentrica di grado lieve-moderato

e minimo versamento pericardico. All'ECG bradicardia sinusale e blocco atrioventricolare di primo grado, in assenza di segni di ipertrofia ventricolare sinistra e alterazioni di tipo ischemico. Al monitoraggio elettrocardiografico continuo segnalati frequenti battiti ectopici ventricolari con morfologia a blocco di branca destra e alcune salve di tachicardia ventricolare non sostenuta. Alla luce della moderata disfunzione ventricolare sinistra associata ad alterazioni della cinetica segmentaria e alla determinazione di Troponina I-hs pari a 28,5-25,9 ng/L, è stato eseguito studio coronarografico con riscontro di ateromasia coronarica in assenza di lesioni angiograficamente significative. La risonanza magnetica cardiaca ha confermato la lieve ipertrofia parietale simmetrica del ventricolo sinistro e la disfunzione sistolica ventricolare sinistra di grado moderato con severa ipocinesia dei segmenti basali, evidenziando inoltre una moderata disfunzione sistolica del ventricolo destro (FE 41%), peraltro di normali dimensioni, e allo studio del late gadolinium enhancement aree di ritardato wash-out mid-wall con pattern "ring-like" nei segmenti basali e medi. Il paziente veniva dimesso con diagnosi di cardiomiopatia aritmogena ed è stato riferito presso il centro "Cardiomiopatie". Al momento della prima valutazione il paziente riferiva miglioramento soggettivo con dispnea per sforzi di grado moderato (NYHA II). All'ECG si constatava l'assenza di extrasistolia ventricolare. All'ecocardiogramma si assisteva ad un miglioramento della funzione sistolica globale (FE 47%), confermando l'ipertrofia parietale con spessore massimo a livello del setto posteriore basale (max 1,5 cm). Essendo predominante il quadro di ipertrofia ventricolare sinistra, sono stati eseguiti: dry blood spot per malattia di Anderson-Fabry (negativo), scintigrafia ossea total body con 99m Tc-DPD con riscontro di ipercaptazione cardiaca (Perugini score=2), immunofissazione sierica e urinaria (negative), dosaggio delle catene leggere libere kappa e lambda (negativo), con diagnosi finale di amiloidosi cardiaca da transtiretina. L'analisi genetica ha confermato la presenza di mutazione Ile68Leu del gene della transtiretina e una valutazione neurologica con elettromiografia ha posto diagnosi di sindrome del tunnel carpale bilaterale e di polineuropatia sensitiva distale degli arti inferiori. Veniva intrapreso trattamento specifico ed avviato lo screening familiare nei parenti di primo grado.

Conclusioni. il presente caso clinico denota come la diagnosi di amiloidosi cardiaca, tutt'oggi spesso sottodiagnosticata, rappresenti una vera e propria sfida per il cardiologo clinico. L'importanza di giungere rapidamente alla diagnosi definitiva, grazie anche all'utilizzo delle "red flags" costituite dalla costellazione di segni e sintomi della malattia, rappresenta l'elemento fondamentale per intraprendere idonea terapia e migliorare la prognosi.

A785: PREVALENCE OF WILD-TYPE TRANSTHYRETIN CARDIAC AMYLOIDOSIS: A SCREENING STUDY IN UNSELECTED ELDERLY SUBJECTS

Alberto Aimo (a, b), Giuseppe Vergaro (a, b), Vincenzo Castiglione (a, b), Iacopo Fabiani (b), Andrea Barison (a, b), Francesco Gentile (b), Yu Fu Ferrari Chen (b), Assuero Giorgetti (b), Dario Genovesi (b), Gabriele Buda (f), Maria Franzini (f), Stefano Moscardini (e), Claudio Rapezzi (c), Marianna Fontana (d), Claudio Passino (a, b), Michele Emdin (a, b)

(a) SCUOLA SUPERIORE SANT'ANNA, PISA; (b) FONDAZIONE TOSCANA GABRIELE MONASTERIO, PISA; (c) UNIVERSITÀ DI FERRARA; (d) NATIONAL AMYLOIDOSIS CENTRE, LONDRA; (e) AZIENDA USL TOSCANA NORD OVEST; (f) UNIVERSITÀ DI PISA

Aims. Wild-type transthyretin cardiac amyloidosis (ATTRwt-CA) affects older adults, and is currently considered as a rare disorder (i.e., with a prevalence <0.05%). We investigated for the first time the prevalence of ATTRwt-CA in unselected individuals aged 65-90 years from the general population.

Methods and Results. General practitioners from Pisa, Italy, proposed a screening for ATTRwt-CA to subjects aged 65-90 years, until 1,000 accepted. The following red flags were searched: interventricular septal thickness ≥12 mm, any echocardiographic, ECG or clinical hallmark of CA, or high sensitivity-troponin T ≥14 ng/L. Individuals with at least one red flag (n=346) were asked to undergo the search for a monoclonal protein and bone scintigraphy, and 216 accepted. Four patients were finally diagnosed with ATTRwt-CA, none presenting with a monoclonal protein: Both complaining of dyspnoea on moderate effort. A woman and a man aged 79 and 85 years, respectively, showed an intense cardiac tracer uptake (grade 3), left ventricular (LV) wall thickening, grade 2 to 3 diastolic dysfunction, and N-terminal pro-B-type natriuretic peptide (NT-proBNP)>1,000 ng/L. Two other patients (a man aged 74 years and a woman aged 83 years) showed a grade 2 uptake, an increased LV septal thickness, but preserved diastolic function, and NT-proBNP<300 ng/L. The prevalence of ATTR-CA in subjects ≥65 years was calculated as 0.46% (i.e., 4 out of the 870 subjects completing the screening).

Conclusions. ATTRwt-CA has a prevalence of 0.46% in the elderly population (0.10% in the general population across all age categories).

A786: VALUTAZIONE CARDIOLOGICA DELLE PAZIENTI PORTATRICI DI VARIANTI PATOGENE DEL GENE DMD

Chiara Calore (a), Anna Mutterle (b), Pietro Riguzzi (c), Luca Bello (c), Riccardo Bariani (b), Elena Pegoraro (c), Barbara Bauce (b)

(a) CLINICA CARDIOLOGICA, AZIENDA OSPEDALIERA UNIVERSITÀ DI PADOVA; (b) DIPARTIMENTO DI SCIENZE CARDIO-TORACO-VASCOLARI E SANITÀ PUBBLICA, UNIVERSITÀ DI PADOVA; (c) DIPARTIMENTO DI NEUROSCIENZE DNS, UNIVERSITÀ DI PADOVA

Background. La distrofia muscolare di Duchenne (DMD) è una malattia geneticamente determinata X-linked caratterizzata da mutazioni del gene DMD, responsabile della produzione della distrofina. Clinicamente, la malattia è caratterizzata da una progressiva compromissione fisica con perdita della deambulazione verso i 12 anni di età. A livello cardiaco i pazienti presentano dilatazione e disfunzione sistolica del ventricolo sinistro (Vsin) che, insieme alla compromissione respiratoria, è spesso responsabile del decesso del paziente. La prognosi della DMD è migliorata nel corso degli anni grazie all'introduzione della ventilazione assistita e delle terapie farmacologiche per la cura dello scompenso cardiaco e l'aspettativa di vita, attualmente, è di 30-40 anni. Le portatrici di sesso femminile di mutazioni patogene del gene DMD sono generalmente protette dallo sviluppo del fenotipo DMD-like per la presenza di un allele sano; tuttavia possono sviluppare la patologia cardiaca che ne riduce l'aspettativa di vita rispetto alla popolazione sana.

Scopo dello studio. Descrivere dal punto di vista clinico le pazienti portatrici di varianti del gene DMD, con particolare riguardo al fenotipo cardiaco. Inoltre, ricercare eventuali correlazioni tra le manifestazioni neurologiche e cardiologiche della malattia.

Materiali e metodi. Sono state esaminate 51 pazienti portatrici di mutazioni del gene DMD. Per ciascuna paziente sono stati valutati i dati amnestici, genetici e clinico-strumentali (sia neurologici che cardiologici). In particolare, la valutazione cardiologica comprendeva esame obiettivo, ECG a 12 derivazioni, ECG dinamico Holter delle 24 ore, ecocardiogramma Color-Doppler e risonanza magnetica cardiaca (RMC) con contrasto.

Risultati. L'età media delle pazienti era di 49 anni (min 16, max 83 anni) e il 76% presentava storia familiare positiva per DMD. L'analisi molecolare ha mostrato la presenza di inattivazione random del cromosoma X nel 55%, mentre nel 30% l'inattivazione era "skewed". Il 29% delle pazienti sono state sottoposte a biopsia muscolare che ha rivelato un mosaico di fibre distrofino-positive e negative all'immunofluorescenza. La CPK sierica era aumentata nell'80% delle pazienti, con una media di 914,7 U/L. Il 43% del campione risultava sintomatico dal punto di vista neuromuscolare. La valutazione cardiologica è stata eseguita in 46 pazienti, di cui 11 sono risultate affette da cardiopatia, diagnosticata come presenza di dilatazione e/o disfunzione del Vsin. L'ECG era alterato nel 50% delle pazienti con cardiopatia, le quali mostravano all'ECG Holter una media di 1565 extrasistoli ventricolari/24 ore. Il confronto tra il fenotipo cardiologico con quello neurologico, ha mostrato che il 67% delle pazienti con cardiopatia mostrava anche un fenotipo neurologico intermedio o severo. La RMC è stata eseguita in 6 pazienti ed ha mostrato presenza di LE epicardico a livello della parete postero-laterale basale in 4 pazienti classificate come affette da cardiopatia ed in 2 che mostravano un ecocardiogramma nei limiti di norma. Durante il follow-up, due pazienti sono state sottoposte ad impianto di ICD ed una paziente è deceduta per scompenso cardiaco refrattario.

Conclusioni. La DMD è una malattia fortemente invalidante nella popolazione maschile affetta ma può avere delle manifestazioni anche nelle portatrici di sesso femminile, soprattutto di carattere cardiologico. Le pazienti che presentano una variante genetica patogena del gene DMD devono essere sottoposte a follow-up cardiologico periodico, con esecuzione anche di RMC.

A787: INDICATION AT ICD IN HYPERTROPHIC CARDIOMYOPATHY: WHICH IS THE IMPACT OF DIFFERENT GUIDELINES?

Giorgia Benzoni (a), Valeria Rella (d), Davide Mariani (d), Martino Meda (d), Silvia Castelletti (d), Sabrina Salerno (d), Silvia Ravaro (c, d), Paolo Cerea (d), Franco Cecchi (d), Gianfranco Parati (a, b), Lia Crotti (a, d)

(a) UNIVERSITY OF MILANO- BICOCCA- MEDICINE AND SURGERY DEPARTMENT, CARDIOVASCULAR DISEASE RESIDENCY PROGRAM; (b) IRCCS ISTITUTO AUXOLOGICO ITALIANO; (c) UNIVERSITY OF MILANO- BICOCCA; (d) IRCCS ISTITUTO AUXOLOGICO ITALIANO, CARDIOMYOPATHY UNIT, CENTER FOR CARDIAC ARRHYTHMIAS OF GENETIC ORIGIN AND LABORATORY OF CARDIOVASCULAR GENETICS

Introduction. Different guidelines provide different indications regarding use of implantable cardioverter defibrillators (ICD) in patients with hypertrophic cardiomyopathy (HCM). This may have a significant impact on the decision to implant an ICD in clinical practice.

Aim. The aim of our study was to evaluate how the different guidelines are impacting on the number of patients that will enter in a class of indication for ICD implant.

Methods. We retrospectively analyzed 231 patients affected by hypertrophic cardiomyopathy (HCM), and we calculated for each patient Sudden Cardiac Death (SCD) Risk Score based on 2014 European Society of Cardiology (ESC) guidelines for HCM: for each patient we considered the class of recommendation for implantable cardioverter defibrillator (ICD), and we compared each result to ESC 2022 guidelines for the Management of Patients with Ventricular Arrhythmias and the Prevention of Sudden Cardiac Death and to ESC 2023 guidelines for the manage-

ment of cardiomyopathies. Parameters considered in 2022 ESC guidelines are the same of ESC 2014 guidelines, but for patient which totalize SCD risk score under 4% or between 4-6% other parameters have been included to better stratify the risk and to delineate indications for ICD implantation. Furthermore, we also made a comparison with the 2020 American Heart Association (AHA) guidelines for the diagnosis and treatment of patient with hypertrophic cardiomyopathy.

Results. 7% of our patients population received a class IIa indication at ICD implant following ESC 2014 guidelines (Fig1) the same percentage of ESC 2023 guidelines (Fig 4), but this percentage increased to 15% applying the 2022 ESC guidelines (Fig.2) and to 40% when considering the 2020 AHA guidelines (Fig.3). Patients with no indications to ICD implant (class III) were the vast majority (74%) when considering 2014 ESC guidelines (Fig.1), 66% considering ESC 2023, but this percentage decreases to 63% (Fig.2) and to 39% (Fig.3) by applying the 2022 ESC and the 2020 AHA criteria, respectively. Under ESC 2023 guidelines 26% received a class IIb indication (Fig 4) substantially in line with previous European guidelines. Therefore, application of different criteria provided by different guidelines has a significant impact on the number of patients in whom an indication to ICD implant is given.

Conclusions. Our data show how the application of different guidelines may lead to different indications regarding ICD implantation. Shifting from ESC 2014 to ESC 2022 and to AHA 2020 guidelines led to a progressive increase in the number of patients in which an ICD could/should be recommended, with the greatest percentage obtained applying American rather than European guidelines; ESC 2023 went back to a more conservative approach. Although Sudden Cardiac Death is one of the leading causes of death in HCM, ICD implantation is not free of risk. Therefore, a re-evaluation of the discrepant indications provided by different guidelines could be usefully made through the assessment of the risk-benefit ratio of this procedure in studies including a large patients population.

Figure 1. **Figure 2.** **Figure 3.** **Figure 4.**

A788: THROMBOSIS IN LEFT VENTRICULAR NON-COMPACTION: A TEN YEARS CHALLENGE

Matilde Bertamino (a), Carla Zannelli (a), Henri Xhakupi (a), Roberta Della Bona (a)
(a) IRCCS OSPEDALE POLICLINICO SAN MARTINO

Left ventricular non-compaction (LVNC) is an autosomal dominant and still unclassified cardiomyopathy caused by the arrest of myocardial compaction during embryogenesis; this condition is characterized by an extremely thick endocardial layer with prominent trabeculations and deep recesses communicating with left ventricular cavity. Usually, the diagnosis is primarily suspected when myocardium appears "spongy" on the echocardiogram, although it is confirmed by not standardized cardiac MRI and computed tomography (CT) imaging criteria. The most typical sequelae are heart failure, arrhythmias, and thrombus formations that may lead to cardioembolic events within adults. The management of these patients is therefore difficult, and treatment relies on neurohormonal inhibition therapy for heart failure (HF), ICD implantation, lifelong anticoagulation, and sometimes, heart transplantation. We present the case of a 77-year-old woman who was admitted to our department for acute decompensated heart failure in a known left ventricular non compaction (LVNC) cardiomyopathy, previously undergone intracardiac defibrillator (ICD) implant. The echocardiogram showed a severe left ventricular (LV) dilation and dysfunction and revealed a remarkable thick hyperechogenic ridge along the midventricular portion of the LV lateral wall. This finding was suggestive for calcification, also visible at chest X-rays and subsequently confirmed by a CT scan (Figure 1, panel D and B, respectively). The patient was on anticoagulation therapy with dicumarols after that, ten years before, a cardiac MRI performed to confirm the diagnosis of LCNC had shown a massive thrombosis extending along the inner layer of the LV mid-apical lateral non-compaction area (Figure 1, panel A). The comparison of the images suggests a complete calcified evolution of the previous massive thrombosis. Even if thrombus formation is a typical sequela and chronic thrombi may develop spotty calcifications, large foci or a diffuse appearance is rare. This case illustrates an unusual evolution over ten years of an extensive thrombus attached to the uncompacted layer of the myocardium. Unfortunately, we couldn't perform a cardiac MRI because of the ICD but the comparison between the previous cardiac MRI and the actual CT scan is still quite impressive. To the best of our knowledge this is the first report describing a complete calcified evolution of an apical thrombus detected ten years earlier in a LVNC cardiomyopathy.

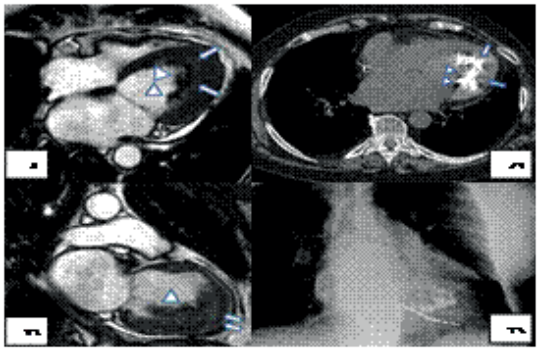

A-B. (2009) Cine gradient echo MRI images. A 4-chamber view, B 2-chamber view; an irregular dark mass (arrowheads) adherent to trabeculations appears in both images. C-B. (2021) Calcific evolution of the thrombotic deposition showed on CT scan (C) and chest X-rays (D).

A789: SERIAL CARDIAC MAGNETIC RESONANCE IMAGING FOR GUIDANCE OF THERAPY MANAGMENT IN PATIENTS TREATED WITH ANAKINRA DUE TO RECURRENT PERICARDITIS

Francesca Coretti (c), Francesco Bianco (b), Valentina Bucciarelli (b), Elena Raffaelli (b), Serena Cataldi (a), Francesca Damadei (a), Alessia Omenetti (a), Bianca Lattanzi (a), Giuseppe Ciliberti (c), Federico Guerra (c), Carlo Catassi (a), Antonio Dello Russo (c)
(a) DEPARTMENT OF PEDIATRICS, UNIVERSITY HOSPITAL "UMBERTO I - LANCISI - SALESI", MARCHE POLYTECHNIC UNIVERSITY OF ANCONA; (b) DEPARTMENT OF PEDIATRIC AND CONGENITAL CARDIOLOGY AND CARDIAC SURGERY, UNIVERSITY HOSPITAL "UMBERTO I - LANCISI - SALESI" OF ANCONA; (c) CARDIOLOGY AND ARRHYTHMOLOGY CLINIC, UNIVERSITY HOSPITAL "UMBERTO I - LANCISI - SALESI", MARCHE POLYTECHNIC UNIVERSITY OF ANCONA

Background. Recurrent pericarditis (RP) is a pericarditis occurring after a symptom-free interval of 4–6 weeks from a documented first episode of acute pericarditis. The current 2015 ESC guidelines recommend anakinra in cases of proven infection-negative, corticosteroid-dependent RP not responsive to colchicine, but it remains debated the duration of the therapy and when to start its tapering.

Purpose. To determine the utility of serial cardiac magnetic resonance (CMR) imaging for guidance of therapy management in patients treated with anakinra due to RP, compared with c-reactive protein (CRP) assay alone.

Methods. In 2018-21, we enrolled 18 (14.5±1.8-year-old, 72% males) consecutive RP patients treated with anakinra due to RP corticosteroid-dependent, or not responsive to colchicine or non-steroidal anti-inflammatory drugs (NSAIDs). Clinical assessments, laboratory tests, electrocardiogram, echocardiography, and a baseline CMR were achieved in all patients at the time of the enrollment. Next, they were 1:1 randomized to CMR [no pericardial edema and/or late gadolinium enchantment (LGE)] or CRP (<0.6 mg/dL). Tests were repeated every 3-months until negative to halve the anakinra dosage and cessation. Corticosteroids, colchicine, or NSAIDs were contextually administrated and suspended 1-week after halving anakinra.

Results. The idiopathic etiology was the most prevalent (n=8, 44%), followed by postpericardiotomy (n=6, 33%). All the participants presented with chest pain and the new demonstration of pericardial effusion, while only n=6 (33%) presented with a new demonstration of ST-changes at the ECG. After basal CMR, the majority (n=11, 61%) presented with moderate pericardial effusion, while all the participants resulted with pericardial LGE and edema. After a median treatment period of 8.7±3.6 months, CRP-guided RP patients experienced more recurrences than CMR-guided ones (6 vs. 1, P=0.016), with a significant increased time of anakinra treatment (12.7±2 vs. 16.1±3.4 months, P=0.019). In a multivariable exploratory Cox regression model, moderate-to-severe pericardial effusion at the basal CMR, the idiopathic etiology and a higher peak of CRP after the hospitalization were independent predictors of RP during the anakinra treatment (HR 5.27, 95% CI: 1.47-18.8, P=0.011, HR 5.1, 95% CI: 1.29-26.5, P=0.022; HR 1.48, 95% CI: 1.03-2.13, P=0.031, respectively). The recurrences were subsequently directed to CMR imaging, and therapy modified according to the LGE/edema trend. After 1-year follow-up, no further recurrence was detected.

Conclusions. Among patients with RP and treated with anakinra, serial CMR imaging of the pericardium (edema and LGE visualization) can be utilized as an imaging biomarker, more informative for therapy duration than the solely CRP assessment.

A790: ARE THERE ALTERNATIVES TO LOW VOLTAGE ECG CRITERIA FOR PERICARDIAL EFFUSION?

Marco Biasin (a), Nicolò Cordioli (a), Joey Zaylah (a), Alessandro Varriale (a), Alberto Comuzzi (a), Pilan Matteo (a), Alessia Gamabaro (a), Flavio Luciano Ribichini (a)
(a) UNIVERSITÀ DEGLI STUDI DI VERONA

Introduction. Historical studies have demonstrated that conventional low voltage criteria on ECG have high specificity but limited sensitivity in detecting pericardial effusion (PE). This study aimed to introduce new criteria organized into a score called ARENA, to enhance ECG diagnostic performance in detecting PE. Furthermore, we compared the sensitivity and specificity of traditional low voltage ECG criteria with the ARENA score using the most recent data collected.
Methods. This retrospective case-control study was conducted at an Italian public university hospital from January 2022 to May 2023. Inclusion criteria were: age ≥18 years old, an available 12 lead ECG and an echocardiogram performed within 5 days from the recorded ECG. The population included a test group (≥1.0 cm pericardial effusion) and a validation group (no effusion). Demographic data were obtained from clinical records. ECG parameters were evaluated by two blinded cardiologists. Echocardiographic images were reviewed by an expert echocardiographer. Optimal ECG criteria with the highest ROC curve area were selected from the test cohort to develop the ARENA score. Both cohorts were assessed using traditional low voltage ECG criteria and the novel ARENA score.
Results. The test group comprised 50 patients, and the validation group had 47 patients. The ARENA Score showed sensitivity of 52.0% (95% CI: 39.2% to 64.8%), compared to 14.0% (95% CI: 6.2% to 21.8%) with traditional criteria. Specificity was 94% (95% CI: 84.1% to 100%) for ARENA Score and 100% (95% CI: 96.3% to 100%) for traditional criteria. Accuracy of the ARENA Score was 70.0%, compared to 57% for the traditional criteria. The McNemar test indicated a p-value of <0.001 in the performance comparison. ARENA score's AUC was 0.781.
Conclusions. The novel ARENA Score demonstrated improved sensitivity while maintaining high specificity, indicating its potential as a valuable diagnostic tool for pericardial effusion.

Traditional Low Voltage Criteria	ARENA Score
All QRS complexes in peripheral leads measuring ≤ 5 mm OR All QRS complexes in peripheral leads measuring ≤ 10 mm	• At least 3 QRS complexes in peripheral leads measuring ≤ 5 mm: 1 point • Heart rate (HR) > 90 BPM: 2 points if in sinus rhythm (RS), 0 points if in atrial fibrillation (AF) • Tallest T-wave measuring < 4 mm: 1 point • Sum of QRS amplitude in leads V4 and V5 < 20 mm: 2 points if exhibiting a left bundle branch block (LBBB) pattern, 1 point if not LBBB • Presence of at least 3 QRS complexes measuring < 10 mm in precordial leads: 1 point • Ratio between QRS amplitude in lead V5 and maximum T-wave amplitude < 2: -1 point If the cumulative score is greater than or equal to 3, it indicates a positive diagnosis for pericardial effusion.

A791: STRESS MYOCARDIAL BLOOD FLOW INDEX DETECTS SUBCLINICAL REJECTION BEYOND ALLOGRAFT VASCULOPATHY AMONG HEART TRANSPLANT RECIPIENTS

Giandomenico Bisaccia (a, b), Isabella Leo (b), Roberto Licordari (b), Maria Cristina Procopio (b), Giulia La Vecchia (b), Maria Perotto (b), Nikolaos Miaris (b), Fabrizio Ricci (a), Sabina Gallina (a), Joyce Wong (b), Chiara Bucciarelli-ducci (b, c)
(a) UNIVERSITÀ «G. D'ANNUNZIO» DI CHIETI-PESCARA, CHIETI, ITALIA; (b) ROYAL BROMPTON AND HAREFIELD HOSPITALS, GUYS' & ST THOMAS NHS TRUST, LONDON, UNITED KINGDOM; (c) SCHOOL OF BIOMEDICAL ENGINEERING AND IMAGING SCIENCES, FACULTY OF LIFE SCIENCES AND MEDICINE, KING'S COLLEGE UNIVERSITY, LONDON, UNITED KINGDOM

Background. Stress perfusion cardiac magnetic resonance (CMR) imaging is recommended in the international guidelines in class I in patients with known or suspected coronary artery disease. Patients status post orthotopic cardiac transplantation (OHT) are at risk of cardiac allograft vasculopathy (CAV) and graft rejection (GR). We sought to evaluate the potential clinical of quantitative adenosine stress perfusion CMR in patients with OHT and suspected CAV in the outpatient setting, and to evaluate potential CMR biomarkers of significant coronary and graft disease in this population.
Methods. In a retrospective cohort study, we enrolled consecutive OHT recipients undergoing adenosine quantitative stress perfusion CMR for suspected CAV between 2015 and 2023. We stratified patients based on presence of significant cardiac allograft vasculopathy (CAV grades 2-3 versus CAV 0-1) on either invasive or computed tomography coronary angiography, and coupled these findings to results of donor-specific antibody (DSA). Global quantitative perfusion parameters were acquired and indexed to the rate pressure product to account for potential heterogeneity in the response to vasodilator stress.
Results. We identified 59 OHT patients (age 48.7±17.4 years; 32.2% females) undergoing adenosine stress perfusion CMR at a median of 18.6 years after transplantation (IQR 4.0-24.1). Of these, one patient was excluded due to missing DSA results, for a total of 58 patients included in the final analysis. CMR was conducted at a median(IQR) of 36(11-99) days from DSA testing, and at 28(13-53) months from index coronary angiography. Among all included patients (n=58), 31.0% had significant (i.e. grade 2-3) CAV and 37.9% were DSA-positive. Among quantitative perfusion CMR biomarkers, stress myocardial blood flow index (MBFi) was reduced both in patients with significant CAV burden (1.8±0.5 vs 2.4±0.8, p=0.04) and in patients with positivity to DSA (1.9±0.5 vs 2.4±0.8, p=0.03), compared with patients with negative results at respective tests. At logistic regression, a reduced stress MBFi (p=0.005) and MPRi (p=0.027) allowed to identify patients with angiographic CAV, positivity to DSA, or both (OR 0.19, 95%CI 0.05-0.53 for MBFi and 0.41, 95%CI 0.17-0.84 for MPRi, respectively).
Conclusions. Among OHT patients undergoing stress CMR for suspected CAV, stress MBF index was reduced among patients with concomitant positivity to donor-specific antibodies. Hampered stress perfusion in patients with non-significant CAV and positivity to DSA might denote underlying microvascular dysfunction in relation to subclinical rejection.

A792: NON-INVASIVE AND INVASIVE CARDIAC OUTPUT MEASUREMENTS IN REAL-WORLD PATIENTS WITH HEART DISEASES: A MONOCENTRIC EXPERIENCE

Niccolo Bonini (a, b), Maddalena Piras (a), Matteo Menozzi (a), Simona Chiusolo (a), Laura Torlai Triglia (a), Rachele Bertolini (a), Irma Bertolini (a), Francesca Rampini (a), Marta Mantovani (a), Emiliano Guerra (a), Luigi Gerra (a), Marco Vitolo (a, b), Jacopo Francesco Imberti (a, b), Davide Antonio Mei (a), Giuseppe Boriani (a)
(a) CARDIOLOGY DIVISION, POLICLINICO DI MODENA, UNIVERSITY OF MODENA AND REGGIO EMILIA; (b) CLINICAL AND EXPERIMENTAL MEDICINE PHD PROGRAM, UNIVERSITY OF MODENA AND REGGIO EMILIA

Background and Aim. Right catheterization (RC) remains the gold standard for cardiac output (CO) measurement. However, many non-invasive techniques have been proposed in different settings, and they are used in clinical practice for patients with heart diseases. Among these methods, bioimpedance is gaining a pivot role. Real-world comparative data still need to be improved regarding reliability for future clinical decisions based on this CO measurement methods.
Methods. Within our clinical practice, we collected data in patients who underwent RC for different clinical reasons and subsequentially to a measurement of the stroke volume (SV) with non-invasive CO measure strategies (thoracic impedance, TI, and total-body bio-impedance, TbI, method). We performed a descriptive and correlation analyses (Pearson) with the RC parameters.
Results. A total of 31 pts were included, with a median age of 69 years [IQR 61-77], 22.6% female, with a median BMI of 28.7 [25.6-29.3]. The median heart rate was 73 bpm [63-83], median systolic blood pressure was 125 mmHg [112-142] mmHg, and the SpO2 median was 96% [95-97]. Sixteen (51.6%) patients had severe mitral or tricuspidalic regurgitations. Eleven (35.5%) patients had HF history, and 14 (45.2%) patients had atrial fibrillation (AF). The median Hb level was 13.3 g/dL [11.9-14.7], median CKDEPI 94.2 ml/min/m2 [58.0-108.7] and median BNP of 404 pg/L [230-1104]. The median SV were 58.0 mL [45.0-73.0], 76.6 [62.2-101.8] and 64.0 [56.3-83.4] from the RC, TI and TbI methods, respectively. The TI and TbI SV measurements showed a Pearson correlation with RC of 0.72 (p<0.001) and 0.56 (p=0.045), respectively [Figure 1].
Conclusions. In an unselected cohort of patients who underwent RC, the SV measurements by TI and TbI methods showed a moderate to strong correlation with RC data.

Stroke Volume (SV), mL	Total Cohort
SV (RC), median [IQR]	58.0 [45.0-73.0]
SV (TI), median [IQR]	76.6 [62.2-101.8]
SV (TbI), median [IQR]	64.0 [56.3-83.4]

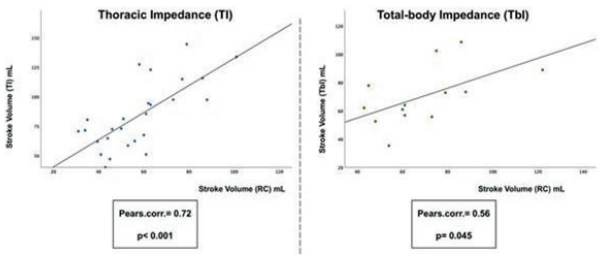

A793: LEFT VENTRICULAR HYPERTRABECULATION AND ANTICOAGULATION THERAPY: WHEN TO START?

Mattia Casati (a), Lorenzo Fini (a), Cristiana Montaldo (b), Carlo Balloi (b), Christian Cadeddu Dessalvi (a)
(a) UNIVERISTÀ DEGLI STUDI DI CAGLIARI; POLICLINCO DULIO CASULA DI MONSERRATO; (b) OSPEDALE SANTISSIMA TRINITÀ DI CAGLIARI

A case of Left Ventricular Hypertrabeculation (LVHT) with severe dilatation of the left ventricle and severe reduction of global systolic ejection function (EF) complicated by cardioembolic stroke. We report a case of a 66-year-old woman suffering from breast cancer in 2019, hypertension, hypercolesterolemia, and dilated cardiopathy (EF 30%) with left bundle branch block diagnosed in 2010. The patient was admitted as

an inpatient, after worsening of systolic function found on outpatient examination, to execute elective invasive coronary angiography (CAG) and cardiac magnetic resonance imaging (MRI). On admission, she was asymptomatic and physical examination showed no clinical signs of heart failure, class NYHA II. Transthoracic echocardiogram showed severe dilatation of the left ventricle with spherical shapes, trabeculae, and deeps intratrabecular recess on the lateral and anterior walls, dyskinetic movements of the septum, diffuse hypokinesia, and EF 15%. CAG showed normal coronary anatomy without coronary artery disease. In the MRI performed, the noncompact/compact myocardium ratio was 2.8, exceeding the threshold of 2.3 according to Petersen's criteria. No atrial thrombus was detected. On the fourth day of hospitalization, the patient had facial hemiparalysis and language difficulties. She underwent an urgent CT, which showed a left gliotic parietal lesion with no neurologic indication for invasive procedures. The day after, an angio-RM with diffusion weighted imaging was performed, showing a signal change in the right temporal insular region, which was due to an acute ischemic insult. In addition, the presence of a scar in the left parietal region was confirmed. After neurological evaluation the diagnosis was minor stroke. During ECG monitoring, the patient had maintained sinus rhythm without AHRE or atrial fibrillation. With suspect of cardioembolic stroke, a transesophageal echocardiogram was performed two days after the event, which revealed a thrombus in the left atrial appendage and anticoagulation therapy with LWH was started. Nine days after the stroke, the patient underwent implantation of CRT-D for resynchronization therapy. Due to difficulties in cannulating the left coronary sinus, the procedure had to be aborted and AICD implantation was performed with the possibility of upgrading to CRT-D. In conclusion, LVHT is a rare and unclassified cardiomyopathy that has been associated with significant risk of developing arrhythmias, thromboembolic complications, severe systolic dysfunction and sudden cardiac death. Management of such cardiomyopathy has been debated in terms of anticoagulation. Not enough data exists in regard to establishing firm guidelines. Based on retrospective analysis, anticoagulation has been recommended in patients of LVHT with severe systolic dysfunction EF <50%, concomitant atrial fibrillation, previous history of embolic events, or presence of ventricular thrombi[1,2]. Recently, Cristina Chimenti et. al have proposed the use of anticoagulant therapy in patients with CHADS2 score ≥2 and normal left ventricular EF (≥50%)[2].

References

Rohan Mandaliya et al.; Left ventricular non-compaction syndrome misdiagnosed as dilated cardiomyopathy on several occasions, presenting with recurrent stroke; Cardiol Res. 2014 Feb; 5(1): 42–47.
Cristina Chimenti et al.; A proposed strategy for anticoagulation therapy in noncompaction cardiomyopathy; ESC Heart Fail. 2022 Feb; 9(1): 241–250.

A794: TOO HOT TO DIAGNOSE: MYOCARDITIS AS THE "HOT PHASE" OF ARRHYTHMOGENIC CARDIOMYOPATHY

Mariachiara Ciarlantini (a, b, c), Ferdinando Pasquale (a, b, c)
(a) CARDIOLOGY UNIT, CARDIAC THORACIC AND VASCULAR DEPARTMENT, IRCCS AZIENDA OSPEDALIERA-UNIVERSITARIA DI BOLOGNA; (b) DEPARTMENT OF MEDICAL AND SURGICAL SCIENCES-DIMEC, IRCCS AZIENDA OSPEDALIERA-UNIVERSITARIA DI BOLOGNA; (c) ALMA MATER STUDIORUM, UNIVERSITY OF BOLOGNA

History of presentation. A 23-years old Caucasian girl was admitted to the cardiologist department for chest pain and palpitations for a few hours. Upon the admission, she didn't present signs of hemodynamic instability (BP of 105/70 mmHg and HR of 70 bpm). Polymorphic ventricular complex were recorded at EKG monitoring.

Past medical history. Two uncles on paternal side died suddenly at a young age and she experienced two episodes of syncope preceded by tachycardia in the past.

Investigation. Routine blood tests demonstrated elevation of cardiac troponin and inflammatory markers, whereas the initial EKG showed low voltage of QRS with infero-lateral negative T wave. On day one of admission, transthoracic echocardiography documented a not dilated left ventricle with EF 54%, hypo-akinesia of basal posterior septum and hypokinesia of medium posterolateral wall, right ventricle with apex akinesia and bulging of RV inflow. The coronary angiography excluded CAD. Given the suspicion of underlying cardiomyopathy, the patient underwent a CMR, that showed a severe intramyocardial edema of lateral wall on T2w sequences with high T1 on mapping, and a subepicardial patchy LGE pattern with enhancement of pericardial leaflets. The cardiovascular imaging oriented toward a myopericarditis, although cardiomyopathy could not be excluded. Therefore endomyocardial biopsy was performed, with no evidence of myocarditis. Antibody panel for infectious and autoimmune origin was negative as well as the research of toxic etiologies. During the hospitalization genetic test was done.

Management. The patient was monitored for the entire hospitalization with evidence of occasional PVC and an episode of non-sustained ventricular tachycardia (maximum HR 150 bpm, 19 beats). Beta-blocker therapy was started. Transthoracic echocardiography repeated before dismiss from the hospital showed a persistence of hypokinesia of posterior septum, minimum infero-lateral wall hypokinesia and apex hypokinesia of right ventricle. CMR and EKG Holter was scheduled in six months time as an outpatient.

Follow up. The CMR demonstrated a reduction in edema and a persistence of multifocal sub epicardial LGE pattern. The EKG Holter recorded isolated PVC. Genetic test detected VUS in heterozygosis DSG-2 gene. Familiar screening was conducted and the father, carrier of the same VUS, fulfilled criteria for arrhythmogenic cardiomyopathy (ACM) diagnosis. On the basis of this and the investigations performed, diagnosis of ACM detected in "hot phase" was made in the patient. The risk stratification resulted in significant risk of SCD (family history of SCD, NSVT during hospitalization, syncope preceded by palpitations), indeed S-ICD was implanted.

Discussion. The diagnosis of ACM is challenging, especially when presentation mimics myocarditis. Multiparametric approach, including familiar screening, is fundamental to reach it.

A795: PARAMETRI ECOCARDIOGRAFICI DI RIMODELLAMENTO E FUNZIONE ATRIALE NEI PAZIENTI CON AMILOIDOSI TTR-RELATA E PORTATORI SANI DI MUTAZIONE DEL GENE TTR: FOCUS SU PA-TDI E FIBRILLAZIONE ATRIALE DI NUOVA INSORGENZA.

Beatrice Dal Passo (a), Matteo Arzenton (a), Anna Cantone (a), Federico Sanguettoli (a), Gioele Fabbri (a), Daniele Maio (a), Martina Vitali (a), Gabriele Guidi Colombi (a), Anna Vittoria Peracin (a), Gianluca Calogero Campo (a), Matteo Serenelli (a)
(a) UNIVERSITÀ DEGLI STUDI DI FERRARA

L'amiloidosi cardiaca da transtiretina (ATTR-CM) è causata dal deposito di fibrille amiloidi nel miocardio secondariamente al *misfoldig* della proteina TTR, ora nella forma wild-type ora in quella mutata. La fibrillazione atriale (FA) è l'aritmia più comune nella ATTR-CM, con una prevalenza di circa il 70%. Tra i parametri ecocardiografici che hanno dimostrato di predire l'occorrenza di FA, vi è il tempo totale di conduzione atriale di derivazione ecocardiografica (PA-TDI), parametro che è stato studiato in diversi setting, ma il cui significato clinico ed i valori di riferimento non sono noti nel contesto della ATTR-CM. Abbiamo realizzato uno studio il cui obiettivo è stato calcolare il valore mediano di PA-TDI in una coorte di pazienti con ATTR-CM e di *carriers* della mutazione del gene della TTR e di definirne il ruolo predittivo in termini di sviluppo di FA. Sono stati arruolati retrospettivamente 61 pazienti, di cui 40 (66%) affetti da ATTR-CM e 21 (34%) *carriers*. La figura mostra i valori dei principali parametri ecocardiografici indicativi di rimodellamento atriale e correlati allo sviluppo di FA nei soggetti con ATTR-CM e nei carriers. Per tutti i parametri analizzati vi è una differenza significativa tra i due gruppi. Il PA-TDI è risultato significativamente più prolungato nel gruppo con ATTR-CM rispetto ai *carriers* (149 ms vs 124 ms; p-value:<0,001). I soggetti con ATTR-CM che hanno sviluppato FA nel follow-up (19%) non presentano un valore di PA-TDI mediano più prolungato rispetto ai *carriers* (157 ms (132-175) vs 150 ms (128-172), p=0.86); vi è invece una differenza statisticamente significativa in termini di strain atriale longitudinale *conduit* (LAScd), che è risultato ridotto (2.8% (2.6-3) vs 7.5% (5.7-9.8), p=0.024). Tra i *carriers*, il 10% dei soggetti ha sviluppato FA. Anche in questo sottogruppo, non sono emerse differenze significative in termini di PA-TDI rispetto ai soggetti che non hanno sviluppato FA (124 ms (110-146) vs 114 ms (112-117), p=0.34). È emersa invece una differenza statisticamente significativa in termini di strain longitudinale atriale *reservoir* (LASr) che è risultato ridotto nei soggetti che sviluppano FA (23% (20-27) vs 39% (32-52), p=0.035); anche il volume indicizzato dell'atrio destro è risultato significativamente più elevato nei soggetti che hanno sviluppato l'aritmia (30 ml/m2 (28-32) vs 20 ml/m2 (17-27), p=0.05). In conclusione, sebbene il PA-TDI sia significativamente più prolungato nei soggetti con ATTR-CM rispetto ai carriers, verosimilmente a causa del deposito di fibrille che provoca una alterazione elettro-meccanica dell'atrio, dalla nostra analisi non è risultato essere un buon predittore di FA. Considerando i *carriers*, l'occorrenza di FA pari al 10% in soggetti con segni ecocardiografici di rimodellamento atriale, in particolare la riduzione del LASr, fa ipotizzare un possibile iniziale coinvolgimento delle camere atriali in assenza di un fenotipo patologico. Un follow-up più prolungato e un campione più ampio saranno necessari sia per approfondire il ruolo del PA-TDI nella ATTR-CM sia il potenziale ruolo del rimodellamento atriale come segno precoce di cardiopatia amiloidotica nei portatori sani di mutazione del gene della TTR.

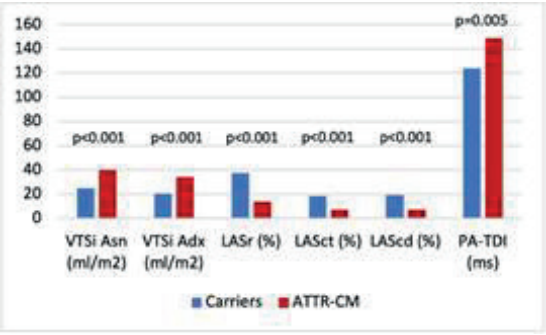

A796: UN CASO DI MIOCARDITE DA PARVOVIRUS B19 E SARS-COV-2 CON CONFERMA TRAMITE BIOPSIA ENDOMIOCARDICA

Valeria Dall´ospedale (a), Antonio Crocamo (a), Gianluca Gonzi (a), Luca Bearzot (a), Angela Guidorossi (a), Francesca Grassi (a), Giorgia Paoli (a), Domenico Corradi (b), Diego Ardissino (a), Giampaolo Niccoli (a), Maria Francesca Notarangelo (a)
(a) CARDIOLOGIA, AZIENDA OSPEDALIERO-UNIVERSITARIA DI PARMA, 43126, PARMA, ITALIA; (b) ANATOMIA PATOLOGICA, AZIENDA OSPEDALIERO-UNIVERSITARIA DI PARMA, 43126, PARMA, ITALIA

Introduzione. Nelle miocarditi l'associazione di più agenti virali non è comune ed è poco documentata. Presentiamo il caso di un paziente con miocardite acuta sospetta di essere causata da un'infezione concomitante da Parvovirus B19 e Sars-CoV-2 e in cui le biopsie endomiocardiche hanno confermato la presenza di Parvovirus B19 nel materiale bioptico.
Caso clinico. Un ragazzo di 21 anni senza precedenti di rilievo accedeva in Pronto Soccorso per cardiopalmo e dolore toracico. ECG ed esame obiettivo erano nei limiti. Gli esami di laboratorio hanno mostrato elevati livelli di troponina e un aumento dei marcatori di infiammazione (TnI hs 2149 ng/L, PCR 16.5 mg/L). All'ecocardiografia è stata notata una funzione contrattile del ventricolo sinistro moderatamente depressa (FE 45%) con ipocinesia diffusa. La RM ha mostrato edema con associato LGE subepicardico della parete infero-laterale medio-basale e versamento pericardico (Figura 1). È stato effettuato un tampone rinofaringeo per Sars-CoV-2, risultato positivo, e sono state rilevate immunoglobuline IgG e IgM e genoma di Parvovirus B19 nel siero. La ricerca di genoma virale su biopsia miocardica ha confermato la presenza di Parvovirus B19, l'analisi istologica ha rilevato miocardio morfologicamente normale con 2-3 linfociti CD3+ e CD4+ per mm^2 (Figura 2).
Discussione. Il Parvovirus B19 è un agente eziologico sia di miocarditi mediate da virus che di miocarditi triggerate da virus, ma si può trovare anche in biopsie di pazienti senza miocardite acuta in atto, di solito affetti da cardiomiopatia dilatativa. Nelle biopsie di quest'ultimi e nel caso descritto, nonostante la presenza di genoma di Parvovirus B19, il quantitativo di linfociti non è tale da soddisfare i criteri di Dallas per miocardite acuta. Report recenti hanno messo in luce come la misura quantitativa della carica virale su biopsia potrebbe essere un parametro utile a distinguere miocarditi acute ed infezioni virali latenti. Nel nostro caso non è stato possibile applicare questa metodica, né dosare il Sars-CoV-2 nel materiale bioptico, per impossibilità tecnica del nostro laboratorio. Questo ha reso difficile determinare il ruolo esatto della co-infezione nel quadro clinico del paziente.
Conclusioni. Durante il ricovero si è assistito alla negativizzazione della troponina e degli indici di flogosi, con risoluzione della sintomatologia, recupero dell'attività contrattile e si è documentata completa risoluzione sia dell'edema che del LGE subepicardico alla RM eseguita cinque mesi dopo la dimissione.

Figura 1. Risonanza magnetica cardiaca; la freccia indica l'edema miocardico nella parete infero-laterale del ventricolo sinistro.

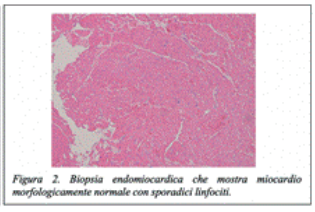

Figura 2. Biopsia endomiocardica che mostra miocardio morfologicamente normale con sporadici linfociti.

A797: 28 YO COMPETITIVE FOOTBALL PLAYER'S SUDDEN CARDIAC DEATH REVEALS FAMILIAR ARRHYTHMOGENIC CARDIOMYOPATHY

Lorenzo-Iupo Dei (a), Federica Re (b), Raffaella Mistrulli (e), Irene Bottillo (c), Monica Luzietti (d), Domenico Gabrielli (b), Luigi Sciarra (a), Silvio Romano (a)
(a) UNIVERSITY OF L'AQUILA, DEPARMENT OF LIFE, HEALTH, AND ENVIROMENTAL SCIENCES, L'AQUILA, ITALY; (b) SAN CAMILLO FORLANINI HOSPITAL, CARDIOLOGY DEPARTMENT, ROME, ITALY; (c) SAN CAMILLO FORLANINI HOSPITAL, MEDICAL GENETICS, MOLECULAR MEDICINE DEPARTMENT, UNIVERSITY LA SAPIENZA, ROME, ITALY; (d) SAN CAMILLO FORLANINI HOSPITAL, CARDIOVASCULAR RADIOLOGY DEPARTMENT, ROME, ITALY; (e) UNIVERSITY LA SAPIENZA, UNIVERSITARY HOSPITAL SANT'ANDREA, CARDIOLOGY DEPARMENT, ROME, ITALY

A 28 yo male competitive football player, suddenly dies during a go kart race. The autopsy states: fibro-fatty replacement of the RV free wall, interventricular septum and left ventricular anterior wall. No genetic testing was performed. We evaluated the family (mother, father, and brother) at the Cardiomyopathy Unit in San Camillo-Forlanini Hospital in Rome. Father: no symptoms, normal ECG, and echocardiography. Mother: no symptoms, fragmented QRS and inverted T waves in inferior leads, low voltage tendency. CMR: normal ventricular dimensions, absence of LGE, two small areas of RV free wall bulging. Brother (25 yo, competitive football player): no symptoms, low atrial rhythm (43 bpm), isolated inverted T waves in III lead, rigid ST segment in aVF lead, early repolarization pattern. CMR: septal midwall LGE and basal infero-lateral midwall and subepicardial LGE. Mild dilatation of both ventricles. We performed a cardiopulmonary exercise test that showed mildly impaired functional capacity (pVO2 71% of the predicted value). The autoptic evidence of the proband was recovered from the Hospital where it had been performed and transported to San Camillo Forlanini Genetic Department. We proceeded to remove the formalin in which it had been fixated and performed the genetic testing. It showed a hot variant for the DES gene (coding for desmin), prone to be reclassified as likely pathogenic (c.[407T>A];[=]), only once described for arrhythmogenic cardiomyopathy and once for dilated cardiomyopathy; two VUS respectively on SCN5a e KCN5a genes. Genetic testing was performed in family members: the father had no mutations, the mother had all three of them, the brother had none (confirmed by a second testing). Common anamnestic element: the proband, mother and brother, had resolved an EBV infection two months before the proband' SCD.
Discussion. Is the myocardial scar of the living brother a disease manifestation, albeit the negative genetic testing results? Could it be the result of an EBV myocarditis? It is interesting that the mother has very little disease evidence, with no LGE albeit having triple mutation and having been through the EBV infection.
Conclusions. EBV is a very rare cause of myocarditis and the autopsy excluded sub-acute flogosis in the proband. Considering the LGE in the living brother's heart as a disease sign, we suggested to quit high intensity physical activity. Based on the CPET results, we educated him on his low and moderate physical activity thresholds. We keep both him and the mother under semestral follow up, with clinical evaluation, ECG, echocardiography, and Holter ECG monitoring.

A798: PERIPARTUM REVERSE TAKOTSUBO CARDIOMYOPATHY IN A 31 YEAR OLD WOMAN

Riccardo Di Febo (a), Francesca Rusconi (a), Marco Guazzi (a)
(a) DIVISION OF CARDIOLOGY, DEPARTMENT OF HEALTH SCIENCES, SAN PAOLO HOSPITAL, UNIVERSITY OF MILAN, MILAN, ITALY

A 31 year old pregnant woman with no medical history and a regular pregnancy (G2P0) presented to the Emergency Room (ER) for premature rupture of membrane at 39+6 weeks. She underwent induction of labor and, the day after, an urgent caesarean section because of placental abruption with active bleeding. In the first post-operative night the patient suffered desaturation with SatO2 82%, tachydyspnea, cough, tachycardia. Arterial gas analysis showed severe hypoxemic acute respiratory failure (PO2/FiO2 ratio 155) with elevated lactates (2.58 mmol/l). Blood test revealed leukocytosis, mild anemia, troponin I (TnI) 1.41 ng/ml, D-dimer 1638 ng/ml, NT-proBNP 9500 pg/ml. ECG showed sinus tachycardia 125 bpm, no signs of ischemia, ventricular repolarization abnormality from volume overload. Chest CT angiography excluded pulmonary embolism, but revealed massive pulmonary oedema and bilateral pleural effusion. A transthoracic echocardiography (TTE) showed severely enlarged left ventricle (EDVi 132 ml/m^2), with diffuse mid-basal hypo/akinesia with apical hypercontractility, ejection fraction (EF) 30%, moderate secondary mitral regurgitation, PAPs 45 mmHg, normal right ventricle size and function. The patient was transferred to Intensive Care Unit to be supported with NIMV FiO2 50% - PEEP 8 cmH2O - PS 12 cmH2O, IV loop diuretics and antithrombotic prophylaxis. A right jugular CVC was placed, CVP measured at 9 mmHg. Rapid amelioration of P/F ratio (up to 293) and rapid weening from NIMV the day after, normal hemogasanalysis parameters in low flow nasal cannula. The patient was relocated in Coronary Care Unit (CCU), a cardioprotective therapy with betablocker, ACE-inhibitor and mineralocorticoid receptor antagonist was started, lactation was inhibited with oral cabergoline. During the ospitalization, we observed gradual clinical improvement reduction of cardiac biomarkers (NT-proBNP 512 pg/ml, TnI <0.012 ng/ml) and diuretic therapy was progressively reduced. Seven days after the first exam, TTE showed partial improvement of left ventricular kinesis (EF 48%) and volumes (EDVi 65 ml/m^2), mild mitral regurgitation and PAPs 22 mmHg. Serial ECGs revealed regular sinus rhythm with slow recovery of ventricular repolarization abnormalities. No major arrhythmias were detected at prolonged telemetry monitoring. Gynecologic follow-up was normal. The patient was discharged with a close outpatient clinical and echocardiographic follow-up, with a strategy of gradual suspension of cardioprotective drugs if complete recovery of cardiac function. We report a case of reverse Takotsubo cardiomyopathy after caesarean delivery with an almost complete recovery. It is imperative to differentiate it from peripartum cardiomyopathy (PPCM), which has a similar clinical presentation, since the latter has different treatment, prognosis and outpatient follow-up. The interesting aspects are the rare form of presentation, the association with peripartum complications, the differential diagnosis with PPCM and the optimal response to ventilatory support and medical therapy.

A799: A RARE CASE OF MESALAZINE-INDUCED MYOCARDITIS

Marco Maria Dicorato (a), Pierpaolo Caretto (a), Caterina Colucci (a)
(a) CARDIOVASCULAR DISEASE SECTION, INTERDISCIPLINARY DEPARTMENT OF MEDICINE (DIM), UNIVERSITY OF BARI ALDO MORO, UNIVERSITY HOSPITAL CONSORTIUM, POLYCLINIC OF BARI, BARI, ITALY

Case report. We report the case of a 25-year-old man in apparent good health status, mild smoker, who accessed our Emergency Department for burning chest pain. His past medical history only included episodes

of fever associated to bloody diarrhea and abdominal pain in the last month. Because of these symptoms he underwent colonoscopy, which evidenced an ileal ulcer but was not conclusive for Intestinal Bowel Diseases (IBD). However, therapy with 5-amynosalicilic acid (5-ASA) 400 mg bis in die was started, with quite alleviation of gastro-intestinal symptoms. After about 2 weeks the patient started to suffer from burning chest pain associated with fever. For this reason, he came to our attention and an increase of high-sensitivity cardiac troponin I (hs-TnI) was found at blood tests. The transthoracic echocardiogram evidenced ipocontractility of the inferior and posterior medium left ventricular segments (LVEF 55%) and cardiac magnetic resonance (CMR) confirmed the suspicion of myocarditis. Antinflammatory and analgesic therapy was started, with improvement of patient's condition and decrease in hs-TnI dosage. The patient was discharged with diagnosis of acute myocarditis, but mesalamine was not interrupted. After 3 weeks he came again to our attention for mild chest pain with high hs-TnI levels found at follow-up blood tests. The echocardiogram showed ipocontractility of medium segment of infero-lateral wall with minimal pericardial effusion. In the suspicion of myocarditis recurrence, we performed blood tests in order to find its etiology, but auto-immunity and microbiological laboratory tests, including blood cultures, were negative. After that we decided to get an endomyocardial biopsy, which was conclusive for subacute myocarditis. Microbiological tests performed on bioptic tissues did not evidence any viral genetic material. The patient was evaluated by a multidisciplinary team, that excluded any possible causes of myocarditis, except for drug-induced form. Because of that we decided to stop treatment with 5-ASA. The patient was discharged with diagnosis of peri-myocarditis recurrence and with lifelong ban of mesalamine assumption. We have been following-up the patient for 6 months: echocardiograms showed complete recovery of contractile function, the patient has not referred any cardiological symptoms and no hs-TnI increase have been registered.

Discussion. 5-ASA is the first-line drug for IBD treatment. 5-ASA induced myocarditis is extremely rare (a few case reports are present in literature) and its mechanisms are not completely understood. Some studies suggest a role of idiosyncratic hypersensitivity reactions and oxidative stress increase. This case report supports the evidence of a hypersensitivity idiosyncratic non-dose dependent reaction. We were able to diagnose the condition first of all through the exclusion of any other possible cause of myocarditis and then looking at symptoms onset within 1 month of starting mesalazine. The complete recovery after 5-ASA interruption, which represents the only effective treatment, definitely confirmed the diagnosis. Furthermore the patient did not have any defined IBD diagnosis: this evidence, in addition to the temporal relationship with the symptoms onset, allowed us to make differential diagnosis from IBD related myocarditis, which is based on systemic inflammation caused by IBD and usually occurs after years from IBD diagnosis. The peculiarity of this case is also represented by the myocarditis recurrence: since the only effective treatment is stopping 5-ASA, after the first hospitalization myocarditis has recurred in our patient because the drug was continued, further supporting our suspicion.

A800: FRAILTY IS ASSOCIATED WITH QUALITY OF LIFE IN PATIENTS WITH TRANSTHYRETIN CARDIAC AMYLOIDOSIS

Carlo Fumagalli (a, b), Lucia Ponti (a), Martina Smorti (c), Mattia Zampieri (a), Carlo Di Mario (a), Raffaele Marfella (b), Iacopo Olivotto (d), Andrea Ungar (d), Francesco Cappelli (a)
(a) CAREGGI UNIVERSITY HOSPITAL, FLORENCE, ITALY; (b) UNIVERSITY OF CAMPANIA, L. VANVITELLI, NAPLES, ITALY; (c) UNIVERSITY OF PISA, PISA, ITALY; (d) UNIVERSITY OF FLORENCE, FLORENCE, ITALY

Introduction. Whether, and to what extent, frailty and other geriatric domains are linked to health status in patients with transthyretin cardiac amyloidosis (ATTR-CA) is unknown. Aim of this study was to assess the association of frailty, marital and social environment with health status (defined by the Kansas City Cardiomyopathy Questionnaire [KCCQ]) in patients with ATTR-CA.

Methods. All consecutive ATTR-CA patients undergoing routine cardiovascular assessment at a tertiary care clinic from April 2022 to April 2023 were invited to participate in the study. Patients were interviewed for the KCCQ, frailty and social environment. Frailty was assessed using the modified Frailty Index (mFI), mapping 11 variables from the Canadian Study of Health and Aging (frailty>0.36).

Results. Overall, 115 patients (96 [83%] men, median age of 79 [75-84] years) were enrolled in the study. Median KCCQ was 66 [50-75]. Fifteen (13%) patients were considered frail and prevalence of overt disability was 7%. Twenty-one (18%) patients were widowers and 23 (20%) were living alone. At multivariable linear regression analysis, factors associated with worsening KCCQ were frailty (b: -24.248, 95% Confidence Interval [C.I.] -47.844, -0.653, p=0.044), NYHA Class (b: -8.299, 95% C.I. -14.530, -2.068, p=0.004), disease duration since diagnosis (b: -0.188, 95% C.I. -0.355, -0.021, p=0.049), and being a widower (b: -15.370, 95% C.I. -26.886, -3.854, p=0.049). Living alone was associated with improved KCCQ (b: 12.552, 95% C.I. 1.120, 23.984, p=0.032). ATTR-CA type, ejection fraction, disease stage and age at diagnosis were not associated to KCCQ.

Conclusions. In older patients diagnosed with ATTR-CA, functional and social environment but not pure instrumental variables were associated with KCCQ. Future research may provide more in-depth knowledge on the association of frailty in patients with ATTR-CA with respect to quality of life.

A801: THE ROLE OF GENETICS IN THE CARDIOPULMONARY TEST RESPONSES IN PATIENTS AFFECTED BY HYPERTROPHIC CARDIOMYOPATHY

Maria Felicia Gagliardi (a), Gabriella Malfatto (b), Claudia Baratto (c), Valeria Rella (c), Martino Meda (d), Paolo Cerea (d), Davide Mariani (d), Alessia Giglio (b), Sabrina Salerno (d), Silvia Ravaro (a, d), Silvia Castelletti (d), Margherita Torchio (e), Denisa Muraru (a, c), Luigi P Badano (a, c), Gianfranco Parati (a, b), Franco Cecchi (b, f), Sergio Caravita (c, g), Lia Crotti (a, d)
(a) DEPARTMENT OF MEDICINE AND SURGERY, UNIVERSITY OF MILANO-BICOCCA, MILAN, ITALY; (b) DEPARTMENT OF CARDIOVASCULAR, NEURAL AND METABOLIC SCIENCES, SAN LUCA HOSPITAL, IRCCS ISTITUTO AUXOLOGICO ITALIANO, MILAN, ITALY; (c) DEPARTMENT OF CARDIOLOGY, SAN LUCA HOSPITAL, IRCCS ISTITUTO AUXOLOGICO ITALIANO, MILAN, ITALY; (d) CARDIOMYOPATHY UNIT, CENTER FOR CARDIAC ARRHYTHMIAS OF GENETIC ORIGIN AND LABORATORY OF CARDIOVASCULAR GENETICS, SAN LUCA HOSPITAL, IRCCS ISTITUTO AUXOLOGICO ITALIANO, MILAN, ITALY; (e) IRCCS, ISTITUTO AUXOLOGICO ITALIANO, LABORATORY OF CARDIOVASCULAR GENETICS, MILAN, ITALY; (f) CARDIOMIOPATHY UNIT, CAREGGI UNIVERSITY HOSPITAL, FLORENCE, ITALY; (g) DEPARTMENT OF MANAGEMENT, INFORMATION AND PRODUCTION ENGINEERING, UNIVERSITY OF BERGAMO, DALMINE BG, ITALY

Introduction. Hypertrophic cardiomyopathy (HCM) is a genetically transmitted arrhythmogenic heart disease, caused by rare genetic variants mainly in sarcomeric genes. A disease-causing variant is usually identified in 60% of HCM patients (pts), and an unfavorable impact on prognosis of a positive genetic analysis has been observed. Since fatigue and dyspnea are common in the clinical history of HCM, assessment of functional capacity by cardiopulmonary exercise test (CPET) is recommended in all HCM pts.

Objective: To evaluate whether, in asymptomatic or slightly symptomatic HCM pts (NYHA class I-II), CPET response was different between pts with or without a pathogenic/likely pathogenic disease-causing variant.

Methods. Among the HCM pts followed in our Cardiomyopathy Outpatient Clinic, we retrospectively analyzed data from 105 of them in NYHA class I-II whose genetic analysis was available and who performed a CPET. We divided these pts in two groups according to the outcome of the molecular screening: 51 pts had a pathogenic/likely pathogenic variant on HCM genes (gene +) and 50 pts were genotype-negative (gene-). Four pts with genetic variants of uncertain significance were excluded from analysis. The main mutated genes identified were MYBPC3 and MYH7 (43 pts, 84%); other genes such as TNNT2, TPM1 and MYL2 were found in 8 pts (16%). Patients' characteristics are shown in Table 1. Variables were expressed as mean + 1 SD or as percentage. The $\chi 2$ test and T-Test were used for discrete and continuous variables, respectively.

Results. Patients in the two HCM groups (gene + vs gene -) were similar in terms of NYHA class, risk factors and echocardiographic variables (left ventricular ejection fraction, maximum wall thickness and indexed left atrial volume); pts with pathogenetic mutations were younger (Table 1). CPET tests results were superimposable in the two groups, showing an overall exercise performance in the lower range of normality (Table 2). However, pts with a moderate-to-severe reduction in pV02 (less than 60% of predicted for age), were more likely to have a pathogenic/likely pathogenic mutation (67% vs 33%, p<0.05 $\chi 2$ test).

Conclusions. This preliminary study shows that in asymptomatic or slightly symptomatic HCM pts with similar conventional echocardiographic characteristics, the overall exercise tolerance is slightly affected by the disease. A poor exercise performance is more likely to be found in the presence of a pathogenic/likely pathogenic variant in known HCM genes. The pathophysiology of this finding deserves further investigation.

Table 1	Overall population (101 pts)	Gene + pts (51 pts)	Gene - pts (50 pts)	P value
Age (years)	54,43 ± 16,26	50,16 ± 14,93	58,88 ± 16,56	0,01
BMI (kg/m2)	26,28 ± 4,45	25,94 ± 3,45	26,61 ± 5,30	0,49
Diabetes mellitus	6 (6%)	3 (50%)	3 (50%)	0,98
Hypertension	45 (45%)	18 (40%)	27 (60%)	0,59
Smoke	30 (30%)	13 (43%)	17 (57%)	0,35
Dyslipidemia	54 (54%)	25 (46%)	29 (54%)	0,27
Left ventricular ejection fraction, LVEF (%)	63,20 ± 8,64	62,74 ± 8,72	63,66 ± 8,64	0,61
Maximum wall thickness (mm)	18,72 ± 4,42	19,23 ± 4,67	18,20 ± 4,13	0,26
Indexed left atrial volume (ml/m2)	46,39 ± 14,41	48,57 ± 16,03	44,16 ± 12,32	0,15

Table 2	Overall population (101 pts)	Gene + pts (51 pts)	Gene - pts (50 pts)	P value
Peak VO2 (ml/kg/min)	20,34 ± 7,52	20,33 ± 7,87	20,35 ± 7,22	0,99
Peak VO2 (% of predicted)	74,94 ± 21,32	71,13 ± 18,91	78,82 ± 23,07	0,07
AT VO2 (% VO2 max predicted)	50,95 ± 19,95	51,33 ± 22,18	50,58 ± 17,66	0,86
O2-Pulse peak (ml/beat)	13,37 ± 10,49	13,52 ± 14,27	13,21 ± 4,35	0,89
O2-Pulse peak (% of predicted)	95,51 ± 29,97	90,06 ± 27,73	100,95 ± 31,41	0,08
VO2/Work slope	9,54 ± 2,27	9,16 ± 1,91	9,88 ± 2,52	0,15
VE/VCO2 slope	30,96 ± 6,25	31,36 ± 7,08	30,55 ± 5,28	0,53
End Tidal CO2, PetCO2 (mmHg)	32,52 ± 5,45	31,49 ± 6,79	33,46 ± 3,69	0,09

A802: AN ARRHYTHMOGENIC PSEUDOHYPERTROPHY

Kristian Galanti (a), Mario Di Marino (a), Allegra Arata (a), Fabrizio Ricci (a), Giulia Renda (a), Sabina Gallina (a)
(a) UNIVERSITÀ DEGLI STUDI "G. D'ANNUNZIO" CHIETI-PESCARA

An apparently healthy 26-year-old male sportsman experienced cardiac arrest linked to ventricular fibrillation. After forty-five minutes of car-

diopulmonary resuscitation and six epinephrine vials, the patient experienced return of spontaneous circulation. After that, the electrocardiogram (ECG) showed sinus rhythm with infero-lateral T wave inversion (TWI), without ST-elevation. A focus assessed transthoracic echocardiogram showed no significant structural abnormality or heart valve disease, and the invasive coronary angiography proved there were no significant lesions to treat. During the hospitalization at the cardiology intensive care unit, an ICD was implanted in secondary prevention with the indication to perform cardiac magnetic resonance (CMR) after 6 weeks. After almost one month, the patient began a cardiac rehabilitation program, where a comprehensive transthoracic echocardiogram was repeated. It showed regular left ventricular dimension and function (EDVi 41 ml/m2; LVEF 56%) with asymmetrical inverse hypertrophy of the inferior and infero-lateral wall, at the medio-basal segments (maximum diameter: 16 mm). Also, papillary muscles looked enlarged and there was an anomalous parietal base-to-apex tapering (inferior apical thickness: 13 mm), in absence of systolic anterior motion of the mitral valve or intracavitary obstructions. In the suspect of hypertrophic cardiomyopathy, that could explain such history, genetic testing was performed showing an uncertain significance mutation of MYH7. Meanwhile, the patient underwent appropriate ICD shock. Finally, CMR was performed, showing normalized wall thickness and, at the PSIR sequences, left ventricular infero-lateral Late Gadolinium Enhancement (LGE) with non ischaemic pattern, at the medio-basal segments. This abstract shows the case of a pseudo-hypertrophic myocarditis-related ventricular fibrillation, in a young sportsman with infero-later TWI at the basal ECG. It is key to perform cardiovascular screening in young athletes with TWI, especially when they exceed the "benign" V2 derivation, do not resemble a juvenile pattern or do not meet the classical Afro-Caribbean benign signs.

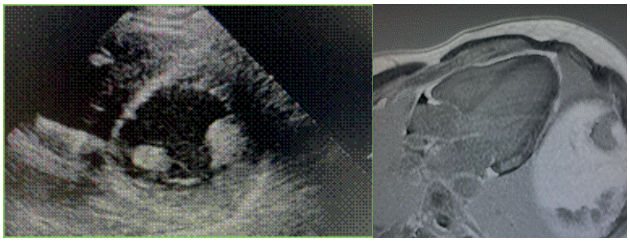

A803: MASSA CARDIACA PRIMITIVA: L'IMPORTANZA DELLA VALUTAZIONE MULTIMODALE

Rosanna Germanò (a), Jacopo Costantino (a), Lucia Ilaria Birtolo (a), Paolo Severino (a), Giovanna Manzi (a), Antonio Lattanzio (a), Federico Ballatore (a), Gianmarco Scoccia (a), Roberto Badagliacca (a), Carmine Dario Vizza (a), Viviana Maestrini (a), Massimo Mancone (a)
(a) UNIVERSITÀ DEGLI STUDI DI ROMA SAPIENZA - POL. UMBERTO I

Introduzione. I tumori cardiaci sono rari e rappresentano lo 0,1,-0,2% di tutti i tumori. Si suddividono in primitivi (5%) e secondari (95%). Tra i primitivi l'80% sono tumori benigni e tra questi il 70% sono mixomi. I tumori maligni cardiaci primari sono nel 95% dei casi sarcomi, il restante 5% sono linfomi. I sintomi con cui si presentano sono aspecifici rendendo difficile la diagnosi che spesso avviene in modo occasionale.
Caso clinico. Un uomo di 82 anni, iperteso e diabetico, si recava in pronto soccorso a seguito di riscontro, durante un'ecografia addominale, di versamento pericardico. Presso il pronto soccorso veniva eseguita un ecoscopia cardiaca che mostrava la presenza di una voluminosa neoformazione iperecogena a livello della giunzione atrioventricolare destra che si estendeva alla parete atriale e ventricolare con associato versamento pericardico di grado severo parzialmente organizzato di massimo 26 mm a livello delle sezioni destre. Il paziente era stato sottoposto 4 mesi prima ad impianto di PMK bicamerale per blocco bifascicolare e sincope. Durante il precedente ricovero aveva eseguito un ecocardiogramma che non documentava la lesione infiltrativa. Si poneva pertanto il sospetto diagnostico di ematoma intramurale iatrogeno e si richiedeva TC. La tomografia escludeva la natura ematica e definiva la presenza di un tessuto espansivo infiltrativo solido, a margini irregolari, che si localizzava prevalentemente nel contesto dello spazio adiposo epicardico lungo tutta l'estensione del solco atrioventricolare destro delle dimensioni massime di 8 cm; non mostrava neoformazioni in altri distretti corporei e mostrava una linfoadenopatia di 2.5 cm paracardiaca. Ricoverato in UTIC, al fine di migliore caratterizzazione del processo eteroplasico, il paziente veniva sottoposto RMN cardiaca che mostrava ampi segni di infiltrazione della parete atriale e ventricolare destra inoltre il reperto appariva tenuemente iperintenso in T2 e ad intensità di segnale intermedia nelle sequenze T1 pesate in assenza di contenuto adiposo, mostrava inoltre restrizione in diffusione e disomogeneo e marcato potenziamento precoce della componente solida con parziale wash-out tardivo e persistenza di aree di potenziamento ad aspetto reticolare, nel contesto della lesione inoltre si evidenziava un'area disomogenamente iperintensa in T2 e ipovascolarizzata priva di potenziamento contrastografico compatibile con area di necrosi. Sulla scorta di questi esami diagnostici multimodali si poneva diagnosi di lesione neoplastica di origine mesenchimale e si poneva indicazione ad eseguire biopsia per definire la natura istopatologica della massa.
Conclusioni. Questo case report dimostra la complessità nella real life di raggiungere una corretta definizione diagnostica dei tumori cardiaci primitivi. L'approccio diagnostico multiparametrico, integrando una vasta gamma di tecniche di imaging con la biopsia miocardica, è cruciale per migliorare la comprensione e la gestione di queste patologie rare e complesse.

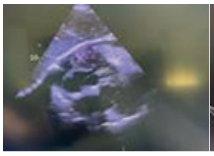

Figura 1. Ecocardiogramma.

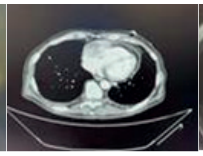

Figura 2. TAC.

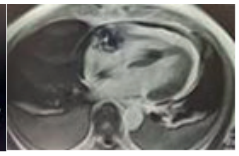

Figura 3. RMN.

A804: PERIMYOCARDITIS AS FIRST MANIFESTATON OF DYSTHYROIDISM: AN UNUSUAL CASE

Elena Gualini (a), Lucia Occhi (a), Cristina Giannattasio (a, d), Patrizia Pedrotti (a), Gianluca Pio Gallone (a), Piero Gentile (b), Paolo Dalino Ciaramella (c), Giulia Maida (e)
(a) CARDIOLOGY 4, CARDIO CENTRE A. DE GASPERIS, ASST GOM NIGUARDA, MILAN; (b) CARDIOLOGY 2, CARDIO CENTRE A. DE GASPERIS, ASST GOM NIGUARDA, MILAN; (c) ENDOCRINOLOGY, ASST GOM NIGUARDA, MILAN; (d) SCHOOL OF MEDICINE AND SURGERY, UNIVERSITY OF MILANO-BICOCCA, MILAN; (e) ENDOCRINOLOGY, IRCCS HUMANITAS HOSPITAL, MILAN

Thyroid and cardiovascular system are inextricably related and cardiovascular complications can occur in both subclinical and overt thyroid dysfunction. We report the case of a 42-year-old woman presenting with chest pain. She had a positive SARS-CoV-2 swab in June and she was hospitalised in suspicion of COVID-related pneumonia and pericarditis in July: treatment with ibuprofen and colchicine was started and patient was discharged. On August 22nd, the patient came back to emergency department due to worsening chest pain and myalgias after therapy decalage. She had face edema and hoarse voice. 12-leads EKG was normal; echocardiography showed 8 mm pericardial effusion and normal ejection fraction. Blood testing revealed no inflammatory signs, a mild increase of Troponin (…) and a high value of CPK (>3000 U/L, n.v. 30-150). Moreover, she had a biohumoral profile of Hashimoto thyroiditis: severe hypothyroidism with increase in TSH levels (538 microU/ml) and positivity to thyroid autoantibodies. The patient underwent a cardiac magnetic resonance imaging that was suggestive for acute perimyocarditis with biventricular diffuse myocardial edema, preserved biventricular function and mild-to-moderate pericardial effusion. Low dose L-T4 therapy was started together with liothyronine that was stopped after few days, once acceptable FT3 concentrations were obtained. At echocardiography control after 8 days, we registered a significant reduction of pericardial effusion (2 mm). Myocarditis is an inflammatory disease of the myocardium and it is predominantly mediated by viral infection. A rare cause of myocarditis is represented by dysthyroidism. In our case, the severe hypothyroidism seems to be the cause of myocardial and pericardial edema. The failure in diagnosis of this endocrinological disorder can determine a delay in specific therapy with possible serious cardiovascular manifestations. So, it would be reasonable to check the thyroid status of all patients presenting with myopericarditis, in the absence of another clearly identifiable aetiology. The role of to the prior SARS-CoV-2 infection in not certain in our case, but the quick recovery after specific endocrinological therapy suggests the low probability of perimyocarditis as SARS-CoV2 related manifestation.

A805: EOSINOPHILIC MYOPERICARDITIS: A CASE SERIES

Lucia Elena Laiso (a), Pier Paolo Bocchino (a), Filippo Angelini (a), Claudia Raineri (a), Stefano Pidello (a), Simone Frea (a), Guglielmo Gallone (a), Gaetano De Ferrari (a, b)
(a) DIVISION OF CARDIOLOGY,, CARDIOVASCULAR AND THORACIC DEPARTMENT, "CITTÀ DELLA SALUTE E DELLA SCIENZA" HOSPITAL, TURIN, ITALY; (b) DEPARTMENT OF MEDICAL SCIENCES, UNIVERSITY OF TURIN, TURIN, ITALY

Background. Eosinophilic myocarditis (EM) is characterized by acute myocardial inflammation due to eosinophilic tissue infiltration. EM is

largely underdiagnosed and it is often associated with a dismal prognosis. The clinical presentation is variable, and treatment depends on its primary cause.
Purpose. To describe 9 cases of eosinophilic myopericarditis.
Methods. 9 consecutive patients with eosinophilic myocarditis were admitted to our Center from February 2021 to August 2023. Diagnosis was based on laboratory tests, echocardiography, and cardiac magnetic resonance (CMR); endomyocardial biopsy (EMB) was performed in uncertain cases. Treatment was performed according to the underlying etiology of EM. All patients underwent regular follow-up at the outpatient heart failure clinic of our Center.
Results. This study includes 9 patients (8 [89%] Caucasian, 7 [78%] women, mean age 48.2±13.6 years). 6 (66.67%) cases occurred in the setting of eosinophilic granulomatosis with polyangiitis (EGPA), 1 (11%) was secondary to B-cell lymphoblastic leukemia, and 2 (22%) were labelled as idiopathic EM. All patients presented with high eosinophil count (6133±4893/mcL), elevated C-reactive protein (57±66 mg/L) and hs-troponin I (3610±5166 ng/L) levels, and in 6 (67%) cases NT-proBNP (10751±4038 ng/L) was elevated; in 5 cases, IgE levels were above the normal range. 6 (67%) patients presented with dyspnea, 5 (56%) with chest pain, and 5 (56%) with fever. On ECG, sinus tachycardia, low QRS voltages and ST segment depression with negative T-waves were common. Thickening of the myocardial walls with reduction of longitudinal strain was seen in all cases; in 4 (44%) cases, the ejection fraction was below 50%; 5 (56%) cases had mild pericardial effusion. 1 patient had intraventricular thrombi at CMR, while another one was complicated by bilateral pulmonary embolism. On CMR, all patients had areas of hypokinesia, myocardial edema, and myo-pericardial late gadolinium enhancement. EMB was performed in 5 cases, confirming the presence of intramyocardial eosinophilic infiltrates. 7 patients required cardiac intensive care monitoring, and 1 needed inotrope (dobutamine) use. The patient with B-cell acute lymphoblastic leukemia was treated with combined chemotherapy. The other EM cases were treated with immunosuppressive therapy consisting of corticosteroids (intravenous methylprednisolone boluses for 3 days followed by oral prednisone) and either cyclophosphamide (5 cases) or rituximab (2 cases) or mepolizumab (1 case with pulmonary involvement). All patients received cardioprotective therapy with beta-blockers and ACE-inhibitors; in patients with pericardial involvement, colchicine was administered. All patients showed rapid clinical improvement following immunosuppressive therapy initiation, with prompt reduction of circulating eosinophils and hs-troponin I values and normalization of the ejection fraction. No ventricular arrhythmias were recorded. On CMR imaging, edema disappeared at follow-up, with LGE replacement in one case. All patients were alive and in good conditions at the last follow-up (mean 11.3±9.1 months).
Conclusions. EM is an underdiagnosed life-threatening disease, which should be suspected in patients with hypereosinophilia who manifest acute signs and symptoms of heart failure or myocardial damage. A careful assessment of the etiology of EM, including virological, parasitic, autoimmune, and hematological screenings, is warranted, as prompt therapy is mandatory to achieve clinical amelioration and good mid-term prognosis.

A806: TROMBOEMBOLISMO SISTEMICO RECIDIVANTE FATALE IN UN PAZIENTE CON AMILOIDOSI CARDIACA AL SENZA EVIDENZA DI FIBRILLAZIONE ATRIALE

Antonio Lattanzio (a), Francesco Ajmone (a), Jacopo Costantino (a), Federico Ballatore (a), Giulia Marchionni (a), Maria Alfarano (a), Carmine Dario Vizza (a), Cristina Chimenti (a)
(a) DAI - DIPARTIMENTO DI SCIENZE CLINICHE INTERNISTICHE, ANESTESIOLOGICHE E CARDIOVASCOLARI

Premessa. L'amiloidosi cardiaca si associa ad un aumentato rischio tromboembolico. Mentre è evidente la necessità di anticoagulare i pazienti in fibrillazione atriale indipendentemente dal CHA2DS2- VASc score, non è chiaro se e quali pazienti in ritmo sinusale debbano essere trattati con farmaci anticoagulanti.
Caso clinico. Un uomo di 51 anni è venuto alla nostra osservazione per ripetuti episodi di dolore toracico e dispnea da sforzo. L'ECG mostrava ritmo sinusale, deviazione assiale sinistra, blocco AV di 1° grado, emiblocco anteriore sinistro. L'ecocardiografia transtoracica ha rivelato pareti del ventricolo sinistro marcatamente ispessite (18 mm) con un aspetto "granular-sparkling" del miocardio, dilatazione bi-atriale, frazione di eiezione del ventricolo sinistro 52%, pattern di flusso mitralico restrittivo con un'onda A molto piccola. I test di laboratorio hanno mostrato un aumento dei livelli di troponina e di NTproBNP e l'immunoelettroforesi sierica ed urinaria ha mostrato una componente monoclonale in zona kappa. Una biopsia del grasso periombelicale è risultata negativa per amiloidosi per cui il paziente è stato sottoposto a una biopsia endomiocardica che ha mostrato positività al rosso Congo, e immunoistochimica positiva per catene leggere kappa e negativa per transtiretina. È stata quindi posta diagnosi di amiloidosi cardiaca AL e il paziente è stato riferito all'ematologo per eseguire terapia specifica. Una settimana dopo la dimissione è stato ricoverato per un dolore acuto agli arti inferiori a causa di un'embolia acuta dell'arteria femorale comune sinistra trattata con embolectomia secondo Fogarty. Durante il ricovero non ha avuto aritmie cardiache. Dimesso in terapia con eparina a basso peso molecolare dopo alcuni giorni è stato nuovamente sintomatico per dolori agli arti inferiori e si è recato in pronto soccorso dove è deceduto per dissociazione elettromeccanica.
Conclusioni. Il nostro caso mostra come l'amiloidosi cardiaca AL sia associata ad un aumentato rischio tromboembolico, indipendentemente dalla presenza di fibrillazione atriale, per la malattia ematologica stessa e per l'infiltrazione dell'atrio da parte della sostanza amiloide. Questo suggerisce che in casi selezionati, con ridotta ampiezza dell'onda A ed evidenza di alterata meccanica atriale, dovrebbe essere considerata l'anticoagulazione empirica anche in ritmo sinusale.

A807: HIGH ARRHYTHMIC RISK IN MID-VENTRICULAR OBSTRUCTIVE HYPERTROPHIC CARDIOMYOPATHY WITH APICAL ANEURYSM: A CASE REPORT

Chiara Lauri (a), Roberta Piccinelli (a), Andrea Imporzani (a), Roberto De Ponti (a), Carlo Campana (a)
(a) UNIVERSITÀ DEGLI STUDI DELL'INSUBRIA

Introduction. Mid-ventricular obstructive hypertrophic cardiomyopathy (MVOHC) with apical aneurysm (AA) is a rare type of cardiomyopathy and it is associated with an elevated risk of sudden cardiac death (SCD) due to ventricular tachyarrhythmias (VTs).
Case description. We report the case of a Caucasian 82-year-old man, who was diagnosed with hypertrophic cardiomyopathy in 2006 and underwent surgical myocardial revascularization by dual coronary artery bypass graft in 2009, followed by angioplasty. The patient was admitted to the local cardiology department in June 2023 due to an episode of chest pain and palpitations. His electrocardiogram (ECG) showed a sustained monomorphic ventricular tachycardia (SMVT) (northwest axis and QS pattern in V1 to V6; cycle 320 msec; Figure 1), therefore electrical cardioversion was performed. After restoration of sinus rhythm, the ECG reported first-degree atrioventricular block (PQ 360 msec), left axial deviation and negative T wave in V2-V6 and D1-aVL. Coronary angiography showed no obstructive stenosis. Transthoracic echocardiogram revealed asymmetric hypertrophy of the left ventricle (maximum wall thickness in interventricular septum, 19 mm), left atrial dilatation (45 mm), a measured ejection fraction of 65%, with AA. A midventricular systolic obliteration with development of significant intraventricular gradient in baseline (Gmax>50 mmHg) was noted. Gadolinium-enhanced MRI confirmed left ventricular hypertrophy with midventricular obstruction and AA (Figure 2). It also revealed right ventricular hypertrophy and no evidence of late gadolinium enhancement. Several arrhythmic recurrences with the same morphology were recorded on continuous ECG monitoring, which were effectively reduced with increased doses of β-blocker and Amiodarone. The risks and the benefits of a transcatheter ablation were discussed with the patient and with the referral center, and the procedure was eventually discarded, also considering that he is a Jehovah's Witness. The patient underwent single chamber implantable cardioverter defibrillator (ICD) implantation for secondary prevention.
Discussion. The present case study shows the strict correlation between anatomy and clinical presentation, since the anatomical substrate of VT is located at the level of the aneurysm rim. Areas of myocardial scarring, contiguous with the scarred rim of the aneurysm at the junction of viable and abnormal tissue where re-entry circuits occur, represent the primary arrhythmogenic substrate for the generation of malignant VTs. For this reason, the presence of AA alone is one of the additional risk factors which should be considered to identify patients requiring ICD implantation. Data on VT management in patients with HCM are scant. According to the 2022 ESC Guidelines for the management of patients with ventricular arrhythmias and the prevention of SCD, antiarrhythmic drugs (AADs) should be considered in HCM patients with symptomatic ventricular arrhythmias, while catheter ablation in specialized centers may be considered for reducing arrhythmic burden in patients who are refractory to AADs.

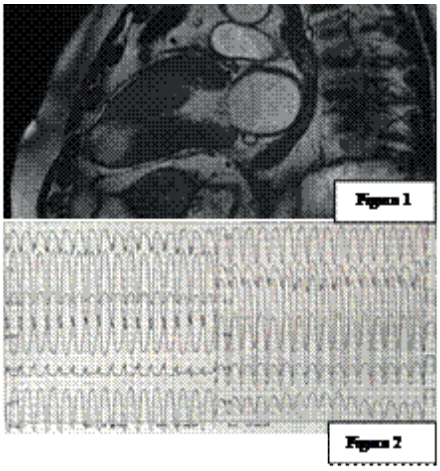

A808: TAKO TSUBO SYNDROME AND ALEXYTHYMIA

Maria Francesca Marchetti (a), Nicola Piredda (a), Marco Licciardi (a), Alessandro Martis (a), Giacomo Boi (a), Luca Fazzini (a), Bianca Maria Noli (a), Martina Mandas (a), Federica Sancassiani (b), Mauro Carta (b), Roberta Montisci (a)
(a) S.C. CARDIOLOGIA-UTIC, POLICLINICO "D.CASULA", MONSERRATO- AOU CAGLIARI; (b) DIPARTIMENTO DI SCIENZE MEDICHE E SANITÀ PUBBLICA, UNIVERSITÀ DEGLI STUDI DI CAGLIARI

Background. Takotsubo Syndrome (TTS), also known as stress cardiomyopathy, is a clinical syndrome characterized by acute reversible myocardial damage due to transient systolic dysfunction of the left ventricle typically following acute emotional or physical stress. Alexithymia is a personality construct characterized by impoverishment of imagination, poor capacity for symbolic thinking and difficulty in experiencing and verbally expressing emotions. The Toronto Alexithymia Scale (TAS 20) is a self-assessment questionnaire consisting of 20 items which aims to measure different areas of the alexithymia construct and is the most used and widespread instrument in the clinical setting. Several studies show that alexithymia is associated with various medical conditions, various mental disorders and psychopathological syndromes. The aim of our study is to evaluate the level of alexithymia in patients suffering from TTS, then study the correlation between stress cardiomyopathy and this personality construct.
Methods. From January 2007 to May 2023, 129 patients with TTS were admitted to our CCU. All the patients enrolled in this study met International Expert Consensus on Takotsubo Syndrome for the diagnosis of TTS. We analyzed the TAS scale in the last 45 patients admitted.
Results. The mean value of the TAS-20 score was 50.82 ± 15.6 with a range of 20-81. 14 patients (31.1%) obtained a score ≥61, indicative of a high degree of alexithymia (AL group), 68.9%, 31 patients, were instead found to have low or intermediate levels of alexithymia (noAL group). We found no differences in terms of age (73.9 ± 10.9 vs 69 ± 11.5, p=0.18) and sex (female 14/14, 100% vs 29/31, 93.5%, p=0.33) and cardiovascular risk factors among AL and non-AL groups. Instead, we found a statistically significant difference in relation to the prevalence of neurological pathologies (28.6% of AL vs 3.2% of non-AL patients, p=0.02), psychiatric pathologies (28.6% vs 3.2%, p=0.02), pneumological pathologies (57.1% vs 16.1%, p=0.01) and neoplastic pathologies (42.9% vs 6.5%, p=0.01). AL patients presented more frequently with dyspnea at onset (64.3% vs 29%, p=0.049) and greater impairment of systolic function (EF 42.36% ± 10.8 in AL vs 49.7 ±10.7 noAL group, p=0.046). We found no difference regarding the presence of stress as a trigger factor and the type of stress (physical or emotional) between the two groups. AL patients had a slightly longer hospital stay 12.57 ± 9.6 vs 10.5 ±4.93, although not in a statistically significant way, but the stay was complicated more frequently by acute pulmonary edema, which occurred in 3/14 AL patients, 21.4% vs 3.2% in noAL patients (p=0.047).
Conclusions. In our preliminary study the prevalence of alexitima seems much higher than what is described in the general population, 9-17% among men and 5-10% among women, compared to 31.1% of our TTS patients. The higher prevalence of comorbidity in patients with AL could justify this finding. AL patients present a clinical characteristics at onset and a more severe hospital course than noAL patients and as described for STEMI, it is possible that the high levels of alexithymia may have a crucial role in the delay in the recognition of symptoms, in the delay in calling for help and perhaps also in the long-term outcome. Our preliminary study suggests the possible usefulness of determining the level of alexithymia in patients with TTS through the administration of TAS-20 to identify patients with more complex TTS and at risk of unfavorable outcome and possible relapses.

A809: PREDITTORI DI SCOMPENSO CARDIACO NELLA CARDIOMIOPATIA ARITMOGENA

Marika Martini (a), Riccardo Bariani (a), Kalliopi Pilichou (a), Martina Perazzolo Marra (a), Sabino Iliceto (a), Domenico Corrado (a), Barbara Bauce (a), Ilaria Rigato (a)
(a) DIPARTIMENTO DI SCIENZE CARDIO-TORACO-VASCOLARI E SANITÀ PUBBLICA, UNIVERSITÀ DI PADOVA

Introduzione. La Cardiomiopatia Aritmogena (CA) è una patologia cardiaca caratterizzata dalla presenza di aritmie ventricolari che possono essere causa di morte improvvisa. Negli ultimi anni, il miglioramento delle capacità diagnostiche (includendo il riconoscimento di forme sinistre) e terapeutiche (tramite trattamenti medici e/o interventistici) ha reso possibile per molti pazienti convivere con la malattia. A causa di questi progressi, un numero sempre maggiore di pazienti affetti da CA arriva a manifestare una significativa disfunzione ventricolare, portando ad un incremento dei casi di scompenso cardiaco (SC). L'obiettivo del nostro studio è quindi quello di valutare le caratteristiche cliniche, elettrocardiografiche, genetiche e di imaging dei pazienti affetti da CA che sviluppano SC, al fine di individuare potenziali fattori predittivi di insorgenza dello scompenso cardiaco.
Metodi. Si tratta di uno studio retrospettivo osservazionale. Dalla coorte di pazienti seguiti presso il nostro centro per la CA, composta da 483 pazienti, sono stati individuati coloro che avevano sviluppato SC durante il follow-up. I dati anamnestici, clinici e strumentali di questi pazienti sono stati confrontati con quelli della restante popolazione di pazienti affetti da CA senza SC.
Risultati. Durante il follow-up medio di 12 anni (max 20, min 1), un totale di 39 pazienti (8% della popolazione, 67% di sesso maschile) ha presentato almeno un episodio di SC (età all'episodio 46 anni + 17). La maggior parte dei pazienti con SC mostrava un fenotipo biventricolare (79.5% verso 27.7%, p<0.001) ed una maggiore incidenza di eventi aritmici, rappresentati sia da fibrillazione atriale (10.3% verso 3.8%, p=0.05) che da aritmie ventricolari maligne (46.2% verso 27.9%, p=0.017). L'analisi genetica ha mostrato che varianti del gene desmoplachina (DSP) erano più frequenti nei pazienti con SC (28.2% verso 19%, p=0.03). Nei pazienti con SC sono state osservate più frequentemente alcune alterazioni elettrocardiografiche, tra cui inversione dell'onda T in sede anteriore (p=0.03) e anterolaterale (p=0.01), onda epsilon (p=0.02), blocco di branca destro e blocco di branca sinistro (p<0.001) e bassi voltaggi (p<0.001). Alla risonanza magnetica cardiaca, la dilatazione e la disfunzione biventricolare sono risultate maggiori nel gruppo SC (p<0.001), così come la presenza di anomalie della cinetica regionale destra e sinistra (p=0.03 e p<0.001 rispettivamente), la presenza di LGE biventricolare (p<0.001) e l'infiltrazione adiposa del ventricolo sinistro (p=0.008). Outcomes sfavorevoli sono risultati prevalenti nei pazienti con SC: morte al follow-up (33% vs 1%, p<0.01) e trapianto cardiaco (43.6%, vs 0%, p<0.001). Infine, la presenza di insufficienza tricuspidalica severa (OR=8.9, IC 1.58-50.87, p=0.013), la frazione d'eiezione ventricolare destra (OR=0.92, IC 0.87-0.97, p=0.003) e la frazione d'eiezione ventricolare sinistra (OR=0.92, IC 0.88-0.97, p=0.002) sono risultati predittori di SC.
Conclusioni. I risultati del nostro studio dimostrano che nella popolazione di pazienti con CA, lo SC è un evento non infrequente che interessa soprattutto coloro che presentano forme più severe di malattia e che presentano varianti genetiche di DSP. La presenza di insufficienza tricuspidalica, la frazione d'eiezione ventricolare destra e la frazione d'eiezione ventricolare sinistra sono risultati predittori di SC. Lo studio infine enfatizza l'importanza d'individuazione precoce dei segni di SC nella popolazione dei pazienti con CA, al fine di stabilire un approccio terapeutico mirato a ridurre la progressione della malattia.

A810: PREDICTORS OF ADVERSE LONG-TERM OUTCOME AFTER SEPTAL REDUCTION THERAPIES IN OBSTRUCTIVE HYPERTROPHIC CARDIOMYOPATHY: INSIGHTS FROM THE SHARE REGISTRY

Niccolò Maurizi (a), Carlo Fumagalli (a), Nathan Aswhin (b), Anjali Owens (b), Sharlene Day (b), Iacopo Olivotto (a)
(a) CARDIOMYOPATHY UNIT, CAREGGI UNIVERSITY HOSPITAL, FLORENCE, ITALY; (b) PENN CENTER FOR INHERITED CARDIOVASCULAR DISEASE, HOSPITAL OF THE UNIVERSITY OF PENNSYLVANIA, PHILADELPHIA

BACKGROUND. Long term outcome and predictors of adverse outcome after septal reduction therapies (SRT) in obstructive Hypertrophic Cardiomyopathy (oHCM) are still debated, since most studies report post-operative results from surgical referral centers on medium to short term follow-ups.
PURPOSE. To evaluate the predictors of long term outcome following SRT in patients with oHCM from the SHaRe Registry.
METHODS. Data from 13 high-volume HCM specialty centers from the international SHaRe Registry were used to describe the natural history of patients with SRT. Patients were followed from SRT until last follow-up or to the composite outcome of heart failure (HF) (cardiac transplantation, implantation of an LV assist device (LVAD), left ventricular ejection fraction (LVEF) <35%, development of NYHA class III-IV symptoms), ventricular arrhythmias (VA) (sudden cardiac death (SCD), resuscitated cardiac arrest, or appropriate implantable cardioverter-defibrillator (ICD) therapy) or HCM related death. Cox proportional hazards models were used to identify predictors of prognosis and incident development.
RESULTS. Of the 10,385 patients part of the ShaRe Registry, 1832 (18%, 968 (53%) males) underwent a SRT. A total of 455 (25%) had Alcohol Septal Ablation (EtOH ablation) and 1377 (75%) had myectomy. Overall perioperative 30-day mortality was 0.4% (8/1832). During 6.8 [3.4-9.8] years of observation (12 565 person-years) after SRT, 77 (4%) died because of HCM (0.6%/year), 236 (13%) presented a composite HF outcome (1.9%/year) and 87 (5%) a composite VA outcome (0.7%/year). Increased age at the procedure was associated with HCM mortality (HR 1.22 (95 CI 1.1-1.3), p<0.01) and HF-outcome (HR 1.14 (95 CI 1.1-1.2), p<0.01), whereas female gender was predictor of HF after SRT (HR 1.4 (95 CI 1.1-1.8), p<0.01). Myectomy was associated with the occurrence of composite VA (HR 1.59 (95 CI 1.02-2.46), p=0.03).
CONCLUSIONS. Long term evolution after SRT was associated with a low overall HCM-related mortality but a significant and time-related burden of HF related events. They were largely associated with advanced age and female gender. Outcome in high clinical expertise and moderate surgical volume centers was comparable to current proposed standards.

A811: ARRHYTHMIAS AS EARLY CLINICAL MARKER OF A SYSTEMIC DISEASE: A RARE CLINICAL PRESENTATION

Valentina Allegro (a), Riccardo Saro (a), Aldostefano Porcari (a), Carla Indennidate (a), Franca Dore (c), Rossana Bussani (b), Gianfranco Sinagra (a), Marco Merlo (a)

(a) CARDIOVASCULAR DEPARTMENT, CENTER FOR DIAGNOSIS AND TREATMENT OF CARDIOMYOPATHIES, AZIENDA SANITARIA UNIVERSITARIA GIULIANO ISONTINA, UNIVERSITY OF TRIESTE, ITALY; (b) CARDIOTHORACIC DEPARTMENT, CENTER FOR DIAGNOSIS AND TREATMENT OF CARDIOMYOPATHIES, INSTITUTE OF PATHOLOGICAL ANATOMY AND HISTOLOGY, AZIENDA SANITARIA UNIVERSITARIA GIULIANO ISONTINA, UNIVERSITY OF TRIESTE, ITALY; (c) DEPARTMENT OF NUCLEAR MEDICINE, AZIENDA SANITARIA UNIVERSITARIA GIULIANO ISONTINA, UNIVERSITY OF TRIESTE, ITALY

A 49-year-old previously healthy gentleman presented in 2021 with palpitation and pre-syncope. His blood pressure was 95/60 mmHg and his ECG demonstrated a supraventricular arrhythmia which was successfully interrupted with adenosine. Resting ECG showed sinus rhythm, 1st degree AV block, antero-septal and inferior Q waves with normal QRS voltages. Echocardiogram demonstrated severely increased LV thickness (max 20 mm) in the absence of abnormal loading conditions with an ejection fraction of 60%. Serum troponin I was increased up to 1120 ng/L. Coronary CT ruled out significant coronary artery disease. Unexplained cardiac hypertrophy coupled with discrepantly normal QRS voltages raised the suspicion of cardiac amyloidosis (CA). The patient was originally from Serbia with a family history of "athlete's heart" and hypotension. He had long-standing hypotension, syncopal episodes, erectile dysfunction and carpal tunnel syndrome. His CMR was characteristic of CA (diffuse gadolinium enhancement and remarkably increased native T1 value). Cardiac scintigraphy with pyrophosphate demonstrated Perugini grade 3 myocardial uptake and serum and urine tests ruled out the presence of monoclonal proteins; a diagnosis of ATTR-CA with NAC ATTR stage I was made. TTR gene sequencing revealed the presence of p.(Glu109Gln) pathogenic mutation and cascade screening identified the same TTR mutation in his elder son (asymptomatic carrier with normal ECG and echocardiogram). This TTR mutation is most commonly associated with cardiomyopathy, but can coexist with neuropathy in one third of cases. Therefore, the patient was referred to neurological consultation that revealed sings of sensory-motor polyneuropathy of the lower limbs consistent with stage I ATTR neuropathy. Given the predominant cardiac involvement, the patient was started on Tafamidis as the only drug ever demonstrated to improve outcomes in ATTR-CA, and with a solid clinical indication for the treatment of stage I ATTR neuropathy. Over time, the patient remained stable on the neurological side, but had disease progression at cardiac level with development of NYHA class II symptoms, exercise intolerance, frequent supraventricular tachy-arrhythmias and increase in natriuretic peptides. He was started on loop diuretic and low-dose beta-blocker (poorly tolerated). His conditions have deteriorated over the last 12 months with need for escalating diuretic therapy. The patient has now entered periodic assessment for development of criteria for cardiac transplantation. This treatment restores organ function and substantially modify the natural history of disease. This case reports an uncommon clinical presentation of ATTR-CA, confirms the efficacy of Tafamidis on slowing or halting neuropathy progression and demonstrates that cardiac disease progression can occur despite treatment with disease-modifying drugs.

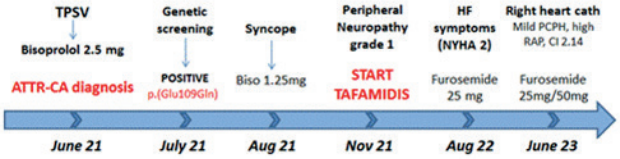

A812: BROADENING THE CLINICAL USE OF ANAKINRA TO RECURRENT PERICARDIAL SYNDROME WITHOUT INFLAMMATION

Valentina Allegro (a), Matteo Dal Ferro (a), Gerardina Lardieri (a), Marco Merlo (a), Gianfranco Sinagra (a)
(a) CARDIOVASCULAR DEPARTMENT, CENTER FOR DIAGNOSIS AND TREATMENT OF CARDIOMYOPATHIES, AZIENDA SANITARIA UNIVERSITARIA GIULIANO ISONTINA, UNIVERSITY OF TRIESTE, ITALY

A 66-year-old woman with no significant underlying comorbidities came to our attention in November 2022 due to a recurring pericardial effusion without signs of systemic inflammation. Her medical history included a similar episode in 2018 when she sought medical care due to exertional shortness of breath. During her initial hospitalization, she required a pericardiocentesis due to a large pericardial effusion (45 mm) with initial signs of cardiac tamponade. The analysis of the pericardial fluid revealed the presence of lymphocytes, red blood cells, and histiocytes, but no cancerous cells, bacteria, or fungi were found. The only notable immunological finding was elevated thyroperoxidase antibodies, with normal thyroid function. Subsequent thyroid ultrasound identified a small benign nodule. Tumor markers were within normal ranges and viral serology was negative. She was discharged with a prescription for Ibuprofen, Colchicine, and Methylprednisolone. During follow-up, each attempt to taper her medication resulted in the recurrence of pericardial effusion, leading to a second hospitalization for progressive pericardial effusion (maximum 46 mm) in 2020. Despite being asymptomatic and showing no particular signs of active inflammation, a single dose of intravenous immunoglobulin was administered and a second pericardiocentesis was performed. Laboratory findings were consistent with the previous hospitalization, and she was discharged with the same medications. Subsequent clinical and instrumental assessments confirmed her dependency on anti-inflammatory and corticosteroid therapy. Prolonged corticosteroid use led to severe osteoporosis with multiple vertebral fractures. Consequently, a gradual discontinuation of corticosteroids was planned. In December 2022, she was admitted to the hospital for the third time due to an increasing pericardial effusion (maximum 33 mm) with no signs of cardiac tamponade, despite her usual lack of symptoms. Extensive investigations failed to identify any specific cause for the pericardial effusion. Thoracic and abdomino-pelvic imaging revealed no abnormalities. After observing poor results with Ibuprofen and Colchicine, Anakinra was initiated, even though she never experienced fever or elevated inflammatory markers. Serial echocardiograms over the following 12 months showed a progressive and significant reduction in pericardial effusion (33 mm ->8 mm). Throughout this time, she tolerated Anakinra well. Presently, we are gradually reducing the frequency of Anakinra administration with favorable outcomes. The pericardial effusion remains contained and stable at 8 mm, without impacting her quality of life. This clinical case underscores the benefits and excellent tolerability profile of Anakinra therapy in a patient with recurrent idiopathic pericardial effusion, in the absence of overt pericarditis episodes and without inflammatory markers, who was unresponsive to conventional treatments.

A813: BELIEVE IN CARDIOPULMONARY EXERCISE TESTING: AN UNEXPECTED CAUSE OF DYSPNEA IN NON-DILATED LEFT VENTRICULAR CARDIOMYOPATHY - A CASE REPORT.

Nikita Baracchini (b), Teresa Maria Capovilla (b), Cosimo Carriere (b), Irena Tavcar (b), Antonio De Luca (b), Gianfranco Sinagra (b, c)
(a) DIPARTIMENTO CARDIOVASCOLARE, AZIENDA SANITARIA GIULIANO ISONTINA, TRIESTE, ITALIA; (b) DIPARTIMENTO CARDIOTORACOVASCOLARE, AZIENDA SANITARIA GIULIANO ISONTINA, UNIVERSITÀ DI TRIESTE, TRIESTE; (c) MEMBER OF ERN-GUARD HEART

Case Summary. A 58-year-old woman, with a history of arterial hypertension and known asthma, was hospitalized for severe dyspnea and chest pain at rest. The patient reported worsening exertional dyspnea during the past month. The physical exam revealed mild peripheral edema without signs of lung congestion. Chest X-ray, electrocardiogram, and blood test didn't provide clear diagnostic clues. Transthoracic echocardiography documented a normal-sized left ventricle (LV end-diastolic volume index 52 ml/m^2) with mild systolic dysfunction (LV ejection fraction 45%), normal right ventricular function and absence of significant valve disease. Systolic pulmonary artery pressure was not estimable due to the absence of tricuspid regurgitation. The coronary angiography was negative. To further investigate the underlying cause of dyspnea, Cardiopulmonary Exercise Testing (CPET) was performed, describing a normal functional capacity (VO_2 peak 19.8 ml/Kg/min, 98% of predicted value) but revealing an evident pulmonary vascular limitation (VE/VCO_2 Slope was 40) with ventilatory inefficiency (low levels of $PETCO_2$, and high VE/VCO_2 ratio). These parameters overall suggested Pulmonary Hypertension (PH) rather than a cardiac origin of symptoms. Subsequent lung SPECT-CT confirmed the diagnosis of chronic thromboembolic pulmonary hypertension (CTEPH).

Case Discussion. This case is remarkable for its rarity. CTEPH's estimated prevalence is 26-38 cases/millions of adults. The patient lacked a history of venous thromboembolism and did not exhibit the typical indirect clinical and instrumental signs of PH. On the contrary, the concurrent diagnosis of non-dilated LV cardiomyopathy could have further delayed the diagnosis. Finally, CPET played a pivotal role in guiding the diagnosis and facilitating the early initiation of oral anticoagulation for CTEPH in this atypical presentation, unequivocally highlighting its effectiveness in such cases.

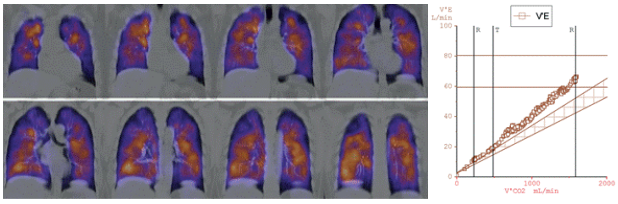

A814: APOPTOSIS, A DISTINCTIVE MARKER OF HOT PHASES IN ARRHYTHMOGENIC CARDIOMYOPATHY

Giulia Bassetto (a), Marco Merlo (a), Matteo Dal Ferro (a), Alessia Paldino (a), Chiara Collesi (c), Martina Setti (a, b), Rebecca Artioli (c), Francesco Loffredo (c, d), Saverio D´elia (d), Paolo Golino (d), Giuseppe Limongelli (d), Enrico Fabris (a), Rossana Bussani (e), Marco Metra (f), Gianfranco Sinagra (a)

(a) CARDIOVASCULAR DEPARTMENT, CENTER FOR DIAGNOSIS AND TREATMENT OF CARDIOMYOPATHIES, UNIVERSITY OF TRIESTE, TRIESTE, ITALY; (b) DIVISION OF CARDIOLOGY, DEPARTMENT OF MEDICINE, UNIVERSITY OF VERONA, ITALY; (c) MOLECULAR MEDICINE LABORATORY, ICGEB; (d) DEPARTMENT OF CARDIOTHORACIC SCIENCES, UNIVERSITÀ DELLA CAMPANIA LUIGI VANVITELLY, NAPLES, ITALY; (e) CARDIOTHORACIC DEPARTMENT, INSTITUTE OF PATHOLOGICAL ANATOMY AND HISTOLOGY, UNIVERSITY OF TRIESTE, ITALY; (f) CARDIOLOGY UNIT, DEPARTMENT OF MEDICAL AND SURGICAL SPECIALTIES, UNIVERSITY OF BRESCIA, BRESCIA, ITALY

Aims. "Hot phases", characterized by chest pain and/or troponin release, are a rare clinical presentation of arrhythmogenic cardiomyopathy. Differential diagnosis with acute myocarditis is an unmet challenge for the clinician. We sought to investigate histological and genetic features in patients with a cardiomyopathy presenting with suspected hot phases.

Methods and Results. A case-series of consecutive patients (n=17) hospitalized for suspected myocarditis vs. hot phase cardiomyopathy in two Italian centers from June 2017 to March 2022 (median follow up 18 months). All patients underwent cardiac evaluation, including both endomyocardial biopsy (including standard histology and immunohistochemistry for cardiac inflammation) and genetic testing (i.e., next generation sequencing). Apoptosis was confirmed with TUNEL Assay. Among 17 patients (76% males, mean age 34±15 years), 13 (77%) had a positive EMB for apoptosis, while only 6 patients (35%) presented severe inflammation. Genetic testing was positive for a pathogenic/likely pathogenic variant in genes involved in cardiomyopathies (most frequently in DSP) in 8 patients (48% of total cohort; 62% of patients with apoptosis on EMB), whereas patients without apoptosis tested negative for P/LP disease-related variants. Left ventricular ejection fraction (LVEF) was lower in patients showing apoptosis at EMB compared to those without (32±10% vs. 54+6% respectively, p=0.003). However, LVEF improved to 47±10% during follow-up (p=0.001) with neuro-hormonal blockade treatment in patients with apoptosis.

Conclusions. Apoptosis, rather than significant inflammation, emerged as a distinct finding at EMB in a consecutive case-series of patients with "hot phase" presentation and carrying variants in cardiomyopathies causing genes. This suggests that apoptosis detection on EMB could be systematically assessed for guiding the clinicians towards the use of genetic testing in the differential diagnosis with acute myocarditis.

A815: CARDIAC MAGNETI RESONANCE FEATURE TRACKING IDENTIFIES PRECLINICAL ABNORMALITIES IN HYPERTROFIC CARDIOMYOPATHY SARCOMERE GENE MUTATION CARRIERS

Francesco Negri (a), Giuseppe Damiano Sanna (b), Giulia Di Giovanna (c), Marco Cittar (c), Giulia Grilli (c), Antonio De Luca (c), Matteo Dal Ferro (c), Nikita Baracchini (c), Massimo Burelli (c), Alessia Paldino (c), Annamaria Del Franco (d), Silvia Pradella (e), Giancarlo Todiere (f), Iacopo Olivotto (d, g), Massimo Imazio (a), Gianfranco Sinagra (c), Marco Merlo (c)

(a) CARDIOLOGY DEPARTMENT UNIVERSITY HOSPITAL "SANTA MARIA DELLA MISERICORDIA" AZIENDA SANITARIA UNIVERSITARIA INTEGRATA DI UDINE; (b) CLINICAL AND INTERVENTIONAL CARDIOLOGY, SASSARI UNIVERISTY HOSPITAL; (c) CARDIOVASCULAR DEPARTMENT, CENTRE FOR DIAGNOSIS AND MANAGEMENT OF CARDIOMYOPATHIES, AZIENDA SANITARIA UNIVERSITARIA INTEGRATA DI TRIESTE; (d) CARDIOMYOPATHY UNIT CARDIOTHORACOVASCULAR DEPARTMENT CAREGGY UNIVERSITY HOSPITAL, FLORENCE; (e) DEPARTMENT OF EMERGENCY RADIOLOGY, CAREGGI UNIVERSITY HOSPITAL, FLORENCE; (f) FONDAZIONE GABRIELE MONASTIERO PISA; (g) DEPARTEMENT OF EXPERIMENTAL AND CLINICAL MEDICINE, MEYER CHILDREN HOSPITAL, UNIVERSITY OF FLORENCE

Background. The assessment of myocardial strain with cardiac magnetic resonance feature tracking (CMR-FT) has been found to be useful in patients with overt hypertrophic cardiomyopathy (HCM). However, little is known about its role in sarcomere gene mutation carriers without overt left ventricular hypertrophy (G+/LVH-) to identify preclinical phenotypes. We hypothesized that CMR-FT is abnormal in G+/LVH-, thus representing a preclinical marker of the disease.

Methods. Thirty-eight G+/LVH- subjects and 42 healthy volunteers were enrolled in this multicenter case-control study. All the study subjects underwent a comprehensive CMR study. Two-dimensional Global Radial (GRS), Circumferential (GCS) and Longitudinal (GLS) Strain of the left ventricle (LV) were evaluated by FT analysis.

Results. The G+/LVH- sample was 41 (22-51) years old and 32% were men. Feature tracking (FT) analysis revealed a reduction of GRS (29±7.2 vs 47.9±7.4; p<0.0001), GCS (-17.3±2.6 vs -20.8±7.4; p<0.0001) and GLS (-16.9±2.4 vs -20.5±2.6; p<0.0001) in G+ compared to control subjects. The significant differences persisted considering the 23 G+/P- (i.e., G+/LVH- individuals without ECG or CMR preclinical abnormalities). ROC curve analyses showed that the differential diagnostic performances of FT in discriminating G+/LVH- from normal subjects were good to excellent (GRS, AUC=0.946; GCS, AUC=0.849; GLS, AUC=0.843). Similar values were found for discriminating G+/P- from healthy volunteers.

Conclusions. CMR-FT-derived parameters are consistently reduced in HCM G+/LVH-, even in those without other early phenotypic abnormalities. CMR-FT-derived might emerge as a good tool order to discover the disease during a preclinical phase.

A816: PROGNOSTIC RISK STRATIFICATION IN MYOCARDITIS: THE MYOCARDITIS PROGNOSTIC SCORE

Daniela Di Lisi (a), Antonia Marotta (a), Cristina Madaudo (a), Chiara Alaimo (a), Marta Gargano (a), Martina Genduso (a), Ottavia Giardina (a), Domenico Scelfo (a), Vincenzo Sucato (a), Egle Corrado (a), Alfredo Ruggero Galassi (a), Giuseppina Novo (a)

(a) DIPARTIMENTO DI PROMOZIONE DELLA SALUTE MATERNO-INFANTILE, DI MEDICINA INTERNA E SPECIALISTICA DI ECCELLENZA UNIPA

Introduzione. la miocardite è una patologia infiammatoria del miocardio avente diverse cause, presentazioni cliniche e prognosi. Vari fattori prognostici predittori di outcomes nei pazienti con miocardite sono noti: la presentazione clinica complicata all'esordio, il ridotto global longitudinal strain del ventricolo sinistro, la sede settale del delayed enhancement (DE) alla risonanza magnetica cuore (RM). Obiettivo del nostro studio è stato quello di ideare uno score prognostico predittore di eventi nei pazienti con miocardite, sulla base dei noti fattori prognostici.

Materiali e metodi.è stato condotto uno studio multicentrico che ha incluso 98 pazienti (età media 30,75 ± 13,74 anni, 69 maschi e 29 femmine) con diagnosi di miocardite acuta confermata o clinicamente sospetta. A tutti i pazienti è stata eseguita una visita cardiologica con elettrocardiogramma al momento del ricovero, ecocardiogramma con valutazione del global longitudinal strain del ventricolo sinistro (GLS), dosaggio dei valori di troponina con valutazione del tempo di persistenza di elevati valori di troponina durante il ricovero, RM cuore con valutazione della sede ed estensione del DE. Tutti i pazienti a 6 mesi hanno eseguito una valutazione ecocardiografica e una RM cuore di rivalutazione ed è stata valutata la variazione dell'estensione del DE. È stata valutata l'insorgenza di eventi avversi cardiovascolari (morte, ospedalizzazione per scompenso cardiaco, trapianto di cuore, recidiva di miocardite, impianto di ICD, sviluppo di cardiomiopatia dilatativa, aritmie ventricolari) dopo un follow-up medio di 3 anni.

Risultati. Dei 98 pazienti rivalutati, 31 pazienti avevano una miocardite complicata all'esordio. Una maggiore incidenza di eventi avversi statisticamente significativa (morte, ospedalizzazione per scompenso cardiaco, trapianto di cuore, sviluppo di cardiomiopatia dilatativa) è stata riscontrata nei pazienti con miocardite complicata all'esordio. Inoltre nei pazienti con eventi sono stati riscontrati valori di LVEF e GLS significativamente più alterati, maggiore presenza di DE a livello settale, valori di troponina elevati per più giorni durante il ricovero per l'evento acuto, la persistenza o aumento del DE a 6 mesi. Alla regressione logistica lineare tali parametri sono risultati essere associati significativamente con gli eventi avversi. A tali parametri sono stati attribuiti punteggi diversi (sulla base dei valori di AUC alle curve ROC) e il "myocarditis prognostic score" è stato ideato. Uno score ≥5 si associava a maggiore probabilità di eventi; uno score ≤2 si associava a bassa probabilità di eventi. Un valore di LVEF ≤45%, GLS>- 15,3% e l'incremento dei valori di troponina>6,9 giorni hanno avuto la maggiore accuratezza diagnostica nel predire gli eventi.

Discussione e Conclusione. la prognosi delle miocarditi è molto varia e associata a vari fattori prognostici clinici, laboratoristici e di imaging. Il nostro studio dimostra la maggiore incidenza di eventi avversi cardiovascolari nei pazienti con miocardite complicata all'esordio. Inoltre è il primo studio ad ideare uno score prognostico che integra dati ecocardiografici, di RM cuore e laboratoristici in grado di identificare i pazienti con miocardite a maggior rischio di eventi avversi e che necessitano di un follow-up più ravvicinato.

A817: SINDROME TAKOTSUBO E DEL QT LUNGO: UN INSULTO ALLA RIPOLARIZZAZIONE

Domenico Scelfo (a), Daniela Di Lisi (a), Federica Manfre´ (a), Francesca Di Salvo (a), Danilo Puccio (a), Vincenzo Sucato (a), Gianfranco Ciaramitaro (a), Giuseppe Coppola (a), Egle Corrado (a), Alfredo Ruggero Galassi (a), Giuseppina Novo (a)

(a) DIPARTIMENTO DI PROMOZIONE DELLA SALUTE MATERNO-INFANTILE, DI MEDICINA INTERNA E SPECIALISTICA DI ECCELLENZA UNIPA

Introduzione. La sindrome Takotsubo (TTS), è una condizione clinica caratterizzata da una disfunzione transitoria del ventricolo sinistro apicale o medio-ventricolare che mima l'infarto del miocardio, in assenza di una lesione coronarica colpevole. La TTS è tipicamente innescata da intenso stress emotivo, psicologico o fisico o da una malattia acuta. Durante la fase acuta e subacuta, è spesso evidente all'ECG la presenza di profonde onde T negative con il prolungamento dell'intervallo QT all'ECG. Nonostante la prognosi della TTS sia generalmente buona, sono stati segnalati decorsi clinici gravi a causa della disfunzione ventricolare sinistra acuta, con shock cardiogeno o tachiaritmie maligne. Presentiamo un caso di sindrome del QT lungo preesistente e clinicamente silente (LQTS) esacerbata dalla sindrome di Takotsubo, determinante aritmie pericolose per la vita.

Caso clinico. Una donna di 72 anni accedeva presso il nostro reparto di cardiologia per dolore toracico oppressivo. Nella stessa giornata aveva subito un forte stress emotivo legato alla morte improvvisa della figlia. All'ECG di ingresso flutter atriale, ESA, QTc 516 ms. La coronarografia mostrava albero coronarico angiograficamente indenne. La curva troponinica era significativa con picco di 297 ng/L (v.n. <14 ng/L). L'ecocardiogramma color-Doppler mostrava ventricolo sinistro di normali dimen-

sioni, con spessori parietali aumentati, ipercinesia dei segmenti basali e acinesia apicale e dei segmenti medi. Frazione d'eiezione 40%. Nel corso della degenza l'ECG evolveva con sottoslivellamento del tratto ST, onde T invertite profonde e intervallo QT prolungato (554 ms). La paziente sviluppava un episodio di torsione di punta dalla durata di pochi secondi e autorisolventesi e veniva trattata con solfato di magnesio e betabloccante. Si assisteva a ulteriori subentranti episodi di torsioni di punta e di tachicardia ventricolare sostenuta monomorfa trattati con shock bifasico e infusione di lidocaina. Per il persistere di instabilità elettrica veniva impiantato pacemaker temporaneo con l'obiettivo di effettuare overdrive pacing, rimosso dopo 4 giorni a risoluzione dell'instabilità elettrica. La valutazione degli elettrocardiogrammi eseguiti durante precedenti degenze ospedaliere documentava la presenza di un intervallo QT patologicamente prolungato (in media 500 ms), e alla luce dello storm aritmico riscontrato nel corso della degenza, si poneva indicazione all'impianto di ICD in prevenzione secondaria. In pre-dimissione veniva eseguito un esame ecocardiografico che documentava regressione dei difetti di cinesi segmentaria con una frazione di eiezione del 55%. In atto è in corso la valutazione genetica per LQTS.

Conclusione. Sebbene la TTS possa associarsi a prolungamento del QTc, casi di overlap sindrome del QT lungo congenito e TTS sono stati documentati in letteratura. La TTS potrebbe anche smascherare la sindrome del QT lungo congenita silente o inapparente.

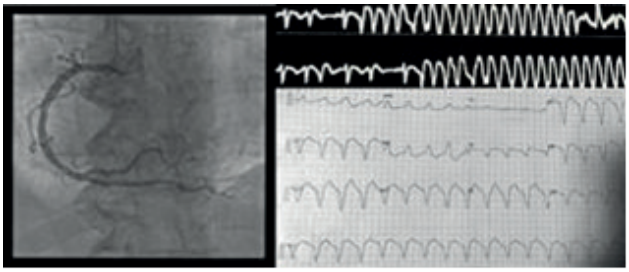

A818: FIRST DESCRIPTION OF PERICARDITIS-INDUCED BRUGADA PHENOCOPY IN INFERIOR LEADS

Andrea Ottaviani (a), Lorenzo Vilhelm Molinari (a), Silvio Saraullo (a), Giulia Renda (a, b), Sabina Gallina (a, b), Fabrizio Ricci (a, b, c)
(a) DEPARTMENT OF NEUROSCIENCE, IMAGING AND CLINICAL SCIENCES, "G. D'ANNUNZIO" UNIVERSITY OF CHIETI-PESCARA, 66100 CHIETI, ITALY; (b) HEART DEPARTMENT SS. ANNUNZIATA HOSPITAL, ASL 2 ABRUZZO, CHIETI, ITALY; (c) DEPARTMENT OF CLINICAL SCIENCES, LUND UNIVERSITY, 21428 MALMO, SWEDEN

Brugada syndrome (BrS) is a genetic disorder caused by altered sodium voltage gated channels and characterized by increased arrhythmic risk. Diagnosis has been historically challenging as ECG patterns are dynamic. Furthermore, diagnosis requires exclusion of phenocopies: conditions characterized by Brugada ECG patterns present in patients without underlying genetic defects or family history of sudden cardiac death. In 2012 Baranchuk proposed a classification of Brugada Syndrome phenocopies (BrP): main causes include metabolic derangements, myocardial ischemia, infiltrative cardiomyopathy, pericardial disease, mechanical mediastinal compression, and pulmonary embolism. This case report concerns a 68-year-old man who came to the Emergency Room suffering from acute chest pain, exacerbated by respiratory movements. Medical history included arterial hypertension, previous episode of pulmonary embolism, type 2 diabetes mellitus, and chronic kidney disease (CKD). Upon clinical examination, the patient was hemodynamically stable, apyretic. Heart sounds were rhythmic and weak. The 12-lead ECG showed a sinus rhythm, heart rate of 76 bpm, and normal PR and QT intervals. ECG filters were 0.05-100 Hz. The inferior leads displayed a "coved" ST elevation, especially evident at a 20mm/mV amplitude, with a type 1 Brugada-like morphology (figure A). Blood tests revealed: negative Troponin I HS, altered inflammatory markers (CRP 146mg/dl), elevated D-dimer (7.62ng/ml) and creatinine (3.12mg/dl). The echocardiogram showed normal biventricular contractility with no significant valvulopathies. Additionally, there was moderate circumferential pericardial effusion (maximum 20mm), predominantly affecting the infero-lateral wall, without signs of increased ventricular interdependence or constrictive physiology. Pulmonary embolism was excluded through angiographic CT. A diagnosis of pericarditis was established and the patient was started on methylprednisolone; colchicine and NSAIDs were contraindicated due to CKD. After one month of treatment, the ECG showed complete normalization, with regression of the Brugada type 1-like pattern in the inferior leads (figure B). The echocardiogram revealed a complete resolution of the pericardial effusion.Inizio modulo Pericarditis-induced phenocopy is a very rare entity; in the available literature we found only other 7 published cases. In all these cases patterns emerged in the right precordial leads, indicating a temporary reduced conduction reserve of right ventricular outflow tract. To our knowledge this is instead the first presentation of pericarditis-induced case of BrP with ECG pattern type I in inferior leads. While direct inflammatory effect of pericardial effusion is possibly the main cause, we might only speculate on its role as an acute modulator of right ventricular outflow tract and long-term prognosis. Interestingly, Sarkozy et al. showed that 4.3% of patients with BrP in inferior leads converted to "inferior BrS" upon provocative tests.

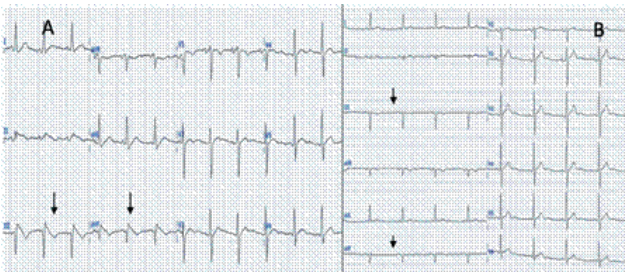

A819: RUOLO TESSUTO ADIPOSO EPICARDICO NELLA CARDIOMIOPATIA ATRIALE

Erika Parente (a), Maddalena Conte (a, d), Paolo Poggio (e), Laura Petraglia (a), Giuseppe Comentale (b), Adele Ferro (c), Emanuele Pilato (b), Dario Leosco (a), Valentina Parisi (a)
(a) DIPARTIMENTO DI SCIENZE MEDICHE TRASLAZIONALI, UNIVERSITÀ DEGLI STUDI DI NAPOLI "FEDERICO II"; (b) DIPARTIMENTO DI SCIENZE BIOMEDICHE AVANZATE, UNIVERISITÀ DEGLI STUDI DI NAPOLI "FEDERICO II"; (c) ISTITUTO DI BIOSTRUTTURE E BIOIMMAGINI, CNR, NAPOLI; (d) CASA DI CURA SAN MICHELE, MADDALONI, ITALIA; (e) CENTRO CARDIOLOGICO MONZINO IRCCS, 20138, MILANO

Obiettivi. La cardiomiopatia atriale (CA) è associata ad eventi cardiovascolari a prognosi sfavorevole. La nostra ipotesi è che il tessuto adiposo epicardico (EAT) possa avere un ruolo nello sviluppo della CA e degli eventi ad essa correlati.

Metodi. Sono stati arruolati retrospettivamente 2466 pazienti sottoposti ad ecocardiogramma All'ecocardiogramma è stato misurato il volume dell'atrio sinistro e il massimo spessore dell'EAT, Abbiamo selezionato 40 pazienti con malattia aterosclerotica coronarica candidati ad intervento cardiochirurgico. Durante l'intervento sono state effettuate biopsie di EAT e di miocardio atriale. Le biopsie miocardiche sono state sottoposte ad analisi istologica per valutare presenza e grado di fibrosi e l'eventuale deposizione di amiloide. Nel secretoma di EAT abbiamo misurato i livelli di 27 mediatori e citochine infiammatorie. In vitro, abbiamo isolato i fibroblasti atriali, e valutato la proliferazione e la sintesi di collagene dopo esposizione ad IL1β.

Risultati. Nei 2466 pazienti, l'aumento dello spessore dell'EAT era associato alla presenza di FA cronica e dilatazione atriale sinistro. Si osserva una relazione diretta tra spessore dell'EAT e aumento della misura di conduit dello strain atriale. Poiché le modifiche dello strain atriale potrebbero essere espressione di cambiamenti strutturali, abbiamo esplorato l'associazione tra spessore di EAT e fibrosi atriale valutata all'istologia ed abbiamo riscontrato un trend di correlazione tra spessore di EAT e fibrosi atriale. All'esame istologico 6 biopsie di miocardio atriale sono risultate positive per deposizione di amiloide, sulle quali è stata condotta un'analisi immunoistochimica con anticorpi anti-Siero Amiloide A (SAA), 5 mostravano colorazione positiva per SAA. Inoltre, per testare l'ipotesi che le citochine infiammatorie secrete da EAT possano modulare il rimodellamento atriale e favorire l'insorgenza di POAF, abbiamo misurato i livelli di diverse citochine e mediatori infiammatori nel secretoma di EAT e abbiamo osservato che IL-1β prodotta da EAT era associata all'insorgenza di POAF.

Conclusioni. L'EAT potrebbe esercitare un ruolo rilevante nel rimodellamento strutturale ed elettrico atriale, contribuendo alla patogenesi della CA. L'infiammazione locale sembrerebbe mediare l'attività sfavorevole dell'EAT promuovendo la proliferazione e la produzione di collagene da parte dei fibroblasti atriali e favorendo il rimodellamento del miocardio atriale e l'aritmogenesi.

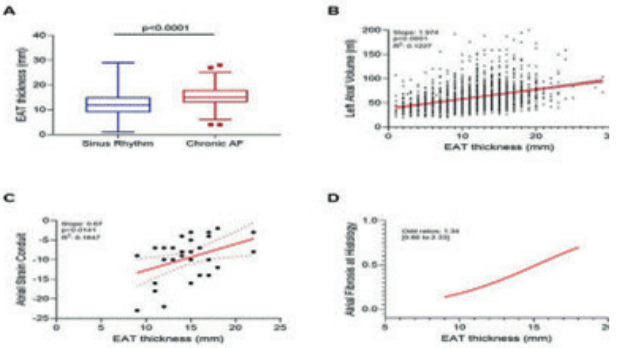

A820: UN RARO CASO DI ASSOCIAZIONE TRA COARTAZIONE AORTICA E CARDIOMIOPATIA IPERTROFICA

Guido Pasero (a), Andrea Pandolfi (a), Federica Valli (b), Filippo Toriello (b), Massimo Saviano (b), Marco Vicenzi (a, b), Stefano Carugo (a, b)
(a) DEPARTMENT OF CLINICAL SCIENCE AND COMMUNITY OF HEALTH, UNIVERSITY OF MILAN, ITALY; (b) DEPARTMENT OF CARDIO-THORACIC-VASCULAR DISEASES, FOUNDATION IRCCS CA GRANDAOSPEDALE MAGGIORE POLICLINICO, ITALY

Introduzione. La coartazione aortica (CoA) è un'anomalia congenita caratterizzata da una diminuzione del calibro aortico che si riscontra in circa lo 0.06-0.08% della popolazione generale. La CoA viene di solito diagnosticata nei primi mesi di vita, un riscontro nell'adulto avviene quasi sempre nel contesto di indagini diagnostiche eseguite nel sospetto di un'ipertensione arteriosa (IA) secondaria. La cardiomiopatia ipertrofica (HCM) è una condizione caratterizzata da aumento della massa cardiaca in assenza di sovraccarico di volume o pressione. La forma più comune è causata da mutazioni a carico di geni sarcomerici e può manifestarsi con sincope aritmica o da ostruzione all'efflusso del ventricolo sinistro, con scompenso cardiaco, oppure essere un riscontro occasionale.
Caso clinico. Un uomo di 60 anni statunitense si presentava al PS del nostro centro per un episodio di perdita di coscienza (PDC) in assenza di prodromi, riferendo episodi analoghi in passato. In anamnesi presentava plurimi fattori di rischio cardiovascolare (IA, diabete mellito) ed un intervento correttivo per coartazione aortica eseguito all'età di 20 anni. L'ECG mostrava ritmo sinusale normofrequente, ritardo aspecifico della conduzione IV con stacco alto del tratto ST in V1-V2. Gli esami ematochimici escludevano un danno miocardico acuto. L'ecocardiografia evidenziava ipertrofia asimmetrica settale e della parete antero-laterale del ventricolo sinistro (VS), con spessori di 16-17 mm. Per meglio definire la causa dell'ipertrofia, nell'ipotesi di una malattia miocardica primitiva, veniva eseguita una risonanza magnetica cardiaca (CMR) che confermava la presenza di ipertrofia spiroide del setto basale e della parete laterale del VS, con contestuale LGE a pattern non ischemico nelle aree ipertrofiche (18% della massa miocardica). Veniva quindi posta diagnosi di HCM. Nell'ottica della prevenzione primaria della morte cardiaca improvvisa veniva stimato il rischio aritmico del paziente tramite HCM- risk-SCD calculator, che restituiva un valore di rischio a 5 anni del 5,6%. Considerato il rischio di livello intermedio e la presenza di un ulteriore fattore di rischio (LGE alla CRM>15%) veniva eseguito l'impianto di ICD. L'analisi genetica e l'eventuale estensione dello screening ai familiari veniva demandata ai colleghi della città di origine del paziente.
Discussione. Frequentemente l'operazione di decoartazione o stenting del tratto di aorta stenotico eseguita nell'adulto non porta a risoluzione dell'IA e, anche intervenendo precocemente nel bambino, persiste un maggiore rischio di sviluppo di IA. La presenza di IA di lungo corso aveva portato a considerare il fenotipo ipertrofico come secondario al sovraccarico cronico di pressione. Una più attenta raccolta anamnestica con evidenza di ripetuti episodi di PDC senza prodromi, le alterazioni ECG non tipiche di ipertrofia secondaria a sovraccarico pressorio e un quadro ecocardiografico sospetto hanno permesso di considerare come possibile diagnosi differenziale una cardiomiopatia primitiva, confermata poi tramite CMR.
Conclusione. Questo raro caso di associazione di CoA e HCM evidenzia come, nella possibilità di più concause di un fenotipo cardiaco ipertrofico, l'integrazione di dati anamnestici, clinici ed elettrofisiologici associati ad un imaging di secondo livello permetta di ottenere una diagnosi definitiva in grado di indirizzare il paziente al giusto percorso terapeutico.

A821: ROLE OF CONTINUOUS ARRHYTHMIA MONITORING IN PATIENTS WITH HYPERTROPHIC CARDIOMYOPATHY

Lucia Molinari (b), Andrea Villatore (a), Elena Paiotti (b), Giulia Randi (b), Gaia Souryal (b), Marianna Cariello (b), Paolo Della Bella (a), Giovanni Peretto (a, b)
(a) IRCCS OSPEDALE SAN RAFFAELE, MILANO; (b) UNIVERSITÀ VITA-SALUTE SAN RAFFAELE, MILANO

Background. The current risk score to predict major ventricular arrhythmias (MVA) in hypertrophic cardiomyopathy (HCM) does not take into account the results of continuous arrhythmia monitoring (CAM) techniques.
Purpose. To assess the incidence of arrhythmias in HCM patients undergoing CAM, and to investigate their possible role in predicting MVA.
Methods. We screened a cohort of 356 patients with cardiomyopathy undergoing prospective follow-up at a referral center. We retrospectively selected patients with proven diagnosis of HCM and undergoing CAM for a minimum follow-up of 5 years. The HCM-risk score was calculated from data available at baseline investigation. Presence and type of arrhythmia was identified by CAM on top of Holter ECGs. The primary endpoint was the occurrence of MVA, defined either as ventricular tachycardia (VT), ventricular fibrillation (VF) or appropriate implantable cardioverter defibrillator (ICD) therapy.
Results. The final study cohort was composed of 29 patients with HCM (76% males, age 57±14 y, mean LVEF 58±10%, undergoing CAM. In detail, CAM devices included either ICD (n=13) or loop recorders (n=15). At baseline assessment, the mean HCM-risk score in the cohort was 3.1±1.7%, and 13 patients (45%) were at low-risk (<4%). By 5-year follow-up, 9 patients (31%) experienced MVA. The incidence of other arrhythmias was: 41% for nonsustained VA, 45% for atrial fibrillation (AF), 21% for atrial flutter/tachycardia, 26% for high-burden premature ventricular beats, and 7% for bradyarrhythmias. Remarkably, no differences in baseline HCM-risk score values were detected in patients with and without anytime documentation of MVA (respectively 3.0±1.9 vs. 3.2±1.6, p>0.05). However, of the 6 patients who experienced MVA despite baseline HCM-risk score <4%, 4 (67%) had atrial fibrillation recorded before MVA episodes. The remaining baseline clinical features, as well as incidence and burden of other arrhythmias, were comparable between groups (all p>0.05).
Conclusions. Our preliminary data point to a possible prognostic for AF in HCM patients currently considered at low risk of MVA.

A822: IMPROVING THE MANAGEMENT OF ARRHYTHMOGENIC CARDIOMYOPATHY: EFFICACY OF IMPLANTABLE LOOP RECORDER MONITORING

Valerio Pergola (c, d), Alessandro Trancuccio (a, b), Deni Kukavica (a, b), Gianluca Pili (b), Gilad Zvielli (b), Maira Marino (a), Patrick Gambelli (a), Mirella Memmi (a), Raffaella Bloise (a), Carlo Napolitano (a, b), Andrea Mazzanti (a, b, c), Silvia G. Priori (a, b, c)
(a) IRCCS ICS MAUGERI, PAVIA, ITALY; (b) UNIVERSITY OF PAVIA, PAVIA, ITALY; (c) CENTRO NACIONAL DE INVESTIGACIONES CARDIOVASCULARES (CNIC), MADRID, SPAIN; (d) UNIVERSITY OF NAPLES FEDERICO II, NAPLES, ITALY

Background. Implantable loop recorders (ILRs) are a minimally invasive diagnostic tool for identifying arrhythmias in patients with unexplained syncope or asymptomatic arrhythmias. Their use in individuals with inherited arrhythmia syndromes has been advocated in the 2022 ESC Guidelines. However, the clinical efficacy of ILRs in patients with arrhythmogenic cardiomyopathy (ACM) has not been explored.
Objective: The objective of this study was to evaluate the efficacy of ILR monitoring in detecting clinically significant events in a single-center cohort of patients with ACM.
Methods. We prospectively collected demographic, clinical, and follow-up data from ACM patients who underwent ILR implantation and were monitored via telemedicine. The primary end point was identification of clinically significant events recorded by ILR that required upgrade to an implantable cardioverter-defibrillator (ICD).
Results. The study included 33 consecutive ACM patients (64% male; mean age at ILR implantation 32±12 years). None of these patients had previously experienced life-threatening arrhythmias. During a median follow-up of 2.5 years (IQR 1.4-3.7 years) after ILR implantation, clinically relevant arrhythmic events were documented in 5 of 33 patients (15%). Specifically, sustained ventricular tachycardia episodes were detected in 3 of these 5 patients, whereas non-sustained ventricular tachycardias were recorded in 2 of 5 patients. In all cases, the detection of such episodes led to the decision to implant an ICD.
Conclusions. ILR monitoring of patients with inherited cardiomyopathies detected clinically significant events in nearly one-fifth of cases, suggesting that the use of ILR could significantly improve the management of these patients.

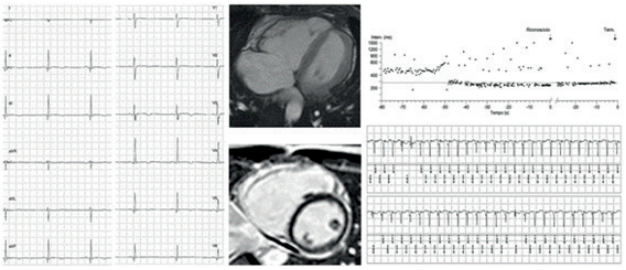

Figure. We present the compelling case of a 19-year-old man with arrhythmogenic right ventricular cardiomyopathy who had a pathogenic PKP2 truncation variant. One year after ILR implantation, the patient complained of palpitations and dizziness on exertion. ILR monitoring revealed rapid tachycardia at 250 beats per minute that persisted for 3 minutes and required ICD implantation. This case highlights the central role of ILRs in therapeutic decisions for inherited cardiomyopathies.

A823: CARDIAC MASSES: CLINICAL, HISTOPATHOLOGICAL AND PROGNOSTIC DIFFERENCES BETWEEN MALES AND FEMALES

Ornella Di Iuorio (a, b), Daniele Cavallo (a, b), Khrystyna Ryabenko (a, b), Francesco Pio Tattilo (a, b), Francesco Angeli (a, b), Luca Bergamaschi (a, b), Nicole Suma (a, b), Matteo Armillotta (a, b), Andrea Impellizzeri (a, b), Damiano Fedele (a, b), Lisa Canton (a, b), Davide Bertolini (a, b), Sara Amicone (a, b), Francesca Bodega (a, b), Angelo Sansonetti (a, b), Andrea Stefanizzi (a, b), Virginia Marinelli (a, b), Claudio Asta (a, b), Camine Pizzi (a, b)
(a) CARDIOLOGY UNIT - IRCSS AZIENDA OSPEDALIERA-UNIVERSITARIA DI BOLOGNA; (b) DEPARTMENT OF MEDICAL AND SURGICAL SCIENCES - DIMEC - ALMA MATER STUDIORUM, UNIVERSITY OF BOLOGNA

Background. The relationship between sex and Cardiac masses (CM) is still unclear and potential differences in incidence, clinical and imaging features between female and male patients remain to be investigated.
Purpose. The aim of this study was to investigate the clinical, demographic and histotype differences between men and women with Cardiac masses and to assess sex-related outcomes at long-term follow-up.
Methods. This observational study included all consecutive patient who underwent non-invasive imaging investigations for suspected CM in our centre between 2004 and 2022. Definitive diagnosis was achieved with histological specimen or, in case of cardiac thrombi, by radiological evidence of thrombus resolution after appropriate anticoagulant treatment.
Results. Of our patients, 99 were affected by malignancies, either primitive or metastatic. Metastasis were more common in the male population. The most frequent tumor was myxoma in both men and women. Benign tumors were more frequently observed in women. Female patients were younger, presented a lower Body Mass Index (BMI) and were less frequently smokers (p<0.001) than men. Interestingly female patients were more prone to peripheral embolism. In men, CMs showed greater dimension and were more frequently sessile with irregular margins, immobile and infiltrated. Male patients presented more frequently with pericardial effusion (p=0.001). Women showed significantly higher survival during follow-up in comparison to men in the overall study population. Nevertheless, we did not observe significant differences in survival of benign and malignant lesions and in the specific histological subgroups between male and female patients.
Conclusions. This study on a large group of cardiac masses with histological diagnosis demonstrates the important role of sex in this clinical scenario. Benign CMs affected female patient more frequently, while malignant tumors affected predominantly men. Despite a different prognosis, sex does not influence the prognosis of benign or malignant neoformations.

A824: CHARACTERIZATION OF CARDIAC MASSES WITH CARDIAC MAGNETIC RESONANCE (CMR): A MULTIPARAMETRIC APPROACH TO DEFINE MALIGNANCY

Lisa Canton (a), Pasquale Paolisso (b, c), Luca Bergamaschi (a), Francesco Angeli (a), Damiano Fedele (a), Matteo Armillotta (a), Angelo Sansonetti (a), Francesca Bodega (a), Sara Amicone (a), Nicole Suma (a), Alberto Foà (a), Marta Belmonte (c, d), Emanuele Gallinoro (b), Anna Giulia Pavon (e), Marco Guglielmo (f), Luigi Lovato (a), Carmine Pizzi (a)
(a) CARDIOLOGY UNIT, CARDIAC THORACIC AND VASCULAR DEPARTMENT, IRCCS AZIENDA OSPEDALIERA-UNIVERSITARIA DI BOLOGNA, ALMA MATER STUDIORUM, UNIVERSITY OF BOLOGNA, ITALY; (b) CLINICAL CARDIOLOGY AND CARDIOVASCULAR IMAGING UNIT, GALEAZZI-SANT'AMBROGIO HOSPITAL, IRCCS, MILAN, ITALY; DEPARTMENT OF BIOMEDICAL AND CLINICAL SCIENCES, UNIVERSITY OF MILAN, MILAN, ITALY; (c) DEPARTMENT OF ADVANCED BIOMEDICAL SCIENCES, UNIVERSITY OF NAPLES, FEDERICO II, NAPLES, ITALY; (d) CARDIOVASCULAR CENTER AALST, OLV HOSPITAL, AALST, BELGIUM; (e) CARDIOCENTRO TICINO INSTITUTE, LUGANO, SWITZERLAND; (f) DEPARTMENT OF CARDIOLOGY, DIVISION OF HEART AND LUNGS, UTRECHT UNIVERSITY MEDICAL CENTER, UTRECHT, THE NETHERLANDS

Background. Multimodality imaging is currently suggested for the non-invasive diagnosis of cardiac masses (CMs). The identification of CMs malignant nature is essential to guide proper treatment.
Aims. To develop a multiparametric CMR-derived model including mass localization, morphology, and tissue characterization to predict malignancy (with histology as gold standard), to compare its accuracy versus a diagnostic echocardiography mass score (DEM Score), and to evaluate its prognostic ability.
Methods. Observational cohort study of 167 consecutive patients undergoing a comprehensive echocardiogram and CMR within 1-month time interval for suspected CM. A definitive diagnosis was achieved by histological examination or, in case of cardiac thrombi, by histology or radiologic resolution after adequate anticoagulation treatment. Logistic regression was performed to assess CMR-derived independent predictors of malignancy, which were included in a multiparametric model to derive the CMR Mass Score. Kaplan-Meier curves and Cox regression were used to investigate the prognostic ability of predictors.
Results. At CMR, mass morphological features (non-left localization, sessile, polylobate, inhomogeneity, infiltration, and pericardial effusion) and mass tissue characterization features (first- pass perfusion and heterogeneity enhancement) were independent predictors of malignancy. The CMR Mass Score (range 0-8, cut-off ≥5), including sessile appearance, polylobate shape, infiltration, pericardial effusion, first-pass contrast perfusion, and heterogeneity enhancement, showed excellent accuracy in predicting malignancy (AUC=0.976, 95% CI 0.96-0.99), significantly higher than DEM score (AUC=0.932, p=0.040). The agreement between the DEM and CMR Mass scores was good (k=0.66). A CMR Mass Score ≥5 predicted higher risk of all-cause death (HR=5.70) at 5-year follow- up.
Conclusions. A multiparametric CMR-derived model, including mass morphology and tissue characterization, showed excellent accuracy, superior to echocardiography, in predicting CMs malignancy, with prognostic implications.

A825: QUALITATIVE ASSESMENT OF BRAIN METABOLISM PATTERNS IN TAKOTSUBO SYNDROME

Damiano D'Alessandro (a), Francesco Santoro (a), Ilaria Ragnatela (a), Rosa Cetera (a), Tommaso Martino (a), Annalisa Matera (a), Michele Correale (a), Natale Daniele Brunetti (a)
(a) CARDIOLOGY UNIT, DEPARTMENT OF MEDICAL AND SURGERY SCIENCES, UNIVERSITY OF FOGGIA, ITALY

Background. Takotsubo Syndrome (TTS) is a transient regional systolic dysfunction, due to an emotional or physical trigger. Pathophysiological mechanisms of this syndrome remain unclear. Several studies have ascertained the link between the brain and heart, however, no study evaluated brain metabolism in TTS patients.
Methods. Twenty consecutive TTS patients underwent 18F-fluorodeoxyglucose positron emission tomography/computed tomography (18F-FDG PET/CT) to assess brain metabolism.
Results. Mean age was 71.5±10.5 years, 3 out of 20 (15%) patients were male. TTS Trigger was emotional in 11 (55%) patients and physical in 9 (45%) patients. At neurological examination, 12 patients had a normal neurological exam, 6 patients had a mild cognitive impairment (MCI) and 2 patients a vascular dementia. At brain 18-FDG PET/TC, there was a reduced uptake in 13 out of 20 (65%) patients. Among TTS patients with normal neurological profile, 6 out of 12 (50%) had normal brain uptake, meanwhile 6 out of 12 (50%) had multiple areas of reduced uptake involving anterior cingulate (33%), temporal lobes (83%), parietal lobes (66%), frontal lobes (82%). Among TTS patients with MCI, one out of 6 (16%) patients had normal brain uptake, 3 out of 5 (50%) had multiple areas of reduced uptake involving temporal, parietal and frontal lobes and 2 out of 5 (34%) patients had only frontal or temporal reduced uptake. Additionally, patients with dementia (2 out of 20, 10%), had multiple areas of reduced uptake involving temporal, parietal and frontal lobes.
Conclusions. Patients with takotsubo syndrome may present area of reduced brain uptake also in case of normal neurological profile. Therefore, a multi-disciplinary evaluation of these patients may be needed.

A826: BETA-BLOCKERS AND RENIN-ANGIOTENSIN SYSTEM INHIBITORS FOR TAKOTSUBO SYNDROME RECURRENCE: A NETWORK META-ANALYSIS

Nicola Di Nunno (a), Francesco Santoro (a), Rodolfo Citro (b), Angelo Silverio (b), Annalisa Matera (a), Ilaria Ragnatela (a), Rosa Cetera (a), Natale Daniele Brunetti (a)
(a) CARDIOLOGY UNIT, DEPARTMENT OF MEDICAL AND SURGERY SCIENCES, UNIVERSITY OF FOGGIA; (b) CARDIOLOGY UNIT, UNIVERSITY OF SALERNO

Introduction. Takotsubo syndrome (TTS) is an acute heart failure syndrome, featured by transient left ventricular systolic dysfunction. Recurrences of TTS are not infrequent and there is no standard preventive therapy. The aim of this study was to evaluate in a network meta-analysis if beta-blockers (BB) and ACE inhibitors/angiotensin receptor blockers (ACEi/ARBs), in combination or not, can effectively prevent TTS recurrences.
Methods. We performed a systematic network meta-analysis, using MEDLINE/EMBASE and the Cochrane Central Register of Controlled Trials for clinical studies published between January 2010 and September 2022. We considered all those studies including patients receiving medical therapy with BB, ACEi/ARBs. The primary outcome was TTS recurrence.
Results. We identified 6 clinical studies encompassing a total of 3407 patients with TTS. At 40±10 months follow-up, TTS recurrence was reported in 160 (4.7%) out of 3407 patients. Mean age was 69.8±2 years and 394 patients (11.5%) out of 3407 were male. There were no differences in terms of TTS recurrence when comparing ACEi/ARBs versus control (OR 0.83; 95% CI 0.47 to 1.47, p=0.52); BB versus control (OR 1.01; 95% CI 0.63 to 1.61, p=0.96) and ACEi/ARBs versus BB (OR 0.88; 95% CI 0.51 to 1.53, p=0.65).Combination of BB and ACEi/ARBs was also not effective in reducing the risk of recurrence versus control (OR 0.91; 95% CI 0.58 to 1.43, p=0.68) vs ACEi/ARBs (OR 0.79; 95% CI 0.46 to 1.34, p=0.38)) and vs BB (OR 0.77; 95% CI 0.49 to 1.21, p=0.26).
Conclusions. Our study did not find sufficient statistical evidence regarding combination therapy with BB and ACEi/ARBs in reduction of TTS recurrence.

A827: AMILOIDOSI SENILE: "NO COUNTRY FOR OLD MEN"

Giuseppe Sena (a), Irene Ruotolo (a), Giulia Saturi (a), Alberto Ponziani (a)
(a) POLICLINICO SANT'ORSOLA UNIVERSITÀ ALMA MATER BOLOGNA

Un uomo di 60 anni viene ricoverato per scompenso cardiaco nel 2017. L'ecocardiogramma mostra un ventricolo sinistro severamente ipertrofico con FE 45%. Il quadro depone per amiloidosi cardiaca. La scintigrafia ossea con mTc99-DPD risulta positiva per moderata captazione miocardica (Perugini score 2). Gli esami ematici escludono la presenza di una componente monoclonale e il test genetico risulta negativo per mutazioni del gene TTR, consentendo di porre diagnosi di amiloidosi TTR relata wild type (ATTRwt). Il follow up è caratterizzato da numerosi ricoveri per scompenso e da un progressivo declino della funzione sistolica (FE fino a 25%) con persistenza di classe NYHA III nonostante un'elevata dose di diureti-

ci. Nel 2021 il quadro precipita rapidamente verso lo shock cardiogeno refrattario, con necessità di prolungato supporto inotropo e assistenza meccanica al circolo, fino ad arrivare al trapianto di cuore in urgenza. Il secondo caso riguarda un uomo di 64 anni, diabetico, obeso, che esegue nel 2022 una visita cardiologica per dispnea da sforzo. L'ecocardiogramma mostra una cardiopatia a fenotipo ipertrofico con una FEVSn del 50% e una marcata elevazione delle pressioni di riempimento per cui viene posto il sospetto di amiloidosi cardiaca. La scintigrafia con mTc99-DPD mostra un Perugini score di 2 e gli esami ematochimici mostrano una significativa elevazione della catene leggere libere k ponendo il dubbio sulla diagnosi differenziale tra forma AL e TTR relata. Soltanto una settimana dopo il paziente ha un arresto cardiaco extraospedaliero. Viene sottoposto prontamente a RCP e Dc-shock su TV monomorfa. Ricoverato, viene esclusa la coesistenza di una malattia coronarica e viene eseguita una biopsia miocardica che permette una diagnosi di certezza di amiloidosi da transtiretina. Il test genetico rivelerà l'assenza di mutazioni nel gene TTR. Il paziente viene sottoposto all'impianto di un ICD in prevenzione secondaria con successivo shock appropriato su una recidiva di TV. Viene introdotto sotalolo e intrapresa terapia specifica con Tafamidis 61 mg/die. A un anno di distanza, non si sono registrati ulteriori eventi clinici di rilievo. L'ATTRwt rappresenta la forma di amiloidosi più frequente, rispetto alla più rara forma ereditaria e all'amiloidosi AL, la seconda per frequenza, associata a patologie ematologiche. L'ATTRwt ha una prevalenza che cresce enormemente con l'età e un decorso lento, con una prognosi in genere migliore rispetto alla forma AL. Fattori come i livelli di peptidi natriuretici e il GFR ci aiutano nella stratificazione prognostica. La storia naturale sta cambiando grazie all'avvento delle terapie disease-modifying. Eppure, a dispetto della precedente definizione di "forma senile" e in contrasto con quanto detto, i casi clinici riportati riguardano due pazienti giovani che vanno incontro ad eventi drammatici precocemente nella loro storia clinica. Se infatti il primo caso ha un decorso di pochi anni prima dello scompenso refrattario che culmina con un trapianto cardiaco, il secondo caso si caratterizza per l'insorgenza di un evento aritmico potenzialmente fatale pochi mesi dopo l'esordio di malattia. È plausibile che un fenotipo clinicamente manifesto in giovane età (<65 anni) sia espressione di una maggiore severità del processo amiloidogenico e che il rischio di una evoluzione sfavorevole sia più alto. Questo dato giustificherebbe uno sforzo ancora maggiore nel cercare di ottenere una diagnosi e un trattamento specifico precocemente nei giovani, nonché una maggiore attenzione nell'impostazione del follow up di questi pazienti.

A828: ISOLATED PREMATURE VENTRICULAR COMPLEXES ABLATION IN TITIN CARDIOMYOPATHY

Stefano Sforna (a), Francesco Notaristefano (b), Gianluca Zingarini (b), Matteo D´ammando (b), Andrea Cardona (c), Giuliana Bardelli (a), Claudio Cavallini (b)
(a) CARDIOLOGY AND CARDIOVASCULAR PATHOPHYSIOLOGY, SANTA MARIA DELLA MISERICORDIA HOSPITAL, UNIVERSITY OF PERUGIA, ITALY; (b) DEPARTMENT OF CARDIOLOGY, SANTA MARIA DELLA MISERICORDIA HOSPITAL, PERUGIA, ITALY; (c) DIVISION OF ADVANCED CARDIOVASCULAR DIAGNOSTICS, REGIONAL HEALTHCARE UNIT, MEDIA VALLE DEL TEVERE HOSPITAL, TODI, ITALY

Introduction. Titin gene truncating variants (TTNtv) are a leading cause of dilated cardiomyopathy (DCM) and have been associated with increased risk of ventricular arrhythmias, especially in patients with severe left ventricular systolic dysfunction (LVSD). Whereas it has been demonstrated that outcomes of ventricular tachycardia (VT) catheter ablation are poor, the efficacy of isolated premature ventricular complexes (PVC) ablation is still unknown.

Case report. A 62-year-old male patient, with TTNtv induced DCM, moderate LVSD and frequent isolated monomorphic PVCs (35% burden) was admitted to our electrophysiology lab for transcatheter ablation. Cardiac magnetic resonance confirmed moderate LVSD and revealed nonischemic myocardial fibrosis of basal interventricular septum (figure 1, arrows). The ECG performed before the procedure (figure 2-A) showed sinus rhythm with ventricular bigeminy and PVCs with left bundle branch block (V3 transition, V2 transition ratio>0.6) and inferior axis morphology, suggesting left ventricular outflow tract (LVOT) origin. The electroanatomic mapping, also guided by intracardiac echocardiography, confirmed LVOT origin, so we performed radiofrequency ablation (figure 3) with complete disappearance of PVCs (figure 2-B). At short-term follow-up, 72-hours ECG-Holter confirmed PVCs disappearance and echocardiography showed initial reduction in LV volumes and increase in LV systolic function.

Discussion. Enriquez et al. in 2021 demonstrated modest outcomes of catheter ablation with high recurrence rate in patients with TTNtv and VT, but patients with isolated PVCs without documented or inducible VT were excluded. Our patient got benefit in terms of symptoms, arrhythmic burden and reverse cardiac remodeling at short-term follow-up, maybe due to early stage disease, suggesting the importance of prompt diagnosis and therapy to avoid the vicious cycle between arrhythmias, cardiac remodeling and fibrosis.

Conclusions. We reported a case of successful catheter ablation of isolated monomorphic PVCs in a patient with titin cardiomyopathy; short-term follow-up showed good results but these observations need confirmation with long-term follow-up and larger studies.

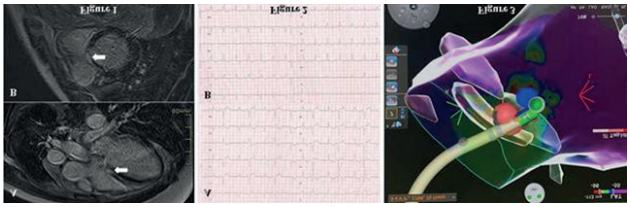

A829: CANCER TREATMENT-RELATED COMPLICATIONS IN PATIENTS WITH HYPERTROPHIC CARDIOMYOPATHY

Mattia Zampieri (a), Stephan A.c. Schoonvelde (b), Michele Vinci (a), Icro Meattini (a), Luca Visani (a), Alessandra Fornaro (a), Raffale Coppini (a), Andrea Romei (a), Alberto Marchi (a), Ilaria Morelli (a), Marjon Van Slegtenhorst (b), Eszter Dalma Palinkas (a), Lorenzo Livi (a), Michelle Michels (b), Iacopo Olivotto (a)
(a) AZIENDA OSPEDALIERA UNIVERSITARIA CAREGGI, FIRENZE; (b) UNIVERISTY MEDICAL CENTER ROTTERDAM, THE NETHERLANDS

Cardiotoxicity relates to direct effects of cancer-related treatment on heart function, commonly presenting as left ventricular contractile dysfunction. However, limited data are available regarding cardiotoxic effects on hypertrophic cardiomyopathy (HCM) since most studies have not specifically analyzed the effects of oncological treatment in HCM populations. This gap in knowledge may lead to unjustified restriction of HCM patients to curative cancer treatments. We aimed to describe the potential clinical cardiotoxicity of oncological treatments in a cohort of consecutive HCM patients, systematically followed up at two national referral centres for HCM.

Methods. We retrospectively analyzed clinical and instrumental data of all consecutive HCM patients who underwent oncological treatment between January 2000 and December 2020, collected in a centralized database.

Results. Of 3256 HCM patients,121 (3.7%) had cancer; 110 (90.9%) patients underwent oncological surgery, 45 (37.2%) chemotherapy, and 22 (18.2%) chest radiation therapy (cRT). After a median follow-up of 5.2 years (IQR 2-13) from oncological diagnosis 32 patients died, the cumulative survival at 5 years was 79.9%. The cause of death was mainly attributed to the oncological condition, while four patients died of sudden cardiac death without receiving previous chemotherapy or cRT. No patient interrupted or reduced the dose of oncological treatment due to cardiac dysfunction. No sustained ventricular tachyarrhythmia was induced by chemotherapy or radiation therapy.

Conclusions. Cancer treatment was well tolerated in HCM patients. In our consecutive series, none died of cardiovascular complications induced by chemotherapy or cRT, or required interruption or substantial treatment tapering due to cardiovascular toxic effects. Although a multidisciplinary evaluation is necessary and regimens must be tailored individually, the diagnosis of HCM per se should not be considered a contraindication to receive optimal curative cancer treatment.

A830: GAUCHER DISEASE: A RARE CAUSE OF HYPERTROPHIC CARDIOMYOPATHY

Stefano Annoscia (a), Ester Maria Lucia Bevere (a), Rossella De Luca (a), Michele Correale (a), Massimo Iacoviello (a), Natale Daniele Brunetti (a)
(a) DEPARTMENT OF MEDICAL AND SURGICAL SCIENCES, UNIVERSITY OF FOGGIA, FOGGIA, ITALY

Introduction. Gaucher's disease is an autosomal recessive inherited condition caused by a deficiency in the activity of the enzyme glucocerebrosidase, resulting in a progressive accumulation of complex lipids such as glucosylceramide in organs like the liver, spleen, and bone marrow. Less than 1% of affected patients may present with heart damage, particularly with early and progressive calcification of the mitral and aortic valve apparatus; cases of cardiomyopathy linked to Gaucher's disease are extremely rare in the literature.

Clinical case. A 37-year-old man with a medical history of grade 2 arterial hypertension, hypercholesterolemia, previous smoking habit, minor talassemia, was admitted to our outpatients clinic, following the echocardiographic finding of hypertrophic cardyomyopathy with left ventricular outflow obstruction. He complained of dyspnea (NYHA functional class II) and denied syncope, lipotimia, and family history of sudden death. Electrocardiogram (ECG) showed signs of left atrial enlargement, marked left ventricular hypertrophy with deep T wave inversions on the left precordial leads and Q-waves in V3-V6. The echocardiogram confirmed left atrial enlargement and severe left ventricular (LV) hypertrophy (19 mm), with increased of LV mass index (LVMI (293.75 g/m2)) and a mild worsening of the LV outflow tract obstruction (PG max from 40 mmHg to 55 mmHg), with systolic anterior motion of the mitral valve and mild-moderate eccentric mitral regurgitation directed towards the lateral wall of the left atrium. The echocardiogram showed mild aortic and mitral annular calcification. LV ejection fraction was preserved (60%) but the diastolic function was compromised and characterized by a diastolic dysfunction of grade II. The following tests were normal: Serum protein electrophoresis, urine immunofixation, serum free light

chain assay, kappa lambda ratio, and a 99Technetium pyrophosphate (99mTc-PYP) planar scintigraphy. The dried blood spot testing identified a heterozygous pathogenic variant in GBA gene which is involved in Gaucher disease. The patient denied ever having had bone pain, bone fractures, abdominal pain, bleeding, bruising, growth problems. Other examinations excluded alterations in blood counts and liver function.
Conclusions. In the literature, reported cases of cardiomyopathies due to Gaucher's disease are rare, but this condition can unfavorably impact the prognosis of patients affected by this condition. It is important for the future to early identify asymptomatic patients with Gaucher's disease and concurrent cardiac involvement to ensure them a better therapeutic management.

A831: AMNESIA GLOBALE TRANSITORIA: UNA RARA PRESENTAZIONE DI MID-VENTRICULAR TAKOTSUBO CARDIOMYOPATHY

Leonardo Borsi (b), Francesco Di Spigno (a), Andrea Biagi (a), Guido Rusticali (a), Piergiorgio Turchio (a), Andrea Tedeschi (a), Daniela Aschieri (a)
(a) OSPEDALE GUGLIELMO DA SALICETO; (b) AZIENDA OSPEDALIERO-UNIVERSITARIA DI PARMA

L'amnesia globale transitoria (TGA) è una sindrome clinica caratterizzata da improvvisa manifestazione di amnesia anterograda e perseverazione nella ripetizione delle stesse domande, della durata fino a 24 ore con la completa risoluzione del quadro e senza coinvolgere altre funzioni neurologiche. Vari case report riportano che differenti manifestazioni di disfunzione cardiaca possono presentarsi correlate ad AGT, anche se ad oggi nessuno studio ha valutato sistematicamente questa associazione. Sono stati proposti differenti meccanismi fisiopatologici per spiegare questo fenomeno, con particolare enfasi del ruolo del sistema nervoso centrale e dell'iperattività del sistema nervoso simpatico, parimenti ai modelli teorici alla base della Sindrome di Takotsubo (TTS). Riportiamo un raro caso di un uomo presentante quadro di mid-ventricular Takotsubo cardiomyopathy concomitante ad episodio di amnesia globale transitoria.

A832: CARDIOMIOPATIA DILATATIVA ATRIALE ASSOCIATA A MUTAZIONE DEL GENE NPPA: UN CASO CLINICO VERAMENTE RARO

Marco Dicorato (a), Maria Cristina Carella (a), Paolo Basile (a), Rosanna Bagnulo (b), Matteo Iacoviello (b), Vincenzo Ezio Santobuono (a), Andrea Igoren Guaricci (a), Nicoletta Resta (b), Marco Matteo Ciccone (a), Cinzia Forleo (a)
(a) CARDIOVASCULAR DISEASE SECTION, INTERDISCIPLINARY DEPARTMENT OF MEDICINE (DIM), UNIVERSITY OF BARI ALDO MORO, UNIVERSITY HOSPITAL CONSORTIUM POLYCLINIC OF BARI, BARI; (b) MEDICAL GENETICS UNIT, DEPARTMENT OF PRECISION AND REGENERATIVE MEDICINE AND IONIAN AREA (DIMEPRE-J), UNIVERSITY OF BARI ALDO MORO, UNIVERSITY HOSPITAL CONSORTIUM POLYCLINIC OF BARI, BARI

Presentazione del caso clinico. Una paziente di 31 anni, fumatrice, accedeva presso il Pronto Soccorso per dolori addominali e veniva ricoverata in reparto internistico. L'ECG all'ingresso mostrava fibrillazione atriale (FA) con onde f di basso voltaggio, un reperto insolito in pazienti giovani. All'ecocardiogramma transtoracico veniva riscontrata modesta dilatazione biatriale, insufficienza mitralica e tricuspidale di grado lieve, funzione biventricolare preservata (FEVS: 60%); l'ECG dinamico delle 24 ore secondo Holter evidenziava FA con sporadici e lunghi periodi di ritmo giunzionale con frequenza ventricolare media compresa tra 40 e 60 bpm. Pertanto, la paziente veniva sottoposta a test da sforzo, che risultò negativo per ischemia miocardica inducibile e per aritmie ipercinetiche ventricolari, e a risonanza magnetica cardiaca, che non identificava alcuna alterazione morfologica e nelle sequenze di late-enhancement riconducibile a cardiomiopatia. Discusso il caso in Heart Team, fu eseguito uno studio elettrofisiologico (SEF) con evidenza di ritmo atriale settale, assenza di attività elettrica ed ineccitabilità della parete libera dell'atrio destro (AD) e blocco atrioventricolare di I grado sopra-hissiano. Nonostante questi risultati, la paziente ha iniziato a lamentare sintomi cardiologici solo due anni dopo: dispnea durante sforzi di lieve intensità, vertigini soggettive e dolore toracico. È stato eseguito un nuovo SEF con evidenza di paralisi atriale ed ineccitabilità della parete e dell'auricola dell'AD associate a ritmo giunzionale. Pertanto, si è deciso di impiantare un pacemaker (PM) permanente a stimolazione hissiana ed è stata avviata la terapia con anticoagulante orale. Durante il follow-up, la paziente presentava peggioramento della dispnea e sporadici episodi di cardiopalmo associato a dolore toracico; la FEVS si manteneva nei limiti di normalità. Il PM registrava una tachicardia ventricolare non sostenuta di 5 battiti. Si intraprendeva, quindi, terapia farmacologica con diuretico dell'ansa, betabloccante, antagonista del recettore dei mineralcorticoidi e bloccante del recettore dell'angiotensina con alleviamento dei sintomi. All'età di 48 anni, la paziente si è sottoposta a prelievi ematici per l'analisi molecolare di 128 geni responsabili di aritmie e cardiomiopatie. È stata così identificata la variante patogenetica p.Arg150Gln (c.449G>A) in omozigosi nell'esone 2 del gene NPPA. La paziente esegue visite cardiologiche periodiche. L'ultimo ecocardiogramma mostrava entrambi gli atri severamente dilatati con ventricoli normali (FEVS 55%).

Discussione e Conclusioni. La cardiomiopatia dilatativa atriale (CMDA) con evoluzione in paralisi atriale è una rara condizione aritmogena, idiopatica (sporadica o familiare) o secondaria, che causa assenza di attività elettrica e meccanica negli atri, esponendo il paziente a un significativo rischio tromboembolico. L'ECG si caratterizza per assenza di onde P e ritmo di scappamento giunzionale. Disertori e Coll. per primi hanno identificato la mutazione c.449G>A (p.Arg150Gln) in una popolazione di 13 pazienti. La CMDA porta a dilatazione biatriale fino alla condizione di atri giganti, aritmie sopraventricolari con perdita progressiva dell'attività elettrica atriale, mentre la funzione biventricolare permane conservata nel tempo. Con il progredire dell'ingrandimento atriale, l'insufficienza valvolare peggiora; i pazienti richiedono l'impianto di PM e terapia anticoagulante cronica. Secondo le più recenti conoscenze, abbiamo descritto il quattordicesimo caso nel mondo di questa rarissima CMDA.

A833: ARRHYTHMOGENIC CARDIOMYOPATHY: DOES THE "RIGHT" VARIANT STILL EXIST?

Annagrazia Cecere (a), Alessandro Sportiello (a), Domenico Corrado (a), Alessandro Zorzi (a), Alberto Cipriani (a), Riccardo Bariani (a), Ilaria Rigato (a), Kalliopi Pilichou (b), Stefania Rizzo (b), Gaetano Thiene (b), Giulia Lorenzoni (c), Dario Gregori (c), Raffaella Motta (d), Giorgio De Conti (d), Cristina Basso (b), Sabino Iliceto (a), Martina Perazzolo Marra (a), Barbara Bauce (a)
(a) CARDIOLOGY UNIT; DEPARTMENT OF CARDIAC, THORACIC, VASCULAR SCIENCES AND PUBLIC HEALTH, UNIVERSITY OF PADUA, PADUA, ITALY; (b) CARDIOVASCULAR PATHOLOGY UNIT; DEPARTMENT OF CARDIAC, THORACIC, VASCULAR SCIENCES AND PUBLIC HEALTH, UNIVERSITY OF PADUA, PADUA, ITALY; (c) UNIT OF BIOSTATISTICS, EPIDEMIOLOGY AND PUBLIC HEALTH; DEPARTMENT OF CARDIAC, THORACIC, VASCULAR SCIENCES AND PUBLIC HEALTH, UNIVERSITY OF PADUA, PADUA, ITALY; (d) RADIOLOGY UNIT; UNIVERSITY OF PADUA - AZIENDA OSPEDALIERA, PADUA, ITALY

Background. The newly introduced Padua Criteria defined the presence of three phenotypic variants of arrhythmogenic cardiomyopathy (AC): the biventricular disease, the left-dominant variant and the right ventricular arrhythmogenic cardiomyopathy (ARVC). The incidence of the three variants, as well as their prognostic impact, are not yet known.
Purpose. The primary end-point of the study was to evaluate, after the introduction of the Padua Criteria, the incidence of these three phenotypic variants in patients with a previous diagnosis of ARVC. The secondary end-point aimed to evaluate the clinical follow-up of these patients.
Methods. 160 patients (104 males, median age: 36 years) with a previous diagnosis of ARVC were included in the study. Based on the Padua Criteria, the patients were further reclassified in: biventricular disease, left and right-dominant disease.
Results. 114 patients (73 males; median age: 40 years) had biventricular disease, 20 pts (12 males; median age: 28 years) had left-dominant phenotype and 26 patients (19 males; median age: 36 years) had an isolated ARVC. Patients with biventricular disease presented a more reduced biventricular systolic function when compared with those with only right or left ventricular involvement (respectively, 47% versus 50% for the right systolic function and 56% versus 60% for the left one, both $p<0.001$). Conversely, patients with only right or left-dominant phenotype had more dilated ventricle (respectively, 114 ml/mq vs 107 ml/mq for the right ventricle, $p<0.001$ and 96 ml/mq vs 90 ml/mq for the left one, $p<0.0043$) and presented more often myocardial fibrosis (respectively, 65% versus 57% in the right ventricle and 100% vs 82% in the left one, both $p<0.001$) than patients with biventricular involvement. At clinical follow-up (median 82 months), patients with biventricular phenotype presented heart failure (n=5), cardiac transplant (n=4), cardiac death (n=1), unexplained syncope (n=1), resuscitated sudden death (n=2), appropriate ICD shock (n=6). Conversely, one patient with ARVC presented a resuscitated cardiac death; 2 patients with left dominant phenotype presented events at follow-up: heart failure (n=1) and appropriate ICD shock (n=1).
Conclusions. AC is a unique entity with different phenotypic variants. The Padua Criteria allowed a critical reclassification of patients with a previous diagnosis of ARVC. The biventricular disease seems to be related to a worse clinical course of the disease.

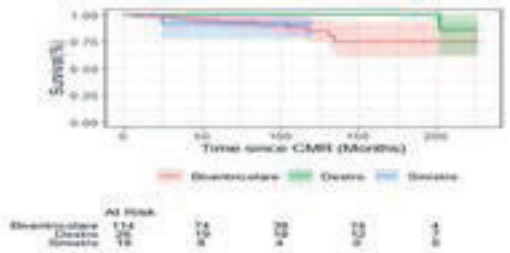

Figure 1. Kaplan-Meier survival curve in patients with the different phenotypes of arrhythmogenic cardiomyopathy.

A834: MOVING TOWARDS TRIGGER FACTORS OF DILATED CARDIOMYOPATHY: LESSONS FROM A CLINICAL CASE OF ADVANCED HEART FAILURE

Camilla Cirelli (a), Paola Ferrari (b), Mauro Gori (b), Anna Merlo (a), Alice Calabrese (b), Giovanni Quarta (b), Andrea Giammarresi (b), Attilio Iacovoni (b), Paolo De Filippo (b), Michele Senni (b), Annamaria Iorio (b)

(a) UNIVERSITY OF MILANO-BICOCCA; (b) ASST PAPA GIOVANNI XXIII, BERGAMO

Case description. In June 2022, a 37-year-old man was admitted to the emergency department with a clinical scenario of cardiogenic shock requiring high doses of vasopressors, intra-aortic balloon pump placement, and endotracheal intubation. The admission electrocardiogram (ECG) showed a regular narrow complex tachycardia with a heart rate of 110 beats/min. Transthoracic echocardiography demonstrated a left ventricular ejection fraction (LVEF) of 10% with global hypokinesia and severe left ventricular (LV) dilatation (Fig 1, Table 1). Coronarography showed normal coronary arteries. Since hemodynamic deterioration, the patient was then transferred to our tertiary center for advanced heart failure (HF) therapies. To better characterize the etiology of his cardiomyopathy, laboratory investigations of disease-specific diagnosis were performed, resulting in unremarkable. Considering the hemodynamic instability without a definite cause, endomyocardial biopsy was performed, but it did not provide any further information. On haemodynamic stabilization, he underwent cardiac magnetic resonance (CMR) confirming no evidence of myocarditis or infiltrative pathology. Notably, despite severe LV dilatation and severely reduced LVEF, there was only minimal septal intramyocardial late gadolinium enhancement along with normal LV wall thickness and atrial volumes. When he was more awake and alert, he reported no history of alcohol abuse and hypertension. Otherwise, family history of idiopathic dilated cardiomyopathy (father with diagnosis of HF and non-ischemic heart disease) emerged and 3-generation family pedigree revealed cardiac disease in three relatives. In respect to his family history, genetic testing was performed using Next Generation Sequencing method, but no mutations-related to cardiomyopathy were detected. In the next few days, he was unable to be weaned off the inotropic agent. At this point, he received a diagnosis of familial DCM and he was discussed in the Heart team for consideration of advanced HF options. Over the clinical course in ICU, he presented a persistent high rate which was attributed to unstable hemodynamic status (90-110 bpm). However, we noticed episodes of high-rate atrial tachycardia (120 bpm). Re-analysis of ECGs suggested an ectopic atrial origin of tachycardia (Fig 2). On the next days, the patient continued to be hemodynamically unstable with persistence of episodes of the arrhythmia, despite inotropic and antiarrhythmic support. Thus, radiofrequency catheter ablation was performed. Over the next 48 h, the patient was weaned from inotropic support. At 3 weeks of medical treatment, the patient was discharged without congestion along with improvement of biventricular function (Fig 1, Table 1), receiving a diagnosis of familiar DCM triggered by sustained supraventricular arrhythmia. At three months of follow-up, he presented sinus rhythm, no recurrence of arrhythmia and cardiac recovery (LVEF 45%, FAC 41%). On medical HF treatment, repeat CMR at 1-year showed normal biventricular function.
Conclusions. In approaching non-ischemic HF, secondary factors need to be ruled out, even when presenting with cardiogenic shock and underlying familial DCM.



Figure 1, Table 1.

Figure 2.

A835: RUOLO DELLA BIOPSIA MIOCARDICA NEI CARRIER ASINTOMATICI DI MUTAZIONE DELLA TRANSTIRETINA: UN CASE REPORT

Jacopo Costantino (a), Giulia Marchionni (a), Federico Ballatore (a), Antonio Lattanzio (a), Maria Alfarano (a), Andrea Frustaci (b), Carmine Dario Vizza (a), Cristina Chimenti (a)

(a) DIPARTIMENTO DI SCIENZE CLINICHE INTERNISTICHE, ANESTESIOLOGICHE E CARDIOVASCOLARI, LA SAPIENZA ROMA; (b) LABORATORIO DI BIOLOGIA CELLULARE E MOLECOLARE, IRCCS SPALLANZANI ROMA.

Introduzione. L'amiloidosi cardiaca da trastiretina (ATTR-CM) è una patologia cardiaca progressiva causata dalla deposizione extracellulare di fibrille amiloidi di transtiretina (TTR) misfolded. Esistono due forme, una wild-type (ATTRwt) e una ereditaria (ATTRv), con trasmissione autosomica dominante, nota per avere un'insorgenza più precoce, un maggiore coinvolgimento neurologico ed una prognosi peggiore. L'introduzione delle nuove terapie specifiche ha permesso di bloccare la progressione della malattia. Il successo di queste terapie è legato prevalentemente alla precocità del trattamento. Per questo motivo la diagnosi precoce rappresenta un obiettivo fondamentale. Ad oggi le metodiche utilizzate comunemente nella pratica clinica non sempre permettono nei carriers asintomatici la corretta definizione del timing di inizio della malattia e di conseguenza una gestione ottimale di questi pazienti.
Case report. Un uomo di 56 anni si presentava alla nostra attenzione per riscontro di una mutazione di significato patogenetico del gene codificante la TTR (Ile68Leu). Il test genetico era stato eseguito a seguito della diagnosi di ATTRv in un familiare di I grado (fratello di anni 58, con insorgenza dei sintomi a circa 55 anni). In anamnesi riportava storia di tunnel carpale bilaterale confermato dall'elettroneurografia e dito a scatto, senza segni di coinvolgimento neurologico. Gli esami ematochimici mostravano normali livelli di NT-proBNP e TroponinaThs (74 pg/mL e 0.005 mcg/L, rispettivamente). L'ECG mostrava ritmo sinusale condotto a 60 bpm con normale conduzione AV e IV, normali voltaggi e assenza di alterazioni della ripolarizzazione ventricolare. L'ecocardiogramma e la risonanza magnetica cardiaca erano normali e in particolare non mostravano segni suggestivi di amiloidosi cardiaca. La tomoscintigrafia miocardica con traccianti ossei eseguita a completamento diagnostico non evidenziava iperfissazione partologica in sede cardiaca (Perugini score 0). In considerazione della età simile di insorgenza della malattia nel fratello affetto (predicted time of disease onset, PADO) e della presenza di tunnel carpale, che tipicamente precede di alcuni anni il manifestarsi di amiloidosi cardiaca, previo consenso informato, in paziente è stato sottoposto a biopsia endomiocardica presso il nostro Istituto Inaspettatamente l'analisi istologica e immunoistochimica ha rivelato la presenza di iniziali depositi di amiloidosi da transtiretina. In seguito alla diagnosi di amiloidosi cardiaca ATTRv in fase iniziale in assenza di neuropatia, il paziente è stato sottoposto a terapia con Tafamidis e a due anni di follow-up non ha manifestato progressione della malattia cardiaca o neurologica.
Conclusioni. L'esperienza di questo caso sottolinea come le metodiche più utilizzate per la valutazione dei carriers di ATTRv non permettano sempre un'efficace valutazione del coinvolgimento cardiaco, ormai ampiamente riconosciuto come il fattore prognostico con maggior impatto sulla sopravvivenza nella ATTR-CM. Nei carriers di mutazioni che raggiungono l'età del PADO, la biopsia endomiocardica potrebbe essere considerata una opzione per l'identificazione di un coinvolgimento cardiaco subclinico iniziando precocemente la terapia e migliorando la qualità di vita e la prospettiva di sopravvivenza a lungo termine.

A836: PERICARDITE RICORRENTE E R202Q: UNA VARIANTE DI NON COSÌ INCERTO SIGNIFICATO

Federica Currò Dossi (a, b), Alessandro Andreis (a, b), Massimo Imazio (c, d), Gaetano Maria De Ferrari (a, b)

(a) DIVISIONE DI CARDIOLOGIA, DIPARTIMENTO CARDIOVASCOLARE E TORACICO, OSPEDALE "CITTÀ DELLA SALUTE E DELLA SCIENZA", TORINO, ITALIA; (b) DIPARTIMENTO DI MEDICINA, UNIVERSITÀ DI TORINO, TORINO, ITALIA; (c) DIPARTIMENTO CARDIOVASCOLARE, OSPEDALE UNIVERSITARIO "SANTA MARIA DELLA MISERICORDIA", ASUFC; (d) DIPARTIMENTO DI MEDICINA, UNIVERSITÀ DEGLI STUDI, UDINE

Introduzione. La pericardite ricorrente in rari casi può essere la prima, nonché unica, manifestazione di Febbre Mediterranea Familiare, una patologia genetica su base autoimmune a carattere autosomico recessivo. Ad oggi sono stati identificati più di 390 polimorfisimi o mutazioni del gene MEFV ad essa associato (cromosoma 16 p13.3), che codifica per la Pirina la quale svolge una funzione regolatrice nella risposta immunitaria innata. Diverse varianti di MEFV si associano a una pletora di presentazioni cliniche, dalla forma asintomatica ad altre caratterizzate da complicanze multi-organo.
Caso: Donna di 31 anni affetta da pericardite ricorrente idiopatica, esordita con dolore pericarditico, febbricola e poli-sierosite con versamento peritoneale, pleurico e pericardico determinante tamponamento cardiaco, con necessità di pericardiocentesi. I pannelli sierologici e autoimmune (LAC, B2GPI, ANA, ENA, ANCA, FR, C3, C4, HLA B51 e B27) e quelli microbiologici su liquido pericardico sono risultati negativi. Stante la pregressa diagnosi di adenocarcinoma cervicale HPV-relato, il work-up diagnostico iniziale è stato completato con esame citologico su liquido pericardico e Tc torace-addome con mezzo di contrasto, che escludevano l'eziologia neoplastica. Agli esami ematochimici è stata evidenziata leucocitosi neutrofila e incremento della proteina C reattiva. Per tali caratteristiche è stata avviata terapia medica con FANS e colchicina, con iniziale beneficio. Il follow-up ambulatoriale è stato caratterizzato nei mesi successivi da plurime recidive di pericardite e necessità di associare corticosteroidi a dosaggio <0.5 mg/kg, tuttavia con frequente ricorrenza dei sintomi in corso di tapering. L'ecocardiogramma mostrava una normale funzione sisto-diastolica biventricolare in assenza di valvulopatie di rilievo, assenza di versamento pericardico o segni di costrizione. È stata eseguita una RM cardiaca che mostrava assenza di cardiopatia strutturale, lieve iperintensità di segnale a livello pericardico nelle sequenze T2 con associato LGE. Sulla base delle caratteristiche cliniche è stato avviato trattamento con anti IL-1 anakinra (100 mg die sottocute), con completa risoluzione dei sintomi e sospensione dei corticosteroidi. Al momento, a distanza di più di 5 anni dal primo episodio, la paziente è in trattamento stabile con buon controllo dei sintomi con anakinra 50 mg a giorni alterni, associata a colchicina 0,5 mg al giorno. L'analisi genetica è risultata negativa per mutazioni a noto significato patologico di MEFV, mostrando tuttavia la presenza della variante R202Q (c605G>A,

pArg202GIn) in omozigosi, attualmente classificata come "variante di significato incerto" (VUS).
Conclusioni. Il nostro caso suggerisce come R202Q potrebbe essere considerata come una variante del gene MEFV patologica e associata a pericardite ricorrente. In questi pazienti può essere considerata una terapia a lungo termine con farmaci anti IL-1, al dosaggio minimo necessario a controllare l'infiammazione. Nei pazienti con pericardite ricorrente refrattaria al trattamento con corticosteroidi, è importante eseguire l'analisi genetica come parte di un work-up diagnostico completo.

A837: FIBROSI VENTRICOLARE DESTRA: NON SOLO CARDIOMIOPATIA ARITMOGENA

Valeria Dall Ospedale (b), Francesco Di Spigno (a), Benedetta Matrone (a), Paola Novara (a), Andrea Tedeschi (a), Daniela Aschieri (a)
(a) U.O.C. CARDIOLOGIA, OSPEDALE GUGLIELMO DA SALICETO, PIACENZA; (b) U.O.C. DI CARDIOLOGIA, AZIENDA OSPEDALIERO-UNIVERSITARIA DI PARMA, PARMA

Introduzione. La cardiomiopatia aritmogena (AC) è una rara malattia genetica che comporta una progressiva sostituzione fibro-adiposa del miocardio. La progressione della malattia è caratterizzata da episodi di dolore toracico, alterazioni ECG e rilascio troponinico conosciuti come "hot-phase". Per la diagnosi della AC sono stati proposti specifici criteri diagnostici, noti come "Criteri di Padova". Le miocarditi sono invece episodi di infiammazione miocardica che comprendono una vasta gamma di presentazioni cliniche e che spesso lasciano cicatrici fibrotiche come conseguenza della riposta immunitaria. Il coinvolgimento del ventricolo destro è raro e si associa a cattiva prognosi. La fibrosi ventricolare dovuta a miocarditi è caratterizzata da una distribuzione a chiazze, la cui estensione dipende dalla gravità dell'insulto infiammatorio. D'altro canto, l'infiltrazione adiposa dell'AC spesso coesiste con aree di fibrosi che coinvolgono tipicamente le regioni subepicardiche e intramiocardiche del ventricolo destro e che talvolta si possono estendere anche al ventricolo sinistro. Questo caso clinico evidenza le difficoltà diagnostiche incontrate nell'indagare l'eziologia di una fibrosi ventricolare destra evidenzia alla risonanza magnetica cardiaca.
Caso clinico. Una donna di 48 anni giungeva a visita cardiologica per dolore toracico atipico e palpitazioni. In anamnesi la paziente riferiva 15 anni prima un ricovero per shock cardiogeno destro; negava famigliarità per AC o morte cardiaca improvvisa. L'ECG a 12 derivazioni mostrava ritmo sinusale con onde T negativa in V1-V3 mentre l'ecocardiografia era nei limiti di norma. È stata eseguita una risonanza magnetica cardiaca che ha evidenziato un aneurisma di circa 3 cm a livello del tratto d'efflusso del ventricolo destro, le pareti della porzione aneurismatica si presentavano fibrotiche ed assottigliate (Fig.1). È stata proposta l'indagine genetica per cardiomiopatia aritmogena del ventricolo destro che non ha trovato mutazioni compatibili con tale patologia.
Discussione. Secondo i Criteri di Padova, alla presentazione la paziente aveva due criteri maggiori per cardiomiopatia aritmogena; in particolare presentava anomalie strutturali del miocardio (sostituzione fibrosa del miocardio nel tratto di efflusso) e anomalie nella ripolarizzazione dell'ECG (onde T invertite in V1-V3). Tuttavia, l'assenza di aritmie e l'indagine genetica negativa suggeriscono che la diagnosi possa essere alternativa. Secondo gli autori, l'aneurisma nel tratto d'efflusso del ventricolo destro è più probabilmente attribuibile al precedente episodio di miocardite che ad un'AC esordita con hot-phase La storia familiare, i test genetici e il follow-up a lungo termine svolgono un ruolo essenziale nel processo di diagnosi.

Fig.1. Risonanza magnetica cardiaca: le frecce indicano la porzione aneurismatica con pareti fibrotiche ed asottigliate.

A838: IPERTROFIA VENTRICOLARE SINISTRA E WPW: QUANDO LA GENETICA È NEGATIVA, SERVE LA BIOPSIA?

Lorenzo-Lupo Dei (a), Federica Re (b), Irene Bottillo (c), Luigi Sciarra (a), Silvio Romano (a)
(a) CARDIOLOGY, DEPARTMENT OF LIFE, HEALTH AND ENVIROMENTAL SCIENCES, UNIVERSITY OF L'AQUILA, 67100, L'AQUILA ITALY; (b) CARDIOLOGY DEPARTMENT, SAN CAMILLO FORLANINI HOSPITAL, ROME; (c) MEDICAL GENETICS, DEPARTMENT OF MOLECULAR MEDICINE, SAPIENZA UNIVERSITY, SAN CAMILLO-FORLANINI HOSPITAL, ROME, ITALY

Donna, 40 anni. In anamnesi: Storia familiare positiva per WPW, ipertrofia ventricolare e morte improvvisa (padre e zia paterna). Storia di WPW, già sottoposto ad ablazione, ma recidivato. Portatrice di ICD in prevenzione primaria. ECG: ritmo sinusale 55 bpm, PR corto, onda delta, segni di ipertrofia ventricolare massiva con consensuali alterazioni patologiche della ripolarizzazione. Ecocardiogramma: ipertrofia ventricolare marcatissima, diffusa e simmetrica (spessore max SIV 38 mm). Completa occlusione della cavità ventricolare in sistole per meccanismo sfinteriale. Aumento delle pressioni di riempimento, dilatazione biatriale, insufficienza mitralica moderata. Non ostruzione intraventricolare o all'efflusso sinistro a riposo. Non ipertensione polmonare o compromissione destra. Test cardiopolmonare (ultimo di 4 totali in anamnesi): test indicativo di moderata riduzione della tolleranza allo sforzo migliorata dopo il potenziamento della terapia antiscompenso con Forxiga 10 mg. Ridotto global longitudinal strain. Ostruzione provocabile di grado lieve sotto sforzo. RMN: Aree mesocardiche di LGE del Vsx a livello dei segmenti basali e medi delle pareti settale ed inferiore ed a livello giunzionale superiore ed inferiore. Stria mesocardica di LGE a livello della parete laterale basale e media del Vdx. Genetica: Nel corso della storia clinica era già stata studiata geneticamente con pannello classico cardiomiopatie che risultava negativo. A distanza di cinque anni viene studiata nuovamente analizzando l'intero genoma, senza evidenza di mutazione. La paziente è sintomatica per angor e dispnea da sforzo ed attualmente in terapia con: Tareg 80 mg ½ x 2, Cardicor 2,5 mg, Ranexa 750 mg x 2, Luvion 50 mg ½ cp, Forxiga 10 mg, Pantorc 20 mg. Agli esami ematici: NTproBNP 9000 pg/ml. Il quadro ricorda una glicogenosi. Al momento la paziente è in attesa di eseguire biopsia endomiocardica, che verrà eseguita a settembre 2023.

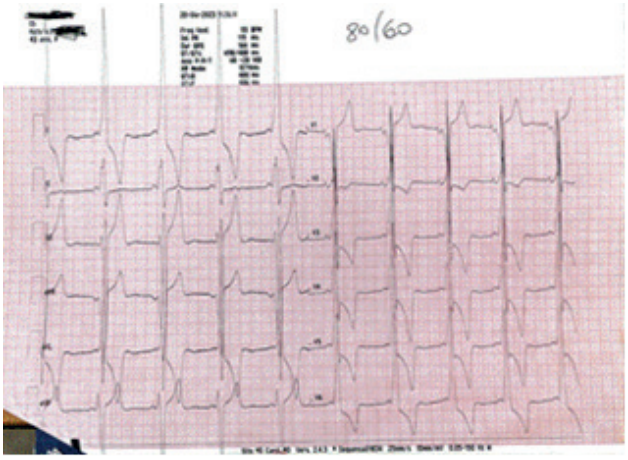

A839: A RARE CASE OF PURULENT PERICARDITIS

Michele Fabrizio (a), Rossella Ruggiero (a), Samuela Carigi (a), Francesco Contorni (a), Filippo Ottani (a)
(a) CARDIOVASCULAR DEPARTMENT, INFERMI HOSPITAL, RIMINI, ITALY

76-year-old patients, with an history of diabetes mellitus complicated by foot ulcer, was admitted to cardiological department for fever and chest pain enhanced by the position. The echocardiographic evaluation revealed a mild pericardial effusion and a dilatation of the ascending aorta (47mm); therefore, an initial Contrast-enhanced CT was performed which excluded an acute aortic syndrome. Due to severe chronic kidney disease, it was decided to initiate a treatment with cortisone and colchicine for the pericarditis. Furthermore, blood cultures were performed and revealed a systemic infection by Staphylococcus Aureus methicillin resistant (MRSA), therefore specific antibiotic therapy was introduced. Due to persistent chest pain with electrocardiographic modifications, coronary angiography was performed, and the patient underwent to stent implantation on a critical ulcerated plaque in the left main. Despite adequate antibiotic therapy, blood culture was persistently positive. Therefore, transesophageal echocardiography was performed, and revealed a periaortic pseudo-aneurism associated to aspect of purulent pericarditis. The subsequent contrast-enhanced CT confirmed the diagnosis. The patient was, then, immediately transferred to the surgical department and underwent to therapeutic pericardiotomy and treatment of the pseudo-aneurism. Unfortunately, he died few days later due to complications of the sepsis. In the post-antibiotics era purulent pericarditis represents a

rare, yet life-threating disease, whose incidence is increasing lately due to the rising of antibiotic resistance. The prompt recognition of this condition is of outmost importance to improve outcomes in these patients.

A840: A STEP BEFORE LOEFFLER ENDOCARDITIS: A CASE REPORT

Lorenzo Frau (a), Andrea Segreti (a), Mariagrazia Piscione (a), Dajana Polito (a), Sara Mastroberardino (a), Francesca Vespasiano (a), Francesco Piccirillo (a), Gian Paolo Ussia (a), Francesco Grigioni (a)
(a) FONDAZIONE POLICLINICO UNIVERSITARIO CAMPUS BIOMEDICO

A 57-year-old woman went to our Emergency Department (ED) for chest pain, cough and fever appeared a few days before. As comorbilities, she suffered from bronchial asthma since she was a child. Because of a right bundle block of new onset and the increase in myocardionecrosis enzymes, it was suggested to undergo to a coronary angiography, which showed coronary arteries free from lesions. The cardiac magnetic resonance (cMR) showed mildly reduced left ventricle ejection fraction (LVEF) with hyper-intensity of the anterolateral wall. A transthoracic echocardiogram demonstrated an important diastolic dysfunction with reduction of the global longitudinal strain (GLS). The high resolution chest tomography (HRCT) demonstrated: diffuse parenchymal thickenings, partly with a ribbon-like morphology and with a ground glass appearance. During hospitalization it was observed a high count of eosinophils both in peripheral blood and in bronchoalveolar lavage (BAL). To conclude, even a healthy person, who has an atopic predisposition, may experience an hypersensitivity reaction to an inhaled antigen and may develop a lung or a cardiac affection. Our patient's symptoms improve on high-dose steroids and she was discharged on a prednisone taper. The CT (chest tomography) and transthoracic echocardiogram showed a general improvement after the treatment. This may be justified with a possible immune- related origin of the pathology so that it may be thought that eosinophilic pneumonia represents the stage before heart infiltration and Loeffler endocarditis presentation.

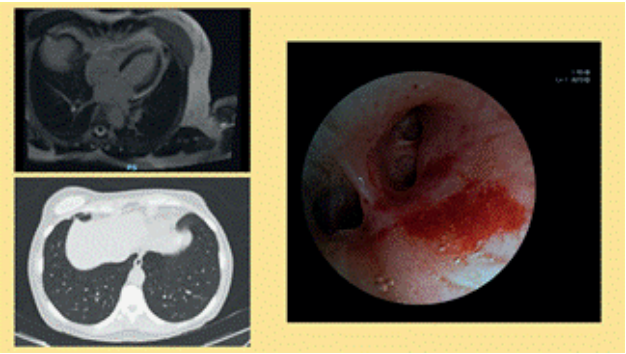

A841: EXTRACELLULAR MATRIX REMODELLING AND INFLAMMATION IN TRANSTHYRETIN AMYLOIDOSIS

Alessia Argirò (a), Giulia Guidotti (b), Martina Berteotti (b), Viola Liberati (b), Mattia Zampieri (a), Federico Perfetto (a), Marco Allinovi (a), Rossella Marcucci (b), Francesco Cappelli (a)
(a) TUSCAN REGIONAL AMYLOIDOSIS CENTER, CAREGGI UNIVERSITY HOSPITAL FLORENCE, ITALY; (b) DEPARTMENTS OF EXPERIMENTAL AND CLINICAL MEDICINE, ATHEROTHROMBOTIC UNIT, CAREGGI UNIVERSITY HOSPITAL, FLORENCE, ITALY

Background. Transthyretin cardiomyopathy (ATTR-CM) is an exemplar interstitial disease, characterized by extracellular deposition of amyloid fibrils. Inflammation and extracellular matrix markers are altered in light chain amyloidosis while little is known in ATTR amyloidosis especially in those with cardiac phenotype or ATTRwt.

Population and Methods. 49 patients with ATTR CM evaluated at Careggi University Hospital underwent clinical evaluation, electrocardiography, echocardiography and laboratory evaluation. The Bio-Plex Suspension Array System was used for the assay of the biohumoral markers under study. The laboratory results obtained have been compared to those of a matched for age and sex cohort of 50 patients with sole atrial fibrillation.

Results. Mean age was 70±5 years and 80% of patients were men. Forty-two (86%) had ATTRwt, 7 (14%) had ATTRv. Patients with ATTR-CM presented higher concentration of inflammatory biomarkers compared to controls, such as IL6 (2.9 (1.6-1.33) vs 1.56 (0.43-3.12), p<0.01), IL8 (17.21 (11.94-34.8) vs 8.54 (5.15-13.3), p<0.01) and VEGF (101.03 (59.05-146.2), p<0.01). The anti-inflammatory interleukin IL-10 was lower compared controls (0.2 (0.1-0.2) vs 2.89 (0.33-3.46), p<0,001). Serum levels of metalloprotease MMP12 (1060 (745-1260) vs 414 (49.73-612), p<0.001), TIMP-1 (177.26 (158-212) vs 157 (129.84-201), p=0.03) and TIMP3 (68.78 (47.88-92.79) vs 36.11 (28.71-55.9), p<0.01) were higher in ATTR-CM compared to controls but with and imbalance towards ECM degradation.

Conclusions. In patients with ATTR-CM the inflammatory biomarkers were increased compared to controls and ECM homeostasis was altered with degradation prevailing over synthesis of ECM.

A842: NON COSÌ RARA, QUASI MAI ISOLATA: UN CASO TIPICO DI ATTR A DIAGNOSI RITARDATA

Raffaele Jiritano (a), Ennio Abramo (a), Davide Demasi (a), Lucio Cascini (c), Ciro Indolfi (b), Francesco Andreozzi (a)
(a) UNIVERSITÀ DEGLI STUDI MAGNA GREACIA-U.O.C. MED. INT.-DIPARTIMENTO SCIENZE MEDICHE E CHIRURGICHE; (b) UNIVERSITÀ DEGLI STUDI MAGNA GRAECIA-U.O. CARDIOLOGIA-DIPARTIMENTO SCIENZE MEDICHE E CHIRURGICHE; (c) UNIVERSITÀ DEGLI STUDI MAGNA GRAECIA-U.O. MEDICINA NUCLEARE-DIPARTIMENTO SCIENZE MEDICHE E CHIRURGICHE

PC, paziente anziano di 84 aa, giunge alla nostra attenzione lamentando cardiopalmo non associato a sforzo insieme ad occasionale astenia non giustificata da età e stile di vita. Il paziente presenta una storia di cardiopatia ischemica cronica sottoposta a rivascolarizzazione nel 2015 per un IMA NSTEMI con stenting di IVA, per cui l'iter iniziale è orientato a escludere una riduzione del flusso coronarico nelle aree a valle della vecchia culprit lesion. L'esame TTE evidenzia effettivamente una ipocinesia diffusa del SIV, parete inferolaterale, anterolaterale come già suggerito da un ecocardiogramma dalla refertazione lacunaria eseguito in altra sede, ma si dimostra altresì un aspetto iperecogeno del setto (riferito in prima istanza a fibrosi), severa ipertrofia del SIV (1,6 cm diastolico al tratto medio), stenoinsufficienza aortica lieve (con ispessimento dei lembi valvolari, ricondotto inizialmente a degenerazione calcifica). L'operatore integra allora con speckle tracking evidenziante pattern di apical sparing. Colloqui mirati con il paziente rivelano elementi di sospetto ulteriore taciuti alla raccolta anamnestica perché da questi ritenuti non pertinenti (riferisce un "ingrandimento delle pareti del cuore" già riferitogli anni prima e non approfondito, stenosi canale cervicale e lombare anche essi riferiti alla naturale senescenza). Si conclude l'iter diagnostico iniziale con miocardioscintigrafia di perfusione che non evidenzia ischemia a riposo o inducibile ed esecuzione di Holter ECG evidenziante FA parossistica per cui si avvia TAO presa visione del CHA_2DS_2-VASc di 5 a fronte di un HASBLED di 2. In ossequio al sospetto diagnostico e persistente uno scompenso cardiaco con disfunzione oramai sistodiastolica a FE 40%, con trascurabili miglioramenti dati dalla terapia medica convenzionale, si eseguivano Freelite, immunofissazione sierica e urinaria (escludenti componenti monoclonali come da amiloidosi AL) e scintigrafia total body, con un quadro come da ATTR Perugini 3. Il paziente veniva poi sottoposto a tampone buccale per la tipizzazione del tipo di ATTR, con esclusione dello stato mutazionale per i geni responsabili più comuni e una diagnosi completa di ATTR-wt.

Discussione. La classica definizione di Amiloidosi come patologia rara porta la diagnosi a essere presa in considerazione, specie in ambito non strettamente cardiologico come quello internistico, soltanto come ultima ratio in pazienti non responsivi a terapie tradizionali per HF; è altresì vero che la cardiologia territoriale ancora spesso si accontenta di un iter diagnostico tradizionale per cui vale l'equazione "aumento spessori parietali-cardiopatia ipertensiva" e "HF con disfunzione diastolica/sistolica-sofferenza su base micro/macrovascolare", ossia i motivi per cui dal territorio il paziente giungeva alla nostra attenzione. È altresì vero che aspettarsi una perfetta aderenza del paziente alla descrizione in letteratura, con la coesistenza di patologia osteomuscolare, neuropatia e disfunzione autonomica può risultare restrittivo e ritardare la diagnosi. Considerata l'effettiva prevalenza dell'ATTR nella popolazione generale, il peso enorme rappresentato sulla salute pubblica dalle altre patologie cardiovascolari, l'invecchiamento della popolazione, nonché l'esistenza delle note red flags valutabili economicamente anche in sede ambulatoriale, occorre sensibilizzare ulteriormente la medicina ambulatoriale e del territorio a non escludere aprioristicamente la patologia e a considerarla possibile in tutti i pazienti compatibili con la diagnosi, al fine di permettere un trattamento efficace.

A843: RENIN ANGIOTENSIN SYSTEM INHIBITOR AND OUTCOME IN PATIENTS WITH TAKOTSUBO SYNDROME: A PROPENSITY SCORE ANALYSIS OF THE GEIST REGISTRY

Francesco Santoro (a), Rosa Cetera (a), Federico Guerra (d), Giuseppina Novo (b), Roberta Montisci (g), Ilaria Ragnatela (a), Enrica Mariano (c), Beatrice Musumeci (f), Natale Daniele Brunetti (a), Luca Arcari (e)

(a) CARDIOLOGY UNIT, DEPARTMENT OF MEDICAL AND SURGERY SCIENCES, UNIVERSITY OF FOGGIA; (b) CARDIOLOGY UNIVT, UNIVERSITY OF PALERMO; (c) CARDIOLOGY UNIT, TORVERGATA UNIVERSITY, ROME; (d) CARDIOLOGY UNITY, MARCHE POLYTECHNIC UNIVERSITY, ANCONA; (e) CARDIOLOGY UNIT, VANNINI HOSPITAL, ROME; (f) CARDIOLOGY UNIT, SAPIENZA UNIVERSITY, ROME; (g) CARDIOLOGY UNIT, UNIVERSITY OF CAGLIARI

Background. Few data are available on long-term drug therapy and its potential prognostic impact after takotsubo syndrome (TTS).

Objectives. To evaluate clinical characteristics and long-term outcome of TTS patients on Renin Angiotensin system inhibitors (RASi).

Methods. TTS patients were enrolled in the international multicenter GEIST (GErman Italian Spanish Takotsubo) registry. Comparison of RASi treated vs. untreated patients was performed within the overall population and after 1:1 propensity score matching for age, sex, comorbidities, type of trigger and in-hospital complications.

Results. Of the 2453 TTS patients discharged alive, 1683 (68%) received RASi therapy. Patients with RASi were older (age 71±11 vs 69±13 years, p=0.01), with higher prevalence of hypertension (74% vs 53%, p<0.01) and diabetes (19% vs 15%, p=0.01), higher admission left ventricular ejection fraction (LVEF) (41±11% vs 39±12%, p<0.01) and lower rates of in-hospital complications (18.9% vs 29.6%, p<0.01). At multivariable analysis, RASi therapy at discharge was independently associated with lower mortality (HR: 0.63, 95%CI 0.45-0.87, p<0.01). Survival analysis showed that at long term, patients treated with RASi had lower mortality rates in the overall (log-rank p=0.001) but not in the matched cohort (log-rank p=0.168). The survival benefit of RASi was higher in patients with admission LVEF ≤40% and diabetes both in the overall (HR: 0.54 95%CI 0.38-0.78, p=0.001; HR:0.41, 95%CI 0.23-0.73, p=0.002) and matched cohort (HR: 0.59, 95%CI 0.37-0.95, p=0.030; HR:0.41, 95%CI 0.21-0.82, p=0.011).

Conclusions. Long-term therapy with RASi after a TTS episode could be associated with lower mortality rates among patients with admission LVEF ≤40% or diabetes.

A844: NEUROMETABOLIC FEATURES OF TAKOTSUBO SYNDROME: A BRAIN 18F-FDG PET CASE CONTROL-PROSPECTIVE STUDY.

Francesco Santoro (a), Pierluigi Selvaggi (a), Rosaria D´apollo (a), Ilaria Ragnatela (a), Rosa Cetera (a), Damiano D'Alessandro (a), Enrica Vitale (a), Adriana Mallardi (a), Sergio Modoni (a), Natale Daniele Brunetti (a)

(a) CARDIOLOGY UNIT, DEPARTMENT OF MEDICAL AND SURGERY SCIENCES, UNIVERSITY OF FOGGIA

Background. Takotsubo syndrome (TTS) is an acute left ventricular systolic dysfunction due to an emotional or physical stressor. Previous studies found that an increased amygdala activity could predispose to develop a TTS episode.

Aim. Is to compare the brain metabolism of TTS patients versus a control group.

Methods. Brain metabolism has been assessed in 20 subjects with TTS and 20 matched control subjects, through 18F-fluorodeoxyglucose positron emission tomography/computed tomography (18F-FDG PET/CT). Amygdala activity, recorded as standardized uptake value ratio (SUVR) of this area and whole brain SUVR voxel-wise analysis between TTS and controls was analyzed.

Results. TTS patients had a mean age of 71 ± 10 years and 90% were female. Patients with TTS showed higher amygdala activity as compared with the control group (0.95±0.04 vs 0.88±0.05, p<0.01; t_{38}=4.59, Cohen's d=1.42). At SUVR voxel-wise analysis, TTS patients when compared to controls had increased activity in the amygdala, hippocampus, para-hippocampal gyrus, temporal gyrus and midbrain. Moreover, TTS patients had a reduction in 18F-FDG uptake in cortical and subcortical regions including frontal, parietal, occipital cortices and thalamus. According to brain 18F-FDG PET/CT timing following TTS episode (<1 year, 1-3 years,>3 years), patients were divided into three groups. No differences over time of amygdala activity was found (p=0.59).

Conclusions. Patients with TTS may show a distinct brain metabolism featured by increased activity of brain regions within the limbic system. Tailored psychological support could be included into long-term TTS management.

A845: CARDIOMIOPATIA ARITMOGENA BIVENTRICOLARE: DIFFERENZE CON INTERESSAMENTO ISOLATO DEL VENTRICOLO DESTRO

Francesco Vilei (a), Renè Tezze (a), Alberto Sarti (a), Martina Vitali (a), Marco Giardino (a), Cristina Balla (a), Michele Malagù (a), Matteo Bertini (a), Elisabetta Tonet (a), Francesco Vitali (a)

(a) CARDIOLOGY UNIT, AZIENDA OSPEDALIERO-UNIVERSITARIA DI FERRARA

Introduzione. La Cardiomiopatia Aritmogena (CMA) è un disturbo del muscolo cardiaco che predispone all'insorgenza di aritmie ventricolari non spiegate da cause secondarie. Le basi strutturali consistono nella progressiva perdita di miocardiociti e sostituzione fibro-adiposa. La patologia è geneticamente determinata, con mutazioni prevalentemente di proteine desmosomiali.

Obiettivi. Valutare le differenze clinico-prognostiche, genetiche, elettrocardiografiche e di imaging tra pazienti con diagnosi di CMA isolata del ventricolo destro (VDx) e biventricolare (BIV).

Metodi.È stata analizzata retrospettivamente una coorte di 55 pazienti con diagnosi confermata di CMA. Tutti i pazienti avevano eseguito una RM, un ETT, un'analisi genetica e un ECG. I pazienti sono stati divisi in due gruppi a seconda dell'interessamento BIV (18 pazienti) o del solo VDx (37 pazienti). Abbiamo confrontato i due gruppi in base a criteri anamnestici (sesso, età, storia familiare di morte cardiaca improvvisa, parenti di I grado con malattia), clinici (sincope cardiogena, arresto cardio-circolatorio, tachicardia ventricolare, utilizzo di farmaci antiaritmici, ablazione di tachicardie atriali e ventricolari, necessità di impianto di ICD, episodi di TV, ICD shock), elettrocardiografici e genetici (tutti i pazienti sono stati sottoposti ad analisi di pannello genico).

Risultati. Circa un terzo dei pazienti aveva un interessamento BIV, mentre i restanti due terzi avevano l'interessamento del solo VDx. Nei pazienti con interessamento del solo Vdx è stata individuata una mutazione patogena nel 62% dei casi; questi pazienti avevano un parente di primo grado affetto da CMA nel 30% dei casi. Nei pazienti con interessamento BIV, invece, è stata identificata una mutazione genetica specifica nel 16% dei casi (p=0,008) con solo l'8% dei casi che aveva un familiare di I grado affetto da CMA (p=0,042). Il numero di aritmie ventricolari al follow-up è stato sovrapponibile tra i due gruppi (circa il 33% in entrambi i gruppi), ma l'assunzione di farmaci antiaritmici era del 66% nei pazienti con interessamento BIV, contro il 38% dei pazienti con interessamento isolato del RV (p=0,044). La FE del VDx e del VSn è risultata essere più bassa in entrambi i casi nei pazienti con interessamento BIV rispetto ai pazienti con solo interessamento del VDx (FE VDx 49%±10 vs 41%±10, p 0,048/FE VSn 46%±8 vs 59%±5, p 0,044).

Conclusioni. La CMA BIV è un'entità ancora poco conosciuta con probabilmente diverso pattern genetico/ereditario. I pazienti con interessamento BIV hanno una genetica positiva e un parente di I grado affetto da CMA solo in una piccola percentuale dei casi, rispetto ai pazienti con interessamento isolato del RV. La percentuale di eventi aritmici tra i due gruppi è sovrapponibile, non trascurando la maggiore assunzione di farmaci antiaritmici da parte dei pazienti con forma BIV che potrebbe sottendere un maggiore rischio aritmico nella forma BIV. L'interessamento BIV è associato a una più bassa FE di entrambi i ventricoli rispetto all'interessamento del solo VDx; questa depressione della funzione sistolica potrebbe essere spiegata da uno stadio più avanzato della stessa patologia di base. Non altre differenze statisticamente significative sono state individuate tra i due gruppi per i restanti parametri.

A846: TRANSTYRETIN CARDIAC AMYLOIDOSIS IN THE ELDERLY PATIENT: ALWAYS A WILD TYPE?

Jacopo Costantino (a), Ballatore Federico (a), Giulia Marchionni (a), Antonio Lattanzio (a), Maria Alfarano (a), Carmine Dario Vizza (a), Cristina Chimenti (a)

(a) DIPARTIMENTO DI SCIENZE CLINICHE, ANESTESIOLOGICHE E CARDIOVASCOLARI, LA SAPIENZA UNIVERSITÀ DI ROMA

Background. Transthyretin amyloidosis (ATTR) exists in two forms: a genetic form transmitted by autosomal dominant inheritance (ATTRv) and a wild type form (ATTRwt). Clinically, the hereditary form tends to have an early onset in adulthood and it is characterized by a particular tropism for nervous as well as cardiac tissue. In contrast, the "wild type" form has a later onset with major cardiac involvement and neurological manifestations usually limited to carpal tunnel syndrome.

Methods and Results. In our centre, from September 2021 to June 2023, 52 patients older than 70 years received a diagnosis of cardiac ATTR (87% male, 13% female, mean age 81±5y). In all patients, blood tests showed a significant and stable increase in the values of troponin Ths (0.079 microg/L±0.074) and NT-proBNP (2000±1800 pg/ml), with the absence of a monoclonal component in the blood and urine, and miocardial bisphosphonate scintigraphy positive grade 2/3. All patients underwent genetic testing by amplification of exons 2,3 and 4 of the TTR gene with subsequent sequencing. Unexpectedly, in 10 elderly (70%male, 30% female, mean age 77±4 y) patients (19%) the genetic test resulted positive with 4 different mutations of pathogenetic significance (Val30Met; Ile68Leu; Val142Ile; Phe84Leu). Three patients showed peripheral neuropathy with the presence of carpal tunnel syndrome, while isolated carpal tunnel syndrome was present in the remaining 7 cases. The three patients with neurologic involvement started Patisiran therapy, and 7 patients were treated with Tafamidis. First-degree relatives (16 consanguineous, average age 49±12 years) agreed to be subjected to genetic screening; of these 9 (3 male and 6 females, age 47±8 years) were positive for the corresponding mutation and underwent echocardiogram, MRI and myocardial scintigraphy. These tests were normal in 8 probands, included in an annual follow-up protocol to identify an early manifestation of the disease, and was diagnostic for amyloidosis in 1 patient who started specific therapy.

Conclusions. Our experience shows that 19% of patients older than 70 years with a diagnosis of cardiac ATTR may be affected by a genetic form. Making genetic diagnosis in this context is particularly important for screening family members: current therapies are in fact much more effective if started early before organ damage occurs.

A847: EXCESSIVE TRABECULATION OF LEFT VENTRICLE IN CHILDREN AND ADULTS: WHAT ARE THE DIFFERENCES?

Lara Luciani (a, b), Vito Maurizio Parato (b, c), Germana Gizzi (c), Umberto Ianni (c), Michela Molisana (c), Simone D'Agostino (c)
(a) CLINICA DI CARDIOLOGIA E ARITMOLOGIA, OSPEDALE UNIVERSITARIO "OSPEDALI RIUNITI", ANCONA, ITALIA; (b) DIPARTIMENTO DI SCIENZE BIOMEDICHE E SANITÀ PUBBLICA, UNIVERSITÀ POLITECNICA DELLE MARCHE, ANCONA, ITALIA; (c) CARDIOLOGIA, OSPEDALE "MADONNA DEL SOCCORSO", SAN BENEDETTO DEL TRONTO, ITALIA

Definizione. L'ipertrabecolatura del ventricolo sinistro, definita impropriamente anche come "non compattazione", rappresenta un fenotipo ventricolare, identificato da studi di imaging, che può essere in alcuni casi una variante normale o un adattamento a condizioni di aumentato pre- o post-carico, in altri casi espressione di una cardiomiopatia. Ne possono essere affetti sia i bambini sia gli adulti.
Diagnosi. Le caratteristiche morfologiche e strutturali nei bambini e negli adulti sono simili. I criteri diagnostici più utilizzati sono quelli di Jenni (rapporto non compatto/compatto>2 in telesistole in parasternale asse corto) in ambito ecocardiografico e i criteri di Petersen (rapporto non compatto/compatto>2.3 in telediastole in asse lungo) per quanto riguarda la RMN cardiaca.
Clinica. Può decorrere in maniera completamente asintomatica o manifestarsi, sia nel bambino sia nell'adulto, con una triade caratterizzata da scompenso cardiaco, aritmie e tromboembolismo. I bambini presentano alcune differenze cliniche rispetto all'adulto. Studi presenti in letteratura evidenziano come nel paziente pediatrico l'incidenza delle aritmie sia inferiore rispetto all'adulto; in particolare la fibrillazione atriale è poco frequente nel bambino. Anche l'incidenza del tromboembolismo risulta essere inferiore nel bambino ed è sempre associato a riduzione della funzione sistolica. L'ipertrabecolatura del ventricolo sinistro nel bambino risulta essere più spesso associata a cardiopatie congenite, sindrome di Wolf Parkinson White, dismorfismi facciali e disordini neuromuscolari; pertanto una valutazione clinica estesa anche ad escludere eventuali patologie neuromuscolari o altre eziologie genetiche/metaboliche risulta appropriata in questa popolazione.
Terapia. I principi di trattamento sono gli stessi sia nella popolazione pediatrica sia in quella adulta. L'unica strategia di trattamento attualmente perseguibile è la terapia sintomatica per lo scompenso cardiaco, per le aritmie e per la prevenzione del tromboembolismo e della morte cardiaca improvvisa. Nel bambino l'utilizzo di anticoagulanti e/o antiaggreganti potrebbe essere un'opzione in caso di disfunzione sistolica del ventricolo sinistro.
Prognosi. La storia naturale dei pazienti non è chiara. Pazienti sintomatici al momento della diagnosi hanno generalmente una prognosi peggiore. Alcuni studi hanno evidenziato tra i fattori prognostici negativi un rapporto miocardio non compatto/compatto>3, un diametro telediastolico del ventricolo sinistro>5 cm alla diagnosi, la presenza di LGE alla RMN cardiaca, la disfunzione ventricolare sinistra e il riscontro di mutazioni genetiche (TAZ, DTNA, LDB3 le più frequenti). Nel bambino la prognosi risulta influenzata anche da eventuali cardiopatie congenite associate.
Conclusioni. L'ipertrabecolatura del ventricolo sinistro rappresenta una fenotipo ventricolare che può interessare sia la popolazione pediatrica sia quella adulta con alcune differenze cliniche e prognostiche. La maggiore associazione nel bambino con sindromi genetiche, metaboliche e disordini neuromuscolari rende necessario uno stretto follow-up, mentre il riscontro occasionale di ipertrabecolatura nell'adulto con normale funzione sistolica ventricolare sinistra, in assenza di sintomi e di aritmie non richiede ulteriori accertamenti e può essere considerata una variante normale. Sono auspicabili ulteriori studi per definire meglio strategie terapeutiche e prognosi a lungo termine nel paziente pediatrico.

A848: MIOPERICARDITE IN GASTROENTERITE DA CAMPYLOBACTER JEJUNI

Giulia Passarini (a), Paolo Cimaglia (a), Gabriele Guardigli (a)
(a) AZIENDA OSPEDALIERA UNIVERSITARIA DI FERRARA

Uomo di 19 anni in buona salute, accedeva in PS per dolore toracico modificato dagli atti del respiro e dai movimenti del torso; riferita inoltre presenza da 3 giorni di scariche diarroiche. Dal raccordo anamnestico si evince inoltre assunzione giornaliera di uova crude. All'ECG si evidenzia blocco di branca destra incompleto, sotto-slivellamento diffuso del tratto PR e sopra-slivellamento del tratto ST in V2-V3. Riscontro di leucocitosi neutrofila, aumento della PCR e della Troponina agli esami ematici. L'Ecocardiogramma risultava nei limiti di norma. La Cardio RMN evidenziava edema a distribuzione subepicardica a carico della parete laterale e infero-laterale medio-apicale nelle sequenze T2, con incremento dei valori T2 mapping e con corrispondente LGE non ischemico meso-subepicardico nelle stesse sedi. Le coprocolture hanno evidenziato infine la positività per Campylobacter Jejuni. Sebbene non sia stata eseguita una biopsia endomiocardica, gli esami strumentali hanno permesso di fare diagnosi di miopericardite in infezione da C. Jejuni. Il paziente è stato trattato con idratazione, terapia antinfiammatoria e colchicina per la concomitante pericardite con progressivo miglioramento della sintomatologia toracica ed intestinale, quest'ultima auto-risoltasi senza necessità di terapia antibiotica. La miopericardite viene definita come un processo infiammatorio che coinvolge sia il miocardio che il pericardio. È prevalentemente a genesi virale, meno frequentemente ascrivibile a genesi batterica. La diagnosi si basa principalmente sul sospetto clinico in associazione ad alterazioni evidenziabili agli esami strumentali e laboratoristici; la diagnosi di certezza si può ottenere solo con la biopsia endomiocardica, ma il suo uso è riservato alle miocarditi con presentazione clinica severa e rapidamente evolutiva. Poiché il decorso è spesso benigno, nella pratica clinica la diagnosi viene effettuata con la RM cardiaca che identifica segni di edema miocardico e la presenza di Late Gadolinium Enhancement (LGE) e consente la diagnosi differenziale con l'infarto miocardico nelle presentazioni cliniche dubbie. Il C. Jejuni è una delle principali cause di gastroenterite ad origine batterica e raramente può dare un decorso clinico complicato. La maggior parte delle miocarditi secondarie a C. Jejuni descritte in letteratura sono lievi ed autolimitanti. In questi casi il trattamento si avvale principalmente di terapia di supporto della disidratazione e il ricorso agli antibiotici viene considerato in pazienti con sintomatologia severa, negli anziani e negli immunocompromessi.

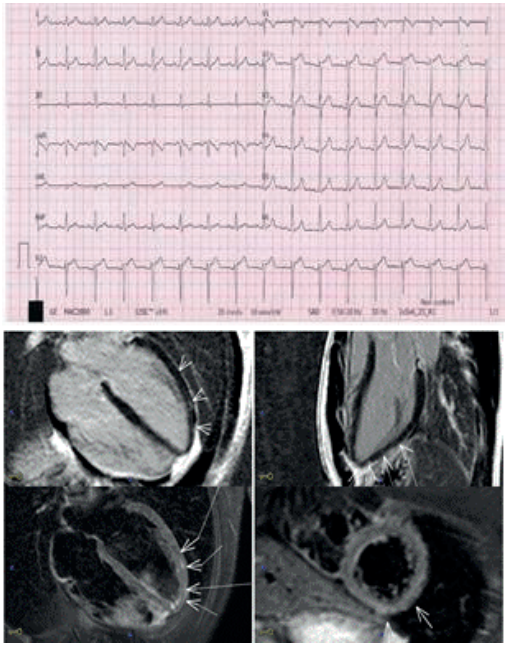

A849: DIAGNOSTIC VALUE OF HISTOLOGY AND CARDIAC MRI IN MYOCARDITIS ASSOCIATED WITH IDIOPATHIC INFLAMMATORY MYOPATHIES

Andrea Villatore (a), Giacomo De Luca (a), Valentina Canti (a), Davide Vignale (a), Luca Bosco (a), Stefania Rizzo (b), Corrado Campochiaro (a), Simone Sala (a), Anna Palmisano (a), Stefano Previtali (a), Lorenzo Dagna (a), Paolo Della Bella (a), Cristina Basso (b), Antonio Esposito (a), Giovanni Peretto (a)
(a) IRCCS SAN RAFFAELE HOSPITAL, MILAN, ITALY; (b) AZIENDA OSPEDALIERA DI PADOVA, PADUA, ITALY

Background. Myocarditis (MC) is considered one of the leading causes of death in patients with idiopathic inflammatory myopathies (IIM), such as dermatomyositis and polymyositis (DM/PM), and seems to correlate with longer disease duration. However, the prevalence and the prognostic value of subclinical cardiac inflammation in IIM are still unknown, since advanced diagnostic techniques are not routinely applied in this setting.
Purpose. To investigate myocardial inflammation in IIM by multimodal diagnostic work-up.
Methods. We retrospectively screened a large cohort of patients with MC in regular follow-up at a third-level center for myocarditis management. Patients who had a concomitant diagnosis of IIM were included. All patients underwent clinical evaluation and first-level cardiological exams. Cardiac magnetic resonance imaging (CMRI) was performed, including Lake Louise criteria (LLC), both traditional and updated (STIR, LGE, and native T1, T2, and ECV, respectively). Whenever appropriate, endomyocardial biopsy (EMB) was used to confirm MC by ESC criteria. The study endpoint was detection of MC in IIM by gold standard techniques.

Results. Twenty-three patients with IIM (median age 55 years, IQR 50-59, 56% females), including 18 polymyositis and 5 dermatomyositis, were enrolled. Diagnosis of IIM preceded that of MC in 87% (20/23) by median 12 months (IQR 6-60 months). Cardiac symptoms were present only in 65% (15/23), mostly as dyspnea (43%). High-sensitivity troponins (median 8 times the upper reference value, IQR 4-125) and CPK (median 722 U/L, IQR 294-1519) were elevated in all cases, while NT-proBNP in 48% (median 124 pg/mL, IQR 50-335). Overall, systolic function was preserved (median left ventricular ejection fraction 60%, IQR 55-61), with only 3 patients showing a mild reduction, and a subsequent recovery in 2 of them. Traditional LLC were positive in only 30% (7/23; LGE in 65%, STIR in 48%), while updated LLC allowed diagnosis of active MC in 74% (17/23; increased T1 in 65%, T2 in 70%, ECV in 65%). EMB was performed in 18/23 patients, achieving a definite diagnosis of myocarditis in 72% (13/18). Remarkably, viral PCR was positive in 39% (7/18), most frequently for bystander PV-B19.
Conclusions. Our single-center experience suggests that in IIM patients the implementation of updated LLC and EMB may enhance the diagnostic sensitivity of myocardial involvement and improve patient-tailored management.

A850: AN ILLUSTRATIVE CASE OF CONSTRICTIVE PERICARDITIS

Ciro Pollio Benvenuto (a), Gabriella Locorotondo (a), Antonio Maria Leone (a)
(a) UNIVERSITÀ CATTOLICA DEL SACRO CUORE

Constrictive pericarditis is a rare, but fatal disease, leading to heart failure due to diastolic dysfunction resulting from fibrotic and non-elastic pericardium. Clinical presentation is sneaky, with initial symptoms of splanchnic and peripheral venous congestion, then with hepatomegaly and ascites: this kind of presentation is not often recognized, delaying diagnosis. In this article, we present the case of an adult male with no previous cardiovascular history, but with diagnosis of hepatic cirrhosis: thanks to hybrid approach with multiple imaging modalities and with cardiac catheterization, investigations in our Centre led to the diagnosis of constrictive pericarditis, successfully treated with pericardiectomy; however, despite effective venous decongestion, it wasn't possible to spare the patient from liver transplant. Finally, we offer a brief critical review of the different imaging modalities used in this field, highlighting the need of their integration with invasive data from cardiac catheterization: an unavoidable step since there is no single test to ensure enough diagnostic accuracy for this challenging diagnosis.

MISCELLANEA

A851: CASO DI FALSA POSITIVITÀ DEL DOSAGGIO DELLA TROPONINA I

Federica Buzzi (a), Stefano Buratti (b), Francesca Bursi (a), Giulia Nemola (a), Riccardo Di Febo (a), Marco Guazzi (a)
(a) UNIVERSITÀ DEGLI STUDI DI MILANO; (b) ASST SANTI PAOLO E CARLO

Un uomo di 30 anni, in buone condizioni generali, fumatore attivo, con anamnesi patologica remota muta, nessuna familiarità per cardiopatie, nessun altro fattore di rischio e nessuna terapia domiciliare accedeva al Pronto Soccorso per comparsa da alcuni giorni di toracoalgie atipiche e odinofagia. Assenza di febbre o disturbi respiratori. Non abuso di sostanze. All'arrivo il paziente si presentava asintomatico. L'esame obiettivo era negativo. L'Rx torace non mostrava anomalie. L'ECG mostrava ritmo sinusale regolare, normofrequente, normale morfologia del QRS e ripolarizzazione. Agli esami ematici veniva rilevato rialzo della troponina I ad alta sensibilità pari a 0.326 ng/mL [valori di riferimento: <0.034 ng/mL esclusione di necrosi miocardica acuta], creatinchinasi 104 U/L [valori di riferimento: 55-170 U/L], PCR 5.6 mg/L [valori di riferimento: <10 mg/L], linfocitosi relativa, nessuna alterazione dei restanti valori di laboratorio. Dopo 3 h veniva ripetuto il dosaggio della troponina I con riscontro di valori di 0.377 ng/mL. Il paziente veniva ricoverato nel reparto di Cardiologia. Nel corso del ricovero il paziente si manteneva asintomatico e apiretico. Al monitoraggio telemetrico non si riscontravano eventi aritmici. Elettrocardiogrammi ripetuti durante il ricovero risultavano normali ed invariati. L'ecocardiogramma era normale, in particolare normali volumi, cinesi segmentaria e globale biventricolare, normali gli apparati valvolari, assenza di versamento pericardico. Data la bassa probabilità clinica complessiva di malattia coronarica, si optava per approfondimento con TC coronarica con evidenza di coronarie indenni da stenosi, assenza di versamento pericardico e di alterazioni focali del parenchima polmonare. Ai prelievi ematici eseguiti nei giorni successivi si riscontravano valori di troponina I persistentemente alti (0.368 e 0.362 ng/mL), in assenza di curva significativa, e valori di NT-proBNP<20 pg/mL [valori di riferimento: 0-125 pg/mL]. In considerazione dei risultati negativi delle indagini effettuate e dell'assenza di indici suggestivi per patologie associate, si ipotizzava che l'aumento della troponina I potesse essere un falso positivo. Si eseguiva quindi un prelievo ematico e, sullo stesso campione, si dosava troponina I e troponina T. Il valore della troponina I risultava nuovamente elevato, pari a 0.305 ng/mL; il valore della troponina T risultava nel range di normalità, pari a 9 ng/L [valori di riferimento: 3-14 ng/L]. Il dosaggio della troponina I veniva eseguito con metodica immunoenzimatica su strumento Vitros della ditta Ortho Clinical Diagnostics; il dosaggio della troponina T con metodica immunoenzimatica su strumento Cobas 8000 della ditta Roche Diagnostics. Tali risultati rafforzavano l'ipotesi che l'incremento della troponina I potesse essere dovuto a sostanze interferenti presenti nel siero del paziente. Si eseguiva Monotest e si richiedevano IgM per Citomegalovirus, Epstein-Barr virus, Coxsackie virus, Parvovirus B19 per ricercare le più comuni cross-reattività, ma risultavano negativi. I casi di interferenza con falsa positività del dosaggio della troponina I sono eventi rari, ma già descritti in letteratura scientifica.

A852: CARDIAC INVOLVEMENT OF GORLIN GOLTZ SYNDROME, NEW LIGHT AMONG THE SHADOWS OF AN OLD CONGENITAL DISORDER

Mihail Celeski (a), Mariagrazia Piscione (a), Francesco Piccirillo (a), Luca D´antonio (a), Andrea Segreti (a), Gian Paolo Ussia (a), Francesco Grigioni (a)
(a) UNIT OF CARDIOVASCULAR SCIENCE, FONDAZIONE POLICLINICO UNIVERSITARIO CAMPUS BIO-MEDICO, ROMA

Background. The Gorlin-Goltz syndrome (GGS) is a hereditary, autosomal dominant condition, with high penetrance and variable expressivity, resulting from mutations in the genes PTCH1, PTCH2, or SUFU. Multiple basal cell carcinomas, a keratocystic odontogenic tumor, and a bifid rib are just a few of the primary characteristics that require being present for a diagnosis to be established. There can be further endocrine, neurological, ophthalmologic, and respiratory changes, however with variable manifestations. Yet, the literature rarely reports cardiac disorders in patients with GGS.
Case summary. A 43 years-old woman, without a significant history for cardiovascular diseases, was admitted to the emergency department for persistent chest pain. She presented tachypneic upon admission, with normal values for her resting blood pressure and peripheral oxygen saturation. The EKG reported sinus rhythm with no appreciable repolarization phase changes. The results of the laboratory analysis showed an increase in troponin I levels and a subsequent drop (554-702-293 pg/ml). Coronary angiography, however, did not show any severe coronary stenosis. Multiple echocardiograms revealed no valvular disorders, a mild (2 mm) pericardial effusion, and preserved global and regional ventricular function. Therefore, a cardiac magnetic resonance (MR) was performed, which revealed anterior and lateral wall hyperintensities in T2 and left midventricular lateral wall hypokinesia. Laboratory results revealed normal blood counts, electrolytes, thyroid hormone levels, and kidney function, but an increase in C-reactive protein. Antibodies for autoimmune disease detection, a viral panel, and blood cultures, however, resulted negative. The patient was diagnosed with myopericarditis, and treatment with ibuprofen and colchicine was prescribed. When vomit and diarrhea began occurring, the treatment was changed to indomethacin, but with limited benefit. However, clinical and laboratory conditions significantly improved once corticosteroids were added. Nevertheless, during the hospital in-stay she developed right upper limb weakness, paresthesia, and a lumbo-sciatic pain. A cerebral MR proved right parietal ischemia lesions, but also showed calcification of the falx cerebri and a cerebellar cleft, while lumbar spine MR indicated posterior disk bulge and minor vertebral abnormalities. The history of multiple basal cell carcinomas removed surgically, edentulism, as well as the unintentionally discovered dysmorphisms on MR, highlighted the possibility of Gorlin-Goltz syndrome. The patient remained asymptomatic a year after her discharge, and a PTCH1 gene mutation test revealed a positive result, confirming the GGS.
Discussion. The only cardiac manifestations reported extremely infrequently in the literature are the existence of dilated cardiomyopathy, cardiac fibroma, and arrhythmias. It is yet unknown if a mutation in PTCH-1 and associated changes to the PTCH1-Sonic Hedgehog pathway, which is crucial for early development, might cause cardiac injury either directly or indirectly. All individuals with this syndrome, as well as any members of their families, should be aware of the importance of genetic counseling. However, echocardiography and cardiological assessment should be another tool included in the family screening, as well as in the management of patients with GGS. To determine the molecular and pathophysiological connection between cardiac manifestations and GGS, additional investigation is required.

A853: STRATIFICAZIONE POST-HOC DEL RISCHIO DI INFEZIONE NEI PAZIENTI ESTRATTI

Domenico Maria Carretta (a), Luca Benedetto (a), Carlo D'Agostino (a), Alessia Dentico (a), Alessandra Ferrieri (a), Francesca Carretta (b)
(a) A.O.U.C POLICLINICO DI BARI-U.O.C CARDIOLOGIA OSPEDALIERA; (b) UNIVERSITÀ CAMPUS BIO-MEDICO DI ROMA

Introduzione. L'infezione rappresenta una delle complicanze più diffuse e temute delle procedure di impianto di CIED. Il più delle volte questa potrebbe evolvere persino in endocardite su elettrocateteri o shock settico, a tal punto che l'unica terapia salvavita diventa l'estrazione transvenosa di elettrocateteri. Per questo spesso ci si pone il problema di prevenire tali quadri infettivi realizzando una valutazione del rischio infettivo prima dell'impianto così da non incorrere nel tempo in queste complicanze. Questo studio si pone l'obiettivo di stratificare post-hoc il rischio infettivo dei pazienti estratti nel nostro centro così da avvalorare l'introduzione e l'utilizzo di score per la valutazione pre-impianto del rischio infettivo.
Metodi. Sono stati valutati 163 pazienti sottoposti ad estrazione transvenosa di elettrocateteri, di cui 130 per infezione di tasca/endocardite su elettrocateteri o sepsi. In questi pazienti è stata fatta una valutazione post-hoc del rischio di infezione secondo lo score UPCM, score ideato dall'Università di Pittsburgh. Un valore di score maggiore o uguale a 7 individua i pazienti maggiormente predisposti a sviluppare nel tempo un'infezione. Questo score tiene conto di fattori di rischio come: reintervento precoce, tipo di dispositivo impiantato (CRTD vs ICD/PM), presenza di più di 2 cateteri in loco, sostituzione o revisione del dispositivo, utilizzo di pacing temporaneo, assunzione di corticosteroidi o anticoagulanti orali, funzionalità renale, febbre nelle 24 ore prima dell'impianto, presenza di diabete o scompenso cardiaco, genere maschile. Particolare attenzione abbiamo poi rivolto ai pazienti sottoposti a procedura di upgrade o a coloro che hanno subìto per due volte una procedura di estrazione.
Risultati. Dei 130 pazienti del nostro centro sottoposti ad estrazione per infezione, 112 hanno uno score maggiore o uguale a 7; 18 sono invece coloro con uno score minore di 7. Il valore medio è risultato essere 22,9.
Conclusioni. L'individuazione di uno score valutabile prima della procedura di impianto di CIED può risultare un ottimo aiuto nell'individuazione di pazienti fragili che a lungo o breve termine potrebbero incorrere in quadri di infezione. Così facendo si potrebbero valutare ulteriori alternative all'impianto transvenoso, come ad esempio l'impianto di pacemaker leadless o ICD sottocutaneo in pazienti non PM dipendenti elegibili a ciò.

A854: MANAGEMENT DELLA PERFORZIONE ATRIALE IATROGENA CAUSATA DA ELETTROCATETERE DI PACEMAKER

Graziano Fiorillo (a), Simone Agizza (a), Giuseppe Gargiulo (a), Paola Gargiulo (a), Francesco Lanza (a), Simona Piccirillo (a), Giovanni Battista Pinna (b), Emanuele Pilato (b), Carmine Morisco (a), Giovanni Esposito (a)
(a) CATTEDRA CARDIOLOGIA FEDERICO II DI NAPOLI; (b) CATTEDRA CARDIOCHIRURGIA FEDERICO II DI NAPOLI

Introduzione. Le complicanze correlate agli impianti di dispositivi cardiaci si attestano tra il 5,3% e il 14,3%. Fra le meno frequenti, ma potenzialmente fatali, vi sono le perforazioni miocardiche, più spesso ventricolari che atriali. Esse possono presentarsi in maniera aspecifica, il che non ne rende immediata la diagnosi. Il nostro caso clinico descrive il management di un tamponamento cardiaco causato da una perforazione atriale da elettrocatetere a vite retraibile.
Caso clinico. Uomo di 79 anni, affetto da ipertensione arteriosa, diabete mellito di tipo 2, dislipidemia, ed ateromasia carotidea. Il paziente era stato già sottoposto a rimozione di pacemaker bicamerale (impiantato per BAV hissiano avanzato nel 2021) dalla sede sottoclaveare sinistra, per infezione della tasca, evidenziata alla PET-TC. La procedura di reimpianto degli elettrodi è stata eseguita per via transvenosa da succlavia destra. Per difficoltà nel posizionamento dell'elettrocatetere atriale in auricola, si è optato per il suo posizionamento sulla parete posteriore dell'atrio destro. Non si sono riscontrate difficoltà nel posizionamento dell'elettrocatetere a vite retraibile in setto interventricolare medio-apicale. A distanza di due giorni dalla procedura è stato registrato un episodio lipotimico associato a dolore toracico e ipotensione. Per tale motivo al paziente sono stati praticati i seguenti esami: ECG (sovrapponibile al precedente); prelievi seriati per hs-TnI e CK-MB (risultati negativi); controllo in telemetria del dispositivo (normale funzionamento). L'ecocardiogramma eseguito in tale circostanza ha mostrato un lieve aumento della PAPs e falda di versamento pericardico in sede apicale lungo le camere destre dello spessore di 7 mm, non emodinamicamente significativo. Successivamente, è stata effettuata TC-torace con m.d.c. che ha mostrato emopericardio (spessore 11 mm), al momento non rifornito. Poche ore dopo si è verificato un repentino peggioramento del quadro emodinamico (PA: 80/30 mmHg), associato all'evidenza ecocardiografica di incremento del versamento pericardico determinante tamponamento cardiaco. Il paziente è stato trasferito in Cardiochirurgia per eseguire intervento di detamponamento chirurgico in regime d'emergenza. In tale circostanza è stata riscontrata una lesione in corrispondenza del tetto dell'atrio destro, che è stata trattata mediante sutura con prolene 5/0 su pledget. La procedura è stata coronata da buon esito con dimissione del paziente a distanza di 5 giorni.
Conclusioni. Sebbene la perforazione atriale iatrogena sia una rara complicanza dell'impianto di devices cardiaci, essa dovrebbe essere sempre considerata, anche in caso di sintomatologia aspecifica, ma soprattutto in presenza di fattori predisponenti quali l'età avanzata, il numero di interventi pregressi, la maggiore sottigliezza dell'atrio, la tipologia e punto di posizionamento degli elettrodi e la sede di accesso vascolare non convenzionale. Pertanto, in considerazione del crescente numero di impianti di devices cardiaci, è necessaria la codifica di procedure standard: A) l'identificazione dei pazienti ad alto rischio di perforazione atriale; B) la definizione di procedure in grado di diagnosticare precocemente il tamponamento cardiaco iatrogeno, al fine di poter migliore la prognosi di questa complicanza.

A855: A RARE CAUSE OF SEVERE PULMONARY ARTERIAL HYPERTENSION

Marta Pasquero (a), Elena Cavallone (a), Amedeo Feneziani (a), Stefano Ruffini (a), Marco Astegiano (a), Erica Franco (b), Claudio Moretti (b), Gaetano Maria De Ferrari (a)
(a) DEPARTMENT OF MEDICAL SCIENCES, UNIVERSITY OF TURIN, TURIN, ITALY; (b) OSPEDALE DI CHIVASSO, CHIVASSO, ITALY

We report the case of a 63-year-old obese and hypertensive woman, admitted in hospital with worsening dyspnea for 2 weeks and syncope. A suspected chronic thromboembolism was diagnosed nine months before for a similar clinical picture; hematologic screening excluded thrombophilia and NOACs were prescribed. Two-dimensional transthoracic echocardiography showed enlargement of right chambers, the interventricular septum shifted to the left ventricle, showing "D" sign. Color Doppler flow imaging showed moderate regurgitation in tricuspid valve, with indirect pulmonary pressure estimation 90 mmHg. Left ventricle was normal for dimensions and function.ECG evidenced sinus tachycardia and no specific ST-T alterations. Blood exams evidenced anemia (Hb 9 mg/dl), negative neoplastic markers and absence of occult blood in feces, mildly elevated inflammatory markers, T-Troponin and D-dimer. Naso-pharyngeal swab for SARSCoV2 infection was negative. Chest computed tomography (CT) with contrast revealed a large filling defect within bilateral main pulmonary arteries. No lymph nodes or pulmonary pneumonia were detected. Lower extremity venous ultrasound was positive for right popliteal deep vein thrombosis. The global clinical picture suggested the diagnosis of chronic pulmonary embolism with recent acute event, severe right ventricle compromise, a concomitant deep vein thrombosis. Some factors were not completely clear: chronic anemia, only mildly increased D-dimer, no specific increase of inflammatory markers. The patient was referred to Cardiac Surgery Unit of Fondazione IRCCS Policlinico San Matteo in Pavia, for pulmonary endarterectomy (PEA). Unexpectedly the surgical finding was a bilateral pulmonary artery sarcoma, confirmed by histological exam. We thus clarified some uncertain clinical aspects, explainable in athe context of a severe neoplastic picture. There were no immediate complications, and a chemotherapy was initiated after a period of cardio-pulmonary rehabilitation. Pulmonary artery intimal sarcoma (PAS) is a very rare disease, its prevalence is about 0.001–0.003%, it can originate from the left and right pulmonary arteries and intimal layer of pulmonary arteries, forming a tumor growing in the nodular cavity or spreading along the intimal surface.

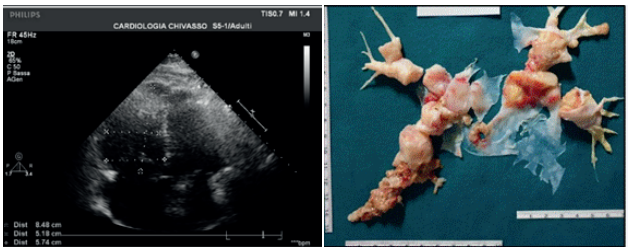

A856: WHEN BENIGN MEETS ACUTE: A PUZZLING CASE OF ATRIAL MYXOMA WITH ACS-LIKE PRESENTATION

Fulvio Cacciapuoti (a), Fabio Minicucci (b), Brenno Fiorani (c), Anna Maria Gallotta (b), Francesco Sessa (b), Mafalda Esposito (b), Elisa Di Pietro (b), Ciro Mauro (a), Federico Cacciapuoti (d)
(a) DEPARTMENT OF CARDIOLOGY "A. CARDARELLI" HOSPITAL - NAPLES, ITALY; (b) DEPARTMENT OF CARDIOLOGY "SAN LEONARDO HOSPITAL" - CASTELLAMMARE DI STABIA, NAPLES, ITALY; (c) DEPARTMENT OF CARDIAC SURGERY "G. MOSCATI" HOSPITAL - AVELLINO, ITALY; (d) CHAIR OF INTERNAL MEDICINE "L. VANVITELLI" UNIVERSITY - NAPLES, ITALY

Atrial myxoma (AM), a benign cardiac tumor primarily located in the left atrium, presents a diagnostic conundrum due to its diverse clinical manifestations. This case report delves into the intricate interplay between AM and acute coronary syndrome (ACS), shedding light on the complexities of cardiac pathology and the challenges encountered in accurate diagnosis. The patient, a 44-year-old woman with a hi-

story of chronic arterial hypertension and dyslipidemia, was admitted with sudden-onset epigastralgia, dyspnea, and chest pain. Clinical assessment revealed a regular heart rate and rhythm, alongside a distinct "tumor plop" sound during early diastole. Elevated blood pressure and reduced oxygen saturation were noted, with electrocardiography reflecting sinus rhythm, elevated ST segments in anterior leads, and elevated cardiac biomarkers. Bedside echocardiography unveiled akinesia in the left ventricular apex, contributing to a decreased ejection fraction and a hyperechoic mass originating from the left atrium. Although ACS was initially suspected due to the clinical presentation and electrocardiographic changes, transthoracic echocardiography revealed that the underlying cause was AM, which had led to thromboembolic events affecting the coronary arteries. The management strategy involved ticagrelor administration, aspirin therapy, and nitroglycerin, resulting in partial alleviation of symptoms. Coronary angiography exposed thrombotic occlusion within the anterior descending artery, necessitating successful mechanical thrombus aspiration. Subsequent transesophageal echocardiography confirmed the presence of a voluminous hyperechoic mass within the left atrium. Surgical excision was performed, and histological analysis confirmed the tumor's AM nature. This case highlights the complexity of AM's clinical presentations, which often lack specificity, and emphasizes embolization as a frequent complication. Moreover, the case underscores the rare occurrence of ACS induced by AM-related embolism. The case's unique aspects shed light on the potential for thrombosis when AM surfaces are irregular and the facilitation of embolic events through the mitral valve. The convergence of AM with ACS, though rare, added an intriguing layer of complexity. While ACS was a contributing factor to the patient's presentation, the thromboembolic events stemming from the AM were the fundamental drivers of her clinical scenario. This case highlights the necessity of meticulous clinical assessment and investigative scrutiny, particularly when symptoms and findings appear atypical for the assumed diagnosis. It also emphasizes the importance of considering a broad range of differential diagnoses, including those that might be initially dismissed due to their rarity.

A857: CAN 24 HRS ECG MONITORING STILL BE USEFUL FOR DIAGNOSIS OF CORONARY ARTERY SPASM?

Alberto Dotto (a), Leonardo Varotto (a), Bianca Rocca (a), Carlo Bonanno (a), Francesco Caprioglio (a)
(a) SAN BORTOLO HOSPITAL, VICENZA

This case presented a 45 years old male patient with history of sporadic episodes of chest pain at rest and palpitations. In his medical history: arterial hypertension, dyslipidemia, former smoker. The patient underwent ambulatory ECG (panel A), echocardiogram (both normals) and 24-hours ECG Holter monitoring, that showed episodes of relevant transient ST elevation followed by nonsustained ventricular tachycardia (NSVT) (B). The patient was hospitalized and underwent coronary angiography with evidence of high takeoff of right coronary artery with mild atherosclerotic disease and moderate stenosis of left anterior descending coronary artery, functionally not significant (iFR: LAD=0.94, RCA=0.93). The night after coronary angiography the patient had chest pain lasting 10 minutes and regressed spontaneously, with evidence of ST elevation followed by NSVT at ECG monitoring(C, D). In absence of significant atherosclerotic coronary disease and considering the medical history of the patient, diagnosis of coronary artery spasm (CAS) was suspected. Therefore, therapy with diltiazem and nitrates was started. The patient remained always asymptomatic and underwent exercise stress echocardiogram after initiation of therapy, resulted negative for inducible ischemia. This case highlights the usefulness of Holter ECG monitoring for the diagnosis of CAS, that often results challenging, due to transience of coronary spasms. Holter ECG monitoring could appears as an obsolete examination, conversely it is a low-cost and non-invasive examination that can give valuable information in selected patients. The indication for implantable cardioverter defibrillator (ICD) implantation and its role in primary prevention in patients with CAS still not clearly established. However, ICD implantation should be considered in high-risk patients despite optimal medical treatment.

A858: EVALUATION OF THE STRESSFUL EVENT IN PATIENTS PRESENTING WITH TAKOTSUBO SYNDROME: HOW MUCH STRESS IS NEEDED?

Andrea Galli (a), Stefano Marzorati (a), Marco Pozzoli (a), Valentina Alba Sassi (b), Silvia Rogiani (b), Roberto De Ponti (a)
(a) UNIVERSITÀ DEGLI STUDI DELL'INSUBRIA, VARESE; (b) OSPEDALE DI CIRCOLO, VARESE

Introduction. The association between Takotsubo syndrome (TTS) and exposure to physical or emotional stress is of common knowledge. The patient usually presents with angina-like chest pain and/or dyspnea and a typical ECG pattern with diffuse T-wave inversion, sometimes preceded by ST-segment elevation. Generally, Nt-proBNP increases disproportionally compared to troponin, which is only mildly elevated. In its most typical variant, echocardiography shows apical ballooning and hyperkinetic basal segments. The diagnosis is confirmed by exclusion of coronary artery obstruction and/or dissection at angiography. Higher mortality is expected in patients with severe mitral regurgitation (MR) due to left ventricular (LV) dilatation and systolic dysfunction which can occur in the first hours after the acute event. Another critical complication is represented by ventricular tachyarrhythmias associated with Q-T interval prolongation observed in the typical ECG pattern. The aim of this evaluation is to identify the stressful event associated with TTS in patients admitted to our hospital.

Methods. We analyzed a population of 11 patients admitted to the Cardiology Unit of Ospedale di Circolo in Varese (mean age: 73 yrs; mean hospitalization: 12.2 days) with diagnosis of TTS, between 01/01/2023 and 31/08/2023. The diagnosis was confirmed by the typical ECG pattern, echocardiography, troponin alterations and coronary angiography.

Results. In the majority (9 out of 11) of our patients there is a predominance of emotional stress, and only 2 of them were diagnosed with TTS after a physical stress: 1 after a long walk into the woods, 1 as a consequence of evacuation after constipation lasting 1 week. In 9 patients an emotional stress was identified as follows: in 3 symptoms occurred when already hospitalized (2 for pacemaker implantation – 1 of them was a psychiatric patient – and 1 for colon-rectal surgery); 4 patients developed symptoms as a consequence of an argument (1 with her husband, 2 with a friend – 1 simply during a card game – and 1 at the workplace); 1 patient manifested the syndrome after a nightmare and the last one after an unexpected birthday party. Moreover, based on a general consensus, the stress event could be considered mild in 8/11 patients (72%). Finally, in 3/11 patients there was a severe functional impairment: in 2 MR with systolic anterior movement and in 1 reduction of ejection fraction to 30% with severe multi-jet MR was observed. Interestingly, in 2 of these 3 cases the TTS was caused by only a mild emotional stress. All patients were discharged asymptomatic with significant improvement of LV function.

Conclusions. Based on these data, as even mild emotional stress can cause the syndrome, we hypothesize the role of individual pre-existing psychological factors in the symptoms break out. This seems important considering the possibility of TTS recurrence. The severity of the LV impairment with MR apparently is not associated with the severity of the stressful event.

A859: CORONARY AND CARDIAC SCREENING IN LIVER TRANSPLANTATION CANDIDATES: A LONG JOURNEY WITH FREQUENT IDENTIFICATION OF MODERATE AND SEVERE CORONARY ARTERY DISEASE

Alice Bernardelli (b), Sofia Hassan (b), Virginia Klun (b), Marta Masini (b), Tommaso Semino (b), Erika Tempo (b), Gabriele Crimi (a), Matteo Vercellino (a), Rocco Vergallo (a), Marco Canepa (a), Italo Porto (a), Giorgio Ghigliotti (a)
(a) CHAIR OF CARDIOVASCULAR DISEASES, DEPT. OF INTERNAL MEDICINE AND SPECIALTIES (DI.M.I.), UNIVERSITY OF GENOA, ITALY AND CARDIOLOGY UNIT, CARDIOTHORACIC AND VASCULAR DEPT., IRCCS OSPEDALE POLICLINICO SAN MARTINO, GENOA, ITALY; (b) CHAIR OF CARDIOVASCULAR DISEASES, DEPT. OF INTERNAL MEDICINE AND SPECIALTIES (DI.M.I.), UNIVERSITY OF GENOA, ITALY

Background. In patients (pts) with Liver cirrhosis (LC) CV risk stratification before major liver surgery (Liver Transplantation and Liver resection) is a complex task due to the unique cardiovascular physiology of this subset of pts, and is aimed to detect coronary artery disease (CAD) and nonCAD cardiac abnormalities. NASH is a faster-growing indication for liver transplantation and is an independent risk factor for presence of obstructive CAD. LC pts often show anemia and platelets (PP) reduction, that may impact on risk related to invasive vascular procedures, such as PCI/CABG.

Aims. To describe in LC pts: 1) temporal shifts (2013-2023) in etiological LC burden; 2) features of non-ST parameters at exercise stress test reflecting functional capacity; 3) tools/tests used and duration required for assessment of CV risk; 4) incidence of anemia, low PP count (<100 10^9/L) and CAD.

Methods. Ambispectic Single-Centre Study collecting data on exercise EKG parameters (MET at peak, maximal heart rate incompetence [MHR-I], heart rate recovery at 1 min [HRR1']) in 194 LC pts (age 59.8±10.3), 125 CONTR (58.2±15.6) and 18 CHF (72.1±11.2). Within LC pts, multiple noninvasive (exercise stress testing, myocardial perfusion

imaging [MPI], pharmacological Stress echocardiography [Echo-stress]) and invasive modality of imaging and of stress testing were used. Coronary computed tomography angiography (CT) to derive Ca-score and coronary stenosis and invasive coronary angiography (ICA) were used to quantify CAD presence and critical CAD.

Results Metabolic cause (NASH) of LC moved overtime from 2.7% to 21.9% while viral (HBV/HCV) and EtOH causes moved from 12%/39% and 23% to 6%/16% and 38%. Exercise Stress test parameters collected within study groups (CONTR, LC, CHF) are: MET peak: 7.1±1.8, 5.0±1.6, 4.5±1.2; MHR-I: 0.76±0.15, 0.57±0.23, 0.65±0.21; HRR1': 21.1±8.7, 13.7±7.5, 10.9±7.9 (p<0.01 CONTR vs other groups). Time required (days) for cardiac consult to rule in/out access to liver surgery is 3±6 days for those undergoing visit+Echo only; with additional testing: 51±54 +CT/ICA, 61±60 + Echo-stress, 63±61 + MPI and 89±69 +PCI. Within LC pts undergoing coronary imaging: Hb levels (g/L) and PP count (10^9/L) are (IQ 25-50-75) 111-125-138 and 68-104-162; Ca-score at CT is 0-99 (19.5%), 100-399 (11%),>400 (69.5%); CAD identified is subcritical 39.1%, intermediate 21.8%, critical 31.1%, PCI and stenting are done for 1V/2V disease (76.9%/23.1%) and in proximal/non proximal segments 46%/56%, with no complications in pts with low PP count.

Conclusions. An increase of metabolic burden has been observed overtime in the LC pts; functional capacity is reduced in LC pts, and the blunted chronotropy and reduced cardiorespiratory fitness, similar between LC and CHF pts, result in low sensitivity and suboptimal negative predictive value for the detection of coronary artery disease; significant CAD is better searched with noninvasive or invasive coronary angiography. Collecting cardiac information may be a time-consuming task, requires 3-89 days and includes search for presence of CAD in 50% LC pts. In CAD pts, PCI is done at proximal segments in 46% LC pts, and the frequent finding of count of PP<100 10^9/L was not associated to excess in bleeding risk.

A860: ION AND DIONYSUS: NEVER DISTRACTED ABOUT DIFFERENTIAL DIAGNOSIS.

Alessandro Laschera (a), Daniele Torella (a), Sabato Sorrentino (a), Alessandro Caracciolo (a), Vincenzo Riverso (a), Francesco Caggiano (a), Alessandro Lucchino (a), Salvatore De Rosa (a)

(a) DIVISION OF CARDIOLOGY, DEPARTMENT OF MEDICAL AND SURGICAL SCIENCES, MAGNA GRAECIA, CATANZARO, ITALY

Background. In normal individuals, cellular and urinary responses prevent significant potassium accumulation in the extracellular fluids. This phenomenon, called "potassium adaptation", could be compromised in the case of acute renal injury with the risk of a dangerous Potassium overload in the extracellular Fluid. Acute variation of this ion concentration could alter the Myocardial conduction system by changing cardiomyocyte membrane potential and the work of voltage-dependent ion channels, producing characteristic EKG changes that could simulate other pathological scenarios delaying a prompt diagnosis. EKG modifications strictly depend on the level of potassium in the blood (high voltage and pointed T waves, QRS enlargement, Atrioventricular block, disappearance of P wave, ST elevation, fusion of QRS with T waves, ventricular fibrillation and asystole. The most common extra-cardiac causes of the rise of troponin with ST-segment elevation are acute neurologic injuries like stroke or subarachnoid haemorrhages, sepsis, acute renal failure and pulmonary embolism.

Case presentation. We presented the case of a 60-year-old patient, who manifested Syncope preceded by asthenia and vomiting, transferred to our cath lab for a suspected SCA-STEMI Diagnosis. On-site ECG showed spread ST elevation in all peripheral and precordial leads. The patient arrived with altered sensorium and consciousness (GCS =7), hypoxic and hypercapnic respiratory failure. The initial diagnosis was SCA-STEMI, so we performed coronary angiography as the first exam, excluding any coronary obstruction and secondary CT thorax and Brain scan to exclude pulmonary embolism and cerebral haemorrage. Arterial blood gas analysis showed severe metabolic acidosis with high levels of potassium 9 mEq/L and lactate (13 mmol/L). Based on clinical status and the Blood exam results, an Acute kidney injury diagnosis was formulated (supported by the presence of Diabetes, dehydration and concomitant assumption of metformin). The patient was transferred to the intensive care unit to perform invasive mechanical ventilation and hemodialysis, with total recovery in a few hours, EKG alterations reversion and Blood values normalization in a few hours.

Conclusions. A Prompt differential diagnosis of ECG modification and recognition of ionic alteration allows early management with the right therapy and reversion of clinical state. Sometimes, ST elevation differential diagnosis could be challenging and not immediate. It is fundamental to not delay the diagnosis based on the clinical history and latter-day symptoms and to avoid performing all diagnostic exams to exclude the most severe pathologies potentially linked to the ECG abnormalities. AI-implemented technologies like Machine learning applied to ECG interpretation can significantly help in the most accurate differential diagnosis of ECG abnormalities to direct fast diagnostic algorithms to the right pathology and to provide a prompt therapeutic intervention.

A861: LOEFFLER'S ENDOCARDITIS WITH BIVENTRICULAR APICAL THROMBI DUE TO STRONGYLOIDES STERCORALIS INFECTION: A CASE REPORT

Federico Baccino (a), Ailia Giubertoni (b), Alice Panizza (b), Sara Bacchini (b), Luisa Airoldi (b), Simona Devecchi (b), Lidia Rossi (b), Patrizia Pedrotti (c), Giuseppe Patti (a, b)

(a) UNIVERSITÀ DEGLI STUDI DEL PIEMONTE ORIENTALE, NOVARA; (b) A.O.U. MAGGIORE DELLA CARITÀ, NOVARA; (c) OSPEDALE NIGUARDA, MILANO

Introduction. Loeffler's Endocarditis (LE) is a rare condition caused by eosinophilic proliferation and characterized by endomyocardial thickening and intracardiac thrombi formation that may lead to restrictive cardiomyopathy. We report a case of LE with biventricular apical thrombi due to Strongyloides stercoralis infection.

Case presentation. A 78-year-old woman was admitted to our Cardiac Intensive Care Unit for acute pulmonary oedema. In her past medical history she reported hypertension, active smoking and mild hypercholesterolemia. Electrocardiography revealed sinus rhythm with deep negative T waves and ST segment depression in V4-V6, aVF and DII-DIII. Laboratory findings showed elevated white blood cells count with elevated eosinophil count (0,87 x 10^3/mL), mildly elevated C-reactive Protein levels, elevated brain natriuretic peptide (1605 pg/ml, normal values 0-60 pg/mL) and cardiac troponin I of 206 ng/L (normal values: 0-37 ng/l). The echocardiogram revealed an hyper-echogenic, homogeneous and hyperkinetic cardiac mass obliterating the apex of left ventricle (LV), preserved ejection fraction and signs of elevated filling pressure of LV. The patient was initially treated with oxygen and diuretics with good clinical and hemodynamic response. Coronary angiography showed mild widespread atheromasia without any critical stenosis. In order to better characterized the ventricular mass, a cardiac magnetic resonance was performed, revealing the presence of thrombi in the apex of both ventricles (24x23 mm on longitudinal plane, 34 mm on axial plane in LV), hyper-enhancement with transmural involvement of the apex of LV and a subendocardial and mesocardial involvement in the lateral and posterior wall of LV in late gadolinium enhancement images. Anticoagulant therapy was started, initially with Low-Molecular Weight-Heparin and then with Warfarin. Bone marrow biopsy was negative for lympho-myeloproliferative disease. Parasitological investigations showed the presence of positive serology for Strongyloides stercoralis with negative coprocolture and elevated eosinophil cationic protein levels. Given this findings, diagnosis of LE due to S. stercoralis infections was made and therapy with ivermectin and prednisone were started. At 4 months follow up the patient was in good clinical conditions, with a clear reduction of left apical thrombus dimensions and a normalization of eosinophilic count.

Conclusions. Cardiac masses are often a diagnostic challenge. Since several conditions can lead to eosinophilic proliferation responsible of the cardiac damage, a multidisciplinary approach is crucial to reach the correct diagnosis and therefore establish an appropriate therapy that can lead to complete resolution of the cardiac involvement. Non-invasive imaging modalities plays a central role allowing early detection and accurate staging of LE.

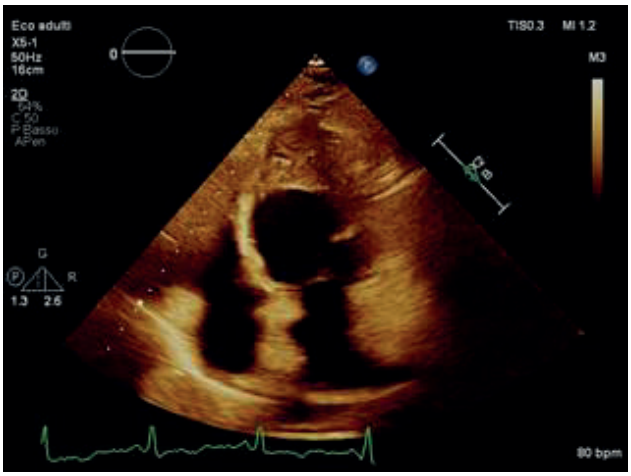

A862: EXCLUSIVE CHRONIC HEAT-NOT-BURN CIGARETTE SMOKING ALTERS THE PROFILE OF CIRCULATING MICRORNAS

Vittorio Picchio (b), Giulio Ferrero (c), Claudia Cozzolino (b), Barbara Pardini (d, e), Erica Floris (b), Sonia Tarallo (d, e), Xhulio Dhori (b), Cristina Nocella (b), Lorenzo Loffredo (b), Giuseppe Biondi Zoccai (b), Roberto Carnevale (b), Giacomo Frati (b), Isotta Chimenti (b), Francesca Pagano (a)

(a) CONSIGLIO NAZIONALE DELLE RICERCHE- ISTITUTO DI BIOCHIMICA E BIOLOGIA CELLULARE; (b) SAPIENZA UNIVERSITÀ DI ROMA; (c) UNIVERSITÀ DEGLI STUDI DI TORINO; (d) ITALIAN INSTITUTE OF GENOMIC MEDICINE; (e) CANDIOLO CANCER INSTITUTE

Background. Traditional combustion cigarette (TCC) smoking still is a major risk factor for several types of cancer and cardiovascular diseases. Circulating microRNAs represent key molecules mediating pathogenetic mechanisms, and potential biomarkers for personalized risk assessment. Several transcriptomics studies showed that TCC smoke exposure globally changes the profile of circulating miRNAs, both in the presence or absence of co-morbidities. The use of heat-not-burn cigarettes (HNBCs) as novel smoking devices is rising exponentially worldwide, with still unknown long-term effects on health. Comprehensive data on the circulating miRNA profile in chronic HNBC smokers is still lacking.
Purpose. To define for the first time the profile of circulating miRNAs in serum samples of chronic exclusive HNBC smokers, and to identify potentially pathogenetic circulating miRNAs signatures. Methods. Serum samples were obtained from subjects enrolled in the SUR-VAPES CHRONIC trial, including 3 groups of 20 healthy young subjects, stratified as chronic HNBC smokers (mean exclusive use=1.5 years), TCC smokers, and non-smokers (NS). 4 sub-groups of 5 subjects were randomly created (tested for non-statistical differences in available anthropometric and clinical parameters). 3 sub-groups were used to create 3 pooled samples per group for small RNA sequencing; the fourth sub-group constituted the validation set. Data were analyzed using DEseq2.
Results. The principal component analysis showed a neat separation between NSs and both smoker groups, with a less pronounced difference between TCC and HNBC smokers sera. Differential expression analysis revealed 101 miRNAs significantly modulated between groups (Adj p<0.05). We found a global downregulation of circulating miRNAs with only 20 miRNAs upregulated in both groups of smokers. Head-to-head comparison revealed that 65 miRNAs were exclusively modulated in TCC, 26 miRNAs were commonly modulated in both smoker groups, and 10 miRNAs were exclusively modulated in HNBC samples. Most miRNAs of the HNBC group displayed an intermediate level between NS and TCC groups. KEEG pathway analysis on target genes of significantly modulated miRNAs with high counts (cutoff>500 norm DESeq counts) revealed a relevant number of cancer-associated pathways, followed by signaling and cardiovascular disease pathways. Although TCC smokers presented a significantly higher number of dysregulated miRNAs in their sera, the target and pathway analyses returned overlapping terms for both commonly deregulated miRNAs and those deregulated only in one of the smoker groups.
Conclusions. Our results define for the first time a global miRNA profile in the serum of exclusive chronic HNBC smokers. Despite the globally lower extent of the differences observed, data suggest a significant impact of HNBCs on circulating miRNAs with overlapping of predicted target pathways compared to the miRnome of TCC smokers.

A863: HEART, LUNGS AND STATINS: IS IT AN EASY COHABITATION?

Dajana Polito (a), Andrea Segreti (a), Mariagrazia Piscione (a), Francesca Vespasiano (a), Gian Paolo Ussia (a), Francesco Grigioni (a)
(a) FONDAZIONE POLICLINICO UNIVERSITARIO CAMPUS BIOMEDICO

Statins are pivotal drugs for preventing coronary artery disease and ischemic stroke. Their beneficial effects include lowering serum cholesterol by inhibiting hepatic cholesterol biosynthesis and anti-inflammatory and pleiotropic properties. Even though statins are widely considered effective, a small percentage of patients may develop some side effects, including lung inflammation and possible interstitial lung disease. However, statins have also been proposed as a therapeutic tool for treating interstitial lung disease, thanks to their anti-inflammatory and anti-fibrogenic properties. Therefore, despite the well-known beneficial cardiovascular effects, the role of statins on the lungs is still controversial. In addition, the concomitant use of drugs that alter statin metabolism and the synergic role in inducing lung damage require specific considerations. Furthermore, diagnosing this harmful side effect can be delayed in patients with concomitant heart diseases because of common symptomatology. Therefore, this review aims to analyze the controversial role of statins, a pivotal drug for treating cardiovascular diseases, but with effects on respiratory system that has yet to be fully clarified.

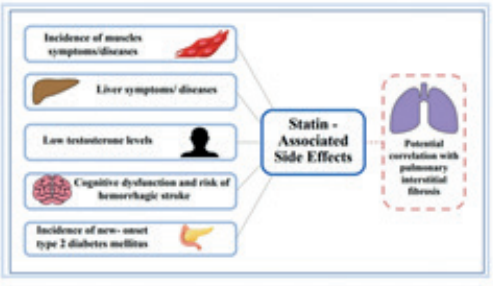

Figure 1. Side effects of statins
While the main adverse effects are known, including myalgia without CK elevation to life threatening rhabdomyolysis, incidence of new-onset DM2, cognitive dysfunction and possible haemorrhagic stroke, liver symptoms and, finally, low testosterone levels, potential lung-related side effects are rarely mentioned.

PREVENZIONE E RIABILITAZIONE

A864: EXERCISE GAS EXCHANGE PHENOTYPING IN APPARENTLY HEALTHY SUBJECTS: DIFFERENCES ACROSS NORMAL WEIGHT, OVERWEIGHT AND OBESE

Francesca Di Lenarda (a), Maurizio Losito (a), Melissa Gandolfi (a), Ross Arena (b), Marco Guazzi (a)
(a) OSPEDALE SAN PAOLO, MILANO; (b) DEPARTMENT OF PHYSICAL THERAPY, UNIVERSITY OF ILLINOIS, CHICAGO

Background. Obesity is a widespread medical condition consisting in a BMI higher than 30 kg/m^2. Diseases correlating with obesity are, above all, cardiovascular related. Functional capacity and gas exchange analysis derived from cardiopulmonary testing is, to date, widely used to describe and cluster patients or athletes, but quite little is provided on apparently healthy subjects.
Aim. The aim of this study was to evaluate how BMI may differentiate functional capacity and how it may better perform in defining cardiovascular risk when analysed in the context of cardiopulmonary exercise test (CPET)-derived measures.
Methods. Apparently healthy individuals (N=932, 54.7% females) presenting with none to five cardiovascular risk factors (MCVRF; hypertension, diabetes, tabagism, dyslipidaemia, body mass index>25), underwent CPET. The cohort analysis was carried out by dividing and analysing patients into groups based on sex, BMI and number of MCVRF. VO_2max was considered within normal limits for a predicted value>80%. Analysis was carried out using R-studio software.
Results. The number of MCVRF significantly increased (CI 95%, p-value 0,009) through the BMI strata: the average number of MCRVF in normal weight, overweight and obese was respectively 1.6, 2.7, 2.9. VO_2 max significantly (CI 95%, p-value <0,001) decreased with rise of BMI (Precisely, for normal weight, overweight and obese VO_2 max was respectively 21.8, 18.7 and 15.5). Moreover, normal weight and overweight presented with a significant correlation between the increase in number of MCRVF and the decrease in functional capacity (respectively -0.44 and -0.30, p-value <0,001). The obese population exhibited the lowest mean VO_2max which, interestingly enough, didn't show a significant decreasing correlation with the increase of the number of MCVRF.
Conclusions. In a population of healthy subjects, a higher BMI (obese population) peculiarly shows a strong correlation with the decrease in functional capacity; less relevant is the association with the extent of MCVRF. On the contrary in the normal weight and overweight population, the extent of MCVRF is primarily affecting exercise function. These data add insights and better help to phenotype the link between functional capacity and CV risk and may help to better target underlying causes of exercise intolerance.

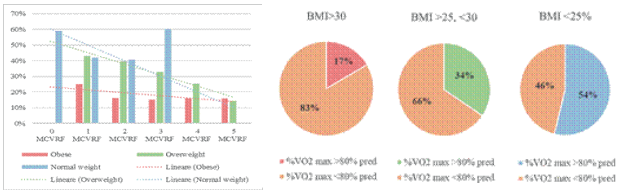

A865: VISIT-TO-VISIT LDL CHOLESTEROL VARIABILITY IN PATIENTS TREATED WITH STATINS AND EZETIMIBE VS. PCSK9I: IS THERE A LINK WITH CARDIOVASCULAR OUTCOMES?

Gianantonio De Michele (a), Arturo Cesaro (a), Francesco Scialla (a), Vincenzo Acerbo (a), Gianmaria Scherillo (a), Giovanni Signore (a), Francesco Paolo Rotolo (a), Giuseppe Raucci (a), Domenico Panico (a), Gennaro Porcelli (a), Fabio Fimiani (a), Felice Gragnano (a), Elisabetta Moscarella (a), Paolo Calabrò (a)
(a) CARDIOLOGIA - UNIVERSITÀ DEGLI STUDI DELLA CAMPANIA "LUIGI VANVITELLI'' - AORN S. ANNA E S. SEBASTIANO, CASERTA

Background. The role of low-density lipoprotein cholesterol (LDL-C) as a cardiovascular risk factor is well established. The treatment of dyslipidemia, long relying solely on statins, has been revolutionized by the advent of the PCSK9 inhibitors (PCSK9i). The aim of our study is to compare the "visit-to-visit'' LDL-C levels between patients on PCSK9i compared to those on statin and/or ezetimibe and how this variability, and thus the use of PCSK9i, may influence the incidence of major adverse cardiovascular events (MACE).
Method and Results. A population of 466 patients has been enrolled. Among them, 192 were under treatment with PCSK9i, whereas 274 were treated with statin and/or ezetimibe. Visit-to-visit variability was defined as variability in low-density lipoprotein (LDL) values between visits. Variability was assessed by calculating standard deviation (SD) between the consecutive measurements. The coefficient of variation of LDL-C (LDL-C-CV) was used to correct the mean. The "visit-to-visit'' variability of serum LDL-C levels was calculated by measuring these levels at 1-3-6-18 months of follow-up. To avoid result bias, the first LDL-C value was excluded from the measurement of "visit-to-visit'' variability. In the PCSK9i group, a higher percentage of patients showed low variability of LDL-C levels

between visits (89.1% vs. 22.6%, P<0.001). Furthermore, in the PCSK9i population, the mean expected time before a cardiovascular event was higher, although this difference was not statistically significant (43 vs. 42.74 months, P=0.272). Finally, diabetes and baseline high serum LDL-C values have been identified as variables statistically associated with a higher risk of MACE (1.9 and 2.3-fold, respectively, P<0.05).
Conclusions. Therapy with PCSK9i is associated with reduced visit-to-visit variability of serum LDL-C levels. This reduced variability, and thus treatment with PCSK9i, appears to be associated with a longer time free of adverse cardiovascular events. Further studies are needed to confirm our results.

A866: EFFICACY AND SAFETY OF CARDIAC REHABILITATION IN PATIENTS WITH LEFT VENTRICULAR THROMBOSIS AFTER ACUTE MYOCARDIAL INFARCTION

Alessia Giglio (a), Gabriella Malfatto (a), Federico Paoletti (c), Kevin Bonacina (d), Silvia Ravaro (a), Martina De Martin (a), Gino Seravalle (a), Carlotta Munforti (a), Gerardina Fratianni (a), Roberto Chianca (a), Silvia Castelletti (a), Gianfranco Parati (a, b), Mario Facchini (a), Lia Crotti (a, b)
(a) ISTITUTO AUXOLOGICO ITALIANO IRCCS, DIPARTIMENTO DI SCIENZE CARDIOLOGICHE, NEUROLOGICHE E METABOLICHE, UO DI RIABILITAZIONE CARDIOLOGICA, OSPEDALE SAN LUCA, MILANO, ITALY; (b) DIPARTIMENTO DI MEDICINA E CHIRURGIA, UNIVERSITÀ DI MILANO-BICOCCA, MILANO, ITALY; (c) SCUOLA DI SPECIALIZZAZIONE IN MEDICINA DELLO SPORT E DELL'ESERCIZIO FISICO, UNIVERSITÀ DI MILANO-BICOCCA, MILANO, ITALY; (d) SCUOLA DI SPECIALIZZAZIONE IN MEDICINA DELLO SPORT, UNIVERSITÀ DEGLI STUDI DI MILANO, MILANO, ITALY

Background. The incidence of left ventricular thrombus (LVT) after acute myocardial infarction (AMI) has declined in recent decades due to early primary percutaneous coronary intervention (PCI) and effective antithrombotic regimen. However, LVT remains an important complication of AMI. It is unclear whether patients (pts) with LVT after the acute AMI phase may engage in cardiac rehabilitation (CR) since physical exercise might favour systemic embolism.
Methods. From 2012 to 2022, 706 pts with AMI underwent CR in our Hospital. Of them, 25 (3.4%) had LVT in the Coronary Care Unit (CCU), where oral anticoagulant (OAC) treatment was started. In 18 pts (2.6%), LVT was still present in our Rehabilitation Unit: OAC was continued. CR was performed as in-patient for 7 to 10 days and out-patient for 6 weeks. Remarkably, no abnormalities in the coagulation pathway were found. Table 1 shows the clinical characteristics of all pts. Physical training in CR was based on a preliminary six-minutes walking test (6MWT); its intensity was kept to 80% of that of pts without LVT, with weekly echocardiographic check for presence and size of LVT.
Results. During CR we did not observe complications. At CR completion, we reached optimal medical treatment in 23/25 pts (blood pressure, LDL and Hb_1Ac at target). The 6MWT improved from 556 ± 110 to 582 ± 119 mt (p<0.05). Five pts still showed LVT at the end of CR albeit reduced in size: their EF and PAPs were similar to those of the 14 pts in whom LVT was not detected and whose bicycle stress test was normal. All pts underwent echocardiographic follow-up at 3 and 6 months. At 3 months, LVT persisted in 3 of 4 pts showing it at CR discharge so that OAC was continued; the 14 pts without LVT were studied after 2 weeks of OAC washout: in 11 no LVT was observed, and they continued DAPT; in 3 pts in whom LVT relapsed, long term OAC was continued with a single antiplatelet agent. At 6 months, 2 pts showing a small apical LVT were left with long-term OAC.
Conclusions. We confirm that in the real world the incidence of LVT after AMI is low and related to anterior STEMI with persistingly akinetic apexes and slightly reduced EF. They can safely undergo a CR period, with the possibility of reaching good exercise capability, obtain optimal medical treatment and receive a standardized follow-up program. A small minority of patients still show LVT in the long term, with no evidence of an abnormal coagulation pathway.

TABLE 1	All pts n=25	LVT in CCU n=7	LVT in CR n=18
Age (years)	57.2 ± 13.6	65.0 ± 14.2	54.2 ± 12.3
Gender (M/F)	23/2	5/2	18/0
STEMI/NSTEMI (%)	25/0	7/0	18/0
Site (anterior; inferior; lateral; posterior)	anterior	anterior	anterior
Culprit artery (LM; IVA; RCA; CX)	IVA/IVA-LM =20/5	IVA/IVA-LM =2/5	IVA/IVA-LM =13/5
Apical akinesis/bulging (3; 4)	23/2	5/2	16/2
Left ventricle ejection fraction (EF) %	42.7 ± 7.9	41.6 ± 6.2	43.2 ± 8.6
Pulmonary pressure (PAP) mmHg	29.7 ± 4.8	29.0 ± 7.1	30.0 ± 6.2
Antithrombotic treatment	DAPT + OAC	DAPT + OAC	DAPT + OAC

LM, left main coronary artery; IVA, interventricular coronary artery; RCA, right coronary artery; CX, circumflex coronary artery; DAPT, double anti-platelet; OAC, oral anticoagulant.

A867: POLYVASCULAR ATHEROSCLEROSIS INVOLVEMENT AND CARDIAC REHABILITATION: FUNCTIONAL IMPROVEMENT AND RISK RECLASSIFICATION

Stefano Pezzoli (a), Alessandro Maloberti (a, b), Chiara Tognola (a, b), Rita Cristina Myriam Intravaia (b), Paolo Ossola (a), Michela Algeri (b), Marta Alloni (b), Cristina Giannattasio (a, b)
(a) SCHOOL OF MEDICINE AND SURGERY, MILANO-BICOCCA UNIVERITY, MILAN ITALY; (b) CARDIOLOGY IV, ASST GOM NIGUARDA, MILAN ITALY

Background. Polyvascular atherosclerotic involvement is one of the definitions of extreme CV risk. For this reason, the search for carotid or lower limb asyntomatic atherosclerotic pathology can be useful to guarantee more intensive treatments for these individuals, who have already had a myocardial infarction.
Aim. To understand how much the polyvascular patients can improve in functional terms after Cardiological Rehabilitation, comparing them with monovasculars. Furthermore, we want to evaluate how many patients are reclassified with an active research of asyntomatic atherosclerotic disease with carotid ultrasound and Ankle Brachial Index (ABI).
Methods. The study sample was composed by 87 patients who underwent a cardiological rehabilitation cycle at the Niguarda hospital in Milan from March 2021 to April 2022. Anamnestic, clinical, laboratory and instrumental data were collected. Functional improvement was assessed as the difference in meters walked on the 6-minutes walking test (6MWT) at the beginning (6MWT-1) and at the end of the rehabilitation (6MWT-2). All patients underwent ABI (to evaluate asyntomatic PAD) and carotid ultrasound (to evaluate asyntomatic cerebrovascular disease).
Results. Pre-riclassification, polyvascolar patients (13) compared to monovascular (74) were older (70 years vs 59 years, p=0.01), more frequenly males (100% vs 73%, p<0.001), had more previous recurrent myocardial infarctions (46% vs 8%, p=0.002) and had a worse performance in terms of 6MWT-1 (428m vs 514m, p=0.002) and 6MWT-2 (517m vs 597m, p=0.008). However, absolute functional improvement durgin rehabilitation is similar between the two group (81m vs 82m, p=0.919). Following reclassification, 7 patients switched from monovascular (87) to polyvascular (20).
Conclusions. Our data showed that polyvascular patients can improve as much as monovasculars after Cardiological Rehabilitation. Furthermore, following ABI and carotid ultrasound, 8% of patients were reclassified. Polyvascular patients may receive more targeted and intensive therapies if properly diagnosed.

A868: SAFETY AND EFFICACY OF EARLY REHABILITATION AFTER MITRAL VALVE REPAIR

Andrea Savastano (a, b), Massimo Piepoli (a, b)
(a) UNIVERSITÀ DEGLI STUDI DI MILANO; (b) IRCCS POLICLINICO SAN DONATO

Background. Cardiac rehabilitation (CR) is highly recommended after cardiac surgery, including mitral valve repair (MVR) surgery, however the timing of CR initiation remains controversial. We aim to demonstrate the safety of an early rehabilitation program, defined as an exercise training program started immediately after discharge from the cardiac surgery ward, after having achieved clinical stabilization, in patients with mitral insufficiency undergoing MVR surgery. In addition, we want to prove the effectiveness of this program in improving the performance and functional ability.
Methods. In a single center retrospective observational study, all consecutive patients who underwent MVR between 2020-2023 and were subsequently admitted in the CR service, were enrolled. The onset of complications such acute heart failure, cardiogenic shock, cardiac ischemic events, and major arrhythmic events (ventricular tachycardia or fibrillation) was evaluated. Functional evaluation was assessed by the 6 min walking test (6MWT) and the gait speed test (GST). NYHA functional class was evaluated at the beginning and at the end of CR. In addition, an echocardiographic evaluation was performed on the first and the last day of CR.
Results. We analyzed 133 patients. Exercise training started on average 9 ± 4 days after surgery. First tests were performed in the beginning and repeated 22 ± 6 days after MVR. The early CR program was associated with no major adverse event; mostly frequently observed complications were arrhythmic events: 27 patients experienced episodes of atrial fibrillation (AF); 6 patients had episodes of non-sustained ventricular tachycardia (NSVT); there were 5 cases of supraventricular tachycardia (SVT). The occurrence of these adverse events was associated with cardiovascular risk factors, i.e. arterial hypertension (in 57%) smoking habit (42%). An improvement in echocardiographic parameters was observed: indexed volume of the left atrium (Vsi) reduced (37.26±12 vs 31.48±11, p<0,005); left ventricle end diastolic volume (LVEDV) reduced (99±37 vs 86±28, p<0,005); left ventricle ejection fraction (LVEF) and mitral regurgitation (MR) mean grade remained stable. An improvement is seen in all three functional parameters: there was an increase of 13% (p<0,005) in 6MWT after CR, GST passed from 0,96 m/s to 1.2 ms (p<0,005). NYHA was 2.28 at first evaluation and 1.11 at the end (p<0,005).
Discussion. Early CR program was well tolerated without deleterious effect on MV function and was effective in improving patient's functional ability and exercise tolerance. Further valuations are needed, with a larger sample size and longer follow-up interval.

A869: IMPATTO DELL'INQUINAMENTO INDOOR SUL SISTEMA NERVOSO AUTONOMO E INFIAMMAZIONE: IMPLICAZIONI CARDIOVASCOLARI

Michele Baroni (b), Angelica Carandina (a), Beatrice Arosio (a), Gloria Santangelo (b), Marco Vicenzi (b), Massimiliano Ruscica (b), Giacomo Fanti (c), Andrea Spinazzè (c), Domenico Cavallo (c), Andrea Cattaneo (c), Nicola Montano (a), Matteo Bonzini (c), Stefano Carugo (b), Eleonora Tobaldini (a)
(a) UNIVERSITÀ DEGLI STUDI DI MILANO, DIPARTIMENTO DI SCIENZE CLINICHE E DI COMUNITÀ; (b) FONDAZIONE IRCCS CA' GRANDA OSPEDALE MAGGIORE POLICLINICO, UNITÀ DI CARDIOLOGIA; (c) DIPARTIMENTO DI SCIENZE E ALTA TECNOLOGIA DELL'UNIVERSITÀ DEGLI STUDI DELL'INSUBRIA

Introduzione. Il global burden of disease ha dichiarato l'esposizione all'inquinamento dell'aria come il terzo fattori di rischio di morte prematura nel mondo, dopo ipertensione arteriosa e esposizione al fumo di sigaretta. Un ruolo chiave nella relazione tra inquinamento atmosferico e patologie cardiovascolari è giocato da due meccanismi fisiopatologici fondamentali: una disregolazione del sistema nervoso autonomo e una attivazione dei meccanismi pro-infiammatori. Da un lato, infatti, è stato osservato che l'esposizione agli inquinanti ambientali outdoor induce un'alterazione della bilancia simpato-vagale a favore di una predominante modulazione simpatica, dall'altro lo sviluppo di uno stato pro-infiammatorio cronico a basso grado. Queste due alterazioni sono note per essere associate a tutte le patologie cardiovascolari croniche quali insufficienza cardiaca, ipertensione arteriosa, alterazioni del ritmo cardiaco. Tuttavia pochi dati sono disponibili sugli effetti dell'inquinamento indoor in questo ambito. Scopo del nostro studio è quindi quello di valutare la relazione tra l'esposizione all'inquinamento dell'aria indoor, il controllo autonomico cardiovascolare (CAC), l'infiammazione in una popolazione di soggetti volontari sani.
Metodi. Abbiamo arruolato 11 soggetti sani (età media 27±2; M=2/11). È stato utilizzato un dispositivo wireless in grado di monitorare per 7 giorni in continuo i parametri elettrocardiografici sia in fase di veglia che in fase di sonno, l'attività respiratoria e l'actigrafia. Durante questo intervallo di tempo è stato inoltre analizzato il livello di esposizione domestica a particolato fine, biossido di azoto (NO2) e composti organici volatili utilizzando un campionatore ad hoc. Gli indici di CAC e qualità del sonno sono stati derivati dai biosegnali acquisiti: la frequenza cardiaca durante il sonno, l'efficienza del sonno, la latenza all'addormentamento, il tempo in stato di veglia dopo il primo addormentamento l'indice di sforzo toracico (CEI=n° di eventi/ora) e l'indice di variazione ciclica della frequenza cardiaca (CVHRI=n° eventi/ora), questi ultimi due indicatori del rischio di sviluppo di apnee notturne e potenziali surrogati di severità del disturbo del sonno. Dopo il monitoraggio, è stato raccolto un campione ematico per l'analisi del profilo infiammatorio attraverso il dosaggio plasmatico di TREM 1, biomarcatore pro-infiammatorio.
Risultati. Abbiamo riscontrato una significativa correlazione positiva tra l'esposizione media all'NO2 nelle 24 ore e gli indici CEI e CVHRI (B=0.748; p=0.033 e B=0.875; p=0.004 rispettivamente). L'analisi del profilo infiammatorio ha invece mostrato una significativa correlazione positiva tra l'esposizione media all'NO2 nelle 24 ore e la concentrazione ematica di TREM 1 (r=0.741; p=0.047).
Discussione. I nostri dati, seppur preliminari, sembrano evidenziare che esposizione a inquinanti indoor si associ a due indicatori di possibile iniziale alterazione del controllo autonomico cardiovascolare durante il sonno. È stato inoltre evidenziato che l'esposizione ad elevati livelli di inquinanti indoor si associa a uno stato pro-infiammatorio sistemico.

A870: EXTREME CARDIOVASCULAR RISK IN CARDIOLOGICAL REHABILITATION: PREVALENCE AND IMPACT ON PATIENT'S FUNCTIONAL IMPROVEMENT

Alessandro Maloberti (a, b), Chiara Tognola (a, b), Rita Cristina Myriam Intravaia (b), Eleonora Senini (a), Marta Alloni (b), Michela Algeri (b), Saverio Fabbri (a), Claudio Ciampi (a), Francesca Daus (a), Alfonso Riccio (a), Cristina Giannattasio (a, b)
(a) SCHOOL OF MEDICINE AND SURGERY, MILANO-BICOCCA UNIVERSITY, MILAN ITALY; (b) CARDIOLOGY IV, ASST GOM NIGUARDA, MILAN ITALY

Background. Among patients at very high cardiovascular risk, some are more likely to experience recurrent cardiovascular events. In may 2022, an article was published in the European Heart Journal proposing different definitions of patients at extreme cardiovascular risk. However, the process of defining the patient at extreme cardiovascular risk is still ongoing and more data also on its prevalence are needed.
Aims. To assess the prevalence of patients at extreme cardiovascular risk in cardiological rehabilitation, to evaluate the clinical features of these patients. Furthermore, we want to establish how the extreme cardiovascular risk condition correlates with the functional improvement obtained during cardiac rehabilitation.
Methods. The study included 938 patients suffering from atherosclerosis who attended the cardiological rehabilitation of Niguarda Hospital in Milan. Patients diagnosed with non-ischemic heart failure or congenital heart disease have been excluded. Patients classified as at extreme cardiovascular risk were compared with the remaining patients and a multivariate linear regression was performed with absolute functional improvement as the dependent variable.
Results. Among 938 patients, 26.9% belong to the category of extreme cardiovascular risk. Patients at extreme cardiovascular risk showed a higher average age (67.8 ± 10.4 vs 64.1 ± 11.1 years; p ≤0.001), a higher prevalence of significant comorbidities (peripheral arterial disease, cerebrovascular disease, chronic kidney disease, dyslipidemia, diabetes, hypertension) and a lower functional improvement during cardiac rehabilitation (102.9 ± 68.6 vs 138.1 ± 86.5 m; p ≤0.001). At multivariate analysis extreme cardiovascular risk remains a significant determinant of the absolute functional improvement at Six-Minute Walking Test obtained during cardiac rehabilitation with b =-0.137 and p=0.035, together with female sex (b =-0.136; p=0.035).
Conclusions. Extreme cardiovascular risk is a widespread condition among patients with chronic coronary syndrome and adversely affects the patient's functional improvement during cardiac rehabilitation. The identification of patients at extreme cardiovascular risk is a goal to be pursued in order to intensify secondary prevention strategies.

A871: VALUTAZIONE DEL RISCHIO CARDIOVASCOLARE IN BASE A GENERE ED ETNIA: RISULTATI PRELIMINARI DI UN PROGETTO DI SCREENING

Maria Luisa Poli (a, b), Eleonora Rodighiero (a, b), Letizia Reggianini (a), Elisa Lodi (a, b), Maria Grazia Modena (a, b)
(a) CENTRO P.A.S.C.I.A. (PROGRAMMA ASSISTENZIALE SCOMPENSO CARDIACO, CARDIOPATIE DELL'INFANZIA E A RISCHIO), AOU POLICLINICO DI MODENA;
(b) UNIVERSITÀ DI MODENA E REGGIO EMILIA - SCUOLA DI SPECIALIZZAZIONE IN MEDICINA DELLO SPORT E DELL'ESERCIZIO FISICO CHIMOMO DEPT C/O POLICLINICO DI MODENA

Razionale e scopo. Il centro PASCIA (Programma Assistenziale Scompenso cardiaco dell'adulto, Cardiopatie dell'Infanzia e donne A rischio) con sede presso l'Azienda Ospedaliera Universitaria di Modena ha messo in atto un progetto di screening rivolto a donne immigrate residenti nella provincia di Modena offrendo loro la possibilità di sottoporsi ad una visita cardiologica comprensiva di elettrocardiogramma (ECG) ed ecocardiogramma, in maniera gratuita e senza necessità di prenotazione. Questo con lo scopo di aiutare una categoria di donne che più difficilmente svolgono controlli sanitari e per implementare le conoscenze mediche sulle differenze di genere ed etnia in relazione alla valutazione ed al trattamento dei principali fattori di rischio cardiovascolare. Questo progetto rientrava all'interno di un'iniziativa di prevenzione alla salute più ampia dal nome "H-OPEN WEEK sulla salute della donna" che si è tenuta dal 17 al 22 aprile 2023 in molti ospedali "Bollini Rosa" italiani. L'iniziativa è promossa annualmente da ONDA (Osservatorio nazionale sulla salute della donna e di genere) che si pone l'obiettivo di promuovere la cura al femminile, sottolineare l'importanza della prevenzione primaria, della diagnosi precoce e dell'aderenza terapeutica.
Metodi. Sono state esaminate 50 donne immigrate e residenti nella provincia di Modena che sono state indirizzate presso il centro PASCIA grazie alla collaborazione dell'Associazione "Donne nel Mondo" e AIW (Association for the Integration of Women). Il 2% aveva origini Sud-Americane, Il 4% dell'Europa Orientale, il 41% dell'Africa Nord-Orientale e il 53% dell'Africa sub-sahariana, con un intervallo di età di 20-73 anni e una media di 47 anni. Il campione è stato sottoposto ad una visita cardiologica, comprensiva di anamnesi, esame obiettivo, misurazione della pressione arteriosa, ECG, Ecocardiografia.
Risultati. Si è analizzata la prevalenza dei principali fattori di rischio cardiovascolare da cui è emerso che 18 donne su 50 presentavano ipercolesterolemia e solo 5 di queste assumevano una terapia mirata; che quasi la metà delle donne era in stato di sovrappeso/obesità e che il 36% era affetto da ipertensione arteriosa in trattamento, ma al controllo effettuato solo 5 di queste hanno mostrato valori pressori a target. Di minor impatto la prevalenza di problematiche legate alla gravidanza, di diabete mellito di tipo 2 e dell'abitudine tabagica.
Conclusioni. Di rilevanza statistica il dato riguardante l'alta prevalenza di sovrappeso/obesità e dislipidemia: molte donne, arrivando in Italia versano in condizioni economiche precarie, abbandonano le abitudini alimentari salutari e si nutrono principalmente di alimenti meno costosi spesso ricchi in zuccheri semplici, carboidrati e grassi. Interessante anche l'alta percentuale (42%) di donne provenienti dall'Africa sub-sahariana con ipertensione incontrollata e/o con danno d'organo (ipertrofia ventricolare sinistra). La causa potrebbe risiedere nella resistenza della popolazione africana ai farmaci più comunemente usati per il trattamento dell'ipertensione arteriosa in Europa e nel mondo occidentale, quali ACE-inibitori e Sartani. Andrebbero usate altre classi farmaceutiche come i Calcio Antagonisti e gli Alfa-bloccanti a cui rispondono con più efficacia. Significativo il fatto che la maggioranza delle donne visitate non aveva mai svolto un controllo cardiologico o ricevuto indicazioni su un adeguato stile di vita. Il progetto di screening verrà implementato al fine di incrementare la casistica e acquisire nuove conoscenze sul profilo di rischio cardiovascolare delle immigrate nel nostro territorio. È nostra intenzione, infine, impostare un piano di formazione per i Medici di Medicina Generale sulla prevenzione e il trattamento dei fattori di rischio mirata alle differenze di genere e all'etnia.

A872: NEL CUORE DELLA CINA: VALUTAZIONE DEL RISCHIO CARDIOVASCOLARE IN SOGGETTI DI ORIGINE CINESE RESIDENTI IN EMILIA-ROMAGNA

Eleonora Rodighiero (a), Maria Luisa Poli (a),
Paolo Alberto Gasparini (b), Elisa Lodi (a), Maria Grazia Modena (a)
(a) CENTRO P.A.S.C.I.A. (PROGRAMMA ASSISTENZIALE SCOMPENSO CARDIACO, CARDIOPATIE DELL'INFANZIA E DONNE A RISCHIO) - AOU POLICLINICO DI MODENA, UNIVERSITÀ DEGLI STUDI DI MODENA- SCUOLA DI SPECIALIZZAZIONE IN MEDICINA DELLO SPORT; (b) UNIVERSITÀ DI MODENA E REGGIO EMILIA - AOU POLICLINICO DI MODENA

Il centro PASCIA (Programma Assistenziale Scompenso cardiaco dell'adulto, Cardiopatie Dell'Infanzia e donne A rischio) con sede presso l'Azienda Ospedaliera Universitaria di Modena ha messo in atto un progetto di screening gratuito rivolto alla popolazione a cui hanno aderito cinesi immigrati residenti in Emilia-Romagna. Il progetto rientrava all'interno di un'iniziativa di prevenzione dal nome "H-OPEN WEEK sulle malattie cardiovascolari" che si è tenuta dal 26 settembre al 2 ottobre 2023, organizzata da Fondazione Onda, (Osservatorio nazionale sulla salute della donna e di genere), con l'obiettivo di promuovere l'informazione, la prevenzione e la diagnosi precoce delle malattie cardiovascolari. Sono stati esaminati 93 pazienti, 41 uomini e 52 donne, immigrati di origine cinese e residenti nelle province di Modena e Reggio Emilia, provenienti dalla città di Wenzhou situata a sud della Municipalità di Shanghai. L'età media era di 51 anni con un range di età di 23 – 74 anni. In presenza di una mediatrice culturale, il campione è stato sottoposto ad una visita cardiologica comprensiva di esame obiettivo, misurazione della pressione arteriosa, ECG, Ecocardiografia. Sono stati inoltre somministrati dei questionari bilingue in cinese/italiano per indagare l'anamnesi familiare, l'anamnesi patologica, le terapie assunte, l'attività fisica, le abitudini alimentari (Questionario PREDIMED Primary Prevention of Cardiovascular Disease with a Mediterranean Diet) e il consumo di sale. Si è analizzata la prevalenza dei principali fattori di rischio cardiovascolare da cui è emerso che il 53% dei pazienti presentava ipercolesterolemia, di questi solo il 30% assumevano una terapia mirata. 30% erano ipertesi, di cui 10 già in trattamento e 18 nuove diagnosi. 30% dei soggetti fumava o aveva smesso da meno di 10 anni. Il 63% riferisce di aver riscontrato un aumento peso da quando risiede in Italia, con un BMI medio di 23. Solamente 5 pazienti hanno riferito di svolgere regolare attività fisica, mentre i restanti riferiscono di non avere sufficiente tempo libero. Sebbene il tempo trascorso in Italia sia in media di 22,4 anni, il punteggio medio al questionario PREDIMED è stato di 5, pertanto nessun soggetto aveva una buona aderenza alla dieta mediterranea (corrispondente ad un punteggio PREDIMED>10). Il 50% dei soggetti riferiva di seguire una dieta a moderato contenuto di sale e di glutammato monosodico. 9 pazienti erano diabetici in terapia.

Conclusioni. Di rilevanza statistica il dato riguardante l'alta prevalenza di ipertensione e dislipidemia: I soggetti visitati presentavano un BMI medio di 23, che secondo i range corretti per popolazione asiatica proposti da WHO corrisponde a sovrappeso. Nella popolazione asiatica infatti è stata descritta una differente associazione tra BMI, percentuale di massa grassa e rischio cardiovascolare rispetto alla popolazione europea, con un aumentato rischio di insorgenza di diabete mellito di tipo 2 per valori inferiori di BMI. In seguito al trasferimento in Italia la maggior parte dei pazienti riferisce di aver riscontrato un aumento di peso: anziché acquisire le abitudini virtuose della dieta mediterranea hanno incrementato il consumo di carne rossa ed in particolar modo di salumi. Questa settimana di prevenzione ha permesso di fornire indicazioni sul corretto stile di vita in immigrati di origine cinese che solitamente non si sottopongono a controlli cardiologici in Italia a causa della barriera linguistica. È nostra intenzione, infine, impostare un piano di formazione per i Medici di Medicina Generale sulla prevenzione e il trattamento dei fattori di rischio mirata alle differenze di genere e all'etnia.

A873: PRESCRIZIONE DI ESERCIZIO FISICO IN PREVENZIONE CARDIOVASCOLARE: DATI PRELIMINARI RELATIVI AD UN QUINQUENNIO DI ATTIVITÀ DELLA UOC MED SPORT TREVISO

Teresina Vessella (a), Flaviano Giorgiano (a), Laura Merlo (a),
Cinzia Pegoraro (a), Giovanna Biasi (a), Barbara Barra (a),
Giulia Meneguzzo (a), Paola Astolfo (a), Federica Michieletto (b),
Francesca Russo (b), Patrizio Sarto (a)
(a) UOC MED SPORT AULSS2 TREVISO; (b) REGIONE VENETO

Introduzione. L'esercizio fisico riveste un ruolo fondamentale nella prevenzione primaria e secondaria delle malattie croniche non trasmissibili. Ciononostante, ad oggi, la prescrizione di esercizio rivolta a soggetti con cronicità non risulta ancora essere in linea con quanto richiesto dalle linee guida. In Veneto, già da diversi anni, si sta perseguendo l'obiettivo di ridurre il gap tra le indicazioni delle linee guida e la loro reale applicazione. Mancano tuttavia dati regionali indicativi del reale impatto clinico di tale "modello".

Obiettivo. Valutare l'efficacia di un modello strutturato di presa in carico di soggetti con patologie croniche attraverso la prescrizione di esercizio fisico.

Metodo. Abbiamo valutato l'impatto del modello sulla popolazione di soggetti con patologia cronica afferenti al nostro Servizio tra il 2014 ed il 2019. In questo quinquennio presso la nostra struttura sono afferiti 366 soggetti residenti nella provincia di Treviso con storia di cardiopatia (prevalentemente esiti di sindrome coronarica acuta e disfunzione ventricolare sinistra) e/o diabete ai quali sono state fornite precise indicazioni (sotto forma di prescrizione) circa l'esercizio fisico da praticare in prevenzione secondaria, in base al quadro clinico-strumentale osservato. Per ciascun soggetto è stata valutata l'aderenza alla prescrizione di esercizio consegnata. La popolazione in studio è stata quindi suddivisa in 3 gruppi: 0=per nulla aderente (soggetto non praticante esercizio); 1=soggetto praticante attività fisica non strutturata/esercizio fisico non monitorato e/o non completamente aderente alla prescrizione consegnata in termini di intensità, durata e frequenza; 2=soggetto praticante esercizio fisico strutturato e monitorato, svolto nel rispetto della prescrizione consegnata. Per ciascun soggetto si è considerata anche l'eventuale sospensione temporanea e successiva ripresa dell'attività e si è tenuto conto del periodo di cessazione dell'attività nell'arco del periodo di monitoraggio. Per ciascun gruppo si sono, quindi, analizzati i dati relativi a spesa farmacologica, nuovi ricoveri e decessi (analisi di database provinciale eseguita dal nostro Dipartimento di Igiene e Sanità Pubblica) successivi al nostro intervento.

Conclusione. Dall'analisi preliminare dei nostri dati emerge una significativa riduzione della sopravvivenza nei soggetti appartenenti al gruppo 0 rispetto ai soggetti dei gruppi 1 e 2. L'esercizio fisico strutturato e monitorato, a target per intensità durata e frequenza, inoltre, sembra determinare una protezione ancora maggiore anche rispetto ad una attività fisica non strutturata o ad esercizio fisico strutturato ma non monitorato e/o non a target.

A874: INTERVENTO RIABILITATIVO INETNSIVO DOPO EVENTO ACUTO: FREQUENZA DI EVENTI CARDIACI E SICUREZZA CLINICA

Antonella Capomolla (a), Soccorso Capomolla (a),
Valentina Pannace (a), Josef Ranieli (a), Simone Lo Gatto (a)
(a) DON MOTTOLA MEDICAL CENTER

Premessa. La riabilitazione cardiologica costituisce un importante intervento terapeutico nei pazienti cardiopatici. La gestione delle patologie cardiache e le tecniche gestionali dei processi sanitari negli ultimi anni sono migliorati. Dati di sicurezza gestionale della seduta di training sono riferiti a studi retrospettivi. La sicurezza della seduta di training dopo evento acuto nel nuovo scenario gestionale è stata poco considerata.

Scopo. Valutare la frequenza di eventi cardiaci maggiori (infarto miocardio, scompenso cardiaco acuto, aritmie ipercinetiche) o minori (episodi lipotimici, angina) durante la seduta di training in una popolazione di soggetti con evento acuto inviata in modo consecutivo all'intervento riabilitativo.

Metodi. Sono stati arruolati in modo consecutivo 192 pazienti (54 ♀, 138 ♂) di anni 67±11, affetti da scompenso cardiaco cronico (27%), esiti di intervento cardiochirurgico (63%)e recente rivascolarizzazione miocardica con PTCA e stent (10%). L'attivazione del paziente al servizio è stato governato da una serie di schede che valutavano la dipendenza clinica e la dipendenza fisica del paziente. Sono stati considerati le seguenti variabili: walking test, Tempo medio di attivazione al programma dopo evento (T); il tempo di esercizio totale (TE); il tempo di training individuale (TI); il carico allenante; il numero di eventi cardiocircolatori (EC).

Risultati. All'ingresso 57/192(29%) presentavano dipendenza fisica e/o clinica con una attivazione tardiva e parziale nel servizio. Tale sottogruppo presentava un case mix più complesso (1,51±.07 vs 1.2±.08 p<.01). Non sono stati rilevati eventi cardiaci maggiori; in 2/192 pazienti è occorsa ipotensione sintomatica. Alla dimissione è stato rilevato un incremento della capacità funzionale (399±94 vs 290±97 mt p<0.001).

Conclusioni. Dopo un evento indice cardiaco una discreta coorte di pazienti presenta dipendenza clinica e/o fisica. Le complicanze cardiache in pazienti precocemente attivati nel servizio fisioterapico, dopo un evento acuto, sono rari e di ridotto rischio.

Tempo attivazioneT (gg)	6±9
Tempo di training totale (ore)	4045
Tempo di training individuale (ore)	29,9
N eventi maggiori	-
N eventi minori	2

A875: PROGNOSTIC IMPLICATIONS OF PRECLINICAL ATHEROSCLEROSIS IN TERM OF CARDIOVASCULAR, CEREBROVASCULAR EVENTS AND MORTALITY, IN A SEVEN YEARS FOLLOW-UP

Girolamo Manno (a, f), Daniela Di Lisi (a, b), Cristina Madaudo (a, b),
Andrea Pappalardo (e), Andrea Flex (c, d), Paolo Tondi (c, d),
Salvatore Novo (a), Giuseppina Novo (a, b)
(a) DEPARTMENT OF HEALTH PROMOTION MOTHER AND CHILD CARE, INTERNAL MEDICINE AND MEDICAL SPECIALTIES (PROMISE) "G. D'ALESSANDRO", UNIVERSITY OF PALERMO, PALERMO (ITALY); (b) DIVISION OF CARDIOLOGY, UNIVERSITY HOSPITAL "PAOLO GIACCONE", PALERMO, ITALY; (c) DIVISION OF ANGIOLOGY, IRCCS UNIVERITY HOSPITAL FOUNDATION "A. GEMELLI", ROME, ITALY; (d) DEPARTMENT OF MEDICINE, CATHOLIC UNIVERSITY OF THE SACRED HEART, ROME, ITALY; (e) PROVINCIAL HEALTH COMPANY OF PALERMO, PALERMO (ITALY); (f) PROVINCIAL HEALTH COMPANY OF AGRIGENTO, AGRIGENTO (ITALY)

Background. The aim of our study was to assess in subjects with cardiovascular risk factors (CRFs), the impact of pre-clinical atherosclerosis parameters in an overall seven years follow-up, in terms of onset of cardiovascular (CV) and cerebrovascular (CBV) events and mortality.
Methods. We enrolled 100 patients (M:F=67:33) with cardiovascular risk factors and undamaged angiographic coronary arteries. Patients underwent physical examination, electrocardiogram (ECG) and standard transthoracic echocardiography (TTE) including evaluation of diastolic and systolic function, measured as left ventricular ejection fraction (LVEF), left ventricular global longitudinal strain (GLS). Furthermore carotid intimal-media thickness (cIMT) and arterial stiffness were assessed in term of Beta Index and pulse wave velocity (PWV). The parameters were measured at baseline (T0) and a two years (T1) and seven years (T2) clinical follow up were carried out.
Results. We observed that at T1 both the cIMT, Beta index and PWW were a positive predictive factors of CV events, but statistical significance was only achieved by the PWV parameter (Odds Ratio 2.088; p value=0.023). If we consider follow up at T2, it emerged that beyond Beta index and PWW, also cIMT were results strong predictors of CV events. Also insulin resistence was a strong independent positive predictive factor of CV events and mortality both at T1 and T2.
Conclusions. Our study demonstrates that CRFs, in particular insulin resistance, are associated with subclinical alterations at vascular level, such as cIMT and increased arterial stiffness, which represent important markers of pre-clinical atherosclerosis, cardiovascular events and mortality both at two and seven years follow up.

SCOMPENSO CARDIACO

A876: PREDICTORS OF LEFT VENTRICULAR REVERSE REMODELLING TO SODIUM-GLUCOSE COTRANSPORTER 2 INHIBITORS (SGLT2I) IN PATIENTS WITH SYSTOLIC HEART FAILURE: A MULTICENTER STUDY

Alberto Giannoni (a, b), Maria Concetta Pastore (c), Paolo Sciarrone (a, b), Giulia Elena Mandoli (c), Anas Khalil (a, b), Claudia Taddei (a, b), Riccardo Inciardi (d), Maria Giulia Bellicini (d), Giovanni Benfari (e), Anna Piccoli (e), Matteo Lisi (f), Giovanni Andrea Luisi (f), Anna Degiovanni (g), Giuseppe Patti (g), Andrea Stefanini (c), Giuseppina Novo (h), Concetta Zito (i), Cesare De Gregorio (i), Annalisa Pasquini (j), Michele Correale (k), Pietro Mazzeo (l), Federico Guerra (n), Ciro Santoro (m), Matteo Cameli (c)
(a) HEALTH SCIENCE INTERDISCUPLINARY CENTER, SCUOLA SUPERIORE SANT'ANNA, PISA, ITALY; (b) CARDIOLOGY AND CARDIOVASCULAR DEPARTMENT, FONDAZIONE TOSCANA G.MONASTERIO, PISA, ITALY; (c) DEPARTMENT OF MEDICAL BIOTECHNOLOGIES, DIVISION OF CARDIOLOGY, UNIVERSITY OF SIENA, SIENA, ITALY; (d) DEPARTMENT OF MEDICAL AND SURGICAL SPECIALTIES, RADIOLOGICAL SCIENCES AND PUBLIC HEALTH, UNIVERSITY OF BRESCIA, BRESCIA, ITALY; (e) SECTION OF CARDIOLOGY, DEPARTMENT OF MEDICINE, UNIVERSITY OF VERONA, VERONA, ITALY; (f) DEPARTMENT OF CARDIOVASCULAR DISEASE-AUSL ROMAGNA, DIVISION OF CARDIOLOGY, OSPEDALE S.MARIA DELLE CROCI, RAVENNA, ITALY; (g) DEPARTMENT OF THORACIC, HEART AND VASCULAR DISEASES, MAGGIORE DELLA CARITÀ HOSPITAL, NOVARA, ITALY; (h) DIVISION OF CARDIOLOGY, DEPARTMENT OF HEALTH PROMOTION, MOTHER AND CHILD CARE, INTERNAL MEDICINE AND MEDICAL SPECIALTIES (PROMISE), UNIVERSITY HOSPITAL PAOLO GIACCONE, UNIVERSITY OF PALERMO, ITALY; (i) CLINICAL AND EXPERIMENTAL MEDICINE DEPARTMENT, CARDIOLOGY UNIT, UNIVERSITY OF MESSINA, ITALY; (j) DEPARTMENT OF CARDIOVASCULAR AND THORACIC SCIENCES, FONDAZIONE POLICLINICO UNIVERSITARIO A.GEMELLI, IRCCS, UNIVERSITÀ CATTOLICA DEL SACRO CUORE, ROME, ITALY; (k) DEPARTMENT OF MEDICAL AND SURGICAL SCIENCES, UNIVERSITY OF FOGGIA, FOGGIA, ITALY; (l) CARDIOVASCULAR DEPARTMENT, AZIENDA OSPEDALIERA REGIONALE "SAN CARLO" POTENZA, ITALY; (m) DEPARTMENT OF ADVANCED BIOMEDICAL SCIENCE, FEDERICO II UNIVERSITY HOSPITAL, NAPLES, ITALY; (n) CARDIOLOGY AND ARRHYTHMOLOGY CLINIC, MARCHE POLYTECHNIC UNIVERSITY, ANCONA, ITALY

Introduction. Sodium-glucose cotransporter 2 inhibitors (SGLT2-i) have revolutionized the treatment of heart failure by positively impacting on hospitalization and cardiovascular mortality. This multicenter study aimed to identify predictors of left ventricular (LV) reverse remodelling (LVRR) following SGLT2-i therapy in patients with HF.
Methods. The study included patients with systolic HF (LVEF<50%) who required treatment with SGLT2 inhibitors from multiple Italian centers. Demographic, clinical, biohumoral and echocardiographic parameters were assessed as potential predictors of LVRR. LVRR was defined as a reduction in left ventricular end-systolic volume (LVESV) by ≥10% and an improvement in left ventricular ejection fraction (LVEF) by ≥10% at the 6-month follow-up.
Results. A total of 197 patients were included in this preliminary analysis (mean age of 67±14 years, 85% being male). The mean LVEF was 32.5±6.4%, and the average N-terminal pro-brain natriuretic peptide (NT-proBNP) levels were 988 [453-2215] ng/L. Most patients (95%) were on betablockers, with 28% on ACE-inhibitors/angiotensin receptor blockers (ARBs), 63% on angiotensin receptors-neprilysin inhibitors (ARNI), 80% on mineralocorticoid receptor antagonists (MRA), and 71% on loop diuretics. At the 6-month follow-up, 33% of the patients showed early LVRR. Univariate analysis identified several predictors (at baseline) of early LVRR at 6 months, including female gender, shorter time from HF diagnosis, initiation of SGLT2-i therapy during hospitalization, lower left atrial volume index, lower LVEF, lower pulmonary systolic pressure, and lower time to peak global longitudinal strain (all p<0.05). However, in the backward stepwise selection multiple logistic regression analysis, only shorter time from HF diagnosis remained an independent predictor of LVRR (p=0.04).
Conclusions. The initial findings from this multicentric study emphasize the significance of the time from HF diagnosis as a key predictor of left ventricular reverse remodeling in patients with systolic heart failure (HF) undergoing SGLT2 inhibitor therapy. These results suggest that early initiation of SGLT2 inhibitors may have a positive impact on cardiac remodeling and potentially lead to improved clinical outcomes in this patient population. These findings warrant further investigation with larger cohorts and longer follow-up periods to validate and expand upon these preliminary results.

A877: THE CHRONIC HEART FAILURE EVOLUTIONS: DIFFERENT FATES AND ROUTES

Mattia Chiesa (a), Elisabetta Salvioni (a), Michele Emdin (b), Michele Senni (e), Massimo Piepoli (c), Massimo Mapelli (a), Giuseppe Limongelli (f), Giangranco Parati (g), Piergiusepope Agostoni (a)
(a) CENTRO CARDIOLOGICO MONZINO, ITALY; (b) UNIVERITÀ DI PISA, ITALY; (c) POLICLINICO SAN DONATO, ITALY; (d) UNIVERSITÀ DI TRIESTE, ITALY; (e) AZIENDA OSPEDALIERA PAPA GIOVANNI XXIII BERGAMO, ITALY; (f) UNIVERSITÀ DI NAPOLI, ITALY; (g) UNIVERSITÀ MILANO BICOCCA, ITALY

Background. Individual prognostic assessment and disease evolution pathways in chronic heart failure (HF) are unmet needs. The application of unsupervised learning methodologies could help at: a) identification of HF patient phenotypes; b) identification of the evolution states and progression in each phenotype and c) assessment of risk of adverse event.
Methods. We retrospectively analyzed the MECKI registry including 7948 HF patients. After preliminary preprocessing, we selected 4876 patients with a minimum 2-year follow-up. We implemented a Topological Data Analysis (TDA), based on 43 variables derived from clinical, biochemical, cardiac ultrasound and exercise evaluations, to identify several patients' clusters. Thereafter, we used the trajectory analysis to describe the evolution of HF states, which is able to identify bifurcation points, characterized by different follow-up paths, as well as stopping points, i.e. specific end-stages conditions of the disease. Finally, we conducted a survival analysis to generate 5-year time-to-event curves using as study endpoint the composite of cardiovascular death, LVAD or urgent heart transplant. Findings were validated on internal (n=527) and external (n=777) populations.
Results. Nineteen patient clusters were identified by TDA. Trajectory analysis revealed a path characterized by 3 bifurcation points with 2 different follow-up path each and 4 stopping points. Clusters survival rate varied from 44% to 100% at 2 years and from 20% to 100% at 5 years, respectively. Finally, we compared the event frequency at a 5-year follow-up for each study cohort cluster with those in the validation cohorts (R =0.94 and R =0.84, p<0.001, for internal and external cohort, respectively).
Conclusions. Each HF phenotype has a specific disease progression and prognosis. The bifurcation points need attention since are followed by different disease routes as the 4 different disease end-stages which are characterized by different prognosis. These findings allow to individualize HF patient evolutions and to tailor assessment.

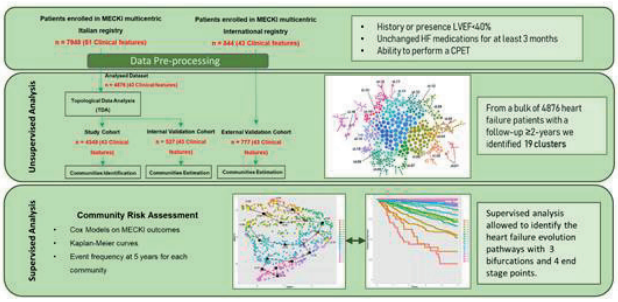

A878: IL RUOLO DEL BNP NELLA STRATIFICAZIONE PROGNOSTICA-TERAPEUTICA IN PAZIENTI CON INSUFFICIENZA CARDIACA TRATTATI CON LEVOSIMENDAN

Beatrice Simeone (a), Erica Rocco (a), Gianmarco Sarto (b), Luigi Spadafora (b), Marco Bernardi (b), Francesco Versaci (c), Sebastiano Sciarretta (a)
(a) UOC DI UTIC/CARDIOLOGIA UNIVERSITARIA, ISTITUTO ICOT DI LATINA, SAPIENZA UNIVERSITÀ DI ROMA, POLO PONTINO; (b) SCUOLA DI SPECIALIZZAZIONE IN MALATTIE DELL'APPARATO CARDIOVASCOLARE, SAPIENZA UNIVERSITÀ DI ROMA; (c) UOC DI CARDIOLOGIA, UTIC ED EMODINAMICA, OSPEDALE SANTA MARIA GORETTI, LATINA

Introduzione. Ad oggi non è noto quale sia il subset ottimale di pazienti affetti da scompenso cardiaco che possano beneficiare maggiormente del trattamento con levosimedan e quali marker correlino con la valutazione dell'efficacia terapeutica nei singoli pazienti.
Obiettivo: L'obiettivo dello studio è stato ricercare parametri che permettano di valutare quali pazienti possano beneficiare maggiormente della somministrazione di levosimendan, in modo tale da poter trattare con questa terapia solamente i soggetti idonei ed esposti a minor rischio di complicanze o effetti collaterali.
Metodi. Sono stati analizzati retrospettivamente i dati di 95 pazienti (età media 68.3 ± 1,3 anni; FE 31,6 ± 0,8%) ospedalizzati presso l'Ospedale Santa Maria Goretti di Latina per insufficienza cardiaca acuta e severa disfunzione sistolica (FE<35%). La popolazione è stata sottoposta durante il ricovero a terapia infusionale con levosimendan per 24 ore, come da protocollo terapeutico standard. Un controllo del BNP è stato effettuato prima e dopo l'infusione del farmaco. Infine, durante la degenza, sono stati valutati parametri biometrici, clinici, ematochimici ed ecocardiografici, prima e dopo la somministrazione del levosimendan.
Risultati. Inizialmente, dall'analisi di correlazione esplorativa, è emerso che il rapporto tra i livelli di BNP prima e dopo infusione di Levosimendan (RATIO BNP pre/post) si correli negativamente con sottogruppi di pazienti che presentavano in anamnesi cardiopatia ischemica (p<0.01), diagnosi di STEMI nel passato (p<0.001) e valori di troponina sopra la mediana (p<0.001). In seguito, analisi aggiuntive di tipo paired hanno confermato una riduzione significativa dei livelli di BNP post-trattamento nell'intera popolazione, sebbene sia risultata essere meno impattante in pazienti affetti da cardiopatia ischemica e con storia di STEMI rispetto alle altre categorie di pazienti (p<0.05). Di contro, è stata dimostrata una correlazione positiva tra gruppi di pazienti affetti da malattia valvolare, cardiomiopatia dilatativa primitiva o con miocardite pregressa con la RATIO BNP pre/post somministrazione di levosimendan (p<0.001), suggerendo una migliore risposta al trattamento in questa categoria di pazienti.
Conclusioni. Il nostro studio ha evidenziato che pazienti ospedalizzati per scompenso cardiaco acuto a frazione d'eiezione ridotta con storia di STEMI, cardiopatia ischemica e livelli di troponina sopra la mediana, presentavano una riduzione minore dei livelli di BNP in seguito a infusione di levosimendan rispetto ai valori di ingresso in confronto a pazienti con cardiopatia su base non ischemica, con patologia valvolare, con cardiomiopatia primitiva o infiammatoria. Probabilmente la caduta di pressione non è ben tollerata in presenza di una malattia coronarica, in quanto vengono meno i meccanismi di compenso e di regolazione del flusso coronarico, da cui ne consegue un peggioramento della funzionalità miocardica sinistra che porta a un ridotto miglioramento dei marker di scompenso cardiaco, come il BNP. Queste evidenze contribuiranno a una nuova stratificazione prognostica-terapeutica nei pazienti con insufficienza cardiaca, ma studi futuri sono fondamentali per confermare l'associazione tra il levosimendan ed i pazienti con malattia coronarica. L'obiettivo è quindi di affinare ulteriormente la selezione dei pazienti scompensati candidati a terapia infusionale con levosimendan, al fine di trattare con questo farmaco solamente i pazienti con le caratteristiche più idonee ed esposti a minor rischio di eventi avversi.

A879: GUIDELINE-DIRECTED MEDICAL THERAPY PATTERNS IN HEART FAILURE WITH REDUCED EJECTION FRACTION: THE OPTIMA-HF REGISTRY

Christian Basile (a), Stefania Paolillo (a), Piergiuseppe Agostoni (b), Pietro Ameri (c), Savina Nodari (i), Ciro Indolfi (h), Laura Casalino (j), Franco Guarnaccia (g), Angelo Aloisio (f), Adele Lillo (e), Giuseppe Putortì (d), Gennaro Galasso (k), Federica Marzano (a), Pasquale Perrone Filardi (a)
(a) UNIVERSITÀ DEGLI STUDI DI NAPOLI "FEDERICO II"; (b) UNIVERSITÀ DEGLI STUDI DI MILANO; (c) UNIVERSITÀ DEGLI STUDI DI GENOVA; (d) AMBULATORIO DI CARDIOLOGIA, ASP REGGIO CALABRIA; (e) DISTRETTO SANITARIO N 10, ASL BARI; (f) CASA DI CURA VILLA VERDE, TARANTO; (g) ARCA CAMPANIA; (h) UNIVERSITÀ DEGLI STUDI DI CATANZARO "MAGNA GRAECIA"; (i) UNIVERSITÀ DEGLI STUDI DI BRESCIA; (j) AMBULATORIO DI CARDIOLOGIA, ASL 3 LIGURIA; (k) UNIVERSITÀ DEGLI STUDI DI SALERNO

Background. Guidelines strongly recommend treating patients with heart failure with reduced ejection fraction (HFrEF) with multiple medications proven to improve clinical outcomes, as tolerated. The degree to which gaps in medication use and dosing persist in contemporary outpatient practice is unclear.
Objectives. This study sought to characterize patterns and factors associated with use and dose of HFrEF medications in clinical practice.
Methods. The OPTIMA-HF (Optimization of Therapy in the Italian Management of Heart Failure) registry included outpatients in Italy with chronic HFrEF receiving at least 1 oral medication for management of HF. Patients were characterized by baseline use and dose of angiotensin-converting enzyme inhibitor (ACEI)/angiotensin II receptor blocker (ARB)/angiotensin receptor neprilysin inhibitor (ARNI), beta-blocker, mineralocorticoid receptor antagonist (MRA) and sodium glucose co-transporter II inhibitor (SGLT2i). Patient-level factors associated with medication use were examined.
Results. Overall, 1,291 patients from 28 ambulatory cardiology practices and university hospitals were included. Mean age was 69 ± 12 years, 23% were female, and mean EF was 32 ± 6%. Among eligible patients, 7%, 4%, 23% and 33% were not prescribed ACEI/ARB/ARNI, beta-blocker, MRA and SGLT2i therapy, respectively (Figure). When medications were prescribed, few patients were receiving target doses of ACEI/ARB (15%), ARNI (16%), and beta-blocker (17%), whereas a higher proportion were receiving target doses of MRA therapy (49%) and all were receiving target dose for SGLT2i. Among patients eligible for all classes of medication, 1% were simultaneously receiving target doses of ACE/ARB/ARNI, beta-blocker, MRA and SGLT2i. In an adjusted logistic regression model, older age, lower BMI, lower EF, ambulatory cardiology practice, atrial fibrillation, renal insufficiency, not being on cardiac resynchronization therapy, and recent HF hospitalization generally favored lower medication utilization or dose.
Conclusions. In this contemporary outpatient HFrEF Italian registry, significant gaps in use and dose of guideline-directed medical therapy remain. Multiple clinical factors were associated with medication use and dose prescribed. Strategies to improve guideline-directed use of HFrEF medications remain urgently needed, and these findings may inform targeted approaches to optimize outpatient medical therapy.

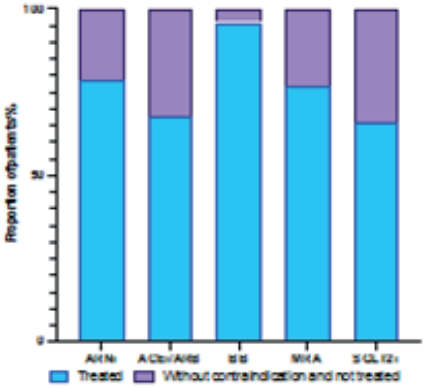

A880: PROGNOSTIC VALUE AND ASSOCIATION WITH DIASTOLIC DYSFUNCTION OF THE LEFT ATRIOVENTRICULAR COUPLING INDEX IN HEART FAILURE PATIENTS

Federico Fortuni (a, b, c), Paolo Biagioli (a), Sandra D´addario (a), Caterina Viti (a), David Mecali (a), Giovanni Russo (a), Marco Dell´uomo (a), Stefano Sforna (a), Rosanna Lauciello (a), Jeroen Bax (c), Nina Ajmone Marsan (c), Erberto Carluccio (a), Giuseppe Ambrosio (a)
(a) CARDIOLOGY AND CARDIOVASCULAR PATHOPHYSIOLOGY, SANTA MARIA DELLA MISERICORDIA HOSPITAL, UNIVERSITY OF PERUGIA, PERUGIA, ITALY.; (b) SC CARDIOLOGIA E UTIC, OSPEDALE SAN GIOVANNI BATTISTA, FOLIGNO (PG), ITALY.; (c) DEPARTMENT OF CARDIOLOGY, LEIDEN UNIVERSITY MEDICAL CENTER, LEIDEN, THE NETHERLANDS.

Background. Left atrioventricular coupling index (LACI), an index coupling left atrial (LA) to left ventricular (LV) volume at end-diastole, is a novel echocardiographic parameter that showed to be associated with poor outcomes in different clinical settings. Whether LACI reflects LV diastolic dysfunction (DD), and independently predicts outcome in heart failure (HF) remains to be investigated.
Methods. A total of 1158 hemodynamically stable HF patients (mean age 66 ± 12 years, 75% males), on optimal therapy (derivation cohort), were retrospectively included. Clinical and echocardiographic features were characterized across LACI tertiles. The independent prognostic value of LACI (primary outcome: all-cause death/HF-hospitalization) was assessed by Cox regression analyses. Results were validated in an external validation cohort of 242 HF patients.
Results. In the derivation cohort, the median value of LACI was 0.29 (IQR: 0.19-0.42). Patients in the third LACI tertile (>0.36) were older, in more advanced NYHA class, and received higher loop diuretic doses. While prevalence of grade-1 DD (ASE/EACVI classification) progressively decreased across LACI tertiles (67%, 40%, and 18% in the first, second, and third tertile, respectively P<0.0001), prevalence of grade-3 significantly increased (8%, 23%, and 46%, respectively P<0.0001). A cut-off value of ≥0.26 identified moderate-to-severe DD with a good diagnostic accuracy (AUC =0.75). During a median follow-up of 28 months (IQR: 11-53), 407 (35%) patients reached the primary endpoint. By multivariable analysis, LACI was independently associated with outcome (HR per 1-unit-increase 2.34; 95%CI 1.35-4.03; P=0.002 –Figure), and showed incremental prognostic value over DD grading system (P<0.0001). The prognostic value of LACI was consistent in the external validation cohort.
Conclusions. LACI is associated with DD severity and is an independent predictor of outcomes in HF patients.

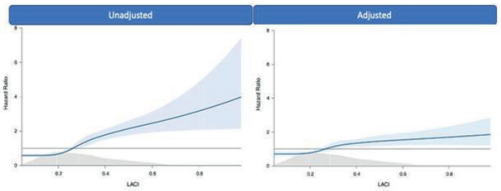

A881: RUOLO DELL'ACCOPPIAMENTO VENTRICOLO-ARTERIOSO E DELLE SUE COMPONENTI SULL'OUTCOME A LUNGO TERMINE DOPO TRAPIANTO DI CUORE

Andrea Golfetto (a), Mattia Coriano´ (a), Vincenzo Tarzia (b), Annalisa Angelini (a), Antonio Gambino (b), Chiara Tessari (b), Marny Fedrigo (c), Nicola Pradegan (b), Giuseppe Toscano (b), Sabino Iliceto (a), Gino Gerosa (b), Francesco Tona (a)
(a) DIPARTIMENTO DI SCIENZE CARDIO-TORACO-VASCOLARI E SANITÀ PUBBLICA, UNIVERSITÀ DI PADOVA, ITALIA; (b) UNITÀ DI CARDIOCHIRURGIA, DIPARTIMENTO DI SCIENZE CARDIO-TORACO-VASCOLARI E SANITÀ PUBBLICA, UNIVERSITÀ DI PADOVA, ITALIA; (c) UNITÀ DI PATOLOGIA CARDIOVASCOLARE E ANATOMIA PATOLOGICA, DIPARTIMENTO DI SCIENZE CARDIO-TORACO-VASCOLARI E SANITÀ PUBBLICA, UNIVERSITÀ DI PADOVA, ITALIA

Background. La disfunzione del graft è associata ad una prognosi sfavorevole dopo trapianto cardiaco (TC). Una diagnosi precoce di disfunzione miocardica è complessa, in quanto pazienti asintomatici spesso presentano una normale frazione di eiezione del ventricolo sinistro (FE-VS). Lo studio della relazione tra la funzione cardiaca ed il postcarico, espressa dall'accoppiamento ventricolo-arterioso (VAC), può avere un ruolo nel riconoscimento precoce di pazienti ad alto rischio di eventi avversi dopo TC.
Obiettivo: In primis, sono state confrontate le variabili derivate dalla relazione pressione-volume (P-V) tra pazienti sottoposti a TC ed un gruppo di controlli sani. In secundis, è stato indagato il ruolo del VAC e dei suoi componenti, quali elastanza arteriosa (Ea) ed elastanza ventricolare (Ees), nel determinare disfunzione del graft ed una prognosi sfavorevole.
Metodi. In questo studio di coorte osservazionale monocentrico, sono stati inclusi i pazienti sottoposti a TC sopravvissuti al primo anno dopo l'intervento ed aventi: FE-LV≥50, assenza di vasculopatia cardiaca da allotrapianto, segni di rigetto. Il VAC e gli altri parametri derivati dalla P-V sono stati misurati con un metodo non invasivo utilizzando formule semplificate e poi confrontati retrospettivamente con un gruppo di controlli sani. La sopravvivenza veniva considerata a partire dal primo anno post trapianto, e l'endpoint indagato è stato la mortalità per tutte le cause.
Risultati. Sono stati arruolati 345 pazienti dal 1985 al 2015. Il gruppo dei TC aveva un valore di VAC simile ai controlli sani (0,66 vs 0,64; p=0,7) sebbene avessero un valore più alto di Ea (2,47 vs 6,01, p=0,0001) ed Ees (1,65 vs. 3,89, p=0,0001). Inoltre, lo stroke work, l'energia potenziale e l'area P-V risultavano ridotti nel gruppo TC. Dopo una mediana di 11.3 anni di follow-up, nel gruppo TC si sono verificati 59 eventi. Non sono state notate differenze tra i pazienti con VAC elevata e ridotta (p=0,06). Al contrario, i pazienti con Ea>4 mmHg/ml ed Ees ≤6,75 mmHg/ml presentavano una prognosi peggiore. Entrambe le variabili erano indipendentemente associate ad un maggiore rischio di morte anche dopo aggiustamento (Ea>4 mmHg/ml: HR 1,8; CI 1,3-4,9; Ees ≤6,75 mmHg/ml: HR 1,8; CI 1,3 – 4,7).
Conclusioni. In pazienti sottoposti a TC con FE-LV nella norma, il VAC non differisce dai controlli sani e non è utile nello stratificare l'outcome. Tuttavia, l'analisi dei componenti del VAC ha un valore nell'identificare i pazienti a maggior rischio di prognosi sfavorevole. In particolare, un elevato valore di Ea ed un basso valore di Ees sono risultati indipendentemente associati a una prognosi inferiore dopo TC.

	Controlli (n=345)	Pazienti TC (n=345)	*p*
Ea (mmHg/ml)	1.65 (1.31-2.07)	3.89 (3.24-4.61)	**<0.0001**
Ees (mmHg/ml)	2.47 (1.86-3.23)	6.01 (4.86-7.74)	**<0.0001**
VA coupling	0.66 (0.42-0.73)	0.64 (0.54-0.71)	**0.7**
SW (mmHg.ml)	6336 (5616-8118)	3676 (3039-4452)	**<0.0001**
PE (mmHg.ml)	2070 (1620-2376)	1172 (930-1421)	**<0.0001**
PVA (mmHg. ml)	8352 (7371-9936)	4807 (3997-6036)	**<0.0001**
Efficiency (%)	75 (73-82)	75 (73-78)	**0.4**
Eed (mmHg/ml)	0.14 (0.13-0.19)	0.33 (0.26-0.40)	**<0.0001**



A882: ACCURATEZZA DELLA VALUTAZIONE ECOCARDIOGRAFICA NON INVASIVA IN PAZIENTI CON SCOMPENSO CARDIACO AVANZATO IN LISTA PER VALUTAZIONE DI TRAPIANTO CARDIACO

Francesco Morrone (a, b), Simona Pavoncelli (a, b), Andrea Stefanini (a, b), Luca Martini (a, b), Francesca Vannuccini (a, b), Alessandro Campora (a, b), Antonio Pagliaro (c), Alberto Palazzuoli (a)
(a) UNITÀ DI MALATTIE CARDIOVASCOLARI, DIPARTIMENTO CARDIO-TORACO-VASCOLARE AOUS, UNIVERSITÀ DEGLI STUDI, SIENA; (b) SCUOLA DI SPECIALIZZAZIONE IN MALATTIE DELL'APPARATO CARDIOVASCOLARE, DIPARTIMENTO DI BIOTECNOLOGIE MEDICHE, UNIVERSITÀ DEGLI STUDI, SIENA; (c) CARDIOLOGIA CLINICO-CHIRURGICA, AOU SENESE, OSPEDALE SANTA MARIA ALLE SCOTTE, SIENA.

Background. La valutazione non invasiva del riempimento diastolico mediante ecocardiografia Doppler fornisce importanti informazioni prognostiche e diagnostiche sulla funzionalità del ventricolo sinistro (LV) ed è considerata una metodica attendibile per la stima della pressione di riempimento (LVDP). Tuttavia, la reale accuratezza del rapporto E/e' nel predire la wedge pressure e il confronto con altre misure invasive ottenute durante il cateterismo cardiaco non sono state ampiamente studiate. In questo studio abbiamo valutato l'accuratezza delle velocità di riempimento transmitralico e dell'annulus mitralico, indagate rispettivamente con Doppler pulsato e Doppler tissutale, e visto che possono essere considerati parametri affidabili rispetto alle misure invasive ottenute durante il cateterismo cardiaco.
Metodi. Quarantacinque pazienti sottoposti a cateterismo cardiaco sono stati contemporaneamente studiati con eco-Doppler. Il cateterismo cardiaco destro è stato effettuato con cateteri a punta micromanometrica eseguito come screening diagnostico per l'inserimento in lista di trapianto cardiaco. Tutti i pazienti sono stati preventivamente sottoposti a screening secondo i seguenti criteri: rapporto E/e'>8, E/A>1, Pressione polmonare>35 mmHg e frazione di eiezione <35%. Le misurazioni invasive ed ecocardiografiche sono state eseguite contemporaneamente: Pressione polmonare sistolica (PAPs), Pressione polmonare media (PAPM), Wedge pressure (PAW) e pressione atriale destra (RAP) sono state misurate mediante cateterismo. I parametri di funzionalità diastolica quali onde transmitraliche E ed A, il tempo di decelerazione (DT) e il tempo di rilasciamento isovolumetrico (IVRT) sono stati misurati mediante il Doppler pulsato (PW). L'onda e' è stata misurata utilizzando il metodo TDI in sede basale-laterale e basale-settale dell'anello mitralico. La velocità di rigurgito tricuspidalico e polmonare sono state valutate rispettivamente sulla valvola tricuspide e polmonare mediante analisi del CW Doppler. Infine, sono stati valutati il diametro e la collassabilità della Vena Cava Inferiore (VCI) in proiezione sottocostale.
Risultati. Il nostro studio ha dimostrato una correlazione significativa tra PAW e E/e' laterale. Infatti, un valore di E/e' laterale>16 corrisponde a una PAW di 15 mmHg. Il rapporto E/e' settale invece correla debolmente con la PAW. Inoltre, dal nostro studio è emerso che il rapporto E/A>1 non ha correlazione significativa con le misure invasive. Al contrario, una riduzione del DT <130 msec correla significativamente con la PAW e la PAM. Il valore di IVRT <70 msec è risultato inversamente correlato alla PAW. Infine, i nostri dati hanno evidenziato che la velocità di rigurgito tricuspidalico>2.9 m/s correla con la stima della PAPs invasiva. Sebbene i pazienti con E/e' compreso tra 8 e 15 abbiano mostrato una maggiore variabilità, l'analisi simultanea di DT e IVRT è stata in grado di identificare i pazienti con valori di PAW più elevati.
Conclusioni. La valutazione del Doppler tissutale e pulsato in corrispondenza dell'annulus mitralico e la misurazione delle velocità di riempimento transmitralico permettono di identificare con accuratezza i pazienti con PAW elevata. I risultati mostrano che valori di E/e' laterale>16, un DT <130 e la velocità di rigurgito tricuspidalico aumentata sono predittori di ipertensione polmonare e potrebbero essere un ulteriore strumento diagnostico da utilizzare nei pazienti con HF avanzato.

A883: APPLICATION OF ACUTE-HF SCORE TO PREDICT IN-HOSPITAL MORTALITY IN ACUTE HEART FAILURE PATIENTS

Maria Concetta Pastore (a), Alessandro Campora (a), Giulia Elena Mandoli (a), Renzelli Andrea (a), Gabriele Olivoni (a), Mara Toscano (a), Simona Pavoncelli (a), Elvira Delcuratolo (a), Matilde Lambardi (a), Francesco Morrone (a), Luna Cavigli (a), Marta Focardi (a), Flavio D'Ascenzi (a), Serafina Valente (a), Matteo Cameli (a)
(a) DEPARTMENT OF MEDICAL BIOTECHNOLOGIES, DIVISION OF CARDIOLOGY, UNIVERSITY OF SIENA, ITALY

Background. ACUTE HF is a multiparametric score combining clinical, biochemical and echocardiographic indexes, which was developed and

validated in different studies as prognostic tool in acute heart failure (HF) patients for the prediction of 30-days, 6-months and 5-years mortality after discharge. However, in these critical patients the prediction of in-hospital mortality may be fundamental to guide therapeutic management during hospital stay. The aim of our study was to assess the prognostic value of ACUTE HF score for in-hospital mortality in an external cohort of patients hospitalized for acute HF.

Methods. Consecutive patients hospitalized for acute HF in our University Hospital were retrospectively enrolled. Patients with unclear diagnosis of de-novo, decompensated HF or HF relapse were excluded. Clinical, biohumoral and echocardiographic data were collected. ACUTE HF score was calculated as: 1.4*[serum creatinine>2mg/dl]+0.8*[ejection fraction<30]+ 0.7*[age>76]+0.7*[prior hospitalization for AHF]+0.9*[prior stroke/transient ischemic attack]+0.5*[more than moderate mitral regurgitation]+0.8*[use of non-invasive ventilation]. Then, it was used to divide the population into three risk groups (low risk: ACUTE HF ≤1.5; intermediate risk: 1.5<ACUTE HF≤3; high risk: ACUTE HF ≥3). Primary endpoint was in-hospital mortality.

Results. Overall, 1291 patients were included in the present study (age=77±13 years, mean ejection fraction =41±13%). Median in-hospital follow up was 9 [6;15] days, during which 115 patients died. Patients who died during hospitalization were older, had worse renal function and higher mitral regurgitation severity, and more frequently had arterial hypertension, diabetes mellitus, chronic obstructive pulmonary disease and history of stroke. With ROC curves, it showed to be a good predictor of in-hospital mortality, with an AUC=0.66, which was even higher in patients with preserved ejection fraction (AUC=0.76). With multivariate analysis, ACUTE HF score showed to be a predictor of in-hospital mortality independent from arterial hypertension, diabetes mellitus, chronic kidney disease (OR =1.5 [C.I. 1.22 – 1.81 each point increase]. Kaplan Meier analysis showed a good risk stratification of study cohort divided into 3 risk groups according to ACUTE HF (Fig.1)

Conclusions. ACUTE HF score is an independent and reliable predictor of in-hospital mortality in patients hospitalized for acute HF. After multiple external validation, considering its rapid and easy calculation, we suggest its use in the management algorithms of acute HF patients in daily clinical practice.

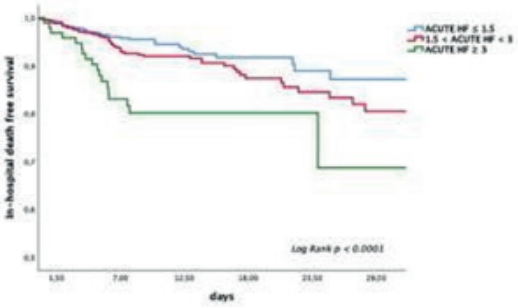

A884: DAPAGLIFLOZIN EFFECTS ON CARDIAC DEFORMATION IN HEART FAILURE WITH REDUCED AND MILDLY REDUCED EJECTION FRACTION AND SECONDARY CLINICAL OUTCOME - DAPA ECHO

Maria Concetta Pastore (b), Andrea Stefanini (b), Giulia Elena Mandoli (b), Pietro Piu (a), Maria Alma Iuliano (b), Enrico Emilio Diviggiano (b), Leonardo Carli (b), Andrea Marchese (b), Alessio Pecere (b), Luca Martini (b), Luna Cavigli (b), Marta Focardi (b), Flavio D'Ascenzi (b), Serafina Valente (b), Matteo Cameli (b)
(a) DEPARTMENT OF MEDICINE, SURGERY AND NEUROSCIENCE, UNIVERSITY OF SIENA, ITALY; (b) DEPARTMENT OF MEDICAL BIOTECHNOLOGIES, DIVISION OF CARDIOLOGY, UNIVERSITY OF SIENA, SIENA, ITALY

Background. Sodium-glucose cotransporter type 2 inhibitors (SGLT2i), particularly dapagiflozin and empagliflozin have shown to reduced morbidity and mortality heart failure (HF) patients with and without diabetes mellitus. However, the potential effects of dapagliflozin in non-diabetic patients with HFrEF and HF with mildly reduced ejection fraction (HFmrEF) on systo-diastolic function assessed by speckle tracking echocardiography (STE) has not been evaluated to date.

Methods. This randomized, prospective, single-center, open-label trial has compared, at baseline and 6 months after treatment, consecutive non-diabetic outpatients with HFrEF or HFmrEF receiving Dapagliflozin with patients treated with optimal medical therapy (OMT) except SGLT2i (since the study was planned and initiated when the latest guidelines were not released yet). Primary endpoint was the modification of left ventricular (LV) global longitudinal strain (GLS), diastolic function (as peak atrial longitudinal strain, PALS) and right ventricular (RV) function by STE from baseline to 6 months.

Results. Overall, 88 patients (38% HFrEF) were enrolled and randomized to treatment with Dapagliflozin (DAPA group=44) and to continue with OMT (OMT group=44). All STE values improved in DAPA group at 6 months follow up, while there was only a slight improvement of GLS in OMT group (Figure 1). DAPA group had a GLS mean value at follow up significantly lower compared to OMT group (-2.53, 95% confidence interval, CI =1.56; 3.5 vs. -0.13, 95% CI 0.84;1.11). Moreover, when comparing the modification of GLS at follow up in HFrEF and HFmrEF patients (Fig.1, panel A), only the main effect treatment resulted statistically significant in both groups (p<0.0001), indicating a significant difference between DAPA and OMT. There was a higher change under DAPA Treatment for HFrEF (Figure 1, panel B). The same effect was observed for fwRVLS and global PALS.

Conclusions. This study provided randomized data on the beneficial effect of Dapagliflozin in non-diabetic patients with HFrEF and HFmrEF in terms of myocardial performance measured by the most sensitive echocardiographic technique i.e. STE. This suggests its useful role to provide LV reverse remodeling and better quality of life in patients with HFrEF and HFmrEF.

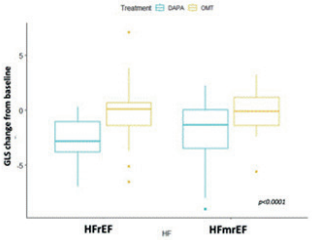

Figure 1. Panel A.

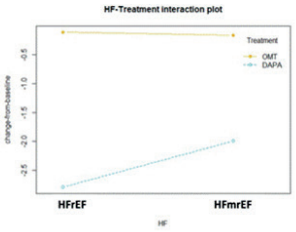

Figure 1. Panel B.

A885: DEFORMATION IMAGING BY STRAIN IN CHRONIC HEART FAILURE OVER GLIFLOZINS: AN ECHOCARDIOGRAPHIC REGISTER ON SODIUM-GLUCOSE COTRANSPORTER-2 INHIBITORS (DISCOVER SGLT2I)

Maria Concetta Pastore (b), Alberto Giannoni (a, c), Paolo Sciarrone (a, c), Giulia Elena Mandoli (b), Anas Khalil (a, c), Claudia Taddei (a, c), Riccardo Inciardi (d), Maria Giulia Bellicini (d), Giovanni Benfari (e), Anna Piccoli (e), Matteo Lisi (f), Giovanni Andrea Luisi (f), Anna Degiovanni (g), Giuseppe Patti (g), Andrea Stefanini (b), Giuseppina Novo (h), Annalisa Pasquini (j), Michele Correale (k), Pietro Mazzeo (l), Federico Guerra (m), Ciro Santoro (n), Matteo Cameli (b)
(a) HEALTH SCIENCE INTERDISCIPLINARY CENTER, SCUOLA SUPERIORE SANT'ANNA, PISA, ITALY; (b) DEPARTMENT OF MEDICAL BIOTECHNOLOGIES, DIVISION OF CARDIOLOGY, UNIVERSITY OF SIENA, SIENA, ITALY; (c) CARDIOLOGY AND CARDIOVASCULAR DEPARTMENT, FONDAZIONE TOSCANA G. MONASTERIO, PISA, ITALY; (d) DEPARTMENT OF MEDICAL AND SURGICAL SPECIALTIES, RADIOLOGICAL SCIENCES AND PUBLIC HEALTH, UNIVERSITY OF BRESCIA, BRESCIA, ITALY; (e) SECTION OF CARDIOLOGY, DEPARTMENT OF MEDICINE, UNIVERSITY OF VERONA, VERONA, ITALY; (f) DEPARTMENT OF CARDIOVASCULAR DISEASE - AUSL ROMAGNA, DIVISION OF CARDIOLOGY, OSPEDALE S. MARIA DELLE CROCI, VIALE RANDI 5, 48121, RAVENNA, ITALY; (g) DEPARTMENT OF THORACIC, HEART AND VASCULAR DISEASES, MAGGIORE DELLA CARITÀ HOSPITAL, NOVARA, ITALY; (h) DIVISION OF CARDIOLOGY, DEPARTMENT OF HEALTH PROMOTION, MOTHER AND CHILD CARE, INTERNAL MEDICINE AND MEDICAL SPECIALTIES (PROMISE), UNIVERSITY HOSPITAL PAOLO GIACCONE, UNIVERSITY OF PALERMO, ITALY; (i) CLINICAL AND EXPERIMENTAL MEDICINE DEPARTMENT, CARDIOLOGY UNIT, UNIVERSITY OF MESSINA, AZIENDA OSPEDALIERA UNIVERSITARIA ´POLICLINICO G. MARTINO,´ VIA CONSOLARE VALERIA 1, 98125, MESSINA, ITALY; (j) DEPARTMENT OF CARDIOVASCULAR AND THORACIC SCIENCES, FONDAZIONE POLICLINICO UNIVERSITARIO A. GEMELLI, IRCCS, UNIVERSITÀ CATTOLICA DEL SACRO CUORE, ROME, ITALY; (k) DEPARTMENT OF MEDICAL AND SURGICAL SCIENCES, UNIVERSITY OF FOGGIA, VIALE LUIGI PINTO 1, 71122 FOGGIA, ITALY; (l) CARDIOVASCULAR DEPARTMENT, AZIENDA OSPEDALIERA REGIONALE "SAN CARLO," POTENZA, ITALY; (m) CARDIOLOGY AND ARRHYTHMOLOGY CLINIC, MARCHE POLYTECHNIC UNIVERSITY, 60121 ANCONA, ITALY; (n) DEPARTMENT OF ADVANCED BIOMEDICAL SCIENCE, FEDERICO II UNIVERSITY HOSPITAL, NAPLES, ITALY

Background. Sodium-glucose cotransporter type 2 inhibitors (SGLT2i) have revolutionized the treatment of heart failure (HF) and are currently recommended as first-line therapy for HF with reduced ejection fraction (HFrEF). These drugs have shown to reduce HF mortality and cardiovascular events, mainly due to favorable effects on myocardial remodeling and hemodynamics. Speckle tracking echocardiography (STE) is an accurate technique to quantify functional and structural modifications of all cardiac chambers, overcoming many limitations of basic echocardiographic indices. The aim of this analysis from the multicenter register DISCOVER-SGLT2i was to describe the changes of myocardial deformation ("strain") by STE in patients undergoing therapy with SGLT2i.

Methods. The prospective, multi-center, Italian study DISCOVER-SGLT2i (ClinicalTrial.gov identifier: NCT 05344963), which is currently ongoing, has been enrolling patients with acute or chronic HFrEF receiving therapy with SGLT2i dapagliflozin and empagliflozin in adjunction to optimal guideline-directed therapy for HF. Patients starting sacubitril/valsartan <6 months are excluded. Clinical, biohumoral and echocardiographic evaluation completed by STE of all cardiac chambers are performed at baseline and after 6 months and 12 months follow up, then, long-term clinical follow-up is planned to assess cardiovascular events (Fig.1). The

primary endpoint of this preliminary analysis was to evaluate the early modification of left ventricular (LV), left atrial (LA) and right ventricular (RV) strain by STE after 6 months of therapy with SGLT2i.
Results. Overall, 226 patients were included in this analysis (187 treated with dapagliflozin, 37 with ±empagliflozin). Mean age was 66 ± 13 years, 86% (n=195) were male. At baseline, mean ejection fraction was 30 ± 8%, mean LA volume was 98±34 ml and median N-terminal pro-brain natriuretic peptide (NT-proBNP) was 955 [interquartile range=455, 2100] pg/ml. Patients showed an early improvement of LV and LA volumes, LV ejection fraction and pulmonary artery pressures. As concerning STE parameters, patients had reduced values of global longitudinal strain (GLS, -9.3 ± 3.4%), peak atrial longitudinal strain (PALS, 15.2 ± 8%), peak atrial contraction strain (8.23 ± 3.6%) and free wall RV strain (-18.7 ± 6.1%) at baseline. An early improvement of at more than 10% was shown for all strain values after 6 months of treatment with SGLT2i.
Conclusions. the results of our analysis suggest early reverse remodelling of all cardiac chambers after therapy with SGLT2i in patients with HFrEF on a multicenter basis. STE may be useful to assess response to treatment in patients undergoing SGLT2i. However, assessment in larger cohorts is warranted to confirm these findings.

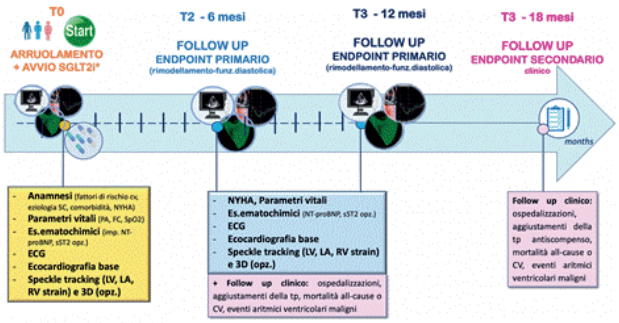

A886: SGLT2I AND IRON METABOLISM: PREDICTORS OF CARDIAC REMODELLING IN HEART FAILURE WITH REDUCED EJECTION FRACTION

Anna Piccoli (a), Giovanni Benfari (a), Annalisa Castagna (b), Annachiara Benini (a), Elisa Antinori (b), Eleonora Bonvicini (a), Elena Maria Santina Jannello (a), Giulia Urbani (a), Domenico Girelli (c), Flavio Ribichini (a)
(a) DIVISION OF CARDIOLOGY, CARDIO-THORACIC DEPARTMENT, SCHOOL OF MEDICINE, UNIVERSITY HOSPITAL OF VERONA, VERONA, ITALY; (b) DEPARTMENT OF MEDICINE, SECTION OF INTERNAL MEDICINE, UNIVERSITY OF VERONA AND AZIENZA OSPEDALIERA UNIVERSITARIA INTEGRATA VERONA, VERONA, ITALY; (c) DEPARTMENT OF MEDICINE, SECTION OF INTERNAL MEDICINE, EUROBLOODNET CENTER, UNIVERSITY OF VERONA AND AZIENDA OSPEDALIERA UNIVERSITARIA INTEGRATA VERONA, VERONA, ITALY

Background. Sodium/glucose cotransporter 2 inhibitors (SGLT2i) have modified heart failure's therapy and prognosis. Their contribution to cardiac reverse remodelling and the merging effects on iron metabolism could be the substrate of the reduction in cardiovascular morbidity and mortality. Aim of our study was to prospectively analyse biochemical, clinical and echocardiographic parameters at 6 months follow-up in comparison to baseline in a cohort of consecutive patients with heart failure with reduced ejection fraction (HFrEF) treated with SGLT2i, and to identify independent predictors of cardiac reverse remodelling at follow-up.
Methods. We enrolled 100 consecutive patients with symptomatic HFrEF, already on other optimal medical therapy, who initiated SGLT2i. We performed a comprehensive evaluation at baseline and at follow-up including medical history, physical examination, electrocardiogram, blood sampling and echocardiography.
Results. Eighty-seven completed the study protocol. Mean age was 65 years and the cause of heart failure was ischemic in 50% of cases. At follow-up we observed a minor non clinically significative decrease of systolic blood pressure, a significant decrease of renal filtration and sharp decline of NT-proBNP. Patients at follow-up had higher values of hemoglobin and red blood while iron and ferritin levels declined significantly. Interestingly hepcidin values dropped with a consistent increase of erythroferrone serum concentration. At 6 months follow-up we observed a significative reduction of end diastolic volume of the left ventricle (LV) with a consistent increase of LV ejection fraction and 8 patients showed a significant LVEF improvement leading to a theoretical escape from ICD implantation. Furthermore in our population were observed a reduction of restrictive pattern and moderate to severe mitral regurgitation. Patients had a better function of left atrium (PALS) and right ventricle (RV free wall strain). Basal levels of hepcidin was as the only independent predictor of LV reverse remodeling at multivariable analysis. If basal hepcidin was higher than 25 nmol/L patients in our population had 50% of probability to remodel.
Conclusions. This is the first in-human study that showed erythroferrone increase in HFrEF patients after SGLT2i tharapy and a strong correlation between basal levels of hepcidin and cardiac reverse remodelling, suggesting the possible role of iron metabolism and inflammation.

A887: ROLE OF SMALL NUCLEOLAR RNA SNORD3A IN HUMAN HEART FAILURE

Pina Polese (a), Roberta Paolillo (a), Stefania D´apice (a), Giacomo Gabriele Schiattarella (a), Christopher Holley (b), Danila Ioele (a), Raffaella Iaccarino (a), Alessandro Della Corte (c), Ciro Bancone (c), Giovanni Esposito (a), Cinzia Perrino (a)
(a) DIPARTIMENTO DI SCIENZE BIOMEDICHE AVANZATE UNIVERSITÀ DEGLI STUDI DI NAPOLI FEDERICO II; (b) DUKE UNIVERSITY MEDICAL CENTER; (c) UNIVERSITÀ DEGLI STUDI DELLA CAMPANIA LUIGI VANVITELLI

Background. Heart failure (HF) is a complex clinical syndrome and leading cause of mortality, morbidity and hospitalization in industrialized countries. It is particularly relevant to identify circulating biomarkers reflecting the pathological condition of the myocardium, particularly in lymphocytes extracted from peripheral blood (PBL). During the last decade, it has become evident that RNAs transcribed from non-coding regions of the genome, such as small nucleolar RNAs (snoRNAs), are implicated in the regulation of several cellular physiological and pathological processes.
Purpose. In the present study we aimed to identify novel circulating biomarkers mirroring human myocardial dysfunction in HF.
Methods. Cardiac left ventricle samples and PBLs from 8 HF patients undergoing heart transplantation and 2 control patients (CTRL) were analyzed by RNA sequencing (RNASeq) to identify transcripts that were regulated in both hearts and PBLs. Among identified RNAs, expression levels of the snoRNAs SNORD3A were confirmed by quantitative real-time PCR in heart and PBLs from HF patients and assayed in myocardial tissue samples and in PBLs isolated from 8-week-old wild type C57BL/6 mice with pressure overload-induced HF by transverse aortic constriction (TAC). Sham-operated mice (sham) were used as controls. After twelve-week-TAC (12w) or sham, mice underwent echocardiography to assess cardiac function, and cardiac samples and PBLs were collected after sacrifice. To test the role of SNORD3A in cardiomyocyte survival, H9C2 cardiomyoblasts were transfected with SNORD3A-targeted antisense oligonucleotides (ASO) and cell survival was analyzed under normoxic and hypoxic conditions.
Results. RNASeq analysis identified a small set of genes differentially expressed in the heart and PBLs from HF patients. Among them, SNORD3A was up-regulated in cardiac samples and PBLs from HF patients compared to CTRL (Fig.1, A and B). Similarly, in the mouse model of HF, rtPCR showed that SNORD3A levels were increased in both hearts and PBLs from TAC mice (Fig. 1, C and D). SNORD3A expression levels were also significantly increased in H9C2 cells exposed to in vitro hypoxia (Fig. 1E). Transfection of H9C2 with SNORD3A-specific ASO significantly reduced hypoxia-induced SNORD3A upregulation (Fig. 1 F), and reduces hypoxia-induced cell death (Fig. 1 G).
Conclusions. Ours results show that SNORD3A is a novel possible biomarker in human HF, similarly up-regulated in the heart and PBLs, induced by hypoxia and modulating cell survival.

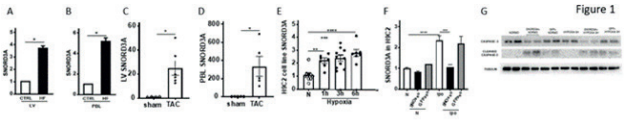

A888: HEART FAILURE PATIENTS WITH IMPROVED EJECTION FRACTION: INSIGHTS FROM THE MECKI SCORE DATABASE

Massimo Mapelli (a), Elisabetta Salvioni (a), Francesca Romana Pluchinotta (c), Arianna Galotta (a), Alice Bonomi (a), Damiano Magrì (d), Stefania Paolillo (e), Marco Metra (f), Gianfranco Sinagra (g), Irene Mattavelli (a), Massimo Piepoli (h), Piergiuseppe Agostoni (a)
(a) CENTRO CARDIOLOGICO MONZINO, IRCCS, MILANO, ITALY; (b) UNIVERSITY OF MILAN, MILANO, ITALY; (c) ASTRAZENECA, MILANO, ITALY; (d) LA SAPIENZA, UNIVERSITÀ DI ROMA, ITALY; (e) FEDERICO II, UNIVERSITÀ DI NAPOLI, ITALY; (f) UNIVERSITÀ DI BRESCIA, ITALY; (g) UNIVERSITÀ DI TRIESTE, ITALY; (h) POLICLINICO SAN DONATO, ITALY

Aims. Improvement of left ventricular ejection fraction is a major goal of heart failure (HF) treatment. However, data on clinical characteristics, exercise performance and prognosis in HF patients who improved ejection fraction (HFimpEF) are scarce. The study aimed to determine whether HFimpEF patients have a distinct clinical phenotype, biology and prognosis than HF patients with persistently reduced ejection fraction (pHFrEF).
Methods. 7948 patients enrolled in the Metabolic Exercise Cardiac Kidney Indexes (MECKI) score database were evaluated (median follow-up of 1490 days). We analyzed clinical, laboratory, ECG, echocardiographic, exercise, and survival data from HFimpEF (n=1504) and pHFrEF (n=6017) patients. The primary endpoint of the study was the composite of cardiovascular death, left ventricular assist device implantation, and urgent heart transplantation.

Results. Main results are shown in Figure 1. HFimpEF patients had lower HF severity: LVEF 44.0[41.0-47.0] vs. 29.7[24.1-34.5]%, BNP 122[65-296] vs. 373[152-888] pg/mL, hemoglobin 13.5[12.2-14.6] vs. 13.7[12.5-14.7] g/dL, renal function by MDRD 72.0[56.7- 89.3] vs. 70.4[54.5-85.3] ml/min, peakVO_2 62.2[50.7-74.1] vs. 52.6[41.8-64.3]%pred, VE/VCO_2 slope 30.0[26.9-34.4] vs. 32.1[28.0-38.0] in HFimpEF and pHFrEF, respectively (p<0.001 for all). Cardiovascular mortality rates were 26.6 and 46.9 per 1000 person-years for HFimpEF and pHFrEF, respectively (p<0.001). Kaplan–Meier analysis (Fig.2) showed that HFimpEF had better a long-term prognosis compared with pHFrEF patients. After adjustment for variables differentiating HFimpEF from pHFrEF, except echocardiographic parameters, the Kaplan–Meier curves showed the same prognosis.
Conclusions. HFimpEF represents a peculiar group of HF patients whose clinical, laboratory, ECG, echocardiographic, and exercise characteristics parallel the recovery of systolic function. Nonetheless, these patients remain at risk for adverse outcome.

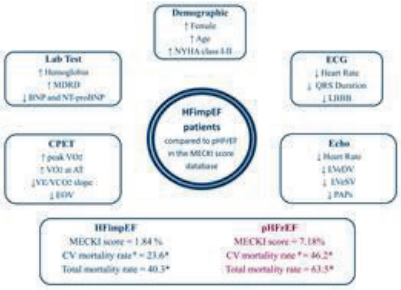

Figure 1.

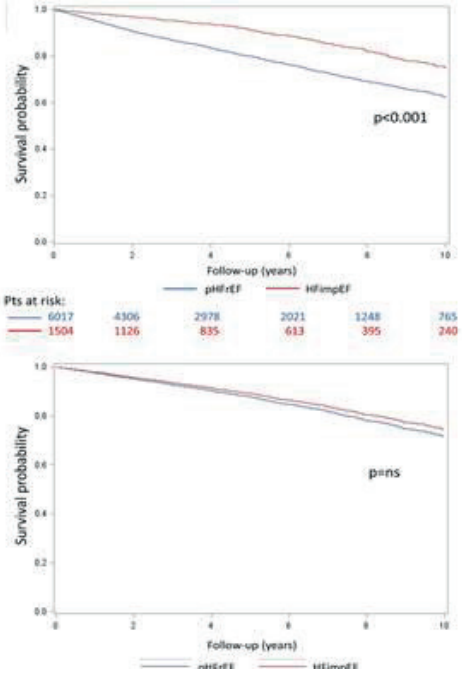

Figure 2.

A889: DAPAGLIFLOZIN EFFECT O CARDIOPULMONARY FUNCTION IN HFREF PATIENTS

Massimo Mapelli (a), Irene Mattavelli (a), Carlo Vignati (a), Elisabetta Salvioni (a), Valentina Mantegazza (a), Anna Garlaschè (a), Paola Gugliandolo (a), Teresa Maria Capovilla (b), Alessandro Marongiu (a), Gaetano Maranzano (a), Piergiuseppe Agostoni (a)
(a) CENTRO CARDIOLOGICO MONZINO, IRCCS; (b) AZIENDA SANITARIA ISONTINA (ASUGI), TRIESTE

Background. Sodium-glucose co-transporter-2 inhibitors (SGLT2i) are currently a standard therapy for patients with heart failure with reduced ejection fraction (HFrEF). This study aims to assess the effects of Dapagliflozin on exercise capacity, cardiac biomarkers, fluid retention, renal and pulmonary function.
Methods. We prospectively enrolled a cohort of stable HFrEF outpatients (left ventricular ejection fraction, LVEF<40%, New York Heart Association, NYHA, class II or III) eligible for SGLT2i therapy and performed serial cardiopulmonary exercise tests (CPET), pulmonary function tests (standard spirometry and diffusing capacity of the lungs for carbon monoxide, DLCO), laboratory and echocardiographic assessments before the beginning of treatment with Dapagliflozin and after 6 months, in order to evaluate its effects on exercise capacity, ventricular remodelling, cardiac biomarkers, fluid retention, renal and pulmonary function.
Results. 49 patients (86% males, age 64±12 years) on optimal medical therapy (84% on sacubitril/valsartan; 98% on β-blockers, 84% on MRAs) were evaluated. We observed an increase in LVEF (32.8±7.1 vs. 35.5±8.3%; p<0.001) and a reduction in left ventricular end-diastolic (EDV) and end-systolic (ESV) volumes (EDV: 209±83 vs. 199± 77 mL, p=0.004; ESV: 143±73 vs. 133± 68 mL, p<0.001). There were no significant changes in peak oxygen uptake, while ventilatory efficiency during exercise (VE/VCO_2 slope) showed a significant improvement (fig.1). Hemoglobin (Hb) and hematocrit levels improved, while renal function sodium and potassium levels remained stable, as did blood urea nitrogen, while BNP, NT-proBNP, glycated Hb, ST2, and hs-TNI did not reach statistical significance in this sub-population. NYHA functional class improved, together with a significant decrease of MECKI (Metabolic Exercise test data combined with Cardiac and Kidney Indexes) score, from 3.9% to 2.7% with a positive impact on two-year prognosis.
Conclusions. Medium-term treatment with Dapagliflozin demonstrated beneficial effects on LV remodelling, exercise ventilatory efficiency and functional status. In particular, an improvement in VE/VCO_2 slope and MECKI score paralleled with an enhancement in echocardiographic parameters and NYHA functional class was observed. However, our study did not detect medium-term effects of Dapagliflozin on spirometry values, DLCO, fluid retention and NT-proBNP. These results suggest that some favourable effects could unfold over a longer period of time. Further studies with longer follow up are desirable to assess Dapagliflozin effects even in such a well-treated HF population.

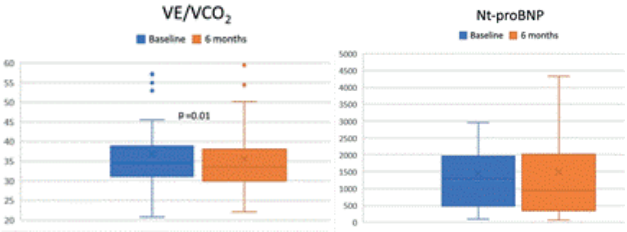

	Baseline		6 Months		p
Weight (kg)	78.39	±13.45	78.35	±13.42	0.906
FEV1 (L/s)	2.78	±0.77	2.70	±0.73	0.216
FVC (L)	3.46	±0.94	3.42	±0.91	0.952
DLCO (mL/min/mmHg)	17.08	±5.96	17.63	±6.21	0.996
Peak VO_2 (mL/min/kg)	17.10	±5.76	16.71	±5.11	0.387
Peak load (Watt)	115	±49	115	±50	0.922
VE/VCO_2	36.9	[31.1-38.4]	33.5	[30.0-37.8]	0.015
Hemoglobin (g/dL)	13.89	±1.45	14.77	±1.59	<0.001
Hematocrit (mg/dL)	40.69	±5.92	43.89	±4.14	<0.001
Creatinine (mg/dL)	1.15	±0.36	1.20	±0.36	0.117
Blood Urea Nitrogen	53.59	±20.33	52.31	±18.55	0.540
Sodium (mmol/L)	140.5	±1.9	140.7	±2.2	0.525
Potassium (mmol/L)	4.42	±0.41	4.41	±0.39	0.845

A890: SEX DIFFERENCES IN HEART FAILURE MANAGEMENT ARE MAINLY RELATED TO DISTINCT CLINICAL PROFILES RATHER THAN CULTURAL BEHAVIORS AND CLINICAL INERTIA: INSIGHTS FROM THE LARGE ITALIAN MULTICENTRE REAL-HF REGISTRY

Giuseppe Damiano Sanna (a), Gian Luca Erre (b), Matteo Cameli (c), Federico Guerra (d), Maria Concetta Pastore (c), Alessandro Marini (a), Alessandro Campora (c), Pierpaolo Gironella (d), Mario Costamagna (d), Giulia Elena Mandoli (c), Mirko Casiraghi (a), Gavino Casu (a), Martino Deidda (e), Christian Cadeddu Dessalvi (e)
(a) CLINICAL AND INTERVENTIONAL CARDIOLOGY, SASSARI UNIVERSITY HOSPITAL, SASSARI (ITALY); (b) RHEUMATOLOGY UNIT, DEPARTMENT OF MEDICINE, SURGERY AND PHARMACY, AOU AND UNIVERSITY OF SASSARI (ITALY); (c) UNIVERSITY OF SIENA, DIVISION OF CARDIOLOGY, DEPARTMENT OF MEDICAL BIOTECHNOLOGIES, SIENA (ITALY); (d) MARCHE POLYTECHNIC UNIVERSITY OF ANCONA, CLINICA DI CARDIOLOGIA ED ARITMOLOGIA, DIPARTIMENTO DI SCIENZE BIOMEDICHE E SANITÀ PUBBLICA, ANCONA (ITALY); (e) UNIVERSITY OF CAGLIARI, DEPARTMENT OF MEDICAL SCIENCES AND PUBLIC HEALTH, CAGLIARI (ITALY)

Purpose. Heart failure (HF) is a major healthcare problem affecting 1-2% of adults, especially the elderly. There are marked sex differences and women, traditionally underrepresented in clinical trials, are also considered to be often undertreated. However, it is not clear whether such differences are due to cultural behaviors and clinical inertia, or if they simply reflect different clinical profiles and the impact of sex on hard clinical outcomes. We aimed to analyze the sex-related differences in patients hospitalized for HF in Italy.

Methods. We analyzed data of 4016 adult patients hospitalized for HF in the period 2020-2021 and enrolled in a large multicenter national registry (REAL-HF). Data were derived from discharge letters and electronic hospital records.
Results. Women (n=1818 [45%]) were older than men (83 vs 77 years, p<0.0001), with a higher prevalence of arterial hypertension (73% vs 69%, p=0.011) and atrial fibrillation. Ischemic aetiology of HF was prevalent in men (44% vs 24%). Women presented more often with HF and preserved ejection fraction – HFpEF (55% vs 32%, p<0.001), while a reduced ejection fraction – HFrEF was more common in men (49% vs 25%, p<0.001). Hospitalizations probably reflected these different clinical profiles, with women more often hospitalized in internal medicine departments (71% vs 51%), and men in highly specialized cardiology units (49% vs 29%). However, when considering specific HF medical treatments and prescriptions in the HFrEF subgroup (n=1525), there were no significant differences (49% of women treated with guideline-directed medical therapy – GDMT vs 52% of men, p=0.197). In terms of outcomes, sex was not associated neither with hospital readmissions (30-days OR[95% CI] =0.89 [0.69-1.16], p=0.407; 1-year OR[95% CI] =1.05 [0.89-1.24], p=0.536) nor with mortality (in-hospital OR[95% CI] =0.97 [0.68-1.38], p=0.876; 1-year OR[95% CI] =1.05 [0.86-1.30], p=0.620).
Conclusions. Women and men hospitalized for HF exhibited distinct clinical profiles. This may have had an impact on patients admissions (cardiology units vs internal medicine departments) and medical prescriptions. However, when considering homogenous groups (e.g., HFrEF) women were not undertreated. Moreover, sex was not associated with worse clinical outcomes. Our findings suggest that the suboptimal treatment of women and their adverse outcomes probably represents a misperception largely attributable to different clinical profiles.

A891: EFFECTS OF SACUBITRIL–VALSARTAN THERAPY ON GLOBAL MYOCARDIAL WORK AND FUNCTIONAL MITRAL REGURGITATION

Stefano Sforna (a), Paolo Biagioli (a), Federico Fortuni (b), Anna Mengoni (a), Daniela Grassano (a), Alessandro Lupi (a), Chiara Belardinelli (a), Eugenio Trovarelli (a), Benedetta Casini (a), Cinzia Zuchi (a), Giuseppe Ambrosio (a), Erberto Carluccio (a)
(a) CARDIOLOGY AND CARDIOVASCULAR PATHOPHYSIOLOGY, SANTA MARIA DELLA MISERICORDIA HOSPITAL, UNIVERSITY OF PERUGIA, ITALY; (b) DEPARTMENT OF CARDIOLOGY, SAN GIOVANNI BATTISTA HOSPITAL, FOLIGNO, ITALY

Background. Sacubitril/valsartan therapy has been shown to improve functional mitral regurgitation (MR) severity. The noninvasive assessment of left ventricular (LV) myocardial work (MW) by pressure-strain loops analysis (PSL) is a new tool for the evaluation of myocardial performance. The aim of this study was to evaluate the effects of sacubitril/valsartan on LV MW and whether these effects are associated with improvement in MR severity in heart failure (HF) patients.
Methods. Forty-eight chronic HF patients with LV ejection fraction ≤40% (mean age 63±13 years), in which sacubitril/valsartan therapy was started and no other HF treatment was expected to change, were prospectively evaluated. Echocardiography was performed before and 8-12 months after sacubitril/valsartan therapy. Myocardial work was estimated using custom software of the GE ultrasound system both at baseline and follow-up.
Results. At follow-up, a significant reduction in LV and atrial volumes, as well as an improvement in LV ejection fraction (29.0±8 vs. 38.9±11.5%, P<0.0001) was observed. Mean effective regurgitant orifice area was also reduced (-0.078±0.13 cm2, P<0.001). Global constructive MW significantly increased (885.2±304.8 vs. 1170.2±422.1 mmHg%, P<0.0001), as well as the number of patients with global work efficiency>90% (13% vs. 44%, P<0.05), with a nonsignificant decrease in global wasted work (155.5±78.1 vs. 150.9±79.7 mmHg%, P=0.692). There was a significant relationship between the improvement in global constructive MW and the reduction in the effective regurgitant orifice area (beta -0.53, P<0.001).
Conclusions. In patients with HF with reduced EF, sacubitril/valsartan improves global constructive MW and myocardial efficiency. These effects are associated with improvement in functional mitral regurgitation severity.

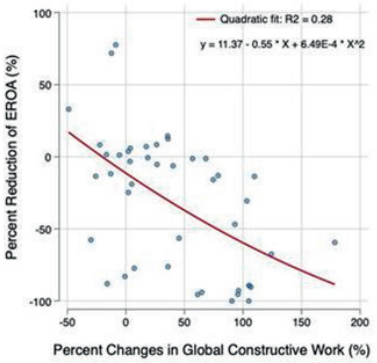

A892: SACUBITRIL/VALSARTAN EFFECTS ON RIGHT VENTRICULAR-PULMONARY ARTERIAL COUPLING IN HEART FAILURE WITH REDUCED EJECTION FRACTION ACCORDING TO LEFT VENTRICULAR REMODELING AND FILLING PRESSURES

Stefano Sforna (a), Erberto Carluccio (a), Frank L. Dini (b), Michele Correale (c), Giuseppe Dattilo (d), Michele Ciccarelli (e), Daniele Masarone (h), Stefano Ghio (i), Valentina Mercurio (j), Natale Daniele Brunetti (c), Savina Nodari (f), Giuseppe Ambrosio (a), Alberto Palazzuoli (g)
(a) CARDIOLOGY AND CARDIOVASCULAR PATHOPHYSIOLOGY, UNIVERSITY OF PERUGIA, ITALY; (b) CARDIAC, THORACIC AND VASCULAR DEPARTMENT, UNIVERSITY OF PISA, ITALY; (c) DEPARTMENT OF CARDIOLOGY, UNIVERSITY HOSPITAL FOGGIA, ITALY; (d) DPT. OF CLINICAL AND EXPERIMENTAL MEDICINE SECTION OF CARDIOLOGY, UNIVERSITY OF MESSINA, ITALY; (e) CHAIR OF CARDIOLOGY, DEPT. OF MEDICINE, SURGERY AND DENTISTRY, UNIVERSITY OF SALERNO, ITALY; (f) DEPARTMENT OF CARDIOLOGY, UNIVERSITY OF BRESCIA AND ASST SPEDALI CIVILI DI BRESCIA, ITALY; (g) CARDIOVASCULAR DISEASES UNIT, DEPARTMENT OF INTERNAL MEDICINE, UNIVERSITY OF SIENA, ITALY; (h) HEART FAILURE UNIT, AORN DEI COLLI, MONALDI HOSPITAL, NAPLES, ITALY; (i) DIVISION OF CARDIOLOGY, FONDAZIONE I.R.C.C.S. POLICLINICO SAN MATTEO, PAVIA, ITALY; (j) DEPARTMENT OF TRANSLATIONAL MEDICAL SCIENCES, FEDERICO II UNIVERSITY, NAPLES, ITALY

Background. Impaired right ventricular (RV) function coupled with progressive uncoupling of the pulmonary artery (PA) represents an important determinant of heart failure (HF) progression with negative consequences on prognosis. The ratio between tricuspid annular plane systolic excursion (TAPSE) to pulmonary artery systolic pressure (PASP) is generally used as a measure of RV-to-PA coupling in patients with heart failure with reduced ejection fraction (HFrEF).
Aim. To evaluate the effect of sacubitril/valsartan treatment on TAPSE/PASP in patients with HFrEF.
Methods. In this multicenter, open-label study, 735 HFrEF outpatients underwent comprehensive echocardiography at baseline (before starting sacubitril/valsartan) and after 8-12 months. Left ventricular reverse remodeling (LVRR) was defined by reduction in ESVI ≥15% from baseline. According to changes in LV filling pressure (LVFP), patients were grouped as follows: A) Stable-Low-LVFP [at baseline and follow-up]; B) improved-LVFP; c) Worsened-LVFP; D) Stable-High-LVFP.
Results. After 1 year of treatment with sacubitril/valsartan, TAPSE/PASP ratio significantly increased in the overall population (from 0.61±0.28 to 0.66±0.31, P<0.0001). Although the improvement in TAPSE/PASP was greater in patients with LVRR (n=214, from 0.61±0.28 to 0.71±0.27, P<0.0001), it was also appreciable in those without LVRR (n=521, from 0.60±0.28 to 0.64±0.32, P<0.0001). TAPSE/PASP ratio improved in patients with Stable-Low/Improved-LVFP (n=649; from 0.63±0.28 to 0.70±0.30, P<0.0001), but it worsened in patients with stable-High/worsened-LVFP (n=86, from 0.41±0.19 to 0.36±0.12, P=0.001).
Conclusions. Sacubitril/valsartan improves RV-PA coupling in patients with HFrEF. This effect seems to be mainly a result of reduced LV filling pressure, rather than a result of LV reverse remodeling.

A893: SYNERGIC EFFECTS ON NTPROBNP LEVELS BY ARNI AND SGLT2-I COMBINATION THERAPY IN HFREF

Marco Stracqualursi (a), Giulia Nemola (a), Silvia Moscardelli (a), Gloria Santangelo (c), Federica Valli (c), Andrea Faggiano (a), Filippo Toriello (c), Stefano Buratti (b), Maurizio Losito (b), Stefano Carugo (a, c), Marco Guazzi (a, b), Francesca Bursi (a, b)
(a) UNIVERSITY OF MILAN; (b) DIVISION OF CARDIOLOGY, SAN PAOLO HOSPITAL, DEPARTMENT OF HEALTH SCIENCES, UNIVERSITY OF MILAN; (c) FONDAZIONE IRCCS CA'GRANDA OSPEDALE MAGGIORE POLICLINICO, CARDIAC UNIT, UNIVERSITY OF MILAN

Background. Among patients with heart failure with reduced ejection fraction (HFrEF) Sacubitril/Valsartan (SV) improves outcomes, reduces NTproBNP levels and improves heart function. Sodium-Glucose Cotransporter-2 inhibitors (SGLT2i) favorably impact on mortality and HF hospitalization. However, the mechanisms responsible for these benefits remain to be elucidated. Whether they influence neurohumoral regulation in patients receiving optimized therapy including SV have not yet been examined.
Aims. In a real-life population of outpatients with HFrEF we aimed to examine, the changes of NTproBNP after the introduction of SV and after treatment with both SV and SGLT2i.
Methods. We collected medical reports, echocardiographic data and NTproBNP levels at baseline, before SV introduction in all patients and at follow-up. We compared two groups one receiving SV only, the other SV + SGLT2i. We excluded patients who discontinued SV within 6 months of introduction and those who did not complete at least 6 months of follow-up with either drug.
Results (Figure 1): 137 HFrEF patients (mean age 69 years±12, left ventricular ejection fraction (LVEF) 29±6%) received optimal medical therapy and all were treated with Sacubitril/Valsartan (100% of patients) for at least 6 months. In 48 (35%) patients SGLT2i were also introduced, while in 89 (65%) patients were not. At baseline, NTproBNP was similar the two groups (median of 1823 [IQR 836-4222] in SV group, 1405 [IQR 629-3250] in SV+SGLT2i group, p=0.184). NTproBNP impro-

ved in both groups after therapy initiation. The median reduction of NTproBNP levels in the total population was 950 pg/ml (IQR 127-1950). At follow-up, compared to patients receiving only SV, those treated with both drugs showed a trend for lower NTproBNP levels (median 758 in SV group vs 460 pg/ml in SV+SGLT2i, p=0.08) and greater reduction (median 571 [IQR 15-1323] and 1352 pg/ml [IQR 800-3750] respectively; p<0.001).
Conclusions. In HFrEF patients, the combined treatment with SGLT2 inhibitors and SV showed a better modulatory effect on proBNP levels. This finding suggests a synergistic activity effect on the natriuretic peptide pathway and provides new evidence on the positive results observed on hard endpoints.

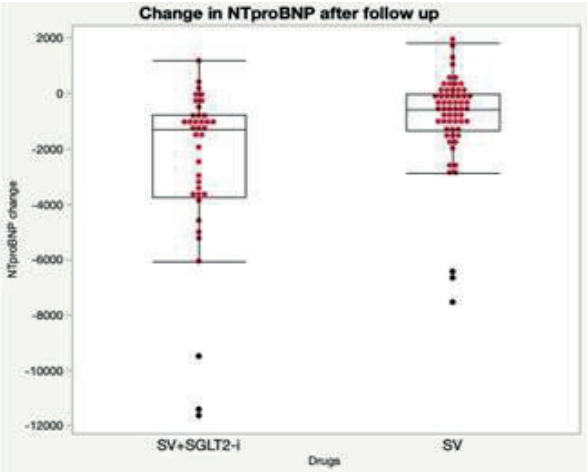

Figure 1. Change in NTproBNP at follow up among SV+SGLT2i group versus SV alone group.

A894: ELEGIBILITY FOR SACUBITRIL/VALSARTAN IN ITALIAN CLINICAL PRACTICE: INSIGHTS FROM THE OPTIMA-HF REGISTRY

Ermanno Nardi (a), Stefania Paolillo (a), Stefano Carugo (b), Giuseppe Patti (c), Gianfranco Sinagra (d), Roberta Montisci (f), Natale Daniele Brunetti (g), Giosuè Santoro (e), Ferdinando Ferrara (e), Federica Marzano (a), Pasquale Perrone Filardi (a)
(a) UNIVERSITÀ DEGLI STUDI DI NAPOLI "FEDERICO II"; (b) UNIVERSITÀ DEGLI STUDI DI MILANO; (c) UNIVERSITÀ DEL PIEMONTE ORIENTALE; (d) UNIVERSITÀ DEGLI STUDI DI TRIESTE; (e) ARCA CAMPANIA; (f) UNIVERSITÀ DEGLI STUDI DI CAGLIARI; (g) UNIVERSITÀ DEGLI STUDI DI FOGGIA

Background. Guidelines strongly recommend patients with heart failure with reduced ejection fraction (HFrEF) be treated with multiple medications proven to improve clinical outcomes, as tolerated. Among them, angiotensin receptor blocker/neprylisin inhibitor (ARNi) are the foundation of neuro-hormonal blockade in patients with HFrEF, however the degree to which gaps in this medication use and dosing persist in outpatient practice is unclear.
Objectives. To assess the proportion of patients with HFrEF who are eligible for ARNi based on the PARADIGM-HF trial criteria and the association between eligibility and baseline characteristics.
Methods. The OPTIMA-HF (Optimization of Therapy in the Italian Management of Heart Failure) registry included outpatients in Italy with chronic HFrEF receiving at least 1 oral medication for management of HF. Patients were characterized by baseline use and dose of angiotensin-converting enzyme inhibitor (ACEI)/angiotensin II receptor blocker (ARB)/ARNI, beta-blocker, mineralocorticoid receptor antagonist (MRA) and sodium glucose co-transporter II inhibitor (SGLT2i). Patient-level factors associated with medication use were examined.
Results. Outpatients with HFrEF from 28 ambulatory cardiology practices and university hospitals in the OPTIMA-HF registry recruited between January 2022 and September 2023 were included. Of 1291 patients, 1018 (79%) met the PARADIGM-HF criteria and 949 of them (93%) were on ARNi. Of the enrolled patients, 342 (27%) were not on ARNi, however only 129 (38%) did not met the PARADIGM-HF inclusion criteria for ARNi prescription. Reasons for not meeting PARADIGM-HF criteria were no beta-blocker background therapy (22%), hyperkalemia (4%), hypotension (15%), chronic kidney disease (65%) and hyperkalemia (79%). In a logistic regression model not being on ARNi was associated with older age, chronic kidney disease, not being on cardiac resynchronization therapy, lower systolic blood pressure, lower BMI, and higher PAPs (Figure), representing the picture of a more fragile patient net of compliance with the PARADIGM-HF criteria.
Conclusions. Among outpatients with HFrEF in the OPTIMA-HF Registry, 79% met the PARADIGM-HF criteria. Strategies to improve guideline-directed use of HFrEF medications remain urgently needed, and these findings may inform targeted approaches to optimize outpatient medical therapy.

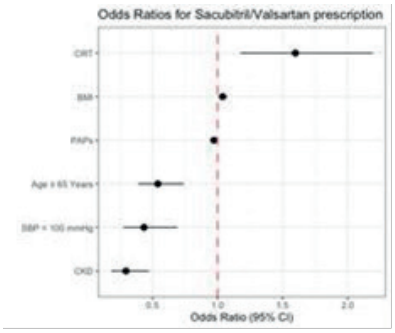

A895: ELIGIBILITY FOR SGLT2 INHIBITORS IN THE REAL-WORLD SETTING: RESULTS FROM THE OPTIMA-HF REGISTRY

Mariafrancesca Fierro (a), Stefania Paolillo (a), Erberto Carluccio (b), Federico Guerra (c), Francesco Grigioni (d), Matteo Cameli (e), Paolo Calabrò (f), Paolo Severino (g), Mauro Larcher (h), Emilia Chiuini (i), Deborah Cosmi (j), Ugo Oliviero (k), Federica Marzano (a), Pasquale Perrone Filardi (a)
(a) UNIVERSITÀ DEGLI STUDI DI NAPOLI "FEDERICO II"; (b) UNIVERSITÀ DEGLI STUDI DI PERUGIA; (c) UNIVERSITÀ POLITECNICA DELLE MARCHE; (d) UNIVERSITÀ CAMPUS BIO-MEDICO; (e) UNIVERSITÀ DEGLI STUDI DI SIENA; (f) UNIVERSITÀ DEGLI STUDI DELLA CAMPANIA "LUIGI VANVITELLI"; (g) UNIVERSITÀ DEGLI STUDI DI ROMA "LA SAPIENZA"; (h) ARCA TRENTINO ALTO ADIGE; (i) AMBULATORIO DI CARDIOLOGIA, ASL UMBRIA 1; (j) CARDIOLOGIA, OSPEDALE GUBBIO-GUALDO TADINO, PERUGIA; (k) ARCA CAMPANIA

Background. Guidelines strongly recommend patients with heart failure with reduced ejection fraction (HFrEF) be treated with multiple medications proven to improve clinical outcomes, as tolerated. Among them, Sodium glucose co-transporter II inhibitor (SGLT2i) are a new addition in the guideline-directed medical therapy in patients with HF across the spectrum of ejection fraction, however the degree to which gaps in this medication use and dosing persist in contemporary outpatient practice is unclear.
Objectives. To assess the proportion of patients with HFrEF who are eligible for SGLT2i based on the common criteria of the DAPA-HF and EMPEROR-Reduced trials, as well as the association between eligibility and baseline characteristics.
Methods. The OPTIMA-HF (Optimization of Therapy in the Italian Management of Heart Failure) registry included outpatients in Italy with chronic HFrEF receiving at least 1 oral medication for management of HF. Patients were characterized by baseline use and dose of angiotensin-converting enzyme inhibitor (ACEI)/angiotensin II receptor blocker (ARB)/ARNI, beta-blocker, mineralocorticoid receptor antagonist (MRA) and SGLT2i. Patient-level factors associated with medication use were examined.
Results. Outpatients with HFrEF from 28 ambulatory cardiology practices and university hospitals in the OPTIMA-HF registry recruited between January 2022 and September 2023 were included. Of 1291 patients, 1114 (86%) met the inclusion criteria for SGLT2i prescription, reasons for not meeting criteria were hypotension (46%) and chronic kidney disease (54%), however only 741 (66%) were on SGLT2i. Of the enrolled patients, 465 (36%) were not on SGLT2i, however only 92 (20%) did not met the inclusion criteria for SGLT2i prescription. In a logistic regression model not being on SGLT2i was associated with older age, chronic kidney disease, not being on cardiac resynchronization therapy, while atrial fibrillation and hospitalization for HF in the year before enrollment were associated with higher probability of being on SGLT2i (Figure), representing the picture of a more fragile and unstable patient net of compliance with the trials inclusion criteria.
Conclusions. Among outpatients with HFrEF in the OPTIMA-HF Registry, 86% met the SGLT2i inclusion criteria, however only 66% were on therapy. Strategies to improve guideline-directed use of HFrEF medications remain urgently needed, and these findings may inform targeted approaches to optimize outpatient medical therapy.

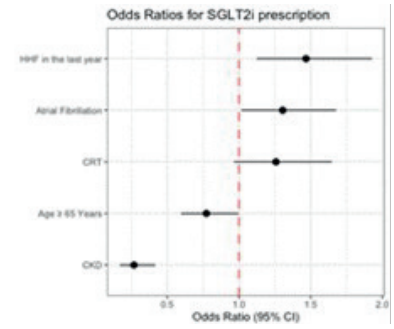

A896: PROGNOSTIC VALUE OF MYOCARDIAL BLOOD FLOW INDEX AMONG HEART TRANSPLANT RECIPIENTS

Giandomenico Bisaccia (a, b), Isabella Leo (b), Roberto Licordari (b), Maria Perotto (b), Maria Cristina Procopio (b), Giulia La Vecchia (b), Nikolaos Miaris (b), Fabrizio Ricci (a), Sabina Gallina (a), Joyce Wong (b), Chiara Bucciarelli-Ducci (b, c)
(a) UNIVERSITÀ «G. D'ANNUNZIO» DI CHIETI-PESCARA, CHIETI, ITALIA; (b) ROYAL BROMPTON AND HAREFIELD HOSPITALS, GUYS' & ST THOMAS NHS TRUST, LONDON, UNITED KINGDOM; (c) SCHOOL OF BIOMEDICAL ENGINEERING AND IMAGING SCIENCES, FACULTY OF LIFE SCIENCES AND MEDICINE, KING'S COLLEGE UNIVERSITY, LONDON, UNITED KINGDOM

Background. Quantitative stress perfusion CMR is increasingly utilized in the long-term assessment of orthotopic heart transplant (OHT) recipients. However, a precise threshold for quantitative CMR parameters to detect significant cardiac allograft vasculopathy (CAV) at index testing (i.e., invasive coronary [ICA] or computed tomography angiography [CTCA]) has not been described in this specific patient population, nor its potential prognostic value. We set out to assess the prognostic value of global myocardial blood flow index (MBFi) and myocardial perfusion reserve index (MPRi).

Methods. We retrospectively reviewed all index stress perfusion CMR studies performed in OHT patients at a large-volume center, and collected relevant demographic, clinical and CMR parameters, along with angiographic (CTCA or ICA) results. Patients were included if they underwent a diagnostic adenosine stress perfusion CMR study, along with angiography (ICA or CTCA). ROC analysis was undertaken to evaluate the accuracy and identify thresholds for quantitative CMR parameters to detect CAV. The ROC-identified thresholds were validated in survival analysis to account for time variation between CMR and index angiography. Patients were followed up for unplanned cardiac hospitalization and death and analysis of Kaplan Meier curves was performed to evaluate the prognostic value of CMR parameters.

Results. A total of 63 OHT patients were identified. Of these, 4 underwent a regadenoson study, while in 8 angiography was not available or quantitative assessment was deemed non-diagnostic. Finally, 51 patients were included in the analysis. Among these, prevalence of significant CAV on index angiography was 29.4%, and 37.8% patients were positive to donor-specific antibodies at the time of scan. Stress MBF index, but not stress MBF, was associated with the presence of significant CAV at angiography with a ROC-identified stress MBFi threshold of 2.2 (sensitivity 91.7%, specificity 57.6%). On the contrary, MPR index (p=0.122), standard MBF (p=0.11) or MPR (p=0.3) had no discriminative ability. During follow-up, 13 patients underwent cardiac hospitalization and 1 subsequently died. At Kaplan-Meier analysis, patients with a stress MBFi>2.2 remained free from cardiac hospitalization, while those with reduced stress MBFi did not (p=0.016). After adjustment for age, sex, and positivity to DSA, stress MBFi remained a powerful predictor of cardiovascular risk (adjusted HR, 0.04, 95%CI 0.00, 0.33, p=0.003).

Conclusions. Among OHT recipients undergoing CMR for suspected CAV, stress MBFi, but not MPRi or their non-indexed equivalents, was found to discriminate patients with significant CAV at angiography and at risk of future cardiac hospitalization when applying a threshold of 2.2.

A897: L'AFR NEL TRATTAMENTO DELLO SCOMPENSO CARDIACO REFRATTARIO IN ETÀ PEDIATRICA, UNA CASISTICA MONOCENTRICA

Biagio Castaldi (a), Elena Cuppini (a), Jennifer Fumanelli (a), Alice Pozza (a), Irene Cattapan (a), Francesco Prati (a), Domenico Sirico (a), Giovanni Di Salvo (a)
(a) UNIVERSITÀ DEGLI STUDI DI PADOVA - AZIENDA OSPEDALE UNIVERSITÀ DI PADOVA - UOC DI CARDIOLOGIA PEDIATRICA

Introduzione. L'Atrial Flow Regulator (AFR, Occlutech International, Helsingborg, Svezia) è un dispositivo in nitinolo autoespandibile utilizzato per stabilire una comunicazione interatriale con un diametro predeterminato. La creazione di tale shunt è consigliabile in numerose malattie cardiovascolari. Nella popolazione pediatrica, l'esperienza è limitata a pochi casi clinici che descrivono pazienti con fallimento del principio di Fontan, ipertensione polmonare o grave insufficienza cardiaca. Il nostro obiettivo è riportare l'esperienza iniziale di un singolo centro con l'impianto di AFR in bambini con malattie cardiache congenite e acquisite.

Metodi. Questa è un'analisi retrospettiva, monocentrica di pazienti pediatrici ricoverati presso il nostro istituto tra dicembre 2021 e giugno 2023. L'impianto di AFR è stato proposto a tutti i pazienti con insufficienza cardiaca sintomatica, refrattari alla terapia medica massimale e avevano una storia di patologie congenite complesse o malattie cardiache acquisite.

Risultati. Abbiamo arruolato 10 pazienti (di età compresa tra 6 mesi e 16 anni). Le indicazioni al trattamento erano: disfunzione sistolica ventricolare sinistra in 6 pazienti, cardiomiopatia restrittiva con ipertensione polmonare in 2 pazienti, disfunzione RV postoperatoria dopo riparazione chirurgica di un TOF nativo in uno, e Fontan scompensata in 1. Due pazienti erano in ECMO durante la procedura, 5 pazienti erano ricoverati in terapia intensiva ed in terapia inotropa, in 3 pazienti la procedura era stata programmata elettivamente per sintomi (classe NYHA o Ross III) ed anamnesi di>2 accessi in terapia intensiva negli ultimi 6 mesi nonostante terapia medica massimale. L'impianto di AFR è stato ottenuto con successo in tutti i pazienti. In un caso, il bambino più piccolo, abbiamo eseguito una procedura ibrida durante il bendaggio chirurgico dell'arteria polmonare, con un approccio transatriale attraverso la parete libera dell'atrio destro. In 8 casi è stata necessaria la settostomia atriale, negli altri 2 casi sono stati utilizzati PFO preesistenti e ASD fenestrato. La pre-dilatazione del palloncino è stata eseguita in 9 casi. In tutti i casi è stato impiantato il dispositivo AFR-8 mm. Il tempo medio della procedura è stato di 52 minuti, il tempo medio di fluoroscopia è stato di 17 minuti, la dose media di esposizione alle radiazioni è stata di 3,4 Gy/cm2. Non sono state riportate complicazioni durante la procedura. Non è stata osservata alcuna occlusione acuta o subacuta dello shunt, ictus o scompenso cardiaco destro di nuova insorgenza. Due pazienti sono deceduti al follow-up, tre sono arrivati a trapianto cardiaco. I rimanenti 5 pazienti sono in follow-up, con miglioramento dei sintomi e della FE (27±10% vs 42±12%, p<0,05).

Conclusione. L'impianto di AFR è sicuro e fattibile nei bambini con specifiche malattie cardiache congenite e acquisite, consentendo lo scarico delle cavità destra/sinistra e il miglioramento dell'emodinamica e dei sintomi. Nonostante il dispositivo AFR possa essere utilizzato in sicurezza anche in contesti di soccorso o di emergenza, il tasso di mortalità rimane elevato a causa dello stadio terminale di malattia e della sottostante insufficienza multiorgano.

A898: EFFICACY AND SAFETY OF DUAL DIURETIC STRATEGY IN ACUTE HEART FAILURE: A SYSTEMATIC REVIEW AND NETWORK META-ANALYSIS

Luca Gallo (a), Cristian Basile (a), Angela Colella (a), Francesca Carbone (a), Antonio Maria Parlati (a), Davide Buonocore (a), Ermanno Nardi (a), Simona Soriano (a), Luisa Simeoli (a), Chiara Di Paolo (a), Maria Francesca Fierro (a), Teresa Guarnaccia (a), Cinzia Abbate (a), Federica Marzano (a), Stefania Paolillo (a), Pasquale Perrone Filardi (a), Paola Gargiulo (a)
(a) UNIVERSITÀ DEGLI STUDI DI NAPOLI "FEDERICO II"

Background. In patients affected by chronic heart failure (HF), pharmacological treatment has been proven to favorably prognosis, however, the natural history of HF includes phases of clinical stability interrupted by episodes of acute decompensation often leading to hospitalization with need or intravenous diuretics, thus resulting in a new equilibrium with diminished functional capability. Acute decompensated HF (ADHF) is a clinical syndrome characterized by a rapid onset of symptoms and/or signs of HF leading to an unplanned hospital admission or an emergency department visit, with high mortality risk and high rates of readmission if congestion is not properly treated. Despite considerable effort in randomized controlled trials, there is no drug tested in ADHF that reduce hard endpoints, so to date the primary aim of current therapies is to stabilize the patient, reduce congestion, alleviate symptoms, and minimize the day of in-hospital stay.

Objectives. The present systematic review and network meta-analysis investigated the efficacy and safety of dual diuretic strategies compared to furosemide alone in patients admitted for ADHF.

Methods. This network meta-analysis was performed based on the PRISMA guidelines and registered on PROSPERO (CRD42022370434). PubMed and Web of Science were searched without any restrictions from inception to 25 October 2022. The primary outcome was the length of in-hospital stay. Secondary outcomes were successful decongestion and absolute weight reduction.

Results. Of 7318 papers identified in the initial research, 24 studies were included, including 22577 patients and published between 2007 and 2022. Regarding the length of hospital stay, the addition of acetazolamide (SMD -1.14, 95% CI -2.01, -0.27) and hydrochlorothiazide (SMD -1.39, 95% CI -2.70, -0.08) to furosemide significantly reduced the days of hospitalization compared to furosemide alone (Figure). Acetazolamide also had a significant impact of clinical decongestion (RR 1.38, 95% CI 1.06, 1.81), while the addition of hydrochlorothiazide led to a significant reduction in weight at discharge (SMD 823.84, 95% CI 9.56, 1638.45). The addition of Empagliflozin was associated with clinical decongestion (RR 1.33, 95% CI 1.04, 1.71) and reduced weight at discharge (SMD 1552.79 g, 95% CI 742.75, 2362.83). Regarding safety, the use of furosemide alone was associated with lower incidence of electrolytic imbalance (RR 0.47, 95% CI 0.33, 0.67) and worsening renal function (RR 0.49, 95% CI 0.26, 0.94) compared to the combination with hydrochlorothiazide.

Conclusions. Compared to furosemide alone, acetazolamide provided a significant reduction in the length of hospital stay and clinical congestion, while retaining a positive safety profile. Hydrochlorothiazide significantly reduced the length of hospital stay and weight at discharge, albeit with a significantly higher incidence of electrolytic imbalance and worsening renal function. Empagliflozin provided a significant reduction of clinical congestion and weight at discharge, however with no impact of the length of hospital stay.



A899: ROLE OF CARDIOPULMONARY EXERCISE TESTING IN PATIENTS WITH SUSPECTED HEART FAILURE WITH PRESERVED EJECTION FRACTION

Davide Lazzeroni (a), Valentina Ziveri (a), Eleonora Guazzi (a), Nicolo´ Pasini (a), Luca Moderato (a), Claudio Centorbi (a), Giovanna Cacciola (a), Umberto Camaiora (a), Simone Geroldi (a), Valerio Brambilla (a), Davide Donelli (b), Giulia Magnani (b), Filippo Luca Gurgoglione (b), Lorenzo Brambilla (a), Matteo Bini (a), Francesco Nicolini (b), Diego Ardissino (b), Giampaolo Niccoli (b)
(a) PREVENTION AND REHABILITATION UNIT, IRCCS FONDAZIONE DON GNOCCHI, PARMA, ITALY; (b) DEPARTMENT OF CARDIOLOGY, OSPEDALE MAGGIORE ED UNIVERSITÀ DI PARMA, ITALY

Background. Several millions of people are affected by heart failure with preserved ejection fraction (HFpEF), which accounts for 4.9% of the over-60 population, nevertheless, HFpEF non-invasive diagnosis is still challenging. In the presence of a non-conclusive H2FPEF score, further diagnostic evaluations are recommended such as cardiopulmonary exercise testing (CPET), since allows to define specific peripheral, cardiovascular, and ventilatory causes of exercise intolerance.
Aim. The present study aimed to evaluate CPET parameters, beyond functional capacity, useful in intermediate-to-high-risk patients' reclassification.
Methods. 896 consecutive subjects with preserved EF were enrolled. Subjects underwent cardiovascular evaluation, H2FPEF scores assessment, and cardiopulmonary exercise testing. Different cardiopulmonary responses to exercise were compared between different groups of HFpEF risk: low-risk, intermediate-to-high and definite HFpEF diagnosis.
Results. According to the H2FPEF score, 252 (28.1%) subjects had 0 points (no risk), 463 (51.7%) had 1 or 2 points (low risk), 152 (17%) had 3, 4, or 5 points (moderate-to-high risk) and 29 (3.2%) had definite HFpEF diagnosis. Both HFpEF and Intermediate-to-high-risk groups showed a lower VO2/kg at peak, cardiac output (CO) at peak, heart rate (HR) at peak (p<0.001), stroke volume (SV) at peak (p=0,022), and higher VE/VO2 peak and VE/VCO2 slope (p<0.001). Three variables showed the highest accuracy in HFpEF diagnosis: VO_2 (ml/kg/min) at peak (AUC 0,901; p<0,001), Cardiac output (CO, l/min) at peak (AUC 0,762; p<0,001), VE/VO2 at peak (AUC 0,652; p=0,004). More specifically, VO2/kg showed a moderate sensitivity of 75.9%, and a high specificity of 87.4% (AUC 0,815; p<0,001), CO at peak (AUC 0,704; p<0,001) a high specificity (89.1%) but low sensitivity (51.7%). Moreover, VE/VO2 (AUC 0,633; p=0,004) was sensitive (86.2%) with low specificity (40.5%). The composite variable included VE/VO2>32 or CO <6.5 l/min (AUC 0,650; p<0,001) and had the highest sensitivity (93.1%), resulting positive in about two-thirds of intermediate-to-high-risk subjects (figure).
Conclusions. CPET represents a useful tool in non-conclusive HFpEF diagnostic criteria patients, since, combining cardiac output and ventilatory data at peak, may allow to potentially reclassify two-thirds of intermediate-to-high-risk patients.

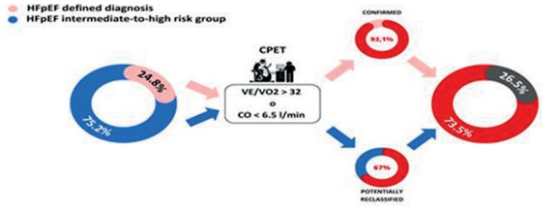

A900: IN-HOSPITAL EVOLUTION OF SECONDARY MITRAL REGURGITATION IN ACUTELY DECOMPENSATED HEART FAILURE

Daniele Cocianni (a), Maria Perotto (a), Davide Barbisan (a), Stefano Contessi (a), Jacopo Giulio Rizzi (a), Giulio Savonitto (a), Eugenio Zocca (a), Enrico Brollo (a), Elisa Soranzo (a), Antonio De Luca (a), Enrico Fabris (a), Marco Merlo (a), Gianfranco Sinagra (a), Davide Stolfo (a)
(a) UNIVERSITÀ DI TRIESTE

Background. Secondary mitral regurgitation (MR) is common in acutely decompensated heart failure (ADHF) and negatively affects prognosis. However, it can be rapidly sensitive to changes in volume status and medical interventions.
Objectives. We sought to assess the evolution of secondary MR in patients hospitalized for ADHF, and to assess the prognostic implications of in-hospital changes in MR severity.
Methods. We retrospectively enrolled 782 patients admitted for ADHF with ≥2 in-hospital echocardiographic evaluations of MR. We classified MR severity as none-mild or moderate-severe. Based on MR evolution, patients were divided into "persistent moderate-severe MR", "improved MR" (from moderate-severe to none-mild) and "persistent none-mild MR".
Results. 440 patients (56%) had moderate-severe MR at first evaluation, of whom 144 (33% of patients with baseline moderate-severe MR) had "improved MR", while 296 (67%) had "persistent moderate-severe MR". Patients with improved MR had better clinical, laboratory and echocardiographic parameters of decongestion at discharge compared to persistent moderate-severe MR subgroup. 5-years mortality was 29.4%. After adjustment, no differences in 5-years survival were observed according to baseline MR severity (HR=0.791, 95%C.I. 0.514-1.218, p=0.287). When patients were stratified according to the in-hospital changes in MR severity, improved MR was associated with lower risk of 5-years mortality, compared to both persistent none-mild MR (HR=0.505, 95%C.I. 0.271-0.943, p=0.032) and persistent moderate-severe MR (HR=0.556, 95%C.I. 0.318-0.974, p=0.040).
Conclusions. The severity of MR frequently improved during hospitalization in patients with ADHF, and this was related to less residual congestion. Consistently, in-hospital improvement in MR severity was associated with higher 5-years survival.

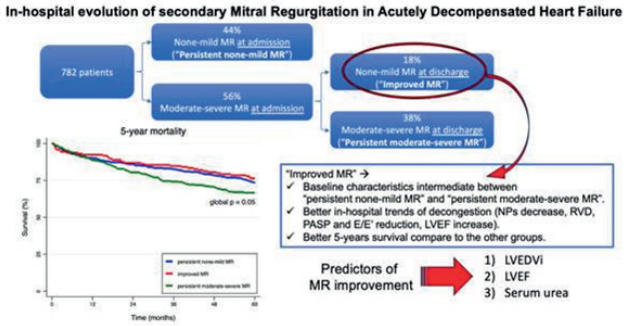

A901: IMPACT OF IMPROVED TRICUSPID REGURGITATION ON OUTCOME IN ACUTELY DECOMPENSATED HEART FAILURE

Daniele Cocianni (a), Davide Stolfo (a), Maria Perotto (a), Davide Barbisan (a), Stefano Contessi (a), Jacopo Giulio Rizzi (a), Giulio Savonitto (a), Eugenio Zocca (a), Elisa Soranzo (a), Enrico Brollo (a), Marco Merlo (a), Gianfranco Sinagra (a)
(a) UNIVERSITÀ DI TRIESTE

Background. Secondary tricuspid regurgitation (TR) has been related to higher mortality in patients admitted for acutely decompensated heart failure (ADHF). However, the severity of secondary TR can vary in response to medical therapies in the acute phase of HF management.
Objectives. We sought to assess the prevalence of improved TR and its association with the long-term risk of mortality and re-hospitalization for ADHF after discharge.
Methods. We retrospectively enrolled a series of patients admitted for ADHF who had at least 2 echocardiographic re-evaluations of TR during hospitalization (at admission and before discharge). Patients were divided into three groups: 1) "no TR" (stable trivial-mild TR at both exams); 2) "improved TR" (from moderate-severe to trivial-mild TR); 3) "persistent TR" (stable moderate-severe TR).
Results. We included 898 patients (median age 70 years, 68% males). At admission, 622 (69%) had trivial-mild TR ("no TR") and 276 (31%) had moderate-severe TR. Among patients with moderate-severe TR, 129 (47%) had improved TR, whereas 147 (53%) had persistent TR. Compared to those with improved TR, patients with persistent TR were older, more likely females, and had worse clinical characteristics and more impaired renal function. Right ventricular dysfunction and moderate-severe MR were more frequent and pulmonary artery systolic pressure higher, whereas they had less likely reduced ejection fraction. At 5-year follow-up, 275 (30.6%) patients died. After adjustment, improved TR compared to persistent TR was associated with a lower risk of 5-year all-cause death (HR=0.531, 95%CI 0.328-0.860, p=0.010) and of 5-year all-cause death/HF hospitalization (HR=0.514, 95%CI 0.342-0.772, p=0.001). The risk of 5-year all-cause death and of 5-year all-cause death/HF hospitalization was instead comparable to patients with no TR.
Conclusions. In ADHF, about 30% of patients presented with significant TR at admission, of whom 47% improved TR after stabilization. Early improvement of TR was associated with lower risk of mortality and morbidity outcomes.

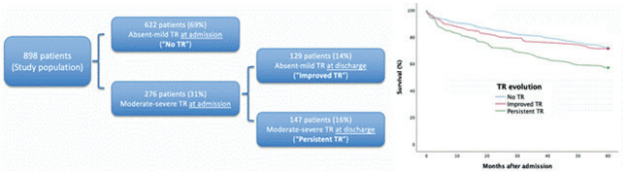

A902: CARDIOPULMONARY EXERCISE TESTING PHENOTYPING IN PATIENTS WITH DISPROPORTIONATE EXERCISE-INDUCED PULMONARY HYPERTENSION

Silvia Moscardelli (a), Marcello Rizzi (a), Irene Rusconi (a), Giulia Nemola (a), Marco Guazzi (a, b)
(a) UNIVERSITÀ DEGLI STUDI DI MILANO, MILANO; (b) OSPEDALE SAN PAOLO, ASST-SANTI PAOLO E CARLO, MILANO

Background. Heart failure with preserved ejection fraction (HFpEF), the dominant phenotype of heart failure is characterized by multiple and heterogeneous cardiac and non-cardiac abnormalities such as pulmonary hypertension (PH). Due to the worse outcome of patients with PH, it is crucial its early detection. In HFpEF patients, especially in presence of lower degrees of congestion, the development of exercise PH may not be detectable at rest. A disproportionate increase in mPAP, induced by CO augmentation during exercise, reflects an abnormal pulmonary vascular response explaining symptoms and improving therapeutic approaches.

Aims. The goal of our analysis is to evaluate CPET characteristics in patients with disproportionate exercise-induced pulmonary hypertension, with or without a positive HFA-PEFF Score.

Methods. We performed an observational, single-center study enrolling 37 patients with dyspnea. All patients performed combined CPET. We divided the patients in two group: DEi-PH (n=18) and Non DEi-PH (n=19). DEi-PH was defined by exercise-induced pulmonary hypertension as a median mPAP/CO slope greater than 1.8 mmHg/L/min (median value). Continuous variables were reported as mean ± standard deviation (SD) or median and compared with Student's t-test, based on the normality of the data. Categorical variables were compared with the Chi-square test.

Results. No significant differences of comorbidities rate were found between the two groups. At rest, there were no significant differences in LV systolic or diastolic function. Therefore, CPET allowed to better investigate the underlying pathophysiological characteristics showing that, compared with controls, non-DEi-PH (n=19) and DEi-PH (n=18) demonstrated worse exercise capacity by lower peak oxygen consumption (p=0.009), and worse ventilatory efficiency peak exercise (VE/VCO2 Slope p=0.015). [Figure: The Wasserman 9-Panel Plot of a non DEi-PH (on the left), and DEi-PH (on the right).]

Conclusions. The distinct exercise features of DEi-PH, suggest that CPET is a relevant to uncover different phenotypes in patients with similar symptoms' complain. These findings could help to generate a gas exchange score to increase the diagnostic sensitivity and clinical patients' categorization.

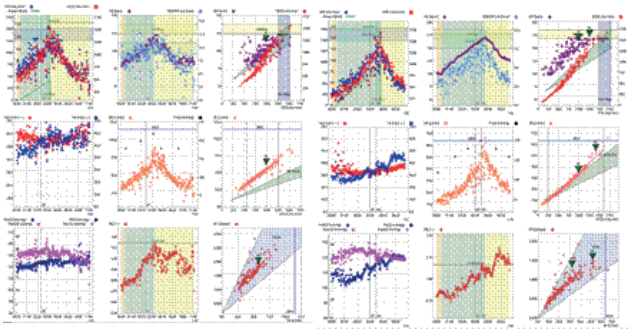

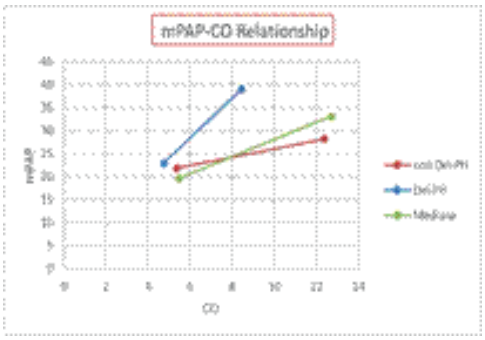

A903: HYPOCALCEMIC CARDIOMYOPATHY PRESENTING AS HEART FAILURE EXACERBATION DUE TO UNTREATED PRIMARY HYPOPARATHYROIDISM: A CASE REPORT

Alessandro Alberto Nepitella (a, b), Massimo Mapelli (a, c), Stefano Ferdico (a), Alberto Formenti (a), Andrea Baggiano (a), Jeness Campodonico (a, c), Michela Ranieri (d), Giulia Vettor (a), Matteo Sambenedetto (a, b), Cristina Basso (e), Piergiuseppe Agostoni (a, c)
(a) CENTRO CARDIOLOGICO MONZINO, IRCCS, MILANO; (b) POLICLINICO UNIVERSITARIO D. CASULA, CARDIOLOGIA - AOU CAGLIARI, CAGLIARI; (c) UNIVERSITÀ DEGLI STUDI DI MILANO, MILANO; (d) NEUROLOGIA OSPEDALE DI MELEGNANO, ASST MELEGNANO-MARTESANA, MELEGNANO (MI); (e) UOC PATOLOGIA CARDIOVASCOLARE, AZIENDA OSPEDALIERA DI PADOVA, PADOVA

Introduction. Hypocalcemic cardiomyopathy (HC) is a rare and potentially reversible cause of heart failure. Primary hypoparathyroidism, due to accidental damage to the parathyroid glands during thyroid surgery, is one of the most common causes of hypocalcemia. Identifying this etiology, in order to establish the optimal therapy, is crucial.

Case report. We report the case of a 54 y.o. man affected by arterial hypertension and hypothyroidism, who presented to our hospital for worsening dyspnea. He had undergone total thyroidectomy for thyroid cancer 20 years earlier. An echocardiogram revealed a dilated cardiomyopathy with severe left ventricular systolic dysfunction (LVEF 22%), biatrial dilatation, reduced right ventricular systolic function and elevation in pulmonary artery pressure. An ECG showed sinus rhythm, lateral and inferior repolarization abnormalities, QTc 470 msec. BNP was increased (1888 pg/ml) and troponin value was normal. Blood calcium and phosphorus values were not performed on admission. Due to the presence of heart failure exacerbation, intravenous diuretic therapy was administered with good clinical response and disease-modifying pharmacological therapy with bisoprolol, sacubitril/valsartan and eplerenone was started and gradually uptitrated. Coronary CT excluded significant coronary lesions. Cardiac MRI showed increased native T1-T2 values and an intramyocardial "patchy" distribution of late gadolinium enhancement involving the interventricular septum. Endomyocardial biopsy excluded the presence of viral DNA/RNA and signs of active inflammation. After a few days an episode of dysarthria, spatial/temporal disorientation and muscle spasms was reported. Urgent brain CT was performed, which excluded acute ischemic or hemorrhagic events, but showed diffuse basal ganglia calcification. Blood tests revealed severe hypocalcemia in the setting of primary hypoparathyroidism (total calcium 1.57 mmol/L, ionized calcium 0.61 mmol/L, PTH 8,8 pg/ml). Trousseau's sign (also known as "obstetrician's hand") was positive, suggesting the presence of latent tetany. Hypocalcemia was treated with i.v. calcium gluconate, oral calcium carbonate and calcitriol administration. QTc on ECG was 522 msec with subsequent normalization. In the following days, progressive neurological improvement and normalization of calcium values were reported. After about a week he was discharged in good clinical status. At the follow-up visits we observed a progressive improvement in biventricular systolic function with complete normalization of LVEF and ventricular volumes at 9 months.

Conclusions. HC must be suspected when a patient presents with myocardial dysfunction, neuro-muscular signs and QT prolongation on ECG. Diuretics administration, such as furosemide, may aggravate hypocalcemia by increasing urinary calcium excretion. Normalization of calcium concentration could lead to a complete recovery of cardiac function.

A904: VALUTAZIONE ULTRASONOGRAFICA DELLA CONGESTIONE CARDIACA POLMONARE E SISTEMICA IN PAZIENTI CON SCOMPENSO CARDIACO ACUTO

Alberto Palazzuoli (a), Alessandra Cartocci (c), Filippo Pirrotta (a), Maria Cristina Tavera (a), Francesco Morrone (b), Simona Pavoncelli (b), Elvira Delcuratolo (b), Alessandro Campora (b), Francesca Vannuccini (b), Gaetano Ruocco (d)
(a) UNITÀ DI MALATTIE CARDIOVASCOLARI, DIPARTIMENTO CARDIO-TORACO-VASCOLARE AOUS, UNIVERSITÀ DEGLI STUDI, SIENA; (b) SCUOLA DI SPECIALIZZAZIONE IN MALATTIE DELL'APPARATO CARDIOVASCOLARE, DIPARTIMENTO DI BIOTECNOLOGIE MEDICHE, UNIVERSITÀ DEGLI STUDI, SIENA; (c) DIPARTIMENTO DI BIOTECNOLOGIE MEDICHE, UNIVERSITÀ DEGLI STUDI SIENA; (d) U.O.C. CARDIOLOGIA, "BUON CONSIGLIO HOSPITAL" FATEBENEFRATELLI, NAPOLI.

Background. La congestione polmonare è raramente valutata ecograficamente durante scompenso cardiaco acuto (AHF). Infatti, mancano studi che valutino gli indici ecografici di congestione polmonare e sistemica durante le fasi precoci del ricovero.
Scopo dello studio. Valutare il ruolo dell'ecografia nella congestione polmonare e sistemica in una coorte di pazienti ospedalizzati per AHF; analizzare l'impatto prognostico dei parametri ecocardiografici ed ecografici polmonari tradizionali (LUS) nel predire il rischio di morte e riospedalizzazione.
Metodi. In questo studio prospettico abbiamo valutato pazienti con diagnosi di scompenso cardiaco acuto (AHF), divisi in base alla frazione di eiezione ventricolare in scompenso cardiaco a frazione di eiezione preservata (HFpEF) e ridotta (HFrEF). È stato eseguito un esame ecocardiografico e LUS entro 24 ore dal ricovero. Abbiamo stabilito uno score di congestione ecografica misurando i seguenti parametri: congestione cardiaca definita dalla presenza contemporanea di E/e'>15 e pressione polmonare sistolica (PAPS)>35 mmHg; congestione polmonare definita dalla presenza di un numero di linee B>25 all'ecografia polmonare; congestione sistemica definita dalle dimensioni della vena cava inferiore (VCI)>21 mm associata a un ridotto collasso inspiratorio (>50%).
Risultati. Abbiamo valutato 230 pazienti, 135 con diagnosi di HFrEF e 95 con diagnosi di HFpEF secondo la soglia del LVEF del 50%, 122 pazienti hanno manifestato eventi avversi durante i 180 giorni di follow-up. L'analisi delle curve ROC ha mostrato che l'escursione sistolica dell'anello tricuspidale (TAPSE) (AUC 0,34[0,26-0,41]; p<0,001), E/e' (AUC: 0,62[0,54-0,69]; p=0,003) e ICV (AUC: 0,70[0,63-0,77]; p<0,001) correlano tutti con una prognosi sfavorevole. L'analisi di regressione di Cox univariata ha rivelato che la congestione cardiaca in termini di E/e' e PAPS (HR: 1,49 [1,02-2,17]; p=0,037), TAPSE (HR: 0,90 [0,85-0,94]; p<0,001) e congestione sistemica (HR: 2,64 [1,53-4,56]; p<0,001) correlavano significativamente con l'outcome a 180 giorni. Dopo la correzione per potenziali fattori confondenti, solo TAPSE (HR: 0,92 [0,88-0,98]; p=0,005) e VCI (HR: 1,92 [1,07-3,46]; p=0,029) hanno confermato il loro ruolo prognostico. L'analisi multivariabile della congestione multipla in termini di congestione sistemica più cardiaca (HR: 1,54 [1,05-2,25]; p=0,03), sistemica più polmonare (HR: 2,26 [1,47-3,47]; p<0,001) e di tutte e tre le tipologie di congestione (HR: 1,53 [1,06-2,23]; p=0,02), ha rivelato un ruolo prognostico crescente per ciascun parametro ecografico aggiuntivo.
Conclusione. Tra gli indici ecografici di congestione, la congestione sistemica e il TAPSE correlano significativamente con una prognosi sfavorevole. L'aggiunta di parametri di congestione polmonare e cardiaca aumenta l'accuratezza della diagnosi nei pazienti a rischio. I nostri dati hanno confermato che la disfunzione ventricolare destra e la congestione sistemica sono i fattori predittivi più significativi nella AHF.

A905: RIGHT VENTRICULAR STRAIN AS PROGNOSTIC MARKER IN PATIENTS WITH HEART FAILURE RECEIVING SACUBITRIL/VALSARTAN: A SUB-ANALYSIS OF DISCOVER-ARNI, A MULTICENTER ITALIAN STUDY

Maria Concetta Pastore (a), Giulia Elena Mandoli (a), Alberto Giannoni (b), Francesca Rubina Ginetti (a), Michele Correale (c), Natale Daniele Brunetti (c), Andrea Igoren Guaricci (d), Laura Piscitelli (d), Anna Degiovanni (e), Giuseppe Patti (e), Alessandro Malagoli (f), Luca Moderato (g), Erberto Carluccio (h), Matteo Cameli (a)
(a) DEPARTMENT OF MEDICAL BIOTECHNOLOGIES, DIVISION OF CARDIOLOGY, UNIVERSITY OF SIENA, SIENA, ITALY; (b) CARDIOLOGY AND CARDIOVASCULAR MEDICINE DEPARTMENT, FONDAZIONE TOSCANA G.MONASTERIO, PISA; (c) CARDIOLOGY DEPARTMENT POLICLINICO RIUNITI UNIVERSITY HOSPITAL, FOGGIA, ITALY; (d) UNIVERSITY CARDIOLOGY UNIT, CARDIOTHORACIC DEPARTMENT, POLYCLINIC UNIVERSITY HOSPITAL, BARI, ITALY; (e) DEPARTMENT OF THORACIC, HEART AND VASCULAR DISEASES, MAGGIORE DELLA CARITÀ HOSPITAL, NOVARA, ITALY; (f) DIVISION OF CARDIOLOGY, NEPHRO-CARDIOVASCULAR DEPARTMENT, BAGGIOVARA HOSPITAL, UNIVERSITY OF MODENA AND REGGIO EMILIA, MODENA, ITALY; (g) CARDIOLOGY DEPARTMENT, OSPEDALE GUGLIELMO DA SALICETO, PIACENZA; (h) CARDIOLOGY ANDA CARDIOVASCULAR PATHOPHYSIOLOGY-HEART FAILURE UNIT, "SANTA MARIA DELLA MISERICORDIA" HOSPITAL, UNIVERSITY OF PERUGIA

Background. Angiotensin receptor/Neprilysin inhibitors (ARNI), with sacubitril/valsartan as first-in-class, have emerged as a medical treatment improving survival and clinical outcome in patients with heart failure and reduced ejection fraction (HFrEF). However, these are still recommended by European guidelines in class IB as an alternative to ACE-inhibitors and many clinicians are still reticent to prescribe ARNI as first therapy. Therefore, the identification of subjects who would most benefit from therapy with ARNI would be useful to improve the selection of patients starting these medications. The aim of this study was to assess the potential value of speckle tracking echocardiography (STE) parameters as prognostic predictors in patients undergoing therapy with ARNI.
Methods. DISCOVER ARNI multicenter Italian register retrospectively included 341 patients with HFrEF referred for therapy with sacubitril/valsartan, who underwent clinical, biohumoral and echocardiographic assessment at baseline and after 6 months of therapy. Among these patients, those who had long-term follow-up data (collected by phone calls or on-site visits) and with available STE data were included in this subanalysis. Primary endpoint was the occurrence of a composite endpoint (all-cause or cardiovascular mortality, hospitalization for heart failure, heart transplantation, left ventricular assist device (LVAD) implantation).
Results. Overall, 136 patients were included (mean age 65±10 years, 82% male, mean left ventricular (LV) ejection fraction =29±6%). Mean follow up was 40±18 months, during which 32 patients reached the primary endpoint (14 deaths of which 10 for cardiovascular reasons, 22 hospitalization, 3 heart transplantation, 1 LVAD implantation). At baseline, patients who had events showed higher LV volumes and ejection fraction (LV end-diastolic volume: 213±66 vs. 175±56ml, end-systolic volume: 156±53 vs. 123±49 ml, LV ejection fraction: 26±5 vs. 30±6%) and lower tricuspid annular plane systolic excursion, TAPSE: 17±4 vs. 19±4 mm) compared with patients without events. All STE parameters were reduced in patients with events (LV global longitudinal strain, GLS: -7.2±2.6% vs. -8.9±2.7%; global peak atrial longitudinal strain, PALS=11.4±3.8% vs. 15.2±7.3%, free-wall right ventricular longitudinal strain, fwRVLS =-15.9±5.5% vs. -19.3±5.5%). With Cox Proportional Hazard Model including LVEF, TAPSE, GLS, PALS, fwRVLS, the last emerged as the only independent predictor of the combined endpoint (odds ratio=1.12 [1.05;1.2], p=0.001). Using receiver operating characteristic (ROC) curves, fwRVLS =-20% was identified as optimal cut-off for the prediction of the combined endpoint (area under curve, AUC=0.70, Figure 1 Panel A). This was used to apply Kaplan Meier survival curves, which showed a good risk stratification of fwRVLS over long-term follow up for the primary endpoint (Figure 1, Panel B).
Conclusions. fwRVLS by STE could be a useful parameter to assess response to therapy with ARNI in terms of overall survival, HF hospitalizations, heart transplantation or LVAD implantation. This may be used ad adjunctive parameter to guide therapeutic management in patients with HFrEF.

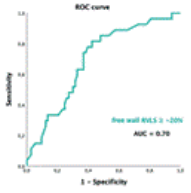

Figure1. Panel A.

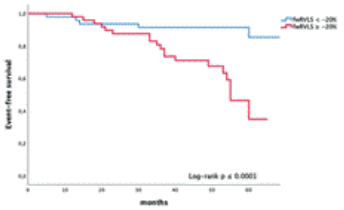

Figure 1. Panel B.

A906: EFFECTS OF SGLT2 INHIBITORS ON MYOCARDIAL DEFORMATION ECHOCARDIOGRAPHIC PARAMETERS IN PATIENTS WITH AMYLOID CARDIOMYOPATHY

Benedetto Mazza (a), Maria Concetta Pastore (a), Elisa Giacomin (a), Maria Alma Iuliano (a), Giulia Elena Mandoli (a), Luna Cavigli (a), Flavio D'Ascenzi (a), Matteo Cameli (a), Marta Focardi (a)
(a) DEPARTMENT OF MEDICAL BIOTECHNOLOGIES, DIVISION OF CARDIOLOGY, UNIVERSITY OF SIENA, SIENA, ITALY

Introduzione. Gli inibitori del cotrasportatore sodio-glucosio di tipo 2 (SGLT2i) sono raccomandati in classe I dalle linee guida internazionali per il trattamento dei pazienti con scompenso cardiaco indipendentemente dal valore di frazione di eiezione (FE) del ventricolo sinistro (VS). La letteratura disponibile in merito all'uso di SGLT2i nei pazienti con amiloidosi cardiaca è ancora scarsa. In particolare, ad oggi gli effetti della terapia con SGLT2i sulla deformazione miocardica misurata mediante ecocardiografia speckle tracking (STE), metodica più sensibile per la valutazione della funzione sisto-diastolica cardiaca, non sono ancora noti. L'obiettivo del nostro studio pilota è stato valutare la variazione dei parametri STE in pazienti con amiloidosi cardiaca sottoposti a terapia con dapagliflozin.
Metodi. Nel presente studio sono stati arruolati 21 pazienti seguiti presso i nostri ambulatori specialistici con nota amiloidosi cardiaca (sia da catene leggere sia da transtiretina), naive da SGLT2i, che presentavano segni e/o sintomi di scompenso cardiaco. I pazienti sono stati sottoposti a valutazione clinica, esami del sangue ed ecocardiografia standard e speckle tracking al basale e successivamente all'avvio del farmaco dapagliflozin. L'endpoint primario è stato la valutazione del rimodellamento inverso stimata come un cambiamento dello strain longitudinale globale (GLS) del VS, della funzione diastolica stimata mediante variazione dello

strain atriale sinistro (peak atrial longitudinal strain, PALS) e della funzione ventricolare destra stimata mediante variazione dello strain della parete libera del ventricolare destro (free wall RVLS). Come endpoint secondari sono stati registrati gli eventi clinici di morte, ospedalizzazioni per scompenso cardiaco ed insorgenza di fibrillazione atriale (FA)/flutter atriale.
Risultati. Sono stati inclusi 21 pazienti (età media di 77.4± 11.8 anni, 19 maschi, NTproBNP=2686[647; 5251]pg/ml) con amiloidosi cardiaca (15 amiloidosi da transtiretina, TTR, 6 con amiloidosi da catene leggere). Inoltre, 7 pazienti erano in terapia con tafamidis, 5 pazienti erano affetti da diabete mellito di tipo 2 e 4 da FA. Dopo un follow up medio di 5 ± 3 mesi, sono state registrate 3 ospedalizzazioni per scompenso cardiaco, 3 FA di nuova insorgenza, nessuna morte. Tra le variabili ecocardiografiche al follow-up è stato riscontrato un significativo miglioramento di tutti i parametri STE rispetto al basale: GLS -12.1 ± 4.2% vs. -10.9 ± 4%; differenza media -1.2%, p=0.03); free wall RVLS =-16.3 ± 5.6% vs. -13.7 ± 4.3%; differenza media -2,6; p=0.03); PALS (14% vs.11.8%, differenza media 2.2, p=0.002). Al contrario, parametri standard come FE VS (FE=50 ± 8.4% vs. 50 ± 8.6%), E/E' (13.8 ± 4.6 vs. 13.4 ± 4.9) e l'escursione sistolica dell'anello tricuspidale (TAPSE =17.5 ± 3.8 mm vs. 17.7 ±3.6 mm) non mostravano variazioni significative.
Conclusioni. Il nostro studio pilota suggerisce un ruolo del dapagliflozin nel miglioramento della funzione sisto-diastolica del VS e ventricolare destra in pazienti con amiloidosi cardiaca. Inoltre, i nostri risultati confermano la maggiore sensibilità dei parametri STE rispetto all'ecocardiografia basale nel rilevare la risposta al trattamento in pazienti con scompenso cardiaco. Tuttavia, tali risultati devono essere confermati in studi di numerosità maggiore.

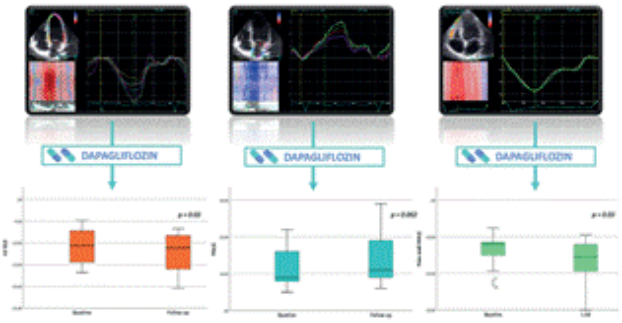

A907: MULTI-MODALITY ASSESSMENT OF CONGESTION IN ACUTE HEART FAILURE: ASSOCIATIONS WITH LEFT VENTRICULAR EJECTION FRACTION AND PROGNOSIS

Gaetano Ruocco (a), Nicolas Girerd (e), Pierpaolo Pellicori (b), Luna Gargani (c), Stefano Coiro (d), Zohra Lamiral (e), Tripti Rastogi (e), Giuseppe Ambrosio (d), Alberto Palazzuoli (f)
(a) CARDIOLOGY UNIT, BUON CONSIGLIO HOSPITAL, FATEBENEFRATELLI, NAPLES, ITALY; (b) SCHOOL OF CARDIOVASCULAR AND METABOLIC HEALTH, UNIVERSITY OF GLASGOW, GLASGOW, UK; (c) DEPARTMENT OF SURGICAL, MEDICAL AND MOLECULAR PATHOLOGY AND CRITICAL CARE MEDICINE, UNIVERSITY OF PISA, PISA, ITALY; (d) HOSPITAL SANTA MARIA DELLA MISERICORDIA, DIVISION OF CARDIOLOGY AND CENTER FOR CLINICAL AND TRANSLATIONAL RESEARCH, CERICLET, PERUGIA, ITALY; (e) UNIVERSITE DE LORRAINE, INSERM, CENTRE D'INVESTIGATIONS CLINIQUES 1433, CHRU DE NANCY, INSERM 1116 AND INI CRCT (CARDIOVASCULAR AND RENAL CLINICAL TRIALISTS),F-CRIN NETWORK, NANCY, FRANCE; (f) CARDIOVASCULAR DISEASES UNIT, CARDIO-THORACIC AND VASCULAR DEPARTMENT, LE SCOTTE HOSPITAL, UNIVERSITY OF SIENA, SIENA, ITALY

Background. Integrating clinical examination with ultrasound measures of congestion could improve risk stratification in patients hospitalized with acute decompensated heart failure (ADHF).
Aim. To investigate the prevalence of clinical, echocardiographic and lung ultrasound (LUS) signs of congestion according to left ventricular ejection fraction (LVEF) and their association with prognosis in ADHF.
Methods. We pooled the data of four cohorts of patients (N=601, 74.9±10.8 years, 59% men) with ADHF and analysed six features of congestion at enrolment: clinical (peripheral oedema and respiratory rales), biochemical (BNP/NT-proBNP>median), echocardiographic (inferior vena cava (IVC)>21mm, pulmonary artery systolic pressure (PASP)>40 mmHg, E/e'>15) and B-lines>25 (8-zones) in those with reduced (<40%, HFrEF), mildly reduced (40-49%, HFmrEF and preserved (>50%HFpEF) LVEF.
Results. Compared to patients with HFmrEF (n=110) and HFpEF (n=201), those with HFrEF (N=290) had higher natriuretic peptides, but prevalence of clinical (39%), echocardiographic (IVC>21 mm: 56%, E/e'>15: 57%, PASP>40 mmHg: 76%) and LUS (48%) signs of congestion was similar. In multivariable analysis, clinical (HR: 3.24(2.15 - 4.86), p<0.001), echocardiographic [(IVC≥21 mm (HR:1.91, 1.21 - 3.03, p=0.006); E/e'≥15 (HR:1.54, 1.04 - 2.28, p=0.031)] and LUS (HR:2.08, 1.34 - 3.24, p=0.001) signs of congestion were significantly associated with all-cause mortality and/or HF re-hospitalization. Adding echocardiographic and LUS features of congestion to a model than included age, sex, systolic blood pressure, clinical congestion and natriuretic peptides, improved prediction at 90 and 180 days.
Conclusions. Clinical and ultrasound signs of congestion are highly prevalent in patients with ADHF, regardless of LVEF and their combined assessment improves risk stratification.

A908: CORRELAZIONE TRA IPOCLOREMIA, BURDEN DI FA E MORTALITÀ IN PAZIENTI AFFETTI DA SCOMPENSO CARDIACO A RIDOTTA FRAZIONE D'EIEZIONE

Gianmarco Sarto (b), Beatrice Simeone (a), Erica Rocco (a), Luigi Spadafora (b), Marco Bernardi (b), Alessandra Roccia (c), Francesco Versaci (d), Sebastiano Sciarretta (a)
(a) UOC DI UTIC/CARDIOLOGIA UNIVERSITARIA, ISTITUTO ICOT DI LATINA, SAPIENZA UNIVERSITÀ ROMA, "POLO PONTINO"; (b) SCUOLA DI SPECIALIZZAZIONE IN MALATTIE DELL'APPARATO CARDIOVASCOLARE, SAPIENZA UNIVERSITÀ DI ROMA; (c) FACOLTÀ DI FARMACIA E MEDICINA, SAPIENZA UNIVERSITÀ DI ROMA, POLO PONTINO; (d) UOC DI CARDIOLOGIA, OSPEDALE SANTA MARIA GORETTI, LATINA

Introduzione. È ormai noto che l'ipocloremia (<96 mmol/L) sia un importante parametro predittore di mortalità indipendente nei pazienti affetti da scompenso cardiaco acuto e cronico. Tuttavia, il meccanismo tramite il quale bassi livelli ematici di cloro si correlino ad una minore sopravvivenza in pazienti con insufficienza cardiaca è ancora fonte di dibattito.
Obiettivo: L'obiettivo dello studio è stato valutare i fattori predittivi di mortalità intra ed extraospedaliera in pazienti con insufficienza cardiaca a frazione d'eiezione ridotta (HFrEF), esaminando con particolare attenzione i parametri che si correlassero con ipocloremia.
Metodi. Sono stati analizzati retrospettivamente i dati di 219 pazienti (età media 70 ± 0,74 anni; FE 30 ± 0,1%) ospedalizzati presso l'Ospedale Santa Maria Goretti di Latina per HFrEF (FE<40%). La popolazione è stata sottoposta durante il ricovero e nei follow-up successivi (a 3, 6 e 12 mesi), a controlli clinici, laboratoristici, ecocardiografici e alla valutazione della terapia farmacologica. Inoltre, durante la degenza, sono state valutate le variabili antropometriche.
Risultati. Livelli di cloremia sopra la mediana sono risultati associati ad una minore mortalità al follow-up (P<0,01). Inoltre, l'analisi di regressione multivariata di Cox ha confermato una maggiore sopravvivenza nei pazienti con livelli di cloremia sopra la mediana indipendentemente dalle altre covariate (P<0,04). D'altro canto, focalizzando le analisi sui pazienti con livelli di cloremia più bassi, è risultata una forte correlazione tra livelli di ipocloremia (<96 mmol/L) sia con alti valori di BNP all'ingresso in ospedale (P<0,02), sia con evidenza di fibrillazione atriale (FA) in anamnesi (P<0,01). In seguito, tramite regressione di Cox, è stata dimostrata una maggiore mortalità al follow-up per i pazienti affetti da FA (P<0,01).
Conclusioni. In questo studio real-life si è osservato come livelli di cloremia superiori alla mediana siano risultati essere un parametro protettivo di mortalità in pazienti affetti da HFrEF. Inoltre, è stato dimostrato che valori di cloremia inferiori al range di normalità si correlano, sia con alti livelli di BNP al momento del ricovero in ospedale, che con la presenza di FA in anamnesi. È possibile che, essendo i canali del cloro (CLC-2) implicati nella stimolazione seno-atriale e nell'aritmogenesi delle cellule cardiache, bassi livelli di cloremia possano correlarsi con un'aumentata insorgenza di FA, in particolare in condizioni di stress miocardico. In tal caso, studi futuri saranno necessari per verificare se l'utilizzo di protocolli terapeutici volti al ripristino di normali livelli di cloremia possano avere un ruolo impattante nella diminuzione dell'incidenza di FA, essendo questa un dimostrato fattore prognostico negativo in pazienti affetti da scompenso cardiaco.

A909: BASELINE CHARACTERISTICS OF PATIENTS WITH ATTR AMYLOIDOSIS ENROLLED INTO THE CONTTRIBUTE REGISTRY

Luca Leonardi (d), Michael Polydefkis (c), Andoni Echaniz-laguna (e), Julian D Gillmore (f), Fabian Knebel (g), Davide Pareyson (b), Brian Drachman (h), Hans Nienhuis (i), Zubair Shah (j), Guilhem Sole (n), Juliette Svahn (k), Shaun Bender (l), Colleen Moffitt (l), Catherine Summers (l), Kelley Capocelli (l), Mathew S Maurer (m)
(a) FONDAZIONE IRCCS INSTITUTO NEUROLOGICO CARLO BESTA, MILAN ITALY; (b) FONDAZIONE IRCCS INSTITUTO NEUROLOGICO CARLO BESTA, MILAN, ITALY; (c) DEPARTMENT OF NEUROLOGY, JOHNS HOPKINS UNIVERSITY SCHOOL OF MEDICINE, BALTIMORE, MD, USA; (d) DEPARTMENT OF NEUROSCIENCE, MENTAL HEALTH AND SENSORY ORGANS, SANT'ANDREA HOSPITAL, SAPIENZA UNIVERSITY OF ROME, ROME, ITALY; (e) DEPARTMENT OF NEUROLOGY, ASSISTANCE PUBLIQUE HOPITAUX DE PARIS, CHU DE BICETRE, LE KREMLIN-BICETRE, FRANCE; (f) NATIONAL AMYLOIDOSIS CENTRE, UNIVERSITY COLLEGE LONDON, DIVISION OF MEDICINE, ROYAL FREE HOSPITAL, LONDON, UK; (g) CHARITE UNIVERSITY HOSPITAL, BERLIN, GERMANY; (h) PENN PRESBYTERIAN MEDICAL CENTER, PHILADELPHIA, PA, USA; (i) AMYLOIDOSIS CENTER OF EXPERTISE, UNIVERSITY MEDICAL CENTER GRONINGEN, GRONINGEN, THE NETHERLANDS; (j) DEPARTMENT OF CARDIOVASCULAR MEDICINE, THE UNIVERSITY OF KANSAS HEALTH SYSTEM, KANSAS CITY, KS, USA; (k) SERVICE DE NEUROLOGIE, HOPITAL PIERRE WERTHEIMER, BRON, FRANCE; (l)

ALNYLAM PHARMACEUTICALS, CAMBRIDGE, MA, USA; (m) COLUMBIA UNIVERSITY IRVING MEDICAL CENTER, NEW YORK, NY, USA; (n) DEPARTMENT OF NEUROLOGY AND NEUROMUSCULAR DISEASES, CHU BORDEAUX, UNIVERSITY OF BORDEAUX, BORDEAUX, FRANCE

Introduction and Purpose. The ConTTRibute registry is a prospective, global, multicenter, long-term observational study (NCT04561518) enrolling patients with ATTR amyloidosis and asymptomatic carriers of TTR variants. The registry aims to describe epidemiologic/clinical characteristics, natural history, and real-world clinical management in these patients.

Methods. Baseline characteristics of ConTTRibute participants at enrollment were reported for patients with confirmed diagnosis of ATTR amyloidosis and for asymptomatic carriers of documented known disease-causing TTR variants.

Results. From November 2020 through June 2023, 704 participants were enrolled from 9 countries; 331 had variant ATTR amyloidosis (ATTRv), 260 wild-type ATTR amyloidosis (ATTRwt), and 113 were asymptomatic carriers. Across patients with ATTRv and carriers, 226 (50.9%) had V30M/V50M variant, 95 (21.4%) V122I/V142I, and 22 (5.0%) T60A/T80A. Most participants were recruited in the US (388 [55.1%]), the remainder in Europe. Most were white (547 [77.7%]); 69 (20.8%) in the ATTRv group were black/African American versus 8.6% across ATTRwt and asymptomatic carrier groups. Mean (SD) age at symptom onset and diagnosis was lower in the ATTRv group (56.5 [15.3] and 58.7 [15.3] years, respectively) versus the ATTRwt group (76.0 [8.3] and 77.7 [7.7] years). Among patients with a confirmed diagnosis of ATTR amyloidosis, similar proportions in the ATTRv and ATTRwt groups presented with a mixed phenotype of polyneuropathy and cardiomyopathy (n=87 [26.3%] and n=70 [26.9%], respectively).

Conclusions. Age at symptom onset and diagnosis was lower for patients with ATTRv. A relatively high proportion, approximately 25%, of patients with ATTR amyloidosis presented with a mixed phenotype of polyneuropathy and cardiomyopathy.

A910: ELEGGIBILITÀ DEGLI SGLT2 INIBITORI E VERICIGUAT IN PAZIENTI CON WORSENING HEART FAILURE

Roberto Tarantini (a, b), Stefano Alonge (a, b), Lorenzo Acone (a, b), Francesco Catagnano (a, b), Marco Foti (a, b), Andrea Mortara (b)
(a) UNIVERSITÀ DEGLI STUDI DI PAVIA, PAVIA, ITALIA; (b) POLICLINICO DI MONZA, DIPARTIMENTO DI CARDIOLOGIA CLINICA, MONZA, ITALIA

Introduzione. "Worsening heart failure" (WHF) è un concetto emergente definito dall'aumento dei segni e dei sintomi di scompenso cardiaco (HF) nei pazienti con scompenso cardiaco cronico (CHF) nonostante una terapia stabile. Dopo un evento di WHF, esiste un periodo di vulnerabilità in cui il rischio di ospedalizzazione e mortalità è elevato. Gli inibitori del sodio-glucosio-co-trasportatore (SGLT2i) e il vericiguat, uno stimolatore della guanilato ciclasi solubile (sGCs), sono stati studiati in pazienti con WHF sia durante il ricovero (EMPULSE) sia dopo la dimissione (VICTORIA e SOLOIST-WHF) con risultati positivi.

Obiettivi. Questo studio propone di indagare l'eleggibilità degli studi VICTORIA, SOLOIST-WHF ed EMPULSE in una popolazione real-world di pazienti ricoverati per WHF e di analizzare le differenze tra questo gruppo di pazienti e i pazienti arruolati nei trial clinici.

Materiali e metodi. In questo studio di coorte retrospettivo sono stati arruolati 275 pazienti ricoverati per WHF nel nostro reparto di cardiologia tra il 2017 e il 2022. Sono state analizzate le percentuali di pazienti eleggibili secondo i criteri di inclusione ed esclusione dei trial VICTORIA, SOLOIST-WHF ed EMPULSE; dunque, sono state valutate le differenze tra le caratteristiche della nostra popolazione e quelle dei trial.

Risultati. 83 pazienti (30,2%) erano eleggibili secondo i criteri dello studio VICTORIA, 35 pazienti (12,7%) secondo SOLOIST-WHF e 186 pazienti (67,6%) secondo EMPULSE. I fattori limitanti erano la frazione di eiezione (EF)>45% nel VICTORIA, la presenza di diabete mellito di tipo 2 (DM2) nel SOLOIST-WHF e i livelli di cut-off di NT-proBNP e BNP. I nostri pazienti erano più anziani (media 78 anni e mediana 80 anni) rispetto alle popolazioni degli studi (67 anni; 69 anni; 71 anni). L'EF era più elevata (media 38% e mediana 35%) rispetto a VICTORIA (29%) e a EMPULSE (31%), ma simile a quella di SOLOIST-WHF (35%). La velocità di filtrazione glomerulare stimata (eGFR) è risultata inferiore rispetto a VICTORIA (56,0 ml/min vs 61,5 ml/min) mentre è risultata superiore rispetto a EMPULSE e SOLOIST (54,0 ml/min vs 49,2 ml/min vs 50,0 ml/min). Il DM2 era meno comune nella nostra popolazione (32,7% vs 47,1% vs 100% vs 46,8%); d'altro canto, i livelli di NT-proBNP (mediana 5080 pg/ml) erano più elevati nella nostra popolazione rispetto agli studi (3377 pg/ml; 1816,8 pg/ml; 3299 pg/ml).

Conclusioni. SGLT2i e vericiguat sono farmaci importanti nella gestione della WHF. Al momento, vericiguat può essere utilizzato solo in pazienti con EF <45% e questo è il fattore più limitante, mentre gli SGLT2i possono essere utilizzati indipendentemente dall'EF. Questi dati mostrano la potenziale applicabilità nei pazienti con WHF evidenziando le differenze tra pazienti "real-world" e i pazienti arruolati. Sono necessari ulteriori dati sull'uso di vericiguat e SGLT2i, soprattutto nei primi giorni di ricovero.

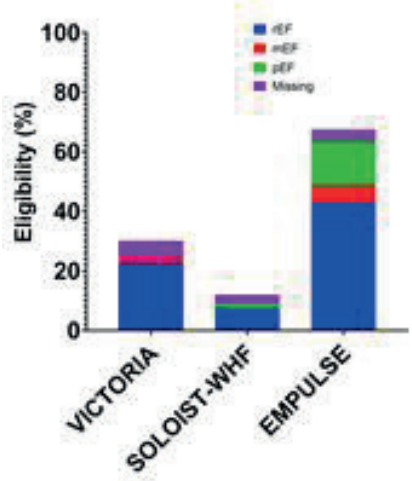

A911: UN CASO DI SCOMPENSO CARDIACO AD ALTA PORTATA: OVVERO COME HO IMPARATO A PREOCCUPARMI E AD AUSCULTARE L'ADDOME

Henri Xhakupi (b), Alberto Abate (b), Carla Zannelli (b), Francesca Lucca (b), Roberta Della Bona (a), Italo Porto (a, b)
(a) UNITÀ MALATTIE CARDIOVASCOLARI, IRCCS POLICLINICO SAN MARTINO, GENOVA, ITALIA; (b) DIPARTIMENTO DI MEDICINA INTERNA, UNIVERSITÀ DEGLI STUDI DI GENOVA, GENOVA, ITALIA

Background. Lo scompenso cardiaco ad alta portata (SCAP) è una forma poco comune di cardiopatia la cui incidenza e prevalenza non sono note. La diagnosi differenziale comprende ipertiroidismo, cirrosi epatica, BPCO e malformazioni artero-venose (MAV), congenite o acquisite. A seguire un caso di SCAP secondario ad aneurisma dell'arteria renale destra e fistola artero-venosa renale destra con shunt.

Discussione. Il presente documento espone il caso di un uomo di 55 anni (iperteso e obeso), il cui padre aveva sofferto di aneurisma dell'aorta addominale in età giovanile (informazione reperita a posteriori), ricoverato presso il nostro reparto per peggioramento di sintomatologia dispnoica (classe NYHA III) e comparsa di edemi declivi in quadro di scompenso cardiaco acuto di nuovo riscontro a frazione d'eiezione moderatamente ridotta (HFmrEF). Riferiva, inoltre, un importante quadro di lombalgia cronico-recidivante medicata in autonomia con FANS al bisogno. L'ECG all'ingresso mostrava ritmo sinusale con blocco atrio ventricolare (BAV) di I grado. Il primo ecocardiogramma riportava moderata dilatazione (DTD 59 mm) e lieve ipertrofia del ventricolo sinistro, con associata lieve riduzione della FE (45%) in assenza di alterazioni segmentarie della cinesi o valvulopatie significative delle camere sinistre; si associava, inoltre, una moderata dilatazione ventricolare destra con insufficienza tricuspidalica (IT) moderata e pressioni in arteria polmonare stimate (PAPs) di 65 mmHg. Durante i primi giorni di ricovero il paziente ha sviluppato febbre per cui sono state avviate emocolture e terapia antibiotica, inizialmente empirica, e solo in seguito mirata, sulla base delle colture positive per MSSA. A completamento diagnostico veniva eseguito ecocardiogramma trans-esofageo, che escludeva la presenza di vegetazioni endocarditiche. Alla luce del concomitante stato infettivo, e dell'elevato rischio di disseminazione ad esso correlato, si soprassedeva all'esecuzione di indagini strumentali invasive per inquadramento cardiopatia (es. cateterismo destro). All'esame obiettivo, si apprezzava un soffio sistolico sincrono con la sistole in fossa iliaca destra. In considerazione del dolore lombare ingravescente e della batteriemia veniva posto il sospetto di spondilodiscite. Si richiedeva, dunque, TC torace-addome, con triplice riscontro: fenomeni flogistico-degenerativi a livello della colonna lombo sacrale compatibili con processo infettivo (quadro confermato alle successive valutazioni di imaging: RMN colonna e PET globale corporea), voluminosa malformazione vascolare renale a destra con shunt artero-venoso e dilatazione aneurismatica dell'arteria renale di destra (diametro massimo di 27 mm). Il quadro è stato interpretato come uno SCAP secondario a MAV, il cui trigger è stato la batteriemia. Dopo la stabilizzazione del quadro clinico e lo spegnimento del focolaio infettivo, veniva eseguito intervento chirurgico di esclusione della MAV. Il paziente, rivalutato a distanza di un mese dall'atto chirurgico, si presentava asintomatico, con funzionalità ventricolare sinistra conservata alla valutazione ecocardiografica, riduzione della dilatazione ventricolare sinistra (DTD 56 mm), e IT minima con PAPs non cifrabili, in assenza di obiettività riconducibile a scompenso cardiaco.

Conclusioni. Le MAV rientrano tra le possibili cause di SCAP. Il caso del nostro paziente dimostra come l'identificazione, tramite integrazione di dati clinici e strumentali, e il precoce trattamento di tale condizione permettono una rapida risoluzione della manifestazione cardiaca associata.

A912: UNMET NEEDS IN END-OF-LIFE CARE FOR HEART FAILURE PATIENTS

Alberto Aimo (a, b), Filippo Quattrone (a), Sara Zuccarino (a), Maria Sole Morelli (b), Francesca Ferrè (a), Angela Gioia (a), Sabina Nuti (a), Michele Emdin (a, b)
(a) SCUOLA SUPERIORE SANT'ANNA, PISA; (b) FONDAZIONE TOSCANA GABRIELE MONASTERIO, PISA; (c) AZIENZA USL TOSCANA NORD OVEST

Objective: To investigate end-of-life (EoL) care for heart failure (HF) in Tuscany (Italy) from healthcare professionals' perspective and identify areas for intervention.
Methods. All the directors of Cardiology units (n=29) and PC units (n=14) in Tuscany were surveyed on the practices of EoL care.
Results. Forty-five percent of cardiologists reported that their hospital had some EoL care services for HF patients. Seventy-five percent did not have a multidisciplinary team providing EoL care for HF patients, and 21% could not request a consult by PC specialists for inpatients; furthermore, 64% stated that <25% of patients who might benefit from PC did receive it, and 18% stated that no patient received PC. For 93% of PC specialists, HF patients accounted for <25% of their patients. PC specialists believed that patients with cancer diseases were much more likely to receive PC than HF patients at EoL, and 36% judged that almost no HF patients were timely referred to hospice care. PC specialists reported a lower ability to satisfy the care needs of HF patients than cancer patients. According to PC specialists, HF patients often did not understand or accept that they had entered the terminal disease stage. Seventy-nine percent of PC specialists reported that almost no HF patient prepared advance healthcare directives, as opposite to 57% for cancer patients.
Conclusions. The management of HF patients in the EoL stage in Tuscany is often suboptimal. EoL care should be implemented to ensure an adequate quality of life to these patients.

A913: SAFETY AND FEASIBILITY OF ADENOSINE STRESS CMR FOR DETECTION OF VASCULOPATHY IN ORTHOTOPIC HEART TRANSPLANT RECIPIENTS

Giandomenico Bisaccia (a, b), Roberto Licordari (b), Isabella Leo (b), Giulia La Vecchia (b), Maria Perotto (b), Maria Cristina Procopio (b), Nikolaos Miaris (b), Joyce Wong (b), Chiara Bucciarelli-ducci (b, c)
(a) DIPARTIMENTO DI NEUROSCIENZE, IMAGING E SCIENZE CLINICHE, UNIVERSITÀ «G. D'ANNUNZIO» DI CHIETI-PESCARA, CHIETI, ITALIA; (b) ROYAL BROMPTON AND HAREFIELD HOSPITALS, GUYS' & ST THOMAS NHS TRUST, LONDON, UNITED KINGDOM; (c) SCHOOL OF BIOMEDICAL ENGINEERING AND IMAGING SCIENCES, FACULTY OF LIFE SCIENCES AND MEDICINE, KING'S COLLEGE UNIVERSITY, LONDON, UNITED KINGDOM

Background. Stress perfusion cardiac magnetic resonance (CMR) imaging is recommended in the international guidelines in class I in patients with known or suspected coronary artery disease. Patients undergoing orthotopic cardiac transplantation (OHT) are at risk of developing cardiac allograft vasculopathy (CAV). Adenosine is relatively contraindicated after transplantation because of a presumed risk of prolonged atrioventricular block in denervated hearts. We sought to evaluate the safety and feasibility of adenosine stress perfusion CMR in patients with OHT and suspected CAV in the outpatient setting.
Methods. In a retrospective cohort study, we analyzed the incidence of adverse effects of adenosine stress CMR in consecutive OHT recipients undergoing quantitative stress perfusion CMR for suspected CAV between 2015 and 2023. We additionally stratified patients based on presence of significant cardiac allograft vasculopathy (CAV grades 2-3 versus CAV 0-1) on either invasive or computed tomography coronary angiography to evaluate potential CMR biomarkers of significant coronary disease in this population. Indices of stress myocardial blood flow (MBFi) and myocardial perfusion reserve (MPRi) were derived by normalizing absolute parameters to the rate pressure product.
Results. We identified 67 adenosine stress CMR studies performed in 59 individual patients (age 48±17 years; 32.2% females) at a median of 18.6 years after transplantation (IQR 4-24.1); 6.8% of studies were conducted within the first year post-transplantation. No life-threatening adverse events, nor brief or prolonged atrioventricular block or other arrythmias occurred after adenosine infusion. Three patients (4.5%) lamented headache and one patient had sinus pauses. Significant myocardial ischemia was reported in 18.6% of patients. When stratified by CAV severity, stress MBF index, but not inducible ischemia on visual inspection or MPR index, was found to significantly differentiate patients with severe CAV from those without significant coronary disease (p=0.029).
Conclusions. Adenosine stress perfusion CMR is safe and feasible in OHT recipients. Quantitative measurement of stress MBF index may represent a promising marker of coronary disease with incremental value over qualitative assessment of ischemia, and should be evaluated in future studies.

A914: SACUBITRIL-VALSARTAN IN ISCHEMIC VS. NON ISCHEMIC HEART FAILURE PATIENTS WITH REDUCED EJECTION FRACTION: A REAL-WORLD-ANALYSIS WITH OUTCOME IMPLICATIONS

Niccolo Bonini (a, b), Federico Muto (a), Marco Stuani (a), Josef Luli (a), Kevin Serafini (a), Francesco Sbarra (a), Vera Laus (a), Irma Marconi (a), Benedetta Cherubini (a), Ilaria Righelli (a), Chiara Birtolo (a), Marco Vitolo (a, b), Jacopo Francesco Imberti (a, b), Davide Antonio Mei (a), Giuseppe Boriani (a)
(a) CARDIOLOGY DIVISION, POLICLINICO DI MODENA, UNIVERSITY OF MODENA AND REGGIO EMILIA; (b) CLINICAL AND EXPERIMENTAL MEDICINE PHD PROGRAM, UNIVERSITY OF MODENA AND REGGIO EMILIA

Background and aim of the study: There is a need for real-world data on heart failure patients (pts) with reduced ejection fraction (HFrEF) with ischemic heart disease (IHD) treated with Sacubitril/Valsartan (Sa/Va) regarding Sa/Va titration, changes in renal function (eGFR), left ventricular ejection fraction (LVEF), and the cardiovascular outcomes. We presented an analysis in a contemporary cohort of ambulatory HFrEF pts.
Methods. A worsening eGFR (w-eGFR) was defined as a eGFR decline of ≥20% vs baseline (bas.). A high response LVEF (hr-LVEF) was defined as an increase of LVEF≥10% vs bas. The clinical outcomes were all-cause death (ACD) and MACE (HF hospitalization, acute coronary syndromes, stroke/TIA and ACD). We performed association and survival analyses.
Results. A total of 243 pts were included with median age of 67 years [IQR 58.0-74.2], 17.8% female, median LVEF 30% [IQR 29-35], median NYHA class 2 [IQR 2-3], with mid-high Sa/Va dosage at bas. in 31.3%. No IHD pts were 125 (48.5%), with a median LVEF of 30 [IQR 33-35] and a median eGFR 72.3 [59.3-86.1], and 118 (51,5%) were IHD pts with a median LVEF of 30 [30-35] and a median eGFR 76.2 [61.8-89.3]. After 759 days [701-847] of follow-up, nine (4.1%) pts interrupted Sa/Va, with no differences between no IHD and IHD pts (p=0.501). The 47,6% of pts received a mid-high Sa/Va dosage, without differences between the two groups (p=0.917). In IHD pts eGFR significantly lowered (p=0.018) attaining a value of 71.6 [54.6-83.2], not significative in no IHD pts (p=0.307). An w-eGFR occurred in 14 pts (15.7%), with a trend towards higher incidence among IHD pts (p=0.054). LVEF improved vs bas. in both groups (p<0.001). A hr-LVEF was observed in 58 pts (46.0%), without differences between the two groups (p=0.271). In IDH group 17 deaths (14.4%) occurred vs 7 (5.6%) in no IHD pts (p=0.021); a higher occurrence for MACEs was observed in IHD pts (p=0.002). At the survival analysis, IHD pts had a higher incidence of MACE (Log-Rank, p=0.041, Figure), not for ACD (Log-rank, p=0.131). At a multivariable Cox regression analysis IHD was independently associated with MACE [Figure], not with ACD (p=0.708).
Conclusions. After two years of follow-up, IHD pts had higher occurrence of ACD and MACE vs no IHD pts, and IHD was independently associated with MACE. No difference in Sa/Va withdrawals was observed between the groups. On average LVEF improved in both groups. The prescription of Sa/Va and monitoring during follow-up should be focused on the highest risk of MACE characterizing IDH real-world HFrEF pts.

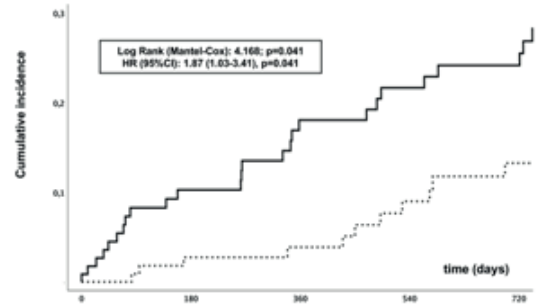

n° at risk					
Non ischemic etiology	120	104	85	74	66
Ischemic etiology	116	95	86	82	74

A915: EARLY POSITIVE CARDIAC REMODELING AFTER SACUBITRIL/VALSARTAN IN PATIENTS WITH ATRIAL FIBRILLATION

Valerio Ciubine (a), Emanuele Maria Giuseppe Cicchirillo (a), Giulia Stronati (a), Alessandro Barbarossa (a), Alice Frangione (a), Edlira Rrapaj (a), Samuele Principi (a), Michela Casella (a), Antonio Dello Russo (a), Federico Guerra (a)
(a) CARDIOLOGY AND ARRHYTMOLOGY CLINIC, MARCHE UNIVERSITY HOSPITAL, ANCONA, ITALY

Background. Indirect evidence suggests that sacubitril/valsartan may enhance left ventricular ejection fraction (LVEF) by promoting reverse remodeling of the left ventricle, targeting a well-established mechanism of heart failure progression. These changes in cardiac structure appear to impact both systolic and diastolic function and appear to be influenced by the dosage of the medication. Additionally, sacubitril/valsartan has been linked to a reduction in sustained ventricular arrhythmias. Furthermore, in patients with advanced functional class and multimorbidity in heart failure with reduced ejection fraction (HFrEF), sacubitril/valsartan has demonstrated advantages by alleviating symptoms, enhancing exercise capacity, and improving overall quality of life.
Aim. We evaluated whether there are differences in positive cardiac remodelling induced by sacubitril/valsartan in patients with HFrEF/HFimpEF according to the presence/absence of atrial fibrillation (AF).

Methods. This was an observational study enrolling all consecutive patients with HFrEF/HFimpEF referred to Cardiology Clinic, University Hospital "Ospedali Riuniti", Ancona, between August 2022 and March 2023. For every patient we collected data about 1) clinical characteristics (age, gender, diagnosis of AF); 2) treatment (beta-blockers, ACE-inhibitors/AT2 receptor blockers, mineralcorticoid receptor antagonists, angiotensin receptor-neprilysin inhibitor); 3) echocardiographic examination (left ventricular ejection fraction LVEF, indexed left ventricular end-diastolic volume iLVEDV, indexed left atrial volume iLAV, right ventricular basal diameter, TAPSE). Then, we gathered data about the follow-up, in the period between March 2023 and September 2023. We included outpatients with HFrEF/HFimpEF, aged>18 years, in stable clinical condition (NYHA I-III).
Results. A total of 119 patients (72% male, mean age 71±13 years) were consecutively enrolled, of which 52 (48%) had a previous diagnosis of AF After discharge (median follow-up: 3 months), LVEF increased similarly both in patients with AF (from 37% to 39%) and without AF (from 35% to 37%; p within groups 0.043; p between groups 0.228). A total of 7.5% were described as HFimpEF at enrolment, increasing to 31.0% at follow-up, with similar incidence of HFimpEF regardless of AF status (AF: 30% vs. no AF 32%; p=0.877). A similar positive cardiac remodelling was seen in both groups for iLVEDV (AF: from 84 ml/m2 to 80 ml/m2, no-AF: from 78 ml/m2 to 66 ml/m2; p within groups 0.049; p between groups 0.324) and for iLAV (AF: from 49 ml/m2 to 45 ml/m2, no-AF: from 38 ml/m2 to 33 ml/m2; p within groups 0.037; p between groups 0.069). No difference were noted during follow-up or between groups related to right ventricular chambers.
Conclusions. Sacubitril/valsartan provides a positive remodelling effect on left ventricular chambers which seems independent from the presence of AF and, thus, the potential atrial cardiomyopathy underlying the arrhythmic disease.

A916: ACHIEVEMENT AND EFFECTS OF GUIDELINE-DIRECTED MEDICAL THERAPY FOR HEART FAILURE WITH REDUCED EJECTION FRACTION ACCORDING TO 2016 OR 2021 ESC GUIDELINES

Paolo Costa (b), Stefano Benenati (b), Martina Solimano (b), Matteo Toma (a), Stefano Giovinazzo (a), Pierfilippo Vianello (a), Italo Porto (a, b), Marco Canepa (a, b), Pietro Ameri (a, b)
(a) IRCCS, POLICLINICO SAN MARTINO GENOVA; (b) UNIVERSITÀ DEGLI STUDI DI GENOVA, DIMI DIPARTIMENTO DI MEDICINA INTERNA E SPECIALITÀ MEDICHE

Background. Class I guideline-direct medical therapy (GDMT) for heart failure with reduced ejection fraction (HFrEF) in ESC guidelines (GL) has changed from a beta-blocker (BB) and an angiotensin-converting enzyme inhibitor (ACEi) or angiotensin-receptor blocker (ARB), followed by a mineralocorticoid receptor antagonist (MRA) in case of persisting symptoms, to the combination of BB, ACEi or AR-neprilysin inhibitor (ARNI), MRA and sodium-glucose cotransporter-2 inhibitor (SGLT2i).
Methods. By reviewing the records of a tertiary HF ambulatory between 2015 and 2023, we retrospectively identified 2 cohorts of HFrEF patients, based on whether they had been evaluated before or after the publication of the 2021 GL (group-2016 and group-2021, respectively). Then, we selected the subjects who had 1 visit ≥3 months after the first one and were not on GDMT at baseline, defined as: no BB and ACEi/ARB, or NYHA>II, left ventricular ejection fraction (LVEF) <35% and no MRA for group-2016; and lack of BB, ACEi/ARNI, MRA or SGLT2i for group-2021. The differences between of 2 cohorts were assessed by chi-square test, unpaired t-test or Mann-Whitney test. NYHA classes and LVEF categories (<25%, 26-30%, 31-40%,>40%) at baseline and follow-up, as well as the indication for an implantable cardioverter defibrillator (ICD), were compared within and between groups by chi-square test. These analyses were repeated after 1:3 propensity score matching of group-2021 and group-2016 by age, sex, body mass index, hypertension, diabetes, smoking history, chronic obstructive pulmonary disease, and atrial fibrillation.
Results. Group-2016 included 344 patients and group-2021 33. Baseline characteristics were comparable. At follow-up, GDMT was prescribed to 11% patients of group-2016 and 54% of group-2021. As shown in the Figure, NYHA class and LVEF improved in either group during follow-up. 18% and 27% patients, respectively, had indication for an ICD.
After propensity score matching, LVEF improved in both groups (group 2016: LVEF <25% from 43% to 15%, p=0.003; group-2021: LVEF <25% from 31% to 19%, p<0.0001), but the proportion of patients with higher LVEF categories was significantly greater in group-2021 (53% vs 15% with LVEF>40%, p=0.01). By contrast, NYHA class distribution improved only in group-2016 (p<0.0001), but there was no significant trend difference between the 2 groups.
GDMT was attained in 53% of subjects in group-2021 vs 28% in group-2016, p=0.01.
Conclusions. This preliminary analysis suggests that HFrEF GDMT as per 2021 GL is achieved more often and results in better improvement in LVEF than as per 2016 GL.

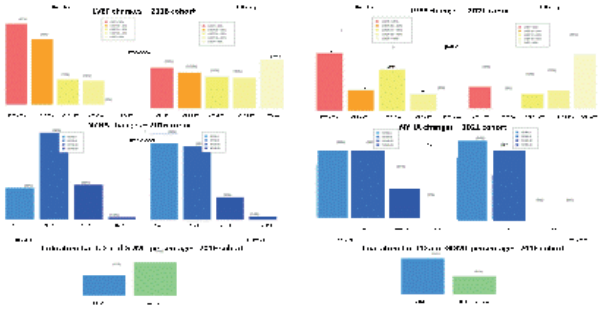

A917: AN EDUCATIONAL CASE OF ACUTE TREATMENT OF CARDIOGENIC SHOCK DUE TO TAKOTSUBO SYNDROME

Giulia Giacomobono (a), Alberto Dotto (a), Solange Piccolo (a), Francesca Ferrigni (a), Matteo Piscopo (a), Roberto Scarsini (a), Gabriele Pesarini (a), Mattia Lunardi (a), Concetta Mammone (a), Alessia Gambaro (a), Valeria Ferrero (a), Domenico Tavella (a), Flavio Luciano Ribichini (a)
(a) AZIENDA OSPEDALIERA UNIVERSITARIA VERONA, PZ.LE DE STEFANI, VERONA, ITALY

Cardiogenic shock treatment in Takotsubo syndrome (TTS) is still a controversial issue, especially when LV outflow tract obstruction (LVOTO) occurs. We reported a case of a 66-year-old woman who presented to emergency department with chest pain after emotional stress and ST elevation in anterior-lateral leads. Urgent coronary angiography showed absence of coronary disease and left ventricular angiography detected apical ballooning, suggestive for TTS. At admission in UCI the patient presented systolic murmur, blood pressure of 85/54 mmHg and heart rate of 85 bpm. Echocardiogram revealed typical apical ballooning, reduction of ejection fraction (EF 35%), LVOTO and moderate mitral regurgitation (MR). Therefore, fluid and albumin administration were started to increase preload; then, in order to increase afterload, we opted for vasopressin infusion, with concomitant use of low dose of esmolol to guarantee an adequate diastolic filling time. Interventional cardiologist and cardiac surgeons were consulted for the possibility of mechanical circulatory support (MCS). Thanks to medical therapy, the patient gradually improved her hemodynamic condition and MCS were avoided. Vasopressin was slowly weaning, esmolol switched to bisoprolol and the patient was transferred to the ordinary ward 4 days after the index event. Echocardiogram before discharge showed resolution on LVOTO and MR, with improvement of ejection fraction (EF 48%). At follow-up visit 1 month later the patient was completely asymptomatic and with normal ejection fraction (EF 64%), evaluated with cardiac RM. In conclusion LVOTO plays a key-role for the management of cardiac shock in TTS; as in the exemplary case we reported, early evaluation of LVOTO is fundamental to assess the optimal medical therapy, avoiding conventional inotropes that in this setting could determinate an unintentional exacerbation of shock.

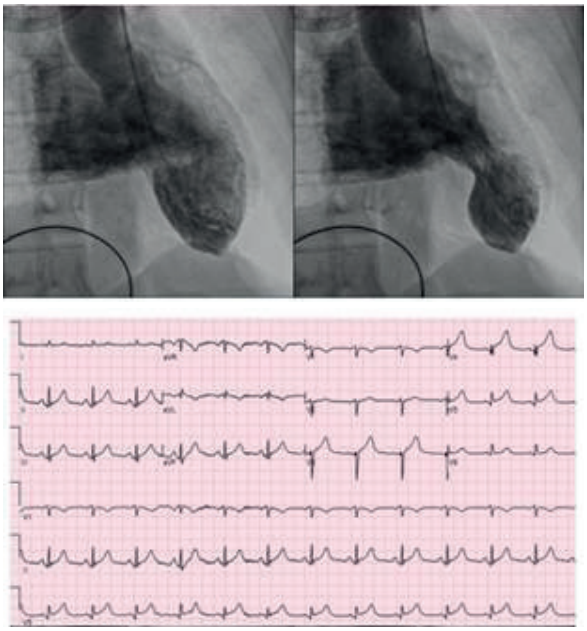

A918: COMPARISON OF LEFT ATRIAL MINIMAL AND MAXIMAL VOLUME TO ASSESS LEFT VENTRICULAR FILLING PRESSURES IN HEART FAILURE PATIENTS

Alessandro Lupi (a), Paolo Biagioli (a), Anna Mengoni (a), Federico Fortuni (a, b), Caterina Viti (a), Sara Morroni (a), Giovanni Russo (a), Marco Dell´uomo (a), Stefano Sforna (a), Andrea Scarpignato (a), Marzia Maltempi (a), Erberto Carluccio (a), Giuseppe Ambrosio (a, c)

(a) CARDIOLOGY AND CARDIOVASCULAR PATHOPHYSIOLOGY, SANTA MARIA DELLA MISERICORDIA HOSPITAL, UNIVERSITY OF PERUGIA, PERUGIA, ITALY.; (b) SC CARDIOLOGIA E UTIC, SAN GIOVANNI BATTISTA HOSPITAL, FOLIGNO (PG), ITALY.; (c) CERICLET - CENTRO RICERCA CLINICA TRASLAZIONALE, UNIVERSITY OF PERUGIA, PERUGIA, ITALY.

Background. Current guidelines recommend assessing left atrial maximal volume (LAVmax) to grade left ventricular (LV) diastolic dysfunction. However, recent studies showed a stronger association between LA minimal volume and prognosis as compared to LA maximal volume in different clinical settings. Nevertheless, whether LA minimal volume better reflects LV filling pressures compared to LA maximum volume remains to be established.

Methods. We retrospectively analyzed 1158 patients with chronic HF [70% with reduced LV ejection fraction (EF, HFrEF)]. The LV filling pressures were estimated with echocardiography using the formula proposed by Ommen et al [LV end-diastolic pressure (EDP) =11.96 + 0.596 * E/e']. LVEDP>20 mmHg was considered to identify increased LV filling pressures. A cut-off value of 40 mmHg was used to identify increased pulmonary artery systolic pressure (PASP). Receiver operating characteristics curves were used to assess the comparative diagnostic accuracy of LA maximum and minimal volume and NT-pro BNP to identify increased LV filling pressures and PASP.

Results. Mean age was 66 ± 12 years and 867 were males (75%). LAVmin (AUC =0.74; 95% CI 0.71-0.76) showed a good accuracy and higher discriminative power to identify increased LVEDP compared to both LAVmax (AUC =0.71; 95% CI 0.68-0.74; P=0.018 – Figure 1A) and NT-proBNP values (AUC =0.62; 95% CI 0.59-0.65; P<0.001 for comparison). Moreover, LAVmin consistently showed a higher diagnostic accuracy to identify increased PASP (AUC =0.75; 95% CI 0.72-0.78) compared to both LAVmax (P=0.005) and NT-proBNP (P<0.0001 - Figure 1B). These data were consistent regardless of the severity of secondary mitral regurgitation.

Conclusions. LA minimal volume better reflects LV filling pressures in patients with chronic HF compared to LA maximum volume and should be taken into account to refine the assessment of LV diastolic function in this clinical setting.

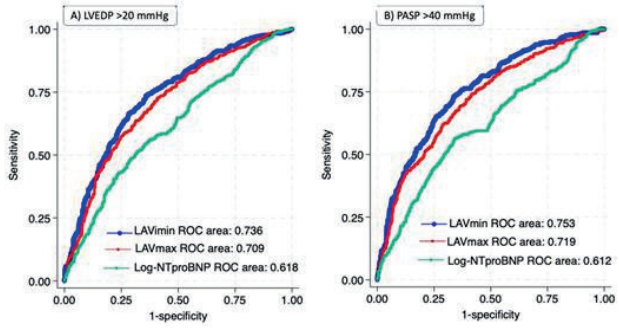

A919: INVASIVE HEMODYNAMIC DIAGNOSIS OF HFpEF: PLEASE STAND UP!

Maria Felicia Gagliardi (a), Claudia Baratto (b), Michele Liberatore (a), Giovanni Battista Perego (c), Marat Fudim (e), Luigi P Badano (a, b), Gianfranco Parati (a, c), Sergio Caravita (b, d)

(a) DEPARTMENT OF MEDICINE AND SURGERY, UNIVERSITY OF MILANO-BICOCCA, MILAN, ITALY; (b) DEPARTMENT OF CARDIOLOGY, SAN LUCA HOSPITAL, IRCCS ISTITUTO AUXOLOGICO ITALIANO, MILAN, ITALY; (c) DEPARTMENT OF CARDIOVASCULAR NEURAL AND METABOLIC SCIENCES, SAN LUCA HOSPITAL, IRCCS ISTITUTO AUXOLOGICO ITALIANO, MILAN, ITALY; (d) DEPARTMENT OF MANAGEMENT, INFORMATION AND PRODUCTION ENGINEERING, UNIVERSITY OF BERGAMO, DALMINE BG, ITALY; (e) DIVISION OF CARDIOLOGY, DUKE UNIVERSITY SCHOOL OF MEDICINE, DURHAM, NORTH CAROLINA, USA; DUKE CLINICAL RESEARCH INSTITUTE, DURHAM, NORTH CAROLINA, USA

Background. Exercise right heart catheterization (RHC) allows to diagnose heart failure with preserved ejection fraction (HFpEF) in patients with unexplained dyspnea, when non-invasive investigations are inconclusive. In particular, a hemodynamic diagnosis of HFpEF can be made when pulmonary artery wedge pressure (PAWP) is>15 mmHg at rest, or ≥25 mmHg during exercise. It is assumed that high PAWP translates in pulmonary congestion, driving patients' symptoms. However, individuals rarely exercise while laying down during daily-life activities, so that the correspondence between supine hemodynamic abnormalities and symptoms might be misleading in the interpretation of one individual's pathophysiology.

Case report. A slightly overweight 51 years-old woman was referred to our Center to undergo an exercise RHC for unexplained and worsening dyspnea after COVID-19 infection. First, she performed the test in supine position. At rest, filling pressures were at the upper limits of normal (PAWP 14 mmHg), with normal cardiac index (CI 3,3 L/min/m2). During exercise, PAWP increased to 36 mmHg, allowing to diagnose HFpEF. Despite this, she had a normal exercise capacity (oxygen consumption, VO2 22 ml/kg/min, 96% of predicted), thanks to an optimal cardiac output (CO) response (CI 7,7 L/min/m2, CO/VO2 slope 7). Then, the patients repeated a hemodynamic evaluation in the upright position. At rest, filling pressures and cardiac index were low (PAWP 0 mmHg, CI 1,9 L/min/m2). At the same maximal workload obtained in the supine position (80 W), PAWP increased just to 12 mmHg. CO response was suboptimal (CI 4,9 L/min/m2, CO/VO2 slope 5,9), leading to reduced exercise capacity (VO2 16 ml/kg/min, 70% of predicted).

Conclusions. The pathophysiology of HFpEF is complex and might be incompletely captured by standard tests, including exercise RHC. Both the hemodynamic behavior we observed in the supine and in the upright position fitted with the definition of heart failure, i.e. an adequate CO response to exercise in spite of high filling pressure (supine), or low CO response (upright). However, based on supine hemodynamics we might have attributed patients' symptoms to pulmonary congestion, while they are likely due to impaired left ventricular filling with low CO, i.e. "preload failure" (this latter potentially favored by COVID-19 infection). This may be relevant for the interpretation of HFpEF pathophysiology and for the therapeutic management of these patients.

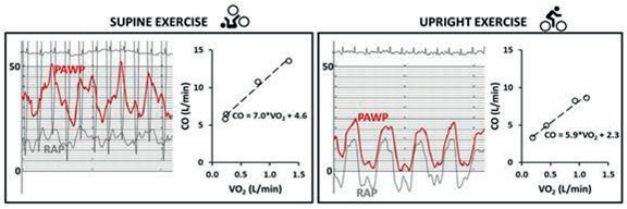

A920: ECHOCARDIOGRAPHIC DERIVED FORWARD LEFT VENTRICULAR OUTPUT IMPROVES RISK PREDICTION IN SYSTOLIC HEART FAILURE

Francesco Gentile (a, b, c), Paolo Sciarrone (a, b), Giorgia Panichella (a, b), Lorenzo Bazan (a), Vlad Chubuchny (b), Francesco Buoncristiani (b), Simone Gasparini (a), Claudia Taddei (b), Elisa Poggianti (b), Iacopo Fabiani (b), Alberto Aimo (a, b), Christina Petersen (b), Claudio Passino (a, b), Michele Emdin (a, b), Alberto Giannoni (a, b)

(a) SCUOLA SUPERIORE SANT'ANNA, PISA, ITALY; (b) FONDAZIONE MONASTERIO, PISA, ITALY; (c) UNIVERSITÀ DI PISA

Objectives. To assess the prognostic significance of the echocardiographic measures of forward left ventricular (LV) output in patients with systolic heart failure (HF).

Background. Though widely used to classify HF patients, the prognostic role of LV ejection fraction (LVEF) is debated. Being more representative of hemodynamics, the echocardiographic measures of forward LV output may improve risk prediction over LVEF.

Methods. Consecutive HF patients with LVEF <50% on guideline-recommended therapies undergoing an echocardiography including the evaluation of forward LV output (i.e., LV outflow tract velocity-time integral [LVOT-VTI], stroke volume index [SVi], and cardiac index [CI]) over a 6-year period, were selected and followed-up for the endpoint of cardiac and all-cause death.

Results. Among the 1,509 patients analyzed (71±12 years, 75% males, LVEF 35±9%), 328 (22%) died during a median 28-month (14-40) follow-up, 165 (11%) of which for cardiac causes. At multivariable regression analysis, LVOT-VTI (<0.001), SVi (p<0.001), and CI (p<0.001), but not LVEF (p>0.05), predicted cardiac and all-cause death. The optimal prognostic cut-offs for LVOT-VTI, SVi, and CI were 15 cm, 35 mL/m^2, and 2.3 L/min/m^2, respectively. Adding each of these measures to a multivariable risk model (including clinical, biohumoral, and echocardiographic markers) improved risk prediction (Chi-square 212 vs. 188, p<0.001). Among the different measures of forward LV output, LVOT-VTI and SVi were more accurate than CI (Chi-square 212 vs.204, p<0.001).

Conclusions. The echocardiographic evaluation of forward LV output improves risk prediction in HF patients across a wide LVEF spectrum over other well-established clinical, biohumoral, and echocardiographic prognostic markers.

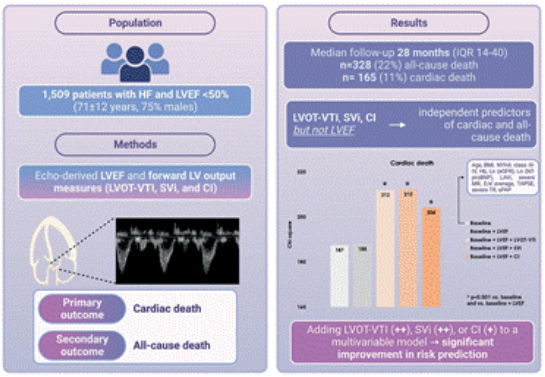

A921: CHARACTERISTICS OF PATIENTS INITIATED ON DAPAGLIFLOZIN FOR HEART FAILURE WITH REDUCED EJECTION FRACTION IN ITALIAN CLINICAL PRACTICE: AN INTERIM ANALYSIS OF EVOLUTION-HF ITALY

Pietro Ameri (a), Pasquale Perrone Filardi (j), Stefano Carugo (c), Alice Damele (d), Andrea Di Lenarda (e), Massimo Iacoviello (f), Ciro Indolfi (g), Giulia Ferrante (c), Andrea Mortara (h), Matteo Oldani (h), Francesco Orso (i), Stefania Paolillo (j), Rosanna Pugliese (f), Barbara Sposato (k), Erika Tempo (d), Massimo Volpe (l), Maurizio Volterrani (k), Andrea Ungar (i), Valentina Granelli (m), Francesca Pluchinotta (n), Francesca Mastromauro (n), Andrea Merlo (n), Marco Gnesi (n), Marco Metra (b), Giuseppe Rosano (k)

(a) DEPARTMENT OF INTERNAL MEDICINE, UNIVERSITY OF GENOVA, GENOVA, ITALY & CARDIOVASCULAR DISEASE UNIT, CARDIAC, THORACIC AND VASCULAR DEPARTMENT, IRCCS OSPEDALE POLICLINICO SAN MARTINO, GENOVA, ITALY; (b) SPEDALI CIVILI DI BRESCIA, BRESCIA, ITALY; (c) FONDAZIONE IRCCS CA' GRANDA OSPEDALE MAGGIORE POLICLINICO DI MILANO, MILANO, ITALY; (d) DEPARTMENT OF INTERNAL MEDICINE, UNIVERSITY OF GENOVA, GENOVA, ITALY; (e) SC PATOLOGIE CARDIOVASCOLARI, DIPARTIMENTO SPECIALISTICO TERRITORIALE, AZIENDA SANITARIA UNIVERSITARIA GIULIANO ISONTINA - ASUGI, TRIESTE, ITALY; (f) AZIENDA OSPEDALIERO UNIVERSITARIA OSPEDALI RIUNITI DI FOGGIA, FOGGIA, ITALY; (g) AZIENDA OSPEDALIERO UNIVERSITARIA MATER DOMINI, CATANZARO, ITALY; (h) POLICLINICO DI MONZA, MONZA, ITALY; (i) UNITÀ SCOMPENSO CARDIACO, SOD GERIATRIA UTIG, AZIENDA OSPEDALIERO UNIVERSITARIA CAREGGI & UNIVERSITY OF FIRENZE; (j) AZIENDA OSPEDALIERO UNIVERSITARIA "FEDERICO II", NAPOLI, ITALY; (k) IRCCS SAN RAFFAELE PISANA, ROMA, ITALY; (l) AZIENDA OSPEDALIERO-UNIVERSITARIA SANT'ANDREA, ROMA, ITALY; (m) FULLCRO S.R.L., ROMA, ITALY; (n) ASTRAZENECA S.P.A., MILANO, ITALY

Background. Dapagliflozin, an inhibitor of the sodium–glucose cotransporter-2 (SGLT2i), reduces the risk of hospitalization for Heart Failure (HF) and cardiovascular death in patients with HF and reduced Ejection Fraction (HFrEF). Currently, evidence is lacking on the use of dapagliflozin for the treatment of HFrEF in clinical practice, with particular reference to patient characteristics, treatment profiles, and patient-reported outcomes (PROs). EVOLUTION-HF Italy is aimed at filling these gaps by collecting Real-World Data from the Italian clinical practice; the study is part of the broader EVOLUTION-HF program, including studies in 13 European countries.

Objectives. The primary objective of the study is to describe the population of patients initiated on dapagliflozin for HFrEF in Italy and to estimate the occurrence of treatment discontinuations. Secondary objectives include the assessment of various PROs, such as HF symptoms and quality of life (Kansas City Cardiomyopathy Questionnaire, KCCQ), patient adherence to prescribed HF treatments (Medication Adherence Report Scale – 5 items, MARS-5), and functional capacity (6-Minutes Walking Test, 6MWT). An interim analysis (reported in this abstract) has been conducted at the end of enrollment, with the aim of describing baseline characteristics of study participants.

Methods. EVOLUTION-HF is an observational, longitudinal, descriptive study. Eligibility criteria are age ≥18 years old and initiation of dapagliflozin according to the approved HFrEF label. Patients with Type 1 Diabetes or previously treated with any SGLT2i are excluded. Dapagliflozin initiation was the index date for the study; in order to ensure that the treatment decision is independent from the decision to include a patient in the study, the enrollment window was set 14-45 days after index, and patients were still eligible if dapagliflozin was discontinued before enrollment. Follow-up lasts 1 year from the start of treatment, with data collection points after three, six, and 12 months after the index date.

Results. 256 participants were enrolled in 11 centres in Italy between April 2022 and April 2023. Mean age was 68.5 (SD 11.6) years, and 75.8% participants were male. A diagnosis of Type 2 Diabetes was recorded in 18.1% of the sample, and hypertension in 57.1%. Mean eGFR was 68.3 (SD 22.6) ml/min/1.73m2. Most participants were in NYHA class II (69.1%) or class II (18.7%) and had HF due to ischemic causes (55.7%); 31.7% had a hospitalization for HF in the previous year. Mean LVEF at index was 31.9% (SD 6.1) and NT-proBNP was elevated (mean 2829.4, SD 5020.0 pg/ml). Atrial fibrillation was observed in 23.8% of 231 patients with ECG data at baseline. Moderate or severe mitral regurgitation and tricuspid regurgitation were reported respectively in 41.6% and 20.4% of the 246 patients with echocardiography data. At the time of enrollment, 91% of patients were on beta-blockers, 70.3% on ARNI, 8.6% on ACEi, 7.4% on ARB, and 78.9% on MRA; 66.4% of patients were treated according to current guidelines for HFrEF (ARNI or ARB or ACEi + BB + MRA + SGLT2i). The median distance at 6MWT was 407.8 m (SD 154.1); median KCCQ total symptom score was 85.5 (IQR 66.5-96.0), median MARS-5 total score was 25 (IQR 24-25). The follow-up is ongoing, and completion of month 6 visits is expected in October 2023.

Conclusions. EVOLUTION-HF Italy study population contributes with novel data on Italian patients with HFrEF initiating dapagliflozin in real-world practice, including relevant information on treatment pattern, clinical parameters, and PROs.

A922: LONG-TERM FUNCTIONAL LIMITATIONS ON CARDIOPULMONARY EXERCISE TESTING IN EMOTIONS-TRIGGERED TAKOTSUBO SYNDROME

Jean Pierre Jabbour (a), Luca Arcari (b), Luca Cacciotti (b), Livia Valeri (a), Enrico Maggio (a), Damiano Magrì (a), Tommaso Recchioni (a), Roberto Badagliacca (a), Carmine Dario Vizza (a), Silvia Papa (a)

(a) SAPIENZA UNIVERSITÀ DI ROMA; (b) ISTITUTO M.G. VANNINI

Background. In patients with prior Takotsubo syndrome (TTS), long lasting functional cardiac limitations were described as compared with normal subjects. Unlike AMI, full recovery of left ventricular ejection fraction (LVEF) at echocardiogram and absence of myocardial scar at cardiac magnetic resonance (CMR) imaging have been described as key features of TTS[2]. Notwithstanding, even in the long-term and after recovery of LVEF, patients with previous TTS may display persistent limiting symptoms, reduced myocardial strain and increased native T1 mapping values at CMR[3,4] as compared to control subjects. Furthermore, TTS patients with a physical trigger have been described as having a worse prognosis both in the short as well as in the long-term[5]Emotions-triggered Takotsubo syndrome (E-TTS) has more favorable outcomes than TTS preceded by a physical trigger or by no identifiable factors. The aim of the present study was to assess long-term cardiac functional limitations in a cohort of asymptomatic E-TTS patients.

Methods. We performed an observational, retrospective case-control study of patients admitted for E-TTS at Vannini Hospital, Rome, Italy. From 2010 to 2018 we followed up 127 TTS patients[8], amongst which we selected all those with emotional triggers (60 patients). Among the latter group, we included in the study those patients with recovered left ventricular ejection fraction and without diastolic dysfunction, moderate to severe valvulopathies or overt clinical symptoms of dyspnea. Control subjects were matched for age, sex, body mass index and cardiovascular risk factors distribution and compared with the patients' cohort. Patients underwent CPET between 2 and 4 years from the acute hospitalization. All patients receiving beta-blocker drugs were discontinued from their therapy 48 hours before performing CPET in order not to affect the VO_2 peak results.

Results. Among 60 E-TTS patients, 40 were asymptomatic in NYHA functional class I. E-TTS patients who performed an exercise with an RER greater than 1.11 were 30 (75%). This cohort was considered for the analysis. Compared with control subjects, patients with prior E-TTS had lower peak VO2 and percentage of predicted peak VO2 (17.5 ± 3.0 vs 23.0 ± 7.0 P<0.001 and 70 ± 12% vs 103 ± 19%, P<0.001), VO2 at anaerobic threshold (AT) (11.4 ± 2,6 vs 15.9 ± 4.4; P<0.001), peak O2 pulse (9.6 ± 2,6 vs 13.7 ± 3.4, P<0.001) and higher VE/VCO2 slope (31 ± 3.7 vs 27,2 ± 3,6; P<0.001) compared with matched controls (Figure 1). We didn't find any statistically significant difference between E-TTS patients and controls in heart rate reserve (HRR) (33,8 ± 20,8 vs 26 ± 14,9; P=0.12), resting mean blood pressure (93 ± 13 vs 91 ± 11,6, P=0.88), peak mean blood pressure (121.3 ± 11 vs 123 ± 10, P=0.58), peak end-tidal Pco_2 (35.7 ± 4.2 vs 37 ± 5.6; P=0.39) and respiratory equivalent ratio (1.15 ± 0,06 vs 1.17 ± 0,09; P=0.26).

Conclusions. Despite their overall favorable outcome, asymptomatic patients with E-TTS were found to have long-term subclinical functional cardiac impairments. CPET proved to be a useful tool in the long-term evaluation of E-TTS patients after recovery of LVEF. Further studies are needed to fully clarify the origin of the detected CPET abnormalities as well as their prognostic relevance in patience with recovered E-TTS.

A923: THE DOUBLE ANAEROBIC THRESHOLD: A SIGN OF HIGHER SYMPATHETIC ACTIVATION IN HEART FAILURE PATIENTS?

Jean Pierre Jabbour (a, b), Domenico Filomena (a, b), Giovanni Rubino (a, b), Annalisa Caputo (a, b), Michela Boromei (a, b), Giorgia Serino (a, b), Giovanna Manzi (a, b), Matteo Neccia (a, b), Silvia Papa (a, b), Carmine Dario Vizza (a, b), Roberto Badagliacca (a, b)

(a) SAPIENZA UNIVERSITÀ DI ROMA; (b) POLICLINICO UMBERTO I

Background. Cardiopulmonary exercise testing (CPET) plays a crucial role in assessing the functional capacity of heart failure (HF) patients. Anaerobic threshold (AT) is a critical variable for determining exercise tolerance and can be calculated using three methods: the V-slope method,

the ventilatory equivalent method, and the end-tidal method. A lack of agreement between the V-slope method (metabolic AT) and the other two methods (ventilatory AT) can be observed, referred to as double threshold (DT) (Figure). DT is frequently observed in patients with heart failure with reduced ejection fraction (HFrEF) and is associated with a reduced ventilatory response during exercise and decreased overall sympathetic activation. Our study aimed to compare patients with and without DT in terms of exercise capacity, ventilatory efficiency, and recovery phase CPET parameters related to the level of sympathetic activation.

Methods. We performed an observational prospective study. From October 2022 to July 2023, we enrolled n=88 HF patients from our HF outpatients clinic (HFrEF 66%, HFmrEF 24%, HFpEF 10%). All patients underwent baseline echocardiography and clinical comprehensive assessment. All patients performed a symptom-limited incremental cycle ergometer CPET. CPET ramp-protocol was chosen in order to attain a VO2 peak in 8-12 minutes. For subsequent analysis, we considered all CPET with an RER greater than 1. AT was identified by three methods: the V-slope, the ventilatory equivalent, and the end-tidal methods. DT was defined as the presence of a divergence between the V-slope and ventilation-derived methods grater than 50 ml/min. Delta heart rate recovery (ΔHRR) was expressed as the difference between peak HR and HR at 1 minute after exercise peak; RER magnitude was expressed as relative increase in RER during recovery phase compared with the peak RER.

Results. Twenty-four patients (27%) showed DT (DT+). Patients DT+ were found to have higher VO2 peak/kg, VO2/HR peak, VO2/Work, Watt peak, PetCO2 peak, ΔHRR and RER magnitude (respectively 20,1 [18-21,5] ml/min/kg, 13,4 [11,7-15,5] ml/beat, 10 [9,3-11] ml/Watt and 114 [88-140] Watt, 35 [34-41] mmHg, 23,5 [19,7-27] beat/min and 0,35 [0,25-0,42]) than patients DT- (16 [13,5-19] ml/min/kg, 11,3 [9-13,5] ml/beat, 9,3 [8,4-10,3] ml/watt, 89 [68-113] Watt, 33 [30-36] mmHg, 14 [9-21] beat/min and 0,26 [9,15-0,3]; P<0.001) and lower VE/VCO2 slope (29,3 [24,5-33] vs 33,2 [30-38]; P<0.002). No difference were found between DT+ and DT- in terms of left ventricular ejection fraction (LVEF) (40 [35-45]% vs 35 [32-45]%; P=0,24), age (63 [55-71] vs 67 [54-73] years; P=0,43) and BMI (27 [25-29] vs 26 [24-28]; P=0,30).

Conclusions. DT+ patients showed higher exercise capacity, higher circulatory efficiency and lower ventilatory inefficiency. Moreover DT+ patients showed higher ΔHRR and RER magnitude consistent with a lower sympathetic activity.

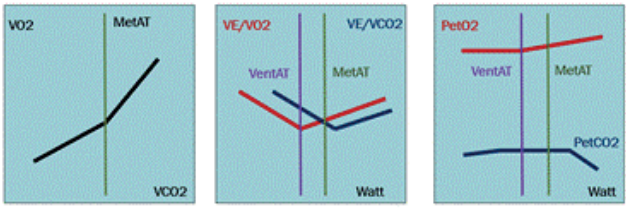

A924: CARDIAC RESYNCHRONIZATION IN ISCHEMIC AND WILD-TYPE TRANSTIRETIN AMYLOIDOSIS CARDIOMYOPATHY WITH HFREF

Carla Indennidate (a), Teresa Maria Capovilla (a), Manuela Iseppi (b), Marco Merlo (a), Gianfranco Sinagra (a), Aldostefano Porcari (a)
(a) CARDIO-THORACIC-VASCULAR DEPARTEMENT OF CATTINARA HOSPITAL, ASUGI, UNIVERSITY OF TRIESTE; (b) UNIVERSITY OF VERONA, DEPARTEMENT OF MEDICINE, SECTION OF CARDIOLOGY

Amyloidosis cardiomyopathy is still rarely associated to ventricular dysfunction although multiple recent analyses denounce high prevalence of this association. In this scenario, heart failure (HF) management is challenging. HF classical indications may be controversial, or efficacy of treatments may be different: only weighted decisions can assure the highest benefit for the patient. We propose the case of a 72-years-old man with permanent atrial fibrillation (AF), ischemic cardiomyopathy and a history of bilateral carpal tunnel syndrome. His first revascularization was performed in 2018 on the LMCA ostium up to proximal LAD artery. One year later, HF onset was associated to subcritical trivascular coronary artery disease and indication to medical therapy was given. EKG displayed normofrequent AF with RBBB and LPFB, and low voltages with pseudonecrosis. Echocardiography showed left ventricular mild dilation and parietal hypertrophy (IVS 23 mm, PW 17 mm) with moderately reduced ejection fraction (LVEF 42%). An infiltrative disease was suspected: CMR highlighted amyloidosis features and scintigraphy confirmed cardiac infiltration (Perugini Score 3). Genetic testing diagnosed TTR wild-type amiloydosis (NT-proBNP 2114 pg/mL, TnI 416 ng/L). Hemodynamic status was labile and worsening (NYHA II-III) and severe biventricular dysfunction progressively developed (LVEF 35%, RVFAC 29%) despite prescribed therapy (SGLT2i, MRA, diuretic). Tafamidis initiation improved symptoms, but not hemodynamic status. His ECG changed through the years with a progressive QRS elongation (150>225 ms) and slowing of atrial fibrillation (mean HR 55 bpm). His arrhythmic profile changed too, showing increasing polymorphic single and repetitive extra-systoles (3695/24h) and rising asystolic pauses (max 2 seconds). Considering his worsening HF likely also influenced by slow rate AF and the progressive elongation of QRS without any other possibility of therapy implementation, CRT appeared a necessary choice. We privileged defibrillation because of the increasing burden of ventricular arrhythmias, severe ventricular dysfunction and diffuse LGE in CMR. We therefore decided to implant a CRT-D (RV electrode in apex, LV electrode in anterolateral branch of coronary sinus). After implantation, 12% shortening of QRS and 95% paced ventricles with an increased heart rate (HR 85 bpm, VVIR 60 -120 bpm) was seen. At 1 month following visit, diuretic dose was reduced, symptoms and hemodynamics had been stable since implantation. In conclusion ischemic and amyloidosis cardiomyopathy can coexist and can determine variegate profiles of disease. An amyloidosis and ischemic HFrEF needs optimized therapy and different classes of risk must be considered. Primary prevention in ATTR amyloidosis hasn't shown benefit on survival and tachyarrhythmia risk is lower than in AL amyloidosis. However, the overall risk of this patient justifies our choice. Despite class IIa indication for CRT in classic non-LBBB HF, in this case ventricular dyssynchrony may be a more powerful contributor of decompensation: in the absence of other actionable therapeutic options, CRT can improve symptoms and survival.

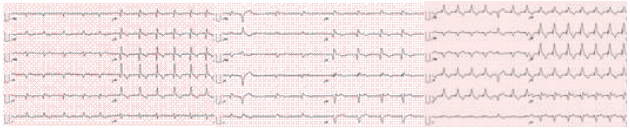

A925: OBESITY AND CLINICAL OUTCOMES IN ACUTE HEART FAILURE ACCORDING TO LEFT VENTRICULAR EJECTION FRACTION

Daniele Cocianni (a), Davide Stolfo (a), Davide Barbisan (a), Stefano Contessi (a), Maria Perotto (a), Jacopo Giulio Rizzi (a), Giulio Savonitto (a), Eugenio Zocca (a), Enrico Brollo (a), Elisa Soranzo (a), Gianfranco Sinagra (a)
(a) UNIVERSITÀ DEGLI STUDI DI TRIESTE, ASUGI

Background. Obesity is highly prevalent in patients with acute heart failure (HF). Previous studies explored the relationship between body mass index (BMI) and clinical outcome in HF, but in the acute setting evidence is more limited.

Objectives. We sought to assess the characteristics and prognostic implications of obesity in acute HF (AHF) across ejection fraction (EF) phenotypes.

Methods. We retrospectively enrolled a cohort of patients hospitalized for AHF. Obesity was defined as body mass index (BMI) ≥30kg/m^2. Patients were classified according to LVEF into two groups: HFrEF (LVEF ≤40%) and HFmrEF/HFpEF (LVEF>40%). Primary end point was 1-year all-cause mortality or rehospitalization for HF.

Results. 2098 patients were enrolled; 561 patients (27%) had BMI ≥30kg/m^2. Obese patients were younger, more frequently males and diabetic, had higher systolic blood pressure (SBP) and lower natriuretic peptides (NPs) at admission; they also presented less commonly mitral or tricuspid regurgitation, and had lower estimated pulmonary pressure (PASP). These differences were found when comparing obese with non-obese patients both in the entire population, in HFrEF phenotype and in HFmrEF/HFpEF phenotype; in HFrEF, obese patients had lower left ventricular indexed volumes, and were treated with higher dosages of anti-neurohormonal drugs and diuretics. At logistic regression multivariable analysis, obesity was an independent predictor of HFmrEF/HFpEF phenotype (OR=1.414, p=0.039). After multiple adjustments, obesity was independently associated with lower risk of 1-year all-cause mortality/HF rehospitalizations (HR=0.579, p=0.001) and 1-year all-cause mortality (HR=0.592, p=0.045). Factors associated with higher risk of 1-year all-cause mortality/HF rehospitalizations in obese patients were ischemic etiology, peripheral artery disease (PAD) and higher PASP, whereas in non-obese diabetes, PAD, SBP, urea, NPs, LVEF and right ventricular dysfunction.

Conclusions. In our cohort of AHF patients, obesity had a prevalence of 27%. Obese patients more likely presented with HFmrEF/HFpEF phenotype. Obesity was associated with lower risk of 1-year mortality or HF rehospitalization. In our population, predictors of clinical events differed between obese and non-obese individuals, and this might encourage a more individualized approach to risk stratification of patients admitted with AHF.

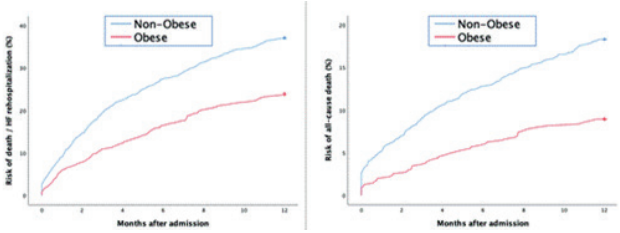

A926: EFFETTO DI SGLT2 INIBITORI SULLA FUNZIONE CARDIACA IN PAZIENTI CON SCOMPENSO CARDIACO AD FE>40%: RISULTATI PRELIMINARI DELLO STUDIO DISCOVER PRESERVED.

Giuseppina Novo (a), Salvatore Milazzo (a), Federico Guerra (b), Concetta Pastore (i), Giovanni Benfari (c), Fabio Balasus (a), Alberto Giannoni (d), Pietro Mazzeo (e), Ciro Santoro (f), Paolo Severino (g), Riccardo Inciardi (h), Michele Correale (k), Erberto Carluccio (l), Anna De Giovanni (m), Matteo Lisi (n), Annalisa Pasquini (o), Concetta Zito (p), Antonella Moreo (j), Matteo Cameli (i)

(a) DIPARTIMENTO DI PROMOZIONE DELLA SALUTE, MATERNO INFANTILE, DI MEDICINA INTERNA E SPECIALISTICA, UNIVERSITÀ DI PALERMO; (b) CLINICA DI CARDIOLOGIA ED ARITMOLOGIA, UNIVERSITÀ POLITECNICA DELLE MARCHE, AZIENDA OSPEDALIERO-UNIVERSITARIA, OSPEDALI RIUNITI, ANCONA; (c) UNIVERSITÀ DEGLI STUDI DI VERONA, DIVISIONE DI CARDIOLOGIA, DIPARTIMENTO DI MEDICINA, VERONA; (d) ISTITUTO DI SCIENZE DELLA VITA, SCUOLA SUPERIORE SANT'ANNA, PISA; (e) DIPARTIMENTO DI SCIENZE MEDICHE E CHIRURGICHE, UNIVERSITÀ DI FOGGIA, FOGGIA, ITALIA; (f) DIVISIONE DI CARDIOLOGIA, DIPARTIMENTO DI SCIENZE BIOMEDICHE AVANZATE, AZIENDA OSPEDALIERA UNIVERSITARIA FEDERICO II, NAPOLI, ITALIA; (g) DIPARTIMENTO DI SCIENZE CARDIOVASCOLARI, RESPIRATORIE, NEFROLOGICHE, ANESTESIOLOGICHE E GERIATRICHE, UNIVERSITÀ DI ROMA SAPIENZA, ROMA, ITALIA; (h) ASST SPEDALI CIVILI DI BRESCIA, DIPARTIMENTO DI SPECIALITÀ MEDICHE E CHIRURGICHE, SCIENZE RADIOLOGICHE E SANITÀ PUBBLICA, UNIVERSITÀ DEGLI STUDI DI BRESCIA, BRESCIA; (i) U.O.C CARDIOLOGIA, DIPARTIMENTO DI BIOTECNOLOGIE MEDICHE, UNIVERSITÀ DEGLI STUDI DI SIENA, SIENA; (j) A. DE GASPERIS CARDIO CENTER, AZIENDE SOCIO SANITARIE TERRITORIALI (ASST) GRANDE OSPEDALE METROPOLITANO NIGUARDA, MILANO, ITALIA; (k) OSPEDALI RIUNITI, FOGGIA; (l) UNIVERSITÀ DI PERUGIA; (m) UNIVERSITÀ DI NOVARA; (n) DEPARTMENT OF CARDIOVASCULAR DISEASE, AUSL ROMAGNA, RAVENNA; (o) UNIVERSITÀ CATTOLICA DEL SACRO CUORE ROMA; (p) UNIVERESITÀ DI MESSINA

Background. Gli SGLT2 inibitori hanno dimostrato di migliorare l'outcome cardiovascolare, indipendentemente dalla presenza di diabete, nei pazienti con scompenso cardiaco ad FE>40%. Obiettivo del nostro studio è stato quello di valutare gli effetti di tali farmaci sui parametri ecocardiografici morfo-funzionali.

Metodi. In uno studio multicentrico, prospettico, osservazionale, sono stati arruolati pazienti con scompenso cardiaco a frazione di eiezione>40%, che per l'ottimizzazione della terapia antidiabetica erano trattati con SGLT2i. Tutti i pazienti sono stati sottoposti ad una valutazione cardiologica al basale e al follow up, includente la valutazione dell'N-TproBNP ed un esame ecocardiografico completo, con analisi degli indici di deformazione miocardica mediante metodica di ecocardiografia avanzata speckle tracking.

Risultati: Sono stati arruolati 85 pazienti con età media di 68 ± 11 anni, M:F =66:19. Il 76% era in trattamento con dapagliflozin 10mg e il 25% con empagliflozin 10mg. La frazione di eiezione basale era lievemente ridotta (49 ±7.4%). Ad un follow up a 6 mesi, la classe funzionale NYHA ha mostrato un miglioramento significativo (T0 NYHA 1: 24.8%; 2: 57.1%; 3: 18.1% al T1 NYHA 1: 38.2%; 2: 50.5%; 3: 11.2%, P=0.05), così come i valori di NT-proBNP (T0: 1963.5 ±2137.6; T1: 1079.8 ±1174.5, P=0.006), la frazione di eiezione e il GLS si sono mantenuti stabili, mentre si è osservato un miglioramento degli indici di funzione diastolica (E/e' medio T0 11.6 ±6.4, T1 9.4 ±5.6, P=0.022), della PAPs (T0: 35.7 ±14.7, T1 31.8 ±10.2, P=0.06) e degli indici di funzione del ventricolo destro (FWRVLS T0 -18.7±5, T1 -20.7 ±6.1, p=0.015).

Conclusioni. In un follow up a breve termine il nostro studio ha dimostrato effetti favorevoli del trattamento di SGLT2i sulla funzione diastolica del ventricolo sinistro e sulla funzione sistolica longitudinale del ventricolo destro in pazienti con HFpEF. Prevediamo di incrementare la popolazione in studio e la durata del follow up per ulteriormente verificare questi risultati.

A927: VALUTAZIONE DELLE MODIFICAZIONI DELLA QUALITÀ DI VITA E DELLA CAPACITÀ FUNZIONALE A SEGUITO DELL'OTTIMIZZAZIONE ECOCARDIOGRAFICA DELLA TERAPIA DI RESINCRONIZZAZIONE CARDIACA IN PAZIENTI AFFETTI DA INSUFFICIENZA CARDIACA

Guido Pasero (a), Alessandro Guareschi (a), Lorenzo Fargione (a), Francesco Moda (a), Filippo Toriello (b), Massimo Saviano (b), Alberto Vincenzo Pollina (b), Federica Valli (b), Marco Vicenzi (a, b), Stefano Carugo (a, b)

(a) DEPARTMENT OF CLINICAL SCIENCE AND COMMUNITY HEALTH, UNIVERSITY OF MILAN, ITALY; (b) DEPARTMENT OF CARDIO-THORACIC-VASCULAR DISEASES, FOUNDATION IRCCS CA GRANDA OSPEDALE MAGGIORE POLICLINICO, ITALY

Introduzione. La terapia di resincronizzazione cardiaca (CRT) è un'opzione terapeutica nei pazienti con scompenso cardiaco a frazione d'eiezione ridotta (HFrEF) associato a specifiche alterazioni della conduzione intraventricolare al fine di migliorare la sintomatologia e ridurre morbidità e mortalità di questi pazienti. La valutazione della risposta alla CRT è alquanto problematica e, ad oggi, i parametri predittivi di risposta, considerati nei maggiori trial, sono stati la durata e la morfologia del QRS. Tuttavia, in letteratura è descritta una percentuale del 30-40% di cosiddetti *non responders*, ossia di pazienti che non traggono un reale beneficio dalla stimolazione biventricolare.

Materiali e metodi. Abbiamo condotto uno studio pilota con l'obiettivo di ottimizzare la risposta alla CRT attraverso la modifica di alcuni parametri di stimolazione elettrica del dispositivo (intervalli di stimolazione A-V e V-V a frequenze cardiache incrementali, così come la frequenza cardiaca basale e massimale di trascinamento impostate sul device) mediante guida ecocardiografica. Quest'ultima ha valutato in *real-time* parametri di funzionalità sistolica, tramite calcolo indiretto dello stroke volume e dell'indice cardiaco, e di rilasciamento ventricolare. I criteri di inclusione per l'arruolamento prevedevano pazienti con HFrEF sintomatici con FEVS ≤45% *non responder* alla CRT con percentuale di pacing biventricolare>97%. L'efficacia dell'intervento è stata oggettivata valutando le modifiche in termini di qualità della vita (QdV), misurata con *Kansas City Cardiomyopathy Questionnaire* (KCCQ), e di capacità funzionale dei pazienti, misurata con test del cammino dei sei minuti (6MWT), scala di Borg e classe NYHA. I dati sono stati raccolti all'arruolamento e al follow-up a 3 mesi e 6 mesi.

Risultati. Lo studio ha mostrato come le ottimizzazioni della CRT sopradescritte abbiano portato ad un miglioramento, in prima analisi, della QdV, con incremento percentuale mediano dei punteggi del KCCQ del 11,1% a 3 mesi e del 7,3% a 6 mesi (mediana KCCQ al T0 75,1 (IQR 13,2), al T1 83,5 (IQR 20,9), al T2 81,1 (IQR 24,6)). Si è assistito, in secondo luogo, ad un miglioramento della capacità funzionale, con crescita della distanza percorsa al 6MWT con incremento percentuale mediano a 3 mesi del 2,3% e a 6 mesi del 7,0% (mediana 6MWT al T0 430m (IQR 78), al T1 440m (IQR 73) e al T2 460m (IQR 49)); riduzione della fatica percepita nello sforzo stimata con punteggio della scala di Borg (50% dei soggetti a 3 mesi, 83% a 6 mesi) e riduzione della scala NYHA (50% dei soggetti a 3 mesi, 66% a 6 mesi).

Conclusioni. Il nostro studio, pur con le limitazioni dovute ad uno scarso *sample size*, mostra come questa nuova metodica di ottimizzazione dei parametri elettrici dei dispositivi per la CRT tramite guida ecocardiografica possa migliorare la qualità della vita e la capacità funzionale dei pazienti. Ulteriori studi sono necessari per confermare questo trend.

A928: SGLT2 IMPROVES HEMODYNAMIC PROFILE IN A REAL WORLD HF POPULATION

Antonella Rispoli (a), Francesco Loria (a), Rosanna Di Fonzo (a), Valeria Visco (a), Carmine Vecchione (a), Gennaro Galasso (a), Michele Ciccarelli (a)

(a) UNIVERSITÀ DEGLI STUDI DI SALERNO

Introduction. Nowadays, heart failure (HF) represents an ever-evolving medical and economic challenge although more and more therapeutic strategies are implemented to prevent the onset and to treat this clinical complex medical syndrome adequately. SGLT2 inhibitors represent a deep revolution of the therapeutic approach to heart failure.

Aims. This observational prospective study had the aim of evaluating how SGLT2 inhibitors impact on clinical, biochemical, echocardiographic and functional parameters in a real-world HF population.

Methods. From January 2022 to June 2023 we enrolled 80 patients with chronic heart failure on optimal medical therapy initiating treatment with SGLT2 inhibitors according to the ESC guidelines. This study included 80 patients from the HF Ambulatory of University Hospital of Salerno. Data on demographics, medical history, pharmacological treatments, clinical characteristics and echocardiographic parameters were collected at the enrollment and after 6 months. After the enrollment we divided patients due to Forrester classification of HF in four hemodynamic profile A: normal flow, normal pressure; B normal flow high pressure; C low flow normal pressure; D low flow, high pressure (Figure 1).

Results. No patient was lost at follow-up and no patient needs to interrupt the treatment with SGLT2 inhibitors. Only 3 (3,75%) patients had an hospitalization for worsening heart failure. Noteworthy, figure 2 and 3 highlight how patients had a significant improvement in NYHA class and quality of life evaluated by EQ-5D questionnaire up to 6 months and how echicardiographic parameters improved and changed after six months from the introduction of SGLT2 inhibitors.

Conclusions. Failing heart is an engine out of fuel whose pathological remodeling determines inefficiencies. In this perspective, SGLT2 inhibitors, in view of their potential direct myocardial and indirect systemic effects, represent a new therapeutic opportunity. Our real-world HF population, according to clinical trials, confirms the beneficial effects of treatment with glyphozines, demonstrating a better hemodynamic balance and improving the quality of life.

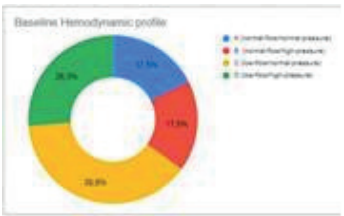

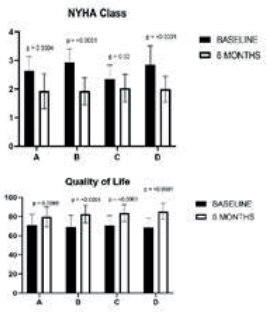

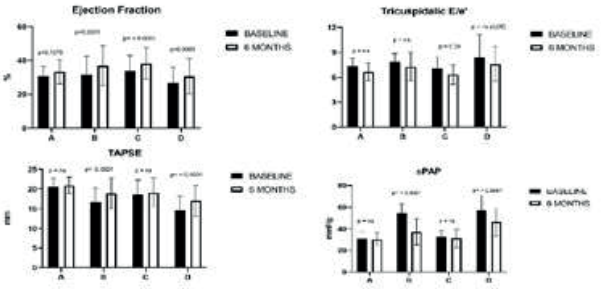

A929: POOR IN-HOSPITAL CONGESTION IMPROVEMENT IN ACUTE HEART FAILURE PATIENTS CLASSIFIED ACCORDING TO LEFT VENTRICULAR EJECTION FRACTION: PROGNOSTIC IMPLICATIONS

Gaetano Ruocco (a), Nicolas Girerd (b), Tripti Rastogi (b), Zohra Lamiral (b), Alberto Palazzuoli (c)
(a) CARDIOLOGY UNIT, BUON CONSIGLIO HOSPITAL, FATEBENEFRATELLI, NAPLES, ITALY; (b) UNIVERSITE DE LORRAINE, INSERM, CENTRE D'INVESTIGATIONS CLINIQUES 1433,CHRU DE NANCY, INSERM 1116 AND INI-CRCT (CARDIOVASCULAR AND RENAL CLINICAL TRIALISTS) F-CRIN NETWORK, NANCY, FRANCE; (c) CARDIOVASCULAR DISEASES UNIT, CARDIO-THORACIC AND VASCULAR DEPARTMENT, LE SCOTTE HOSPITAL, UNIVERSITY OF SIENA, SIENA, ITALY

Background. Residual congestion in acute heart failure (AHF) is related to poor prognosis. However, we lack data on the prognostic value of changes in a combined assessment of in-hospital congestion. We sought evaluated the association of in-hospital congestion changes with subsequent prognosis according to LVEF classification.

Methods. Patients (N=244, 80.3±7.6 years, 50.8% male) admitted for acute HF in 2 European tertiary care centers underwent clinical assessment, echocardiography, lung ultrasound (LUS) ultrasound and natriuretic peptides (NP) measurement at admission and discharge. The primary outcome was the composite of All-cause mortality and/or HF re-hospitalization.

Results. In the 244 considered patients (95 HfrEF, 57 HFmrEF and 92 HFpEF), limited improvement in clinical congestion score (Hazard ratio 2.33, 1.51 to 3.61, p=0.0001), NP levels (2.29, 1.55 to 3.38, p<0.0001) and B-lines count (6.44, 4.19 to 9.89, p<0.001), had significnatly higher risk of outcome compared to patients experiencing more sizeable decongestion. The same pattern of association was observed when adjusting on confounding factors. A limited improvement in clinical congestion score and B-lines count was related to poor prognosis in all LVEF categories.

Conclusions. In AHF, the degree of congestion reduction assessed over the in-hospital stay period, can stratify the subsequent event risk. Limited improvement in both clinical congestion and B-lines count are related to poor prognosis irrespectively of LVEF.

A930: A FUTURISTIC THERAPY IN CURRENT REAL LIFE

Tiziana Spezzano (a), Michela Giovanna Coccia (a), Fabrizio Giofrè (a), Alessio Damiano (a), Pietro Gaetano (a), Amedeo Ferro (a), Carlo Augusto Maria Bosatra (a), Maria Lorennie Breghi (a), Elisabetta Colombi (a), Marco Griffini (a), Riccardo Osti (a), Maria Chiara Paradisi (a), Ada Sacchi (a), Luca Ballerini (a), Michele Pasotti (a), Pietro Broglia (a)
(a) DIPARTIMENTO DI CARDIOLOGIA E UTIC, OSPEDALE CIVILE DI VOGHERA, ASST-PAVIA, ITALIA

Recent clinical evidence and guidelines suggest that patients with heart failure (HF) with reduced ejection fraction (LVEF <35%) due to ischaemic aetiology must be implanted with cardioverter defibrillator (ICD) to prevent sudden cardiac death of arrhythmic genesis. Moreover, in symptomatic patients with HFrEF, in addition to optimal medical therapy, it is possible to use a cardiac resynchronization therapy (CRT) in presence of a left bundle-branch block with QRS ≥150ms or, with a weaker recommendation, QRS duration 130-149ms, in order to improve symptoms. However, two-third of patients with HFrEF do not meet these criteria. Recent literature reports that Cardiac Contractility Modulation (CCM) therapy represents a valid therapeutic option in symptomatic patients, not eligible for CRT and with LVEF between 25% and 45% by improving quality of life and alleviating HF-related symptoms. We present the case of a patient with HFrEF where CCM therapy proved to be effective. A 68-year-old woman came in our Department in February 2022 due to persistent asthenia and dyspnoea in NYHA class II – III. In August 2017 she had an anterior myocardial infarction, treated with PCI, with residual LVEF 25% and moderate mitral regurgitation. Discharged on beta-blocker, MRA and ACEi therapy with subsequent optimization and updating (she was taking ARNI, SGLT2i, MRA and Beta-Blocker) but without improvement of the LVEF and with the persistence of symptoms of HF. In 2020 a single-chamber defibrillator was implanted for primary prevention. In the serial echocardiograms, always performed by the same operator, LVEF was always around 27-30%. During the February visit the echocardiogram showed a persistent reduction of LVEF (27%) due to left anterior wall, apex, and middle-distal septal akinesia and severe dilatation of the left ventricle (EDVi=96.81ml/m2). The electrocardiogram showed a QRS complex of 100ms. After authorization by the hospital, ASST-Pavia, being an innovative therapy and after Informed Consent, in July 2022 we performed the implant of an Optimizer Smart® to deliver CCM therapy. During follow-up visit on April 2023 the patient refers subjective improvement since discharge of hospital and clear reduction in dyspnoea (functional class NYHA I) and improved quality of life. The electrocardiogram showed sinus rhythm, 70 beats per minute and atrial ventricular block type I with PQ interval of 237ms, so we halved dose of beta-blocker. In confirmation of what was reported by the patient, we found in echocardiography left ventricular volume reduction (EDVi=75ml/m2); improvement of LVEF (Biplane=40%, Triplane=36%) with akinetic zones obviously unchanged; improvement in the echo diastolic pattern; reduction of the entity of mitral regurgitation (functional regurgitation of mild degree). This clinical case describes one of the first cases of CCM therapy in Italy. This innovative intervention with implantation of an Optimizer Smart® device improved the patient's quality of life and reduced heart failure symptoms despite having one of the mainstay heart failure therapies (beta-blocker) reduced after CCM implantation. This case report underscores the importance of proper patient selection to achieve the intended goal of improving quality of life. More studies are needed to evaluate the efficacy of this therapy and properly guide patient selection.

A931: ELIGIBILITY FOR VERICIGUAT IN A REAL-WORLD, CONTEMPORARY HEART FAILURE POPULATION

Giuseppe Vergaro (a, b), Alberto Aimo (a, b), Francesco Gentile (a, b), Giulia Elena Mandoli (c), Marta Focardi (c), Vincenzo Castiglione (a, b), Alberto Giannoni (a, b), Francesco Cappelli (d), Alessandra Fornaro (d), Erberto Carluccio (e), Riccardo Liga (f), Matteo Cameli (c), Giorgia Panichella (d), Claudio Passino (a, b), Carlo Di Mario (d), Michele Emdin (a, b)
(a) SCUOLA SUPERIORE SANT'ANNA; (b) FONDAZIONE TOSCANA GABRIELE MONASTERIO; (c) AZIENDA OSPEDALIERA UNIVERSITARIA SENESE; (d) AZIENDA OSPEDALIERA UNIVERSITARIA CAREGGI; (e) AZIENDA OSPEDALIERA UNIVERSITARIA DI PERUGIA; (f) AZIENDA OSPEDALIERA UNIVERSITARIA PISANA

Background. Vericiguat is a soluble guanylate cyclase stimulator and improves survival in patients with heart failure and reduced ejection fraction (HFrEF) with increased risk of decompensation. Real-world data on how many patients could be eligible to vericiguat therapy derive from outdated registries.

Methods. Data from consecutive HF patients undergoing an elective ambulatory visit at 5 University Hospitals from July 3 to July 24, 2023 were collected. Independent investigators assessed which patients 1) met the eligibility criteria of VICTORIA, or 2) complied with HF Guideline recommendations, 3) regulatory agency criteria, or 4) criteria for refundability according to the Italian regulatory agency.

Results. Patients (n=346, 72% men, median age 69 years) had HFrEF in 57% of cases, ejection fraction <45% in 68%, and New York Heart Association class II-IV symptoms in 76%. Nine percent of patients met the eligibility criteria of VICTORIA. European and American HF Guideline recommendations were met in 13% of patients. Patients meeting Food and Drugs Administration (FDA) or European Medicines Agency (EMA) label criteria were 19% and 17%, respectively. Drug costs were covered by the Italian national health system in 10% of patients (if a sodium glucose contransporter 2 inhibitor [SGLT2i] was not mandatory), or in 8% (if SGLT2i was requested).

Conclusions. In a real-world study, 9% of patients met the eligibility criteria of VICTORIA, but up to 15% complied with Guideline recommendations, and up to 19% with FDA or EMA criteria. In Italy, drug costs can be covered in up to 10% of patients.

A932: CHRONIC KIDNEY DISEASE IN HEART FAILURE PATIENTS WITH REDUCED EJECTION FRACTION: A REAL-WORLD ANALYSIS ON SACUBITRIL/VALSARTAN PRESCRIPTION AND OUTCOME IMPLICATIONS

Niccolo Bonini (a, b), Josef Luli (a), Federico Muto (a), Marco Stuani (a), Kevin Serafini (a), Francesco Sbarra (a), Vera Laus (a), Francesco Chiriaco (a), Enrico Tartaglia (a), Emiliano Guerra (a), Rachele Bertolini (a), Marco Vitolo (a, b), Jacopo Francesco Imberti (a, b), Davide Antonio Mei (a), Giuseppe Boriani (a)
(a) CARDIOLOGY DIVISION, POLICLINICO DI MODENA, UNIVERSITY OF MODENA AND REGGIO EMILIA; (b) CLINICAL AND EXPERIMENTAL MEDICINE PHD PROGRAM, UNIVERSITY OF MODENA AND REGGIO EMILIA

Background and Aim. Real-world data of patients (pts) with heart failure with reduced ejection fraction (HFrEF) treated with Sacubitril/Valsartan (Sa/Va) and chronic kidney disease (CKD) are still lacking, especially on the changes in renal function (eGFR), left ventricular ejection fraction (LVEF), and the cardiovascular outcomes. We reported an analysis from a contemporary cohort of HFrEF ambulatory pts.

Methods. CKD pts had an eGFR <60ml/min. A worsening eGFR (w-eGFR) was defined as a decline ≥20% vs baseline (bas.). A high response LVEF (hr-LVEF) was defined as an increase of LVEF≥10% vs bas. Clinical outcomes were all-cause death (ACD) and MACE, a composite outcome of HF hospitalization, acute coronary syndromes, stroke/TIA and ACD.

Results. A total of 219 pts were included with a median age of 66.5 years [IQR 58.5-73.0], 17.8% female, median LVEF 30% [IQR 29-35], median NYHA class 2 [IQR 2-3], with mid-high Sa/Va dosage at bas. in 31.9%. Fifty-seven (26.0%) pts had CKD, with a median eGFR of 53.9 [IQR 47.8-56.6], and 162 (74.0%) were noCKD pts with a median eGFR of 78.8 [70.2-89.8]. After 759 days [701-847] of follow-up, nine (4.1%) pts had interrupted Sa/Va, without significant differences between noCKD and CKD pts (p=0.571). At the end of follow-up, 50.4% pts received a mid-high Sa/Va dosage, with no higher dosages for noCKD vs CKD (p=0.806). In noCKD pts eGFR significantly lowered at follow-up vs bas. (p=0.004) attaining a value of 76.9 [62.8-89.1], while a no changes were found in CKD pts (p=0.958), [Figure]. W-eGFR occurred in 14 patients (15.7%), without differences between the two groups (p=0.173). LVEF improved vs bas. in both CKD and noCKD pts (p<0.001), [Figure]. An hr-LVEF was observed in 54 pts (48.2%), without differences between the two groups (p=0.843). Twelve deaths (7.4%) occurred in noCKD pts vs 7 (12.3%) in CKD pts (p=0.279); no difference was found for MACEs (p=0.506).
Conclusions. After two years of follow-up, CKD HFrEF pts treated with Sa/Va had on average no changes in eGFR and did not require higher withdrawal Sa/Va rates vs noCKD. Moreover, LVEF improvement vs bas. was similar to what observed in noCKD pts. These results indicate that Sa/Va is a safe and beneficial treatment in real-world HFrEF pts with CKD.

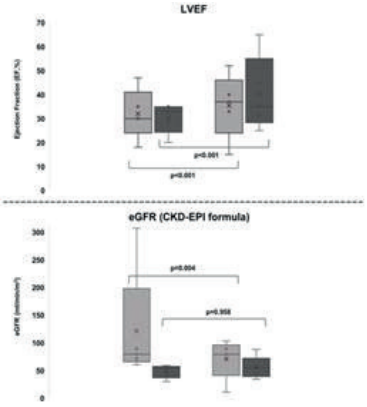

A933: DAPAGLIFLOZIN IN PATIENTS WITH HEART FAILURE, REDUCED EJECTION FRACTION AND CHRONIC KIDNEY DISEASE

Pietro Mazzeo (a, b), Gabriella Bufano (a, b), Michele Correale (c), Vincenzo Ceci (d), Salvatore Ferrara (d), Damiano D'Alessandro (d), Lucia Tricarico (c), Marco Amatruda (d), Luigi Nardella (d), Nicola Di Nunno (d), Michele Granatiero (d), Maria Delia Corbo (a, b), Vincenzo Fioretti (a, b), Donato Gerardi (a), Massimo Iacoviello (d), Daniele Natale Brunetti (d), Eugenio Stabile (a, b)
(a) CARDIOVASCULAR DEPARTMENT, AZIENDA OSPEDALIERA REGIONALE "SAN CARLO", POTENZA, ITALY; (b) CARDIOLOGY DIVISION, "SAN PIO DA PIETRELCINA" HOSPITAL, AZIENDA OSPEDALIERA "SAN CARLO", MARSICOVETERE, ITALY; (c) CARDIOTHORACIC DEPARTMENT, POLICLINICO RIUNITI UNIVERSITY HOSPITAL, FOGGIA, ITALY; (d) DEPARTMENT OF MEDICAL AND SURGICAL SCIENCES, UNIVERSITY OF FOGGIA, FOGGIA, ITALY

Background. chronic kidney disease (CKD) in chronic heart failure (CHF) population is associated with increased morbidity and mortality. Large clinical trials showed that sodium–glucose cotransporter 2 inhibitors ($SGLT_2$-i) improve glycemic control in adults with type 2 diabetes mellitus, with in addition favourable effects on renal and cardiovascular outcomes. In CHF patients, the slope of estimated glomerular filtration rate (eGFR) is faster compared to healthy control and it may affect therapeutic choices. On the other hand, DAPA-CKD trial revealed a slower slope of eGFR in patients with CKD treated with dapagliflozin, but DAPA-CKD trial accounts only 10% of CHF patients. Whether the effect of dapagliflozin on eGFR slope in CKD occurs also in CHF subgroup, especially in heart failure with reduced ejection fraction (HFrEF), is unknown.
Aim. The aim of the study is to evaluate the effect on eGFR slope in CKD patients with HFrEF who received dapagliflozin compared to a control group.
Methods. This is a multicenter, observational study, in which consecutive outpatients with CHF were evaluated in the Daunia-Lucania Heart Failure Registry. Outpatients with HFrEF, expressed as left ventricular ejection fraction (LVEF) below 40% and mild CKD (eGFR 60-90 ml/min/1.73m^2) were enrolled. Dapagliflozin subgroup was constituted by subjects stated on therapy with dapagliflozin. Control group was formed by outpatients in optimized CHF medical therapy but with $SGLT_2$-i intolerance or contraindications, as listed in DAPA CKD trial exclusion criteria. All patients underwent clinical evaluation, transthoracic echocardiography and laboratory tests including renal function. Follow-up evaluation was planned after 6 months.
Results. Between May 2021 and July 2022, 46 patients (68±8.62 years, 82% male, LVEF 31,90 ± 5,56%) with either CKD and HFrEF were enrolled. Dapagliflozin group and control group were homogeneous in all baseline characteristics, including prevalence of type 2 diabetes. At 6 months follow-up we found a slight, although not significant, improvement in renal filtration in dapagliflozin group (62.68 ± 14.39 ml/min/1.73m^2 versus 64.33 ± 16.23 ml/min/1.73m^2, p value: 0.07) in contrast to the control group which showed significative worsening in renal filtration (61.86 ± 17.01 ml/min/1.73m^2 versus 57,92 ± 19.35 ml/min/1.73m^2, p value: 0.02).
Conclusions. the addition of dapagliflozin on top of optimal medical therapy in CKD patients with HFrEF may be associated with a slower slope in eGFR compared to control group.

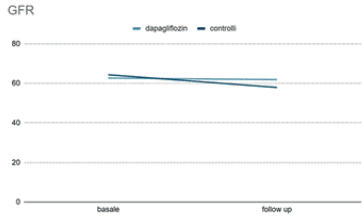

A934: A GIANT TRICUSPID ANNULAR CALCIFICATION AND RIGHT VENTRICULAR FAILURE: AN UNCOMMON LIAISON

Gabriella Bufano (a, b), Pietro Mazzeo (a, b), Costantino Smaldone (a), Maria Delia Corbo (a, b), Vincenzo Fioretti (a, b), Eugenio Stabile (a, b)
(a) CARDIOVASCULAR DEPARTMENT, AZIENDA OSPEDALIERA REGIONALE "SAN CARLO", POTENZA, ITALY; (b) CARDIOLOGY DIVISION, SAN PIO DA PIETRELCINA HOSPITAL, AZIENDA OSPEDALIERA REGIONALE "SAN CARLO", MARSICOVETERE, ITALY

Although mitral annular calcification (MAC) is a relatively common degenerative condition of the fibrous mitral annulus, tricuspid annular calcification (TAC), especially isolated and in absence of congenital heart disease (CHD) is rare. We present the case of a 72-years-old male, with a history of hypertension and kyphoscoliosis, referred for progressive dyspnea. Physical examination revealed a grade 2 systolic murmur on cardiac apex and leg swelling. Electrocardiography showed sinus rhythm with right bundle branch block. Echocardiography revealed a preserved left ventricular (LV) systolic function, right ventricular (RV) and atrial dilation with mild RV dysfunction and a homogeneous, hyperecoic, crescent shaped mass along the tricuspid annulus. Computed Tomography was performed, excluding pulmonary embolism and showing an intense, calcific lesion along the tricuspid annulus. Right heart catheterization revealed a mean pulmonary artery pressure of 25 mmHg, pulmonary vascular resistance of 3 WU, mean pulmonary arterial wedge pressure of 10 mmHg, suggesting pre-capillary pulmonary hypertension. Epicardial coronary arteries were free from significant stenosis. TAC usually occurs in patients with CHD with long-standing RV pressure or volume overload. Since the composition and function of the mitral and tricuspid annuli are similar, and the presence of MAC could be related to high LV pressures, similarly, the presence of chronic RV overload could accelerate calcium deposition on tricuspid annulus. Furthermore, as well as the presence and severity of MAC is associated with impaired LV systolic and diastolic function, in our case the presence of a giant TAC likely led to RV systolic dysfunction.

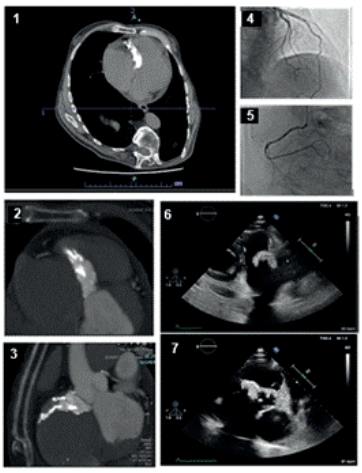

Figure 1, section 1, 2 and 3: cardiac CT showing tricuspid annular calcification. **Section 4:** coronary angiogram showing left anterior descending coronary artery. **Section 5:** coronary angiogram showing right coronary artery. **Section 6:** transthoracic echocardiography. Parasternal long axis (PLAX) view right ventricle inflow. **Section 7:** transthoracic echocardiography. Parasternal short axis (PSAX) view (level great vessels) focus on tricuspid valve.

A935: ANTIOXIDANT TREATMENT COUNTERACTS MYOCARDIAL FIBROSIS AND AMELIORATES CARDIAC FUNCTION IN A MURINE MODEL OF DUCHENNE DYSTROPHY CARDIOMIOPATHY

Irene Cattapan (a, b), Jennifer Fumanelli (a, b), Alice Pozza (a), Ruth Jepchirchir Arusei (a, b, c), Marco Brugnaro (c), Fabio Di Lisa (c), Jolanda Sabatino (a, b), Nina Kaludercic (b, c), Giovanni Di Salvo (a, b)
(a) CARDIOLOGIA PEDIATRICA, DIPARTIMENTO DI SALUTE DELLA DONNA E DEL BAMBINO, UNVERSITÀ DEGLI STUDI DI PADOVA, PADOVA; (b) ISTITUTO DI RICERCA PEDIATRICA CITTÀ DELLA SPERANZA, PADOVA; (c) DIPARTIMENTO DI SCIENZE BIOMEDICHE, UNIVERSITÀ DEGLI STUDI DI PADOVA, PADOVA

Introduction. Dystrophic cardiomyopathy culminates in heart failure and arrhythmias and is a major burden for Duchenne muscular dystrophy (DMD) patients. Mechanism-driven therapies designed to contrast the development of muscular and cardiac dysfunction are still missing. Antioxidant treatments counteract myocyte injury in mdx mice, a genetic model of DMD, supporting the possible role of enhanced reactive oxygen species (ROS) in the pathophysiology of muscular dystrophies. Previous evidence shows that monoamine oxidases (MAO) represent an important source of ROS. In previous studies from our lab, treatment with Safinamide, a MAO-B inhibitor, showed to improve cardiac function without any impact on cardiac remodelling or fibrosis development.

Objectives. We tested whether earlier and longer treatment with different MAO inhibitors could produce a better cardioprotective outcome.

Methods. We treated 27 mdx mice starting at 1 month of life with either saline, safinamide (MAO-B inhibitor) or pargyline (MAO-A and MAO-B inhibitor) for 60 days. Cardiac function was determined by echocardiography. We considered fractional shortening (FS), ejection fraction (EF), left ventricular end-diastolic diameter, end-diastolic and end-systolic volumes (EDV and ESV) and left ventricular strain. Cardiac structure and fibrosis amount were assessed through histology (H&E, Masson's Trichrome).

Results. Among the 27 mdx mice: 8 were treated with saline, 9 with Safinamide and 10 with Pargyline. MAO inhibition with either safinamide of pargyline significantly preserved cardiac function in terms of ejection fraction and fractional shortening compared to saline-treated mice. Saline group, in facts, has significantly lower FS and EF than safinamide ($p<0.001$ for FS, $p=0.001$ for EF) and pargyline ($p=0.009$ for FS and EF). This was accompanied by reduced chamber dilation as shown by the significantly lower left ventricular diameter at end-diastole ($p=0.022$) and significantly lower end-systolic and end-diastolic volumes in the MAO inhibitor-treated group compared to the saline group ($p=0.027$ for EDV and $p=0.008$ for ESV). Analysis of the myocardial strain indicated a trend towards improvement in the circumferential strain and a significant enhancement of the longitudinal strain in both, pargyline- and safinamide-treated mdx mice ($p=0.002$ for safinamide group and $p=0.0016$ for pargyline group). From the structural standpoint there was also a reduction in fibrosis levels afforded by pargyline treatment, but not by safinamide treatment.

Conclusions. These results suggest that ROS content modulation could be a therapeutic target for dystrophic cardiomyopathy. In particular, pharmacological treatment with pargyline, a MAO A and B inhibitor, seems to improve cardiac function as well as ventricular fibrosis in a genetic model of DMD.

A936: MYOCARDIAL WORK DERIVATO DALLO SPECKLE TRACKING E PREDIZIONE DELL'OUTCOME CLINICO NEI PAZIENTI CON SCOMPENSO CARDIACO AVANZATO

Giulia Elena Mandoli (a), Federico Landra (a), Benedetta Chiantini (a), Lorenzo Bonadiman (a), Maria Concetta Pastore (a), Luna Cavigli (a), Marta Focardi (a), Flavio D'Ascenzi (a), Sonia Bernazzali (b), Serafina Valente (a), Massimo Maccherini (b), Matteo Cameli (a)
(a) DEPARTMENT OF MEDICAL BIOTECHNOLOGIES, DIVISION OF CARDIOLOGY, UNIVERSITY OF SIENA; (b) DEPARTMENT OF CARDIAC SURGERY, UNIVERSITY OF SIENA

Background. La prevalenza dello scompenso cardiaco avanzato e il numero di ospedalizzazioni ad esso correlate sono in costante aumento. A causa dell'estrema variabilità del decorso clinico di questa patologia, rimane difficile trovare parametri che ci permettano di eseguire una corretta stratificazione prognostica volta ad una migliore gestione terapeutica.

Obiettivi. Valutare se i principali parametri ecocardiografici di Myocardial Work del ventricolo sinistro, calcolato mediante Speckle Tracking Echocardiography, fossero predittori di outcome clinico in un campione di pazienti con scompenso cardiaco avanzato (AdHF).

Metodi. L'analisi è stata eseguita su un campione di 138 pazienti con AdHF in valutazione per l'impiego di terapie avanzate presso il nostro centro. Per ciascun paziente sono stati valutati i parametri di Myocardial Work al momento della prima visita eseguita nel periodo compreso tra il 1° Gennaio 2018 ed il 31 Ottobre 2020, tra cui Global Work Index - GWI; Global Work Efficiency - GWE; Global Constructive Work - GCW; Global Wasted Work – GWW, utilizzando una misurazione non invasiva della pressione sanguigna. Tutti i pazienti sono stati seguiti per i seguenti outcomes: impianto di LVAD, trapianto cardiaco e decesso per tutte le cause (endpoint composito) e ospedalizzazione non programmata per riacutizzazione di scompenso cardiaco (endpoint secondario).

Risultati. La popolazione aveva un'età media di 58 anni [50-62] ed era composta per lo più da soggetti di sesso maschile (80%). L'eziologia dello AdHF è risultata prevalentemente non ischemica (66%). Dei 138 pazienti totali, 35 (25%) sono andati incontro all'endpoint composito (6 impianti di LVAD, 18 trapianti e 16 decessi) e 19 (14%) sono andati incontro all'endpoint secondario durante un follow up medio di 636 giorni. L'analisi di regressione di Cox univariata ha rilevato un'associazione statisticamente significativa tra l'endpoint secondario e i parametri GWI (HR per incrementi 50mmHg%: 0.905; CI: 0.778 – 0.951; $p=0.025$) e GCW (HR per incrementi 50mmHg%: 0.905; CI: 0.818 – 0.951; $p=0.022$). Nonostante il t-test avesse mostrato un'associazione statisticamente significativa tra l'endpoint composito e i parametri GWI, GCW e GWW, questa non è stata confermata dall'analisi di regressione di COX, probabilmente a causa della limitata numerosità del campione. Tuttavia, le curve ROC dei parametri GWI e GCW hanno mostrato un'accuratezza diagnostica moderata per l'endpoint composito, con un'area sotto la curva>0,7. Attraverso lo Youden Index abbiamo individuato dei valori di soglia ottimali (best cut-off) per i parametri GWI e GCW (rispettivamente di 369 e 613 mmHg%). Le analisi di sopravvivenza di Kaplan-Meier hanno mostrato che i pazienti con valori di GWI e GCW maggiori dei rispettivi best cut-off avevano una prognosi migliore in termini di sopravvivenza libera da endpoint combinato rispetto agli altri pazienti.

Conclusione. GWI e GCW sono risultati predittivi di ospedalizzazione non programmata per scompenso cardiaco nella fase avanzata di malattia, e sembrano in grado di fornire un certo vantaggio rispetto alla sola valutazione del GLS. Se i dati si confermassero su una popolazione più ampia e multicentrica, tali parametri si potrebbero prospettare come utili alleati nella prevenzione dell'ospedalizzazione dei pazienti con AdHF ad esempio programmando cicli infusionali di terapia diuretica o di levosimendan ambulatoriali.

A937: MANAGEMENT OF A WORSENING HEART FAILURE CASE WITH CARDIAC CONTRACTILITY MODULATION THERAPY

Paolo Severino (a), Andrea D'Amato (a), Silvia Prosperi (a), Marco Valerio Mariani (a), Claudia Cestiè (a), Aurora Labbro Francia (a), Vincenzo Myftari (a), Elisa Tomarelli (a), Sara Cimino (a), Lucia Ilaria Birtolo (a), Giovanna Manzi (a), Agostino Piro (a), Viviana Maestrini (a), Roberto Badagliacca (a), Massimo Mancone (a), Carlo Lavalle (a), Carmine Dario Vizza (a)
(a) DEPARTMENT OF CLINICAL, INTERNAL, ANESTHESIOLOGY AND CARDIOVASCULAR SCIENCES, SAPIENZA UNIVERSITY OF ROME, VIALE DEL POLICLINICO 155, 00161, ROME, ITALY

A 89-year-old man was admitted at the emergency room (ER) due to subacute coronary syndrome with ST-segment elevation in the antero-lateral leads. In his medical history he had hypertension and dyslipidaemia, as cardiovascular risk factors. At the admission in ER the patient was complaining of dyspnoea, started ten days back, and peripheral oedema, appeared a couple of days before. These reported symptoms were preceded by an episode of acute chest pain a couple of weeks beforehand. At the admission, systolic blood pressure was 105 mmHg and diastolic blood pressure was 70 mmHg, oxygen saturation 99% at room air. At the same time a blood sample was taken, showing high levels, but stable, of high-sensitivity T-Troponin. A 12 leads ECG was performed showing sinus rhythm at heart rate of 75 beats per minute with ST segment elevation in antero-lateral leads with concomitant necrosis Q waves. Transthoracic echocardiography showed a dilated left ventricle with depressed global systolic function with apical and para-apical akinesis with a LVEF of 38%. Given his asymptomatic state and the ECG presentation indicative of a left ventricle remodeling after an ST-segment elevation myocardial infarction (STEMI), a non-urgent coronary angiography was indicated. Medical treatment for myocardial infarction and HF were initiated and the patient was transferred to the cardiology department. Subsequently, the coronary angiography was performed, and it highlighted a chronic total occlusion of the proximal left anterior descending (LAD) artery. The patient did not undergo revascularization because it was asymptomatic, and the myocardial tissue vascularized by the LAD was not more vital. At the dischargement the following therapy was prescribed: Cardioaspirin 100 mg, Clopidogrel 75 mg, Bisoprolol 2.5 mg, Furosemide 25 mg, Potassium Canrenoate 50 mg, Dapagliflozin 10 mg, Rosuvastatin 20 mg, Ezetimibe 10 mg, Pantoprazol 40 mg. After the discharge the patient was followed up at the HF outpatient service. Medical therapy was progressively up-titrated during the following months, Sacubitril/Valsartan was added at the dosage of 24/26 mg b.i.d. and bisoprolol was up-titrated until the dosage of 5 mg per day. Despite the optimized medical therapy, six months after hospital discharge, patient was followed up and he presented with NYHA class III, increasing values of NT pro BNP (1235 ng/L) and KCCQ-12 low score, despite optimized medical therapy. For this reason, CCM implantation was performed. At six months follow up after CCM implantation, an improvement in NYHA class, from III to II, a stabilization in NT pro BNP values and improvement in KCCQ-12 score have been observed. Mo-

reover, a further up-titration of Sacubitril/Valsartan to 49/51 mg b.i.d was tolerated by the patient. Hyperkalemia, in absence of glomerular filtration rate worsening, occurs as single adverse event and it was attributed to the use of renin angiotensin aldosterone system inhibitors (RAASi). Hyperkaliemia was successfully managed with the addition of sodium zirconium cyclosilicate 5 g per day.

A938: REAL WORLD MEDICAL THERAPY FOR HEART FAILURE WITH REDUCED AND MILDLY REDUCED EJECTION FRACTION: REMEDI-HF STUDY

Francesco Fioretti (a), Alessia Calzoni (b),
Antonio Maria Sammartino (a), Angelica Praderio (a),
Maria Grazia De Angelis (a), Savina Nodari (a)
(a) SPEDALI CIVILI HOSPITAL AND UNIVERSITY OF BRESCIA, BRESCIA, ITALY;
(b) UNIVERSITY OF BRESCIA, BRESCIA, ITALY

Background. The international guidelines strongly recommend patients with heart failure with reduced ejection fraction (HFrEF) and mildly reduced ejection fraction (HFmrEF) be treated with multiple medications proven to improve clinical outcomes, as tolerated. However it is currently not well known the extent to which these recommendations are implemented in clinical practice.
Aim of the study: To evaluate the use of HFrEF "disease-modifying" medications in a real-life outpatient setting and to characterize patterns and factors associated with use and dose of these medications in current clinical practice.
Methods. We performed a prospective monocentric observational study, in which chronic stable HF outpatients (pts) were enrolled consecutively from January 2022 to September 2022. Then, demographical, clinical, laboratory, instrumental data and HFrEF medical therapy were collected.
Results. Overall, 117 pts were enrolled in the study. Mean age of participants was 74 + 12 years, 32% were female; 70 pts (60%) had HFrEF phenotype, 25 (21%) had HFmrEF one and 22 (19%) had HFimpEF one. An ischaemic etiology was found in about 43% of cases. In their clinical history, 43 pts (36.7%) had diabetes mellitus type II, 47 pts (40.2%) had chronic kidney disease, 13 pts (11.1%) had chronic obstructive pulmonary disease, while 58 pts (49.5%) had atrial fibrillation. In the last year, 17 pts (14.5%) had an hospitalization for worsening HF, whereas 18 pts (15.4%) needed for intravenous diuretic therapy for congestion relief. At the enrollment, most pts (101, about 86.3%) had NYHA functional class II, and only 16 pts (about 13.7%) had NYHA functional class III. Mean NT-proBNP value was 3068 + 290 ng/L. The data about HFrEF and HFmrEF medical therapy are shown in Figure 1.
Conclusions. Our results confirm that significant gaps in use and dose of HFrEF and HFmrEF therapy in real world remain. Strategies to improve guideline-recommended medications use are urgently needed, especially encouraging tailored approaches to optimize HF outpatient therapy.

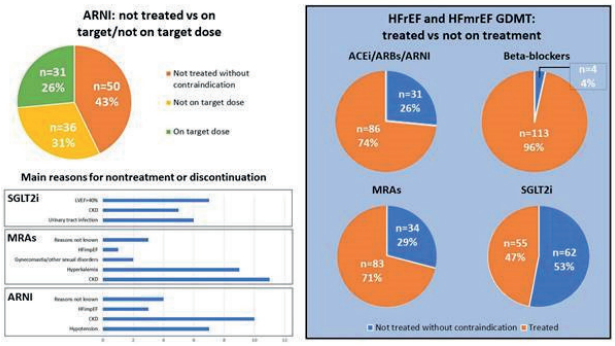

A939: A RARE CASE OF BIVENTRICULAR DISFUNCTION IN SYSTEMIC SCLEROSIS

Lorena Iezzi (a), Andrea Palermi (a), Carmelita Cieri (a),
Sabrina Testa (a)
(a) DEPARTMENT OF NEUROSCIENCE, IMAGING AND CLINICAL SCIENCES,
"G. D'ANNUNZIO" UNIVERSITY OF CHIETI-PESCARA, 66100 CHIETI, ITALY

Systemic sclerosis (SSc) is a rare immune-mediated rheumatic disease characterized by diffuse vasculopathy leading to multiorgan fibrosis. We report the case of a 61-year-old man who was diagnosed with SSc one year before. At the time of diagnosis, the patient exhibited exertional dyspnea (NYHA II-III) due to mild signs of interstitial impairment at chest HRCT and stage 3b of chronic kidney disease (creatinine clearance 40 ml/min as per CG). Echo was performed, showing severe impairment of the right ventricular systolic function in the absence of LV dysfunction. Right heart catheterization (RHC) was unremarkable (mPAP 19 mmHg, PCWP 16 mmHg). Several months later, despite immunosuppressive treatment, the patient experienced clinical worsening, in the absence of remarkable worsening of Echo and RHC parameters. Therefore, he was started with mycophenolate mofetil and tocilizumab as second-line treatment. After 60 days of second line therapy, the patient presented to the ER with severe resting dyspnea (NYHA IV), in a clinical-laboratory data of acute heart failure due to new onset left ventricular dysfunction (EF 36%), and severe impairment of renal function (AKI on CKD; creatinine clearance 23 ml/min as per CG). ECG showed chaotic ectopic atrial rhythm with prolonged atrio-ventricular conduction and frequent polymorphic premature ventricular contractions. The patient was admitted to Cardiology department with the diagnosis of AHF due to biventricular dysfunction and started with optimized medical therapy. This report presents a rare case of primary myocardial involvement in SSc, where right ventricular failure was the initial cardiac manifestation, rapidly progressing to severe biventricular dysfunction. As a potential cause of biventricular systolic dysfunction, we ruled out autoimmune or infectious myocarditis based on consistently negative results for inflammation and viral markers. Additionally, drug-induced cardiotoxicity was ruled-out due to lack of evidence in the literature (despite widespread use of tocilizumab during the COVID pandemic). We proposed second level imaging with cardiac magnetic resonance that was rejected by patient because of claustrophobia. Considering the risk-benefit ratio, coronary angiography was excluded because of severe renal impairment and poor clinical conditions. We assume fibrosis to play a significant role in this case of heart failure, as supported by electrocardiographic features of several conduction disturbances. At the moment of this report, no treatments demonstrated to significantly improve the natural history of primary cardiac involvement in patients with SSc, thus remaining a prognostic factor affecting both survival and quality of life.

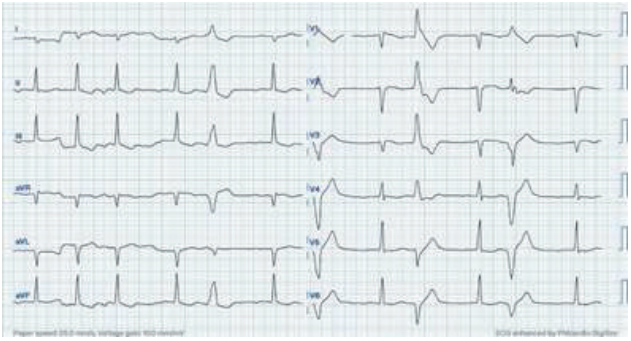

A940: A CASE OF PROLONGED IMPELLA 5.5 SUPPORT AS A BRIDGE TO DECISION IN CARDIOGENIC SHOCK AFTER CORONARY ARTERY BYPASS SURGERY

Nastasia Mancini (a), Maria Vittoria Matassini (b), Matilda Shkoza (b),
Luca Angelini (b), Giulia Pongetti (b), Matteo Francioni (b),
Ilaria Battistoni (b), Alessandro Bontempo (c), Roberto Manfredi (c),
Marco Di Eusanio (d), Christopher Munch (e), Filippo Capestro (d),
Gian Piero Perna (b), Marco Marini (b)
(a) DIPARTIMENTO DI MEDICINA CLINICA E SPERIMENTALE, UOC DI CARDIOLOGIA CON UTIC, UNIVERSITÀ DEGLI STUDI DI MESSINA, MESSINA, ITALIA; (b) DIPARTIMENTO CARDIOVASCOLARE, DIVISIONE DI CARDIOLOGIA, AZIENDA OSPEDALIERO UNIVERSITARIA OSPEDALI RIUNITI DI ANCONA, ANCONA, ITALIA; (c) CLINICA DI CARDIOLOGIA E ARITMOLOGIA, AZIENDA OSPEDALIERO UNIVERSITARIA OSPEDALI RIUNITI DI ANCONA, UNIVERSITÀ POLITECNICA DELLE MARCHE, ANCONA, ITALIA; (d) DIPARTIMENTO CARDIOVASCOLARE, SOD CARDIOCHIRURGIA, AZIENDA OSPEDALIERO UNIVERSITARIA, OSPEDALI RIUNITI DI ANCONA, ANCONA, ITALIA; (e) DIPARTIMENTO CARDIOVASCOLARE, SOD ANESTESIA E RIANIMAZIONE CARDIOCHIRURGICA, AZIENDA OSPEDALIERO UNIVERSITARIA OSPEDALI RIUNITI DI ANCONA, ANCONA, ITALIA

A 60 years old man with an history of smoking, dyslipidemia, carbohydrate intolerance and a previous unstable angina treated with percutaneous revascularization on left anterior descending artery, was hospitalized in a spoke center for myocardial infarction with non-ST segment elevation. The coronary angiography showed multivessel disease with indication for surgical myocardial revascularization. Therefore the patient was transferred to our hub center. While waiting for surgery the patient experimented chest pain with diaphoresis, hemodynamic instability and on electrocardiogram evidence of acute lateral myocardial infarction with the need to urgent coronary artery bypass grafting supported by intra-aortic balloon pump (IABP) and vasopressor with adrenaline 0.02 gamma/kg/min. When transferred to our Coronary Unit, evidence on transthoracic echocardiogram of biventricular severe dysfunction (FAC 34%; EF 35%), severe mitral regurgitation and severe pulmonary congestion. We started noninvasive ventilation with CPAP, diuretics iv and inotropes in absence of significant clinical improvement. We decided to study mitral valve with transesophageal echocardiogram for the evaluation of percutaneous treatment of mitral valve with evidence of unfavorable anatomy. The right heart catheterization showed post capillary pulmonary hypertension. For clinical wor-

sening, fever and pulmonary edema despite medical therapy and IABP, we decided to upgrade the mechanical circulatory support from IABP to Impella CP through percutaneous femoral arterial access. In the following two weeks, the patient significantly improved. However, at the attempt to wean Impella, he once more got worse. Several aspects in that moment contraindicated the referral for urgent transplantation (INTERMACS profile, recent and still active pulmonary infection, fifth degree sacral bedsore) therefore, we upgraded the support from Impella CP to Impella 5.5 via right axillary artery to allow recovery and mobility. After 4 weeks of Impella 5.5 support, patient was compensated, was able to walk and all infective aspects were solved. The case was discussed in the Heart Team with the decision to implant a left ventricular assist device as a bridge to heart transplantation.

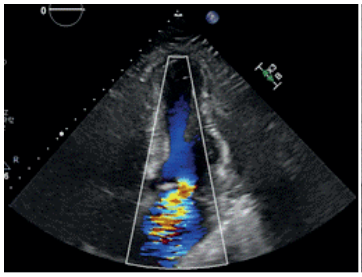

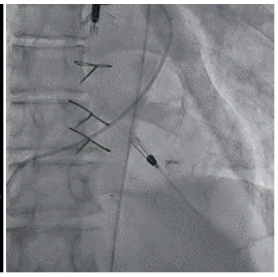



A941: MULTIDISCIPLIONARY APPROACH TO A DIFFICULT CASE OF ACUTE HEART FAILURE DUE TO POSSIBILE ISOLATED CARDIAC SARCOIDOSIS

Massimo Mapelli (a, b), Giulia Grilli (a), Jeness Campodonico (a, b), Carlo Vignati (a, b), Andrea Baggiano (a, b), Benedetta Majocchi (a), Lorenzo Bianchini (a), Monica Ianniruberto (a, b), Francesco Doni (a, b), Fabio Fazzari (a), Gianluca Pontone (a, b), Piergiuseppe Agostoni (a, b)
(a) CENTRO CARDIOLOGICO MONZINO, IRCCS, MILANO; (b) UNIVERSITÀ DEGLI STUDI DI MILANO, MILANO

Background. Cardiac sarcoidosis (CS) is a rare, infiltrative cardiomyopathy that results from granulomatous inflammation affecting the heart with high morbidity and mortality. It is usually associated with a systemic (i.e. pulmonary) involvement, but a lone cardiac involvement has been described. Even with extensive multidisciplinary evaluation making a firm diagnosis is difficult, especially in case of isolated CS where the endomyocardial biopsy (EBM) diagnostic yield is low (20-30%).

Case description. A 71-year-old patient, heavy smoker with no previously known diseases, was admitted with a 3-month history of worsening dyspnea. On admission he showed typical features of heart failure with reduced ejection fraction (HFrEF). A coronary angiography excluded relevant coronary artery disease, while echocardiography (TTE), cardiac magnetic resonance (CMR), and positron emission tomography (FDG-PET) showed a pattern consistent with a non-ischemic dilated cardiomyopathy with severe reduction in systolic function, and signs of active inflammation (highly suspected CS). Two electroanatomic mapping driven EBM were made but no clear histological signs of CS (i.e., granulomatous inflammation) were detected. The patient was treated with corticosteroids and HFrEF optimal medical therapy (sacubitril/valsartan, mineralocorticoid receptor antagonists, beta-blockers, dapagliflozin) and a temporary wearable defibrillator (LifeVest) was applied. At 2-month follow-up, despite a moderate improvement in the systolic function and HF symptoms, after a multidisciplinary discussion, considering the extensive left ventricle scar (late gadolinium enhancement), the inflammatory involvement, and the presence of multiple non-sustained ventricular tachycardia, a permanent cardioverter-defibrillator (ICD) was implanted.

Conclusions. This case highlights how, even with (repeated) extensive multidisciplinary evaluation (TTE, CRM, FGD-PET, EBM), a definitive diagnosis of isolated CS often remains presumptive. The presence of an experienced cardiomyopathy team (HF specialists, cardiac imager, electrophysiologists, internal medicine doctor) can help in the diagnostic-therapeutic management of these patients with inflammatory heart disease.

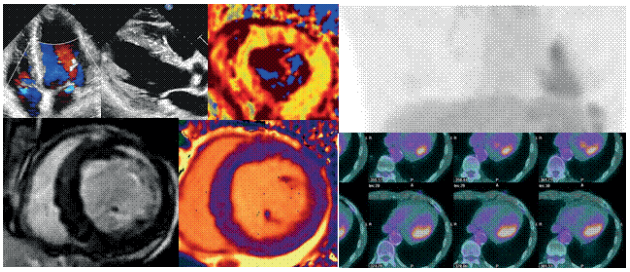

A942: EARLY RELEVANT ALERTS FROM REMOTE MONITORING IN HEART FAILURE PATIENTS WITH A CARDIAC IMPLANTABLE ELECTRONIC DEVICE: WHAT IMPLICATIONS FOR LONG TERM OUTCOME?

Davide Antonio Mei (a), Jacopo Francesco Imberti (a), Francesco Sbarra (a), Kevin Serafini (a), Marta Mantovani (a), Benedetta Cherubini (a), Giulio Leo (a), Chiara Birtolo (a), Luigi Gerra (a), Paolo Cataldo (a), Niccolò Bonini (a), Marco Vitolo (a), Giuseppe Boriani (a)
(a) UNIVERSITÀ DI MODENA E REGGIO EMILIA

Background and Aim. Remote monitoring alerts have been associated with worse clinical outcomes among heart failure (HF) patients with cardiac implantable electronic devices (CIEDs). However, the role of relevant alerts occurring early (early-RA), as well as their possible predictors remain unclear.

Methods. We studied patients with a history of HF implanted with a CRT-D or an ICD, derived from a large Italian single-center retrospective observational study. Early-RA were defined according to the occurrence of a device shock or anti-tachycardia pacing (ATP) or of an HF-score alert in the first 180 days of follow up. The primary clinical outcome of the study was a composite of death, major adverse cardiovascular events (MACEs) and heart failure hospitalization. Logistic and Cox regression analyses were used to determine associations.

Results. A total of 272 patients were included in the analysis (median age 67.4 years, IQR 58.6-74.6, 19.9% female). Twenty-four patients had an early-RA (8.8% of the overall study group) and were found to be older, more severely symptomatic for HF, with a higher prevalence of atrial fibrillation (AF) and chronic kidney disease (CKD). At univariate logistic regression analysis, we found the following factors as significantly associated with early-RA: age (odds ratio [OR] 1.01, 95% confidence interval [CI] 1.00-1.02), AF (OR 1.09, 95% CI 1.02-1.17), CKD stage IIIB or higher (OR 1.24, 95% CI 1.07-1.45), but these results were not confirmed at the multivariable logistic regression. After a median follow-up of 959 days, patients reporting an early-RA had a higher incidence of primary outcome events (composite of death, MACEs, and heart failure hospitalization). At adjusted Cox regression analysis, we found that early-RA were significantly associated with a higher risk of the primary endpoint (hazard ratio [HR] 3.89, 95%CI 1.62-9.32) (Figure).

Conclusions. The occurrence of alerts detected by remote monitoring of implanted devices in a relatively early phase (within 180 days from start of remote monitoring) among HF patients implanted with CIEDs, is associated with a higher risk of adverse cardiovascular events. This finding is important since optimization of medical and electrical treatment should be guaranteed to this high-risk group of CIED patients affected by HF.

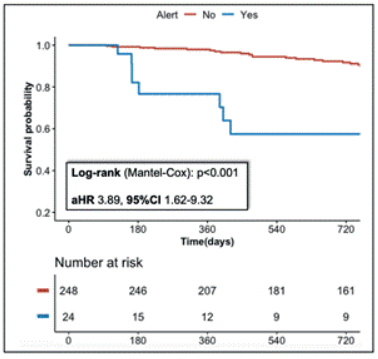

A943: THE IMPORTANCE OF DIFFERENTIAL DIAGNOSIS IN MIXED PRE- AND POST-CAPILLARY PULMONARY HYPERTENSION:A CASE REPORT

Giulia Bassetto (a), Jacopo Giulio Rizzi (a), Damiano Regazzoli (c), Federico De Marco (b), Davide Stolfo (a), Gianfranco Sinagra (a)
(a) CARDIOTHORACOVASCULAR DEPARTMENT, AZIENDA SANITARIA UNIVERSITARIA GIULIANO ISONTINA AND UNIVERSITY OF TRIESTE, TRIESTE, ITALY; (b) CENTRO CARDIOLOGICO MONZINO IRCCS, MILAN, ITALY; (c) CARDIO CENTER, IRCCS HUMANITAS RESEARCH HOSPITAL, ROZZANO-MILAN, ITALY

A 49-years-old man was admitted to ICU for decompensated heart failure (HF). On anamnesis he had been treated in 1989 with chemotherapy and radiotherapy for Hodgkin Lymphoma and was affected by symmetric polyarthritis, post-radiation pulmonary disease and type 1 diabetes. In 2015 he implanted a mechanic aortic valve plus complex mitral annuloplasty with mitral ring, due to worsening heart failure secondary to severe aortic stenosis and severe mitral regurgitation; he also implanted epicardial pacemaker for post-operative complete heart block. During follow up the patient started developing increasing trans-mitral gradients alongside worsening right ventricular failure and pulmonary hypertension (PH) with preserved left ventricular (LV) function. When admitted to the ICU, signs and symptoms of severe congestive HF and low-output syndrome were evident, requiring high diuretic doses and inotropes. Echocardiography showed normal LV function, dilatation and dysfunction of the right ventricle (RV), moderate-to-severe mitral steno-insufficiency (g 19/10 mmHg), normal mechanic aortic valve, severe tricuspid regurgitation (TR), and severe PH (67 mmHg) with evidence of septal D-shape. Right heart catheterization described mixed PH (PAP 65/27/43, PWP 19 mmHg, PVR 3.9 WU), intermediate atrial pressure (RAP 8 mmHg) and mild reduction of cardiac index (indirect Fick 2.72 l/min/m2). Diagnostic work-up was performed to explore the differential diagnosis in a patient with risk factors for all subtypes of PH: pulmonary function tests showed a moderate-to-severe restrictive pattern with severe DLCO impairment (32%), ventilation-perfusion lung scan excluded chronic pulmonary thromboembolism, autoimmune disease was defined as in remission. After careful re-evaluation of patient's history, 2015 surgical report and serial echocardiograms performed during follow-up, a primary role of mitral steno-insufficiency was hypothesized in his worsening condition with convincing data for a severe mitral patient-prothesis mismatch. Following collegial discussion in Heart Team, the patient was accepted for mitral valve-in-ring. In consideration of the patient's comorbidities and the elevated surgical risk, a percutaneous approach was indicated through transeptal BATMAN technique (Balloon Assisted Translocation of Mitral Anterior leaflet to prevent LVOT obstruction) as the estimated risk of LVOT obstruction by the calcific anterior leaflet with conventional valve-in-ring procedure was deemed as prohibitive. He was referred to the Humanitas Research Hospital, Rozzano, where he successfully underwent the procedure after prophylactic implantation of venoarterial-ECMO without complications, allowing us to discharge him a week later. At one-month follow up visit, the patient reported an improvement in symptoms (NYHA 2), quality of life and 6MWT (410 m, +98 m); echocardiogram showed a dilated RV with mild systolic dysfunction, physiologic trans-prosthetic mitral and aortic gradients, without evidence of regurgitation, no LVOT obstruction, severe T with moderate PH (PAPs 53 mmHg, -14 mmHg). In conclusion, in cases of mixed PH, the accurate evaluation of the clinical history and a complete diagnostic work-up are the cornerstones of an appropriate management. New generation percutaneous procedures for the correction of patient-prosthesis mismatch allow to improve functional status and prognosis of high surgical risk cases; in case of irreversible PH a careful follow-up would be required to define potential additional contributors to residual pulmonary vasculopathy.

A944: MODULATORY ACTIVITY OF SGLT2-I ON SECONDARY TRICUSPID REGURGITATION

Giulia Nemola (a), Marco Stracqualursi (a), Silvia Moscardelli (a), Gloria Santangelo (c), Federica Valli (c), Andrea Faggiano (a), Filippo Toriello (c), Stefano Buratti (b), Maurizio Losito (b), Stefano Carugo (a, c), Marco Guazzi (a, b), Francesca Bursi (a, b)
(a) UNIVERSITY OF MILAN; (b) DIVISION OF CARDIOLOGY, SAN PAOLO HOSPITAL, DEPARTMENT OF HEALTH SCIENCES, UNIVERSITY OF MILAN; (c) FONDAZIONE IRCCS CA' GRANDA OSPEDALE MAGGIORE POLICLINICO, CARDIAC UNIT, UNIVERSITY OF MILAN

Background. Tricuspid regurgitation velocity (TRV) is a measure indicative of pulmonary hypertension (PH) and a marker of poor prognosis in patients with heart failure with reduced ejection fraction (HFrEF). Novel medical therapies have been introduced in the past years with significant improvement of both survival and rehospitalization for HF. The effect of combined treatment of SV and SGLT2i on TRV has not been addressed.

Aims. We aimed to evaluate the effect of SV alone vs. SV combined with SGLT2i on TRV in a real-life population of outpatients with HFrEF.

Methods. Patients were treated with either SV alone or with SGLT2i in addition to SV. Baseline TVR was measured in all patients before starting treatment and at follow up. We excluded patients who discontinued SV within 6 months of introduction and those who did not complete at least 6 months of follow-up with either drug. None stopped SGLT2i.

Results (Figure 1): We enrolled 135 HFrEF patients (mean age 69 years±12, left ventricular ejection fraction (LVEF) 29±6%) in optimal medical therapy and all receiving SV (100% of patients) for at least 6 months. In 47 (35%) patients SGLT2i were also introduced. At baseline, TRV was similar in the two groups (median 265 cm/sec [IQR 234-306] in SV group, 273 cm/sec [IQR 237-305] in SV+SGLT2i group, p=0.863). TRV decreased in both groups after therapy initiation. At follow up, compared to patients receiving only SV, those treated with both drugs showed a greater reduction of TRV (median change -23 [IQR -52;30] in SV group vs -56 [IQR -101; -34]in SV+SGLT2i, p=0.016). Interestingly, patients receiving both SV and SGLT2i at follow up, required less loop diuretic prescriptions compared to those treated only with SV (32% versus 11%, respectively, were not in diuretics therapy; p=0.006).

Conclusions. Among patients with HFrEF, the combined treatment with SGLT2i and SV was associated with a significative reduction of TRV. The reduction of TRV may be a consequence of SGLT2i diuretic effect as shown by the lower need of diuretic treatment in patients receiving both drugs. We advance the hypothesis that the known reduced risk of mortality and HF hospitalization in patients receiving SGLT2i could be related, at least in part, to a reduced risk of PH.

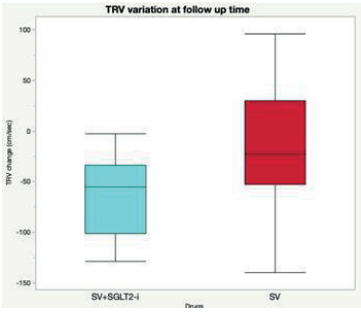

Figure 1 Variation of TRV (cm/sec) at follow up among SV + SGLT2i group versus SV alone group.

A945: THE SERIAL ACCUMULATOR

Davide Nilo (a), Annamaria Carolina Peluso (a), Fabio Luciano (a)
(a) INTERNAL MEDICINE, AOU VANVITELLI, NAPLES, ITALY

A 74 year old lady came to our with non-productive cough, sloping edema and worsening dyspnoea for about 10 days, she had already performed a chest CT scan at home which showed slight bilateral baseline fluid. She decided to go to the ED where they found a mild normocytic normochromic anemia (Hb 11.4 g/dL), Troponin I 148 ng/L, BNP 2554 pg/mL, and LDH 330 U/L. The troponin curve performed with dosage at three and ten hours was not significant due to ischemic in progress. At the anamnestic interview, evidence of arterial hypertension, chronic ischemic heart disease, recent PMK implant (approximately 20 days earlier for the onset of symptoms for BAV II° Mobitz 2), previous HCV infection subjected to eradicating antiviral therapy. On admission, the patient was dyspneic but hemodynamically stable. In the light of the suggestive picture of congestive heart failure, intravenous diuretic therapy was set up with furosemide and potassium canrenoate with consequent benefit on respiratory dynamics. On the fifth day of hospitalization, in order to monitor cardiac function, it was decided to perform a new echocardiogram, which showed severe concentric hypertrophy of the left ventricle with preserved volume, moderate mitral regurgitation and sclerocalcified aortic valve, concluding for probable storage disease. Approximately three days after the last echocardiographic check-up, the patient reported acute precordial pain, the ECG was not suggestive of ACS but there was a rapid increase in the Troponin I value (34624 pg/mL) and consequently the patient went to UTIC to perform coronary angiography, which was negative for coronary lesions. In consideration of the suspicion of cardiac infiltrative pathology, it was decided to perform:

- serum immunofixation for k and lambda chains, which later proved positive for the monoclonal lambda component;
- bone scan with HMDP, tested negative (Score 0 by Perugini);
- endomyocardial biopsy, which confirmed the presence of a picture compatible with storage disease, specifically attributable to "cardiac amyloidosis with myocytolysis";
- immuno-electromicroscopy, with evidence of an ultrastructural picture compatible with AL Amyloidosis (lambda light chains).

Once the acute symptoms were controlled and the patient stabilized, the decision was made to discharge the patient with an indication to continue the therapeutic process at a specialist reference center.

Discussion. Cardiac amyloidosis is a severe and progressive infiltrative disease caused by hereditary or acquired physiological abnormalities that lead to the accumulation of amyloid fibrils in the heart. More than 98% of cardiac amyloidosis is caused by just two types of proteins: immunoglobulin light chains and transthyretin. Typically, cardiac amyloidosis manifests itself with a large number of extracardiac signs and symptoms, defined as "red flags", which can guide the diagnostic suspicion. However, even in the absence of "red flags", a storage disease must always be suspected in patients with multiple ischemic events but with unaffected coronary, and in acute decompensated patients.

A946: VALUTAZIONE FUNZIONALE AL TEST CARDIOPOLMONARE DELL'OTTIMIZZAZIONE ECOCARDIOGRAFICA DELLA TERAPIA DI RESINCRONIZZAZIONE CARDIACA IN PAZIENTI AFFETTI DA INSUFFICIENZA CARDIACA

Andrea Pandolfi (a, b), Giulio Mallardi (a, b), Filippo Toriello (a), Massimo Saviano (a), Francesco Giangiacomi (a, b), Federica Valli (a), Alberto Pollina (a), Marco Vicenzi (a, b), Stefano Carugo (a, b)
(a) DIPARTIMENTO AREA CARDIO-TORACO-VASCOLARE, FONDAZIONE IRCCS CA' GRANDA OSPEDALE MAGGIORE POLICLINICO, ITALIA; (b) DIPARTIMENTO DI SCIENZE CLINICHE E DI COMUNITÀ, UNIVERSITÀ DI MILANO, ITALIA

Introduzione. La terapia di risincronizzazione cardiaca (CRT) fa parte della terapia dello scompenso cardiaco a frazione di eiezione ridotta (HFrEF) con evidenza elettrocardiografica di ritardo di conduzione intraventricolare. Diversi trial hanno mostrato l'efficacia della stimolazione biventricolare nella riduzione di ospedalizzazioni per scompenso cardiaco e mortalità, nonché un miglioramento della sintomatologia di questi pazienti. Nonostante questo, circa il 30% dei soggetti sottoposti a questo trattamento non mostra un miglioramento clinico-strumentale significativo e vengono definiti non responders. Pur essendo stati identificati diversi parametri che correlano con una maggiore probabilità di risposta alla CRT, importanti trial hanno fallito nel trovare un vantaggio nell'implemento di tali criteri per la selezione dei pazienti.
Obiettivo. Questo studio pilota si pone l'obiettivo di testare la possibilità di migliorare la percentuale di risposta alla CRT, valutata tramite parametri oggettivi di funzionalità cardiorespiratoria, ottimizzando il ritardo degli intervalli di stimolazione atrioventricolari (AV) e interventricolari (VV) in base a criteri ecocardiografici, sia per l'intervallo di frequenza di base che di trascinamento a cui viene programmato il dispositivo.
Metodi. Sono stati inclusi pazienti con insufficienza cardiaca sintomatica con FEVS ≤45%, mancata risposta alla CRT e con percentuale di pacing biventricolare>97%. L'ottimizzazione è stata ottenuta modificando gli intervalli di stimolazione AV e VV in modo da massimizzare la portata cardiaca e la funzione diastolica dei pazienti. Tale ottimizzazione è stata eseguita per frequenze cardiache incrementali. Al test da sforzo cardiopolmonare sono stati valutati il consumo di ossigeno massimale (VO2 max), la pendenza della curva dell'equivalente respiratorio per la CO2 (VE/VCO2 slope) e il recupero della frequenza cardiaca a 1 minuto (HRR 1 min). Tali parametri sono stati valutati in basale e dopo tre mesi dall'ottimizzazione.
Risultati. Tutti e 6 i pazienti arruolati sono stati in grado di eseguire un test da sforzo massimale (quoziente respiratorio RQ ≥1.05). Il VO2 di picco è migliorato in modo rilevante (con un incremento>6%) in 2 pazienti, è rimasto invariato in 3 pazienti (variazione tra -6% e 6%) ed è peggiorato in un singolo caso (diminuzione>6%). I valori di VE/VCO2 slope in 2 casi sono migliorati, in 3 sono peggiorati e in un caso sono rimasti stabili. L'HRR ad 1 minuto è migliorata in 5 pazienti e peggiorata nel restante caso. Per questi due parametri non sono disponibili in letteratura percentuali tali da definire un cambiamento significativo. Infine, uno dei due soggetti che in basale presentava un pattern di ventilazione oscillatorio, ha normalizzato tale pattern.
Conclusioni. Da questo studio pilota emerge come l'ottimizzazione ecocardiografica degli intervalli AV e VV effettuata a diversi range di FC sia in grado di migliorare notevolmente la capacità funzionale di alcuni pazienti. Tuttavia, la mancata risposta da parte di alcuni soggetti suggeriscono che di tale intervento possa beneficiarne solamente una parte dei soggetti non responders. Ulteriori studi sono necessari per la ricerca di tali caratteristiche predittive di risposta e per confermare questi risultati.

A947: A NOVEL STRATEGY IN THE SEQUENCING OF HFREF THERAPY: AN UPFRONT AND PROMPT APPROACH

Paolo Severino (a), Silvia Prosperi (a), Andrea D´amato (a), Marco Valerio Mariani (a), Aurora Labbro Francia (a), Claudia Cestiè (a), Vincenzo Myftari (a), Rosanna Germanò (a), Elisa Tomarelli (a), Lucia Ilaria Birtolo (a), Giovanna Manzi (a), Carlo Lavalle (a), Viviana Maestrini (a), Roberto Badagliacca (a), Francesco Fedele (a), Carmine Dario Vizza (a)
(a) DEPARTMENT OF CLINICAL, INTERNAL, ANESTHESIOLOGY AND CARDIOVASCULAR SCIENCES, SAPIENZA UNIVERSITY OF ROME, VIALE DEL POLICLINICO, 155, 00161 ROME, ITALY

Introduction. Heart Failure (HF) is a complex clinical syndrome with high mortality rate (20% at 1 year, 45% at 5 years) and high hospitalization rate, especially within the first few months from hospital discharge, being the first cause of hospitalization for individuals over 65 years of age. The latest European Society of Cardiology guidelines for HF recommend the use of four different classes of drugs, namely Angiotensin Receptor/Neprilysin Inhibitor (ARNI), Beta Blockers (BB), Mineralocorticoid Receptor Antagonists (MRAs) and Sodium Glucose coTransporter-2 inhibitors (SGLT2i). However, guidelines do not clarify the precise timing for optimization of Guideline-Directed Medical Therapy (GDMT), which remains a difficult goal to be achieved for several patients. Currently, the most conventional approach is based on the stepwise introduction of the four drugs, resulting in a delay in full treatment optimization, despite several evidences proving how these drugs work within a few weeks (ranging from 2 to 8 weeks) from treatment initiation.
Aims. To compare the conventional stepwise strategy with our early sequencing of GDMT, based on the rapid introduction of BB, SGLT2i, ARNI, and MRA. The primary endpoint was a composite of cardiovascular (CV) death and HF rehospitalization. Secondary endpoints were the single events constituting the primary endpoint.
Methods. This prospective, observational study included 302 consecutive patients with a HFrEF diagnosis from the Cardiovascular Disease Unit. 278 patients underwent 6-month follow-up. They were divided based on treatment strategy, and were matched through propensity score matching. 139 patients, treated with the conventional stepwise GDMT sequencing, constituted group 1 (G1). 139 patients, treated with our novel, rapid GDMT sequencing, constituted group 2 (G2). Comparison between the two groups was performed at 6-month follow-up.
Results. The two groups were comparable in terms of baseline characteristics. No significant differences have been observed for the primary composite outcome (p=0.135) and for CV mortality (p=0.642) between the two groups. HF rehospitalization risk was significantly lower in G2 group compared to G1 group (p<0.001). This is shown in Figure 1 and Table 1.
Conclusions. The conventional GDMT sequencing and the rapid GDMT sequencing are both effective in reducing CV mortality as well in reaching the composite endpoint. Remarkably, our proposed rapid GDMT sequencing, promptly initiated and implemented, significantly reduces HF rehospitalization risk compared to the conventional, stepwise strategy. This well represents the concept of "the earlier, the better", to be taken into account when managing patients affected by HF.

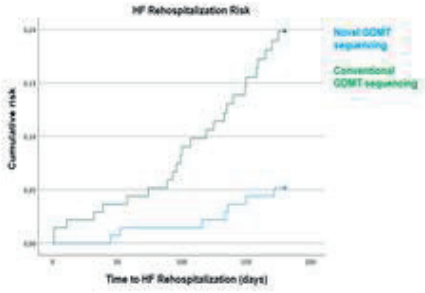

Figure 1. Survival analysis on HF rehospitalization performed through the Kaplan-Meier method.

Variable	Novel GDMT Sequencing (n=139)	Conventional GDMT sequencing (n=139)	p-value
Composite endpoint	17	26	0.135
CV death	11	9	0.642
HF rehospitalization	7	25	<0.001

Table 1. Adverse events occurrence in the novel GDMT sequencing group vs. in the conventional GDMT sequencing group.

A948: PROGNOSTIC PERFORMANCE OF MECKI SCORE IN HEART FAILURE PATIENTS WITH NON VALVULAR ATRIAL FIBRILLATION TREATED WITH EDOXABAN

Irene Mattavelli (a), Massimo Mapelli (a), Elisabetta Salvioni (a), Alice Bonomi (a), Nicolò Capra (a), Carlo Vignati (a), Piergiuseppe Agostoni (a)
(a) CENTRO CARDIOLOGICO MONZINO IRCCS

Background. Risk stratification in heart failure (HF) is crucial for clinical and therapeutic management. The Metabolic Exercise test data combined with Cardiac and Kidney Indexes (MECKI) score is a validated HF model to assess the risk of cardiovascular mortality, urgent heart transplantation and Left Ventricle Assist Device implantation at 2 years. The score integrates cardiopulmonary exercise test (CPET) parameters with hemoglobin, serum sodium, kidney function (MDRD), left ventricle ejection fraction, peak oxygen consumption [% pred] and VE/VCO_2 slope. Non-valvular atrial fibrillation (NVAF) is a common feature in HF patients. Recently, direct oral anticoagulants (DOACs) were introduced as an alternative VKAs and have now emerged as the preferred choice. Aim of the study was to assess the reliability of the prognostic evaluation by MECKI score also in HF patients treated with Edoxaban for NVAF.
Methods. We prospectively enrolled consecutive outpatients with HF and NVAF treated with Edoxaban. Each patient underwent a maximal ramp-protocol CPET and a blood sampling for complete blood count, serum electrolytes and renal function. This population was matched for age and sex by propensity score with a retrospective group of HF patients with NVAF treated with VKA belonging to the MECKI score registry.
Results. 83 patients with HF and NVAF treated with Edoxaban were enrolled. Median follow up was 814[608-1052] days. A control population was identified in the multicentric MECKI score database (n=7800) by

selecting all consecutive patients with HF and NVAF treated with VKA (n=844). The population was propensity score–matched for age and sex. Table 1 compares the main population characteristics. MECKI score performs equally well in predicting the outcome in the two groups (AUC matched population 0.73193, AUC Edoxaban group 0.6557, p=ns) (Figure 1).

Conclusions. MECKI score power was confirmed also in the new population treated with Edoxaban with a slightly higher performance respect to patients treated with VKA.

	Edoxaban pop (n=83)	MECKI score pop (n=83)	p-value
Age (years)	72.13±9.3	72.13±9.3	1
Males (n, %)	73(88%)	73(88%)	1
BMI	26.71±3.9	26.75±4.4	0.953
LVEF (%)	34.34±10.3	34.42±11.4	0.964
peak VO2 (mL/min)	1092.26±318.1	1014.55±290.1	0.105
VE/VCO2 slope	38.2(33.7;43.6)	33(30;38.6)	0.000
Hb (g/dL)	13.77±2	13.35±1.8	0.165
Creatinine (mg/dL)	1.3(1;1.6)	1.2(1;1.6)	0.647
Ischemic etiology (n, %)	39(46.2%)	35(42.2%)	0.611
ACE inhibitor (n, %)	19(22.8%)	50(60.2%)	<.0001
AT1 inhibitor (n, %)	5(6.3%)	20(24.7%)	0.001
ARNI (n, %)	51(63.4%)	7(8.4%)	<.0001
Diuretic (n, %)	70(88.6%)	76(91.6%)	0.528
MRA (n, %)	56(70.9%)	61(73.5%)	0.711
Statin (n, %)	48(60.8%)	31(37.3%)	0.003
Allopurinol (n, %)	22(27.8%)	23(27.7%)	0.984
Antiplatelet (n, %)	35(44.3%)	9(10.8%)	0.000
Digitalis (n, %)	8(10.1%)	31(38.3%)	0.000
Amiodarone (n, %)	48(60.8%)	29(35.8%)	0.002

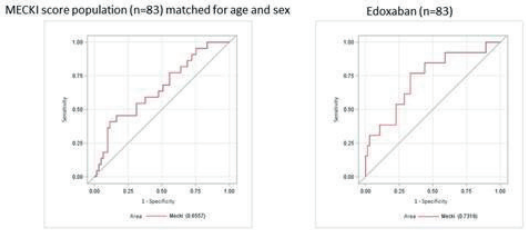

A949: ENDOTHELIAL FUNCTION IN PATIENTS WITH CHRONIC HEART FAILURE AND TREATED BY SGLT2I

Damiano D'Alessandro (a), Massimo Barile (a), Chiara Corsaro (a), Nicola Di Nunno (a), Raffaele Capasso (a), Gabriella Bufano (c), Michele Granatiero (a), Marco Amatruda (a), Adriana Mallardi (c), Pietro Mazzeo (c), Michele Correale (b), Massimo Iacoviello (a), Olga Lamacchia (a), Eugenio Stabile (c), Natale D Brunetti (a, b)
(a) DEPARTMENT OF MEDICAL AND SURGICAL SCIENCES, UNIVERSITY OF FOGGIA; (b) CARDIOTHORACIC DEPARTMENT, POLICLINICO RIUNITI FOGGIA, FOGGIA, ITALY; (c) SAN CARLO REGIONAL HOSPITAL OF POTENZA; (d) DI VENERE HOSPITAL, BARI

Background. Chronic heart failure (CHF) is characterized by higher rates of endothelial dysfunction (ED). Sodium-glucose cotransporter type 2 inhibitors (SGLT-2i) represent a new class of drugs for CHF. Switch to SGLT2i in patients with CHF and T2DM was associated in an observational non-randomized study with an improved endothelial function. Nevertheless, it is unclear whether the benefits of SGLT-2i therapy rely on the endothelial function (EF) in patients with CHF.

Aim. To evaluate possible changes in endothelial function assessed by flow-mediated dilation (FMD) in patients affected by CHF with and without diabetes, switching from other oral hypoglycemic agents to SGLT2i (baseline) and after 3 months of SGLT2i therapy in an observational study.

Methods. Consecutive CHF outpatients were enrolled from 3 heart failure centers in southern Italy (Policlinico Riuniti University Hospital of Foggia, Di Venere Hospital of Bari, San Carlo regional Hospital of Potenza) from January 2022 to December 2023. Patients were compared according to the of SGLT-2i therapy. FMD of the brachial artery is assessed under standardized condition, according to the "Brachial Artery Reactivity Task Force's guidelines" at baseline and 3 months of therapy.

Results. 99 CHF outpatients (68,4 ± 10,6 years, LVEF 36,44 ± 7,68%, 19 female). were enrolled. 60 (59,4%) patients were diabetic. Three months of therapy with SGLT2i was associated with a statistically significant improvement in endothelial function (9,3% vs 15,09%, p: 0.000) in CHF outpatients with T2DM. Therapy with SGLT2i was not associated with a statistically significant improvement in endothelial function in CHF patients without T2DM (13,78% vs 16,74%, p: 0,062).

Conclusions. Switch to SGLT2i in outpatients with CHF and T2DM was associated in an observational non-randomized study with an improved endothelial function.

A950: CORRELATION BETWEEN MICRORNA126 LEVELS IN PLATELET AND PLATELET POOR PLASMA ON HEART FAILURE PATIENTS

Antonella Bordin (a), Elisabetta De Marinis (a), Giacomo Frati (a), Isotta Chimenti (a), Elena De Falco (a)
(a) SAPIENZA UNIVERSITÀ DI ROMA, DIPARTIMENTO DI SCIENZE E BIOTECNOLOGIE MEDICO CHIRURGICHE

Background. The miRNAs are small non-coding RNA molecules expressed in many cell types and secreted into extracellular human fluids. The role of miRNAs in regulating both physiological and pathological conditions such as heart failure (HF), acute myocardial infarction (AMI) and coronary artery disease (CAD) has significantly emerged. The function exerted by miRNAs is not limited to the cardiovascular field, but it also includes platelets, where miRNA expression levels have been suggested as potential biomarkers of their reactivity and response to antiplatelet therapy as tool for risk stratification of ischemic events. The miR126, also acknowledged as angiomiR126, is one of the most abundant free miRNA expressed in the blood of exclusive platelet origin and with both angiogenic and regenerative properties. The levels of miR126 are directly associated to CVDs and have been demonstrated of prognostic significance. The link of miRNA126, heart failure and platelet activity is known, as well as the biological and molecular effects exerted by the miR126 in the blood stream in the form of free miRNA. Despite this, the modality by which the miRNA126 is regulated among the platelet compartment and the blood stream, is unclear as well as the biological effects of potential shifting among the two sources upon pharmacological treatment. These are clinically to recognize the miRNA-126 as biomarkers and therapeutic targets.

Aim. The aim of this study is to investigate the regulation of the miR126 of both platelet and systemic origin in patients clinical therapy for HF, understanding the potential biological advantage of the cardiovascular treatment with specific regard to the gender difference and correlation with clinical parameters and angiogenic properties. Specifically, in this study, we quantified the copy number of miR-126 of platelet and extracellular origin (plasma) by digital droplet PCR.

Results. The results show that in a court of 28 patients with HF express a lower amount of platelet-derived miR-126 compared to the extracellular compartment and differently from 12 healthy controls ($p<0.05$). However, the amount of MiR126 in patient's platelets is decreased respect to controls. When patients are stratified for gender (15 females and 13 males), the above result is confirmed only in men, which expressed higher amount of the miR126 in the plasma compared to the platelet counterpart($p<0.01$). Women with HFD do no show significant differences among the two sources and show a decrease amount of miR126 in plasma compared to men. The gender aspect does not influence the expression of miR126 in both platelet and plasma.

A951: NT-PROBNP NEL CUORE TRAPIANTATO: ANDAMENTO TEMPORALE E CORRELAZIONE CON PARAMETRI PRE E POST-OPERATORI

Giulia Elena Mandoli (a), Giulia Coarelli (c), Luca Martini (a), Andrea Renzelli (a), Cosimo Salvatici (a), Laura Stefania Truica (a), Andrea Zito (c), Sonia Bernazzali (b), Massimo Maccherini (b), Serafina Valente (a), Matteo Cameli (a)
(a) DEPARTMENT OF MEDICAL BIOTECHNOLOGIES, DIVISION OF CARDIOLOGY, UNIVERSITY OF SIENA; (b) DEPARTMENT OF CARDIAC SURGERY, UNIVERSITY OF SIENA; (c) DEPARTMENT OF CARDIOVASCULAR MEDICINE, FONDAZIONE POLICLINICO UNIVERSITARIO A. GEMELLI IRCCS, ROME, ITALY

Introduzione. Il ruolo benefico dei peptidi natriuretici a livello cardiaco è stato ampiamente dimostrato. Nel setting cronico, valori di NT-proBNP<125 pg/ml consentono di escludere lo scompenso cardiaco, avendo questi marcatori un elevato valore predittivo negativo. Inoltre, numerosi studi hanno dimostrato una significativa correlazione tra i valori di NT-proBNP e la prognosi dei pazienti con scompenso cardiaco. L'applicazione delle stesse soglie di NT-proBNP non è mai stata studiata nei pazienti dopo trapianto cardiaco (HTx) che spesso non raggiungono mai una normalizzazione dei valori nonostante normale funzione sisto-diastolica biventricolare.

Obiettivi. Identificare l'andamento dell'NT-proBNP nel follow-up dei pazienti sottoposti a HTx e valutare un'eventuale sua correlazione con parametri preoperatori ed ecocardiografici del cuore trapiantato.

Metodi. Abbiamo condotto uno studio retrospettivo su 74 pazienti sottoposti a HTx nel nostro Policlinico tra il 2001 e 2022, seguiti con regolari follow-up come da indicazioni internazionali. Ciascun paziente è stato valutato nel tempo, considerando variazioni nel peso, valori di pressione arteriosa sistolica e diastolica, dosaggio dei farmaci immunosoppressori, esami di laboratorio (tra cui i valori di NT-proBNP), dati elettrocardiografici (ritmo cardiaco, eventuali ritardi di conduzione intraventricolare) e dati ecocardiografici (tra cui frazione d'eiezione, parametri di funzione diastolica, pressione in arteria polmonare). Per ciascun paziente, sono stati inoltre considerati il valore di NT-proBNP pre-operatorio, i dati derivati dal cateterismo cardiaco destro, l'eziologia della cardiomiopatia (ischemica o non ischemica), l'eventuale necessità di assistenza ventricolare a breve o lungo termine nel pre-trapianto e le modalità di esecuzione del trapianto (in urgenza o in elezione). Abbiamo infine tenuto conto delle possibili complicanze del trapianto cardiaco e segnalato la presenza di episodi di rigetto o coronaropatia del graft.

Risultati. Dall'analisi effettuata mediante test di Friedman è emerso che la riduzione maggiormente significativa di NT-proBNP si realizza entro i primi 90 giorni dal trapianto (valore medio 2008 pg/ml) e ad un anno dal trapianto (valore medio 489 pg/ml). Sono stati analizzati altri due gruppi minori di pazienti di cui disponevamo di un controllo a due anni e a tre anni. Nel primo gruppo, il valore di NT-proBNP sembra ridursi in maniera

significativa (P value <0.001), passando da un valore medio di 2057 pg/ml nei primi 90 giorni, a un valore medio di 491 pg/ml ad 1 anno, fino a un valore medio di 407 pg/ml a 2 anni. Analogamente è avvenuto nel secondo gruppo, in cui il valore di NT-proBNP sembra ridursi in maniera significativa (P value <0.001), passando da un valore medio di 2105 pg/ml nei primi 90 giorni, a un valore medio di 585 pg/ml ad 1 anno, a un valore medio di 490 pg/ml a 2 anni, fino a un valore medio di 367 pg/ml a tre anni. Tuttavia, dai dati finora raccolti, non è emersa una correlazione significativa tra i parametri da noi analizzati (relativi sia al pre- che al post-trapianto, inclusa l'insorgenza di rigetto o di coronaropatia) e l'andamento dei valori di NT-proBNP a un anno dal trapianto.
Conclusioni. Elevati valori di NT-proBNP si riscontrano entro i primi 90 giorni dal trapianto, riducendosi significativamente dopo il primo anno e, seppur in misura minore, un'ulteriore riduzione si osserva a due e tre anni dal trapianto senza una correlazione con la funzione sisto-diastolica o le pressioni polmonari stimate testimoniando una diversa fisiopatologia del cuore trapiantato.

A952: THE EARLY USE OF INOTROPES, BB, SGLT2-I, ACE-I/ARNI AND MRA IN ACUTE HEART FAILURE: THE PENTA-HF OBSERVATIONAL STUDY

Paolo Severino (a), Andrea D´amato (a), Silvia Prosperi (a), Marco Valerio Mariani (a), Claudia Cestiè (a), Aurora Labbro Francia (a), Vincenzo Myftari (a), Rosanna Germanò (a), Lucia Ilaria Birtolo (a), Carlo Lavalle (a), Viviana Maestrini (a), Roberto Badagliacca (a), Massimo Mancone (a), Carmine Dario Vizza (a), Francesco Fedele (a)
(a) DIPARTIMENTO DI SCIENZE CLINICHE, INTERNISTICHE, ANESTESIOLOGICHE E CARDIOVASCOLARI, SAPIENZA UNIVERSITÀ DI ROMA, VIALE DEL POLICLINICO 155, 00161 ROMA, ITALIA

Background. Acute heart failure represents a condition burdened by high mortality rate. The risk of hospitalization and cardiovascular (CV) mortality is high, particularly during the vulnerable phase after a hospitalization due to HF. For this reason, the management of patients during the acute and in the post-acute phase is crucial and challenging.
Hypothesis. The early use of Levosimendan may provide beneficial cardiorenal effects favouring patients' stabilization and rapid optimization of disease modifiers drugs for HFrEF (BB, SGLT2i, ACEi/ARNI and MRAs), impacting on the risk of CV mortality and rehospitalisation due to HF.
Aims. To compare the approach based on the early use of Levosimendan, followed by rapid optimization of HFrEF therapy, to the approach using other inotropes/vasopressors or high-dose diuretic therapy followed by sequential optimization of HFrEF therapy. The primary composite endpoint is represented by hospitalization due to HF and CV mortality. The secondary endpoints are each of the outcome included in the primary endpoint.
Methods. In this prospective, observational study a total of 176 patients admitted due to acute heart failure have been enrolled. 88 patients, treated with a strategy of rapid HFrEF therapy uptitration, following Levosimendan administration constitute the group 1 (G1). 88 patients constitute the control group (G2), consisting of patients who were not treated with Levosimendan, during the acute phase, but with different approaches, such as other inotropes/vasopressors or high-dose diuretic therapy and subsequently treated with classical sequential HFrEF therapy approach. The comparison between the two groups has been performed at the 6-month follow-up.
Results. Kaplan Meier survival analysis showed non statistically significant differences between the two groups in term of the primary composite endpoint (p=0.72) (Figure 1). However, significant difference in term of rehospitalisation due to HF has been found in favour of G1 compared to G2 (p=0.023). No differences have been found in term of CV mortality between the two groups (p=0.08).
Conclusions. Administration of Levosimendan in the acute setting, followed by rapid optimization of BB, SGLT2i, ACEi/ARNI and MRAs results in reduced hospitalization due to HF in the vulnerable post-discharge phase.

Figure 1.

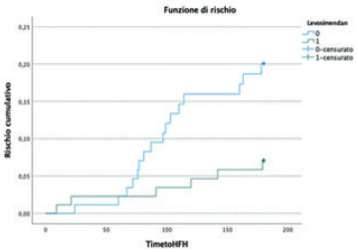

Figure 2. Time to HF Rehospitalization (days).

A953: BIOMARKERS AND HEART FAILURE: THE PROGNOSTIC ROLE OF HS-TROPONIN T

Paolo Severino (a), Andrea D´amato (a), Silvia Prosperi (a), Marco Valerio Mariani (a), Claudia Cestiè (a), Aurora Labbro Francia (a), Vincenzo Myftari (a), Elisa Tomarelli (a), Domenico Filomena (a), Roberto Badagliacca (a), Massimo Mancone (a), Francesco Fedele (a), Carmine Dario Vizza (a)
(a) DEPARTMENT OF CLINICAL, INTERNAL, ANESTHESIOLOGY AND CARDIOVASCULAR SCIENCES, SAPIENZA UNIVERSITY OF ROME, VIALE DEL POLICLINICO 155, 00161 ROME, ITALY

Introduction. The role of natriuretic peptide is widely known as necessary to diagnose and follow up heart failure (HF) patients. High-sensitve (hs)-troponin is a marker of myocardial injury and high levels in HF patients are associated with myocardial necrosis, a different pathway of myocardial damage compared to natriuretic peptides. The aim of this study is to evaluate the prognostic role, in term of cardiovascular mortality, of hs-troponin, in patients hospitalized for HF.
Methods. 252 patients hospitalized for HF have been enrolled. The levels of hs-troponin have been recorded three times for each patient: at the admission, at peak and at the hospital discharge. Two groups have been formed: 182 patients had not an augmentation of the levels of hs-troponin (G1), 70 patients had an augmentation of the levels of hs-troponin (G2). The comparison between the two groups was made at the month 6 of follow-up in term of cardiovascular mortality.
Results. The primary endpoint was reported in 11 patients of the G1 and in 11 patients of the G2. The Kaplan Meier survival analysis showed a statistically significant difference between the two groups in terms of CV mortality (p=0,011) at 6 months. Cox regression analysis confirms that patients with increasing trend of hs-troponin during the index hospitalization were at higher risk of cardiovascular mortality during the following 6 months (HR=2.8).
Conclusions. The increment in the levels of hs-troponin during an index hospitalization due to HF is associated with a worse prognosis, defined as increased risk of CV death, during the 6 months following the hospitalization.

A954: UTILIZZZO DELL'ECOGRAFIA POLMONARE PER GUIDARE LA TERAPIA DELLO SCOMPENSO CARDIACO ACUTO: LO STUDIO PROSPETTICO RANDOMIZZATO LUNGUIDE

Gennaro D'Angelo (a), Greta Barbieri (b, c), Chiara Del Carlo (b), Chiara Deri (b), Luna Gargani (c), Lorenzo Ghiadoni (a, b)
(a) DIPARTIMENTO DI MEDICINA CLINICA E SPERIMENTALE, UNIVERSITÀ DI PISA; (b) SCUOLA DI SPECIALIZZAZIONE DI MEDICINA D'EMERGENZA URGENZA, UNIVERSITÀ DI PISA, MEDICINA DI URGENZA, AZIENDA OSPEDALIERO UNIVERSITARIA PISANA; (c) DIPARTIMENTO DI PATOLOGIA CHIRURGICA, MEDICA, MOLECOLARE E DELL'AREA CRITICA, UNIVERSITÀ DI PISA

Introduzione. Lo scompenso cardiaco (SC) è una patologia con un impatto sanitario rilevante perchè gravata da riacutizzazioni con numerosi accessi presso il Dipartimento di Emergenza (DEA). La congestione è la principale causa di ospedalizzazione ed evidenze suggeriscono che alla dimissione si abbia persistenza di congestione polmonare subclinica. L'ecografia polmonare (LUS) con conteggio standardizzato delle linee B (LUS score) potrebbe quantificare efficacemente questa condizione, guidando il trattamento diuretico nel paziente con lo SC acuto.
Scopo e Metodi. Lo studio LUNGUIDE si propone di valutare se il LUS score applicato con modalità standardizzate e scoring numerico possa essere utilizzato come integrazione ai parametri clinico-laboratoristici per ottimizzare la gestione della terapia diuretica. Il protocollo prevede l'arruolamento di 158 pazienti ammessi in DEA per SC acuto, randomizzati nei due bracci "standard" ed "eco- guidato", su cui applicare gestioni terapeutiche differenti. Le ecografie polmonari sono state eseguite quotidianamente applicando uno schema topografico a 8 spazi e refertate con score numerico in base a modelli già validati in letteratura. Gli esami sono stati effettuati da un Sonographer esperto con registrazione di clips ecografiche di 3 sec ciascuna, sottoposte a successiva revisione da parte di un secondo operatore esperto.
Popolazioni e Risultati. È stata condotta un'analisi preliminare che ha confrontato 38 pazienti, valutati retrospettivamente, ricoverati per SC presso la UO di Medicina di Urgenza gestiti in modo empirico e 36 pazienti prospettici gestiti in base alle più aggiornate linee guida associate ad applicazione di LUS. I pazienti prospettici presentano degenze medie più lunghe (6.6±11.0 vs 9,7±4,3 giorni; p=0.02), che si associano tuttavia a migliori outcome a 30 giorni (migliore stabilizzazione clinico- laboratoristica). I pazienti prospettici del LUNGUIDE mostravano caratteristiche simili nei due gruppi di studio all'arruolamento. L'analisi preliminare evidenzia che nel gruppo "eco-guidato" si sia adottata un utilizzo di dosi maggiori di diuretico durante la degenza. Tale atteggiamento terapeutico ha determinato una maggiore riduzione dell'NT-proBNP alla dimissione, a prezzo di un peggioramento solo temporaneo della funzione renale solo temporaneo e di una degenza più lunga (8.4±2,9 vs 9,9±3.4 giorni; p=0.14). L'outcome combinato (decesso o nuovo accesso per SC) si è verificato in soli 7 pazienti, con una lieve prevalenza nel gruppo "standard" (22% vs 17%, p=0,17) a causa dell'attuale insufficiente scarsa numerosità della popolazione di studio.
Conclusioni. La gestione dei pazienti con SC acuto utilizzando il LUS sco-

re determina una degenza più lunga, necessaria ad un'adeguata risoluzione della congestione polmonare. Nonostante la bassa numerosità, i dati preliminari suggeriscono che LUS consenta di identificare una persistente congestione polmonare, indirizzando verso un potenziamento del trattamento diuretico che non inficia negativamente sulla funzione renale e determina un a maggiore riduzione del NT-BNP alla dimissione. LUS è uno strumento utile nelle mani di un Sonographer esperto, non solo per la diagnosi e monitoraggio, ma anche come guida della gestione terapeutica dei pazienti con SC acuto.

A955: CUORE E MALATTIE REUMATOLOGICHE ACUTE: UN QUADRO DI SCOMPENSO CARDIACO ACUTO

Debora D'Elia (a), Francesco Coppola (a), Antonella Rispoli (a), Emanuele Nigro (a), Costantina Prota (a), Alfonso Campanile (a), Amelia Ravera (a), Carmine Vecchione (a), Gennaro Galasso (a), Federica Di Feo (a)
(a) SAN GIOVANNI DI DIO E RUGGI D'ARAGONA

Il caso che presentiamo riguarda una donna di 65 anni, ricoverata in Dicembre presso il reparto di Cardiologia della nostra AOU per episodio di scompenso cardiaco a bassa gittata esordito con epigastralgia, sudorazione e dispnea. L'anamnesi cardiovascolare era pressocchè muta; presente invece una storia di tiroidite cronica e un'infezione da SARS COV-2. All'esame obiettivo presentava ipofonesi dei campi polmonari basali ed edemi declivi improntabili. Gli esami ematochimici evidenziavano rialzo degli indici di miocardionecrosi, del BNP, della creatininemia e degli indici infiammatori (VES, PCR, beta2microglobulina, ferritina, fibrinogeno), anemia normocromica normocitica, ipogammaglobulinemia, proteinuria ed ematuria. L'ecocardiogramma mostrava severa disfunzione biventricolare ed insufficienza mitralica di grado moderato. Eseguiva pertanto esame coronarografico che evidenziava vasi coronarici epicardici esenti da lesioni significative. La RMN cardiaca evidenziava un diffuso late enhancement subendocardico ventricolare ed atriale a distribuzione non vascolare, suggestivo di patologia autoimmune. Ad un esame obiettivo più attento si notavano piccole teleangectasie al volto, iperpigmentazione del torace e del dorso e tumefazione delle mani. Il pannello anticorpale evidenziava positività degli ANA e ad anti scl-70. Posta così diagnosi di sclerosi sistemica con coinvolgimento cardiaco, alla paziente veniva iniziata terapia con cortisonici ad alto dosaggio in una gestione polispecialistica coinvolgente cardiologi e reumatologi. A gennaio la paziente accedeva nuovamente presso il nostro nosocomio per scompenso cardiaco acuto in corso di FA ad alta risposta ventricolare; veniva ricoverata presso l'unità di Terapia Intensiva Cardiologica. Durante la degenza, nonostante terapia specifica, si evidenziava un progressivo deterioramento dello stato clinico, modifiche ecocardiografiche (aumento degli spessori di parete, pattern di tipo restrittivo) e laboratoristiche (rialzo della troponina, picco monoclonale). Si eseguiva la biopsia del grasso periombelicale, negativa per amiloide, e successivamente la biopsia endomiocardica che evidenziava grossolani aspetti fibroelastosici e depositi di proteina amiloide, concludendo con diagnosi di amiloidosi AA. La sclerosi sistemica è una connettivite caratterizzata da disfunzione endoteliale, iperreattività dei fibroblasti ed alterazione dell'autoimmunità. Clinicamente coinvolge tipicamente la cute ma è frequente l'interessamento di polmoni, cuore e reni. L'interessamento cardiaco (15-35% dei casi fino all'80% nei rilievi autoptici), in associazione a quello polmonare, è ad oggi ritenuto il maggior determinante della prognosi di questi pazienti. Il seguente caso clinico ci dimostra come tale patologia vada ricercata attivamente con l'obiettivo di aggredirla con tutte le possibilità terapeutiche disponibili tenendo conto che quando diventa clinicamente rilevante dal punto di vista cardiologico è spesso segno di una attività di malattia a rapida progressione.

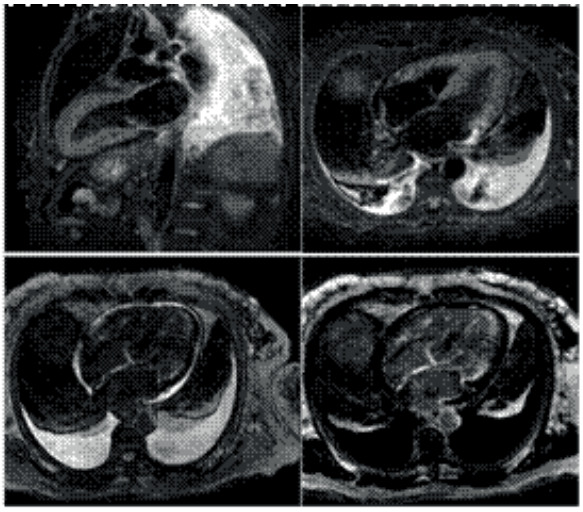

A956: A CASE OF SECONDARY CARDIAC HEMOCHROMATOSIS IN A YOUNG PATIENT

Alessandro Kratter (a, b), Paolo Springhetti (a, b), Martina Setti (a, b), Giovanni Benfari (a, b), Flavio Luciano Ribichini (a, b)
(a) AZIENDA OSPEDALIERA UNIVERSITARIA DI VERONA; (b) SCUOLA DI SPECIALITÀ MALATTIE DELL'APPARATO CARDIOVASCOLARE DI VERONA

Secondary iron overload cardiomyopathy is a preventable and potentially reversible cause of heart failure (HF). Patients may be asymptomatic in the early phase of the disease with hidden progression of cardiac dysfunction. The treatment is based on the targeted chelation of iron and can change the prognosis of these patients. A 32-year-old woman affected by thalassemia was referred to our hospital for a new-onset HF episode symptomatic for exertional dyspnea and declivous oedemas. The patient reported a not pathological transthoracic echocardiogram (TTE), performed three years before; however, she disattended a regular cardiological follow-up and the therapeutic compliance with iron-chelators was suboptimal. Chest radiography revealed lung congestion and increased cardiac profile. An electrocardiogram showed sinus rhythm with early supra-ventricular ectopy, high voltage and concomitant diffuse deep T wave inversion. TTE confirmed a moderate asymmetrical left ventricular hypertrophy with slightly reduced global systolic function and concomitant severe diastolic impairment (restrictive pattern); notably, the posterior wall presented 13 mm width with markedly augmented echogenicity. Inferior vena cava was dilated. Mild to moderate mitral regurgitation was also present. Secondly, cardiac magnetic resonance showed a significant cardiac iron overload in T2 star sequences (T2 value 1.72 ms; normal value 20 ms). Chelation therapy was optimized, and patient compliance was encouraged. Additionally, a regular cardiological follow-up with multi-modality imaging assessment was programmed. This clinical case was emblematic and highlighted how secondary cardiac hemochromatosis should be also searched in young patients with a history of repeated transfusions.

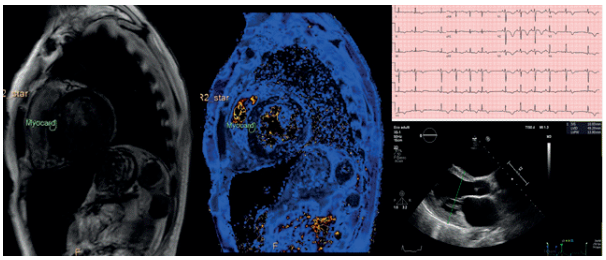

A957: CARDIOPULMONARY EXERCISE TESTING HFPEF SCORE

Silvia Moscardelli (a), Giulia Nemola (a), Irene Rusconi (a), Marco Guazzi (a)
(a) UNIVERSITÀ DEGLI STUDI DI MILANO

Background. The ESC PEFF algorithm for the diagnosis of heart failure with preserved ejection fraction (HFpEF) does not incorporate cardiopulmonary exercise testing (CPET)-derived variables, unless their use is suggested at the earlier step for ruling out non-cardiac causes of dyspnea.
Aims. To implement evidence for the CPET use in the score and better phenotype patients with a positive (PEFF+) vs negative (PEFF-) score.
Methods. 38 subjects (average age, 65 ± 14) with exertional dyspnea and preserved left ventricular ejection fraction (average LVEF, 59%± 6), underwent a CPET assessment along with echocardiography and NT-proBNP measures. Subjects were divided according to the confirmation or not of a HFpEF diagnosis at the Preliminary, Echocardiographic or Functional sequential steps.
Results. (Table): Compared to PEEF- patients, PEFF+ ones were older (73 years old), predominantly female (66%) and with a slightly higher BMI (average BMI 26). They exhibited a significant lower functional capacity with an O_2 pulse and a delta VO2/WR similar to PEFF- patients. They also presented a significantly higher ventilation inefficiency and chronotropic inefficiency. *HRR was calculated as the difference between the maximal heart rate and the resting heart rate.
Conclusions. Our findings provide a clue for an in-depth use of CPET into the diagnostic and phenotyping process of individuals complaining unexplained exertional dyspnea. These perspectives seem promising and need to be confirmed and expanded in larger number studies.

Variables	PEFF-	PEFF +	P value (unpaired T-test)
Age	54,5	74	<0,001*
BMI, m^2	23,9	25,9	0,24
Peak VO_2, ml/min/kg	21,2	14,6	0,0015*
Peak O_2 Pulse	9,9	9,3	0,6
VO_2/Work slope ml/min/watt	10,4	11,2	0,55
VE/VCO_2 slope	34,7	40,6	0,046*
HRR, beats/min *	36,6	27,5	0,59
HR max	137,9	112,9	0,01*

A958: RELEVANCE OF CARDIAC AND NON-CARDIAC COMORBIDITIES ON LEFT VENTRICULAR SYSTO-DIASTOLIC PROPERTIES AND HEALTH RELATED QUALITY OF LIFE IN HEART FAILURE PATIENT

Giovanni Rubino (a, b), Michela Boromei (a, b), Domenico Filomena (a, b), Giovanna Manzi (a, b), Matteo Neccia (a, b), Annalisa Caputo (a, b), Giorgia Serino (a, b), Silvia Prosperi (a, b), Andrea D'Amato (a, b), Paolo Severino (a, b), Silvia Papa (a, b), Carmine Dario Vizza (a, b), Roberto Badagliacca (a, b)
(a) POLICLINICO UMBERTO I; (b) SAPIENZA UNIVERSITÀ DI ROMA

Background and Aim. Patients diagnosed with heart failure (HF), irrespective of their ejection fraction (EF) phenotype, experience a substantial burden of cardiovascular (CVC) and non-cardiovascular (nCVC) comorbidities. This study aimed to assess how CVC and nCVC affect the health status of outpatients diagnosed with HF.

Methods. We enrolled consecutive outpatients diagnosed with HF. The following nCVC were recorded: diabetes, chronic kidney disease, chronic obstructive pulmonary disease (COPD), obstructive sleep apnea syndrome, dyslipidemia, active or prior cancer, and anemia. Additionally, we evaluated the following CVC: chronic coronary syndrome, hypertension, ventricular tachyarrhythmias, atrial fibrillation (AF), peripheral arterial disease (PAD), and prior stroke. We also evaluated previous device implantation, including pacemaker (PMK), cardiac resynchronization therapy, and cardioverter defibrillator. Patients underwent laboratory tests, including NT-pro-BNP, and comprehensive echocardiography. The Kansas City Cardiomyopathy Questionnaire (KCCQ) was administered, and an overall summary score (OSS) was calculated. Health status (HS) was categorized based on OSS as follows: 0 to <25, indicating very poor to poor HS; 25 to <50, indicating poor to fair HS; 50 to <75, indicating fair to good HS; and 75 to 100, indicating good to excellent HS. We employed ordinal logistic regression analysis to examine the association between OSS and comorbidities, with adjustments for age and gender.

Results. A total of 178 patients were enrolled, with hypertension being the most common CVC and dyslipidemia the most prevalent among nCVC (76% and 70%, respectively). We observed very poor to poor HS in 4% of patients, poor to fair HS in 19%, fair to good HS in 29%, and good to excellent HS in 48%. OSS showed no significant correlation with EF, Log NT-pro-BNP while moderately correlated with left atrial volume index (ρ-0.240, p=0.002). Both age and female sex were significantly linked to a lower OSS. Among comorbidities, AF, chronic kidney disease (CKD), anemia, and prior PMK implantation were associated with a lower OSS. After adjusting for age and sex, only anemia and prior PMK implantation remained significantly associated with a poorer health status.

Conclusions. In HF patients, older age, female sex, anemia, and prior PMK implantation are independently associated with a lower self-reported health status.

OSS				
	Unadjusted		Adjusted	
	OR (95% CI)	P	OR (95% CI)	P
Female	0,91 (0,21-0,80)	0,009		
Age	0,95 (0,92-0,98)	<0,001		
AF	0,55 (0,31-0,97)	0,039	0,63 (0,35 - 1,14)	0,128
PMK	0,15 (0,06-0,42)	<0,001	0,22 (0,08-0,63)	0,004
CKD	0,52 (0,28-0,95)	0,035	0,71 (0,37-1,35)	0,299
Anemia	0,27 (0,14-0,51)	<0,001	0,36 (0,18-0,70)	0,003

A959: LE VARIAZIONI DI BNP DURANTE UNLOAGING TERAPEUTICONELLO SCOMPENSO CARDIACO CRONICO HANNO UN SIGNIFICATO PROGNOSTICO?

Soccorso Capomolla (a), Antonella Capomolla (a), Claudia Natale (a), Josef Ranieli (a), Simone Lo Gatto (a), Valentina Pannace (a), Federica Daddesso (a)
(a) DON MOTTOLA MEDICAL CENTER

Premessa. Numerosi studi hanno evidenziato l'utilità del Brain natriuretc peptide(BNP) nella diagnosi e prognosi dei pazienti con scompenso cardiaco cronico. Tuttavia rimane ancora poco definito il significato prognostico delle variazioni di BNP durante unloading terapeutico.

Scopo. Analizzare l'associazione tra le variazioni di BNP durante unloading terapeutico e l'outcome a breve periodo in pazienti con scompenso cardiaco cronico.

Metodi. In condizioni basali,ed in predimissione una valutazione clinica e del dosaggio di BNP sono stati eseguiti in 53 pz (61±11 aa) con SCC (FE 26±7%) secondario a cardiomiopatia dilatativa ischemica (25) o non ischemica (28). Durante una degenza media di 33±18 gg i pz hanno eseguito ottimizzazione terapeutica secondo le linee guida. Alla dimissione è stato nuovamente determinato il livello di BNP. Le variazioni di BNP sono state espresse come% dei valori di ingresso. Un valore di Cut-off di variazione del 30% (mediana) è stato utilizzato per discretizzare il campione. Durante un follow-up medio di 120± 45 gg sono stati considerati come eventi clinici maggiori le reospedalizzazioni e la morte cardiaca.

Risultati. In 30/53(57%) è stata praticata terapia endovenosa con diuretici e nitroprussiato. In tutti i pazienti è stata eseguita ottimizzazione della terapia orale (vedi tab1). 31/53(59%) presentavano una riduzione>30% del BNP basale. Durante il follow-up 16 eventi cardiaci maggiori sono occorsi in 14/53 (26%). 13/16(81%) reospedalizzazioni per SCC e 3/16(19%) morti cardiache. Nel sottogruppo con una riduzione>30% del BNP basale i pazienti con eventi (4/31)(14%))sono stati significativamente minori rispetto al gruppo con una riduzione <30% del BNP basale (12/22), (54%) (logRank p<.01) (fig.1). Alla dimissione una riduzione del BNP>30% era un fattore protettivo rispetto ai pazienti con una riduzione del BNP<30% (RR. 0.33, LC 95% 0.31– 0.44).

Conclusioni. Le variazioni di BNP durante unloading terapeutico sono significamente associate all'outcome clinico a breve termine in pazienti con SCC. Tale evidenza può acquisire un ruolo nella individualizzazione del follow-up del paziente con SCC.

	Ingresso	Dimissione	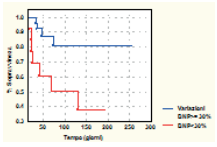 p
BNP	1070 ± 786	706± 967	0.005
ACE-Long-ac.(mg/die)	12 ± 7	12,7 ± 7	ns
ACE – Short-T.(mg/die)	92±41	118 ± 48	.001
Beta-bloccanti.(mg/die)	12±9	23±8	0.08
Nitrati.(mg/die)	37±45	74±51	0.004
Digitale.(mg/die)	.06±.06	.05±.6	ns
Andialdost..(mg/die)	47±31	39±33	ns

A960: STUDY OF ENDOTHELIAL FUNCTION IN PATIENTS AFFECTED BY HEART FAILURE WITH REDUCED EJECTION FRACTION ON TREATMENT WITH SGLT2I

Angelica Cersosimo (a), Ludovica Amore (a), Giuliana Cimino (a), Selene Capuana (a), Matteo Pagnesi (a), Riccardo Maria Inciardi (a), Marianna Adamo (a), Gianmarco Arabia (a), Carlo Mario Lombardi (a), Marco Metra (a), Enrico Vizzardi (a)
(a) UNIVERSITÀ DEGLI STUDI DI BRESCIA

Introduction. It has already been demonstrated the efficacy of sodium-glucose co-transporter 2 inhibitors (SGLT2i) in the treatment of heart failure with reduced ejection fraction (HFrEF), but their mechanisms of action are still unclear, especially regarding their effects on endothelial dysfunction.

Purpose. Endothelial function modification through peripheral arterial tonometry (RHI) measurement in patients with HFrEF and SGLT2i therapy.

Methods. Our study was a single-center, observational study involving 31 patients with HFrEF (left ventricular ejection fraction ≤40%), who initiated SGLT2i (empaglifozin or dapaglifozin) on top of the other guideline-directed medical treatments. Endothelial function was evaluated with peripheral arterial tonometry (EndoPATVR) at baseline (before initiating therapy with SGLT2i) and at 6-9 month follow-up (during SGLT2i therapy). Reactive hyperemia index (RHI) was reported as a measure of endothelial function.

Results. A total of 31 patients with HFrEF were included in the study (mean age 68.3 ± 14.7 years, 77.4% males, 25.8% with diabetes mellitus, 19.5% with de novo heart failure). Mean RHI at baseline was 1.48 ± 0.43 (median value 1.44, interquartile range [IQR] 1.31-1.65). At the scheduled 6-9 month follow-up (median follow-up of 217 days, IQR 196-240 days), mean RHI was 1.35 ± 0.43 (median value 1.38, interquartile range [IQR] 1.12-1.53). A non-significant difference was observed in RHI between baseline and follow-up evaluation (p=0.283 with paired Student t-test). At an overall median follow-up of 287 days (IQR 239-316 days), all-cause death or HF hospitalization was observed in 5 patients (16.1%). Baseline RHI was not significantly associated with the composite of all-cause death or HF hospitalization (hazard ratio 0.53, 95% confidence interval 0.08-3.49, p=0.510). The delta RHI between baseline and 6-9 month follow-up was also not associated with the composite endpoint (hazard ratio 0.14, 95% confidence interval 0.01-1.82, p=0.133).

Conclusions. In our observational study including 31 patients with HFrEF, endothelial function evaluated by means of peripheral arterial tonometry (RHI) did not significantly change after the introduction of SGLT2i therapy.

A961: PERCUTANEOUS CARILLON MITRAL CONTOUR SYSTEM DEPLOYMENT IN A PATIENT WITH PREVIOUS CRT-D IMPLANT: FIRST CASE REPORT

Michela Giovanna Coccia (a), Tiziana Spezzano (a), Alessio Damiano (a), Michele Pasotti (a), Carlo Augusto Maria Bosatra (a), Amedeo Ferro (a), Fabrizio Giofrè (a), Riccardo Osti (a), Elisabetta Colombi (a), Maria Lorennie Breghi (a), Luca Ballerini (a), Ada Sacchi (a), Marco Griffini (a), Mariachiara Paradisi (a), Pietro Broglia (a), Pietro Gaetano (a)
(a) CARDIOLOGY UNIT, VOGHERA HOSPITAL, ASST PAVIA, VOGHERA, ITALY

Functional mitral valve regurgitation is very common in patients with unfavorable left ventricular remodeling or atriomegaly. It causes worsening of symptoms and consequent repeated hospitalization and functional decline[1]. Conventional surgical repair carries a high perioperative risk due to the low ejection fraction (LVEF) and most patients are ruled out. There are percutaneous strategies as alternative treatment option including Mitra-clip procedure and the Carillon Mitral Contour System[2,3]. The latter method is a right heart transcatheter mitral valve repair device that uses the anatomy of the coronary sinus for remodeling mitral valve annulus and performing "indirect " annuloplasty via the coronary sinus (CS). Previous CRT procedure is an absolute contraindication because of the positioning of left ventricle electrode in a peripheral branch of CS[3]. We present the first case of Carillon implant in a patient with previous CRT-d procedure and a "suitable" anatomy of the CS with favorable position of the left electrode. A 71-year-old patient with chronic ischemic heart disease and dilated-hypokinetic evolution, due to previous extensive anterior infarction and partially ineffective percutaneous three-vessel revascularization (2015), was admitted at our ICU for recurrence of CHF. Progression of CAD was excluded and severe functional MR was assessed as main reason for clinical destabilitation. After an effective cicle of ev nitroprusside, the clinical case was submitted to Heart Team evaluation that ruled out traditional surgery or percutaneous MitraClip procedure. After careful evaluation including CS venography, even in presence of the left electrode, we decided that there was "sufficient anatomic space" in coronary sinus for carillon device placement. On 22/12, we performed percutaneous annuloplasty without complications. After indirect percutaneous Anuloplasty via Carillon device we showed a favorable reverse ventricular remodeling with improvement in left ventricular function, left ventricular filling pressures, diastolic function and hemodynamic parameters. LVEF (left ventricular ejection fraction) =42% vs 29% PAPs=25mmHg vs 65 mmHG, mild-to-moderate MR with symmetric tethering and meso-telesystolic centrovalvular jet vs severe mitral regurgitation with asymmetric tethering and holosystolic eccentric jet. Normal vs dilated right ventricular TAPSE (tricuspid annular plane systolic excursion) 17 vs15mm Antero-posterior mitral annulus diameter 29mm vs 36mm, mid-lateral diameter 31mm vs 36, tenting height 1cm vs 1.5, tenting area 1.9cm2 vs 4.7. At 6 months follow up, right heart catheterization evidenced improved cardiac index (CI) and normalization of vascular resistence (PVR) finding a moderate only post capillary pulmonary hypertension with normal vascular resistances and only slightly reduced CI (CI=2.05 l/min vs 1.7 l/min) PAPs 53 vs 78 mmHg, PAPm 39 vs 45 mmHg, wedge 30 vs 25 mmHg, PVR 2.14 vs 5.9 wu. Therefore, the Carillon procedure can be considered a viable alternative in patient with advanced left ventricular dysfunction and functional mitral regurgitation not eligible for alternative traditional or other percutaneous procedures.

References

1. Cardiovasc Diagn Ther. 2021 Jun; 11(3): 781–792.
2. Front Cardiovasc Med 2020 Nov 20; (7):576058
3. ESC Heart Fail 2021 Jun;8(3):1885-1891.

A962: IMPACT OF SODIUM-GLUCOSE CO-TRANSPORTER 2 INHIBITORS ON CLINICAL, LABORATORISTIC AND ECHOCARDIOGRAPHIC PARAMETERS IN PATIENTS WITH HEART FAILURE AND REDUCED EJECTION FRACTION ALREADY ON ARNI TREATMENT: A REAL WORLD STUDY

Francesco Fioretti (a), Alessia Calzoni (b), Antonio Maria Sammartino (a), Angelica Praderio (a), Maria Grazia De Angelis (a), Marco Parola (b), Savina Nodari (a)

(a) SPEDALI CIVILI HOSPITAL AND UNIVERSITY OF BRESCIA; (b) UNIVERSITY OF BRESCIA

Background. SGLT2i are currently one of the four cornerstones of HFrEF therapy. Despite its proven efficacy and safety, to date there is not enough data about the impact of SGLT2i in real world.

Aim of the study: To determine, in real world practice, the impact of SGLT2i on clinical, laboratoristical, echocardiographic parameters and on worsening heart failure (WHF, defined as need for i.v. diuretic therapy or hospitalizazion for HF) in patients (pts) with HFrEF, on OMT according to the latest international guidelines and already on ARNI.

Methods. Monocentric observational study, enrolling pts with HFrEF, OMT and ARNI between November 2020 and June 2023. All pts underwent a baseline evaluation and a follow up visit after 1 year, then divided into 2 groups: those who started SGLT2i at baseline and those without SGLT2i (for clinical reasons or pts preference). Differences between means after 1 year were evaluated with Student's t test for two independent populations, while differences between proportions with 2-sample Z test. A level of significance α =0.05 was chosen.

Results. 82 pts in SGLT2i group and 88 in those without SGLT2i were included. Respectively, 34 and 29 pts (41% versus 33%, p=0.33) had DM, 47 and 49 (57% versus 55%, p=0.95) had CKD, with serum creatinine at baseline of 1.11 ± 0.3 and 1.5 ± 0.7 mg/dL (p=0.11). 64 and 59 pts (78% versus 67%, p=0.15) had an OMT (with a β-blocker, an MRA and ARNI), while 54% versus 42% (p=0.17) already had CRT. Mean LVEF at baseline was respectively 31% ± 5% and 30% ± 7% (p=0.45), while mean furosemide dose was 63 and 83 mg (p=0.15). The results of the inferential analysis between the two groups after one year of treatment are shown in Table 1.

Conclusions. After 1 year, SGLT2i significantly reduced daily furosemide dose, improved LVEF and renal function, with a non statistical significant trend toward an uptitration of ARNI dose and a reduction in WHF episodes. These data on a limited sample of HFrEF pts confirm the efficacy and safety of SGLT2i in real world, with an additive effect compared with ARNI alone.

	Not on SGLT2i (n = 88)	On SGLT2i (n = 82)	p-value	95% [Confidence Interval]
SBP (mmHg)	114.6 ± 15.8	116.0 ± 19.2	0.66	[-7.80 - 5.00]
DBP (mmHg)	70.94 ± 9.6	73.4 ± 8.9	0.16	[-5.90 - 1.02]
eGFR (mL/min/1,73 m²)	49.8 ± 24.9	57.1 ± 18.0	0.02	[-13.32 -1.10]
LVEF (%)	34.7 ± 9.6	40.9 ± 8.1	<0.001	[-8.90 -3.50]
sPAP (mmHg)	32.3 ± 10.1	33.3 ± 12.0	0.60	[-4.50 - 2.60]
Daily furosemide dose (mg)	94.6 ± 86.5	52.4 ± 42.8	<0.001	[21.70 - 62.70]
Highest dose of ARNI, n (%)	33 (37.5%)	37 (45%)	0.40	[-0.08 - 0.24]
WHF episodes, n (%)	19 (21.6%)	12 (14.6%)	0.33	[-0.20 - 0.06]

Table 1. Inferential Analysis between patients with and without SGLT2i therapy after 1 year of treatment.
SBP: Systolic Blood Pressure; DBP: Diastolic Blood Pressure; eGFR: extimated Glomerular Filtration Rate (calculated with CKD-EPI formula); LVEF: Left Ventricle Ejection Fraction, sPAP: systolic Pulmonary Artery Pressure; ARNI: Angiotensin Receptor and Neprilysin inhibitor; WHF: Worsening Heart Failure

A963: CLINICAL SURVEY: 10 YEARS OF CARDIAC TRANSPLANTATION IN SARDINIA

Martina Giusti (b), Marco Corda (a), Daniele Pasqualucci (a), Christian Cadeddu Dessalvi (b), Ferdinando Perra (b)

(a) ARNAS BROTZU; (b) AOU CAGLIARI

A 10-year clinical survey was conducted on patients undergoing heart transplants in Sardinia. A period of 10 years was taken into consideration, from 01 January 2012 to 31 December 2022. There were 52 patients who underwent heart transplantation. 65% of the population is made up of men and 35% of women with a global average age of 50 years. The main indication for transplantation was dilated cardiomyopathy (44%), followed by ischemic heart disease (25%) and hypertrophic cardiomyopathy (12%); the remaining 19% includes outcomes of myocarditis and fulminant myocarditis, non-compact myocardium, transplant reintervention for graft vasculopathy and restrictive cardiomyopathy. 15 patients underwent transplantation through a national emergency call (29%). Mortality was found to be higher in males (83% of total deaths), with a prevalence in the first 30 days after transplantation (55% of total deaths), with an increase of mortality of 28% within the following 6 months and a further 11% within one year from the operation. The pathology with the highest mortality is dilated cardiomyopathy (50% of total deaths) with a male component equal to 78%, followed by male patients suffering from end-stage hypertrophic cardiomyopathy (17%) and ischemic heart disease (11%).

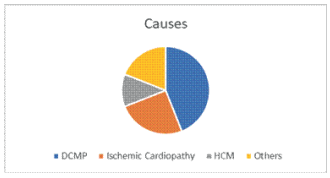

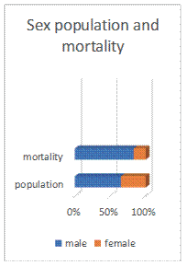

A964: EFFETTI DI UNA NUOVA MODALITÀ DI OTTIMIZZAZIONE ECOCARDIOGRAFICA DELLA TERAPIA DI RESINCRONIZZAZIONE CARDIACA IN UN PAZIENTE AFFETTO DA INSUFFICIENZA CARDIACA A FRAZIONE D'EIEZIONE RIDOTTA NON RESPONDER

Alessandro Guareschi (a), Lorenzo Fargione (a), Guido Pasero (a), Francesco Moda (a), Filippo Toriello (b), Massimo Saviano (b), Alberto Vincenzo Pollina (b), Federica Valli (b), Marco Vicenzi (b, c), Stefano Carugo (a, b)

(a) DEPARTMENT OF CLINICAL SCIENCES AND COMMUNITY HEALTH, UNIVERSITY OF MILAN, ITALY; (b) DEPARTMENT OF CARDIO-THORACIC-VASCULAR DISEASES, FOUNDATION IRCCS CA' GRANDA OSPEDALE MAGGIORE POLICLINICO, ITALY; (c) DYSPNEA LAB, DEPARTMENT OF CLINICAL SCIENCES AND COMMUNITY HEALTH, UNIVERSITY OF MILAN, ITALY

Un uomo di 56 anni con anamnesi di sindrome coronarica acuta a presentazione tardiva (da occlusione dell'arteria interventricolare anteriore prossimale trattata mediante angioplastica e posizionamento di stent medicato) condizionante insufficienza cardiaca a frazione d'eiezione ridotta (HFrEF) ad evoluzione ipocinetico-dilatativa, blocco atrio-ventricolare (BAV) completo parossistico e blocco di branca alterante veniva sottoposto a terapia di resincronizzazione cardiaca (CRT) mediante posizionamento di defibrillatore biventricolare. Per persistenza nei follow-up successivi di sintomatologia clinica (NYHA II-III) e severa disfunzione sistolica del ventricolo sinistro (32%) in terapia medica ottimizzata e adeguata stimolazione biventricolare (>97%) si configurava il quadro di pazien-

te non responder alla CRT. Il paziente veniva, pertanto, sottoposto ad ottimizzazione eco-guidata in real time dei parametri elettrici del dispositivo attraverso un'analisi di quale configurazione di frequenza cardiaca (FC) basale, massimale di trascinamento e degli intervalli A-V e V-V fornisse i migliori valori in termini di stroke volume e indice cardiaco derivati all'ecocardiografia e di rilasciamento ventricolare. Alla visita di follow-up a distanza di 6 mesi si osservava netto miglioramento soggettivo mediante valutazione della qualità di vita percepita al questionario KCCQ e decremento della classe funzionale NYHA. Dal punto di vista ecocardiografico si assisteva ad incremento della frazione d'eiezione del ventricolo sinistro (da 32% a 44%) e a reverse remodelling della camera con riduzione dei volumi telediastolico e telesistolico. Alla valutazione del doppler pulsato transmitralico, a parità di FC di stimolazione, si osservava comparsa dell'onda A con scomparsa del pattern di fusione, espressione di un più fisiologico pattern di riempimento ventricolare. Non esistono dati su un approccio standardizzato all'ottimizzazione eco-guidata dei settaggi dei dispositivi per la CRT. Nel caso riportato, mediante introduzione dell'adeguamento real-time non solo dei parametri di A-V e V-V delay, ma anche della FC basale e di trascinamento massimale, e della valutazione di indici indiretti ecocardiografici di funzione sistolica e diastolica, si è osservato un beneficio confermato dai dati clinici ed ecocardiografici. Questa nuova modalità di settaggio dei dispositivi per la CRT potrebbe essere un valido strumento nei pazienti non responder e futuri studi saranno necessari per confermare tale ipotesi.

A965: ACUTE RIGHT HEART FAILURE IN YOUNG WOMAN: A TWO HEADED MONSTER

Stefania Lo Giudice (a), Rossella Lombardo (a), Pasquale Crea (a), Gianluca Di Bella (a), Antonio Micari (a), Scipione Carerj (a)
(a) UNIT AND SCHOOL OF CARDIOLOGY, DEPARTMENT OF CLINICAL AND SPERIMENTAL MEDICINE, UNIVERSITY OF MESSINA, MESSINA, ITALY

M.C.G female patient, 43 years old, obese. She denies cardiovascular risk factors or cardiological history worthy of note. Suffering from atopic dermatitis, psoriasis and irritable bowel syndrome (diarrheal variant). Due to the onset of dyspnea for mild exertion for about ten days and severe peripheral edema, a cardiologist performs an examination including Electrocardiogram (ECG) and transthoracic echocardiogram (TTE). These exams show atrial fibrillation at average ventricular rate 180 bpm on and severe right ventricular dysfunction, which need to be invastigated. For this reason, the patient is admitted to our U.O.C Cardiology with UTIC. At the admittion, the patient presents dyspnoic at rest. At objective examination evidence of anasarchatic status, with an ECGrafic picture of atrial fibrillation with high ventricular response (170 bpm). Control ultrasound is performed, made difficult by the high acoustic impedance of the chest, which shows right ventricular dilatation, TAPSE 12 mm, moderate tricuspid insufficiency, biatrial dilatation, dilated and hypocollapsing inferior vena cava. The patient, in the suspicion of acute pulmonary embolism undergoes, CT angiography, with negative results;in addition the presence of right pleural effusion and marked increase in thyroid volume are documented. Heart rate control therapy is undertaken, without success, and anticoagulant therapy is started. The acute heart failure associated with atrial fibrillation with high ventricular response and the absence of therapeutic response of the patient lead to suspect a picture correlated with a thyrotoxic crisis. Therefore laboratory exams are performed to evaluate the pituitary-thyroid axis function and presence of markers of autoimmunity. The endocrinological examination integrated with thyroid ultrasound makes a diagnosis of multinodular Graves-Basedow disease; diagnosis subsequently confirmed by blood chemistry tests that showed a positive antibody titer (TGAb, TPOAb, TRAb). A therapy with Tapazole is started, with immediate clinical benefit of the patient. We perform a Transesophageal Ecocardiography (TEE) to investigate the presence of any additional secondary causes responsible for dilation and right ventricular dysfunction, recognizable to the control TTEs. The TEE excludes the presence of intra-atrial emboligenic masses and documents the presence of interatrial defect type ostium secundum. In consideration of clinical and instrumental improvement t (reduction of segmental kinetic abnormalities) thanks to therapy, the patient is discharged with an indication for evaluation for closure of the interatrial defect and cardiological and endocrinological follow-up. Acute heart failure should be treated with general measures and it's necessary to identify and correct the triggers. In our case, indeed, the correct differential diagnosis is essential because therapy with anti-thyroid agents and the correction of the interatrial defect lead to an improvement in the general clinical status and biventricular function.

A966: THE ROLE OF IVABRADINE IN CARDIAC MANAGEMENT OF DUCHENNE DILATED CARDIOMYOPATHY

Raffaele Quarta (a), Giuseppina De Benedittis (b), Giulia Della Rosa (d), Prisco Piscitelli (b), Nevio Dubbini (c), Alessandro Distante (c), Cesare De Gregorio (e)
(a) LOCAL HEALTH AUTHORITY ASL, BRINDISI,ITALY; (b) LOCAL HEALTH AUTHORITY ASL, LECCE, ITALY; (c) ISBEM, EURO MEDITERRANEAN SCIENTIFIC BIOMEDICAL INSTITUTE, BRINDISI, ITALY; (d) DEPARTMENT OF MOLECULAR MEDICINE, UNIVERSITY OF PAVIA, PAVIA, ITALY; (e) DEPARTMENT OF CLINICAL AND EXPERIMENTAL MEDICINE, UNIVERSITY OF MESSINA, MESSINA, ITALY

Objectives. Dilated cardiomyopathy (CMP) and heart failure are common complications in patients with Duchenne Muscular Dystrophy (DMD), older than 18 years. Pharmacological treatment with beta blockers improves cardiac function but the optimal dose is almost never reached due to frequent side effects, such as arterial hypotension, asthenia and bronchoconstriction. Recent evidence suggests the combination of the maximum tolerated dose of beta blocker with ivabradine, a drug that reduces the heart rate (HR) through the selective inhibition of the sodium if current in the pacemaker cells of the sinoatrial node, to attain such HR target. In this study we evaluated the clinical effects of this drug combination in DMD patients on a long-term follow-up.
Methods. In this prospective and observational study, the combination ivabradine + bisoprolol was administered and monitored through clinical, electrocardiographic and echocardiographic monitoring. Diagnosis of DMD was made according to current neurological guidelines, and CMP was diagnosed with Doppler-echocardiography. Target of therapy was to achieve and maintain an optimal HR between 60 and 70 b/min, avoiding interference on blood pressure (BP), over at least 12-month follow-up.
Results. Twelve patients mean age 24±5 (range 18-37) years, BSA 1.67±0.17 $m^{-2.7}$, were studied. At baseline, mean HR was 86±10 (range 72-102) bpm, mean systolic BP 102±8 mmHg and diastolic 71±9 mmHg. On echocardiographic examination, 6 patients (50%) had a dilated CMP, and another 6 had a hypokinetic form. Left ventricular ejection fraction was 42±7 (range 28-49)%. All patients reached a 18-month follow-up, undergoing clinical controls every 6 months. The average dose of ivabradine was 5 mg 1 tablet day and that of bisoprolol 1.25 mg/day. At the end of follow-up, there was a significant reduction in HR (66±8 bpm, p<0.005). The systolic and diastolic BP remained substantially stable (106±8 and 75±5 mmHg, respectively, p=NS), as the left ventricular ejection fraction did (42±10%). NT-proBNP levels showed a negative trend, although burdened by a wide variability (from 455±482 to 325±395 pcg/ml, p=NS). Each patient reported an improvement in his clinical condition (respiratory rate, reduction in dyspnea and palpitations).
Conclusions. Combination therapy with ivabradine and low-dose bisoprolol was effective in achieving the optimal HR target, and well tolerated in our patients with DMD cardiomyopathy, during an 18-month follow-up. Furthermore, we recognized a steady left ventricular function, and a slight reduction in the NT-proBNP level.

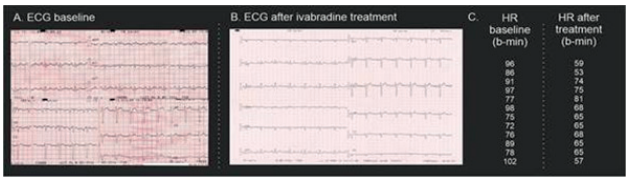

Figure 1. A. Representative example of ECG baseline. B. Representative example of ECG after ivabradine treatment.
C. Heart rate (HR) baseline and after ivabradine treatment.

A967: SIGNIFICATO PROGNOSTICO INCREMENTALE DEL BNP IN PAZIENTI CON PATTERN DI FLUSSO TRANSMITRALICO DI TIPO RESTRITTIVO DOPO OTTIMIZZAZIONE ETRAPEUTICA.

Soccorso Capomolla (a), Antonella Capomolla (a), Simone Lo Gatto (a), Josef Ranieli (a), Valentina Pannace (a), Federica Daddesso (a)
(a) DON MOTTOLA MEDICAL CENTER

Premessa. Numerosi studi hanno evidenziato l'utilità del Brain natriuretc peptide(BNP) e del deceleration Time(DT) nella prognosi dei pazienti con scompenso cardiaco cronico. Tuttavia rimane ancora poco definito il ruolo complementare di tali markers prognostici.
Scopo. Verificare in pazienti con pattern di flusso trasmitralico di tipo restrittivo se esiste associazione tra le variazioni di BNP e l'outcome a breve periodo in pazienti con scompenso cardiaco cronico.
Metodi. In 28 pazienti (58±11 aa) con SCC (FE 24±4%) secondario a cardiomiopatia dilatativa ischemica (16) o non ischemica (12) e pattern di flusso transmitralico restrittivo dopo ottimizzazione terapeutica, in condizioni basali,ed in predimissione è stato eseguito il dosaggio di BNP. Le variazioni di BNP sono state espresse come % dei valori di ingresso. Un variazione del 30% (mediana) di BNP alla dimissione è stato utilizzato categorizzare la popolazione. Durante un follow-up medio di 91± 61 gg sono stati considerati come eventi clinici maggiori le reospedalizzazioni e la morte cardiaca.
Risultati. In 24/28(86%) è stata praticata terapia endovenosa con diuretici e nitroprussiato. In tutti i pazienti è stata eseguita ottimizzazione della terapia orale (vedi tab1). 18/28(64%) presentavano una riduzione>30% del BNP basale. Durante il follow-up 10/28(37%) pazienti hanno subito un reospedalizzazione. Nel sottogruppo con una riduzione>30% del BNP basale gli eventi (4/18, 22%)sono stati significativamente minori rispetto al gruppo con una riduzione <30% del BNP basale (6/10, 60%) (c^2 4 p<.04).
Conclusioni. Le variazioni di BNP in pazienti con pattern di flusso trasmitralico di tipo restrittivo dopo unloading terapeutico sono significamen-

te associate all'outcome clinico a breve termine in pazienti con SCC. Tale evidenza può acquisire un ruolo nella definizione nell'iter decisionale e del follow-up del paziente con SCC.

	Ingresso	Dimissione	p
BNP	1230 ± 1035	877± 1169	0.03
ACE-Long-ac.(mg/die)	10 ± 6	11 ± 7	ns
ACE – Short-T.(mg/die)	93±46	115 ± 48	.02
Beta-bloccanti.(mg/die)	12±13	18±11	0.02
Nitrati.(mg/die)	40±48	68±58	0.004
Digitale.(mg/die)	.05±.06	.04±.6	ns
Diuretici.(mg/die)	81±68	34±62	ns
Andialdost..(mg/die)	45±40	34±35	ns

A968: TRATTAMENTO FARMACOLOGICO DELLO SCOMPENSO CARDIACO: LINEE GUIDA E MONDO REALE

Alessia Ciarlitto Salvadori (b), Cristian Parisi (a), Francesco Cicogna (a), Francesca Fanisio (a), Emanuele Canali (a), Federica Toto (a), Marco Serani (a), Claudia Tota (a), Leonardo Calo´ (a), Francesco Barilla´ (b)
(a) POLICLINICO CASILINO; (b) POLICLINICO UNIVERSITARIO TOR VERGATA

Introduzione. Lo scompenso cardiaco rappresenta una delle principali cause globali di mortalità e morbilità, con una prevalenza nel mondo dell'1-3% della popolazione generale, che supera anche il 10% in specifiche aree geografiche e fasce di popolazione. Nonostante gli innegabili progressi svolti, la prognosi dei pz che ne sono affetti rimane insoddisfacente, con un tasso di mortalità a 5 anni dalla prima diagnosi tra il 50 ed il 75%. Inoltre, si tratta della diagnosi che si associa al maggior numero di riospedalizzazione ad un mese da un precedente ricovero, con impatto estremamente severo su aspettativa e qualità della vita dei pz, nonché sui bilanci dei sistemi sanitari per i quali, nel mondo, tale malattia rappresenta una delle principali voci di spesa. Pertanto, la ricerca sullo scompenso cardiaco è continuamente in atto e ciò si traduce nell'aggiornamento costante della gestione dei pz affetti, dalla diagnosi al trattamento.
Obiettivo dello studio. Lo scopo di questo lavoro è presentare i primi risultati di uno studio osservazionale retrospettivo in corso sui pz con scompenso cardiaco che afferiscono al nostro Centro ad alto volume per prima diagnosi o riacutizzazione di malattia, volto a fornire un'immagine "real world" dei dati di adeguatezza prescrittiva ed aderenza terapeutica successivamente all'uscita delle ultime linee guida europee sullo scompenso cardiaco (ESC 2021).
Materiali e metodi. Abbiamo selezionato 30 pz ricoverati in seguito all'uscita delle ultime LLGG ESC e dimessi con diagnosi di scompenso cardiaco; 2/3 e 1/3 provenienti rispettivamente dai reparti di Cardiologia e di Medicina Interna. Abbiamo quindi creato un database contenente i dati tra cui la categoria di scompenso cardiaco (HFrEF, HFpEF), le comorbidità, i markers ematochimici, la terapia che i pazienti assumevano all'ingresso e quella con cui sono stati dimessi, con particolare attenzione alle categorie farmacologiche in Classe I secondo LL GG ESC 2021.
Risultati. Dei 30 pz analizzati il 37% era affetto da una forma di tipo HFpEF; l'82% di questi assumeva già una terapia diuretica domiciliare ed il 100% dei pz è stato dimesso con terapia diuretica. Riguardo i pz affetti da HFrEF, nessuno assumeva una terapia medica ottimale secondo LLGG al momento del ricovero. Nello specifico, il 74% assumeva terapia BB, il 42% ACEi/ARNI, il 26% MRA, il 10% SGLT2i. Degli stessi pz, al termine del ricovero, il 79% veniva dimesso con terapia BB, il 42% con ACEi/ARNI, il 79% con MRA ed il 42% con SGLT2i. Dei pz affetti da HFrEF solo il 21% è stato dimesso dal ricovero con terapia medica ottimale.
Conclusioni e prospettive: I nostri primi risultati, in linea con la letteratura, evidenziano come i pz con necessità di ricovero per scompenso cardiaco siano per lo più scoperti da una terapia medica ottimale, nonostante le indicazioni delle linee guida e quelle delle più recenti evidenze scientifiche. Inoltre, solo una parte di questi pz riceve tale terapia alla dimissione. Tali dati suggeriscono la necessità di una sensibilizzazione ancora maggiore tanto dei pz quanto dei medici prescrittori, per poter sfruttare a pieno il potere delle armi farmacologiche in nostro possesso. In quest'ottica, presso il nostro Centro stiamo iniziando un'analisi prospettica basata sullo svolgimento di periodici incontri tra Cardiologi ed Internisti sul tema della sensibilizzazione, volti al miglioramento dell'utilizzo dello Standard of Care con particolare focus sui nuovi approcci terapeutici promossi dalle ultime linee guida sull'insufficienza cardiaca, che si allontanano dallo storico approccio dell'implementazione a favore della prescrizione simultanea delle principali classi di farmaci.

A969: LA TERAPIA CCM IN PAZIENTI CON SCOMPENSO CARDIACO CON FE LIEVEMENTE RIDOTTA: INIZIALE ESPERIENZA DI UN SINGOLO CENTRO

Giovanni Russo (a), Mafalda Esposito (a), Francesco Sessa (a), Salvatore Madonna (a), Fabio Minicucci (a)
(a) OSPEDALE SAN LEONARDO DI CASTELLAMMARE DI STABIA

Introduzione. La terapia di modulazione della contrattilità cardiaca (CCM) è indirizzata al trattamento di pazienti con insufficienza cardiaca da moderata a grave che presentano sintomi nonostante una terapia medica ottimizzata (OMT) dimostrando un miglioramento della qualità della vita nonché della tolleranza all'esercizio fisico. Dati di letteratura rivelano che la terapia CCM ha effetti più evidenti nella popolazione di pazienti con scompenso cardiaco sistolico cronico con FE lievemente ridotta (HFmEF).
Metodi. Nel nostro centro sono stati impiantati 3 dispositivi CCM in 3 pazienti di sesso femminile con HFmEF nel periodo da marzo 2022 a gennaio 2023, età media di 75 anni, FE media di 42%, affette da cardiopatia dilatativa primitiva, QRS non largo (valore medio 105 ms) con episodi di riospedalizzazione per scompenso nonostante OMT. Tutte le pazienti erano in FA cronica trattate con dosi di beta-bloccante tollerabili per mantenere la frequenza cardiaca media sotto ai 110 bpm (limite max per la funzionalità della terapia CCM). Nessuna delle pazienti era portatrice di altro dispositivo.
Risultati. La prima paziente ha raggiunto un FU di 17 mesi, la terza paziente un FU di 6 mesi. Ad oggi, in tutte le pazienti rispetto al basale si è notato un aumento della FE ed in 2 di esse un miglioramento della QoL misurata col questionario KCCQ; nessun ricovero per scompenso cardiaco dopo l'impianto di device (vedi tabella). Una sola paziente ha migliorato la classe NYHA dal preimpianto.
Conclusioni. Nella nostra iniziale esperienza, la terapia CCM si è mostrata efficace già nel breve termine, in termini di miglioramento della FE e riduzione delle riospedalizzazioni per scompenso cardiaco, confermando quanto evidenziato in letteratura. Inoltre, agendo precocemente nel trattamento di pazienti con HFmEF si potrebbe evitare un peggioramento della FE e quindi ottenere una riduzione dell'impianto di dispositivi ICD.

parametri	Basale			3 Mesi			6 Mesi			9 mesi			12 mesi		
	Paz 1	Paz 2	Paz 3	Paz 1	Paz 2	Paz 3	Paz 1	Paz 2	Paz 3	Paz 1	Paz 2	Paz 3	Paz 1	Paz 2	Paz 3
FE	43	42	42	45	45	46	50	45		n.d	55	no FU	50	no FU	No FU
KCCQ	30	19,1	50	60,9	41,8	37,3	80	23,6		n.d	n.d	no FU	60,9	no FU	No FU
NYHA	[illegible]	[illegible]	[illegible]	[illegible]	[illegible]	[illegible]	I	[illegible]		n.d	[illegible]	no FU	[illegible]	no FU	No FU

A970: THE IMPACT OF HEART FAILURE ON QUALITY OF LIFE: A MIXED METHOD STUDY PRELIMINARY RESULTS

Myriam Letizia Li Vigni (a)
(a) UNIVERSITÀ DEGLI STUDI DI PISA

Introduction. More than 64,000 individuals are affected by heart failure each year, resulting in hospital readmissions and mortality, making it a significant concern (Savarese et al., 2023). Although efforts have been made, 20% of HF patients do not survive beyond the first year after diagnosis, while 50% of people in their 80s have a life expectancy of 5 years (Dharmarajan & Ricco, 2017). However, the 5-year survival rate for those who undertake follow-up has increased by 20% (Braunwald, 2013). Worldwide, HF affects 1-3% of the general population in developed countries (Seferović et al., 2019). In Europe, there are 15 million people with HF (Savarese et al., 2023), while in Italy, 2% of the population is suffering from HF, with a mortality rate of around 20% and a 10% increase in patients over 70 years of age (Heidenreich et al., 2022). Patients with HF often experience reduced quality of life (QoL), with negative effects on their psychosocial health (Lupón et al., 2013). QoL has a prognostic value for three-year survival (Hoekstra et al., 2013), indeed patients with low QoL tend to have more adverse events such as hospital readmissions and mortality (Ly et al., 2023).Therefore, assessing QoL over time, also using new technologies for home monitoring, is crucial. Telemedicine, including telemonitoring, can have a positive and lasting impact on increasing QoL (Morken et al., 2022).
Methods. This mixed-method study inquire into investigate the perception of QoL in geriatric patients with heart failure, in relation to the different degree of HF. The participants in our study were patients with HFrEF and HFpEF receiving outpatient care at the HF Lab unit of a tertiary hospital. The study was divided into two phases: a quantitative and a qualitative survey. The KCCQ 23 scale was used to measure self-reported quality of life (QoL) during an in-person meeting and again via phone follow-up at 6 and/or 12 months. During the qualitative phase, semi-structured interviews were carried out via video calls.
Results and Discussion. The study involves 478 patients with heart failure (HF) with a mean age of 75.33 years. The majority of participants were male (58.8%), while the remaining 41.2% were female, NYHA severity class II is the most common (49.8%), and the majority of HF cases belong to the HFpEF category (54.8%). During the study period, 26 deaths occurred among the patients. Women, who are less represented, seem to experience a lower overall QoL than men in heart failure, as has also been revealed in previous studies (Lupon, 2013). From the information gathered in the survey and after transcription, reading and re-reading of the interviews, 6 emerging themes were identified that encapsulated the perception of quality of life reported by patients with HF including future prospects, awareness of the disease and their own health status, sociality, emotional state, self-care and functionality. Women, who often perform the role of caregivers, seem to experience a lower overall QoL than men in heart failure, as has also been found in previous studies. Iin addition, it was seen that deceased patients who received follow-up reported significantly worse QoL scores than those who did not.

A971: EARLY SURVIVAL AFTER HEART TRANSPLANT ACCORDING TO SEX: A SINGLE CENTER EXPERIENCE

Martina Giusti (b), Marco Corda (a), Daniele Pasqualucci (a), Christian Cadeddu Dessalvi (b), Ferdinando Perra (b)
(a) ARNAS BROTZU; (b) AOU CAGLIARI

We performed an eleven years single-center descriptive analysis of heart transplant recipients and estimated 1 year overall freedom from posttransplant death stratified by sex, from 01 January 2012 to 31 December 2022, in ARNAS Brotzu Cagliari, Sardinia. The study cohort comprised 52 heart transplant recipients (65% men, 35% women). Compared with male recipients, female recipients were more likely younger (46.6 years mean average vs 51.55) and had a different distribution of heart failure etiology, with a higher prevalence of dilated (72% vs 29.5%), hypertrophic (10% vs 14.7%) and ischemic cardiomyopathy (5% vs 29.5%). Two male patients underwent heart transplantation after LVAD implantation. 1 - year overall freedom from post-transplant death was 66% in male sex and 84% in female sex. Of note, most of the deaths in the first year follow up occurred in the first 30 days after heart transplant (75% in men and 33% in women). Mortality etiologies according to sex needs further investigations, because of the heterogeneity of the study sample.

A972: SEX DIFFERENCES IN HEART FAILURE: WHAT DO WE KNOW?

Allegra Arata (a), Fabrizio Ricci (a), Mohammed Y. Khanji (b), Cesare Mantini (a), Francesco Angeli (c), Roberta Aquilani (d), Angela Di Baldassarre (e), Giulia Renda (a), Anna Vittoria Mattioli (f), Savina Nodari (g), Sabina Gallina (a)
(a) DEPARTMENT OF NEUROSCIENCE, IMAGING AND CLINICAL SCIENCES, G. D'ANNUNZIO UNIVERSITY OF CHIETI - PESCARA; (b) WILLIAM HARVEY RESEARCH INSTITUTE, NIHR BARTS BIOMEDICAL RESEARCH CENTER, QUEEN MARY UNIVERSITY, LONDON; (c) DEPARTMENT OF MEDICAL AND SURGICAL SCIENCES, UNIVERSITY OF BOLOGNA; (d) CARDIAC SURGERY INTENSIVE CARE UNIT, HEART DEPARTMENT, SS ANNUNZIATA UNIVERSITY HOSPITAL, CHIETI; (e) DEPARTMENT OF MEDICINE AND AGING SCIENCES, AND REPROGRAMMING AND CELL DIFFERENTIATION LAB, CENTER FOR ADVANCED STUDIES AND TECHNOLOGIES (CAST), G. D'ANNUNZIO UNIVERSITY CHIETI-PESCARA; (f) SURGICAL,MEDICAL AND DENTAL DEPARTMENT OF MORPHOLOGICAL SCIENCES RELATED TO TRANSPLANT, ONCOLOGY AND REGENERATIVE MEDICINE, UNIVERSITY OF MODENA AND REGGIO EMILIA; (g) DEPARTMENT OF CARDIOLOGY, UNIVERSITY OF BRESCIA AND ASST "SPEDALI CIVILI" HOSPITAL, BRESCIA

Heart failure (HF) remains an important global health issue, substantially contributing to morbidity and mortality. According to epidemiological studies, men and women face nearly equivalent lifetime risks for HF. However, their experiences diverge significantly when it comes to HF subtypes: men tend to develop HF with reduced ejection fraction more frequently, whereas women are predominantly affected by HF with preserved ejection fraction. This divergence underlines the presence of numerous sex-based disparities across various facets of HF, encompassing aspects such as risk factors, clinical presentation, underlying pathophysiology, and response to therapy. Despite these apparent discrepancies, our understanding of them is far from complete, with key knowledge gaps still existing. Current guidelines from various professional societies acknowledge the existence of sex-based differences in HF management, yet they are lacking in providing explicit, actionable recommendations tailored to these differences. In this comprehensive review, we delve deeper into these sex-specific differences within the context of HF, critically examining associated definitions, risk factors, and therapeutic strategies. We provide a specific emphasis on aspects exclusive to women, such as the impact of pregnancy-induced hypertension and premature menopause, as these unique factors warrant greater attention in the broader HF discussion. Additionally, we aim to clarify ongoing controversies and knowledge gaps pertaining to the pharmacological treatment of HF and the sex-specific indications for cardiac implantable electronic devices. By shining a light on these issues, we hope to stimulate a more nuanced understanding and promote the development of more sex-responsive approaches in HF management.

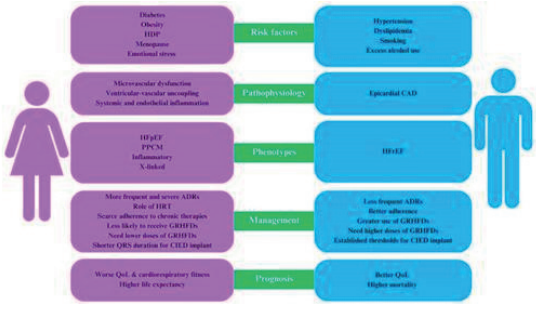

Figure 1. Clinical profiles of HFpEF in females vs. males. ADRs = adverse drug reactions; CAD = coronary artery disease; CIED = cardiac implantable electronic device; GRHFDs = guideline-recommended heart failure drugs; HFpEF = heart failure with preserved ejection fraction; HFrEF = heart failure with reduced ejection fraction; HPDs = hypertensive disorders; HTR = hormone replacement therapy; PPCM = peripartum cardiomyopathy; QoL = quality of life.

A973: TARGETING SLEEP-DISORDERED BREATHING IN HEART FAILURE: ROLE OF SGLT2 INHIBITORS

Fulvio Cacciapuoti (a), Ciro Mauro (a), Antonio D´onofrio (b), Valentina Capone (a), Luca Gaetano Tarquinio (d), Federico Cacciapuoti (c)
(a) DEPARTMENT OF CARDIOLOGY "A. CARDARELLI" HOSPITAL - NAPLES, ITALY; (b) DEPARTMENT OF CARDIOLOGY "V. MONALDI" HOSPITAL - NAPLES, ITALY; (c) CHAIR OF INTERNAL MEDICINE "L. VANVITELLI" UNIVERSITY - NAPLES, ITALY; (d) POSTGRADUATE SCHOOL OF EMERGENCY MEDICINE AND CRITICAL CARE "L. VANVITELLI" UNIVERSITY - NAPLES, ITALY

Sleep-disordered breathing (SDB) significantly impacts cardiovascular risk, contributing to conditions such as hypertension, arrhythmias, ischemic heart disease, and left ventricular remodeling, which may progress to heart failure. Obstructive sleep apnea syndrome (OSA), characterized by intermittent breathing cessation during sleep, is more prevalent in heart failure patients, especially those who are obese and hypertensive, further exacerbating left ventricular dysfunction. Recognizing and treating these sleep breathing disorders early is crucial to reducing cardiovascular morbidity and mortality. Sleep apnea and heart failure share similar clinical manifestations and neuro-hormonal characteristics, contributing to the development and progression of heart failure, including both preserved and reduced ejection fraction forms. Nocturnal continuous positive airway pressure (CPAP) treatment has shown cardiovascular benefits in heart failure patients with OSA, but its efficacy is limited in central apnea (CSA). Angiotensin-neprilysin receptor inhibitors (ARNIs) have demonstrated a favorable impact on patients with heart failure and sleep apnea, reducing the apnea-hypopnea index (AHI). The pathophysiology of OSA involves hypoxia-reoxygenation cycles and autonomic nervous system dysfunction, leading to a pro-inflammatory and pro-fibrotic state, left atrial dilatation, and reduced left ventricular compliance. These changes contribute to the onset and progression of heart failure. In advanced heart failure with reduced ejection fraction, CSA may occur due to congestion of the pulmonary circulation and subsequent hyperventilation and hypocapnia. Sodium-glucose co-transporter inhibitors (SGLT2i) have emerged as a new therapeutic approach in heart failure treatment. Studies show that SGLT2i can improve AHI in diabetic patients with OSA, reduce cardiovascular and renal complications, and lead to weight loss and decreased preload. The reduction in visceral fat and pro-inflammatory adipokines may further benefit patients with heart failure and sleep apnea. SGLT2i's natriuretic effect reduces blood pressure and volume overload without causing hypotension or dehydration. In conclusion, the close relationship between sleep apnea and heart failure demands a comprehensive approach to managing these conditions. Incorporating SGLT2i into heart failure therapy, particularly in patients with preserved ejection fraction and obesity, could positively influence AHI and desaturation indices, potentially reducing the incidence of sleep apnea and improving heart failure prognosis. Further research is needed to fully understand the cardioprotective mechanisms of SGLT2i in heart failure patients with sleep apnea.

A974: UN SINGOLARE CASO DI SEVERA DISFUNZIONE VENTRICOLARE: "BREAKING BAD" ALLA MILANESE

Luca Donisi (a, b), Alessandro Guareschi (a, b), Guido Pasero (a, b), Margherita Calcagnino (b), Elisa Gherbesi (b), Andrea Garascia (c), Marco Vicenzi (a, b), Stefano Carugo (a, b)
(a) DEPARTMENT OF CLINICAL SCIENCES AND COMMUNITY HEALTH, UNIVERSITY OF MILAN; (b) DEPARTMENT OF CARDIO-THORACIC-VASCULAR DISEASES, IRCCS CA' GRANDA OSPEDALE MAGGIORE POLICLINICO; (c) "DE GASPERIS" CARDIO CENTER, NIGUARDA HOSPITAL, ASST GRANDE OSPEDALE METROPOLITANO NIGUARFA

In un uomo di 39 anni di origini filippine e un'anamnesi dimostratasi successivamente incompleta con nuovo riscontro di severa cardiopatia ipocinetica dilatativa veniva indagata l'eziologia mediante l'esecuzione di risonanza magnetica cardiaca, PET-TC, angio-TC coronarica, angiografia coronarica e biopsia endomiocardica con riscontro di verosimile methamphetamine-associated cardiomyopathy in overlap con un quadro di coronaropatia trivasale critica.

TELECARDIOLOGIA ED E-HEALTH

A975: EFFECTS OF VIRTUAL REALITY ON REHABILITATION IN PATIENTS WITH HEART FAILURE (VIRTUAL-HF): A PROTOCOL FOR A RANDOMIZED CONTROLLED TRIAL

Valentina Micheluzzi (a, b), Gavino Casu (a, f), Giuseppe Damiano Sanna (a), Paolo Iovino (c), Gabriele Caggianelli (d), Ercole Vellone (b, e)
(a) CLINICAL AND INTERVENTIONAL CARDIOLOGY, UNIVERSITY HOSPITAL, SASSARI, ITALY; (b) DEPARTMENT OF BIOMEDICINE AND PREVENTION, UNIVERSITY OF ROME TOR VERGATA, ROME, ITALY.; (c) HEALTH SCIENCES DEPARTMENT, UNIVERSITY OF FLORENCE, FLORENCE, ITALY; (d) SAN GIOVANNI ADDOLORATA HOSPITAL, ROME, ITALY; (e) DEPARTMENT OF NURSING AND OBSTRETRICS, WROCLAW MEDICAL UNIVERSITY, WROCLAW, POLAND; (f) DEPARTMENT OF MEDICINE, SURGERY AND PHARMACY, UNIVERSITY OF SASSARI, SASSARI, ITALY

Introduction. Patients with heart failure (HF) suffer from a variety of physical and psychological symptoms that contribute to poor quality of life, high rates of rehospitalization, increased morbidity and mortality and high healthcare costs. To improve symptoms and reduce poor outcomes related to HF progression, international guidelines recommend cardiac rehabilitation, which is considered one of the cornerstones in the treatment of patients with HF, particularly those with a reduced ejection fraction. Unfortunately, patient access and adherence to rehabilitation programs remain suboptimal, with dropouts ranging from 15.4 to 63.3%. An innovative and promising intervention that could improve adherence to rehabilitation in patients with HF is virtual reality. Although virtual reality appears to be effective in improving rehabilitation adherence, there is no evidence of effectiveness in the setting of cardiac rehabilitation and HF-related clinical outcomes. The aim of this trial is to evaluate the effectiveness of virtual reality in improving overall adherence to a cardiac rehabilitation program (primary outcome), functional capacity, effort perception, heart rate, oxygen saturation, blood pressure, angina, cardiopulmonary exercise testing (CPET) parameters (i.e., maximal oxygen uptake - VO2max, VE/VCO2 slope, oxygen pulse - VO2/HR), blood values (NT-proBNP), quality of life and HF-related rehospitalization (secondary outcomes) in patients with HF.
Methods. This is the study protocol of a longitudinal, pre-post-test randomized controlled trial. A calculated sample of 80 patients with HF referred to cardiac rehabilitation will be enrolled in an university hospital in Italy and allocated in two parallel balanced groups (1:1). Patients will individually undergo eight rehabilitation sessions lasting 30 minutes each, twice a week. The study protocol will include for both groups: evaluation of adherence to cardiac rehabilitation measured as the number of sessions performed, compared to the scheduled sessions; evaluation of clinical outcomes such as functional capacity through the six-minute walking test, perceived exertion through the Borg scale, vital signs (i.e. heart rate, blood pressure and oxygen saturation) through a digital monitor, severity of angina through the Canadian Cardiovascular Society grading of angina, VO2max, VE/VCO2 slope and VO2/HR through CPET, values of NT-proBNP through blood tests, quality of life through the Minnesota Living with Heart Failure Questionnaire (MLHFQ) and HF-related rehospitalization rates. Outcome measurements will be collected at baseline and at the end of the fourth and eighth sessions. The experimental group will undergo the rehabilitation program with immersive virtual reality using a PICO 4® viewer and TREADMILL XR® app. This equipment, characterized by high-definition video and audio, will allow participants to be immersed in natural environments. An app with natural content was chosen because immersion in such environments can activate a powerful distraction with an almost total refocus of attention that could stimulate motivation, improve adherence to cardiac rehabilitation and, consequently, improve clinical cardiac outcomes. The control group will undergo standard cardiac rehabilitation.
Results. A significant improvement in primary and secondary outcomes is expected in patients in the intervention group, confirming the underlying hypothesis of the study. Virtual reality could be an innovative, safe, easy and low-cost new digital health intervention in patients with HF.
Conclusions. This randomized trial could provide evidence of the usefulness of virtual reality in the setting of cardiac rehabilitation in HF patients.

A976: BRUGADA SYNDROME: ARRHYTHMIC RISK STRATIFICATION IN ASYMPTOMATIC PATIENT BY REMOTE MONITORING

Maria Cristina Carella (a), Vincenzo Ezio Santobuono (a), Marco Maria Dicorato (a), Eugenio Carulli (b), Paolo Basile (a), Nicola Bozza (b), Michele Luca Dadamo (a), Riccardo Memeo (a), Marco Matteo Ciccone (a), Andrea Igoren Guaricci (a), Cinzia Forleo (a)
(a) U.O.C. CARDIOLOGIA UNIVERSITARIA - A.O.U.C. POLICLINICO DI BARI; (b) U.O.C. CARDIOLOGIA E UTIC - P.O. MADONNA DELLE GRAZIE - MATERA

Background. In accordance with the recent Guidelines (LGs) on the Prevention of Sudden Cardiac Death (SCD), Brugada Syndrome (SBr) can be diagnosed in the presence of spontaneous type 1 pattern, independent of symptoms, whereas a sodium channel blocker drug-induced type 1 pattern requires the presence of other clinical features, such as documented episodes of polymorphic ventricular tachycardia (VT), ventricular fibrillation (VF), arrhythmic syncope, or relevant family history. In patients with SBr and unexplained syncope, loop-recorder implantation is indicated in class IIa. Although the data regarding the importance of telemedicine and remote monitoring also applied to the implantable loop recorders (ILR) and intracardiac monitors (ICM) devices are limited, however in clinical practice it emerges that they are an indispensable tool in the patient's diagnostic-therapeutic path. The heart rhythm 24/24 hours observation allows clinicians to act promptly in young subjects often asymptomatic but at potentially high arrhythmic risk.
Case presentation. Here we report a case of a previous health 18-year-old boy, with paternal familiarity for syncopal episodes and ischemic heart disease, came to our observation after cardiologic examination performed for competitive activity. On ECG, an rSr' appearance in V1 was documented. Vital parameters, objective examination, and blood chemistry tests were normal. In contrast, the cycle-ergometer stress test showed an accentuation of the rSr' aspect during exercise, with regression in the recovery phase. Echocardiogram and CMR documented normal biventricular function. The 24-hour dynamic ECG according to Holter showed no notable changes. When tested for Flecainide, the patient was positive for induced Brugada type I pattern. In the light of the murky family history of the boy, in accordance with the LGs and pending genetic results, although asymptomatic for heart palpitations and syncope, we decided to implant a loop recorder with remote monitoring system. During monitoring a few months later, a 5-hour episode of paroxysmal atrial fibrillation associated with sustained PVT was found. Immediately contacted, the patient denied loss of consciousness, angor or dyspnea and reported heart palpitation associated with feeling of anxiety lasting several hours, spontaneously regressing after intense emotional stress. Admitted to our department, a spontaneous Brugada type 1 pattern was detected during the hospitalization. The patient was therefore undergoing implantation of a subcutaneous cardioverter-defibrillator. To date, the patient remains under remote monitoring and has regular follow-ups at our center.
Discussion and Conclusions. Our case demonstrates how continuous ECG monitoring by implanting injectable loop-recorders equipped with current remote monitoring systems is now an essential tool in the hands of the clinician, enabling accurate assessment of arrhythmic risk and guiding therapeutic decisions. Telemedicine is now an integral part of clinical practice and is destined to play an increasingly important role. To the best of our current knowledge, this is the first case of sustained PVT finding upon remote monitoring of an implanted loop recorder in a young subject with induced Brugada type 1 pattern.

A977: SMARTWATCH DETECTS VENTRICULAR TACHYARRHYTHMIAS IN HEART FAILURE PATIENTS

Giuseppe Scalzi (a), Letizia Rosa Romano (a), Biagio Malizia (a), Miriam Festa (a), Ciro Indolfi (a), Antonio Curcio (a)
(a) DIVISION OF CARDIOLOGY, DEPARTMENT OF MEDICAL AND SURGICAL SCIENCES, MAGNA GRAECIA UNIVERSITY, CATANZARO, ITALY

Background. Among patients with heart failure (HF), especially in those with milder symptoms, death can occur suddenly and unexpectedly. The main causes are electrical disturbances such as ventricular tachyarrhythmias (VT). Premature ventricular contractions (PVCs) are related with a major susceptibility of more dangerous arrhythmias, especially when heart disease is associated. In some patients, PVC are triggered by the same mechanisms that give rise to life-threatening arrhythmias and occurrence of VT has a dramatic impact on prognosis of HF patients.
Aims. Wearable devices, including smartwatch (SW), are particularly popular to enhance health monitoring and care delivery and might provide real-time informations in patients at risk of VT. We therefore evaluated if SW detection of QRS main parameters such as interval width and voltage could reproducibly detect VT and/or PVCs in HF patients in comparison to standard electrocardiogram (ECG).
Methods. From November 2022 to May 2023 patients with HF diagnosis (N=100) underwent continuous ECG recordings through telemetry and SW during hospital admission. Statistical analysis was performed with SPSS, correlation of the ECG results obtained with both methods was addressed using Pearson's analysis for normally distributed data and Sperman's analysis for nonparametric data. Bland-Altman method was used for reliability between telemetry and SW ECG measurements.
Results. In overall population mean left ventricular ejection fraction was 45.92±12.12%; mean pro-BNP was 2825.85±5823 pg/ml. Using the SW and the ECG data, QRS width and voltage correlation coefficients were 0.990 ($p<0.001$) and 0.974 ($p<0.001$), respectively. Concordance was found between the two assessments for QRS width (bias, 0.20; SD 3.0; lower limit, –5.68; upper limit, 6.08), and voltage (bias, -0.029; SD, 0.611; lower limit, –1.227; upper limit, 1.169). Moreover, we found correlation coefficients of 0.964 ($p<0.001$) and 0.970 ($p<0.001$), respectively, for PVCs width and PVCs voltage using SW and telemetry or other ECG report. Similarly, both techniques showed positive concordance for PVCs width (bias, 0.368; SD, 2.65; lower limit, -4.83; upper limit, 5.56) and PVCs voltage (bias, 0.54; SD, 1.25; lower limit, -1.91; and upper limit, 2.996).
Conclusions. VT identification by the SW is reproducible compared with standard ECG. These results could be of great interest considering the currently wide diffusion of smartwatches. Therefore, remote monitoring through SW might be considered in HF patients upon discharge.

A978: THE IMPACT OF ECG AND HOLTER-ECG REPORTING IN TELEMEDICINE TO REDUCE MORTALITY AND MORBIDITY

Assunta Di Costanzo (a), Giovanni Canino (a), Antonio Curcio (a), Ciro Indolfi (a)
(a) DIVISION OF CARDIOLOGY, UNIVERSITY MAGNA GRAECIA, CATANZARO, ITALY

Background. Difficulty in accessing care is a current problem in the health care system, especially in the field of cardiovascular disease, which is the leading cause of death in industrialized countries to date (32% of all deaths). Very long wait times, an overburdened system and rapid advances in digital technology have brought telemedicine service to the forefront of health care. The ability to perform a simple 12-lead electrocardiogram (ECG) or continuous heart rhythm monitoring (24-hour-Holter-ECG) with a telemedicine reporting system could support the health care system, offer rapid service to patients, and make the job easier for cardiologists.

Objectives. In this study, we evaluated the number of pathological examinations found in patients who had requested a 12-lead ECG or 24-hour Holter-ECG using a telemedicine service (Cardiodigital) offered by the service pharmacy.
Methods. Data were collected retrospectively from May 2021 to September 2023. The devices and platform used in the study complied with standards in telemedicine described by the Italian Society of Cardiology (SIC) consensus document. Diagnostic examinations were performed in pharmacies equipped with the platform and uploaded to the database for reporting. Telemedicine reporting was performed by cardiologists. In addition to the reporting, the specialist had the option to indicate the examination as normal, abnormal, or borderline.
Results. A total of 2890 examinations were performed. The total number of ECGs was 1409; 14 were excluded because they were judged not reportable due to artifacts in the trace. Of the 1395 ECGs included in the evaluation, most of the tracings were labeled as normal (78.5%, n=1095), 14.5% (n=202) were labeled as borderline and required in-depth clinical evaluation by specialist visit, and while 7.0% (n=98) were referred as abnormal and required emergency admission. The total number of 24h Holter-ECGs was 1482; 25 were excluded because they were not reportable. Of the total of 1457 examinations, 59.6% (n=869) were reported and labeled as normal, about one-third were described as abnormal (30.9%, n=450), and 9.5% (n=138) were defined as borderline.
Conclusions. The telemedicine service, provided through the service pharmacy with adherence to equipment standards and reporting quality, was useful in ECG reporting 98 times (7% of cases) and for 24-hours-Holter-ECG 450 times (30.9% of cases). We believe that the provision of telemedicine health care services through remote reporting of instrumental examinations can be a valuable support to the health care system to increase the diagnostic supply on the territory and offer a quick and accessible service to patients, especially in the field of cardiovascular diseases.

A979: MACHINE LEARNING APPROACH FOR PREDICTION OF OUTCOMES IN PATIENTS WITH ATRIAL FIBRILLATION ON ANTICOAGULANT THERAPY

Andrea Bernardini (a, d), Luca Bindini (b), Martina Berteotti (d), Emilia Antonucci (c), Sophie Testa (e), Gualtiero Palareti (c), Daniela Poli (d), Paolo Frasconi (b), Rossella Marcucci (d)
(a) CARDIOLOGY AND ELECTROPHYSIOLOGY UNIT, SANTA MARIA NUOVA HOSPITAL, FLORENCE; (b) DEPARTMENT OF INFORMATION ENGINEERING, UNIVERSITY OF FLORENCE, FLORENCE; (c) ARIANNA ANTICOAGULAZION FOUNDATION, BOLOGNA; (d) DEPARTMENT OF EXPERIMENTAL AND CLINICAL MEDICINE, UNIVERSITY OF FLORENCE; (e) HAEMOSTASIS AND THROMBOSIS CENTER, LABORATORY MEDICINE DEPARTMENT, ASST CREMONA

Background. Despite the availability of various risk scores, the actual tools for predicting outcomes in AF (atrial fibrillation) patients still have a modest level of accuracy. In the AF population, ML (Machine Learning) has been used to predict outcomes, but evidence about outcome prediction in a completely anticoagulated AF population is lacking. This study uses data from the Italian AF START-2 Register to predict outcomes in anticoagulated patients with atrial fibrillation.
Methods. Different ML models as Multi-Gate Mixture of Experts (MMoE), Gradient Boosting Decision Tree (GBDT) and multi-task neural networks (MTNN) were applied to predict all-cause death, stroke, and major bleeding. Analyses were conducted on global population (GP), patients anticoagulated with vitamin K antagonist (VKA) or direct anticoagulants (DOAC).
Results. 11077 AF patients (male n=6028, 54.3%), were enrolled with a median follow-up period of 1.5 years [IQR 1.0-2.6]. Patients on VKA were 5135 (46.4%) while 5943 (53.6%) were on DOAC. During follow-up, 785 patients died, 240 major bleeding events were recorded, and 50 stroke occurred. Using MMoE, a cross-validated AUC of 0.779 ± 0.016 was obtained for the prediction of all-cause death the GP. The best ML model outperformed CHA_2DSVA_2SC and HAS-BLED for all-cause death prediction (p<0.001 for both). When compared to HAS-BLED, Gradient Boosting improved major bleeding prediction in DOACs patients (0.711 vs. 0.586, p<0.001). The most significant variables for ML prediction of outcomes resulted body mass index, age, glomerular filtration rate, and hemoglobin levels.
Conclusions. In anticoagulated AF patients, ML models demonstrated good discriminative power to predict all-cause death in all populations considered and major bleeding only in the DOAC population, outperforming CHA_2DS_2VASC and the HAS-BLED scores for risk prediction in these populations.

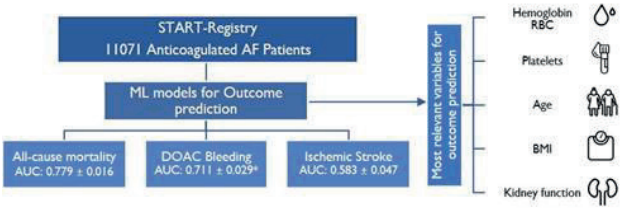

A980: DIGITAL-APP BASED DYSLIPIDEMIA MONITORING FOR CARDIOVASCULAR PREVENTION

Letizia Rosa Romano (a), Giuseppe Scalzi (a), Anna Bartone (a), Letizia Velato (a), Biagio Malizia (a), Ciro Indolfi (a), Antonio Curcio (a)
(a) DIVISION OF CARDIOLOGY, DEPARTMENT OF MEDICAL AND SURGICAL SCIENCE, MAGNA GRAECIA UNIVERSITY, CATANZARO, ITALY

Introduction. Globally one of the most common causes of mortality is atherosclerotic cardiovascular disease (ASCVD). The causal association between LDL cholesterol (LDL chol) and ASCVD is one of the most consolidated topics of modern medicine. In the prevention of cardiovascular (CV) disease, risk factor management is, therefore, a cornerstone, but it requires frequent and/or multiple follow-ups. In this contest, digital devices for their widespread diffusion, can be a useful tool in the assessment of these patients.
Aims. We supposed that motivational alerts sent through telemedicine to patients could improve adherence to therapy in ASCVD patients; therefore, we evaluated the impact of a digital-APP in dyslipidemia management, particularly on LDL chol reduction.
Methods. From March 2022 to May 2023, fifty patients with dyslipidemia diagnosis (40 males; mean age 62 ± 9 years; age range 40 - 81 years) were followed through digital APP in comparison with further fifty dyslipidemic patients (43 males; mean age 63 ± 9 years; age range 40 - 81 years) who underwent standard outpatient visits. Patients' access to digital APP was remotely monitored and reports were used for therapy adjustments. Statistical analysis was performed with GraphPad Prism 7; comparisons were carried out by two-way ANOVA and by chi-square test.
Results. We observed a significant reduction of LDL chol values in both groups at six months follow-up (from 93.3 ± 36.4 mg/dL to 72.1 ± 35.2 mg/dL; P=0.024 in app-monitored patients and from 90.8 ± 43.8 mg/dL to 76.7 ± 38.6 mg/dL; P=0.008 in monitored by standard visits patients). We also identified two further subgroups within the main cohorts (26 ischemic vs 24 non ischemic subjects in APP group; 33 ischemic vs 17 non ischemic subjects in standard visit group). Telemedicine APP-based control showed greater reduction in LDL chol than standard dyslipidemic control [F (1, 76) =12.54; P=0.0007]. Similarly, lower LDL chol values were obtained in APP-monitored non-ischemic subgroup [F (1, 96) =27.07; P<0.0001]. Finally, telemedicine-based APP method resulted more effective than standard monitoring method (P=0.04).
Conclusions. We found a better control of LDL-chol values in APP-based group and ischemic subgroup. Use of mobile APP can help patients to keep a greater adherence to pharmacological therapy and indirectly improve CV risk factor control by increasing the patient's attention to their clinical condition through greater knowledge of CV disease. Furthermore, aggressive lipid lowering therapies should be implemented with remote patients monitoring, mostly in the post-ischemic setting.

A981: USING AI TO IDENTIFY LEFT VENTRICULAR EJECTION FRACTION FROM THE ECG: THE SOLOMAX (SOCIAL NETWORK OF MEDICAL EXPERIENCES) PROJECT

Valeria Visco (a), Antonio Robustelli (c), Francesco Loria (a), Antonella Rispoli (a), Andrea Martorella (a), Albino Carrizzo (a), Alessia Bramanti (a), Gianni D'Angelo (c), Carmine Vecchione (a, b), Michele Ciccarelli (a, b)
(a) DEPARTMENT OF MEDICINE, SURGERY, AND DENTISTRY, UNIVERSITY OF SALERNO, SALERNO, ITALY; (b) CARDIOLOGY UNIT, UNIVESRITY HOSPITAL "SAN GIOVANNI DI DIO E RUGGI D'ARAGONA", SALERNO, ITALY; (c) COMPUTER SCIENCE DEPARTMENT, UNIVERSITY OF SALERNO, SALERNO, ITALY

Background. The interest in machine learning-based algorithms in the cardiovascular field is rapidly growing, especially for diagnostic and prognostic purposes. Recent evidence has demonstrated that certain electrocardiographic (ECG) parameters are predominantly associated with systolic function, estimated as left ventricular ejection fraction (LVEF) by echocardiography, albeit with still relatively low accuracy. Nonetheless, the ECG is a fundamental, ubiquitous, and cost-effective tool in cardiology practice, and recent advances in artificial intelligence (AI) have shown that it can provide much more information for diagnosing such conditions than is currently being leveraged. Consequently, this study aims to develop an AI-based model capable of predicting LVEF from ECG data in an Italian population.
Methods. Within the SOLOMAX project, we collected paired ECG-Echocardiography exams from 105 patients (64.82±16.02y;62.86%male). Precisely, we excluded patients with atrial fibrillation at the time of the ECG, PMK or electrostimulated rhythm, valve prostheses, previous cardiac surgery, O2 therapy or COPD, previous ablation or invasive electrophysiology procedures, currently hospitalized for Takotsubo or ACS, heart failure exacerbation, inotropic therapy, ACS over the last 3 months. We recorded anthropometric, clinical, biochemical, ECG, and Echocardiography parameters. The collected data was studied using AI-based techniques to create a new model to predict LVEF from ECG. Using an approach based on evolutionary algorithms, genetic programming was used. This approach solves a symbolic regression problem through genetic algorithms and provides a mathematical model of the relationship between ECG parameters and LVEF. The formula obtained was then used to build a simple explainable classifier, which provides a global interpretation of the link between ECG parameters and LVEF.

Results. The performance of the proposed approach and the reliability of the results were assessed using the k-fold cross-validation method and by estimating standard metrics derived from the confusion matrix associated with a binary classifier, that is, accuracy, sensitivity, specificity, precision, and F-Measure. The proposed approach consistently demonstrated its ability to distinguish patients with preserved LVEF from those with reduced LVEF. Each metric averaged across all experiments scored approximately 95%. Furthermore, in the expression generated by the AI model, the axes of the P, QRS, and T waves play a prominent role, as they are likely to provide a better interpretation of the three-dimensional cardiac geometry and, consequently, cardiac function.
Conclusions. AI applied to ECG data can be used to create cost-effective diagnostic and predictive tools for assessing LVEF. Indeed, the obtained formula highlights the relationship between ECG parameters and LVEF, as well as its complexity, which can aid in detecting heart diseases. However, further studies are required to understand better its limitations and the factors influencing its accuracy.

A982: BLOCKCHAIN TECHNOLOGY IN CARDIOVASCULAR MEDICINE: A GLANCE TO THE FUTURE? RESULTS FROM A SOCIAL MEDIA SURVEY AND FUTURE PERSPECTIVES.

Luigi Spadafora (a)
(a) SCUOLA DI SPECIALIZZAZIONE IN MALATTIE DELL'APPARATO CARDIOVASCOLARE, SAPIENZA UNIVERSITÀ DI ROMA

The leverage of digital facilities in medicine for disease diagnosis, monitoring, and medical history recording has become increasingly pivotal. However, the advancement of these technologies poses a significant challenge regarding data privacy, given the highly sensitive nature of medical information. In this context, the application of Blockchain technology, a digital system where information is stored in blocks and each block is linked to the one before, has the potential to enhance existing technologies through its exceptional security and transparency. This paradigm is of particular importance in cardiovascular medicine, where the prevalence of chronic conditions leads to the need for secure remote monitoring, secure data storage, and secure medical history updating. Indeed, digital support for chronic cardiovascular pathologies is getting more and more crucial. For these reasons, we conducted a survey targeting cardiologists to gauge their awareness and perception of Blockchain technology's potential applications in cardiovascular medicine. The survey garnered participation from 122 individuals across LinkedIn and Twitter. The respondents were posed a series of questions regarding their familiarity with Blockchain technology and its healthcare applications. A notable 18.2% of participants indicated awareness of blockchain's potential in healthcare, while the majority, comprising 81.8%, admitted unfamiliarity with the technology. Interestingly, 63.6% of cardiologists expressed a greater sense of confidence in utilizing a Blockchain-based medical record application tailored specifically for cardiovascular patients. Moreover, a substantial 78.6% of respondents acknowledged the potential of an anonymous and secure database platform based on Blockchain technology for facilitating the secure exchange of data among researchers focusing on rare cardiovascular diseases. Therefore, we have conceptualized a web application tailored specifically to cardiovascular care based on blockchain technology in which several types of information can be stored: cardiological clinical history; main cardiovascular risk factors; main cardiological symptoms; home therapy; blood analysis; comprehensive cardiovascular physical examination; measurement of blood pressure; electrocardiograms; echocardiogram The app, which is currently under development, will be integrated with the main cardiovascular scores endorsed by the ESC guidelines, both for cardiovascular prevention and for specific diseases. Any implanted devices, such as pacemakers, will also integrate their data with it. We believe that Blockchain technology may contribute to a breakthrough in healthcare digitalization, especially in the field of cardiology. In this context, we hope that the present work may be inspiring for physicians and healthcare stakeholders.

A983: STRATIFICAZIONE DEL RISCHIO ARITMICO NEI PAZIENTI RICOVERATI PER SINDROME CORONARICA ACUTA: IL RUOLO DEL &LDQUO;PRAISE SCORE&LDQUO; DERIVATO DALL'INTELLIGENZA ARTIFICIALE

Paola Abbiati (b), Luca Cumitini (a, b), Ailia Giubertoni (a), Domenico D'Amario (a, b), Lidia Rossi (a), Giuseppe Patti (a, b)
(a) A.O.U. MAGGIORE DELLA CARITÀ - NOVARA; (b) UNIVERSITÀ DEL PIEMONTE ORIENTALE "AMEDEO AVOGADRO"

Razionale dello studio. Il PRAISE (PRedicting with Artificial Intelligence riSk aftEr acute coronary syndrome) score è un modello validato basato sull'intelligenza artificiale per la previsione a 1 anno del rischio di morte per tutte le cause, di infarto del miocardio e di sanguinamento nei pazienti ricoverati per sindrome coronarica acuta (SCA). Abbiamo voluto verificare la potenziale capacità predittiva del PRAISE score nel valutare il rischio di aritmie ventricolari (VA) e fibrillazione atriale (FA) in una popolazione di pazienti ricoverati per SCA.
Metodi. Sono stati inclusi nello studio osservazionale prospettico 365 pazienti adulti ricoverati per SCA e sottoposti ad intervento coronarico percutaneo. I pazienti sono stati sottoposti a monitoraggio elettrocardiografico durante tutto il periodo di degenza. Abbiamo calcolato per ogni paziente il rischio di mortalità PRAISE utilizzando il calcolatore disponibile online, suddividendo i pazienti in due gruppi: il primo a non alto rischio di mortalità (con valori di rischio intermedio-basso) ed il secondo ad alto rischio di mortalità. L'incidenza di FA è stata valutata come almeno un episodio di durata di almeno 5 minuti. L'incidenza di VA è stata intesa come almeno un episodio di tachicardia ventricolare non sostenuta, tachicardia ventricolare sostenuta o fibrillazione ventricolare.
Risultati. Dall'analisi dei dati è emerso che il numero di eventi aritmici è stato più elevato nel gruppo con valori elevati di rischio PRAISE di mortalità, sia per quanto riguarda l'incidenza di FA (53% vs 4%; p=0.001) sia per l'incidenza di VA (93% vs 34%; p=0.001). Le caratteristiche operative del ricevitore calcolate per il PRAISE score hanno dimostrato valori di area sotto la curve (AUC) per ciascuna aritmia tali da riconoscerlo come un modello predittivo accurato, soprattutto per la FA [AUC=0.89; intervallo di confidenza (IC) 95%: 0.82-0.9; p=0.0001], meno per le VA (AUC=0.69; IC 95%: 0.64-0.75; p=0.0001). L'incidenza cumulativa di aritmie a 30 giorni di ospedalizzazione si è dimostrata essere maggiore nel gruppo ad alto rischio sia per le VA (77% vs 35% p=0.0001) sia per la FA (30% vs 4%, p=0.0001) (Fig. 1). Abbiamo poi identificato come un alto rischio di PRAISE score sia predittore indipendente sia di FA [Hazard Ratio (HR) 4.08, IC 95% 1.14-14.58; p=0.030) sia di VA (HR 2.36, IC 95% 1.08-5.14; p=0.030).
Conclusioni. Il PRAISE score è in grado di predire il rischio di aritmie intraospedaliere nei pazienti ricoverati per SCA. La semplicità di utilizzo di tale score lo può rendere un utile strumento per indirizzare misure preventive e personalizzare la gestione terapeutica, migliorando così la prognosi di tali pazienti.

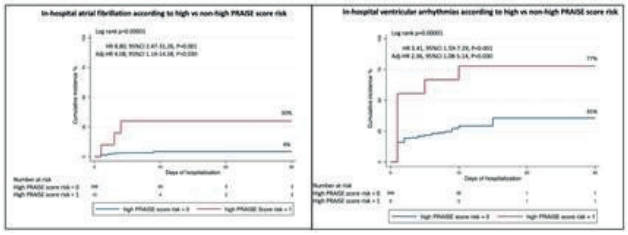

VALVULOPATIE

A984: THE FIRST TEN TRILOGY JENAVALVE IMPLANTED IN ITALY TO TREAT PURE AORTIC REGURGITATION: EARLY OUTCOMES

Nicolò Azzola Guicciardi (a), Buzzatti Nicola (a), Matteo Longoni (a), Alessandro Faggi (a), Federica Gramegna (a), Cosmo Godino (a), Pamela Gatto (a), Paolo Denti (a), Stefano Stella (a), Michele De Bonis (a), Eustachio Agricola (a), Francesco Maisano (a)
(a) HEART VALVE CENTER SAN RAFFAELE

Transcatheter treatment of pure aortic regurgitation (AR) with conventional prostheses is often challenging due to lack of calcium and big annulus dimensions and it is still off-label without evidence-based recommendations from current guidelines. The recently CE-marked Trilogy by JenaValve is a new device designed on purpose to target AR with a dedicated mechanism of anchoring that attaches to the aortic leaflets. While very promising, clinical experience is still limited. We present the first and unique Italian experience with Trilogy JenaValve implantation for the treatment of pure AR. From July 2022 to July 2023, the Trilogy valve was successfully implanted in 10 patients with AR at the San Raffaele Valve Center. All the patients had an increased risk for surgery (median age =80.8 years, IQR [72.6-84.6], EGFR =52.5 ml/min IQR [34.5-65.5], STS score =2.3 IQR [1.5-3.6]), and 7 out of 10 had a NHYA class ≥3. In the 90% of the cases the aortic valve was tricuspid. Every case was discussed in Heart Team. The procedure was performed in local anesthesia with femoral access in all cases. The median size of the bio-prothesis was 25 mm, IQR [24.5-27]. The technical success was 100%. Post-operative course was uneventful for all patients except for one case with preprocedural right bundle branch block and elongated PR interval who developed a third grade atrial-ventricular block requiring pacemaker implantation. Median length of stay was 4 days [4-6]. The transthoracic echocardiogram at discharge demonstrated the absence of significant transaortic gradient (mean gradient =6 mmHg, IQR [4,75-8,25]) and of any significant paravalvular leak. The first Italian experience with Trilogy JenaValve for pure AR has been promising. Further technology application, more data and long-term follow-up will be needed. The Trilogy Jena has the potential to change the guidelines for the treatment of AR in the next years.

A985: CARDIOPULMONARY PERFORMANCE AND 6MWD IMPROVEMENT AFTER MITRAL TRANSCATHETER EDGE-TO-EDGE REPAIR: A PILOT STUDY

Giulio Leo (a), Chiara Mari (a), Niccolo Bonini (a), Sabrine Saaidi (a), Salvatore Arrotti (a), Fabio Alfredo Sgura (a), Rosario Rossi (a), Giuseppe Boriani (a), Francesca Coppi (a)
(a) CARDIOLOGY DIVISION, UNIVERSITY OF MODENA AND REGGIO EMILIA, POLICLINICO DI MODENA, 41124, ITALY

Background. The aim of this study is to evaluate changes in cardiopulmonary performance throught cardiopulmonary exercise test (CPET) and/or six-minute walking test (6MWT) after transcatheter edge-to-edge repair (TEER) with MitraClip in patients with organic or functional mitral regurgitation (MR).

Methods and Results. This is a retrospective registry of 7 patients with organic or functional mitral regurgitation (MR) who underwent elective TEER between April 2020 and March 2023 in our institution. Treadmill exercise testing with respiratory gas exchange analysis was carried out in 6 patients while 6MWT was carried out in 7 patients (male, 28.6%; median age, 83,71 years old) within the month prior to the procedure and at at least 6-month follow-up. TEER was successfully performed in all patients. At 6-month follow-up, TEER showed an improvement in New York Heart Association functional class and a reduction in MR severity. Patients completed pre-procedural and post-procedural CPET and 6MWT. Compared with pre-procedural CPET, patients showed a trend of amelioration in exercise time, VO_2 peak, ventilatory anaerobic threshold and workload. In addition, a significant increase in 6MWT distance at follow-up was noticed. Despite the trend of amelioration was clear, no statistical significance was reached. It could be explained by many reason, firstly the short population evaluated, secondly the frail status and the old age of all the patients tested which made the follow-up assessment often invalidated by incoming comorbidities or clinical happening (falls, bleedings, physical deconditioning). In addition CPET implies an active role of patients and a large-scale clinical applicability is uncertain, especially in those who are not motivated and unfit.

Conclusions. Transcatheter edge-to-edge repair with MitraClip was associated with an enhancement in cardiopulmonary performance and in six-minute walking distance in patients with mitral regurgitation at mid-term follow-up. Further studies are needed to assess the role of these functional tests in order to deeply understand the pathophysiological processes below mitral regurgitation.

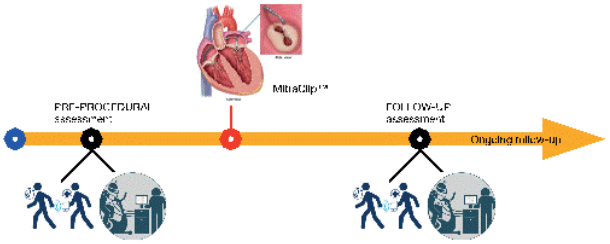

Figure 1. Timeline of functional test assessment in our cohort of patient.

A986: MORPHOLOGIC PHENOTYPES OF TRICUSPID REGURGITATION

Denis Leonardi (a), Paolo Springhetti (a), Luca Ciceri (a), Alberto Dotto (a), Sebastiano Bertola (a), Martina Setti (a), Caterina Maffeis (a), Elvin Tafciu (a), Corinna Bergamini (a), Licia Formigaro (a), Roberto Scarsini (a), Flavio Luciano Ribichini (a), Giovanni Benfari (a)
(a) UNIVERSITY OF VERONA, DEPARTMENT OF MEDICINE, SECTION OF CARDIOLOGY

Introduction. In the last years a growing body of research emerged focusing on Tricuspid Regurgitation (TR) and a new morphologic classification has been recently suggested. However, at best of our knowledge there are only few large sized studies applying it: we aimed to further test its impact on event free survival.

Methods. We retrospectively analyzed consecutive outpatients with at least moderate functional TR referred over 7 years for echocardiography and clinical evaluation. Exclusion criteria were primary and cardiac implantable electronic device (CIED) induced TR. The cohort of patients was divided into ventricular and atrial TR (V-TR and A-TR), the former mostly related to right ventricular dilatation and/or tethering of leaflets, the latter mainly due to atrial enlargement and leaflets' mal-coaptation.

Results. Among 327 patients with TR, V-TR was predominant (63%). A-TR patients were younger (74 ± 9 vs. 77 ± 10, p=0.006) and more frequently presenting with AF vs. V-TR (75% vs. 64%). Relevant PHTN (defined as sPAP ≥50 mmHg) was found in 37% of patients (n=119), mostly related to V-TR (n=103), and severe TR in 33% (n=108). V-TR was present in 85% (n=108) of patients with relevant left-sided valve disease, and always occurred with history of heart failure. During a median follow-up of 6.1 [IQR 1.9 – 8.7] years, 95 (29%) patients died and 20 (6%) patients had heart failure hospitalization after diagnosis of at least moderate TR. V-TR had worse event-free survival than A-TR (Figure): 76 ± 5% vs. 91% ± 3 at 4 years, 59 ± 4% vs. 75% ± 4 at 8 years [HR 1.91; 95% CI 1.21 – 2.99, P=0.005].

Conclusions. Morphologic classification significantly impacts on outcome of functional TR. Pathophysiological mechanisms should be deeply further studied to better display natural history and stratify patients aiming at prompt treatment of TR.

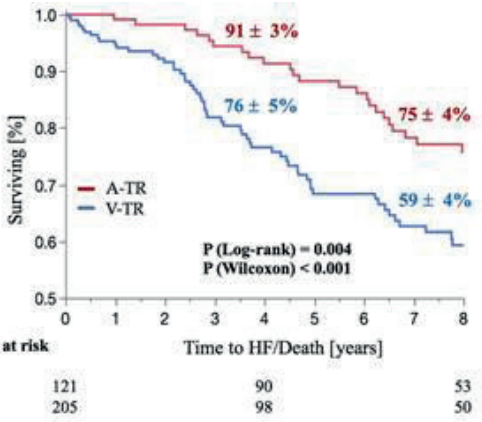

Figure. Kaplan Meier event-free survival by morphologic phenotypes. A-TR, atrial tricuspid regurgitation; V-TR, ventricular tricuspid regurgitation.

A987: RIGHT ATRIAL REMODELING AND OUTCOME IN PATIENTS WITH SECONDARY TRICUSPID REGURGITATION

Giordano M. Pugliesi (a, b), Michele Tomaselli (a), Daniela N. Radu (c), Denisa Muraru (a), Francesco P. Perelli (a, b), Francesca Heilbron (a), Andrea Cascella (a, b), Mara Gavazzoni (a), Giorgio Oliverio (a), Marco Penso (a), Sergio Caravita (a, b), Claudia Baratto (a), Samantha Fisicaro (a), Gianfranco Parati (a, b), Cristina Giannattasio (b), Luigi P. Badano (a, b)
(a) ISTITUTO AUXOLOGICO ITALIANO - OSPEDALE SAN LUCA; (b) UNIVERSITÀ "BICOCCA" DI MILANO; (c) CAROL DAVILLA UNIVERSITY OF MEDICINE AND PHARMACY, PROF. DR. C. C. ILIESCU INSTITUTE, BUCHAREST, ROMANIA

Background. In patients with secondary tricuspid regurgitation (STR), right atrial remodeling (RAR) is a proven marker of disease progression. However, the prognostic value of RAR, assessed by indexed RA maximal volume (RAVi) and reservoir strain (RAS) remains to be clarified. Accordingly, the aim of our study is to investigate the association with outcome of RAR in patients with STR.

Methods. We enrolled 397 patients (44% men, 73±13 years) with STR, ranging from mild to severe. Complete two-dimensional and speckle-tracking echocardiography analysis of RA and right ventricular (RV) size and function were obtained in all patients. The primary endpoint was the composite of death from any cause and heart failure (HF) hospitalization.

Results. After a median follow-up of 15 months (IQR: 6-23), the endpoint was reached by 158 patients (39%). Patients with RAS <13% and RAVi>48 mL/m² had significantly lower survival rates compared to patients with RAS ≥13% and RAVi ≤48 mL/m² (log rank p<0.001). On multivariable analysis, RAS <13% (HR 2.11; 95% CI, 1.43-3.11; p<0.001) and RAVi>48mL/m² (HR 1.49; 95% CI, 1.01-2.18; p=0.04) remained associated with the combined endpoint, even after adjusting for RV free-wall longitudinal strain (RV-FWLS), significant chronic kidney disease, and NYHA class. STR excess mortality increased exponentially with values of 18.2% and 51.3 mL/m² for RAS and RAVi, respectively. In nested models, the addition of RAS and RAVi provided incremental prognostic value over clinical, conventional echocardiographic parameters of RV size and function, and RV-FWLS.

Conclusions. In patients with STR, RAR was independently associated with mortality and HF hospitalization. Assessment of RAR could improve risk stratification of patients with STR, potentially identifying those who may benefit from optimization of medical therapy and a closer follow up.

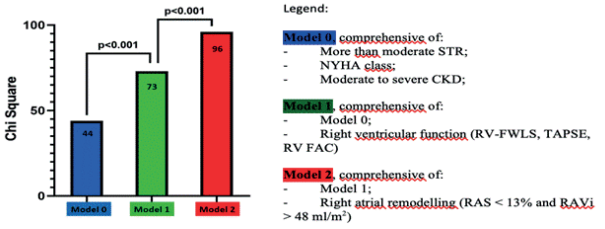

A988: LEFT ATRIAL STRAIN BASED RISK-STRATIFICATION IN MODERATE AND SEVERE AORTIC STENOSIS

Paolo Springhetti (a), Michele Tomaselli (b, c), Giovanni Benfari (a), Salvatore Milazzo (d), Luca Ciceri (a), Marco Penso (b), Matteo Pilan (a), Alexandra Clement (e), Paolo Alberto Del Sole (a), Denisa Muraru (b, c), Flavio Ribichini (a), Luigi Badano (b, c)
(a) DEPARTMENT OF MEDICINE, DIVISION OF CARDIOLOGY, UNIVERSITY OF VERONA, VERONA, ITALY; (b) DEPARTMENT OF CARDIOLOGY, ISTITUTO AUXOLOGICO ITALIANO, IRCCS, MILAN, ITALY; (c) DEPARTMENT OF MEDICINE AND SURGERY, UNIVERSITY OF MILANO-BICOCCA, MILAN, ITALY; (d) DIVISION OF CARDIOLOGY, UNIVERSITY HOSPITAL PAOLO GIACCONE, PALERMO, ITALY; (e) INTERNAL MEDICINE DEPARTMENT, "GRIGORE T. POPA", UNIVERSITY OF MEDICINE AND PHARMACY, IASI

Aims. We sought to investigate the association with outcome of left atrial strain in a large cohort of patients with moderate to severe AS in sinus rhythm.
Methods and Results. we analyzed 467 patients (mean age 80.6 ± 8.2 years; 51% men) with moderate to severe AS. The primary study endpoint was the composite of all-cause mortality and hospitalizations for heart failure. After a mean follow-up of 19.2 (IQR 12.5 – 24.4) months, 96 events occurred. Using the ROC curve analysis, the ideal cut-off value of PALS associated with outcome was <16% [AUC (95% CI: 0.63 – 0.78), p<0.001]. The Kaplan Meier curves demonstrated a higher rate of events for patients with PALS<16% (log-rank p<0.001). On multivariable analysis PALS [adjusted HR (aHR) 0.95 (95% CI 0.91 - 0.99), p=0.017] and age were the only variables independently associated with the combined endpoint. PALS provided incremental prognostic value over left ventricular (LV) global longitudinal strain (GLS), LV ejection fraction (LVEF), and right ventricular function. Subgroup analysis revealed that impaired PALS was independently associated with outcome also in asymptomatic/mild symptomatic [aHR 0.98 (95% CI 0.97 - 0.98), p=0.048], moderate AS [aHR 0.92, (95% CI 0.86 - 0.98), p=0.016], and low flow AS [aHR 0.90, (95% CI 0.83 - 0.98), p=0.020].
Conclusions. In our study, PALS was independently associated with outcome in patients with moderate to severe AS. PALS could be a potential marker of subclinical damage, leading to better risk stratification, earlier treatment and avoidance of futile treatments in patients with AS.

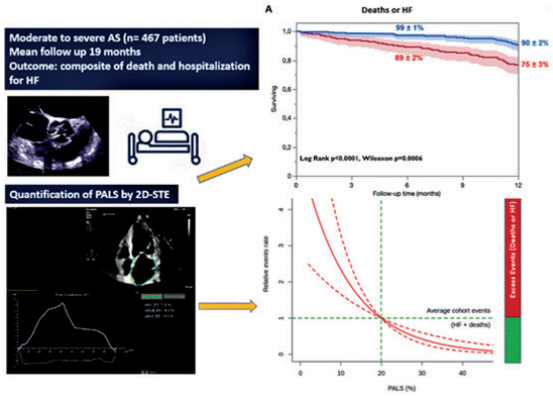

A989: ACUTE TRICUSPID VALVE ANNULUS REMODELING AFTER TRANSCATHETER EDGE-TO-EDGE REPAIR WITH TRICLIP

Giorgio Antonelli (a), Valeria Maria De Luca (a), Valeria Cammalleri (a), Myriam Carpenito (a), Edoardo Nobile (a), Aurelio De Filippis (a), Simona Mega (a), Francesco Grigioni (a), Gian Paolo Ussia (a)
(a) UNIVERSITÀ CAMPUS BIO-MEDICO DI ROMA

Background. Right ventricular (RV) adverse remodeling together with RV dysfunction, and not only tricuspid regurgitation (TR) severity, are independently associated with survival in patients with medically treated significant TR. A notable reverse remodeling has been reported in the majority of patients undergoing tricuspid valve (TV) surgery for significant TR. Nevertheless, changes in RV dimensions and function after transcatheter tricuspid valve intervention and their association with outcomes remain largely unexplored, as well as tricuspid valve annulus (TVA) reverse remodeling. Aim of our study is to assess acute remodeling of TVA after tricuspid transcatheter edge-to-edge repair (T-TEER) with the TriClip device (Abbott Vascular, Santa Clara, CA, USA) using intraprocedural trans-esophageal echocardiography (TEE).
Methods. This prospective, single-center study, conducted at Fondazione Policlinico Universitario Campus Bio-Medico of Rome, enrolled 35 consecutive symptomatic patients referred with the diagnosis of at least severe TR who underwent T-TEER from March 2021 to August 2023 with TriClip System. Intraprocedural TEE was performed using Siemens Acuson SC2000 (Siemens Medical Systems, Pleasanton, CA, USA). The eSie Valves package, appropriately modified to be tailored for tricuspid valve, was used to analyze the TVA. All these measures were performed during the procedure, before and after T-TEER.
Results. The mean age of the study cohort was 78,77 ± 6,15 years, and 77% were female. Sixteen patients (46%) had severe (3+), fourteen patients (40%) massive (4+) and four patients (11%) torrential (5+) tricuspid regurgitation. The majority of them had atrial functional tricuspid regurgitation, mostly due to annular dilatation. Procedural success was achieved in all patient, with a TR reduction of at least 1-grade. We observed a significative reduction of TVA three-dimensional measurements immediately after the procedure. Specifically, the septal-lateral and the anterior-posterior diameter, major and minor diameters, area, perimeter and eccentricity index significantly varied after the TR reduction.
Conclusions. In our study we observed that the reduction of TVA happened immediately after clip positioning, proving that T-TEER is effective in reducing TR and in inducing reverse remodeling of the TV apparatus. Our data are gathered during T-TEER procedure, follow up data are needed for monitoring right ventricular performance.

A990: PROGRESSION OF TRICUSPID REGURGITATION AFTER TRANSCATHETER AORTIC VALVE REPLACEMENT AND COMBINED STEPWISE MANAGEMENT

Giorgio Antonelli (a), Valeria Maria De Luca (a), Valeria Cammalleri (a), Edoardo Nobile (a), Myriam Carpenito (a), Maria Grazia Piscione (a), Aurelio De Filippis (a), Federica Coletti (a), Dario Gaudio (a), Annunziata Nusca (a), Francesco Grigioni (a), Gian Paolo Ussia (a)
(a) UNIVERSITÀ CAMPUS BIO-MEDICO DI ROMA

Background. The impact of tricuspid regurgitation (TR) in patients who underwent transcatheter aortic valve implantation (TAVI) is not well known. In addition, right ventricular (RV) dysfunction, together with TR may impact the prognosis of patients with TAVI. Multivalvular heart disease currently represents a challenge for cardiac surgeons and interventional cardiologists, as well and affects long-term prognosis compared to isolated aortic stenosis (AS). For this reason, it is crucial to offer patients adequate treatment. Some studies have reported that there is sometimes a TR progression after TAVI, and it is more likely observed in patients with low transaortic gradients, atrial fibrillation, or pulmonary hypertension. TR progression after TAVI is associated with increased all-cause mortality and heart failure hospitalization.
Methods. From March 2021 to August 2023, 35 consecutive patients suffering from severe TR underwent tricuspid transcatheter edge-to-edge repair (T-TEER) with the TriClip System (Abbott Vascular, Santa Clara, CA, USA) at Fondazione Policlinico Universitario Campus Biomedico of Rome. Among them, six patients (17%) had previously undergone TAVI for severe AS. The echocardiograms performed before TAVI were retrospectively reviewed and compared with those performed before and after T-TEER. New York Heart Association (NYHA) functional status and self-assessed state of health before and after T-TEER were also evaluated and compared with the assessments recorded before TAVI.
Results. The mean age of the entire TriClip population was 78.77±6.15 years, with 77% of females. The subgroups of TAVI patients had a mean age of 82.66±6.28 years, with 84% of females. Three patients (50%) had severe (3+), one patient (17%) massive (4+) and two patients (33%) torrential (5+) TR before T-TEER. When compared with the echocardiograms before TAVI, two patients (33%) had moderate (2+), three patients (50%) severe (3+) one patient (17%) massive TR. The etiology was functional in most of them. Procedural T-TEER success was achieved in all patients, with a TR reduction of at least 1-grade in all patients. We also observed a significant improvement in symptoms, especially dyspnea and functional capacity, more marked after T-TEER rather than after TAVI alone.
Conclusions. In patients with prior TAVI and persistent TR we observed that T-TEER is safe and presents clinical benefits by reducing symptoms and by improving quality of life. Our findings show the feasibility and the efficacy of a staged approach for transcatheter treatment of AS and TR and suggest the potential clinical benefits of careful monitoring of TR after aortic valve interventions to find out the good time to perform T-TEER. However, further studies are needed, especially because TR progression after TAVI is emerging as a critical parameter that should be routinely assessed during follow-up because it can significantly affect outcomes.

A991: TRANSCATHETER TREATMENT OF AORTIC REGURGITATION WITH TRILOGY JENAVALVE: THE FIRST ITALIAN CASE

Nicolò Azzola (a), Nicola Buzzatti (a), Matteo Longoni (a), Alessandro Faggi (a), Federica Gramegna (a), Cosmo Godino (a), Pamela Gatto (a), Paolo Denti (a), Stefano Stella (a), Michele De Bonis (a), Eustachio Agricola (a), Francesco Maisano (a)
(a) HEART VALVE VENTER SAN RAFFAELE

Due to the large annulus dimensions and absence of calcium, transcatheter therapy of pure aortic regurgitation (AR) is still off-label and does not have any evidence-based recommendations from current guidelines. The new CE-marked Trilogy JenaValve is an innovative tool created specifically to target AR with an anchoring mechanism that attaches to the aortic leaflets. Clinical experience is still limited despite appearing very promising. For the very first time in Italy, Trilogy JenaValve was successfully implanted in July 2022 at San Raffaele Valve Center. We report the case of a 70-year-old man, with pure severe aortic regurgitation and increased risk for surgery with dyspnea for mild efforts (NHYA class III). CT scan re-

vealed lack of any valve calcification but favorable anatomy for transfemoral TAVI with Trilogy JenaValve (mean diameter 25 mm, area of 492 mm^2. After Heart team discussion, a 26 mm size Trilogy JenaValve was successfully implanted. The procedure was performed in local anesthesia with right femoral access. Postoperative course was uneventful, and the patient was discharged home in IV day. At discharge the transthoracic echocardiogram revealed the absence of residual AR with a transaortic mean gradient of 2 mmHg. No significative post-procedural EKG alterations were noted. At one year follow-up echocardiographic results are stable with no evidence of residual AR or prothesis degeneration (mean gradient 3 mmHg). The patient reports an improvement in terms of symptoms (NYHA class I-II) and a reduction of the diuretic therapy. The very first case of Trilogy JenaValve for pure AR in Italy was very encouraging up to 1 year follow-up. More data and longer follow-up are needed.

A992: INCREMENTAL CLINICAL VALUE OF REGURGITANT FRACTION ASSESSED BY THREE-DIMENSIONAL ECHOCARDIOGRAPHY IN PATIENTS WITH SECONDARY TRICUSPID REGURGITATION

Andrea Cascella (a, b), Mara Gavazzoni (a, b), Michele Tomaselli (a, b), Noela Radu (d), Francesco Perelli (a, b), Francesca Heilbron (b), Alexandra Clement (a, d), Samantha Fisicaro (b), Claudia Baratto (a, b), Sergio Caravita (b, c), Marco Penso (b), Giorgio Oliverio (b), Cristina Giannattasio (a), Gianfranco Parati (b), Luigi Paolo Badano (a, b), Denisa Muraru (a, b)

(a) DEPARTMENT OF MEDICINE AND SURGERY, UNIVERSITY OF MILANO-BICOCCA, MILAN, ITALY; (b) DEPARTMENT OF CARDIOLOGY, ISTITUTO AUXOLOGICO ITALIANO, IRCCS, MILAN, ITALY; (c) DEPARTMENT OF MANAGEMENT, INFORMATION AND PRODUCTION ENGINEERING, UNIVERSITY OF BERGAMO, DALMINE, ITALY; (d) CAROL DAVILA UNIVERSITY OF MEDICINE AND PHARMACY, BUCHAREST, ROMANIA

Background. Quantitative parameters of tricuspid regurgitation severity have been recommended by current guidelines due to their strong association with patient outcome and limited reliability of qualitative and semi-quantitative severity indices. Differently from the effective regurgitant orifice area (EROA) and the regurgitant volume (RegVol), the regurgitant fraction **(**RegFr) accounts for the size and the function of the right ventricle (RV).

Aim. To evaluate the association with outcome of the tricuspid RegFr assessed by Doppler and three-dimensional (3DE) echocardiography in patients with secondary tricuspid regurgitation (STR).

Methods. A total of 331 patients with at least mild STR were enrolled (47% men, 71±14 years). RegFr was computed as the ratio between the RegVol, calculated using the proximal isovolumic surface area (PISA) method by Doppler and the total right ventricular (RV) stroke volume computed as difference between the RV end-diastolic and end-systolic volumes measured by 3DE. To compare the association of EROA, RegFr and RegVol with outcome, we used a composite endpoint of hospitalization for heart failure and death of any cause.

Results. After a median follow-up of 20 months, 133 patients (40%) reached the composite endpoint. Among the quantitative parameters of STR severity (EROA, RegVol, RegFr), at ROC analysis, the AUC of the RegFr (C- statistics 0.65, 95% CI: 0.59-0.71) was significantly larger than AUC of EROA (C-statistics 0.61, 95% CI: 0.55-0.67; p=0.041). At Cox regression, RegFr was associated with outcome both in the univariate (HR 1.012, CI 1.003-1.020, p=0.006) and in multivariate analysis, adjusted for several clinical and echocardiographic correlates (age, RV free-wall longitudinal strain, RV ejection fraction). By testing each single quantitative parameter of STR severity, only RegFr significantly increased the prediction of the basal model (p=0.007); in addition, RegFr had a significant incremental value compared to EROA alone for the risk-stratification of the patients (Net Reclassification Index: 0.2833, p=0.011). In the subgroup of patients with non-severe STR (i.e. EROA<0.4 cm^2), the RegFr identified the patients with a significantly higher risk of events. In these patients, the cumulative incidence of the combined endpoint was 73% in patients with RegFr≥50% vs. 51% in patients with RegFr<50% (p=0.02).

Conclusions. Among the quantitative parameters of STR severity, RegFr obtained by Doppler and 3DE had the strongest association with patient outcome and had a significant incremental value compared to EROA alone for the risk-stratification of the STR patients. Our results reinforce the guidelines recommendation to implement transthoracic 3DE for optimal diagnosis and risk stratification of STR patients in clinical practice.

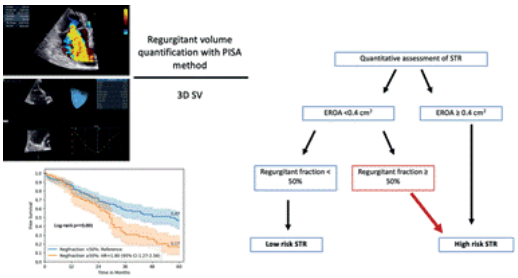

A993: TOP-HAT PROCEDURE IN TRICUSPID VALVE SURGICAL DECISION MAKING: AN 'ELEGANT' SOLUTION IN CHALLENGING ANATOMICAL SCENARIOS.

Domenico Galzerano (a, b), Bandar Al Amro (a, b), Valeria Pergola (c), Amal Alshammari (a), Loay Tashkandi (b), Wassima Kaidali (b), Naji Kholaif (a, b), Lana Arbili (b), Giovanni Di Salvo (d), Zohair Al Halees (a)

(a) THE HEART CENTRE, KING FAISAL SPECIALIST HOSPITAL& RESEARCH CENTER, RIYADH, SAUDI ARABIA.; (b) COLLEGE OF MEDICINE, ALFAISAL UNIVERSITY, RIYADH, SAUDI ARABIA.; (c) DEPARTMENT OF CARDIO-THORACO-VASCULAR SCIENCES AND PUBLIC HEALTH, UNIVERSITY OF PADUA, PADUA, ITALY.; (d) PEDIATRIC CARDIOLOGY AND CONGENITAL HEART DISEASE DEPARTMENT, UNIVERSITY OF PADUA, PADUA, ITALY.

The surgical intervention for tricuspid valve (TV) anomalies remains challenging, particularly in cases of severe TV dysplasia and dilation of the right ventricle or previous surgical/percutaneous interventions. In such scenarios tricuspid valve replacement (TVR) sometimes becomes unfeasible, due to associated complexities making the Top-hat procedure (TH) an alternative. This approach uses unstented semilunar homograft or Hancock conduit placed inverted for TVR.

Purpose. To describe imaging and outcomes of TH in a case series.

Methods. Retrospective registry,clinical and echocardiography (ECHO) data of 4 patients with different etiologies from 2018 to 2023 who underwent TH procedure using Hancock conduit for TVR.

Results. 4 female, ranged 17-39 year-old TH procedure for TVR. Patient 1: status post history of tetralogy of Fallot (TOF) repair and percutaneous pulmonary valve implantation with severe TV regurgitation and right atrium (RA) and right ventricle (RV) dilation with reduced systolic function. In 2018 Underwent successful Top-hat procedure as an alternative to TV replacement or repair for the concomitance of the presence of the Bioprosthetic struts protruding in RVOT; because in the TH procedure the conduit placed inverted is protruding in RA, while the TV bioprosthesis struts in RV, it was chosen as best surgical option. 5 years Follow-up demonstrated optimal tricuspid conduit functioning with improved RV size and systolic function. Patient 2: Ebstein's anomaly, atrial fibrillation, and patent foramen ovale (PFO), significant RA and RV dilation with mild RV systolic dysfunction. Given the TV dysplasia, the apical leaflet insertion and the RV size in Ebstein's anatomy associated with potential RV arrhythmogenicity, the pt underwent TH with optimal results. Patient 3: dysfunction of TV prosthesis (redo initially for rheumatic heart disease); TH with good post op result. Post-operative ECHO revealed a well-seated conduit, moderately reduced RV systolic function. Patient 4: known End-stage renal disease with history of TV endocarditis post TVR with severe TV degeneration (regurgitation).Successful TH with Hancock valved conduit.

Discussion. Our case series report on the imaging and clinical data of on old and rarely utilized type of TV replacement and highlights its ability to overcome difficulties in TV R in particular anatomical scenarios. Only few cases are reported mainly in non adult age. The early success and in one case a 5 years follow up, underscores its effectiveness **Conclusions.** This series of cases confirms the efficacy of the TH as a valuable alternative approach in managing challenging TV surgical decision making scenario in adult patients.

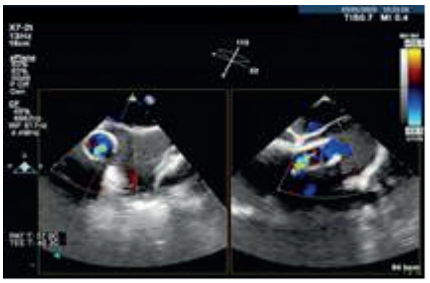

Figure 1. 2D TEE xplane showing the position of the conduit at the level of tv annulus, RV, RA.

Figure 2. 3D TEE Ra view of the conduit.

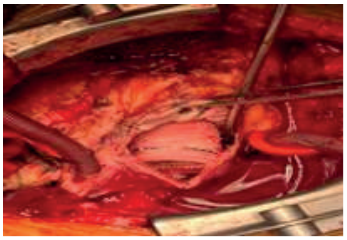

Figure 3. Intraoperative, Hancock conduit for Tricuspid valve.

A994: IN PATIENTS WITH SECONDARY TRICUSPID REGURGITATION THE USE OF THE CONVENTIONAL APICAL 4-CHAMBER VIEW UNDERESTIMATES THE RIGHT ATRIAL VOLUMES CALCULATED BY TWO DIMENSIONAL ECHOCARDIOGRAPHY

Mara Gavazzoni (a, b), Andrea Cascella (a, b), Marco Penso (b), Giordano Maria Pugliesi (a), Alexandra Clement (a), Michele Tomaselli (a, b), Francesca Heilbron (b), Giorgio Oliverio (b), Sergio Caravita (a, b, c), Claudia Baratto (b), Samantha Fisicaro (b), Gianfranco Parati (b), Cristina Giannattasio (d), Luigi Paolo Badano (a, b), Denisa Muraru (a, b)

(a) DEPARTMENT OF MEDICINE AND SURGERY, UNIVERSITY OF MILANO BICOCCA, ITALY; (b) IRCCS ISTITUTO AUXOLOGICO ITALIANO, DEPARTMENT OF CARDIOLOGY, SAN LUCA HOSPITAL, MILANO; (c) DEPARTMENT OF MANAGEMENT, INFORMATION AND PRODUCTION ENGINEERING, UNIVERSITY OF BERGAMO, DALMINE, ITALY; (d) DEPARTMENT OF HEALTH SCIENCE, UNIVERSITY OF MILANO BICOCCA, MONZA, ITALY

Background. In patients with significant secondary tricuspid regurgitation (STR), right atrial (RA) remodeling has pathophysiological and prognostic relevance. According to current guidelines, RA volumes (RAV) should be obtained from an apical 4-chamber view (4Ch) using two-dimensional echocardiography (2DE). Recently, our group validated the RAV measured by three-dimensional echocardiography (3DE) against cardiac magnetic resonance (CMR) measurements.

Aim. To compare the accuracy and the reproducibility of maximal (RAVmax), minimum (RAVmin) RA volumes, and RA emptying fraction (RAEF) calculated by 2DE using either the conventional apical 4Ch or the apical RV-focused view (RVF) in patients with different phenotypes of STR and wide range of regurgitation severities.

Methods. Consecutive patients with STR and adequate quality of the recorded datasets for quantification of 2DE and 3DE RAV were enrolled for this analysis. Patients with cardiac implanted electronic device (CIED) were excluded. Using Bland-Altman analyses, the relative biases (ml/m^2, %) and limits of agreement (LOA) of the measures obtained from the 4Ch and the RVF 2DE approaches were compared, considering RAV volumes measured by 3DE as reference.

Results. A total of 384 patients with STR (34% mild, 36% moderate, and 30% severe STR) were included. Of these, 157 patients had atrial STR (41%), and the rest had ventricular STR. Compared to 3DE RAV max, the RAVmax calculated using the 4Ch view provided a significantly larger underestimation [bias=-13 mL/m^2 (-24%), LOA±20 ml/m^2] than the RAVmax calculated using the RVF view [bias=-8 mL/m^2 (-14%), LOA ± 21 ml/m^2] (p<0.001). Similarly, the agreement and the correlation of RAEF was significantly lower when measurements were performed using 4Ch compared to RVF (bias: - 5% for 4CH vs. -1%, LOA: ±31% vs ±26%; ICC: 0.504 vs. 0.706, p<0.001). The relative bias between 2DE calculations vs 3DE measurements of RAVmax was larger in less severe STR (-28% in mild STR, -23% in moderate STR, and -19% in severe STR, p=0.001 using 4Ch, and -17% in mild, -14% in moderate, and -11% in severe STR, p=0.005 using RVF). Moreover, the relative bias was larger in the atrial STR phenotype compared to the ventricular STR phenotype: -35% vs -24% (4Ch, p=0.001); -18% vs. -14% (RVF, p=0.03). Inter and intra-observer variabilities were lower when RAVs were obtained from the RVF.

Conclusions. Using apical RV-focused view to calculate RA volumes by 2DE provides more accurate and reproducible calculations of the RAVmax and RAEF compared to the standard 4Ch view recommended by current guidelines. The underestimation of RAVmax using 4Ch view was particularly evident in patients with the atrial phenotype of STR and in those with less severe STR, likely due to the asymmetric dilation of the RA in the earlier stages of the disease. Our results support the recommendation to use dedicated RV-focused views, not only for the RV quantification, but also for RA evaluation by conventional 2DE.

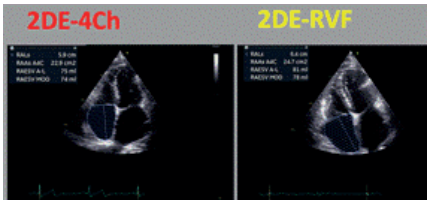

A995: CONCOMITANT VALVE DISEASE EVOLUTION AND ITS LONG-TERM CLINICAL IMPACT IN PATIENTS WITH MULTIPLE VALVULAR HEART DISEASE UNDERGOING TAVI

Silvia Malara (a), Francesco Burzotta (a, b), Francesca Graziani (a), Francesco Bianchini (a), Enrico Romagnoli (a), Cristina Aurigemma (a), Gabriella Locorotondo (a), Rosa Lillo (a), Maria Chiara Meucci (a), Natalia Pavone (a, b), Lisa Nesta (a), Piergiorgio Bruno (a, b), Antonella Lombardo (a, b), Carlo Trani (a, b)

(a) FONDAZIONE POLICLINICO UNIVERSITARIO A. GEMELLI IRCCS, ROME, ITALY; (b) UNIVERSITÀ CATTOLICA DEL SACRO CUORE, ROME, ITALY

Importance: Multiple valvular heart disease (VHD) is a common condition, often including aortic stenosis plus mitral or tricuspid disease. Transcatheter aortic valve implantation (TAVI), performed to treat aortic stenosis (AS), leads to hemodynamic changes that may positively influence the function of other valves and affect prognosis.

Objective: The effect of TAVI on multiple VHD and its prognostic implication.

Design: A retrospective study was conducted on prospectively collected data of patients undergoing TAVI between January 2016 and December 2022. Echocardiography was performed before and after the procedure by physicians blinded to the outcome. Mean follow-up duration was 31 months.

Setting: A tertiary care medical centre.

Participants: 177 consecutive patients affected by severe AS and concomitant ≥moderate mitral or tricuspid valve disease who underwent TAVI. 18 valve-in-valve TAVI patients were excluded.

Main Outcome(s) and Measure(s): Impact of TAVI on concomitant valve disease and difference in all-cause mortality and cardiovascular hospitalisations at follow up in patient improving versus not improving concomitant valve disease.

Results. A total of 159 patients (88 women; mean [SD] age, 80.8 [7.8] years) with multiple VHD undergoing TAVI were identified. 72 (45.3%) had mitral regurgitation, 69 (43.4%) had tricuspid regurgitation and 18 (11.3%) mitral stenosis. After TAVI, 77 significantly improved the second valve disease, while 82 did not. Female gender (p<0.001), pacemaker before TAVI (p=0.046) and the rheumatic aetiology (p=0.012) were predictors of second valve disease persistence. At a median follow-up of 31 months (26-51), patients showing persistence of the concomitant valve disease had increased risk for all-cause mortality and cardiovascular re-hospitalisations (p=0.028) compared to the improved group. Persistence was independently associated with the primary outcome (p=0.013), together with NYHA class III/IV (p=0.044) and pre-TAVI creatinine levels (p=0.019).

Conclusions and Relevance: The hemodynamic changes occurring after TAVI improved concomitant valve disease in a significant proportion of multiple VHD patients, who showed better clinical outcomes in a long-term follow up.

A996: ACUTE CHANGES OF BASIC AND ADVANCED ECHOCARDIOGRAPHIC INDICES IN PATIENTS WITH PRIMARY MITRAL REGURGITATION AND NORMAL EJECTION FRACTION UNDERGOING SURGICAL TREATMENT

Maria Concetta Pastore (a), Matteo Lisi (d), Alfonso Santoro (a), Francesca Rubina Ginetti (a), Maria Alma Iuliano (a), Francesca Vannuccini (a), Lorenzo Tanzi (a), Giulia Elena Mandoli (a), Martina Rizzo (c), Gianfranco Montesi (c), Annalisa Pasquini (b), Luna Cavigli (a), Marta Focardi (a), Flavio D'Ascenzi (a), Matteo Cameli (a)

(a) DEPARTMENT OF MEDICAL BIOTECHNOLOGIES, DIVISION OF CARDIOLOGY, UNIVERSITY OF SIENA, SIENA, ITALY; (b) FONDAZIONE POLICLINICO UNIVERSITARIO A.GEMELLI, IRCCS, UNIVERSITÀ CATTOLICA DEL SACRO CUORE, ROME, ITALY; (c) DEPARTMENT OF CARDIOTHORACIC AND VASCULAR DISEASE, DIVISION OF CARDIAC SURGERY, UNIVERSITY OF SIENA, SIENA,ITALY; (d) SANTA MARIA DELLE CROCI HOSPITAL, RAVENNA, ITALY

Background. It is known that surgical mitral repair or replacement produces an early reduction of hemodynamic overload after the procedure. However, several authors described a reduction of left ventricular (LV) ejection fraction (EF) after mitral valve surgery, despite normal values at baseline, which may persist over long-term follow-up. Speckle tracking echocardiography (STE) has shown to provide more sensitive indices of all cardiac chambers performance in several clinical settings, among which MR. Myocardial work (MW) allows for the assessment of LV performance by considering the effect of LV afterload. The aim of this study was to describe acute postoperative changes of cardiac function and hemodynamics using basic echocardiography, STE and MW indices in patients with primary MR and to find preoperative predictors of early LV dysfunction after surgery.

Methods. Consecutive patients with severe MR and preserved LV EF undergoing surgical treatment (mitral valve repair or replacement) were prospectively enrolled. Exclusion criteria were atrial fibrillation at the time of enrolment, previous cardiac surgery, concomitant aortic or coronary surgery, poor acoustic window. Patients underwent clinical, biohumoral and echocardiographic evaluation before and within one week after surgery during the hospitalization period. STE and MW were performed offline by experienced operators blinded to other data.

Results. Overall, 42 patients were enrolled (mean age 65 ± 12 years, 50% male, mean LV EF 59 ± 4%). Before intervention, patients had high left

atrial volume and pulmonary artery pressure, normal right ventricular function (Fig.1). After intervention, 48% of patients showed LV EF reduction (n=20), while most patients showed a reduction of STE and MW parameters of all chambers (Table 1). Particularly, global work index (GWI) was reduced in 79% of patients (n=33). With univariate and multivariate analysis including preoperative LV EF, left atrial volume index, tricuspid systolic wave (s') by tissue Doppler imaging, global peak atrial longitudinal strain (PALS), free wall right ventricular longitudinal strain, global PALS was the only independent predictor of GWI reduction after surgery (RR 1.26 [1.03-1.55, p=0.021].

Conclusions. Advanced echocardiography offers a more sensitive and load-independent assessment of acute LV dysfunction after surgery in patients with primary MR, and preoperative global PALS could be used to predict early postoperative LV contractility impairment as GWI reduction. These indices could add additional information to optimize pre, peri- and post-operative management of patients undergoing mitral valve surgery.

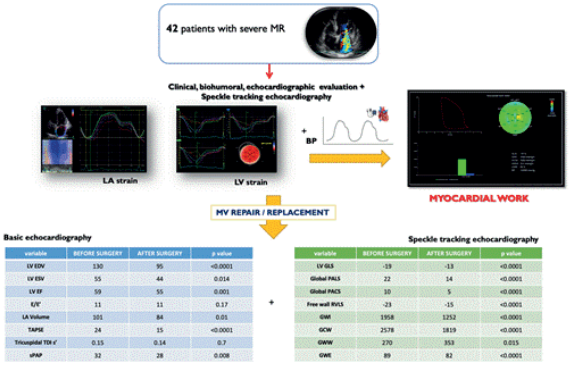

variable	BEFORE SURGERY	AFTER SURGERY	p value
LV EDV	130	95	<0.0001
LV ESV	55	44	0.014
LV EF	59	55	0.001
E/E'	11	11	0.17
LA Volume	101	84	0.01
TAPSE	24	15	<0.0001
Tricuspidal TDI s'	0.15	0.14	0.7
sPAP	32	28	0.008

variable	BEFORE SURGERY	AFTER SURGERY	p value
LV GLS	-19	-13	<0.0001
Global PALS	22	14	<0.0001
Global PACS	10	5	<0.0001
Free wall RVLS	-23	-15	<0.0001
GWI	1958	1252	<0.0001
GCW	2578	1819	<0.0001
GWW	270	353	0.015
GWE	89	82	<0.0001

A997: CORONARY MICROVASCULAR DYSFUNCTION AND LONG-TERM FOLLOW-UP AFTER TAVI

Leonardo Portolan (a), Roberto Scarsini (a), Francesco Della Mora (a), Margherita Fabroni (a), Stefano Andreaggi (a), Andrea Mainardi (a), Paolo Springhetti (a), Alberto Dotto (a), Paolo Alberto Del Sole (a), Simone Fezzi (a), Sara Pazzi (a), Domenico Tavella (a), Concetta Mammone (a), Mattia Lunardi (a), Gabriele Pesarini (a), Giovanni Benfari (a), Flavio Ribichini (a)
(a) DIVISION OF CARDIOLOGY, DEPARTMENT OF MEDICINE, UNIVERSITY OF VERONA, VERONA, ITALY

Background and Objectives. Although coronary microvascular dysfunction (CMD) was described in aortic stenosis (AS), its relationship with advanced extravalvular cardiac damage (EVCD) and its prognostic role remain to be explored. Recently, the angiography-derived index of microcirculatory resistance (IMR_{angio}) was proposed to evaluate CMD in other clinical scenarios. In this study, we sought to evaluate the accuracy of IMR_{angio} in predicting CMD in AS using pressure/thermodilution IMR as a reference, to explore the interplay between CMD and advanced EVCD in AS and to assess the prognostic role of CMD at long-term follow-up after transcatheter aortic valve implantation (TAVI).

Methods. 50 measurements of wire-based IMR and IMR_{angio} were prospectively collected and compared in a first cohort. Subsequently, IMR_{angio} was assessed offline in the left anterior descending artery of 250 patients with severe AS undergoing coronary angiography during the TAVI work-up. According to the Genereux staging advanced EVCD was defined as relevant pulmonary hypertension (≥60 mmHg) and/or moderate to severe tricuspidalic regurgitation and/or relevant right ventricular dysfunction (TAPSE <17 mm). The primary endpoint was a composite of cardiovascular death and rehospitalizations for heart failure.

Results. IMR_{angio} was accurate in predicting IMR-defined CMD (AUC 0.862 [95%CI 0.742-0.983], p<0.0001), with an excellent negative predictive value (100%). 28 (11.2%) patients suffered the primary endpoint at a median follow-up of 22 (12-30) months. Patients with CMD met the primary endpoint more frequently compared with patients without CMD (22.9% vs 2.8%, p<0.0001) and were more frequently characterized by an advanced EVCD (33 [31.4%] vs 27 [18.6%], p=0.024). Notably, CMD was an independent predictor of cardiovascular mortality and rehospitalizations for heart failure (aHR 6.672 [2.251-19.778], p=0.001) with incremental prognostic value compared with clinical variables and advanced EVCD.

Conclusions. IMR_{angio}-defined CMD is associated with poor clinical outcomes (cardiovascular mortality and rehospitalizations for heart failure) after TAVI.

A998: MICROVASCULAR RESISTANCE RESERVE AND ITS ASSOCIATION WITH EXTRAVALVULAR CARDIAC DAMAGE AND LOW FLOW PHENOTYPE IN PATIENTS WITH AORTIC STENOSIS UNDERGOING TAVI

Leonardo Portolan (a), Roberto Scarsini (a), Emanuele Gallinoro (b, c), Marco Ancona (d), Pasquale Paolisso (b, e), Paolo Springhetti (a), Francesco Della Mora (a), Andrea Mainardi (a), Marta Belmonte (b, e), Francesco Moroni (d), Luca Ferri (d), Barbara Bellini (d), Filippo Russo (d), Ciro Vella (d), Dario Tino Bertolone (b, e), Gabriele Pesarini (a), Giovanni Benfari (a), Marc Vanderheyden (b), Matteo Montorfano (d, f), Bernard De Bruyne (b), Emanuele Barbato (g), Flavio Ribichini (a)
(a) DIVISION OF CARDIOLOGY, DEPARTMENT OF MEDICINE, UNIVERSITY OF VERONA, VERONA, ITALY; (b) CARDIOVASCULAR CENTER AALST, OLV-CLINIC, AALST, BELGIUM; (c) DIVISION OF UNIVERSITY CARDIOLOGY, IRCCS GALEAZZI - SANT'AMBROGIO HOSPITAL, MILAN, ITALY; (d) INTERVENTIONAL CARDIOLOGY UNIT, IRCCS SAN RAFFAELE SCIENTIFIC INSTITUTE, MILAN, ITALY; (e) DEPARTMENT OF ADVANCED BIOMEDICAL SCIENCES, UNIVERSITY FEDERICO II, NAPLES, ITALY; (f) SCHOOL OF MEDICINE, VITA SALUTE SAN RAFFAELE UNIVERSITY, MILAN, ITALY; (g) DEPARTMENT OF CLINICAL AND MOLECULAR MEDICINE, SAPIENZA UNIVERSITY, ROME, ITALY

Background and Objectives. Coronary microvascular dysfunction (CMD) was described in aortic stenosis (AS) but its relationship with extravalvular cardiac damage (EVCD) and low-flow phenotype remains to be explored. Recently, microvascular resistance reserve (MRR) was proposed and validated as an innovative measure of coronary microvascular function independent of epicardial resistances. In this study, we aim to explore whether MRR is associated with adverse cardiac remodeling in terms of advanced extravalvular cardiac damage and low-flow phenotype.

Methods. In a prospective multicentric international cohort of 134 severe aortic stenosis patients undergoing transcatheter aortic valve implantation (TAVI) in three European high-volume centres coronary microvascular function was evaluated immediately before and after TAVI with an invasive thermodilution-based assessment in the left anterior descending artery. CMD was defined as the lowest tertile of pre-TAVI MRR in the study cohort (≤2). Advanced EVCD was defined as stages 3 and 4 of the validated Genereux classification (systolic pulmonary arterial pressure ≥60 mmHg and/or moderate to severe tricuspidalic regurgitation and/or right ventricular dysfunction) while low-flow phenotype was defined by a stroke volume index ≤35 ml/m2.

Results. Patients with low MRR were more frequently females, with a lower estimated glomerular filtration rate and a higher rate of atrial fibrillation. MRR was significantly lower in patients with advanced EVCD (1.80 [1.26-3.30] vs 2.50 [1.87-3.41], p=0.038) and in low-flow low-gradient AS (LFLGAS) (1.85 [1.20-3.04] vs 2.50 [1.87-3.40], p=0.008). Overall, coronary microvascular function tended to improve after TAVI and, in particular, MRR increased significantly after TAVI in the subgroup with low MRR at baseline. However, MRR was significantly impaired in 38 (28.4%) patients immediately after TAVI. Advanced EVCD (adjusted odds ratio 3.08 [1.22-7.76], p=0.017) and low-flow phenotype (adjusted odds ratio 3.36 [1.08-10.47], p=0.036) were significant predictors of CMD.

Conclusions. In patients with severe aortic stenosis undergoing TAVI coronary microvascular dysfunction defined by thermodilution-derived MRR is associated with advanced EVCD and low-flow phenotype.

A999: MACHINE-LEARNING PHENOTYPING OF PATIENT WITH FUNCTIONAL MITRAL REGURGITATION UNDERGOING TRANSCATETHER EDGE-TO-EDGE REPAIR

Vittoria Scavino (a, b), Elena Cavallone (a, b), Fabrizio D´ascenzo (a, b), Corrado Pancotti (a, b), Pierpaolo Bocchino (a, b), Cristina Giannini (a, b), Filippo Finizio (a, b), Victoria Camman (a, b), Nuccia Morici (a, b), Leor Perl (a, b), Saverio Muscoli (a, b), Gabriele Crimi (a, b), Paolo Boretto (a, b), Ovidio De Filippo (a, b), Giuseppe Biondi-zoccai (a, b), Federico Conrotto (a, b), Sonia Petronio (a, b), Arturo Giordano (a, b), Christian Templin (a, b), Gianluca Aluffi (a, b), Jacopo Orelgia (a, b), Mario Iannaccone (a, b), Mario Pocar (a, b), Stefano Pidello (a, b), Alessandro Vairo (a, b), Ran Kornowski (a, b), Piero Fariselli (a, b), Simone Frea (a, b), Michele La Torre (a, b), Claudia Raineri (a, b), Giuseppe Patti (a, b), Italo Porto (a, b), Antonio Montefusco (a, b), Gaetano Maria De Ferrari (a, b), Filippo Angelini (a, b)
(a) DIVISION OF CARDIOLOGY, CARDIOVASCULAR AND THORACIC DEPARTMENT, "CITTÀ DELLA SALUTE E DELLA SCIENZA" HOSPITAL, TURIN, ITALY; (b) DEPARTMENT OF MEDICAL SCIENCES, UNIVERSITY OF TURIN, TURIN, ITALY

Background. Severe functional mitral regurgitation (FMR) may benefit from transcatheter mitral valve repair (TMVR), but selection of patients remains to be optimized.

Objectives. The aim of this study was to use Machine-Learning (ML) approaches to uncover concealed connections between clinical, echocardiographic, and hemodynamic data potentially associated with patients' outcomes.

Methods. Consecutive patients undergoing TVMR in 9 International Centres from 2009 to 2020 were included in the MITRA-AI registry. Eleven relevant clinical and echocardiographic variables were included in a clustering-based model. The optimal number of clusters was chosen based on the maximum of a composite metric based on the silhouette coefficient score together with the elbow method. The primary endpoint was a composite of cardiovascular death or heart failure hospitalization at one year.

Results. 822 patients were included in the present analysis. The composite primary endpoint occurred in 250 (30%) patients. Four clusters with increasing risk of the primary endpoint were identified (20%, 25%, 37%

and 42% from cluster 4 to cluster 1, respectively). Clusters were combined into a high-risk (clusters 1 and 2) and a low-risk phenotype (clusters 3 and 4). High-risk phenotype patients had larger LVs (greater than 107 ml/m²), lower LVEF (less than 35%) and more prevalent ischemic etiology (51% to 60% vs. 30% to 40%) compared to low-risk phenotype patients. Moreover, within the high-risk group, patients with diabetes mellitus and with advanced age were at increased risk. Within the low-risk group, the ischemic etiology increased the risk of cardiovascular death, while permanent atrial fibrillation amplified that of HF hospitalizations.
Conclusions. We proposed a novel machine-learning analysis to identify meaningful clinical phenotypic presentations in FMR undergoing TVMR. We determined four clusters with increasing risk of cardiovascular death or heart failure hospitalizations.

A1000: A NOVEL HEMODYNAMIC INDEX CHARACTERIZING MITRAL REGURGITATION UNDERGOING TRANSCATHETER EDGE TO EDGE REPAIR: THE MITRAL PULSE PRESSURE FRACTION

Antonio Maria Leone (b), Federico Di Giusto (a), Katia Lucarelli (c), Andrea Viceré (a), Gianluca Anastasia (a), Domenico Galante (a, b), Edoardo Petrolati (a), Francesco Burzotta (a), Cristina Aurigemma (a), Antonella Lombardo (a), Gabriella Locorotondo (a), Francesca Graziani (a), Vito Casamassima (c), Massimo Grimaldi (c), Carlo Trani (a)
(a) UNIVERSITÀ CATTOLICA DEL SACRO CUORE - POLICLINICO A. GEMELLI IRCSS - ROMA; (b) OSPEDALE FATEBENEFRATELLI ISOLA TIBERINA - GEMELLI ISOLA; (c) OSPEDALE GENERALE REGIONALE F. MIULLI ACQUAVIVA DELLE FONTI

Objectives. Our study sought to investigate the role of invasive hemodynamic monitoring during Transcatheter Edge to Edge Repair (TEER) procedure on top of transesophageal echocardiographic (TEE) guidance.
Background. Direct hemodynamic impact of residual MR after TEER is not always univocally measured by TEE assessment alone. When analyzing TEER procedure result operators often encounter discrepancy between TEE guidance and invasive hemodynamic monitoring.
Methods. We analyzed 78 patients with moderate-to-severe or severe mitral regurgitation (MR) who underwent TEER. Mitral pulse Pressure Fraction (MPF) was extracted from intraprocedural continuous left atrial pressure monitoring. 23 patients with the same grade of MR not undergoing TEER were included as a control group.
Results. TEER had a significant impact reducing MR burden on both TEE guidance and invasive hemodynamic monitoring. Post-TEER MPF was significantly reduced compared to both pre-TEER setting (p<0.001) and control group (p=0.004). MR reduction assessed by TEE guidance was not found to be correlated with improved clinical and functional status at follow-up as assessed by New York Heart Association (NYHA) classification (p=0.424) and 12-items Kansas City Cardiomyopathy Questionnaire (KCCQ) (p=0.1). On the contrary, a greater reduction in MPF was associated with a significant amelioration of both NYHA classification (p=0.003) and 12-items KCCQ (p<0.001) during the follow-up period.
Conclusions. MPF provides an immediate estimate of the real hemodynamic impact of MR and can offer a prompt prediction of the functional improvement after TEER.

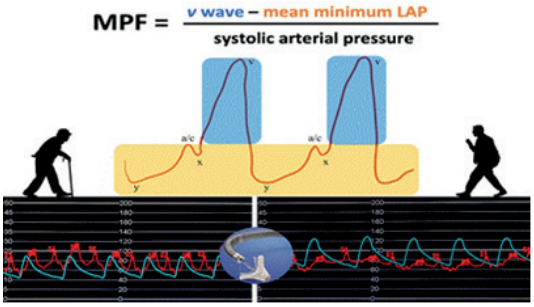

A1001: 10-YEAR EVOLUTION OF ISOLATED TRICUSPID REGURGITATION TREATMENT: SINGLE-CENTER EXPERIENCE

Irene Vitale (a), Nicola Buzzatti (b), Federica Gramegna (b), Nicolò Azzola Guicciardi (b), Paolo Denti (b), Francesco Ancona (d), Eustachio Agricola (d), Francesco Maisano (b), Michele De Bonis (b), Cosmo Godino (c), Alessandro Faggi (b), Guido Ascione (b)
(a) VITA-SALUTE SAN RAFFAELE UNIVERSITY; (b) IRCCS SAN RAFFAELE HOSPITAL, CARDIAC SURGERY UNIT; (c) IRCCS SAN RAFFAELE HOSPITAL, CARDIOLOGY UNIT; (d) IRCCS SAN RAFFAELE HOSPITAL, CARDIOVASCULAR IMAGING UNIT

Introduction. After decades of oblivion, tricuspid regurgitation (TR) has recently begun to receive increasing attention from the cardiological community, especially after the introduction of transcatheter tricuspid valve interventions (TTVI). The purpose of this work is to assess the evolution of TR treatment over the past decade and to evaluate the impact of the advent of transcatheter devices.
Methods. All patients admitted to our Cardiac Surgery Department with isolated moderate-severe or worse (≥3+) TR from January 2013 to December 2022 were retrospectively reviewed. Transcatheter tricuspid therapies started to be continuously performed since 2018, therefore patients within two timeframes before (2013-2017) and after (2018-2022) this timepoint were compared.
Results. Patients were similarly old (70 vs 73 years-old, P=0.22), high-risk (TRI-score 8 vs 8, P=0.60) and symptomatic (NYHA≥III 49% vs 52%) before and after the introduction of transcatheter therapies. In the 2018-2022 timeframe, the total number of admitted patients grew +79%, from 91 to 163 patients. The proportion of patients managed with guideline-directed medical therapy hence not receiving a procedure decreased from 31.1% to 13.4% (P<0.001). More surgical procedures were performed (59 vs 78, P<0.001) as well as transcatheter interventions (3 vs 58, P<0.001). In-hospital mortality decreased, although not significantly (7.8% vs 3.2%, P=0.11). Transcatheter patients were older (77.5 vs 65 years-old, P<0.001), higher-risk (TRI-score 14 vs 5, P<0.001), and more symptomatic (NYHA≥III 67% vs 40%, P=0.002) than surgical candidates. Despite patients' sicker profile, transcatheter procedures were associated with reduced mortality (0% vs 6.4%, P=0.05) and less post-operative complications (length of stay 7 vs 13 days, P<0.001) compared to surgery. Residual TR was more frequent after transcatheter interventions (TR>moderate in 34.5% vs 0%, P<0.001).
Conclusions. Over the past decade, after the introduction of transcatheter procedures in the clinical practice, the number of patients referred for TR correction has significantly increased. Despite a similarly severe clinical profile, more patients now receive an intervention and less (only 1/10) remain managed conservatively. Compared to surgery, transcatheter procedures are performed in sicker patients but are associated with reduced in-hospital mortality and complications, at the price of a more significant residual TR.

A1002: UPDATED DEFINITION OF PULMONARY HYPERTENSION AND OUTCOME AFTER TRANSCATHETER AORTIC VALVE IMPLANTATION

Federico Arturi (a), Francesco Cardaioli (a), Saverio Continisio (a), Giulia Masiero (a), Chiara Fraccaro (a), Luca Nai Fovino (a), Tommaso Fabris (a), Massimo Napodano (a), Aurora Trevisanello (a), Sabino Iliceto (a), Giuseppe Tarantini (a)
(a) DEPARTMENT OF CARDIAC, THORACIC, VASCULAR SCIENCES AND PUBLIC HEALTH, UNIVERSITÀ DEGLI STUDI DI PADOVA, PADOVA, ITALY

Objective: The European Society of Cardiology guidelines have recently defined new cut-offs for pulmonary hypertension (PH) and pulmonary vasculature resistance (PVR; median pulmonary artery pressure (mPAP)>20 instead of 25 mm Hg and PVR>2 instead of 3 Wood unit). The prognostic value of this updated classification after transcatheter aortic valve implantation (TAVI) is unknown.
Methods. 579 consecutive patients treated by TAVI with preprocedural right heart catheterisation evaluation were included. Patients were grouped as: (1) no PH, (2) isolated precapillary/combined (I-PreC/Co) PH and (3) isolated postcapillary PH (I-PoC). All-cause death, cardiovascular death and hospitalisations for heart failure (HF) were evaluated at follow-up. We also analysed the prognostic role of residual postprocedural PH.
Results. Out of 579 patients, 299 (52%) had PH according to the new criteria compared with 185 (32%) according to the previous ones. Overall median age was 82 years, while 55.3% patients were male. Patients with PH were more frequently diagnosed with chronic obstructive pulmonary disease and atrial fibrillation and were characterised by higher surgical risk as compared with patients without PH. At a median follow-up of 2.9 years, the presence of PH according to previous definition was associated with worse survival (p<0.001) (Fig 1.) and HF hospitalisation (p=0.002) rates, irrespective of PVR values. With newer cut-offs, PH was associated with worse outcomes only in patients with increased PVR, while no differences were found between patients with PH and normal PVR values and those without PH (Fig 2). Postprocedural mPAP normalisation was observed in 45% of the cases, but it was associated with improved long-term survival only in the I-PoC PH group.
Conclusions. New ESC PH cut-offs increased the number of PH diagnoses. The presence of PH, particularly in the setting of increased PVR, identify patients at higher risk for postprocedural mortality and rehospitalisation. Normalisation of PH was associated with better survival only in I-PoC group.

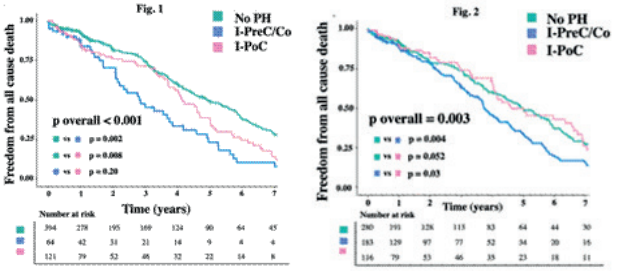

A1003: IMPACT OF INVASIVE RIGHT VENTRICULAR PARAMETERS AFTER TRASCATHETER MITRAL VALVE REPAIR

Federico Arturi (a), Giulia Masiero (a), Chiara Fraccaro (a), Luca Nai Fovino (a), Tommaso Fabris (a), Massimo Napodano (a), Francesco Cardaioli (a), Andrea Panza (a), Andrea Bertolini (a), Elisa Boscolo Soramio (a), Giulia Lorenzoni (b), Sabino Iliceto (a), Giuseppe Tarantini (a)

(a) DEPARTMENT OF CARDIAC, THORACIC, VASCULAR SCIENCES AND PUBLIC HEALTH, UNIVERSITÀ DEGLI STUDI DI PADOVA, PADOVA, ITALY; (b) UNIT OF BIOSTATISTICS, EPIDEMIOLOGY AND PUBLIC HEALTH, UNIVERSITÀ DEGLI STUDI DI PADOVA, PADOVA, ITALY

Background. Right heart catheterization is a common step in mitral valve transcatheter edge to edge repair (M-TEER) work-up. Right ventricle hemodynamic parameters has been identified as predictors of adverse outcomes in patient treated with M-TEER. We investigated the impact of right ventricle invasive hemodynamic indexes on adverse outcomes after M-TEER.

Methods. Out of 135 patients treated with MitraClip due to symptomatic severe mitral regurgitation (MR) between December 2014 and April 2023 at our facility, 59 underwent elective invasive right heart catheterization before transcatheter procedure. Pulmonary capillary wedge pressure (PCWP), mean pulmonary arterial pressure (mPAP) and right atrial pressure (RAP) were directly recorded during catheterization. Pulmonary artery pulsatility index (PAPi), pulmonary artery compliance (PAC), right ventricle stroke work index (RVSWi) and PCWP/RAP ratio were derived. The M-TEER procedure was performed according to current clinical practice. Follow-up was performed through outpatient visit or telephone call. The main outcomes of of interest were all cause mortality and hospitalization for heart failure (HFH).

Results. The median patients' age was 75 (69% men) with high prevalence of comorbidities as atrial fibrillation (68%), coronary artery disease (70%), arterial hypertension (81%), diabetes (24%) and dyslipidemia (62%). The mean LVEF was 46%. The most prevalent MR etiology was functional (49.2%). At a median follow-up of 2.5 ± 2.1 years, mortality rate was 48% and HFH rate was 30%. At the univariate analysis, among invasive variables, only PAC (Hazard Ratio HR 0.46, 95% Confidence Interval CI 0.24-0.87, p=0.018) was significantly associated with HFH. After checking for confoundings, patients with lower PAC had a significantly reduced risk of HFH (HR 0.34, 95% CI 0.12-0.96, p=0.042). Moreover, PCWP (HR 1.06, 95% CI 1.01-1.11, p=0.027), mPAP (HR 1.07, 95% CI 1.02-1.11, p=0.02), RAP (HR 1.14, 95% CI 1.04-1.25, p=0.006) and RVSWi (HR 1.10, 95% CI 1.01-1.18, p=0.021) were significantly associated with all cause mortality. After adjustment, only RAP remained independently associated with all cause mortality (HR 1.16, 95% CI 1.00-1.35, p=0.05). ROC analysis revealed that a cutoff value of 4.5 mm Hg of RAP had the best discriminatory value (92% sensitivity, 35% specificity, AUC 0.69) for 1-year survival (Fig 1). As a matter of fact, RAP values>4.5 mmHg was associated with a significantly 5-fold higher risk (HR 4.77, CI 1.11-20.47, p=0.035) of all cause mortality at long term follow up (Fig.2).

Conclusions. Our findings suggested that, among invasive hemodynamic RV parameters, RAP and PAC have a strong prognostic impact on all cause mortality and HFH in patients treated with M-TEER.

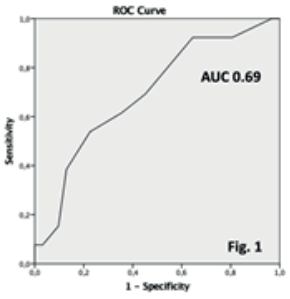

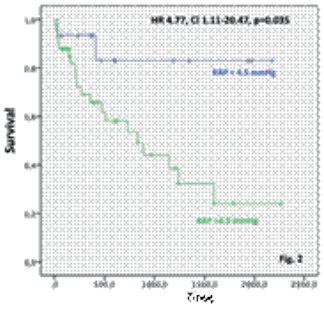

A1004: ROLE OF THREE-DIMENSIONAL (3D) INTEGRATED WILKINS SCORE WITH TRANSOESOPHAGEAL ECHOCARDIOGRAPHY IN THE RHEUMATIC MITRAL VALVE DISEASE UNDERGOING PERCUTANEOUS MITRAL COMMISSUROTOMY

Paolo Basile (a), Cataldo Davide Memmola (b), Mara Piccolo (b), Fulvio Bertrandino (a), Giorgia Falco (a), Alessio Falagario (a), Giovanni Addante (b), Vincenzo Pestrichella (b), Andrea Igoren Guaricci (a), Marco Matteo Ciccone (a), Sabino Iliceto (c)

(a) UO CARDIOLOGIA UNIVERSITARIA, DIPARTIMENTO INTERDISCIPLINARE DI MEDICINA (DIM), UNIVERSITÀ DEGLI STUDI DI BARI ALDO MORO, AOU POLICLINICO DI BARI, BARI; (b) UOC CARDIOLOGIA, MATER DEI HOSPITAL, BARI; (c) UNIVERSITÀ DEGLI STUDI DI PADOVA, PADOVA

Introduction. Rheumatic mitral valve disease (RMVD) remains a healthcare problem in low and middle-income countries. Nowadays, its prevalence is low in industrialized countries, although an increase was expected in the near future due to raised migratory flows. The percutaneous mitral commissurotomy (PMC) represents a well-established therapeutic option in selected patients. The three-dimensional (3D) transoesophageal echocardiography (TOE) is a valuable resource in the diagnostic workflow and during the intraprocedural phases of PMC.

Case presentation. A 34-years-old Moroccan woman, recently emigrated in Italy, was referred to our cardiologic ward for worsening dyspnoea. The TOE revealed the presence of a RMVD with a severe stenosis (mitral valve area: 0.8 cm^2; mean transvalvular gradient 25 mmHg) and an associated mild regurgitation. Moreover, the aortic and tricuspid valve were involved, with a fibrotic thickening without the severe stenosis or regurgitations. The left atrium was markedly dilated with a spontaneous echo contrast, in absence of thrombi. The Wilkins Score (WS) was 7, due to the normal mobility of the mid and base portions of leaflets, the mild thickening of subvalvular structures, the thickening and scattered areas of brightness restricted to the leaflet margins. In addition, the 3D TOE en face view of the mitral valve identified a mild fibrotic thickening of mitral annulus and a marked calcification of the valve commissures without asymmetry. A PMC was performed on the basis of the classic WS, despite commissures anatomy, under general anaesthesia and guided by real-time 3D TOE, with the evidence of an immediate post-procedural reduction of transvalvular gradient. However, the identification of an acute severe mitral regurgitation related to commissural flail after the balloon dilation required an urgent surgical mitral valve replacement with a mechanical prosthesis.

Discussion. The PMC is a valuable therapeutic approach for RMVD in selected cases. The immediate and long-term results are good with low procedural risks. However, a common complication is the onset of moderate-to-severe mitral regurgitation after the balloon dilation (1.4-9% of cases). The intraprocedural TOE plays a pivotal role in the guidance of the transseptal puncture, in the proper placement of the balloon and in the immediate evaluation of the results and permits a fast identification of complications. The 3D TOE is necessary for a more detailed morphological assessment of the mitral valve. In fact, 3D techniques provide a more exhaustive evaluation of valve planimetry, amount of leaflets calcification, the fusion of the subvalvular apparatus and the status of mitral annulus. The WS represents a useful tool in the identification of suitable mitral valves to PMC. The 3D-integrated WS, including the degree of annulus calcification, as well as of the commissures and their symmetry, was used for a more accurate evaluation of PMC feasibility in order to obtain a reliable selection of patients.

Conclusions. PMC is a therapeutic option in selected cases of RMVD, although sometimes unexpectedly complications may occur. 3D TOE should provide additional information in the diagnostic and therapeutic management as compared to bidimensional TOE, making PMC safer and more effective, which will be evaluated in our ongoing study.

A1005: RIGHT VENTRICULAR REMODELING FOLLOWING TRICUSPID TRANSCATHETER EDGE-TO-EDGE REPAIR

Sara Bombace (a, b), Sebastian Rosch (b), Anne R. Schöber (b), Maximilian Von Roeder (b), Florian Schlotter (b), Karl-philip Rommel (b), Christian Lücke (c), Matthias Gutberlet (c), Anna Sannino (d, e), Holger Thiele (a, b), Philipp Lurz (a, b), Karl-patrik Kresoja (a, b)

(a) LEIPZIG HEART SCIENCE, LEIPZIG, GERMANY; (b) DEPARTMENT OF INTERNAL MEDICINE/CARDIOLOGY, HEART CENTER LEIPZIG, LEIPZIG, GERMANY; (c) DIAGNOSTIC AND INTERVENTIONAL RADIOLOGY, UNIVERSITY OF LEIPZIG HEART CENTER, LEIPZIG, GERMANY; (d) FEDERICO II UNIVERSITY, NAPLES, ITALY; (e) BAYLOR SCOTT AND WHITE RESEARCH INSTITUTE, DALLAS, TEXAS USA

Background. The impact of tricuspid transcatheter edge-to-edge repair (T-TEER) on right ventricular (RV) remodeling is poorly understood.

Objectives. This study aimed to investigate the response of RV ejection fraction (RVEF) to T-TEER.

Methods. Patients with severe tricuspid regurgitation (TR) who underwent T-TEER and cardiac magnetic resonance (CMR) imaging were included. Post-intervention CMR imaging was performed 1 to 3 months after the procedure. The primary outcome was a composite of all-cause mortality or heart failure hospitalization.

Results. The study included 69 patients (median age 78 years; 54% females). Patients were categorized into three groups based on their RVEF changes: group 1 (46% of patients) with decreased RVEF, group 2 (39%) with stable RVEF, and group 3 (15%) with increased RVEF. Groups 1 and 2 showed significant reduction in TR, whereas group 3 exhibited worsening TR at follow-up. The change in RVEF after T-TEER was primarily driven by a mismatch between contractility and afterload. In group 1, afterload increased over contractility leading to decreased RVEF, while a decrease of afterload at stable contractility resulted in increased RVEF in group 3. Patients with stable RVEF showed a trend of increase in both contractility and afterload, leading to preserved coupling. During a median follow-up of 2.7 years, patients in group 3 had the worst outcome, while patients in group 2 had the lowest event rates (log rank p=0.004).

Conclusions. The response of the RV to T-TEER is complex and heterogeneous, mostly influenced by the progression of TR, baseline intrinsic RV function, RV-vascular interaction, and loading conditions.

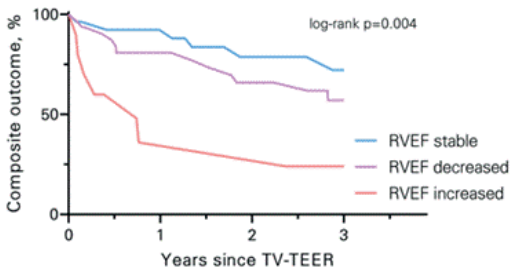

A1006: NON-CORONARY SINUS OF VALSALVA THROMBOSIS AFTER VALVE-IN-VALVE TRANSCATHETER AORTIC VALVE REPLACEMENT

Nicola Cangiano (a), Alberto Cresti (b)
(a) DIPARTIMENTO DI BIOTECNOLOGIE MEDICHE, DIAGNOSTICA CARDIOVASCOLARE, UNIVERSITÀ DEGLI STUDI DI SIENA, SIENA; (b) DIPARTIMENTO DI CARDIOLOGIA, OSPEDALE MISERICORDIA, GROSSETO

Background. Valve-in-valve transcatheter aortic valve replacement (VIV-TAVR) procedure has emerged as a successful non-surgical treatment in patients with degenerated bioprosthetic surgical aortic excluded from surgical re-do due to high operative risk. Thrombosis within a sinus of Valsava is a known complication after TAVI, but no case has been reported about sinus Valsava thrombosis after VIV-TAVR. We report a case of non-coronary sinus of Valsava thrombosis after VIV-TAVR.

Case presentation. A 79-year-old man was referred to our center because of atrial fibrillation. In 2007 he underwent aortic valve prosthetic implantation (with Carpentier Edwards Magna 23) because of severe aortic insufficiency on a bicuspid valve. In March 2022, a valve-in-valve supranular implantation with a CoreValve evolut R n°29 self-expanding bioprosthesis was performed due to a degeneration of the previous prosthesis. After about a month he developed atrial fibrillation so a transesophageal echocardiography examination (TEE) was performed. TEE showed a left atrial appendage without thrombosis but revealed a thrombosis of non-coronary sinus with a hypoechogenic/isoechogenic structure. To evaluate thrombosis extension and exclude other complications, a CT exam was performed that revealed a complete thrombosis of the non-coronary sinus.

Discussion and Conclusions. This is the first reported case describing thrombosis of the non-coronary sinus of Valsalva following VIV-TAVR. A similar case has been published in a patient with complete thrombosis of the non-coronary sinus and a partial thrombosis of the left coronary cusp after TAVR in the bicuspid aortic valve. Thrombus formation on the leaflets of the valve has emerged as a major issue in such procedures and the non-coronary sinus seems to be the site most affected by thrombosis; however, the reason is unknown. In recent studies, the physical mechanism of flow stasis in neo sinus after aortic valve replacement and the absence of sinus washout by coronary flow might explain a higher risk of thrombosis in the non-coronary sinus. No evidence is available concerning the treatment. Our patient was considered at high surgical risk, so medical treatment was chosen. He began non-fractionated heparin in parallel with the warfarin until the international normalized ratio(INR) value reached 2.0 -3.0 and then went on with warfarin alone until the next check. After 3-month sinus thrombosis was still present without an increase in size and other complications. During the follow-up period, our patient continued with oral anticoagulation without ischemic or hemorrhagic events.

A1007: EFFECT OF EDGE-TO-EDGE REPAIR ON MITRAL ANNULUS ANATOMY: RESULTS FROM VEGA INTERNATIONAL REGISTRY

Claudia Carassia (a, b), Marco Giovanni Mennuni (a), Anna Degiovanni (a, b), Giuseppe Patti (a, b), Simona De Vecchi (a), Alessandro Parodi (a), Leonardo Grisafi (a), Domenico D'Amario (a, b), Laura Fusini (a, b, c), Gianluca Pontone (c), Federico De Marco (c), Nicole Karam (d), Tania Puscas (d)
(a) DIPARTIMENTO TORACO-CARDIO-VASCOLARE, AOU MAGGIORE DELLA CARITÀ, NOVARA, ITALIA; (b) DIPARTIMENTO DI MEDICINA TRASLAZIONALE, UNIVERSITÀ DEL PIEMONTE ORIENTALE, NOVARA, ITALIA; (c) CENTRO CARDIOLOGICO MONZINO IRCCS, MILANO, ITALIA; (d) UNIVERSITÉ PARIS DESCARTES, HOPITAL EUROPEEN GEORGE POMPIDOU, PARIGI, FRANCIA

Background. Transcatheter edge-to-edge repair (TEER) is an emerging treatment option for mitral regurgitation (MR) using either Mitraclip and Pascal device. No extensive data are available on the impact of TEER on mitral valve geometry according to MR type. Moreover, Mitraclip implantation has already been shown to reduce mitral annular measures, whereas similar data after Pascal implantation are lacking.

Aims. Our aim is to evaluate the acute changes in mitral valve annular geometry by three-dimensional (3D) transesophageal echocardiography (TEE) after TEER according to the type of MR (degenerative, DMR, or functional, FMR) and the type of device (Mitraclip or Pascal).

Methods and Results. This international prospective Registry, involving 3 high-volume centers (Novara, Milan and Paris), enrolled 134 patients at high surgical risk (median EuroSCORE II 7.8%) undergoing successful TEER with Pascal (n=22, 16%) or Mitraclip (n=112, 84%) system. Patients were separately considered by etiology of valve dysfunction: n=54 (40%) with DMR and n=80 (60%) with FMR. 3D acquisitions of the mitral valve were obtained by TEE before and immediately after intervention. Mitral valve annular geometry was post-procedurally reconstructed using a Qlab software (R4.1; Qlab 10.3-Philips Healthcare). A post-TEER reduction of mitral valve annulus dimensions was mainly observed in patients having FMR compared to DMR (FMR group: antero-posterior (AP) diameter 40.5 mm vs. 36.9 mm, p<0.001; medio-lateral (ML) diameter 40.0 mm vs. 36.6 mm, p=0.013; annular area 15.5 cm^2 pre- vs. 14.5 cm^2 post, p=0.025; DMR group: AP diameter 44.4 mm vs. 41.8 mm, p=0.020; ML diameter 43.5 mm vs. 43.4 mm, p=0.855; annular area 14.2 cm^2 vs. 14.0 cm^2, p=0.754). After intervention the Pascal device was associated with decrease of AP diameter (34.5 mm pre- vs. 32.3 mm post-, p<0.001) and ML diameter (39.8 mm vs. 36.7 mm, p=0.031), without significant effect on annular area (11.9 cm^2 vs. 11.3 cm^2, p=0.213). The use of Mitraclip system resulted in reduction of AP diameter (40.7 mm pre- vs. 38.0 mm post-, p<0.001), but no change in ML diameter (44.7 mm vs. 43.5 mm, p=0.130) and annular area (15.5 cm^2 vs. 14.9 cm^2, p=0.112).

Conclusions. Besides by leaflets approximation, TEER with either Mitraclip and Pascal system reduces MR also by mitral annular geometry modification. This annuloplasty-like effect is more evident in patients with FMR; however, its impact in terms of clinical improvement and durability during follow-up needs to be demonstrated.

A1008: DUAL CORONARY SINUS PACING AND TRANSCATHETER TRICUSPIDAL VALVE-IN-VALVE PROCEDURE: AN ALTERNATIVE METHODOLOGY IN A YOUNG PATIENT WITH TRICUSPID BIOPROSTHESIS ENDOCARDITIS AND COMPLETE ATRIOVENTRICULAR BLOCK

Vincenzo Ezio Santobuono (a), Carella Maria Cristina (a), Marco Gentile (a), Annalisa Logiacco (a), Eugenio Carulli (c), Nicola Bozza (c), Paolo Basile (a), Cinzia Forleo (a), Emanuela De Cillis (b), Marco Matteo Ciccone (a), Andrea Igoren Guaricci (a)
(a) U.O.C. CARDIOLOGIA UNIVERSITARIA - A.O.U.C. POLICLINICO DI BARI; (b) U.O.C. CARDIOCHIRURGIA - A.O.U.C. POLICLINICO DI BARI; (c) U.O.C. CARDIOLOGIA E UTIC - P.O. MADONNA DELLE GRAZIE - MATERA

Introduction. One of the most common complications that tricuspid valve replacement (TVR) can result in is the occurrence of complete heart block, requiring permanent pacing. However, the transvalvular endocardial lead may interfere with the function of the prosthesis, making it necessary to find other sites for pacing. To the best of our knowledge, we present the first case of a combined electrophysiologic and hemodynamic procedure consisting of implantation of a univentricular bifocal pacemaker and repair of the valve defect by means of a transcatheter tricuspid valve (TVIV) in a young patient who had developed severe dysfunction of the tricuspid prosthesis, implanted for endocarditis, and resulting in the need for permanent pacing for a complete atrioventricular block (AVB).

Case presentation. A 30-year-old man underwent TVR with a bioprosthetic valve because of Streptococcus aureus endocarditis. Twenty-four days later, electrocardiogram (ECG) revealed complete AVB; therefore, a permanent dual-chamber pacemaker was implanted. During follow-up four years later, the echocardiogram showed prosthesis dysfunction, such that it resulted in severe steno-insufficiency. In addition, the patient had NYHA class III and presented with significant dyspnoea and liver congestion. Cardiac surgeons had judged redo surgery unfavourable, and leadless pacemaker implantation was not recommended because of the subject's young age. Due to patient's pacemaker dependence and the inability to implant a catheter through the diseased valve, a temporary pacemaker was implanted, then pacemaker generator and lead extraction from the right ventricle were performed. A coronary sinus (CS) venogram was performed to study its anatomy and identify an appropriate site for pacing. Two electrodes were implanted into two different branches of the CS by active fixation: a bipolar pacing lead was inserted in the anterior branch of the CS, while a quadripolar lead was inserted in the lateral ones. The leads, including the previously implanted right atrial lead, were connected to the biventricular pacemaker generator: bipolar lead for left ventricular pacing at the right ventricular site and quadripolar lead for left ventricular pacing at the left ventricle site. Finally, the temporary pacemaker lead was removed. Ultimately, univentricular bifocal pacing with two electrodes into two different branches of the CS was inserted. The valvular defect was repaired by TVIV with aortic bioprosthetic Edwards S3 29 mm. Prosthetic valve function was normal at the 1-year follow-up, and EF was 60%. NYHA class was II. Device interrogation revealed excellent pacing values, with threshold values below 1 V.

Discussion and Conclusions. Right-sided infective endocarditis (IE) accounts for 5% to 10% of all IE cases and is most often associated with intravenous drug use, intracardiac devices, and central venous catheters. One of the most common complications is valve insufficiency, which may require surgery, such as valve repair or replacement with a bioprosthesis or mechanical valve. Tricuspid valve (TV) surgery is associated with a

high risk of need for pacemakers postoperatively because of the intimate relationship between the TV and atrioventricular conduction tissue. Our case demonstrates how dual CS pacing via left ventricular lead can be used in selected cases other than cardiac resynchronization therapy, for example, in the presence of tricuspid valve replacement with mechanical prosthesis. It is a safe, effective, and very valuable treatment as an alternative to the traditional transvenous RV pacing.

A1009: IMPATTO DEL TRATTAMENTO CHIRURGICO DELL'INSUFFICIENZA MITRALICA SEVERA DA PROLASSO MITRALICO SULLE ARITMIE VENTRICOLARI

Luna Cavigli (a), Flavio D'Ascenzi (a), Alex Di Florio (a), Lorenzo Bonadiman (a), Maria Concetta Pastore (a), Giulia Elena Mandoli (a), Gianfranco Montesi (a), Serafina Valente (a), Matteo Cameli (a), Marta Focardi (a)
(a) DIPARTIMENTO DI BIOTECNOLOGIE MEDICHE, DIVISIONE DI CARDIOLOGIA, UNIVERSITÀ DI SIENA

Introduzione. Il prolasso valvolare mitralico (PVM) è una valvulopatia che talvolta può associarsi ad aritmie ventricolari complesse e a morte cardiaca improvvisa. Il PVM può associarsi alla presenza di disgiunzione dell'anello valvolare mitralico e di fibrosi evidenziabile tramite Late Gadolinium Enhancement (LGE) alla Risonanza Magnetica Cardiaca (RMC), in particolare a carico della parete inferolaterale basale e dei muscoli papillari. In letteratura sono presenti pochi dati riguardanti il trattamento dei pazienti con prolasso valvolare mitralico aritmico e, in particolar modo, non è chiaro se l'intervento chirurgico correttivo della valvulopatia mitralica possa avere un impatto significativo sulla riduzione del burden e della complessità aritmica.
Scopo. Lo scopo del nostro studio è stato quello di valutare l'impatto della chirurgia correttiva della valvola mitralica, nei pazienti con insufficienza mitralica severa da prolasso valvolare, sulle aritmie ventricolari in termini di complessità e di incidenza.
Metodi. Abbiamo valutato pazienti con insufficienza mitralica severa da prolasso valvolare con indicazione all'intervento di correzione chirurgica. Sono stati esclusi dal nostro studio pazienti che non rispettavano la definizione di prolasso, pazienti con concomitante CABG (Coronary Artery Bypass Graft)/ulteriore valvulopatia diversa dal PVM o affetti da cardiomiopatie, pazienti che hanno subito variazioni della terapia antiaritmica dopo l'intervento o, comunque, affetti da qualsiasi comorbidità pro-aritmogena. Tutti i pazienti arruolati nello studio sono stati sottoposti ad una valutazione preoperatoria comprensiva di ECG, ecocardiogramma, Holter ECG 24h a 12 derivazioni e RMC. I pazienti, inoltre, sono stati seguiti nel post-operatorio con rivalutazione Holter ECG 24h a 3-6 mesi dall'intervento.
Risultati. La popolazione finale era costituita da 23 pazienti sottoposti ad intervento correttivo per insufficienza mitralica severa con valvuloplastica e posizionamento di anello. Nel 26% dei pazienti sono stati riscontrati episodi preoperatori di aritmie complesse (tachicardia ventricolare sostenuta e non sostenuta). Nella popolazione analizzata non è stata riscontrata una riduzione significativa delle aritmie ventricolari, sia in termini di burden aritmico che di complessità dopo l'intervento chirurgico. Alla RMC il 56,5% dei pazienti presentava LGE dei muscoli papillari e/o della parete infero-laterale basale.
Conclusioni. I risultati del nostro studio hanno evidenziato che, nonostante la correzione chirurgica della valvulopatia mitralica, non ci siano state modificazioni significative in termini di complessità e incidenza delle aritmie ventricolari nel post-operatorio rispetto al preoperatorio. Questi dati preliminari suggeriscono che l'intervento chirurgico è sicuramente necessario per la correzione dell'insufficienza mitralica quando indicato, ma potrebbe non associarsi ad una riduzione del rischio aritmico in questi pazienti in quando esso sembra associarsi ad altre caratteristiche intrinseche del PVM.

A1010: THE ENIGMA OF TIMING FOR CARDIAC SURGERY IN INFECTIVE ENDOCARDITIS WITH CEREBROVASCULAR COMPLICATIONS AND BEYOND

Mihail Celeski (a), Laura Gatto (b, c), Gian Paolo Ussia (a), Francesco Grigioni (a), Francesco Prati (b, c)
(a) UNIT OF CARDIOVASCULAR SCIENCES, DEPARTMENT OF MEDICINE, CAMPUS BIO-MEDICO UNIVERSITY OF ROME, ITALY; (b) CARDIOVASCULAR SCIENCES DEPARTMENT, SAN GIOVANNI ADDOLORATA HOSPITAL, ROME, ITALY; (c) CENTRO PER LA LOTTA CONTRO L'INFARTO - CLI FOUNDATION, ROME, ITALY

Background. Infective endocarditis (IE) remains one of the most challenging entities due to its multisystemic presentation, high mortality, and paucity of randomized studies. Despite evidence of improved survival in IE patients with earlier surgical treatment, a significant proportion of patients with IE and neurological complications either undergo delayed surgery or do not have surgery at all, even when surgery is indicated, and guideline endorsed. However, the ideal timing for surgery in IE with preoperative neurological events remains controversial. Therefore, physicians and surgeons are caught in a common conundrum where the urgency of the heart operation must be balanced against the real or perceived risks of neurological exacerbation and cardiovascular deterioration.
Case summary. An 80-year-old woman, with hypertension and no significant history of heart disease, presented to the emergency department with dysarthria, mild ataxia, and mild right upper limb weakness. She presented eupneic, apyretic, with blood pressure 110/60 mmHg and oxygen saturation 99% in room air. The ECG showed sinus rhythm without conduction or repolarization abnormalities. Laboratory analysis revealed anemia, neutrophilic leukocytosis, rise and fall of the troponin curve (troponin peak 15757 ng/ml) and high C-reactive protein and procalcitonin levels. Trans-thoracic echocardiography (TTE) was performed that showed left ventricular inferior wall akinesia with ejection fraction of 40% and a 24 mm mobile vegetation on the aortic valve causing a moderate to severe aortic valve regurgitation. A few hours after, there was a worsening of the neurological symptoms and new onset of right lower limb weakness. The patient was referred for urgent cerebral computed tomography that revealed right cerebellar hypodense area. An empiric antibiotic therapy with vancomycin was initiated, switched to Ampicillin 12 gr/day and Ceftriaxone 2 gr twice a day after blood cultures became positive for Enterococcus faecalis. Another TTE and a trans-esophageal echocardiography revealed aortic vegetation with reduced dimensions (10 mm vs 24 mm). A cardiac surgery consultation has been requested for an urgent procedure which was denied because of the increased risk of cerebral hemorrhage in the actual clinical condition of the patient. Subsequently, the patient developed a high-grade atrio-ventricular block. Considering the presence of sepsis and IE, we opted for insertion of an active fixation transvenous pacing lead through a subcutaneous tunneled approach. Despite the improvement of infection parameters, after a week from the admission she developed a multiple organ failure that terminated with death.
Discussion. As illustrated in our case, delaying surgery may allow a longer duration of antibiotic therapy and reducing the risk of worsening neurologic symptoms, but incurs the risk of disease progression with valve destruction, heart block, embolic complications, and even death. We emphasize the significance of multidisciplinary 'endocarditis team' approach and the importance to refer complex IE patients to larger centers with advanced cardiac and neuro-interventional capabilities. The decision about surgical timing in patients with IE and stroke should be made considering the patient's hemodynamic status, risk of new or recurrent embolization, neurological deterioration, and cardiac complications. Imaging and improved risk-scoring models for IE may help to clarify the decision-making process. Although benefits of early surgery have emerged in the past decades, robust evidence in the future is required to resolve the controversies regarding the surgical indications for IE, especially in patients with neurological complications.

A1011: ETIOLOGICAL SPECTRUM OF LOW-FLOW AORTIC STENOSIS: CLINICAL CHARACTERISTICS AND OUTCOMES

Paola Cunsolo (a), Giorgio Fiore (a), Michele Morosato (a), Federico Biondi (a), Marco Gamardella (a), Margherita Fabris (a), Francesco Ancona (a), Stefano Stella (a), Giacomo Ingallina (a), Annamaria Tavernese (a), Davide Margonato (a), Martina Belli (a), Eustachio Agricola (a)
(a) IRCCS OSPEDALE SAN RAFFAELE

Aims. Low-flow aortic stenosis (LFAS) is characterized by stroke volume index (SVi) ≤35ml/m2. Prevalence and prognostic impact of different etiologies of LF remain currently unknown. Primary aim was to identify the specific etiological factors of LF and their prevalence in patients with LFAS. Secondary aim was to analyze their prognostic implications on outcomes: MACE (composite of all-cause mortality, hospitalizations due to HF, myocardial infarction, unscheduled coronary revascularization, cerebrovascular accident) and each single component.
Methods and Results. Retrospective, observational, monocentric study including consecutive patients with diagnosis of "LFLG aortic stenosis" by transthoracic echocardiography between December 2018 and December 2022. Etiology of LF was ascertained by two blinded experienced echocardiographers. When concomitant factors coexisted and no predominant cause of LF could be established, LF was ascribed to mixed etiologies. In patient with a follow-up time of at least 6 months, events were collected through revision of medical software systems records and via phone-calls. Univariate and multivariate Cox regression analyses were performed to assess the correlation with MACE and each single component. 257 patients (mean age 80±11 years, 50.6% female) were included. The most common cause of LF was EF<50% (n=141 patients, 55%, mean EF 34±8%). Among patients with EF≥50% (n=116, 45%) five etiologies were observed: (i) concentric remodeling with small LV cavity (n=43, 37.1%), defined by RWT>0.42 and LVEDVi<40 ml/m2; (ii) mixed forms (n=38, 32.8%); (iii) isolated significant mitral regurgitation (MR) (n=23, 19.8%); (iv) isolated significant tricuspid regurgitation (n=9, 7.8%); (v) significant isolated mitral stenosis (n=3, 2.6%). Patients with EF≥50% were more commonly female, had lower BSA and prevalence of CAD, higher EF and smaller LV volumes. Concerning treatment, 195 patients (76%) underwent aortic valve intervention (TAVR n=166, 65%; SAVR n=29, 11%) whereas 58 patients (23%) remained untreated and no information on treatment could be found for 4 patients (1%). Follow-up was completed for 177 patients. At a median follow-up of 11.5 (IQR 4.5 - 24.3) months, 102 patients reached the primary endpoint (57%). To-

tal mortality was 39% (n=69, n=40 due to cardiovascular causes) and 70 patients (40%) were hospitalized. At univariate analysis, no specific etiology of LF was associated with MACE nor with each single event. In the global population, predictors of MACE at univariate and multivariate analysis were CAD (adj. HR 1.62 (1.07-2.45), p<0.05) and MR (adj. HR 1.58 (1.02-2.44), p<0.04). Aortic valve intervention was the only protective factor for MACE (adj. HR 0.46 (0.30-0.70), p<0.001), drawn by a significant effect on all-cause mortality (HR 0.39 (0.24-0.64) but not on hospitalizations (HR 0.97 (0.56-1.68), p=0.9). Interestingly, AV intervention was associated with a reduced risk of cardiovascular mortality (HR 0.27 (0.11-0.63), p<0.001) and no effect on non-cardiovascular mortality (HR 0.42 (0.17 – 1.06), p 0.06).
Conclusions. In LFAS, EF<50% was the main cause of LF. In patients with EF≥50%, altered LV geometry and mixed forms were the main causes of LF. No single etiology of LF seemed to influence patient outcomes. Aortic valve intervention emerged as a strong protective parameter for MACE, total mortality and cardiovascular mortality.

A1012: RIPARAZIONE EDGE-TO-EDGE DELL'INSUFFICIENZA TRICUSPIDALICA CON SISTEMA TRICLIP: RISULTATI DELLO STUDIO TR-INTERVENTIONAL

Valeria Maria De Luca (a), Valeria Cammalleri (a), Myriam Carpenito (a), Giorgio Antonelli (a), Aurelio De Filippis (a), Maria Grazia Piscione (a), Edoardo Nobile (a), Anna Laura Di Pumpo (a), Massimilano Carassiti (a), Domenico Sarubbi (a), Francesco Grigioni (a), Ussia Gian Paolo (a)
(a) UNIVERSITÀ E FONDAZIONE POLICLINICO UNIVERSITARIO CAMPUS BIO-MEDICO DI ROMA

Background. L'insufficienza tricuspidalica (IT) è una valvulopatia con elevata prevalenza nella popolazione generale. Il 7% della comunità è affetta da IT moderata o severa, il 12% dei pazienti ospedalizzati per scompenso cardiaco. L'IT compromette la qualità di vita ed è associata ad un elevato burden di morbilità. La chirurgia tradizionale della valvola tricuspide ha un impiego limitato per l'alto rischio di mortalità ed è raccomandata solo in pazienti selezionati che devono sottoporsi a chirurgia valvolare del cuore sinistro o per pazienti sintomatici senza grave disfunzione del ventricolo destro. Sono state, pertanto, sviluppate molteplici tecniche di riparazione valvolare transcatetere per il rigurgito tricuspidalico, tra cui il sistema TriClip (Abbott Vascular, Santa Clara, CA, USA).
Metodi. Questo è uno studio prospettico di coorte condotto in singolo centro. Da marzo 2021 ad agosto 2023 abbiamo arruolato 35 pazienti consecutivi sottoposti a riparazione edge to edge dell'IT con sistema TriClip. Tutti i pazienti sono stati sottoposti a una valutazione preoperatoria con ecocardiografia transtoracica, utilizzando una stadiazione dell'IT a cinque gradi, e ad una valutazione ecocardiografica transesofagea. In tutti i pazienti è stato eseguito un follow-up clinico e strumentale a 30 giorni. 10 pazienti hanno eseguito un follow-up a 12 mesi.
Risultati. L'età media della popolazione di studio era di 79 ± 6 anni e il 77% erano femmine. Il 46% dei pazienti presentava IT severa (3+), il 40% IT massiva (4+) e l'11% IT torrenziale (5+). Il 57% dei pazienti presentava IT funzionale, il 23% lead induced, il 3% IT organica e nel 17% dei pazienti l'eziologia era mista. Il successo procedurale, definito come la riduzione dell'entità del rigurgito di almeno 1 grado, è stato raggiunto in tutti i pazienti. Non sono stati segnalati eventi avversi intra-ospedalieri. A 30 giorni di follow-up, tutti i pazienti erano vivi e non si sono verificati ulteriori ricoveri per riacutizzazione di scompenso cardiaco. La riduzione del grado di rigurgito si è dimostrata valida al follow-up ecocardiografico in associazione a un riferito miglioramento clinico e della qualità della vita.
Conclusioni. Nella nostra esperienza di singolo centro, la riparazione transcatetere edge to edge con sistema TriClip si è dimostrata un'opzione terapeutica valida e sicura in pazienti affetti da IT severa. Il follow-up eseguito a 30 giorni ha evidenziato che il sistema TriClip permette una riduzione del grado di IT con risultati stabili.

A1013: TRANSCATHETER MANAGEMENT OF TRICUSPID REGURGITATION: A TWO-YEAR SINGLE-CENTER EXPERIENCE

Guido Del Monaco (a, b), Carlo Andrea Pivato (a, b), Francesco Cannata (a, b), Stefano Figliozzi (a), Riccardo Mantovani (a), Renato Maria Bragato (a), Damiano Regazzoli (a), Ottavia Cozzi (a), Alessandro Sticchi (a, b), Bernhard Reimers (a), Giulio Giuseppe Stefanini (a, b), Gianluigi Condorelli (a, b), Antonio Colombo (a), Antonio Mangieri (a, b)
(a) CARDIO CENTER, IRCCS HUMANITAS RESEARCH HOSPITAL, 20089, ROZZANO, MILAN, ITALY.; (b) DEPARTMENT OF BIOMEDICAL SCIENCES, HUMANITAS UNIVERSITY, 20090, PIEVE EMANUELE, MILAN, ITALY

Introduction. Transcatheter treatment approaches have revolutionised the management of tricuspid valve regurgitation (TR). Here, we report a two-year single-centre retrospective cohort study to evaluate the safety, feasibility, and effectiveness of two innovative transcatheter systems, TriClip and TricValve, in managing TR.
Methods. A total of 18 patients with severe TR (72.2% female, mean age 77.7±10.3 years) were enrolled. Baseline patient data were collected over a two-year recruitment period, and outcomes were assessed during hospitalisation and at a six-month follow-up. A comparative analysis was conducted to compare baseline characteristics and outcomes between TriClip and TricValve.
Results. During the two-year enrolment period (January 2021-January 2023), 11 patients (61.1%) underwent the TriClip procedure, while seven (38.9%) received TricValve as initial treatment. At baseline, 89% exhibited New York Heart Association (NYHA) functional class 2 or 3, 11.1% presented ascites, and 83.3% displayed peripheral oedema, with no statistically significant differences between the two treatment groups. All patients had a history of atrial fibrillation. Additionally, there were no statistically significant differences between the groups regarding age, sex, prevalence of hypertension, diabetes, pulmonary disease, chronic kidney disease, history of ischemic heart disease, or peripheral vascular disease. Notably, patients undergoing TricValve had a higher prevalence of prior cardiac valve interventions (71.4% vs. 18.2%, p=0.048). Furthermore, the median values of the Society of Thoracic Surgeons (STS) and Euroscore II were higher in patients undergoing TricValve intervention (12.8 vs. 5.6, p=0.05; 8.8 vs. 3.5, p=0.003, respectively). The most frequent aetiology of TR was atrial functional (72.2%), with eight patients (44.4%) displaying mixed aetiology without any significant difference between the two groups. Acute procedural success in TriClip (defined as TR reduction to at least moderate) was achieved in 8 patients (72.8%), whilst all patients undergoing TricValve had correct post-procedural placement of the system without complication. During hospitalisation, all patients but one (who received TricValve and died due to septic shock after 15 days) had regular post-operative and were discharged without complications. At 6-month follow-up, 12 patients (70.5%) were uneventful, whilst five patients (29.5%) reported adverse events. One patient experienced non-cardiac-related mortality. Additionally, two patients experienced heart failure-related hospitalisation, one of whom underwent transcatheter mitral valve repair with MitraClip for severe regurgitation. Another patient was hospitalised for acute kidney injury. Lastly, one patient presented persistent heart failure symptoms with evidence of clip detachment at echocardiography, leading to subsequent intervention with TricValve for symptom management.
Discussion/Conclusions. Transcatheter interventions represent promising advancements in managing TR, offering less invasive alternatives to traditional surgical repair, particularly in cases where surgery poses an unacceptable risk. In our casuistic, TricValve was preferred in those patients with high surgical risk. Acute procedural success, mortality, and heart failure hospitalisation during post-operative stay and 6-month follow-up were consistent with results previously reported in the literature. No periprocedural deaths, conversions to surgery, device embolization myocardial infarctions, or strokes occurred.

A1014: PERIPROCEDURAL CHANGES OF NT-PROBNP ARE ASSOCIATED WITH SURVIVAL OR REHOSPITALIZATION AFTER TRANSCATHETER AORTIC VALVE IMPLANTATION

Daniel Ferraro (a), Sabato Sorrentino (a), Annalisa Mongiardo (a), Antonio Bellantoni (a), Assunta Di Costanzo (a), Alessandra Panarello (a), Federica Bruno (a), Vincenzo D'Ambrosio (a), Concetta Filardo (a), Filippo Bova (a), Filippo Fabio Valenti (a), Salvatore Giordano (a), Carmen Spaccarotella (b), Salvatore De Rosa (a), Ciro Indolfi (a)
(a) DIVISION OF CARDIOLOGY, DEPARTMENT OF MEDICAL AND SURGICAL SCIENCE, MAGNA GRAECIA UNIVERSITY, CATANZARO, ITALY; (b) DIVISION OF CARDIOLOGY, DEPARTMENT OF ADVANCED BIOMEDICAL SCIENCES,FEDERICO II UNIVERSITY, NAPLES, ITALY

Background. N-terminal pro–B-type natriuretic peptide (NT-proBNP) is a diagnostic and prognostic cardiovascular biomarker, especially in the field of heart failure (HF), and independently predicts adverse events in patients with acute coronary syndrome (ACS) as well as recurrences of atrial fibrillation. However, the effect of alterations in circulating NT-proBNP levels following transcatheter aortic valve implantation (TAVI) on patient survival remains uncertain. We aimed to evaluate whether periprocedural changes of NT-proBNP are associated with adverse events in patients after TAVI.
Methods. This is an observational, single-site registry, including patients with severe aortic stenosis undergoing TAVR from September 2009 to December 2022. Baseline demographic, clinical, and echocardiographic data and in-hospital and long-term clinical outcomes were systematically collected. Blood samples for the evaluation of NT-proBNP were taken at the admission and before discharge. Patients were divided into two groups based on their NT-proBNP–ratio defined as responders (NT-proBNP–ratio <1.1) and non-responders (NT-proBNP–ratio:>1.1). The primary outcome was a composite of death or re-hospitalization for HF. Baseline and in-hospital characteristics between the groups were compared using an independent-sample Student's t-test for continuous variables (presented as mean±SD) and the chi-square test for categorical or binary variables (presented as the number and percentage). Disparities in the primary outcome between the groups were appraised using a Cox proportional hazard model and expressed as adjusted hazard ratio (aHR) with 95% Confidence intervals (95% CIs).
Results. NT-proBNP levels at admission and at discharge were available in 419 patients with a median follow-up of 26.3 months (IQR 10.3-

36.6). Overall, 241 of 419 patients showed a postprocedural decrease in NT-proBNP levels (NT-proBNP ratio <1.1; responders). No differences in age and common cardiovascular risk factors were observed. The operatory risk was similar between the groups (Euroscore II: 5.47 vs. 5.34%, p=0.38), and no differences were observed among procedural variables, including valve-in-valve procedures, type of valve device implanted (self-expandable vs. balloon-expandable), secondary access preferred (femoral or radial), or closure device used (suture vs. plug-based devices). Left ventricle ejection fraction at baseline was higher in the non-responders group (50.57 ± 8.62 vs. 52.71 ± 8.22; p=0.01), which presents a smaller left atrial volume indexed (44.64 ± 10.75 vs. 51.03 ± 17.02; p<0.001) and pulmonary artery systolic pressure (40.31 ± 10.84 mmHg vs. 42.68 ± 12.00 mmHg; p=0.04). The length of the hospital stay was similar between the groups. In-hospital rates of stroke, pacemaker implantation, vascular access complications life-threatening or major bleeding, and mortality were comparable between responders and non-responders groups. At follow-up, non-responders patients had a higher incidence of mortality or rehospitalization for HF [aHR 1.74; 95% CIs (1.09-2.77)].

Conclusions. NT- proBNP ratio provides a simple and quick tool for better risk stratification and is associated with highly significant survival benefits and lower rehospitalization in patients after TAVI. In subjects in whom a reduction in NT- pro BNP values does not occur, closer follow-up should be attempted to optimize medical therapy.

A1015: INFLUENCE OF VALVE TYPE AND POST-BALLOONING ON HEMODYNAMIC PERFORMANCE OF TRANSCATHETER AORTIC VALVE-IN-VALVE PROCEDURE

Laura Fusini (a), Gloria Tamborini (a), Sarah Ghulam Ali (a), Paola Gripari (a), Valentina Mantegazza (a), Anna Garlasche´ (a), Marco Agrifoglio (a), Antonio Bartorelli (a), Federico De Marco (a), Gianluca Pontone (a), Mauro Pepi (a), Manuela Muratori (a)

(a) CENTRO CARDIOLOGICO MONZINO IRCCS

Purpose. Valve-in-Valve transcatheter aortic valve implantation (ViV-TAVI) is used as a therapeutic option for degenerated aortic bioprosthetic valves, particularly in patients with high or prohibitive surgical risk. The size and type of surgical valve and the etiology of structural valve deterioration, as well as valve implantation techniques, greatly influence the postprocedural gradients. Indeed, high post-procedural transprosthetic gradients are more common after ViV-TAVI than after TAVI for native-valve aortic stenosis. The aim of this study was to evaluate transprosthetic gradients (DP) and hemodynamic outcome in patients receiving or not balloon post-dilation with balloon- or self-expandable valve after ViV-TAVI.

Methods. A total of 111 consecutive patients who underwent ViV-TAVI were retrospectively included. Balloon-expandable valves were used in 35 patients (32%, Group 1), self-expandable valves in 76 cases of which 39 (35%, Group 2) without balloon post-dilation and 37 (33%, Group 3) with balloon post-dilation. Transthoracic echocardiography examinations were systematically performed at baseline, at hospital discharge, at 6-12 months follow-up.

Results. Successful ViV-TAVI was performed in 110 patients (99%). Baseline peak and mean DP, left ventricular volumes, ejection fraction, and pulmonary artery systolic pressure were similar among groups. There was no difference with respect to mechanism of degeneration among groups. A significant improvement in all echocardiographic parameters was observed over time in all groups. In particular, a significant reduction in postprocedural gradients was observed at discharge and at 6-12 months follow-up compared to baseline in all groups. At discharge, the lowest value of mean DP was observed in Group 3 (12±6 mmHg) compared to both Group 1 (20±9 mmHg) and Group 2 (18±9 mmHg, p=0.001). This result was confirmed at 6-months follow-up (p=0.010). Rate of small valve size (≤23 mm) implanted was similar among groups (Group 1: 78%, Group 2: 60%, Group 3: 62%, p=0.123). Similar all-cause mortality was observed among groups at 1-year (9%, 13%, 0%, respectively, p=0.090) and 5-year (34%, 31%, 14%, respectively, p=0.096).

Conclusions. In patients with failed surgical aortic prosthesis, ViV-TAVI is an effective option and provides good outcome with sustained improved hemodynamics regardless of transcatheter valve type and use of balloon post-dilation. Anyway, a self-expandable valve with balloon post-dilation is associated with lower transprosthetic gradients.

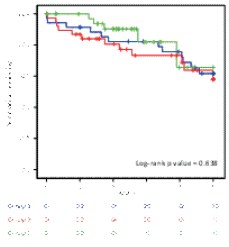

	Baseline	Discharge	6-12 Months	p Value
Group 1				
AVA, cm²	0.67±0.30	1.41±0.40*	1.37±0.31*	<0.001
Mean aortic ΔP, mmHg	41±18	20±9*	23±10*	<0.001
Peak aortic ΔP, mmHg	67±24	34±15*	39±16*	<0.001
PASP, mmHg	42±8	36±7*	36±9*	<0.001
Group 2				
AVA, cm²	1.00±0.53	1.82±0.54*	1.59±0.49*	<0.001
Mean aortic ΔP, mmHg	38±16	18±9*	19±11*	<0.001
Peak aortic ΔP, mmHg	63±28	32±16*	32±17*	<0.001
PASP, mmHg	44±13	34±9*	37±10*	<0.001
Group 3				
AVA, cm²	0.98±0.49	1.71±0.49*	1.55±0.48*	<0.001
Mean aortic ΔP, mmHg	36±15	12±6*	13±7*	<0.001
Peak aortic ΔP, mmHg	62±24	21±10*	24±11*	<0.001
PASP, mmHg	46±13	36±9*	33±9*	<0.001

A1016: INSIGHTS ON PATHOGENESIS, IMAGING, OUTCOME, AND CLASSIFICATION OF VALVULAR ANEURYSMS: A MULTICENTER STUDY

Domenico Galzerano (b), Maie Alshaid (b), Valeria Pergola (c), Antonella Moreo (d), Feras Khaliel (b), Olga Vriz (b), Eduardo Bossone (e), Lana Arbili (f), Abdalla Eltayeb (b), Bandar Alamro (b), Paolo Colonna (g)

(a) DOMENICO GALZERANO; (b) KING FAISAL SPECIALIST HOSPITAL AND RESEARCH CENTER; (c) UNIVERSITY OF PADUA; (d) NIGUARDA HOSPITAL; (e) UNIVERSITY OF NAPLES; (f) ALFAISAL UNIVERSITY; (g) AZIENDA OSPEDALIERA UNIVERSITARIA

Cardiac valvular aneurysms (VA) is a rare and life-threatening manifestation of the wide anatomical spectrum of infective endocarditis(IE) still understudied and challenging in the clinical and imaging arena.

Purpose. The goal of our study was to report on the etiopathogenesis, imaging features, and outcomes of VA

Methods. Our study was a 12-year retrospective observational multicenter study. Inclusion criteria were patients who were found to have VA by echocardiography by two independent expert reviewers. A VA was defined as a saccular bulging or a cyst-like outpouching of a valve leaflet that expands and collapses during systole or diastole.

Results. In a 12-year observational period, 27 pts (18 males and 9 females) were found to have VA. 14 of the patients were diagnosed with native mitral (M) VA, 13 with native aortic (AO) VA, and 1 with M bioprosthetic cusp VA. 25 pts patient had 1 and 2 pts 2 VA. There were 2 pts with VA on a bicuspid aortic valve both affecting the right coronary cusp. The most commonly affected AO valve cusp was the non-coronary cusp (NCC) while the anterior M leaflet was the most involved on M. We had 2 case of double VA 1 on M and one on AO valve; the pt with 2 Mitral VA had Infective endocarditis (IE) and associated AO valve IE with a jet of severe aortic regurgitation directed toward the AML. In 18 pts there was a history of IE. In five of these patients, blood cultures were negative. In the patient with definite IE, blood cultures were reported as positive in 13/18 patients (Staphylococci 7 pts, Pseudomonas 2 pts, streptococcus 3 pts). There was a case of VA in a patient with previous surgery for LA pseudoaneurysm. We had a never reported case of an aortic valve aneurysm post-car accident. VA were detected in two cases of bicuspid aortic valve. A VA of a bioprosthetic mitral valve without findings of IE was also found whose pathogenesis was likely related to degenerative phenomena. The most frequent associated IE anatomical features were perforation in 21 patients followed by vegetations in 15 patients. In a few cases, associated features were abscess, fistula; embolism have been diagnosed in 11 patients. Severe regurgitation was found in 21 patients (12 mitral, 9 aortic).14 patients underwent surgery (all of them had valve replacements except one had mitral valve repair). In an high percentage VA were misdiagnosed or not visualized by transthoracic echocardiography

Discussion. The findings of our series is widening the anatomical spectrum of VA with novel reports on number (double), location (posterior M valve leaflet, bicuspid AO valve, bioprosthesis) and etiopathogenesis (post traumatic) According to the etiopathogenesis VA can be classified as infective, degenerative, post-traumatic, and postsurgical and according to the location on native or bioprosthetic valve. Our series confirmed the prevalence of IE as the leading cause of VA. As VA are extremely rare, correct diagnosis is still challenging and frequently misinterpreted (differential diagnosis includes vegetations, tumors, clots, cystic lesions, annulus calcification/caseous degeneration and abscesses).

Conclusions. We reported the largest series of VA of 27 cases, the only aortic valve aneurysm case series ever described, and the second largest mitral valve aneurysm series, with never described features. VA by transthoracic E are frequently misdiagnosed. 2D TEE, integrated with 3D TEE allowed precise anatomical imaging. As the vast majority of cases with IE were associated worse clinical course with perforation, severe regurgitation, it is crucial to early recognize the characteristics of a VA for the optimal clinical making and surgical decision planning.

A1017: DIFFERENT SURGICAL TECHNIQUES FOR BICUSPID AORTIC VALVE REPAIR: A COMPARISON WITH EXERCISE ECHOCARDIOGRAPHY

Elisa Gherbesi (a), Claudia Romagnoni (a), Fabiola Sozzi (a), Lorenzo Miccoli (a), Andrea Faggiano (a), Alessio Maruccio (a), Rubina Rosa (a), Andrea Mangini (a), Guido Gelpi (a), Stefano Carugo (a)

(a) IRCCS CA' GRANDA OSPEDALE MAGGIORE POLICLINICO

Background. Numerous studies have highlighted the importance of commissural orientation in bicuspid aortic valve (BAV) repair, with angles less than 160° being associated with an increased risk of recurrent aortic valve insufficiency. A proposed approach involves aligning commissures to a 180°–180° geometric configuration. A porcine heart study suggested that while resting conditions did not significantly differ between the two valve configurations, during initial exercise stress, a 120°-oriented commissures demonstrated a higher mean transaortic gradient.

Aim. To assess the variation in transvalvular aortic gradients under exercise conditions between BAV repair patients with 180° commissure orientation and those without it, using exercise echocardiography.

Methods. Patients who underwent repair of a regurgitant bicuspid aortic valve between 2013 and 2022 were included. Surgical indications included severe aortic regurgitation (grade 4) with or without ascending

aorta dilation. Patients underwent exercise on a semisupine bicycle ergometer with gradually increased workload. Continuous 2-D Doppler echocardiography was used to measure transvalvular aortic gradients, and LVOT measurements were taken to derive aortic valve area (AVA) using the continuity equation.

Results. 13 male patients (mean age 44.5 ± 12.2 years) were included. 5 patients underwent a 180°-reimplantation technique, while 8 patients (non-180° group) underwent a non-180° reimplantation technique or annuloplasty with an external aortic ring. Ascending aorta replacement was performed as needed. No significant differences were detected between the 180° and non-180° groups:

- Mean gradient at rest: 10.8 ± 4.9 mmHg vs. 13 ± 4.3 mmHg (p=0.450)
- Peak exercise gradient: 21.6 ± 10.9 mmHg vs. 25.8 ± 9.4 mmHg (p=0.496)
- Variation of mean gradient: 5.2 ± 3.4 mmHg vs. 8 ± 5.6 mmHg (p=0.558)
- Variation of AVA: 0.34 ± 0.28 cm^2 vs. 0.07 ± 0.29 cm^2 (p=0.129)

Conclusions. In our study comparing exercise stress echocardiography outcomes in BAV repair patients with different techniques (commissural orientation of 180° vs. non-180°), no statistically significant differences were found. While these findings are based on a limited sample size, they challenge the notion of inherent superiority of one procedure over the other. Larger studies are recommended to further validate and expand upon these results.

A1018: TRICUSPID BIOPROSTHETIC VALVE FAILURE IN A YOUNG ADULT WITH HUGE ATRIAL DILATATION: HOW TO DEAL WITH IT

Sofia Hassan (a), Fabio Pescetelli (b), Vered Gil Ad (b), Roberta Della Bona (b), Manrico Balbi (a, b), Gabriele Crimi (b), Sergio Berti (e), Giuseppe Buscaglia (c), Francesco Santini (d, g), Margherita Castiglione Morelli (f), Italo Porto (a, b), Matteo Vercellino (b)

(a) DEPARTMENT OF INTERNAL MEDICINE (DIMI), UNIVERSITY OF GENOA, ITALY; (b) CARDIOLOGY UNIT, CARDIO-THORACIC AND VASCULAR DEPARTMENT, IRCSS OSPEDALE POLICLINICO SAN MARTINO, GENOA, ITALY; (c) CARDIOANESTHESIA AND INTENSIVE CARE, CARDIO-THORACIC AND VASCULAR DEPARTMENT, IRCSS OSPEDALE POLICLINICO SAN MARTINO, GENOA, ITALY; (d) CARDIAC SURGERY UNIT, CARDIO-THORACIC AND VASCULAR DEPARTMENT, IRCSS OSPEDALE POLICLINICO SAN MARTINO, GENOA, ITALY; (e) HEART HOSPITAL- FONDAZIONE C.N.R. REG. TOSCANA G. MONASTERIO, CARDIOLOGY DEPARTMENT, MASSA, ITALY; (f) DEPARTMENT OF RADIOLOGY, INTERVENTIONAL RADIOLOGY, IRCSS OSPEDALE POLICLINICO SAN MARTINO, GENOA, ITALY; (g) DEPARTMENT OD SURGERY AND INTEGRATED SCIENCE (DISC), UNIVERSITY OF GENOA, ITALY

A 54-year-old man presented with fatigue and reduced exercise tolerance that heavily affected his quality of life and working activity. Peripheral oedema and ascites emerged at physical examination. He has a remote history of drug abuse and tricuspid valve replacement due to infective endocarditis in 1998. Transthoracic/transesophageal echocardiography (TTE/TEE) and computed tomography (CT) were performed. Bio-prothesis presented severe stenosis (mean pressure gradient 15 mmHg) and moderate-to-severe regurgitation. Right ventricular function was mildly reduced. Severe dilatation (volume>500 ml) with left atrial compression and thrombosis of right atrium were also detected. A lung nodule turned out to be a non-small cell adenocarcinoma (NSCLC) with EGFR expression at biopsy. Control PET-CT showed a metastatic neoplastic disease. Patient was considered at high surgical risk, so stereotactic radiotherapy and targeted therapy with osimertinib (estimated mean survival>12 months) was started. Meanwhile, he was scheduled for transcatheter valve-in-valve (TVIV) intervention as a palliative treatment. A 29 mm Edward Sapien 3 (S329, Edwards Lifesciences) valve was planned to be implanted. Right femoral vein was used as working access. Under general anesthesia with TEE monitoring, degenerated prosthesis was crossed with a standard J-tip 0.035 guidewire and a pigtail catheter, supported with Agilis (Abbott Vascular Inc, CA, USA) steerable catheter 8.5 F. Then standard guidewire was exchanged with double system of pre-shaped wire in the right ventricle: Innowi wire (Symedrix GmbH, Germany) 25 mm and Safari small (Medtronic, MN, USA), as a buddy wire. The S329 was assembled on the delivery system, and it was advanced in the right atrium over the Innowi wire. To facilitate valve crossing, a peripheral 8.0x40 mm balloon was inflated over the Safari wire across the degenerated valve ("shoehorn" technique). The new valve was advanced beyond the degenerated valve annulus under fluoroscopic and TEE guidance. Then Safari wire and balloon were removed. Implantation was performed under rapid pacing directly over the wire. TEE and invasive gradient showed a good valve position with no significant leak and good hemodynamic results (decompression of left atrium and mean trans-valvular gradient of 4 mmHg). The patient was immediately extubated and transferred to ICU. He was discharged after a week with no in-hospital complications. Last TTE showed a stable mean pressure gradient and a trivial tricuspid regurgitation. This case shows that TVIV, adopting some technical precautions, is an easy, effective, and safe interventional procedure. Existing data include some alternatives about guidewire positioning (right ventricle vs pulmonary artery) and vascular access (femoral vein vs jugular vein). We chose to place both wires in the right ventricle through femoral vein, because it offered good coaxial alignment and more space for assemblement of the Edwards Sapien 3 delivery system. For this procedure, it was also paramount the use of double pre-shaped wire system and "buddy balloon" technique to easily cross the degenerated valve.

A1019: ATRIAL STRAIN AS A 'BAROMETRIC INDEX' OF CARDIAC FUNCTION IN SEVERE AORTIC STENOSIS

Luca Cristin (a), Elena Maria Santina Jannello (a), Paolo Springhetti (a), Luca Ciceri (a), Alessandra Roccabruna (a), Alberto Dotto (a), Leonardo Portolan (a), Roberto Scarsini (b), Flavio Luciano Ribichini (b), Giovanni Benfari (b)

(a) UNIVERSITÀ DEGLI STUDI DI VERONA; (b) DIPARTIMENTO DI CARDIOLOGIA, AZIENDA OSPEDALIERA UNIVERSITARIA INTEGRATA VERONA

Aim. Although the pathophysiological role of left atrial function (LAF) is well established in the setting of pressure overload, its determinants are not yet clarified. This study aims to evaluate the associations between peak left atrial strain (PALS) and possible echocardiographic determinants in patients with severe aortic stenosis (AS).

Methods. We retrospectively evaluated consecutive patients with established diagnosis of severe AS who undergone transcatheter aortic valve implantation (TAVI) between January 2021 and November 2021. Exclusion criteria were: permanent atrial fibrillation, severe mitral stenosis (MS), severe aortic regurgitation (AR), previous aortic valve intervention and poor acoustic window. Left atrial strain was evaluated with Tomtec Autostrain version TTA2®.

Results. One-hundred-six patients formed the final study cohort. The median age of the study cohort was 83 (IQR 79 - 87) years, and 56% were male. Almost all patients had NYHA ≥II, 14% had at least one syncopal episode, and 19% complained angina. Moreover, 32 patients (30%) had at least one hospital admission for acute heart failure. Among the most frequent comorbidities there were ischemic coronary artery disease (47%), type II diabetes (32%), and chronic obstructive pulmonary disease (10%). The median estimated glomerular filtration rate, according to the Cockcroft-Gault formula, was 53 ml/min. The mean left ventricular ejection fraction (LVEF) of the study cohort was 61 (IQR 54 – 68) % and more than mild mitral regurgitation was present in 17% of patients. PALS ranged from 3% to 48%, with a median of 23% (IQR 18.5 – 27.5%). The echocardiographic parameters associated with PALS were global longitudinal strain (GLS) (R =0.72, p<0.001), mitral annular plane systolic excursion (MAPSE) (R =0.67, p<0.001), left atrial volume index (LAVI) (R =0.44, p<0.001) and left atrial coupling index (LACI) (R =0.43, p<0.001). A strong correlation was observed between PALS and GLS among patients exhibiting no or mild mitral regurgitation (MR) (R =0.70; p<0.001). However, this correlation didn't reach statistically significancy in patients with coexistent moderate to severe MR (p=0.16). Furthermore, independently from LVEF and LAVI, PALS was associated with a more advanced NYHA class and at least one previous admission for AHF (adjusted HR 1.08 [CI 95% 1.01 – 1.15], p=0.03).

Conclusions. In the setting of aortic stenosis, PALS gathers information on left ventricular longitudinal function (MAPSE and GLS), mitral regurgitation and atrial geometry. Therefore, in this context PALS could be considered a "barometric index" of cardiac function. Additionally, LAF is independently associated to the symptomatic status providing important clinical information.

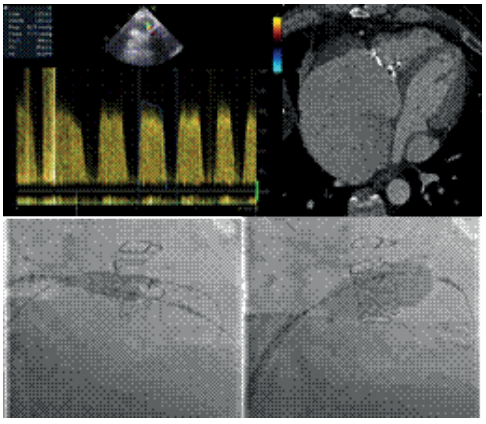

A1020: LONG-TERM SURVIVAL AFTER TAVR IN PATIENTS WITH LOW FLOW-LOW GRADIENT VS NORMAL FLOW-HIGH GRADIENT AORTIC VALVE STENOSIS

Francesco Cardaioli (a), Luca Nai Fovino (a), Tommaso Fabris (a), Giulia Masiero (a), Federico Arturi (a), Andrea Panza (a), Andrea Bertolini (a), Giulio Rodinò (a), Saverio Continisio (a), Massimo Napodano (a), Chiara Fraccaro (a), Giuseppe Tarantini (a)

(a) DEPARTMENT OF CARDIAC, THORACIC, VASCULAR SCIENCES AND PUBLIC HEALT, UNIVERSITY OF PADUA, PADUA, ITALY

Aims. In patients undergoing transcatheter aortic valve replacement (TAVR), the presence of low-flow low-gradient (LFLG) status has been associated with higher short-term mortality. We aimed to evaluate long-term survival after TAVR in patients with classical (cLFLG) and paradoxical (pLFLG) aortic stenosis (AS) compared to high-gradient stenosis (HG-AS).
Methods and Results. Patients undergoing TAVR at our center with a minimum 5-year follow-up were divided into three groups: 1) HG-AS (mean gradient [MG]>40 mmHg), 2) cLFLG-AS (MG <40 mmHg, EF <50%), and 3) pLFLG-AS (MG <40 mmHg, EF>50%). The primary endpoint of the study was all-cause mortality. Propensity score-weighted survival analysis was performed to adjust for possible baseline confounders. A total of 576 subjects were included (73% HG-AS; 15% pLFLG-AS, 11% cLFLG-AS). Patients with cLFLG AS were found to be significantly frailer with a greater number of comorbidities. In unadjusted survival analysis, patients with cLFLG-AS showed the worst long-term prognosis, with a rapid decrease in survival within the first year, while pLFLG and HG-AS presented similar survival rates (p=0.023). However, in the weighted long-term analysis, the three groups presented similar survival rates. Baseline EF was not correlated with long-term survival, but a significant correlation between post-TAVR LV-EF (>10%) improvement and survival time was observed (p=0.04).
Discussion. Our study yielded the following key findings: (1) Patients with cLFLG are typically frailer and sicker compared to the other AS groups. (2) Patients with cLFLG AS presented worse long-term unadjusted survival rates particularly within the first year after the procedure, while a parallel trend has been observed from the first year onward. (3) The worst long-term outcomes in cLFLG AS patients were likely due to higher baseline risk factors rather than the low-flow status itself. (4) Baseline LV-EF did not correlate with long-term prognosis in cLFLG AS patients, but early improvement in LV-EF post-TAVR was associated with longer survival. Our study, the first to evaluate outcomes of LF-LG extensively, reinforces previous findings indicating that TAVR outcomes in pLFLG AS patients closely resemble those in HG-AS patients, whereas individuals with cLFLG typically exhibit poorer unadjusted survival rates. However, our data were the first to highlight the possible relationship between the higher mortality of cLFLG patients and their poor baseline conditions. Moreover, as already shown by other previous analyses, we did not find a significant correlation between baseline LV-EF and post-procedural survival time. In summary, our study confirms the effectiveness and safety of TAVR in LFLG AS patients, highlighting the importance of adequate pre-procedural patient selection and screening.
Limitations. This study is a retrospective analysis with a limited sample size. Most patients were referred to our center after pre-procedural screening, thus data on LV contractile reserve are lacking. Excluding SAVR patients prevented further analyses on the interaction between LF-LG status and procedure type. The study only focused on all-cause death, and no data were reported on cardiovascular mortality.
Conclusions. cLFLG-AS patients presented worse unadjusted long-term post-TAVR survival rates compared to pLFLG-AS and HG-AS patients. However, after adjustment for possible baseline confounders, low-flow status per se did not impact post-procedural long-term mortality. Baseline LF-EF did not correlate with post-TAVR survival time, while early post-TAVR LV-EF recovery seemed to be associated with improved long-term outcomes.

A1021: PROGNOSTIC STRATIFICATION OF PATIENTS WITH MITRAL REGURGITATION UNDERGOING SURGICAL TREATMENT: A SPECKLE TRACKING STUDY

Maria Concetta Pastore (a), Federica Marrese (a), Lorenzo Tanzi (a), Matteo Lisi (b), Giulia Elena Mandoli (a), Andrea Stefanini (a), Martina Rizzo (c), Veronica Lorenz (e), Giuseppe Alba (e), Roxana Florea (d), Gianfranco Montesi (c), Luna Cavigli (a), Marta Focardi (a), Flavio D'Ascenzi (a), Matteo Cameli (a)
(a) DEPARTMENT OF MEDICAL BIOTECHNOLOGIES, DIVISION OF CARDIOLOGY, UNIVERSITY OF SIENA, SIENA, ITALY; (b) DEPARTMENT OF CARDIOVASCULAR DISEASE-AUSL ROMAGNA, DIVISION OF CARDIOLOGY, OSPEDALE S.MARIA DELLE CROCI, RAVENNA, ITALY; (c) DEPARTMENT OF CARDIOTHORACIC AND VASCULAR DISEASE, DIVISION OF CARDIAC SURGERY, UNIVERSITY OF SIENA, SIENA, ITALY; (d) EMERGENCY CLINICAL COUNTY HOSPITAL, ARAD, ROMANIA; (e) AORTIC SURGERY UNIT, SIENA UNIVERSITY HOSPITAL, SIENA, ITALY

Background. Mitral regurgitation (MR) is the second most common valvular heart disease (VHD) in Europe, for which the most resolutive treatment is surgical intervention. A careful preoperative evaluation of patients with MR is important to optimize the timing of intervention and avoid the possible complication after surgery. For this purpose, finding reliable prognostic markers to predict adverse outcome after mitral valve surgery may be fundamental. The aim of this study was to assess prognostic parameters, among basic and speckle tracking echocardiography (STE), including myocardial work (MW) parameters, in patients undergoing surgical treatment for MR.
Methods. We prospectively enrolled patients with severe MR who underwent preoperative clinical, biohumoral and echocardiographic evaluation, completed by STE, before mitral valve surgical repair or replacement. Patients with atrial fibrillation at the time of enrolment, previous cardiac surgery or other severe VHD were excluded. After surgery, patients were followed by on-site visits or phone calls to investigate clinical outcome. The primary endpoint was the occurrence of a composite endpoint (heart failure hospitalizations and all cause-mortality), the secondary endpoint was the assessment of postoperative functional capacity assessed by NYHA class and Borg CR10 and of postoperative hospitalization length.
Results. Among 110 patients (65±13 years), 10 patients reached the primary endpoint (7 deaths and 3 hospitalizations for heart failure). The population presented a preserved left ventricular ejection fraction (58±4%) and dilated left atria (55 ±19 ml/m^2). Among strain variables, there was a reduction of mean peak atrial longitudinal strain (PALS)=22%±8, a mild reduction of mean free wall right ventricular longitudinal strain (FW-RVLS)=-22.3% ± 7.6, and normal left ventricular strain=-20.4% [-17.5 to -22.8]. MW parameters was nearly normal (global work index=1927 ± 573 mmHg%, mean global wasted work (GWW)=243 ± 156 mmHg%). Patients who had events presented lower PALS and FWRVLS values compared with patients without events. Receiver operating characteristic (ROC) curves revealed as optimal cutoff values for PALS ≤21.5% and FW-RVLS ≥-22% for the prediction of the primary endpoint, which was used to divide the population into three groups according to both preserved PALS and FWRVLS, preserved either PALS or FWRVLS ad both reduced PALS and FWRVLS. Event-free survival analysis by Kaplan Meier curves showed a good risk stratification for the three groups (Fig.1). Regarding the functional capacity in the postoperative period (secondary endpoint), it was found that GWW was the only parameter associated with NYHA class>II at follow-up (p=0.04)
Conclusions. The use of speckle tracking through a combined evaluation of global PALS and FWRVLS offers a reliable prediction of unfavorable outcomes in patients undergoing mitral surgery for severe MR.



A1022: PREDICTIVE VALUE OF THE TRI-SCORE FOR IN-HOSPITAL STAY AFTER TRICUSPID TRANSCATHETER EDGE-TO-EDGE REPAIR. SINGLE CENTER EXPERIENCE.

Mariagrazia Piscione (a), Dario Gaudio (a), Valeria Cammalleri (a), Valeria Maria De Luca (a), Giorgio Antonelli (a), Myriam Carpenito (a), Edoardo Nobile (a), Aurelio De Filippis (a), Francesco Grigioni (a), Gian Paolo Ussia (a)
(a) FONDAZIONE POLICLINICO UNIVERSITARIO CAMPUS BIOMEDICO

Background. TRI-SCORE is a dedicated risk score model based on eight simple parameters to guide the clinical and therapeutic decision-making for patients with severe TR, considering that it predicts mortality after isolated tricuspid valve surgery. The aim of this study is to analyze if there is a correlation between TRI-SCORE values and the duration of hospitalization, in-hospital clinical adverse events and mortality in patients with severe TR undergoing transcatheter edge-to-edge repair (TEER).
Methods. The study enrolled 35 consecutive patients who underwent TEER of TR with the TriClip device (Abbott Vascular, Santa Clara, CA, USA) from March 2021 to August 2023 at Fondazione Policlinico Universitario Campus Biomedico of Rome. The study population was divided in three groups based on the TRI-SCORE: low risk (<3), intermediate risk (4-5) and high risk (>6). Moreover, demographic data, the STS score and Euroscore II were calculated. The duration of the hospitalization after the procedure, as well as in-hospital clinical adverse events and mortality at 12 months were recorded.
Results. The mean age of our study cohort was of 78.77±6.15 years and 23% of patients were males. The mean TRISCORE was 5.43±1.84, whereas the STS score and EuroScore II were 7.32%±6.15 and 7.19%±4.11, respectively. The procedural success, defined as reduction by at least one grade of TR, was achieved in all patients and maintained during the follow-up. The low-risk group (TRI-SCORE<3) was composed of 5 patients (14%), 20% of them were males; their mean age was 73.4±6.27 years, the STS score and the Euroscore II were 9.12%±4.58 and 6.63%±3.19, respectively. In the intermediate-risk group (TRI-SCORE 4-5), 16 patients (46%) were included, 19% were males, the STS score and the Euroscore II were 6.26%±4.61 and 7.12%±4.93, respectively. The high-risk group (TRI-SCORE>6) was composed of 14 patients (40%) with a mean age of 78.79±5.49 years, 28% males, with a STS score and Euroscore II of 7.88%±3.15 and 7.47%±3.59, respectively. The duration of hospitalization in the entire population was 4.49±1.44 days. It increased according to the risk estimated with the TRI-SCORE, even if not statistically significant. Specifically, the in-hospital stay after the procedure was 4.2±1.09 days in the low-risk group, 4.25±1.57 days in the intermedia-

te-risk group, 4.86±1.41 days in the high-risk group (p=0.474). No clinical in-hospital adverse events were recorded and only one patient died 15 months after the intervention of Sars Cov-2 pneumonia.
Conclusions. TRISCORE, commonly obtained to predict mortality after isolated tricuspid valve surgery, was associated with the in-hospital duration stay for the first time. In our cohort, patients with the highest TRISCORE had a long in-hospital stay, even though statistical significance was not reached.

A1023: LA TCC COME PREDITTORE DEL RISCHIO CARDIOVASCOLARE NEI PAZIENTI CON STENOSI VALVOLARE AORTICA SEVERA DEGENERATIVA-CALCIFICA CON INDICAZIONE A CORREZIONE.

Maria Teresa Savo (a), Riccardo Bariani (a), Morena De Amicis (a), Elena Cozza (a), Filippo Amato (a), Marika Martini (a), Piero Sonego (a), Giorgio De Conti (a), Ilaria Rigato (a), Giulia Mattesi (a), Barbara Bauce (a), Raffaella Motta (a), Sabino Illiceto (a), Valeria Pergola (a)
(a) AZIENDA OSPEDALE UNIVERSITARIA PADOVA

Background e scopi. La tomografia cardiaca computerizzata (TCC) attualmente svolge un ruolo fondamentale nel planning pre-procedurale della correzione della stenosi valvolare aortica (SVA) degenerativa-calcifica, tuttavia il suo ruolo prognostico nella valutazione di mortalità ed eventi cardiovascolari maggiori (MACE) dopo sostituzione valvolare (SV) non è stato esaustivamente esplorato. La TCC consente di valutare le calcificazioni delle arterie coronariche (CAC), dell'anello mitralico (MAC), della valvola aortica (CVA) e dell'aorta toracica (CAT). Scopo del nostro studio è stato valutare se la presenza e l'estensione delle CAC, MAC, CVA e CAT possano influenzare la mortalità non cardiovascolare (MNC), mortalità cardiovascolare (MC) e MACE in pazienti sottoposti a SV.
Materiali e metodi. Abbiamo condotto uno studio retrospettivo, valutando 244 pazienti con SVA sottoposti tra il 2016 e il 2018 a SV chirurgica o transcatetere, raccogliendo dati clinici e strumentali e revisionando la TCC con un approccio semiquantitativo. Le CAC sono state classificate seguendo il sistema di valutazione visiva proposto nel 2022[1]. Le MAC sono state definite secondo lo studio di Guerrero et al.[2], le CVA secondo il Win Registry[3], le CAT sono state valutate a livello dell'aorta ascendente, dell'arco aortico e dell'aorta discendente secondo la classificazione di Vos[4].
Risultati. La nostra popolazione è formata da 244 pazienti **(**M=59%, età media 80.1±6.6anni), di cui il 91% è stato sottoposto a SV transfemorale. Per ogni paziente è stato stimato il rischio cardiovascolare con l'EuroSCOREII (4.1 ± 4.6) e STSSCORE(5.2 ±4.3). In merito ai fattori di rischio, la MC è risultata significativamente maggiore nei pazienti con ipertensione, vasculopatia cerebrale/periferica, insufficienza renale IV-V stadio e storia di fibrillazione atriale (p=0.012, p<0.001, p=0.005, p=0.034 e p=0.024). La MC inoltre è risultata più rilevante nei pazienti con STS SCORE ≥6.7±5.2 e EuroSCORE II≥5.5± 5.8 (p=0.016 e p=0.037). La presenza di estese CAC (p=0.019), di MAC score>7 (p=0.051), di CVA moderate e severe (p=0.029, p=0.053), di CAT>270° all'arco aortico (p=0.019) sono risultati statisticamente associati ad MC. All'analisi multivariata, il MAC score>7 e la presenza di CVA almeno moderate persistevano come fattori di rischio per MC. La presenza di MAC score>7 (p=0.006) e l'estensione delle CAT discendente per ≥1,5 mm(p=0.034) erano associate a un significativo aumento del rischio di MNC. La MNC inoltre è risultata più rilevante nei pazienti con STS SCORE ≥6.2±5.1 e EuroSCORE II≥5.1± 6 (p<0.001 e p=0.003). La presenza di estensione di CAT ≥270°misurata a livello dell'arco aortico e dell'aorta discendente, sono risultati associati ad un elevato rischio di MACE (p=0.034 e p=0.0504).
Conclusioni. La TCC rappresenta uno strumento prezioso nel valutare il rischio di MC, MNC e MACE nei pazienti con SVA degenerativa-severa sottoposti a SV, aiutando i clinici nella pianificazione pre-procedurale, consentendo una migliore identificazione dei pazienti ad alto rischio e un'ottimizzazione delle strategie terapeutiche.
References

Cury RC et al. 2022 Coronary Artery Disease-Reporting and Data System: An Expert Consensus Document of the Society of Cardiovascular Computed Tomography, the American College of Cardiology, the American College of Radiology, and the North America Society of Cardiovascular Imaging. J Cardiovasc Comput Tomogr. 2022.
Guerrero M. et al. A Cardiac Computed Tomography–Based Score to Categorize Mitral Annular Calcification Severity and Predict Valve Embolization. JACC Cardiovasc Imaging. 2020
Spaziano M et al. Computed tomography predictors of mortality, stroke and conduction disturbances in women undergoing TAVR: A sub-analysis of the WIN-TAVI registry. J Cardiovasc Comput Tomogr 2018
Vos A, Houben IB, Celeng C, et al. Aortic calcification: A postmortem CT validation study in a middle-aged population. Eur J Radiol. 2023

A1024: TRANSEPTAL BALLOON-ASSISTED TRANSLOCATION OF THE MITRAL ANTERIOR LEAFLET (BATMAN) IN PATIENT UNDERGOING MITRAL VALVE-IN-RING IMPLANTATION

Francesco Tartaglia (a, b), Angelo Oliva (a, b), Antonio Mangieri (a), Ottavia Cozzi (a, b), Renato Bragato (a), Alessandro Sticchi (a), Giulio Giuseppe Stefanini (a, b), Bernhard Reimers (a), Antonio Colombo (a), Damiano Regazzoli (a)
(a) CARDIO CENTER, HUMANITAS CLINICAL AND RESEARCH HOSPITAL IRCCS, ROZZANO, MILAN, ITALY; (b) DEPARTMENT OF BIOMEDICAL SCIENCES, HUMANITAS UNIVERSITY, PIEVE EMANUELE, MILAN, ITALY

Introduction. Transcatheter mitral valve replacement (TMVR) is increasingly used for patients with degenerated mitral valve at high surgical risk, but it is associated with specific procedural complications, including left ventricular outflow tract (LVOT) obstruction. Laceration of the anterior mitral leaflet to prevent outflow obstruction (LAMPOON) technique can be used to prevent LVOT obstruction, but some anatomies may not be suitable for it.
Case presentation. A 49-year-old man was referred to our institution for symptomatic heart failure. He had history of post-actinic valvular heart disease for previous Hodgkin's lymphoma treatment and in 2015 underwent surgical aortic valve replacement with mechanical prosthesis On-X (Artivion), mitral valve annuloplasty with a Carpentier-Edwards Physio II 28 mm ring and pericardial patch anterior leaflet extension. Echocardiography showed severe mitral regurgitation and stenosis (mean gradient 13 mmHg), significant pulmonary hypertension and right ventricle dysfunction (Figure 1A). Patient was deemed at prohibitive surgical risk for re-do cardiac surgery and scheduled for transcatheter mitral valve-in-ring implantation. Because of the high risk of left ventricle outflow (LVOT) obstruction, an anterior leaflet modification procedure was planned (Figures 1B to 1C). LAMPOON was excluded because severe calcifications of the anterior leaflet patch would impede adequate laceration. Therefore, we planned a transeptal balloon assisted translocation of the mitral anterior leaflet (BATMAN). The procedure was performed under general anesthesia with periprocedural VA-ECMO, for the anticipated risk of hemodynamic deterioration after leaflet disruption. Embolic protection device Sentinel (Boston Scientific) was placed. Through a 18Fr Dryseal (Gore Medical) introducer sheath from right femoral vein, an infero-posterior septostomy was performed with a 14×40 mm peripheral balloon. A coaxial system composed of a 0.014 inch microcatheter Finecross (Terumo), a 7Fr internal mammary catheter and the steerable introducer Agilis M (Abbott Vascular) was utilized to puncture the anterior mitral leaflet in the mid-point between annulus and A2 segment using an electrified Astato XS 20 wire (Asahi Intecc Medical) (Figures 1D to 1E). Valver 18 mm balloon (Balton) was inflated within the leaflet to determine anterior leaflet translocation and Edwards-Sapien 3 Ultra 26 mm was then deployed with immediate good result (Figures 1F to 1G). Iatrogenic atrial septal defect was closed with a 13.5 mm ASD occluder (Occlutech GmbH). The patient was promptly weaned from ECMO and extubated at the end of the procedure, without any adverse event. Postprocedural echocardiography showed a mean gradient of 7 mmHg, absence of paravalvular leak and no LVOT obstruction (maximum gradient 12 mmHg). (Figures 1H to 1I)
Discussion. BATMAN technique with transapical approach has been proposed as an effective alternative to LAMPOON for preventing LVOT obstruction, and possibly providing a sealing effect to minimize paravalvular leak. To our knowledge, this is the first reported case of a fully transeptal BATMAN procedure, representing a novel less-invasive option for patients requiring transcatheter mitral valve replacement at high risk of LVOT obstruction.

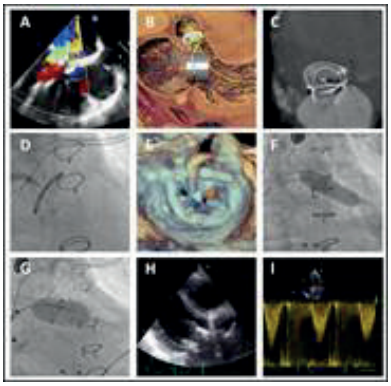

A1025: ELIGIBILITY OF COAPT TRIAL IN DAILY PRACTICE: A REAL WORLD EXPERIENCE

Edoardo Zancanaro (a), Nicola Buzzatti (a), Nicolo Azzola Guicciardi (a), Paolo Denti (a), Eustachio Agricola (a), Francesco Ancona (a), Francesco Maisano (a)
(a) SAN RAFFAELE HOSPITAL

Background. The COAPT Trial was the first ever to demonstrate a survival benefit in treating functional mitral regurgitation (FMR). That was achieved through transcatheter mitral repair in selected patient. The exact proportion of patients fulfilling COAPT selection criteria in the real-world is unknown.
Objectives. To assess the applicability of COAPT criteria in real-world and its impact on patients' survival.

Methods. We assessed the clinical data and follow-up results of all consecutive patients admitted for FMR at our Department between January 2016 and May 2021 according to COAPT eligibility. COAPT eligibility was retrospectively assessed by a cardiac surgeon and a cardiologist.
Results. Among 394 patients, 56 (14%) were COAPT eligible. The most frequent reasons for exclusion were MR<=2 (22%), LVEF <20% or>50% (19%), and non-optimized GDMT (21.3%). Among NON-COAPT patients, weighted 4-year survival was higher in patients who received MitraClip compared to those who were left in optimized medical therapy (91.5% (CI: [0.864, 0.96] vs 71.8% (CI =[0.509, 0.926]) respectively, p=0.027)
Conclusions. Only a minority (14%) of real-world patients with FMR referred to a tertiary hospital fulfilled the COAPT selection criteria.

A1026: TRANSCATHETER MITRAL VALVE REPLACEMENT (TMVR): WHAT ARE THE OUTCOMES IN UN-ELIGIBLE PATIENTS?

Edoardo Zancanaro (a), Nicolo Azzola (a), Nicola Buzzatti (a), Francesco Ancona (a), Francesco Maisano (a), Eustachio Agricola (a)
(a) SAN RAFFAELE

Aims. Transcatheter mitral valve replacement (TMVR) is emerging in recent years as a promising tool to treat mitral regurgitation, however its applicability in the real world remains limited. The aim of the study is to assess the real-world screening success rate of TMVR in native anatomy and the 1-year outcomes of both accepted and refused patients.
Methods and Results. A retrospective analysis was performed on all patients screened for TMVR at our Valve Center, eligible for 1-year follow-up. In-hospital data of all patients admitted to our Department are prospectively collected. Out of 3400 patients referred to mitral treatment at our department between January 2016-January 2022, 92 were submitted to screening for TMVR. Among these, 48 patients (49%) were accepted and treated with TMVR while 44 (44.8%) were refused (RG). The main reasons for rejection were anatomy unfeasibility in 25 patients (59%) and frailty in 5(11%). Main reasons for anatomy unfeasibility were risk LVOT obstruction (n=15; 60%), annular dimension (n=8; 33%) and ventricular dimension (n=2; 8,3%). All patients accepted were treated with TMVR: 7 patients received Tiara and 24 Tendyne. Procedure success in the TMVR group was 96% (46/48). 1-year overall survival 65.2±51.3 vs 54.8±36.5 in TMVR and refused group respectively (p=0.002). 6 deaths (2 cardiac, 33%) occurred in the TMVR compared to 37 (32 cardiac, 86%) in the refused group, (p=0.006). NYHA class improved in 98% of cases in TMVR group but worsened in 80% in refused group, (p<0.001). TMVR screening failure was is associated with increased cardiac death (HR 12 [1,51;95], p<0,019) and death for any causes (HR 17,5 [6,02;51], p<0,001).
Conclusions. In the present experience, approximately 50% of patients screened for TMVR were accepted. The most frequent reasons for screening failure were anatomical issues. With a baseline similar clinical profile, treatment with TMVR provided significant 1-year survival and symptoms improvement compared to those of patients refused, whose prognosis is indeed remarkably poor. These data underline the importance of proper patient selection for TMVR to achieve good outcomes but also the need for technological improvement of devices to expand the proportion of patients who can be treated.

A1027: OUTCOME IMPROVEMENT WITH SECOND GENERATION DEVICE FOR TRANSCATHETER EDGE-TO-EDGE REPAIR IN SEVERE MITRAL REGURGITATION

Mattia Alexis Amico (a), Chiara Piazzai (a), Guido Grossi (a), Gherardo Busi (a), Matteo Vannini (a), Filippo Bruscoli (a), Angela Migliorini (a), Daniele Landi (a), Francesco Meucci (a), Renato Valenti (a), Carlo Di Mario (a), Nazario Carrabba (a)
(a) CAREGGI UNIVERSITY HOSPITAL (AOUC), FLORENCE

Background. Severe mitral regurgitation (MR) is closely associated with heart failure and worse clinical outcomes. Current ESC guidelines recommend Transcatheter Edge-to-Edge Repair (TEER) for aging and inoperable or high-risk patients, with improved survival rates after successful procedure. Technological improvements of second-generation MitraClip device together with the enhancement of procedural skills may explain the better outcomes observed during the last years.
Objective: We aim to compare the efficacy and safety of TEE using second-generation devices in contrast to the first ones in our tertiary center. The primary endpoints were the evaluation of the improvements with a second-gen device in reduction of MR severity, time to device, hospitalization time, complications procedure according to Mitral Valve Academic Research Consortium (MVARC), long-term all cause mortality and re-hospitalization.
Methods. Overall, 139 consecutive patients underwent TEER from 2016 to 2022. The indication for procedure was agreed upon by a multidisciplinary local heart team. The cohort of patients was divided into two groups according to whether a first or second-gen device was implanted. Procedural success was defined as a final MR grade <2. Clinical, echocardiographic, procedural complications and long-term (5-year) re-hospitalization rate and vital status were collected.
Results. A first-gen device was implanted in 50 patients (36%); a second-gen device in 89 (64%). Patients treated with a second-gen device were older (76.9 vs 80.5 yrs, p=0.035), with a similar, high rate of hypertension, renal insufficiency, and chronic obstructive pulmonary disease. By echo, the EROA (0.35 vs 0.35 sq.cm, p=0.86), EF (35.5% vs 41.2%, p=0.07), and LV telediastolic diameter (59.9 vs 57.2 mm, p=0.14) were similar between first and second-gen device groups. With second-gen devices, time-to-device was significantly shorter (68 vs. 103 min., p=0.002), and so was hospitalization time (6.1 vs. 11.2 days, p=0.002). Procedural success rate was archived in 86% of patients. A higher reduction of MR severity was obtained with second-gen devices (2.51 vs 2.74 grades, p=0.035), without a significant difference of MVARC rate between two groups (31.3% vs 21.3%, p=0.79). At 5-year follow-up, event free-survival curves showed a reduction in mortality favoring second-gen devices (log-rank, p<0.045), but a similar re-hospitalization rate was observed (log-rank, p=0.45) (Kaplan-Meyer analyses).
Conclusions. In our tertiary center, the use of second-gen devices for TEER allows us to obtain a greater degree in the reduction of MR compared to the previous ones, allowing an improvement in long-term mortality. However, in terms of re-hospitalization, the benefit using second-gen device is out weight by several comorbidities present in this frail and increasingly elderly population. Reduction of time-to-device and hospitalization times may transate in a better cost-benefit ratio.

A1028: MULTIMODALITY PERCUTANEOUS TREATMENT OF SEVERE TRICUSPID REGURGITATION

Federico Arturi (a), Giulia Masiero (a), Chiara Fraccaro (a), Luca Nai Fovino (a), Tommaso Fabris (a), Massimo Napodano (a), Francesco Cardaioli (a), Andrea Panza (a), Andrea Bertolini (a), Sabino Iliceto (a), Giuseppe Tarantini (a)
(a) DEPARTMENT OF CARDIAC, THORACIC, VASCULAR SCIENCES AND PUBLIC HEALTH, UNIVERSITÀ DEGLI STUDI DI PADOVA, PADOVA, ITALY

Background. Tricuspid regurgitation (TR) is the most common valvular heart disease (VHD) in patients underwent to heart transplantation (HTx). In symptomatic patients with severe TR and prohibitive or high surgical risk, transcatheter edge-to-edge repair (TEER) is an emerging therapeutic option.
Case report. A 58-year-old woman was admitted to our Cardiology Unit with signs of congestive heart failure (CHF) and severe TR. 5 years before, due to an end-stage hypertrophic cardiomyopathy, she underwent to an orthotopic HTx complicated by cardiac tamponade and high-grade AV block requiring a bicameral pacemaker implantation. Progressively, she developed symptomatic severe TR. Taking in to account the progressive worsening CHF despite optimized medical therapy, she was evaluated for an invasive treatment. The transthoracic and transesophageal echocardiogram (TEE) confirmed a severe TR due to: 1) annulus dilation (48 mm diameter) with leaflets tethering, and 3) pacemaker lead interference with the septal leaflet. The right ventricle (RV) function was mildly impaired (RVEDA 17,45 cm2/m2, TAPSE 17.1, FAC 30%) but left ventricular function/dimension and other valves presented no abnormalities. The TRI-SCORE (5/12; 14% hospital mortality risk rate) and EUROSCORE (4% mortality risk rate). Therefore, the Heart Team evaluation stated for a percutaneous double-step approach: a lead extraction with sequential leadless pacemaker implantation first, followed by clinical and instrumental follow-up conferming a transcatheter valve repair treatment option. After the electrophysiological treatment, a moderate-to-severe TR in the absence of structural valvular damage endured. During a close follow-up, due to the persistent signs of CHF, the patient was referred for TV repair with TEER. The preprocedural TEE showed severe TR (EROA 0.48 cmq, Regurgitant volume 40 ml) due to annular dilation and leaflets tethering resulting in a large coaptation gap (8 mm between anterior and septal leaflets). Under general anesthesia and TEE guidance, the patient underwent a single Triclip (Abbott Vascular) implantation (XTW) between septal and anterior leaflets without any complications resulting in a residual mild TR grade with a mean TV gradient of 3 mmHg. Taking in to account the optimal hemodynamic result, no other clips implantation was required. Eventually, at the 6 months follow-up, the patient experienced increased functional capacity and no other admissions for CHF showing a sustained reduction in TR severity (mild grade) and echographic improvements in RV function and volume (RVEDA 14,45 cm2/m2, TAPSE 17.4, FAC 44%).
Conclusions. TR is associated with substantial morbidity and poor quality of life. It is essential to recognize the exact pathophysiological mechanism underlying this valvulopathy in order to provide patients with a comprehensive course of treatment including medical therapy, lead management, and TV interventions. Growing evidence supports the use of transcatheter TV interventions in inoperable or surgical high-risk patients. Tricuspid TEER is safe for patients with severe TR, reduce the severity of TR, and is associated with an improvement in quality of life compared to medical treatment. However, some important questions remain largely unanswered and require rapid resolution by means of large-scale registries and randomized studies as: the long-term benefit, the appropriate timing of interventions, the comparative results of the available transcatheter treatment options and clinical and echocardiographic patients' selection criteria.

A1029: STAGED STRATEGY FOR TRANSCATHETER EDGE-TO-EDGE TREATMENT OF CONCOMITANT MITRAL AND TRICUSPID REGURGITATION: A CASE SERIES.

Federica Coletti (a), Valeria Cammalleri (a), Valeria Maria De Luca (a), Giorgio Antonelli (a), Maria Grazia Piscione (a), Edoardo Nobile (a), Dario Gaudio (a), Myriam Carpenito (a), Elisabetta Ricottini (a), Simona Mega (a), Francesco Grigioni (a), Gian Paolo Ussia (a)
(a) FONDAZIONE POLICLINICO UNIVERSITARIO CAMPUS BIO-MEDICO

Background. Secondary tricuspid regurgitation (TR) is common in patients with mitral regurgitation (MR). The increase in left ventricular filling pressures and, consequently, in left atrial pressures causes post-capillary pulmonary hypertension, with significant increase in right ventricular afterload and subsequent right ventricular dilatation and dysfunction. Because multivalvular heart disease affects long-term prognosis, in comparison with isolated MR or TR, it is crucial to offer patients adequate treatment. However, the treatment of combined valvular diseases currently represents a challenge for both cardiac surgeons and interventional cardiologists since only few data in the literature address the clinical and therapeutic decision-making process related to these complex scenarios. Emerging transcatheter treatments offer the opportunity to treat both valvular defects (MR and TR) either concomitantly or staged.
Clinical case. We report the cases of 2 male patients respectively 72 and 78 years old, referred to our centre for severe MR. The echocardiographic evaluation showed in both patients severe MR (grade 4+) with concomitant significant TR (grade 3+ in one patient, grade 4+ in the other patient). The MR mechanism was in one case secondary to dilatation and dysfunction of the left ventricle, while in the other case mainly degenerative. The TR mechanism was in both cases mixed, due to right ventricular dilatation and lead interference. We decided to perform transcatheter mitral edge-to-edge repair with the MitraClip device (Abbott Vascular, Santa Clara, CA, USA) and a second stage transcatheter edge-to-edge tricuspid valve repair after accurate echocardiographic revaluation. In both cases, the mitral valve repair was successful with a significant reduction of MR and without intrahospital adverse events. At 30 days follow-up no major adverse cardiovascular events or heart failure rehospitalizations were reported; transthoracic echocardiogram showed residual mild MR in one patient and mild-to-moderate MR in the other one, and persistence of severe TR in both patients. Therefore, after about three months from the mitral valve repair, both patients underwent successful transcatheter edge-to-edge tricuspid valve repair with the TriClip device (Abbott Vascular, Santa Clara, CA, USA) with reduction of TR of at least one grade from the baseline. At 30 days follow-up both patients were alive and referred functional and quality of life improvement with no further hospitalizations for acute heart failure.
Conclusions. In patients with MR undergoing transcatheter therapy significant TR is frequent, and it does not regress after successful treatment of the mitral valve in most of the patients. Left untreated, concomitant TR impacts prognosis and impairs functional improvement. In our experience, a staged transcatheter strategy appears to be a valid and safe therapeutic option in patients presenting with multivalvular disease. A stepwise approach permits a follow-up of TR after mitral valve repair, in order to plan, only if necessary, a subsequent percutaneous treatment. Moreover, in a staged strategy, the transcatheter treatment of TR is performed with improved hemodynamic conditions partially related to the positive ventricular remodelling observed after mitral valve repair.

A1030: 10 YEARS EVALUATION OF ISOLATED TRICUSPID REGURGITATION TREATMENT

Federica Gramegna (a), Nicola Buzzatti (a), Nicolò Azzola Guicciardi (a), Irene Vitale (a), Paolo Denti (a), Stefano Stella (a), Elisabetta Lapenna (a), Michele De Bonis (a), Ottavio Alfieri (a), Francesco Maisano (a)
(a) SAN RAFFAELE HOSPITAL, MILAN

Patients affected by tricuspid regurgitation (TR) usually presented high operative risk: this can be related to late presented symptoms that lead to approached at the patients in an advance ventricular dysfunction stage. During last decades, transcatheter technologies has reached tricuspid field. The purpose of the present study is to assess the evolution of TR treatment over the past decade as well as the impact of the advent of tricuspid transcatheter technologies on patients' outcomes. All patients admitted with isolated moderate-severe or worse (≥3+) TR from January 2013 to December 2022 at our Department were retrospectively retrieved. Patients with concomitant other valve pathology (≥3+) as well as other severe diseases requiring treatment were excluded. All data were collected using Departement's database amd patient's medical records. Trough that Triscore was calculated and TR aetiology was assessed: primary, atrial functional, ventricular functional and CIED related. TR and RV function was graded using a multiparametric approach; right ventricle (RV) remodeling was assessed through mid, base and apex diameter. Wide clinical application of transcathter tricuspid technologies take off in sustained manner in 2018. For this reason, we divided population in two groups: those admitted during the 2013-2017 vs 2018-2023 timeframe. Statistical analysis was performed using the SPSS software (IBM, Armonk, NY, USA). Logistic regression model was used to find association between baseline patients' features and the treatement recived. A total of 259 patients were included in this study: 91 patients were included in the first timeframe, 168 patients in the second one. Overall number of patients admitted per year increased with a computed annual grow rate of +18.1%. This was mainly driven by the annual growth of patients receiving transcatheter therapies since 2014 (+58.1% per year), while surgery grew +1.49% and patients receiving no procedure diminished -3.14% per year. The changes over time in patients' number were significant in the transcatheter (P=0.006) and in the no-procedure group (P=0.576) but not in the surgical group (P=0.209). When comparing the timefrmes, patients reciving no treatement decreased from 30.8% to 16.1% (p<0.001). Patients in the two timeframes were similar regarding clinical features. Eatiology of TR was different: atrial TR increasing (from 17.6% to 38.3%) and ventricular TR decreasing (from 51.6% to 38.9%), (p=0.002). Post-operative outcomes between the two groups showed a decreasing in intra-hospital mortality (11.1% vs 3.5%, p=0.03) and in post-operative length of stay (LOS) (8 [6-16] vs 6 [4-9] days, p<0.001). Over the last decade the number of patients affected by isolated TR referred to receive TR correction has steadily increased. Since the introduction of transcatheter therapies, more patients received TR correction and with lower mortality, despite the same sick baseline profile. Follow-up data remain needed to fully understand the added value of transcatheter technologies to the tricuspid therapeutic armamentarium.

A1031: A CASE OF CARCINOID SYNDROME TREATED WITH TRICUSPID AND PULMONARY VALVE REPLACEMENT, COMPLICATED BY COMPLETE ATRIOVENTRICULAR BLOCK - WHAT'S THE BEST STRATEGY?

Monica Ianniruberto (a), Alessandro Nepitella (a), Fabrizio Tundo (a), Filippo Trombara (a), Antonio Frappampina (a), Giovanni Berna (a), Marco Zanobini (a), Francesca Spada (b)
(a) CENTRO CARDIOLOGICO MONZINO; (b) IEO ISTITUTO EUROPEO DI ONCOLOGIA

Background. Carcinoid heart disease (CHD) is an important complication in patients with metastatic neuroendocrine tumours and carcinoid syndrome. It can cause right ventricle fibrosis or hypertrophy, tricuspid and pulmonary valve thickening with consequent valve stenosis or regurgitation. Rarely, left heart chambers are involved as a result of lung metastasis or right-to-left shunts. Current guidelines on CHD recommend the use of somatostatin analogues and valve replacement surgery on top of symptomatic therapy.
Case report. We report a case of a 59-year-old female with an ileal neuroendocrine tumour and liver metastases who became symptomatic for worsening exertional dyspnoea and oedema of the lower extremities. Transthoracic echocardiography revealed severe dilatation of the right heart chambers and a mildly impaired right ventricular function, massive tricuspid valve (TV) regurgitation and severe pulmonary valve (PV) regurgitation. Left ventricular size and function were normal. The patient was admitted to our hospital to undergo TV and PV replacement. Before surgery, a nasal swab revealed MRSA colonisation, so she was treated empirically with nasal Mupirocin ointment. She then underwent TV and PV replacement with bioprosthesis (Magna 29 and Resilia Inspiris 19, respectively). The early post-operative course was complicated by complete atrioventricular block requiring temporary epicardial pacing. The patient also presented with fever and increased inflammatory markers. Empiric antibiotic therapy with Vancomycin and Meropenem was started. Blood and urine cultures were negative. Transthoracic echocardiograms ruled out infective endocarditis. Due to persistence of complete AV block, considering the high risk of device infection, the patient underwent uneventful implantation of a leadless pacemaker (Micra TPS) on 5th postoperative day. Pre-discharge echocardiography showed well-seated and well-functioning tricuspid and pulmonary valve bioprosthesis as well as reduction of right chamber volumes and normalisation of right ventricular function. Due to inadequate atrial sensing, the device was programmed in VVI pacing mode.
Conclusions. Complete atrioventricular block is a common complication of CHD patients who underwent TV replacement surgery, described in up to 30% of patients. According to the most recent evidence, leadless pacemaker implantation should be considered when the risk of device infection is particularly high. Moreover, insertion of a pacing lead after TV replacement could be particularly challenging.

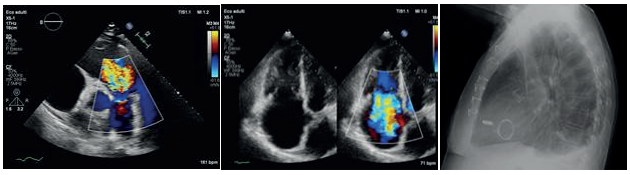

A1032: 3D-ECOCARDIOGRAPHIC ASSESSMENT OF CARDIAC CHAMBER REMODELING AFTER MITRAL TRANSCATHETER EDGE-TO-EDGE REPAIR

Giulio Leo (a), Chiara Mari (a), Niccolo Bonini (a), Sabrine Saaidi (a), Fabio Alfredo Sgura (a), Salvatore Arrotti (a), Giuseppe Boriani (a), Francesca Coppi (a)

(a) CARDIOLOGY DIVISION, DEPARTMENT OF BIOMEDICAL, METABOLIC, NEURAL SCIENCES, UNIVERSITY OF MODENA AND REGGIO EMILIA, POLICLINICO DI MODENA, 41124, MODENA, ITALY

Background. Transcatheter edge-to-edge repair (TEER) by MitraClip is an established therapy for mitral regurgitation (MR) in case of non-eligibility or high risk for surgical treatment. For transcatheter treatment, echocardiography has a crucial role in the initial assessment, the procedural phase and the follow-up. The aim of this study was to determine the role of three-dimensional echocardiography (3DE) in the evaluation of left and right ventricular (LV, RV) and left and right atrial (LA, RA) remodelling after TEER.

Methods and Results. Thirty-five patients (mean age 79.68 years; 54.3% males) undergoing TEER at our centre were prospectively enrolled. All the patients underwent 3DE 0.86 ± 0.5 months before the procedure and after 6.13 ± 3.8 months; functional MR accounted for 65% of cases. Compared to baseline, a statistically significant improvement was recorded in many 2D measurements as in LV end-diastolic and end-systolic diameter (LVEDD, LVESD), LV indexed mass (ILVM), LV end-diastolic and end-systolic volumes (LVEDV, LVESV), indexed LA volume (iLAV) and morpho-functional RV parameters (Table 1). Furthermore, positive remodeling of LV and LA was also assessed by 3DE measurements. In particular, LA improvement was shown from a morphological and a functional variables ad iLAV 3D, LA ejection fraction 3D (EFLA 3D) and PALS (Table 1). Finally a statistically significant improvement was recorded for left ventricle indexed end-diastolic and end-systolic volumes (iLVEDV, iLVEDSV) and LV ejection fraction 3D (LV-EF 3D). As regards right sections, the most relevant positive remodeling was obtained in patients with functional MR with a baseline poorer RV function and more severe RA and RV dilation.

Conclusions. At mid-term follow-up after M-TEER, a positive cardiac remodeling was detected in atrial and ventricular chambers by bi-dimensional and three-dimensional imaging. 3DE could have a crucial role in the selection of patient for tailored intervention on MV.

	Baseline, Median [IQR]	Follow-up, Median [IQR]	p-value
LVEDD (mm)	53.00 [49.00-60.00]	48.00 [45.00-59.00]	<0.001
LVESD (mm)	42.00 [37.00-45.00]	40.00 [36.00-47.00]	<0.001
RWT	0.33 [0.29-0.38]	0.35 [0.31-0.38]	<0.001
iLVM (gr/m2)	102.69 [82.45-121.11]	88.88 [59.83-104.44]	<0.001
2D-iLVEDV (mL/m2)	61.41 [49.00-77.69]	51.00 [39.61-62.89]	<0.001
2D-iLVESV (mL/m2)	27.02 [21.00-38.52]	24.94 [17.80-32.19]	<0.001
2D-LVEF (%)	53.63 [47.52-60.37]	0.55 [0.49-50.50]	0.050
LV-S' (TDI) (cm/s)	8.00 [6.55-9.00]	8.70 [7.00-9.60]	0.048
2D-iLAV (mL/m2)	48.00 [40.84-58.00]	43.60 [34.89-55.76]	<0.001
PALS (%)	10.25 [4.80-14.00]	13.50 [6.15-21.45]	0.002
TR Vmax (m/s)	2.86 [2.59-3.05]	2.50 [2.00-2.76]	0.919
EPSPAP (mmHg)	40.00 [35.00-50.00]	30.00 [20.00-35.00]	0.690
Basal RVD (mm)	39.00 [34.00-42.00]	34.00 [32.00-38.50]	<0.001
Mid-cavity RVD (mm)	29.00 [25.00-34.00]	27.00 [23.50-30.00]	<0.001
Longitudinal RVD (mm)	63.00 [56.00-69.00]	60.00 [53.50-65.00]	0.008
RA Area (cm2)	20.00 [16.00-23.00]	16.80 [14.00-21.00]	0.049
FAC (%)	37.00 [31.00-44.00]	45.00 [40.00-46.50]	0.006
TAPSE (mm)	17.00 [14.00-21.50]	20.00 [17.00-22.00]	<0.001
RV S' (TDI) (cm/s)	11.00 [7.00-12.00]	10.50 [9.00-12.75]	<0.001
RV-FWLS (%)	17.50 [13.00-20.50]	20.50 [18.00-23.00]	<0.001
EF 3D LA (%)	30.00 [18.50-49.50]	36.50 [20.00-46.50]	<0.001
LAV 3D (ml)	121.00 [87.00-136.00]	113.50 [82.50-136.50]	<0.001
LAVi 3D (ml/min)	66.89 [46.38-78.96]	58.53 [48.18-71.07]	<0.001
LVEDV 3D (ml)	143.50 [97.00-168.00]	134.00 [117.50-162.00]	<0.001
iLVEDV 3D (ml/m2)	78.33 [59.45-89.46]	72.58 [63.67-84.65]	<0.001
LVESV 3D (ml)	63.00 [42.50-80.50]	66.00 [49.00-85.00]	<0.001
iLVESV 3D (ml/m2)	32.88 [23.41-42.15]	33.33 [28.39-43.81]	<0.001
LV-EF 3D (%)	54.50 [48.81-59.58]	0.51 [0.47-0.67]	0.016

Table 1. Baseline and follow-up echocardiographic assessment.

A1033: BIOPROSTHETIC PULMONARY VALVE DYSFUNCTION IN A PRIMARY CARDIAC SARCOMA SURVIVOR: CLINICAL CONSIDERATIONS AND TREATMENT OPTIONS

Davide Maione (a, b), Antonio De Luca (b), Andrea Pezzato (a, b), Giancarlo Vitrella (b), Andrea Perkan (b), Elisabetta Rauber (d), Gianfranco Butera (c), Gianfranco Sinagra (b)

(a) POSTGRADUATE SCHOOL OF CARDIOVASCULAR MEDICINE UNIVERSITY OF TRIESTE; (b) AZIENDA SANITARIA UNIVERSITARIA GIULIANO-ISONTINA - DIVISION OF CARDIOLOGY; (c) CHILDRENS HOSPITAL BAMBINO GESÙ DI ROMA; (d) AZIENDA SANITARIA UNIVERSITARIA GIULIANO-ISONTINA - DIVISION OF CARDIAC SURGERY

A 69-year-old woman with a diagnosis of right ventricular outflow tract and pulmonary artery primary sarcoma, was treated with radical excision, reconstruction of the pulmonary artery, and bioprosthetic pulmonary valve replacement. After surgery, the patient started adjuvant chemotherapy and after two years was free of malignancy. However, she developed symptoms and signs of congestive heart failure. Collaterally, a diagnosis of hyperparathyroidism was made. Transthoracic and transesophageal echocardiography showed right ventricular (RV) dilatation and dysfunction, with both stenosis and severe regurgitation of the pulmonary bioprosthesis. To address the pulmonary valve dysfunction, after the Heart Team discussion, the patient successfully underwent transcatheter valve-in-valve implantation. Following the procedure, the patient experienced a significant improvement in symptoms and cardiac function. Primary cardiac malignancies are rare and associated with a poor prognosis. Radical surgical resection remains the main therapeutic approach. Despite the aggressive nature of the malignancy, our patient was alive after two years following the initial diagnosis, surgical treatment, and adjuvant chemotherapy. However, she developed an early degeneration of the bioprosthetic pulmonary valve. In our case, transcatheter valve-in-valve implantation proved to be feasible, safe and effective, leading to a significant clinical improvement and normalization in RV function and dimensions.

A1034: ROLE OF ATRIAL FIBRILLATION AND RENAL FUNCTION AS A PREDICTORS OF CLINICAL OUTCOME IN PATIENTS WITH AORTIC STENOSIS

Leopoldo Pagliani (a), Agnese Di Naro (b), Elisa Nicolosi (b), Gabriele Luzza (b), Roberta Buso (d), Francesco Antonini Canterin (b), Gentian Denas (c), Marcello Rattazzi (c, d)

(a) I.O.V. - ISTITUTO ONCOLOGICO VENETO I.R.C.C.S.; (b) OSPEDALE DI ALTA SPECIALIZZAZIONE DI MOTTA DI LIVENZA; (c) UNIVERSITÀ DEGLI STUDI DI PADOVA; (d) CLINICA MEDICA 1-OSPEDALE CA FONCELLO TREVISO

Background. Aortic stenosis is the most prevalent valvular disease in the Western world, affecting nearly 2% of the general population. It is the third most frequent cardiovascular pathology and has a great impact on the population, mainly the elderly, with a two-year mortality of more than 50%. Study aim – The aim of the present study is to search predictors of cardiovascular events, and valve replacement in patients with moderate-to-severe aortic stenosis.

Methods. The subjects are140 patients included in the Italian regional Registry.

Results. The deceased were 50 subjects (36%) of which 32 (22.9%) without having replaced the valve, the remaining after the replacement event. The mean follow-up was 24.9±21.7 months. Compared to the living at follow-up, the deceased were characterized by older age, increased frequency of atrial fibrillation and renal failure, with worse eGFR, higher blood phosphate level. Older age and atrial fibrillation always appeared to be independently significantly associated with death in univariate and multivariate Cox regression, whereas valve replacement was independently associated with survival. As regards cardiovascular events in the follow-up (24.99±21.72 months), about a third of the subjects had at least one, of which more than half a heart failure (21%), sometimes repeated several times, then in decreasing order AF (13%), heart attack (7.9%), stroke (2.9%), peripheral ischemia (2.1%). In the comparison between the subjects with or without a cardiovascular event, the first were older at enrollment and more affected by atrial fibrillation: on the multivariate age was no longer independently associated with the events, while the significance of the presence of AF remained unchanged. eGFR was significantly lower, while phosphorus appeared higher in the CV event group: Cox regression showed that phosphate levels were significantly associated with CV event occurrence regardless of other factors assessed, including eGFR, and the same was true for kidney function. Kaplan Meyer curves show significant differences in the risk of CV events over time between groups with eGFR greater than/equal to and less than 60 ml/min.

Conclusions. The results of the study suggest that aortic stenosis certainly appears as a pathology linked above all to senescence processes and probably shares a common basis with atherosclerotic pathology, but it would seem to be influenced in its prognostic evolution by further determinants such as FA and phosphorus values in the blood. Autonomic nervous system factors are very important in AF: vagal discharge increases acetylcholine-dependent K+ current (IKACh), reducing APD and stabilizing reentrant circuits. These considerations lead us to reflect on the usefulness of further studies aimed at better understanding the pathogenetic mechanisms that can explain the proven relationship between phosphorus values and the higher frequency of CV events often driven by the remodeling given by even paroxysmal episodes of AF. It is necessary to construct as soon as possible a prognostic score that takes into account these predictive variables and that can help us to better stratify the clinical evolution of aortic stenosis and even more importantly the surgical timing and prophylactic anticoagulant therapy.

A1035: TRICUSPID VALVE LEAFLETS-LEAD INTERACTION: A CASE SERIES ON THE ADJUNCTIVE ROLE OF CARDIAC COMPUTED TOMOGRAPHY FOR CLINICAL DECISION MAKING

Davide Margonato (a, b), Paul Sorajja (a), Vinayak Bapat (a), Joao Cavalcante (a)

(a) CARDIOVASCULAR IMAGING RESEARCH CENTER, MINNEAPOLIS HEART INSTITUTE FOUNDATION, MINNEAPOLIS, MN, UNITED STATES OF AMERICA; (b) CARDIOVASCULAR IMAGING UNIT, CARDIOTHORACIC DEPARTMENT, IRCCS SAN RAFFAELE HOSPITAL, MILAN, ITALY

Data has recently emerged regarding the prevalence and the prognostic role of cardiac implantable electronic devices (CIED)-related tricuspid regurgitation (TR). While the diagnostic approach to CIED-related TR has significantly improved over the last years, the anatomical and causal rela-

tionship between TR and CIEDs is not always easy to assess. However, an answer to this question may be of pivotal importance in patients' management, particularly in light of novel transcatheter edge to edge valve repair (TEER) and replacement (TVR) therapies and of eventual preprocedural lead extraction. Although two and three-dimensional (3D) transesophageal echocardiography (TEE) is essential to understand CIED-TR relationship, suboptimal imaging due to transvalvular lead presence and inherent imaging method limitations may require further examination. The following clinical case series reports our experience with 3 patients with severe TR and CIEDs who underwent cardiac computed tomography (CCT) scan: here we show how the adjunctive role of CCT, by better evaluating lead-leaflet anatomical interaction and anticipating potential feasibility or complication of invasive procedures, may significantly help the clinical decision-making process.Particularly, in the first case, in the presence of inadequate TEE acoustic window, CCT finding of a fixed lead, adherent to the septal leaflet, guided use to consider the patient only eligible for transcatheter valve replacement therapy. In the second case, the identification of leaflets fibrotic remodeling and impingement led us to decide for lead extraction and subsequent transcatheter valve repair therapy. Finally, in the last case, despite two leads crossing the tricuspid valve and preventing reliable TEE evaluation, CCT imaging allowed us to understand lead's trajectory, slack (or lack thereof) and potential mobilization, leading us to decide only for a conservative strategy with medical treatment.

A1036: CASE REPORT OF RECURRENT DOUBLE-VALVE LIBMAN-SACKS ENDOCARDITIS IN A YOUNG PATIENT

Chiara Messina (a), Roberto Cacace (a), Concetta Filardo (a), Giuseppe Scalzi (a), Ludovica Corsello (b), Alessandro Russo (b), Eugenia Pasceri (a), Giuseppina Mascaro (a), Ciro Indolfi (a), Iolanda Aquila (a)

(a) DIVISION OF CARDIOLOGY, DEPARTMENT OF MEDICAL AND SURGICAL SCIENCES, MAGNA GRAECIA UNIVERSITY, CATANZARO, ITALY; (b) UNIT OF INFECTIOUS AND TROPICAL DISEASE, DEPARTMENT OF MEDICAL AND SURGICAL SCIENCES, MAGNA GRAECIA UNIVERSITY, CATANZARO, ITALY

Introduction. Libman-Sacks (LS) endocarditis, also known as marantic or verrucous endocarditis, is a form of nonbacterial thrombotic endocarditis (NBTE) characterized by sterile valvular vegetations, most commonly found on mitral and aortic valves. LS endocarditis may be associated with some autoimmune diseases or malignancy. Though typically mild and asymptomatic, LS endocarditis can lead to significant complications, including severe valvular insufficiency, infective endocarditis and thrombo-embolic events, such as stroke and transient ischemic events. This report describes a case of double-valve replacement in a patient with nonbacterial endocarditis, complicated by vegetations on the bioprosthetic valves and thrombo-embolic events.

Clinical case. A 47 years old woman with diagnosis of ulcerative colitis and spondyloarthritis was hospitalized for dyspnoea and palpitations. New onset atrial fibrillation and significant aortic and mitral regurgitation were detected. Consequently, the patient underwent mitro-aortic valve replacement with biological valves and left auricle closure. Intraoperative inspection showed a mitral valve with inflammatory aspect of annulus and sessile vegetations on anterior leaflet as per active inflammatory process so antibiotic therapy (ABT) was started. Blood cultures and microscopic examination of the excised valves resulted negative. After a moth from surgery, due to the onset of fever she was admitted to our department. Blood test revealed high value of C-reactive protein (CPR) and negative procalcitonin (PCT). Transthoracic echocardiogram (TTE) and chest X-ray were negative. Blood cultures were performed and empiric ABT was started with symptoms regression. After twelve days a control TTE was performed with evidence of vegetations and a subsequent TEE showed multiple mobile formations in correspondence of the mitral annulus and other formation on ventricular side and on the anterior pillar of the valve (Fig. 1). Furthermore, rhythm alterations were documented on the ECG. PET pointed out an intense increase in glucose metabolism in correspondence of the aortic root, above all mitral valve planes and in the pericardial area (Fig. 2). After the exclusion of infectious causes (blood cultures, serological test and blood PCT were persistently negative) and considering the medical history of inflammatory diseases, the diagnosis of non-infectious endocarditis was performed. Meanwhile the patient manifested several cerebral transient ischemic events and a splenic infarction. HFU was administered, according to PTT values, until a following control TTE and TEE showed the resolution of the condition (Fig. 3). Further immunological investigations allowed to make the diagnosis of polychondritis and anti-inflammatory therapy was started.

Conclusions. LS endocarditis is a rare entity and is frequently underestimated. Cardiac imaging is crucial for making the diagnosis and initiating adequate therapy, that should focus on the treatment of the underlying disease and anticoagulation.

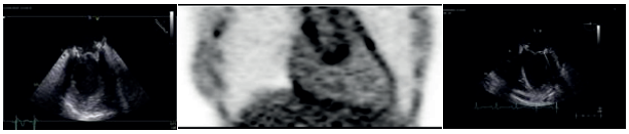

A1037: AN ATYPICAL PRESENTATION OF MULTIVALVULAR ENDOCARDITIS: A CASE REPORT

Antonino Micari (a), Giancarlo Trimarchi (a), Alice Moncada (a), Olimpia Trio (a), Roberta Manganaro (a), Patrizia Grimaldi (a), Danila Calabro (a), Antonio Micari (a), Gianluca Di Bella (a)

(a) DEPARTMENT OF CLINICAL AND EXPERIMENTAL MEDICINE, UNIVERSITY OF MESSINA, AOU POLICLINIC0 "G. MARTINO", CARDIOLOGY UNIT, MESSINA, ITALY

Due to its high morbidity and mortality, the timely identification of infective endocarditis is imperative. Since multivalvular endocarditis involving three or more valves is infrequently observed, the available literature on its optimal management and prognosis remains limited. Moreover, there are contrasting recommendations regarding the treatment approach (i.e., medical versus surgical) for this condition, and few studies exist that shed light on the outcomes of medically treated patients.

Our case report about a 67-year-old woman with endometrial cancer and accidental diagnosis of multivalvular endocarditis, who came to the attention of the cardiologist due to the onset of an episode of atrial fibrillation associated with mild dyspnea. The diagnosis of endocarditis was firstly suspected on transthoracic echocardiogram and was confirmed by transesophageal echocardiogram evaluation and by two sets of positive blood cultures for Enterococcus Faecalis. Transesophageal echocardiography assessment showed, at the level of the aortic valve in a mid-esophageal short-axis view, the presence of a mass adhered to the ventricular side of the left coronary cusp (Figure A, red arrowhead). Another smaller echogenic formation was found on the ventricular side of the edge of the non-coronary cusp (Figure A, red arrow). In a mid-esophageal three-chamber view, two small linear formations of isoechoic appearance, are attached to the atrial side of the mitral valve: the longest is located on the free margin of the posterior leaflet (Figure B, white arrow), while the smaller is located on the anterior leaflet (Figure B, red arrowhead). The tricuspid valve showed a formation adherent to the atrial side of the valve (Figure C, red arrow). The subsequent antibiotic therapy improved the clinical conditions of the patient and progressively reduced the inflammatory biomarkers, with a first negative set of blood cultures 10 days after. Furthermore, after two days from the beginning of the antibiotic therapy, the patient underwent a PET/CT scan to demonstrate the metabolic activity of the lesions and for the detection of distant infectious foci. However, the examination showed no uptake at the valvular level, despite the large extension of the masses evaluated with echocardiogram. This could be attributed to the inadequate diagnostic ability of PET for native valve endocarditis detection, the concomitant administration of antibiotics, and a possible low inflammatory activity of the valvular lesions. Our patient highlights that atypical presentations of endocarditis must also be taken into consideration to early identify the condition and confirms that PET/CT shows limitations in the assessment of the pathology, even in the presence of very extensive vegetations. Furthermore, it suggests that medical therapy can give initial results also in multivalvular endocarditis, even in patients who are not immediately candidates for cardiac surgery.

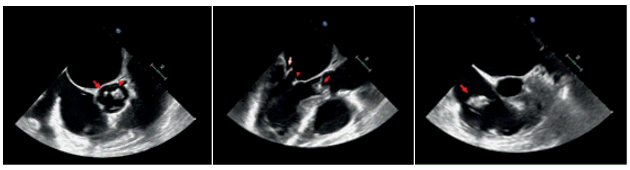

A B C

A1038: CAMBIAMENTI NEL VOLUME ATRIALE SINISTRO DURANTE ECOSTRESS IN PAZIENTI SOTTOPOSTI AD INTERVENTO CARDIOCHIRURGICO DI PLASTICA VALVOLARE MITRALICA

Eliezer Joseph Tassone (a), Gaetano Morabito (b), Giuseppe Carullo (c), Saverio Nardella (d), Daniele Maselli (d)

(a) LABORATORIO ECOCARDIOGRAFIA, MEDICARE - STRUTTURA SANITARIA PRIVATA, LAMEZIA TERME (CZ); (b) U.O.C. CARDIOLOGIA-UTIC-EMODINAMICA, A.O.U. "DULBECCO", CATANZARO; (c) U.O. CARDIOLOGIA, OSPEDALE "JAZZOLINO", VIBO VALENTIA; (d) U.O. CARDIOCHIRURGIA, MEDITERRANEA CARDIOCENTRO, NAPOLI

L'insufficienza valvolare mitralica (IM) rappresenta un quadro clinico ad elevata morbidità e mortalità che, nelle forme complicate da impegno emodinamico, trova soluzione nel trattamento chirurgico spesso riparativo. La maggior parte delle forme si caratterizzano per la presenza di degenerazione mixomatosa che interessa una o più strutture dell'apparato valvolare causando spesso il prolasso di uno o di entrambi i lembi. Ne consegue un incremento di pressione diastolica che porta a una progressiva dilatazione dell'atrio sinistro che rappresenta un fattore determinante nello sviluppo di scompenso diastolico e nella comparsa di aritmie. L'incremento del volume sinistro indicizzato (LAVI) durante ecostress rappresenta un fattore prognostico negativo nell'evoluzione clinica di molte patologie, quali cardiopatia ischemica, cardiomiopatia ipertrofica, scompenso cardiaco a funzione sistolica preservata. In particolare si è visto che un incremento del LAVI picco/riposo>6.8 ml/m^2 correla con una maggior incidenza di riacutizzazione di scompenso, ri-

duzione della riserva contrattile, congestione polmonare. Allo stato attuale non vi sono dati inerenti ai cambiamenti del LAVI durante ecostress in pazienti affetti da IM. Lo scopo dello studio, pertanto, è stato quello di valutare l'effetto del trattamento chirurgico riparativo dell'IM sui cambiamenti del LAVI durante ecostress fisico. Sono stati arruolati 19 pazienti, 11 femmine e 8 maschi, affetti da IM, e sottoposti a ecostress fisico mediante protocollo ABCDE suggerito dalla Società Italiana di Ecografia Cardiovascolare e Cardiovascular Imaging (SIECVI), prima e dopo circa 12 settimane (10+4) dall'intervento cardiochirurgico. Durante ogni test è stato misurato il cambiamento del LAVI (ΔLAVI) espresso come differenza picco/riposo in ml/m^2. Dopo ogni test, inoltre, è stato calcolato lo score prognostico derivante dalla somma dei criteri ABCDE, come anche il calcolo della riserva contrattile del ventricolo sinistro (parametro C dello score), espressione della forza derivante dai cambiamenti emodinamici durante il test. In tutti i pazienti abbiamo osservato una riduzione significativa del ΔLAVI (8.4 + 0.5 ml/m^2 vs 9.7 + 0.7 ml/m^2; p<0.0001) dopo l'intervento cardiochirurgico. Inoltre, si è osservata una riduzione significativa dello score prognostico ABCDE (da 4.19 + 0.43 a 3.48 + 0.37; p=0.002), secondaria all'incremento della riserva contrattile del ventricolo sinistro (parametro C) registrata dopo circa 3 mesi dall'intervento chirurgico (da 1.77 mmHg/ml a 2.44 mmHg/ml, p<0.0001) come anche da una significativa riduzione della congestione polmonare durante stress (parametro B). Non vi sono stati cambiamenti significativi per quanto concerne la frazione di eiezione, il wall motion score index-WMSI (parametro A), la riserva coronarica (parametro D) e la riserva di frequenza cardiaca (parametro E). Questi dati dimostrano, per la prima volta, che l'intervento cardiochirurgico di plastica valvolare mitralica è in grado di ridurre l'incremento del LAVI durante ecostress in pazienti affetti da IM severa sottoposti ad intervento. La procedura chirurgica, inoltre, ha determinato sia un miglioramento della riserva contrattile del ventricolo sinistro sia una riduzione del grado di congestione polmonare che hanno portato, in ultimo, a un miglioramento dello score prognostico ABCDE.

A1039: A RARE COMPLICATION OF BLOOD CULTURE-NEGATIVE INFECTIVE ENDOCARDITIS ON TRICUSPID VALVE

Giovanni Bellina (a)
(a) UNIVERSITÀ DEGLI STUDI DI CATANIA

Endocarditis is an infectious disease with an incidence of about 15 cases per 100.000 people. Infective endocarditis with negative blood cultures (BCNIE) accounts for more than 20% of cases of infective endocarditis representing a diagnostic and therapeutic challenge. Among the urgent and most detrimental complications of BCNIE, perivalvular extension of the infection plays a major role. A 25-year-old Asian patient was admitted due to fever for 15 days and new onset chest pain. He denied drug use and his past medical history was silent. He underwent blood tests which showed an increase in inflammatory indexes. Electrocardiogram, chest X-ray and cardiac examination have shown nothing meaningful. The transthoracic echocardiogram showed a filamentous formation on the posterior leaflet of the tricuspid valve (Figure 1), a broken chordae tendineae with flail of the anterior leaflet and communication between the aorta and right atrium with an important left-right shunt (maximum gradient 80 mmHg). The procedure continued with the request for three sets of blood cultures. Pending this, empirical therapy was administered. A transesophageal echocardiogram (TEE) was performed, which has confirmed the formation on tricuspid valve, the severe insufficiency and the shunt (Figure 2). Finally, a search for foci of systemic embolization was performed by abdomen-chest-brain CT scan, with negative results. A decision for TEE-guided cardiac surgery was made, including anterior flap reconstruction and closure of the fistula between the left ventricle and right atrium. The intervention was successful with minimal tricuspid insufficiency and shunt. During the hospital stay, various blood cultures and serological examinations were performed with negative results, so empirical therapy with beta-lactam and glycopeptide has been continued. The patient was discharged 35 days after surgery. Two months after discharge, the patient underwent echocardiographic follow-up that showed a result comparable to the post-operative examination (Figure 3). The occurrence of a rare complication of endocarditis, fistula (1.6% of cases) and the sequence of several negative blood cultures, highlighting a very rare case of complicated BCNIE of the tricuspid valve. This condition has restricted the therapeutic possibilities to empirical therapy only and to early surgery.

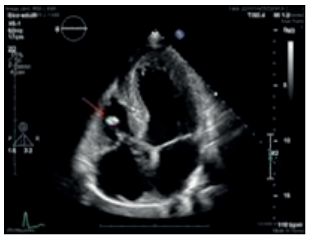

Figure 1.

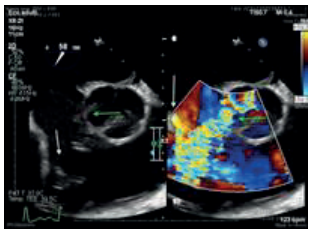

Figure 2.

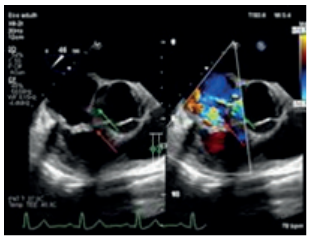

Figure 3.

A1040: PROLASSO MITRALICO: UN APPROCCIO MULTIDISCIPLINARE PER UN CORRETTO ITER DIAGNOSTICO-TERAPEUTICO

Piera Ciaramella (a), Ilaria Lucia Birtolo (a), Sara Cimino (a), Giorgia Serino (a), Rosanna Germanò (a), Gianmarco Scoccia (a), Giovanna Manzi (a), Roberto Badagliacca (a), Massimo Mancone (a), Dario Carmine Vizza (a), Viviana Maestrini (a)
(a) UNIVERSITÀ DEGLI STUDI DI ROMA SAPIENZA-POL UMBERTO I

Introduzione. Il prolasso della mitrale colpisce il 2-3% della popolazione generale e rappresenta una condizione benigna nella maggior parte dei casi. In una minoranza di pazienti (<1%) si associa ad aritmie ventricolari e morte cardiaca improvvisa. Numerosi sono i fattori di rischio cardiovascolari identificati, tra cui dibattuta resta la disgiunzione mitro-anulare (MAD), ma pochi sono i dati disponibili sull'effetto dell'intervento chirurgico sul profilo aritmico.
Anamnesi. 26 anni, noto prolasso mitralico con insufficienza di grado lieve, non fattori di rischio cardiovascolari, storia familiare per morte cardiaca improvvisa o cardiomiopatie negativa, non terapia farmacologica.
Quadro clinico. La paziente si presentava in PS per sincope e venivano documentati alla telemetria episodi di TVNS e bigeminismo ventricolare. All'elettrocardiogramma (Fig A) si rilevavano onde T negative nelle derivazioni infero-laterali e frequenti battiti ectopici ventricolari a morfologia blocco di branca destro con asse inferiore-destro, provenienti dal muscolo papillare anterolaterale. Veniva eseguito un ecocardiogramma transtoracico (Fig B) e transesofageo (Fig C) che mostravano insufficienza valvolare mitralica severa da prolasso e presenza di MAD. Le dimensioni del ventricolo sinistro erano aumentate con lieve riduzione della frazione di eiezione. Durante la degenza veniva iniziata terapia con beta-bloccante, progressivamente titolato, con riduzione della numerosità e della complessità dell'aritmia ventricolare e del cardiopalmo riferito dalla paziente. La TC coronarica escludeva patologie coronariche. La RMN confermava il prolasso con la MAD e documentava l'assenza di late gadolinium enhancement (LGE). Si decideva di sottoporre la paziente a trattamento cardiochirurgico con plastica valvolare mitralica e impianto di anello, con buon esito. Si decideva di soprassedere all'impianto di ICD ma, per i precedenti episodi di aritmia ventricolare complessa e sincope, veniva impiantato un loop-recorder. Al follow-up a 3 mesi la paziente si presentava asintomatica per cardiopalmo e sincope e non ha presentato episodi aritmici ventricolari.
Conclusione. L'approccio multidisciplinare è fondamentale nel guidare l'iter diagnostico-terapeutico dei pazienti con prolasso mitralico aritmico.

A1041: A CURIOUS CASE OF HIGH-RISK NSTE-ACS: NEVER FORGET PROSTHETIC HEART VALVES

Giulio Pio Federico Mallardi (a), Alberto Vincenzo Pollina (b), Beatrice Gregori (a), Stefano Carugo (a)
(a) UNIMI; (b) DEPARTMENT OF CARDIO-THORACIC-VASCULAR DISEASE, FOUNDATION IRCSCS CA' GRANDA OSPEDALE MAGGIORE POLICLINICO, MILAN, ITALY

A 74 year-old woman presented to the emergency department with astenia and dyspnea. He had a mechanical mitral valve implanted ten years ago. He also suffered from a polidistrict vasculopathy, which led to the amputation of his right foot distal end. The patient's medication regimen included warfarin therapy, which had been stopped three days prior to the onset of symptoms on the advice of his dentist, with bridging provided by heparin in preparation for a minor dental surgery. On arrival the patient exhibited signs of dyspnea. His blood pressure was 60/40 mmHg. An electrocardiogram (ECG) revealed a ST-segment elevation in lead aVR and diffuse ST-segment depression in the precordial and limb leads, consistent with a pattern indicative of pan-subendocardial ischemia (Panel A). Suspecting high-risk non-ST-segment elevation myocardial infarction (NSTE-ACS) an emergent transthoracic (TTE) and subsequent transesophageal echocardiograms (TEE) revealed a blocked leaflet with a hyperechogenic mass, adhered to the disk plane, accompanied by an elevated mean transmitral gradient of 15mmHg (Panel C); however the exact cause of the obstruction, whether it was a thrombus, pannus, or a combination of both, was unclear. Considering the normal ventricle wall motion, the patient's recent medical history, which included a negative coronary angiography and discontinuation of warfarin, the hypothesis of NSTE-ACS became less likely. Moreover, a diminished aperture of the aortic valve was observed, therefore, the aortic valve area, ejection fraction and stroke volume was quantified, showing a low flow-low gradient severe aortic stenosis. The patient was transferred to the intensive care unit, with a diagnosis of cardiogenic shock, with septic shock being considered as a potential alternative diagnosis potentially resulting from an infected ulcer of the patient's right leg, subsequently ruled out based on negative blood cultures. A repeated TEE revealed an increase in the trans-valve gradient to 24 mmHg (Panel B). Based on the worsening trans-valve gradient observed on imaging, the acute hemodynamic instability without fever, laboratory analysis showed a low C-reactive protein and low international normalized ratio levels (INR) of 1.4 and recent modification of anticoagulant therapy, the diagnosis of thrombosis was established. A fibrinolytic agent was administered with an improvement in dyspnea. However, the gradient across the valve remained pathologically elevated, raising suspicion that the patient also suffered from chronic pannus. This chronic pannus may have contributed to a sub-acute thrombosis, exacerbating the stenosis. The only definitive approach was surgical intervention, treating also the severe aortic stenosis, with a replacement of the two valves. A pre-operative coronary angiography was performed, which showed the presence of some stenosis in the blood vessels, for which medical therapy was recommended. Additionally, a valve fluoroscopy was conducted, revealing an emiblocked mitralic disk. Subsequently, the patient underwent surgery; however a complication occurred involving a rupture of the aorta, leding to the death of the patient.

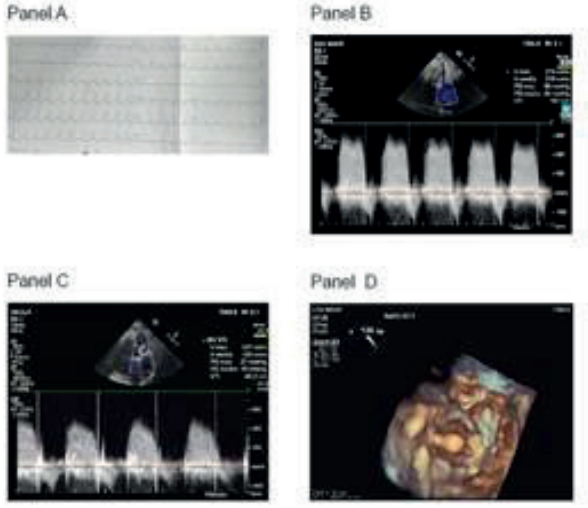

A1042: BIOPROSTHETIC TRICUSPID VALVE DYSFUNCTION TREATED WITH PERCUTANEOUS VALVE-IN-VALVE IMPLANTATION

Andrea Pezzato (a), Enrico Fabris (b), Giancarlo Vitrella (b), Serena Rakar (b), Andrea Perkan (b), Enzo Mazzaro (c), Gianfranco Sinagra (b)
(a) POSTGRADUATE SCHOOL OF CARDIOVASCULAR MEDICINE UNIVERSITY OF TRIESTE; (b) AZIENDA SANITARIA UNIVERSITARIA GIULIANO-ISONTINA - DIVISION OF CARDIOLOGY; (c) AZIENDA SANITARIA UNIVERSITARIA GIULIANO-ISONTINA - DIVISION OF CARDIAC SURGERY

A 49 year-old-man, with hypertension and former smoker, presented at the cardiological outpatient clinic with worsening dyspnea, and functional NYHA class 3. He had a history of tricuspid valve replacement at the age of 40 with a bioprosthesis (Hancock II 31 mm) due to post-traumatic tricuspid regurgitation due to car accident and polytrauma, which included several bone fractures, and pleuro-pericardial effusion. Replacement of the tricuspid valve with a bioprosthesis was decided after several unsuccessful attempts to repair the valve. Cardiological follow up was regular, moderate bioprosthesis regurgitation was present at the age of 48. In the subsequent year the patient started to be clinical symptomatic for worsening dyspnea and the echocardiogram showed a normal dimension and function of left ventricle and left sided valves, but highlighted a right ventricular dilatation and dysfunction (RVFAC 32%, TAPSE 10mm) and tricuspid prosthesis dysfunction with a severely increased gradient (14/10 mmHg) and severe regurgitation, with an estimated systolic pulmonary artery pressure of 32 mmHg. Right heart catheterisation was performed and demonstrated normal pulmonary vascular pressures and resistances, elevated right atrial pressure, normal left filling pressures and a reduced cardiac index (Fick 1.97 l/min/m2). He repeated coronary angiography which showed no significant coronary artery disease. The Heart Team, in consideration of the young age, decided for the elective percutaneous valve-in-valve implantation, as bridge for a possible future cardiac re-intervention. The procedure was performed in in general anaesthesia because transesophageal echocardiography was used as a complementary imaging guidance and with an ECMO-VA stand-by. A 16F guiding catheter was placed in the right femoral venous artery. The Swan-Ganz catheter was advanced in the pulmonary artery, then Amplatz super stiff guide was placed in the left pulmonary artery. The Edwards Sapien 3 29 mm bioprosthesis was implanted inside the degenerated tricuspid bioprosthesis without rapid pacing, with a good final result, and absence of leak or residual gradient. The patients was discharged after 6 days. At 1-month the patients was in NYHA I and echocardiogram showed a mild ventricular dilatation with normal function, tricuspid prosthesis without regurgitation and a mild gradient (5/3 mmHg). In the literature there are only few case series and small registries describing this kind or procedure. The populations described in literature show that tricuspid valve-in-valve percutaneous implantation can be considered safe and as in our case an emerging alternative technique for the treatment of tricuspid bioprosthesis valve degeneration.

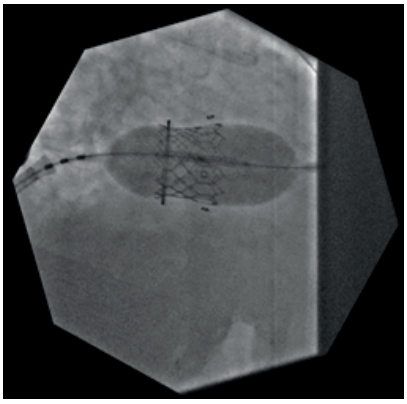

A1043: TRANSCATETHER VALVE REPLACEMENT IN THE MANAGEMENT OF CARCINOID HEART DISEASE: A CASE REPORT

Michele Morosato (a, d), Carlo Gaspardone (b, d), Andrea Tripoli (b, d), Lorenzo Zaccaria (b, d), Daniele D´atri (b, d), Gianluca Ricchetti (a, d), Sara Dormio (a, d), Paolo Denti (c), Francesco Maisano (c, d), Anna Salerno (b), Alberto Margonato (b, d), Cosmo Godino (b)
(a) CARDIOTHORACIC DEPARTMENT, IRCCS SAN RAFFAELE SCIENTIFIC INSTITUTE, MILAN, ITALY; (b) CARDIOLOGY UNIT. IRCCS SAN RAFFAELE SCIENTIFIC INSTITUTE, MILAN, ITALY; (c) CARDIAC SURGERY UNIT, IRCCS SAN RAFFAELE SCIENTIFIC INSTITUTE, MILAN, ITALY; (d) VITA-SALUTE SAN RAFFAELE UNIVERSITY, MILAN, ITALY

Introduction. Carcinoid syndrome is a rare clinical entity, encountered in less than 20% of patients with neuroendocrine tumors (NETs), chiefly originating from intestinal NETs with liver metastases. A significant cardiovascular manifestation in up to 60% of these cases is Carcinoid Heart Disease (CHD). Predominantly affecting the right-sided cardiac valves, CHD is largely mediated by tumor-secreted serotonin. Although surgical treatment is the standard approach for severe valvular dysfunction in CHD, it is associated with high morbidity and mortality. In this context, transcatheter approaches to CHD represent a promising alternative for high-risk surgical candidates.

Case report. A 76-year-old male with no previous cardiovascular history presented to the ED with steatorrhea. Subsequent diagnostic investigations revealed a 21 mm hypervascularized pancreatic nodule and multiple secondary hepatic lesions, the largest measuring 81 mm. Biopsy confirmed a pancreatic G2 NET with liver metastases. The patient was initiated on symptomatic therapy (Lanreotide) and chemotherapy (Capecitabine and Temozolomide) with a cytoreductive intent, pending

surgical intervention. He subsequently developed exertional dyspnea. Diagnostic tests, including transthoracic echocardiography (TTE) and cardiac magnetic resonance (CMR), revealed mild left ventricular dysfunction (LV ejection fraction 45%), severe pulmonary and tricuspid regurgitation, and a dilated yet functionally normal right ventricle. Coronary angiography identified critical left anterior descending (LAD) artery stenosis, subsequently managed with drug-eluting stent (DES) implantation. Right heart catheterization (RHC) exhibited normal pulmonary arterial pressures and vascular resistance. Given the patient's high surgical risk (TRI-SCORE 7, predicted operative mortality 34%) and the favorable prognosis of pancreatic NETs following cytoreductive surgery, the Multidisciplinary Meeting recommended a transcatheter approach. The patient underwent successful Transcatheter Pulmonary Valve Implantation (TPVI) using a Venus P-Valve 32-25 mm, with no evidence of paravalvular leak. He was later discharged and has since undergone hepatic ablation and further cytoreductive surgery. Currently, he is being screened for Transcatheter Tricuspid Valve Implantation (TTVI) using the Cardiovalve system, being excluded from transcatheter edge-to-edge treatment due to unfavorable anatomy.
Conclusions. The case highlights feasibility of transcatheter interventions in managing severe valvular dysfunctions in CHD, particularly for patients at high surgical risk. It also underscores the importance of a multidisciplinary approach for comprehensive patient care. Further studies are required to establish long-term outcomes and optimal strategies for these patients.

A1044: BENEFICI DELLA MITRACLIP NELLO SCOMPENSO CARDIACO ACUTO POST ISCHEMICO

Gennaro Galasso (a), Carmine Vecchione (a), Michele Ciccarelli (a), Emilio Di Lorenzo (b), Francesca Lanni (b), Fiore Manganelli (b), Michele Tedeschi (a), Debora D´elia (a)
(a) UNIVERSITÀ DEGLI STUDI DI SALERNO; (b) A.O.R.N. MOSCATI

Uomo di 75 aa giungeva nel pronto soccorso della nostra AORN per angina pectoris e sudorazione profusa.
In anamnesi patologica remota ipertensione arteriosa in trattamento farmacologico, tabagismo ed eccesso ponderale. Il paziente si presentava dispnoico, si riscontravano crepitii basali bilaterali ed edemi improntabili agli arti inferiori. I parametri vitali rilevati al primo contatto erano i seguenti: PA 140/90 mmHg, FC 115 bpm, SpO2 95% (in Maschera di Venturi al 60%). Al tracciato ECG grafico si poneva diagnosi di SCA-STEMI con immediato trasporto in sala di emodinamica, dove eseguiva angioplastica primaria con impianto di 2 DES su ramo Circonflesso. L'ecocardiogramma mostrava severa disfunzione sistolica del ventricolo sinistro (FE 35%) per acinesia delle pareti antero-laterale, inferiore medio-apicale e postero-laterale. Si rilevava inoltre una insufficienza mitralica di grado moderato. Nei giorni seguenti sviluppava un quadro di scompenso cardiaco nonostante ottimizzazione della terapia medica: al torace si evidenziava graduale ipofonesi dei campi polmonari basali bilaterali con crepitazioni, all'RX torace si osservavano linee B diffuse con versamento pleurico medio basale sinistro e basale destro. Agli esami ematochimici si rilevava un progressivo peggioramento della funzionalità renale. Considerato il quadro clinico, alla luce della sovrapponbilità ecocardiografica transtoracica, si praticava ecocardiografia transesofagea per una più accurata definizione del vizio valvolare mitralico, con il seguente referto: Cinetica invariata rispetto al precedente controllo transtoracico; insufficienza mitralica di grado severo (EROA 0,48 cmq, Vol Rig 54 ml) con jet predominante centro-laterale da tethering prevalente del lembo posteriore (lunghezza LPM 11 mm, coaptation depth 13 mm). In accordo con i risultati ricavati dal registro IREMMI, il nostro paziente veniva considerato candidabile all'intervento di MitraClip per correzione del vizio valvolare acuto. Il percorso terapeutico si concludeva con successivo impianto di ICD. Il paziente veniva dimesso, asintomatico per dispnea e con un quadro clinico generale in sostanziale risoluzione. Recenti trials dimostrano come la MitraClip sia una valida alternativa all'intervento chirurgico in pazienti critici con insufficienza mitralica di grado severo cronica post ischemica. Il registro IREMMI arruola pazienti con insorgenza acuta di insufficienza mitralica di grado severo in seguito a sindrome coronarica acuta, e documenta come l'intervento precoce di correzione con dispositivo MitraClip sia egualmente sicuro ed efficace.

A1045: PROLASSO VALVOLARE MITRALICO E RISCHIO DI MORTE CARDIACA IMPROVVISA IN PAZIENTE CON ARITMIE VENTRICOLARI: IL RUOLO PROGNOSTICO DELLA RISONANZA MAGNETICA CARDIACA

Tiziano Maria Mazza (a), Alessandra D´ambrosi (a), Paolo Trambaiolo (a), Silvio Romano (b), Antonino Granatelli (a)
(a) UOS TERAPIA INTENSIVA CARDIOLOGICA, UOC CARDIOLOGIA, PO SANDRO PERTINI, ROMA; (b) CATTEDRA DI CARDIOLOGIA, UNIVERSITÀ DELL'AQUILA, L'AQUILA

Introduzione. Il prolasso valvolare mitralico rappresenta nella maggior parte dei casi una condizione benigna, tuttavia nel 2% dei casi è stata associata a rischio di morte cardiaca improvvisa (MCI). Basso et al hanno evidenziato in pazienti deceduti per MCI con prolasso della mitrale fibrosi del muscolo papillare e della parete infero-laterale del ventricolo sinistro alla Risonanza Magnetica Cardiaca.
Caso clinico. Paziente di 59 anni, ricoverato presso la Cardiologia dell'Ospedale Pertini per episodi vertiginosi ed episodi di tachicardia ventricolare non sostenuta in due morfologie al monitoraggio ECG delle 24 ore. Anamnesi negativa per fattori di rischio cardiovascolari con evidenza all'ecocardiogramma di rigurgito valvolare mitralico moderato secondario a prolasso valvolare con disgiunzione anulo-mitralica (MAD) (Fig.1). Considerata l'età del paziente associata alla bassa probabilità pre-test di malattia coronarica, il paziente è stato sottoposto a TC coronarica che evidenziava un albero coronarico indenne da lesioni. La Risonanza Magnetica Cardiaca mostrava un ventricolo sinistro di volumi aumentati e funzione sistolica lievemente ridotta, prolasso valvolare di entrambi i lembi mitralici condizionante rigurgito moderato e con Late Gadolinium Enhancement (LGE) intra-miocardico a carico della parete inferiore ed infero-laterale con estensione alla porzione prossimale del muscolo papillare inferiore compatibile con la presenza di fibrosi (Fig.2). Alla luce di tali rilievi per una valutazione del burden aritmico si è proceduto ad effettuare studio elettrofisiologico (SEF) endocavitario che con un doppio extra-stimolo dal tratto di efflusso del ventricolo destro ha indotto una tachicardia ventricolare polimorfa a partenza dal muscolo papillare inferiore, degenerata in fibrillazione ventricolare.
Discussione. In considerazione di tutti i suddetti reperti, si è posta diagnosi di prolasso valvolare mitralico ad alto rischio di aritmie maligne e si è deciso per l'impianto di defibrillatore cardiaco sottocutaneo.
Conclusioni. Ad oggi non esiste una stratificazione del rischio aritmico condivisa, né linee guida specifiche. È fondamentale, dunque, un approccio strutturato allo screening e alla diagnosi con l'identificazione di caratteristiche che identificano un profilo di pazienti con aumentato rischio. Tra tutte, la caratterizzazione tissutale alla RMC (LGE a livello dei muscoli papillari, parete postero-laterale basale) riveste un ruolo fondamentale nella stratificazione prognostica per l'impianto di defibrillatore in prevenzione primaria.

Fig.1: ecocardiogramma TT che mostra PVM con MAD

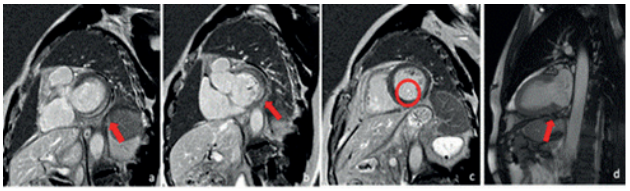

Fig. 2: RM cardiaca con late-enhancement della parete infero-laterale (a-b) e del muscolo papillare (c) ed evidenza di disgiunzione anulare mitralica (MAD) (d).

A1046: TRICUSPID ENDOCARDITIS: A COMPLEX CASE IN A YOUNG DRUG-ADDICT PATIENT

Sara Sfredda (a), Umberto Ianni (b), Michela Molisana (b), Vito Maurizio Parato (b), Federico Guerra (a), Antonio Dello Russo (a)
(a) OSPEDALI RIIUNITI TORRETTE DI ANCONA; (b) OSPEDALE MADONNA DEL SOCCORSO SAN BENEDETTO

Introduction. Infective endocarditis of the tricuspid valve presents a challenge in terms of management and treatment, as the primary individuals involved are intravenous drug users with a consequent higher risk of recurrences and complications.
Clinical case. A young 33-year-old patient arrived at the emergency room with an acute onset of dyspnea and chest pain associated with diffuse arthromyalgia. He also reported recent intravenous cocaine use in the right upper limb. Initially, a typical pneumonia was suspected since the initial cardiac evaluation excluded signs of infective endocarditis. However, the respiratory condition worsened, leading to the discovery of septic pulmonary embolization and small filling defects in segmental and sub-segmental pulmonary arteries bilaterally on chest CT angiography. Staphylococcus aureus MSSA was isolated from blood cultures, prompting targeted antibiotic therapy and a transesophageal echocardiogram in persistent suspicion of infective endocarditis. The examination confirmed the diagnosis by detecting a large vegetation attached to the anterior leaflet of the tricuspid valve, measuring approximately 5 cm x 2 cm. Cardiac surgery was initially considered as a postponable option but became essential due to the development of massive tricuspid regurgitation caused by perforation of the anterior leaflet, with signs of isolated right heart failure. However, there was no longer evidence of

the previously reported valve vegetation. Valve repair surgery was performed without complications, and the patient subsequently regained complete functional capacity.
Conclusions. Infective endocarditis of the right heart is less common than that of the left heart and is strongly associated with intravenous drug use. The most commonly affected valve is the tricuspid, with Staphylococcus aureus being the primary implicated microorganism. In the majority of cases, therapy is medical, with surgery reserved for a minority of patients (according to ESC guidelines, patients with persistent bacteremia despite antibiotic therapy, vegetations>20 mm following recurrent septic pulmonary embolisms, and right heart failure secondary to severe tricuspid insufficiency). In any case, valve repair is always preferred when possible. As in our case, there is often hesitation in operating on drug-addict patients with tricuspid infective endocarditis. However, a careful case evaluation is necessary, and establishing the correct timing for intervention is crucial to avoid the development of complications that could pose greater risks to the patient.

A1047: UN CASO CLINICO DI CALCIFICAZIONE CASEOSA DELL'ANNULUS MITRALICO: QUANDO PORRE INDICAZIONE ALL'INTERVENTO CHIRURGICO?

Alessio Falagario (a), Caterina Colucci (a), Sergio Maria Caparrotti (b), Massimo Gagliardi (b), Marco Matteo Ciccone (a)
(a) UNIVERSITÀ DEGLI STUDI DI BARI; (b) MATER DEI HOSPITAL, BARI

Introduzione. La calcificazione dell'annulus mitralico è una condizione degenerativa della valvola mitrale relativamente comune. Una sua rara variante è la calcificazione caseosa dell'annulus (caseous calcification of the mitral annulus, CCMA), tipicamente localizzata nella sua porzione posteriore. Sebbene sia di natura benigna e di riscontro occasionale, essa può determinare disturbi di conduzione del ritmo cardiaco o embolizzazione periferica di frammenti di materiale caseoso. Pertanto, dal punto di vista terapeutico, non c'è alcuna chiara evidenza di quale sia la migliore strategia da seguire.
Caso clinico. Una donna di anni 64, ipertesa, diabetica, dislipidemica, mono-rene e con storia di tubercolosi miliare in età giovanile, giungeva presso il Pronto Soccorso per la comparsa di epigastralgia, vomito e improvvisa riduzione del visus sinistro. Negative le valutazioni neurologiche e oftalmologiche, si riscontrava un incremento marcato degli enzimi di miocardionecrosi mentre l'ECG non mostrava alterazioni significative. All'ecocardiogramma transtoracico si evidenziava una voluminosa massa iper-ecogena localizzata a livello dell'annulus mitralico posteriore. L'ecocardiogramma trans-esofageo e la TC-torace confermavano la presenza di tale formazione di 27 x 23 mm, dall'aspetto disomogeneo, su tutto l'annulus posteriore e coinvolgente il lembo posteriore della mitrale. Il quadro era compatibile con quello di una estesa CCMA, determinante rigurgito mitralico di grado severo con jet prevalentemente eccentrico diretto verso il setto inter-atriale. Pertanto, la paziente è stata sottoposta ad intervento di esposizione della mitrale tramite atriotomia sinistra che ha evidenziato assenza di soluzione di continuità tra annulus posteriore e lembo valvolare posteriore con sospetto rigonfiamento dell'area stessa. La sua incisione ha portato a fuoriuscita di notevole quantità di materiale caseoso. Per obliterare la cavità residua e per conservare la continuità anulo-papillare, si è proceduto dapprima alla ricostruzione della zona con patch di pericardio e, successivamente, all'impianto di una protesi mitralica biologica di diametro adeguato. Nel decorso post-operatorio non sono state registrate complicanze. L'esito bioptico ha documentato la presenza di materiale necrotico e di infiltrati infiammatori con tendenza alla formazione di granulomi. Le colture per la ricerca di batteri e miceti sono risultate negative.
Discussione. La CCMA è più frequentemente riscontrabile nelle donne anziane, ipertese, con insufficienza renale cronica o alterata omeostasi calcio-fosforo. Tuttavia, la sua precisa eziopatogenesi è ancora dibattuta. Attualmente, non esiste alcuna raccomandazione specifica sulla sua gestione terapeutica. Sebbene tecnicamente complesso, l'intervento chirurgico risulta necessario in presenza di severa disfunzione valvolare e sintomi di cardio-embolia.
Conclusioni. Il progressivo perfezionamento delle tecniche di imaging sta agevolando l'identificazione ed una precisa definizione morfologica della CCMA, fondamentale per la pianificazione dell'intervento chirurgico di tali lesioni. La chirurgia costituisce ancora oggi l'unico presidio terapeutico efficace in questi casi, ma ulteriori evidenze scientifiche sono necessarie per una precisa selezione dei pazienti con CCMA che potrebbero beneficiarne.

A1048: ACUTE PULMONARY EDEMA DURING HYSTEROSCOPY IN A YOUNG WOMAN-A FIRST TIME PRESENTATION OF SEVERE MITRAL STENOSIS-A CASE REPORT

Marialucia Milite (a, b), Alessandro Santoro (b), Francesco Melillo (b), Dimitris Christodoulakis (b), Gaetano De Fazio (b), Concettina Iuliano (b), Valerio Scala (b), Luigi Zarrella (b), Giuseppe Gallo (b), Luigi Salemme (b), Tullio Tesorio (b), Francesco Barillà (a)
(a) UNIVERSITÀ DEGLI STUDI DI ROMA TOR VERGATA; (b) CLINICA MONTEVERGINE, MERCOGLIANO (AV)

We report a rare case of severe mitral stenosis that presented with severe hypoxia and acute pulmonary edema in a young woman during a hysteroscopy procedure. A 29-year-old, Caucasian woman, normal social class, without any previous cardiac history or any cardiovascular risk factors, developed severe hypoxia and rapid pulmonary edema during a hysteroscopy. She was admitted to our intensive care unit in a certain scenario of acute pulmonary edema with dyspnea, respiratory failure, at the blood gas analysis hypoxaemia-hypercapnia with an oxygen saturation of 89%, tachypnoea with>25 breaths/min. The echocardiography exam showed a preserved LVEF but a severe mitral stenosis, unknown so far. She was managed with oxygen, with continuous positive airway pressure, non-invasive positive-pressure-ventilation and with i.v. diuretics to reduce pulmonary congestion. She was discharged from the intensive care unit after resolution of clinical and instrumental scenario. We performed a close follow-up at 2 and 4 weeks, during which the patient reported repeated episodes of pharyngo-tonsillitis in childhood and complained of dyspnea for mild exertion. Therefore we performed a transesophageal echocardiogram to study the mitral stenosis (MVA 1.1 cm2, transvalvular mean gradient 14 mmHg, Wilkins' Score <8). Considering the patient's symptoms, the stenosis' severity, the presence of mild associated mitral insufficiency and the anatomical and morphological characteristics of the valve, a percutaneous mitral valvuloplasty procedure was performed, achieving an obtimal echocardiographic result and clinical benefit both acutely and at follow-ups at 2 - 4 and 6 weeks. Rheumatic fever is the most common cause of mitral stenosis worldwide. Its prevalence has greatly decreased in industrialized countries, but it remains a significant healthcare problem in developing countries and affects young patients. In developing countries, rheumatic heart disease remains the leading cause of valvular heart disease with a prevalence between 20 and 30 cases per 1000 subjects. The patients become symptomatic ≥20 years after rheumatic fever, more often in female subjects, with a scenario of congestive cardiac failure. Non-surgical balloon mitral valvuloplasty for mitral stenosis has been initiated. We want to report this clinical case due to the now rare finding of mitral stenosis of rheumatic origin in industrialized countries, infact the mitral stenosis is the rarest of valve pathologies in our country.

A1049: HEMOPTYSIS AS A RED FLAG OF A DOUBLE VALVULAR VICE: A CASE REPORT

Mariagrazia Piscione (a), Andrea Segreti (a), Dajana Polito (a), Vincenzo Nafisio (a), Francesca Vespasiano (a), Valeria Maria De Luca (a), Mihail Celeski (a), Gian Paolo Ussia (a), Francesco Grigioni (a)
(a) FONDAZIONE POLICLINICO UNIVERSITARIO CAMPUS BIOMEDICO

We describe the case of an 81-year-old man with a history of dyslipidemia and a past smoking habit presented with recurrent episodes of hemoptysis, previously investigated with chest tomography (CT) and fibrobronchoscopies which resulted negative for infective, inflammatory, and autoimmune disorders. The patient had a prior history of acute articular rheumatism in 1959. The transthoracic echocardiogram, done twenty years before, revealed a moderate-severe aortic regurgitation. Hospitalization in the Department of Cardiology was arranged. Severe aortic valve steno-regurgitation and moderate mitral valve stenosis without pulmonary hypertension were confirmed. Based on guidelines, the patient underwent aortic valve replacement and mitral valve repair, resulting in the cessation of hemoptysis, indicating a cardiac origin of the bleeding. To summarize, the mitralic valvular vice has caused loci minoris resistentiae due to the aneurysm formation of bronchial vessels or bronchial varices. Still, the aortic stenosis itself has been responsible for angiodysplasia, probably due to poor blood perfusion, decreased pulse pressure, and a drop in HMW multimers (acquired vW disease). However, what is sure is that correcting valve abnormalities has led to a complete resolution of pulmonary bleeding.

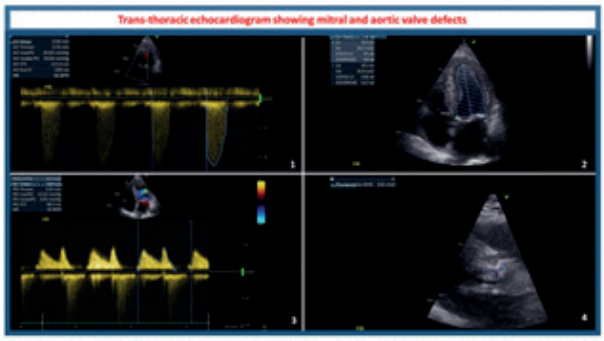

Figure 1: 1.1 - Trans-thoracic echocardiogram showing severe aortic valve stenosis (AV Vmax 4.58 m/sec, AV meanPG 59.60 mmHg, AV VTI 127.4 cm); **1.2** - Left ventricular preserved global and segmental ejection fraction (calculated 65%); **1.3** - Trans-thoracic echocardiogram showing mild-moderate mitral valve stenosis (MVA VTI 0.7 cm^2, MV meanPG 4.93 mmHg, MV VTI 68.7 cm); **1.4** – Evidence of severe aortic valve stenosis (AVA 0.6 cm^2).
Abbreviations: AV: aortic valve; **Vmax:** maximum velocity; **PG:** pressure gradient; **VTI:** velocity time integral; **MVA:** mitral valve area; **AVA:** aortic valve area.

A1050: ENDOCARDITE INFETTIVA. QUELLO CHE LE LINEE GUIDA NON DICONO

Donatella Tansella (a), Marta Possamai (b)
(a) UNIVERSITÀ DEGLI STUDI DI PADOVA; (b) OSPEDALE CA' FONCELLO - TREVISO

L'endocardite infettiva è una patologia con elevato tasso di mortalità intraospedaliera. I pazienti con complicanze neurologiche hanno peggior outcome clinico. Una delle complicanze più temute è rappresentata dall'emorragia intracranica (5%); la causa principale è rappresentata dalla rottura di aneurismi micotici. Le scelte terapeutiche in questi pazienti sono estremamente delicate e vanno discusse caso per caso. Uomo di 60 anni veniva ricoverato per febbre e dolore lombare ingravescente. Non precedenti cardiologici, potus attivo. Isolamento alle emocolture di Streptococcus Salivarius, negati interventi odontoiatrici. Alla RMN del rachide lombare riscontro di spondilodiscite L2-L3, all'ecocardiogramma evidenza di endocardite su valvola aortica con perforazione e rottura della cuspide non coronarica con insufficienza di grado severo, massa di dimensioni 16x20 mm sul lembo anteriore mitralico con perforazione e aneurisma del lembo determinante insufficienza di grado severo. Veniva impostata terapia antibiotica con Ampicillina e Vancomicina. Alla TC encefalo, evidenza di multiple alterazioni emorragiche pseudo-nodulari e modica quota emorragica subaracnoidea in quadro compatibile con embolizzazione settica. All'angiografia evidenza di aneurisma micotico alla biforcazione tra arteria pericallosa e calloso-marginale di sinistra con aspetto arteritico delle arterie omonime, non aggredibile dal punto di vista endovascolare. Presenza inoltre di embolizzazioni settiche ischemiche a carico della milza e soffusione flogistica dell'arteria mesenterica inferiore. Il caso veniva condiviso con i colleghi Cardiochirurghi e, alla luce delle multiple lesioni cerebrali con infarcimento emorragico e dell'aneurisma micotico si differiva l'intervento considerato l'elevatissimo rischio emorragico. Dopo qualche giorno, in pieno benessere soggettivo, improvvisa perdita di coscienza, iperdiaforesi, respiro periodico, pupille miotiche e areagenti. Si eseguiva angioTC cerebrale che documentava: vasta emorragia subaracnoidea in sede silviana bilaterale e tra i lobi frontali e marcato incremento delle dimensioni del noto aneurisma. Il caso veniva nuovamente discusso collegialmente e si escludeva il paziente da qualsiasi opzione chirurgica alla luce dell'elevato rischio di complicanze procedurali. Se ne constatava il decesso dopo due giorni. La terapia dell'endocardite infettiva è basata sull'antibiotico-terapia e sulla chirurgia cardiaca. Il corretto timing per la chirurgia deve tener conto del rischio di emorragia intracranica, a causa dell'inevitabile uso di alte dosi di anticoagulante per la circolazione extracorporea e della necessità di prevenire ulteriori embolismi sistemici ed episodi di scompenso cardiaco. Per questo nei pazienti con embolismo cerebrale di solito, la chirurgia è rimandata, proprio come nel caso proposto. Scegliere il giusto timing è piuttosto complicato e deve essere valutato caso per caso.

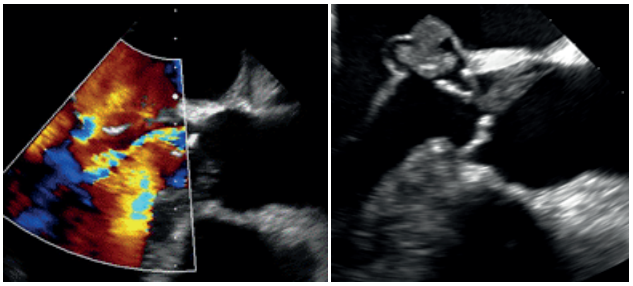

A1051: AORTIC STENOSIS, HEART FAILURE WITH MID-RANGE EJECTION FRACTION AND IRON DEFICIENCY ANEMIA: THE DANGEROUS RELATIONSHIPS

Fulvio Cacciapuoti (a), Rodolfo Nasti (b), Carlo Liguori (c), Loredana Pica (d), Savio Saviano (d), Ciro Mauro (a), Federico Cacciapuoti (e)
(a) DEPARTMENT OF CARDIOLOGY "A. CARDARELLI" HOSPITAL - NAPLES, ITALY; (b) DEPARTMENT OF EMERGENCY MEDICINE "SAN PIO" HOSPITAL - BENEVENTO, ITALY; (c) DEPARTMENT OF RADIOLOGY "OSPEDALE DEL MARE" HOSPITAL - NAPLES, ITALY; (d) DEPARTMENT OF GASTROENTEROLOGY "A. CARDARELLI" HOSPITAL - NAPLES, ITALY; (e) CHAIR OF INTERNAL MEDICINE "L. VANVITELLI" UNIVERSITY - NAPLES, ITALY

Due to the increase in average life expectancy in industrialized countries, the incidence of calcific degeneration of the aortic valve is constantly increasing, reaching a prevalence of 3.4% of severe aortic stenosis, especially in elderly patients (over 75 years of age). Among the most disabling clinical elements of this form of valvulopathy are chest pain, fatigue, and dyspnea, which can progress to heart failure and pulmonary edema. In some cases, acquired coagulation disorders worsen the symptoms and disease progression, caused by a functional alteration of von Willebrand factor, leading to progressive anemia. Colonic angiodysplasia is a degenerative vascular malformation of the gastrointestinal tract, mainly related to aging, primarily occurring in the right colon. It is characterized by fragile and leaking blood vessels and ranks as the second most common cause of lower gastrointestinal tract bleeding in patients over 60 years of age, resulting in iron deficiency anemia with a prevalence of more than 60%. Heyde syndrome is characterized by the coexistence of severe aortic stenosis, angiodysplasia of the colon, and gastrointestinal bleeding, which can contribute to iron deficiency anemia in the long term, negatively impacting left ventricular compliance. The pathophysiological basis of gastrointestinal bleeding is an acquired von Willebrand syndrome, caused by the passage of von Willebrand factor through the stenotic aortic valve, altering its conformation and rendering it ineffective in maintaining coagulative homeostasis. Anemia, coupled with the obstruction of left ventricular outflow caused by aortic stenosis, can lead to a progressive deterioration in systolic function, ultimately resulting in heart failure and pulmonary edema. Since Heyde syndrome is a progressive disease, early diagnosis and treatment are essential to reduce morbidity, hospitalizations, and mortality. We discuss the diagnostic usefulness of the RiCOF/Ag ratio for the qualitative assessment of vWF instead of the analysis of vWF multimers since it is not standardized and requires specialized equipment. The correction of the aortic valve defect allowed the qualitative normalization of circulating von Willebrand factor, rebalanced hemostasis, and restored normal blood flow through the left ventricular outflow channel, resulting in improved ventricular compliance.

A1052: MULTI-MODALITY IMAGING ASSESSMENT OF MITRAL AND TRICUSPID VALVE DISEASE IN ATHLETES

Mihail Celeski (a), Andrea Segreti (a), Luigi Maria Monticelli (a), Alfonso Perillo (a), Simone Pasquale Crispino (a), Valeria Cammalleri (a), Simona Mega (a), Giuseppe Di Gioia (a, b, c), Chiara Fossati (b), Fabio Pigozzi (b), Rocco Papalia (d), Gian Paolo Ussia (a), Francesco Grigioni (a)
(a) UNIT OF CARDIOVASCULAR SCIENCE, FONDAZIONE POLICLINICO UNIVERSITARIO CAMPUS BIO-MEDICO, ROMA; (b) DEPARTMENT OF MOVEMENT, HUMAN AND HEALTH SCIENCES, UNIVERSITY OF ROME FORO ITALICO; (c) INSTITUTE OF SPORTS MEDICINE, SPORT AND HEALTH, NATIONAL ITALIAN OLYMPIC COMMITTEE, ROME; (d) RESEARCH UNIT OF ORTHOPAEDIC AND TRAUMA SURGERY, FONDAZIONE POLICLINICO UNIVERSITARIO CAMPUS BIO-MEDICO, ROMA

Vigorous training in competitive athletes leads to a constellation of structural and functional adaptations involving cardiac chambers and atrioventricular valve systems. A proper evaluation of athlete with valve disease is necessary to evaluate the eligibility for competitive sports and identify those requiring more follow-up. Indeed, some valve pathologies are associated with an increased risk of severe arrhythmias and potentially sudden cardiac death. Traditional and advanced imaging modalities help clarify clinical doubts, allowing essential information about the athlete's physiology and differentiating between primary valve diseases from those secondary to training-related cardiac adaptations. Multimodality imaging helps evaluate athletes with valve diseases during exercise to reproduce the sport setting and better characterize the etiology and valve defect mechanism. Elite athletes have a significant dilatation of the mitral (MA) and tricuspid annulus (TA) dimensions and an increase in the tenting of both atrioventricular valves compared to non-athlete counterparts, indicating that atrioventricular annuli undergo disproportionate remodeling in response to regular training. Indeed, through a combination of annulus enlargement and tethering of the valve leaflets, functional regurgitation of the mitral valve (MV) or tricuspid valve (TV) has been primarily linked to left ventricle (LV) and right ventricle (RV) remodeling, respectively. Hence, a mixed form (atrial and ventricular) of functional regurgitation might be assumed in athletes with mitral (MR) or tricuspid regurgitation (TR). Athletes with MR have a higher MA and TA and a more pronounced saddle shape of the MA than those without MR. A broad spectrum of imaging modalities is available to evaluate the athletes, measure and quantify atrioventricular valve diseases differentiating between athletic and non-athletic populations and allow clinicians to adopt a step-by-step and comprehensive approach. Trans-thoracic echocardiography can provide complementary information on cardiac morphology, functional properties using strain techniques, as well as comprehensive evaluation of the sub-valvular complex, severity of valve disfunction, pulmonary artery pressure, and other hemodynamic consequences. 3D echocardiography enhances the diagnostic power of cardiac ultrasound in athletes as it allows precise measuring of MV and TV area, TR severity according to new grading scheme, and chamber volumes. Moreover, exercise stress echocardiography plays crucial role by helping to uncover latent symptoms, discover inducible ischemia, measure contractile reserve, evaluate for latent or progressive valve dysfunction, and assess eligibility for competitive sports in athletes with valve disease. Nowadays, discordance revealed using strain techniques are overcome thanks to new, less load-dependent methods such as myocardial work (MW) assessment obtained non-invasively through LV pressure-strain loop analysis. MW indices help evaluate myocardial contraction, arrhythmic MV prolapse, RV function in TR and add essential information to differentiate between physiological remodeling or pathological remodeling, for example, due to valve regurgitation. Furthermore, while cardiac computed tomography is more frequently applied to athletes at

risk for sudden cardiac death, cardiac magnetic resonance is an essential tool that provides precious information evaluating myocardial morphology and functioning, wall motion, fibrosis, atrio-ventricular valve stenosis and regurgitation and by tissue characterization. Correctly identifying those athletes requiring treatment is a necessary step contributing to safer sports participation.

A1053: LIFE-TIME MANAGEMENT OF REPEATED AORTIC VALVE PROCEDURES IN THE YOUNG: THE KEY ROLE OF TAVI, PLANNING AND PATIENT-CENTERED CARE

Nicola Buzzatti (a), Paolo Denti (a), Matteo Saccocci (a), Pamela Gatto (a), Cosmo Godino (a), Eustachio Agricola (a), Antonio Esposito (a), Francesco Maisano (a)
(a) DIPARTIMENTO DI CARDIOCHIRURGIA, VALVE CENTER OSPEDALE SAN RAFFAELE, MILANO

We report a case of a young and obese patient who developed severe aortic regurgitation after an intervention of replacement of the aortic root and ascending aorta with reimplantation of the native aortic valve and coronary arteries (David II procedure), efficaciously treated with transcatheter aortic valve implantation (TAVI).